



Radiology
Team 438



Radiological anatomy of cardiorespiratory

Lecture 3

Objectives

- Technique
 - Learn the difference between PA vs. AP CXR
 - Learn the utility of a lateral decubitus CXR
 - Understand the terms inspiration, penetration, and rotation as they apply to determining a technically adequate film
- Anatomy
 - Learn the basic anatomy of the fissures of the lungs, heart borders, bronchi, and vasculature that can be seen on a chest x-ray
- Interpretation
 - Develop a consistent and thorough technique for reading images
 - Learn how the silhouette sign can help localize pathology
- Pathology

Color Index:

Main text Males slides Female slides Dr's notes Important Golden note Extra

Team Leaders:



Rahaf Almotairi



Mayssam Aljaloud



Sultan Alshehri

Done by:



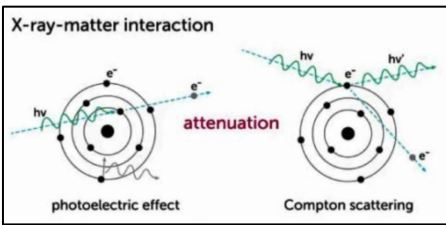
Alhnouf Alyami



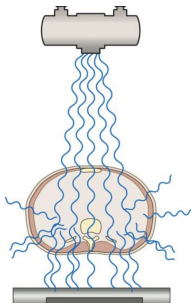
Mohammed Alzeer

Editing File

» How x-ray works ?



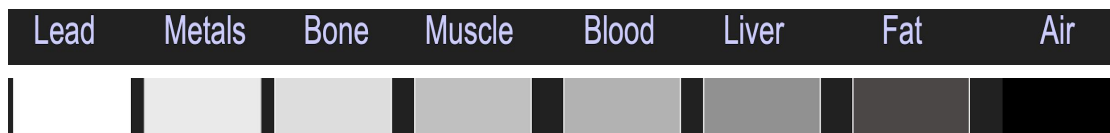Ionizing radiation



- X-ray is high energy photons, once it hits the body it'll interact with soft tissues through physical effect called photoelectric effect
- The atoms absorbs the X-ray energy and get excited
- In general, some X-rays will:
 - pass through in order to make an image
 - will absorbed inside the atoms and then get different shadows (black, white or gray)

» What determines black, gray, white?

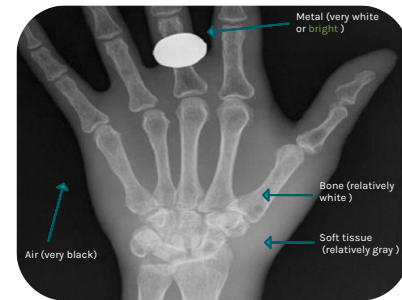
Atomic # n and path length



WHITE:
Radiopaque;
"More", Like Metal
High atomic #





BLACK:
Radiolucent; "Less",
Like Air
Low atomic #



- Metal is very high dense compact material, if you hit it with x-ray it won't be able to get through, all of it will be absorbed. That's why you get white
- air or fat are very low density material, so most of the x-ray won't interact with this material. That's why you get black
- Two dimensions are very important in radiology

» ONE View is NO View



Always read together

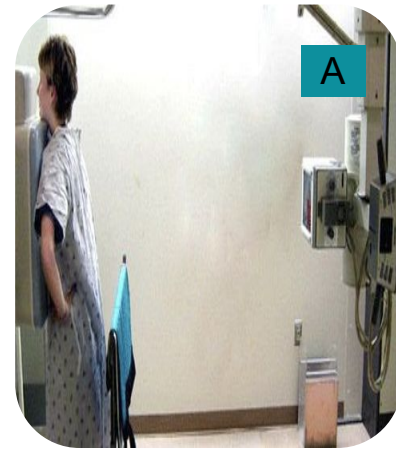
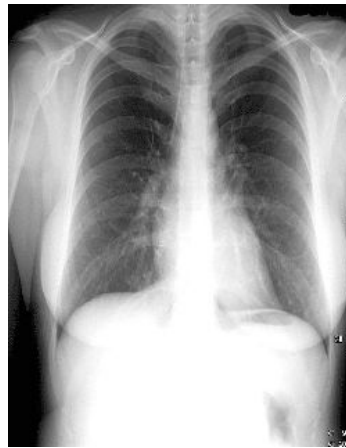- Must take two Projection
- X-ray image is plain films > two dimensional
- You can't tell that it's a cup from this view

Positioning

» Positioning

» Posterior Anterior position (PA)

- It's the projection of X rays going through the patient back (posterior) then leaving through his chest (anterior).
- as shown in Image A, the patient elevate the arms and places the hands-on his waist to push the scapula away from the lungs way to get a better image of the lung
- distance between the x-ray and the film 2m (6 feet) -> to lower magnificic effect.
- PA is the best way to acquire chest X-ray



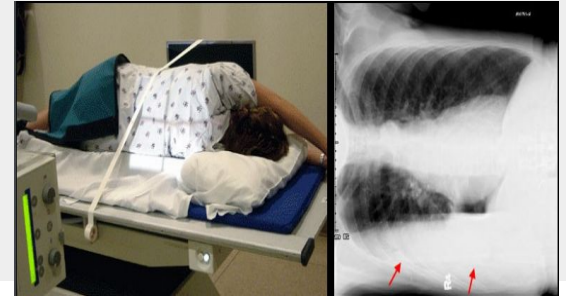
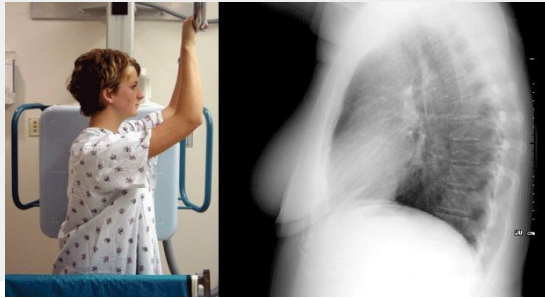» positioning lateral



Lateral

Lateral Decubitus

Image



Position

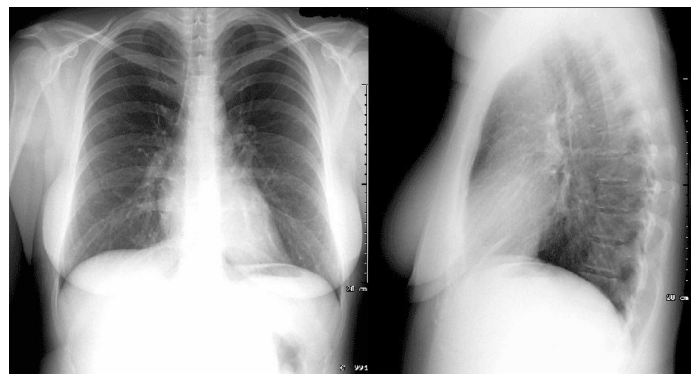- The X-ray tube is on the right of the patient and the film is on the left
- The Patient stands up with hands held high
- The Film is placed on the left to reduce heart magnification

- Helpful in assessing the volume of pleural effusion and determine whether its mobile or loculated
- the patient should roll on the suspected side
- We don't use it nowadays
- We use it in case we have something inside the pleural cavity like pleural effusion and want to know if this pleural effusion is simple pleural effusion (if the fluid move freely) or is it empyema , abscess or mass It is extremely sensitive as it can detect even 50 ml of fluid in the lungs (extremely sensitive).

Always read them together

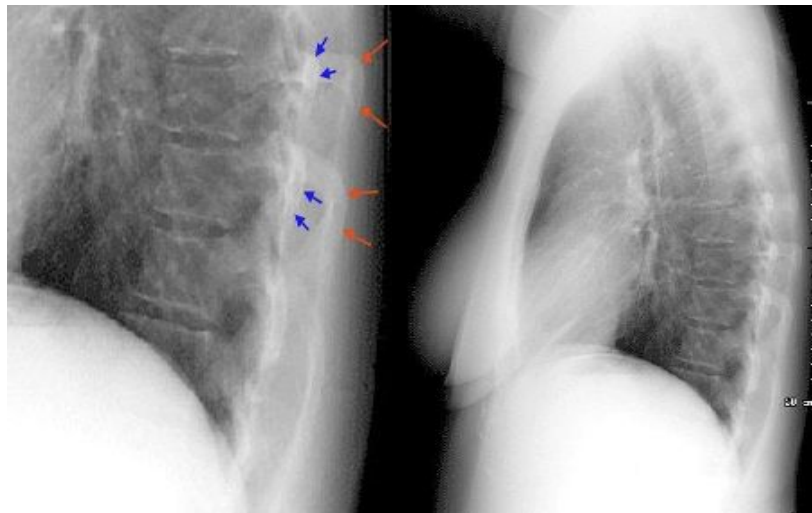
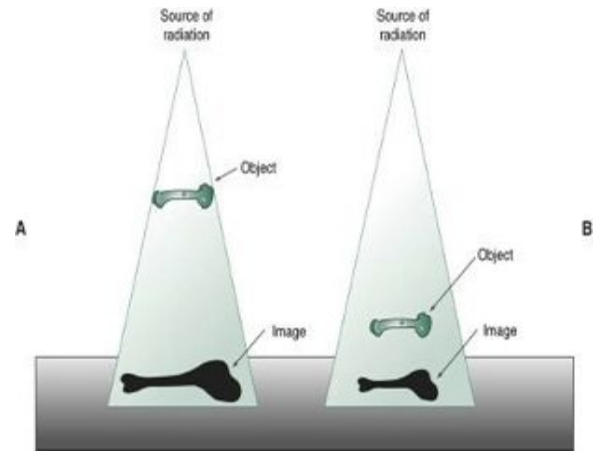
since x-ray is one dimensional images are set superimposed on each other

- in the PA view we can't see behind the heart
- so lateral view can help localise the pathology



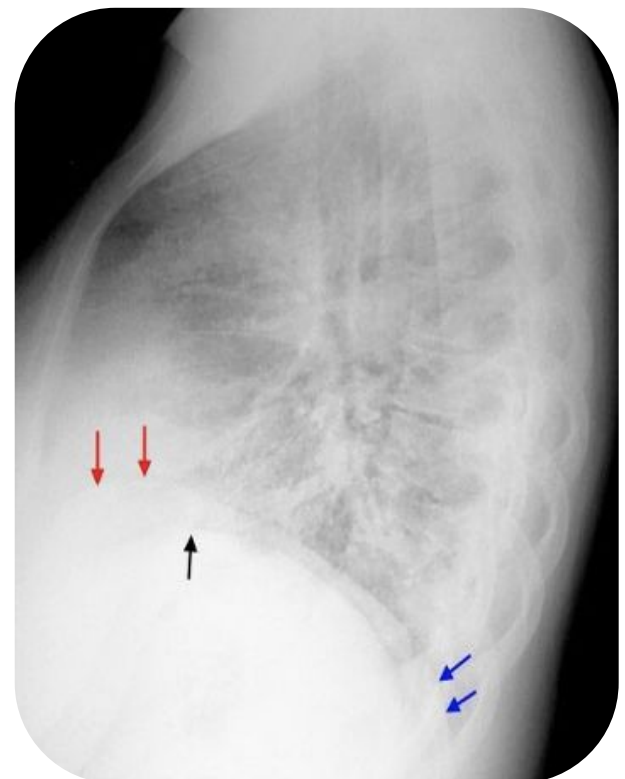
» Magnification Effect

- magnification effect the closer the object to the X-Ray source the larger the divergence of the image giving a larger image
- Magnification effect: As we said, x-rays are high energy light photons so light has a divergent path (start from a point then divergent) ex: if you have something in the middle closed to the source will get magnified, and as the structure get closer to the plain film, if gets the two proportions of it. It's big issue in radiology
- That's why we do PA projection: the heart located anteriorly , you want the heart to be closer to plain film in order not to be magnified so we do PA projection



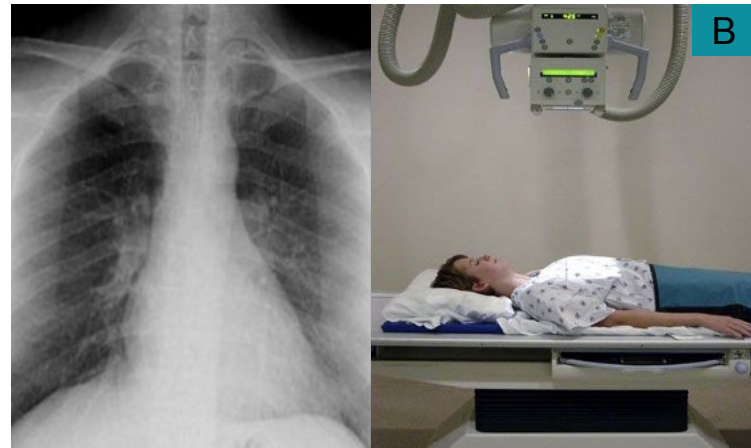
the blue arrow represents the left ribs
 Red arrow represents the right ribs.
 Note: the right ribs look larger due to the divergence. (magnification effect)
 notice that one breast is larger than the other

- ❖ The Same principle applies on the diaphragm:
 - posteriorly: the right hemidiaphragm continues posteriorly to meet the right ribs and gets magnified with them.
 - anteriorly: the right hemidiaphragm continues all the way to the anterior aspect of the thorax
- ❖ The left hemidiaphragm continues anteriorly and can't be seen further because the heart sits on the left hemidiaphragm therefore it obscures its border, this phenomenon called The Silhouette sign.

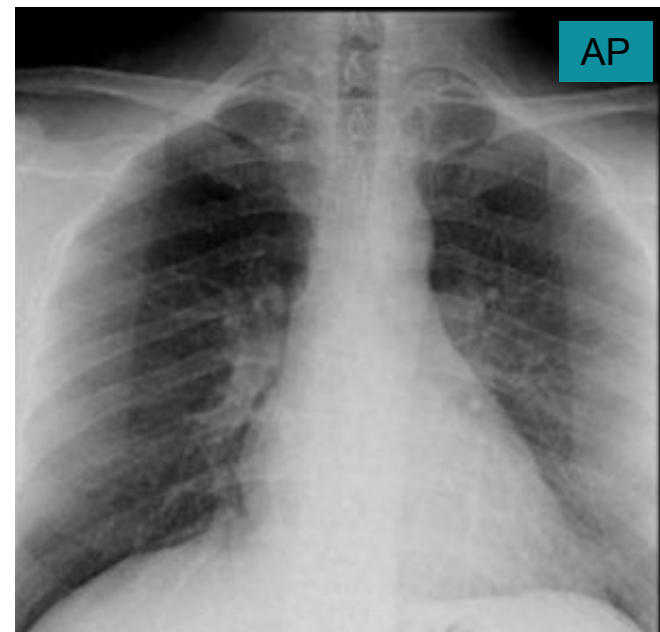
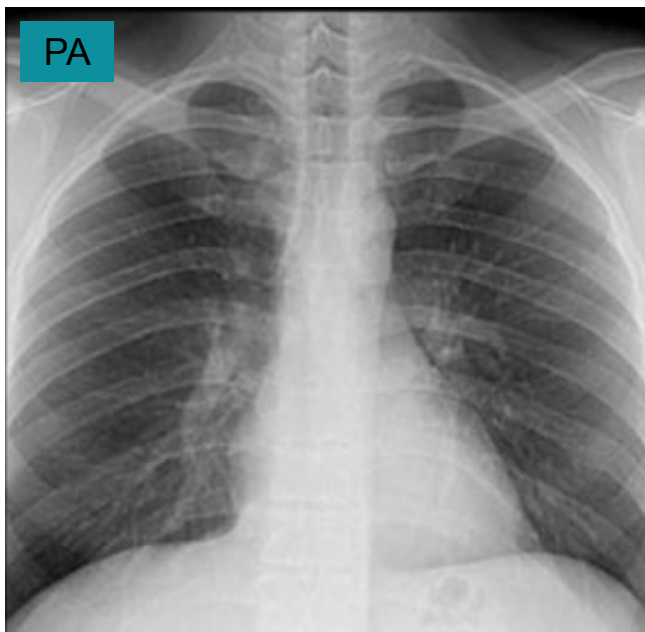


» Anterior Posterior position (AP)

- The AP position is always done when the patient is in a supine position (image B), in this position the patient is closer to the X-ray source which causes a magnification effect.
- used only in ill patients who can't stand
- 70/80 cm from the source and object.
- PA view is more detailed compared to AP projection,



» PA VS AP View



	PA view	AP view
Clavicle	V shaped, over lung fields	straight, Above lungs apex
Scapulae	Away from lung fields, because we ask the patient to rise his hand	Over lung Fields
Ribs	Posterior ribs distinct	Anterior ribs distinct
Heart		magnification (so we don't measure the Cardiothoracic ratio). widening of the mediastinum

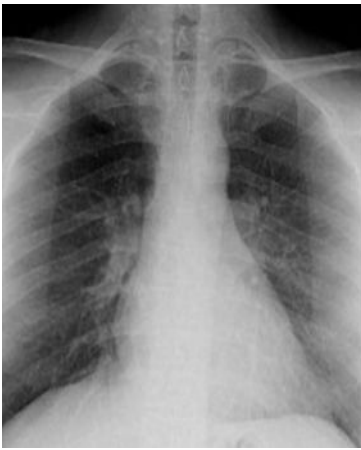PA view is superior to AP view, but in some patients who can't stand AP view is the only option the difference between PA vs. AP CXR? In anterior to posterior (AP) radiographs, the posterior structures are closer to the detector, and in posterior to anterior (PA) images, the anterior structures are closer to the detector. Therefore, as an example, chest radiographs are generally obtained PA to minimize magnification of the cardiac silhouette

» Adequacy of Film

- We determine technical adequacy of the film, by 3 measures:
 1. Inspiration
 2. Penetration
 3. Rotation

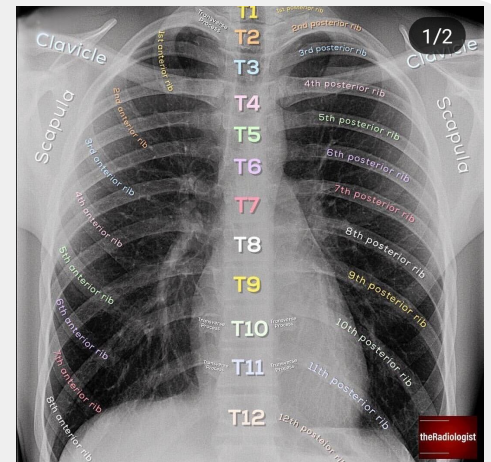
» Inspiration

- Patients should be examined while taking full inspiration to open up the lungs and examine the pathologies
- During inspiration the diaphragm is pulled down and the vessels are stretched
- If blood vessels are close to each other the image will become less clear and might lead to a false diagnosis

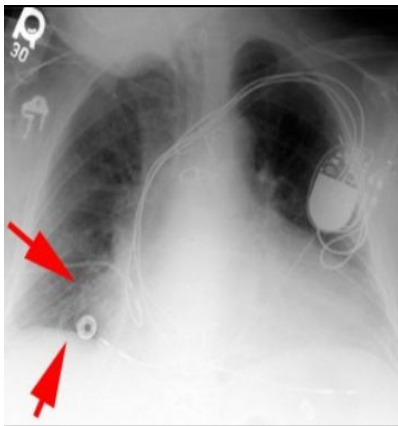

Revision:

- Ribs on The chest X-ray have both anterior and posterior aspects for each rib
- Ribs start from the costovertebral junction (vertebrae) to the costosternal junction (sternum)

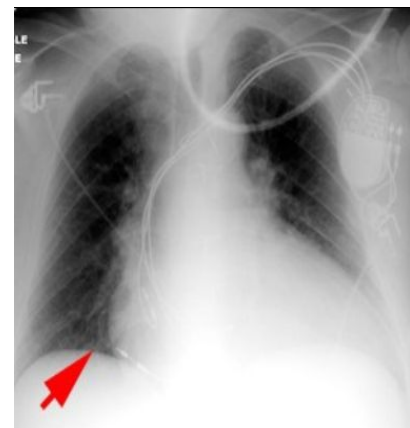


- To assess adequate inspiration 8-10 posterior ribs must appear and 5-7 anterior ribs
- Below than this? Poor inspiratory effort
- Higher than this? Hyperinflation or emphysema especially in patients with chronic asthma (hyperinflated lung)



Inadequate films

- In inadequate films, the lungs are lighter because of the proximity between blood vessels
 - Blood is radiopaque
- cant see the cardiac outline, so we are not sure if there is abnormality
- Poor inspiration as the counted ribs are less than 5

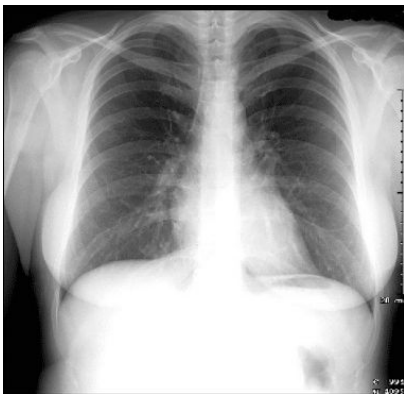
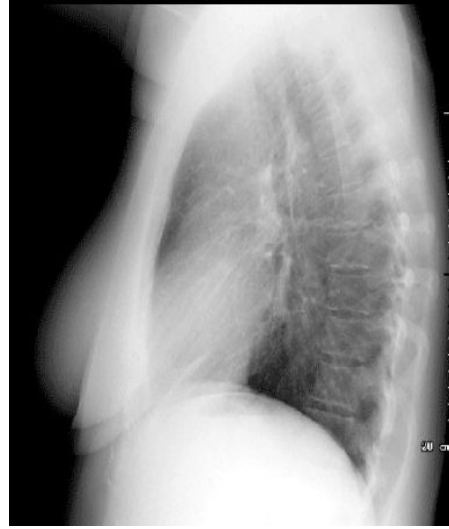
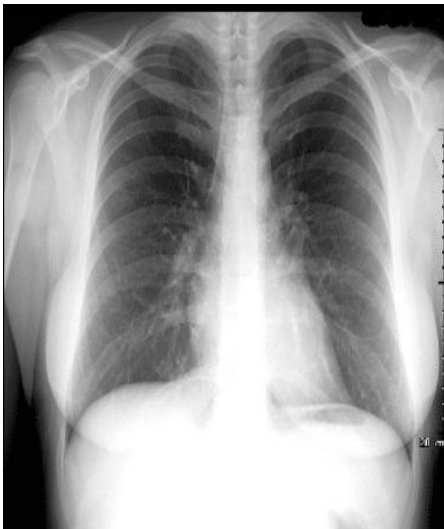Adequate films

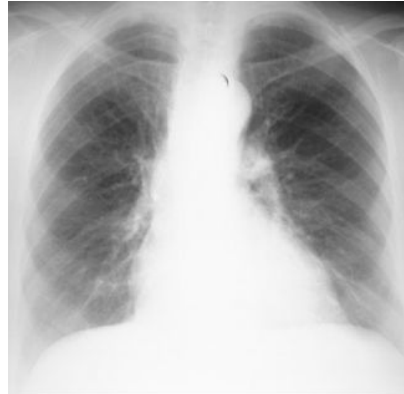- the same patient, with well inspiration
- In adequate films, the lungs are darker because of the air-filled in it
 - Air is radiolucent
- can see the cardiac outline, we can see that the patient is normal

» Penetration

- Penetration is the degree to which the X-ray passed through the body.
 - High energy X-ray >penetrate further and create black images
 - Low energy X-ray >it won't penetrate that much
- To assess penetration,
 - On a good PA film, you should see the dorsal spine through mediastinum, with few details of the disc spaces and border of vertebral bodies. Bronchovascular structures can usually be seen through the heart
 - On a good lateral film, the spine will appear darker as you move caudally (downward) because there is more air,more lungs. you can see the dorsal spine in more details
 - The sternum should be seen edge-on
 - posteriorly you should see two sets of ribs

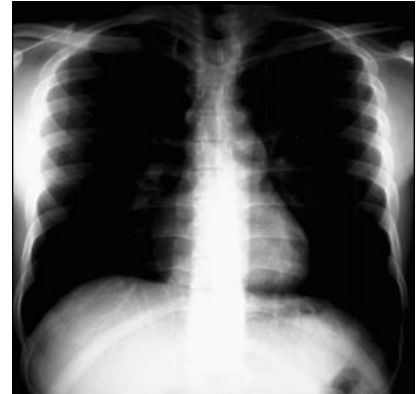

Well penetrated



Underpenetrated

underpenetrated film you can't see the the dorsal spine, prominent lung vessels.
pathology behind the mediastinum can be missed



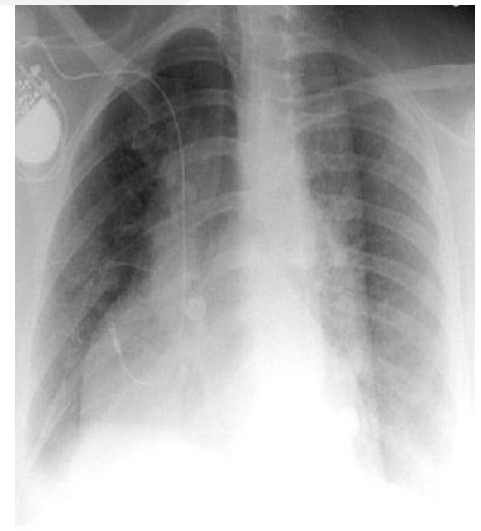
Over penetrated

over the penetrated film you can see super details of the dorsal spines, black lungs you don't see the vessels. pathology in the lung can be missed.

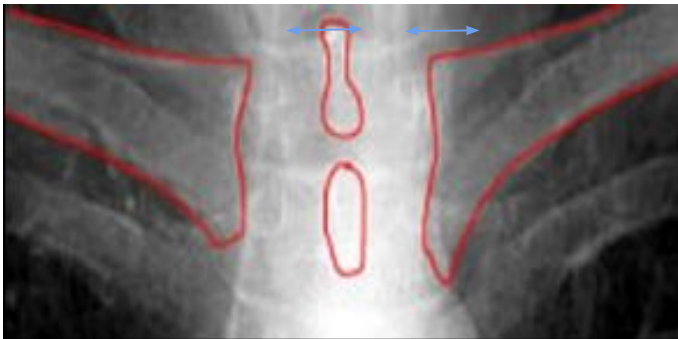
» Rotation

- If there is a rotation of the patient, the mediastinum may look very unusual
- To assess rotation,
 - Check if the clavicle medial heads are equidistant to the vertebral spinous process
- In this rotated film, notice how the clavicular head is away from the spinous process (**red arrows**) which lead to the widening of the mediastinum and might be falsely diagnosed with tension pneumothorax (**blue arrows**) but are just skin folds

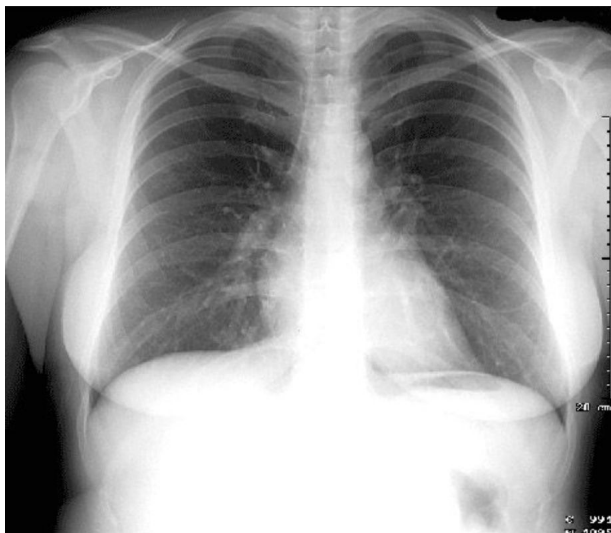
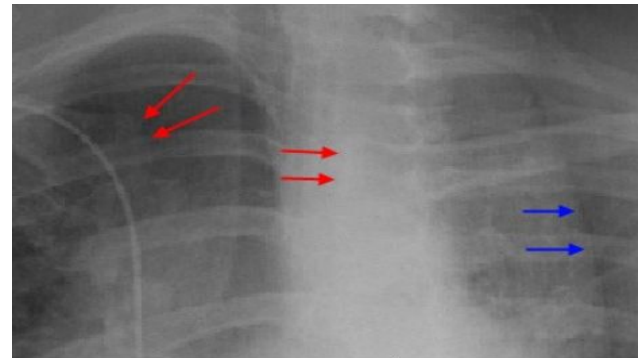
Rotated images MUST be repeated, because most common factor that can affect the CXR quality



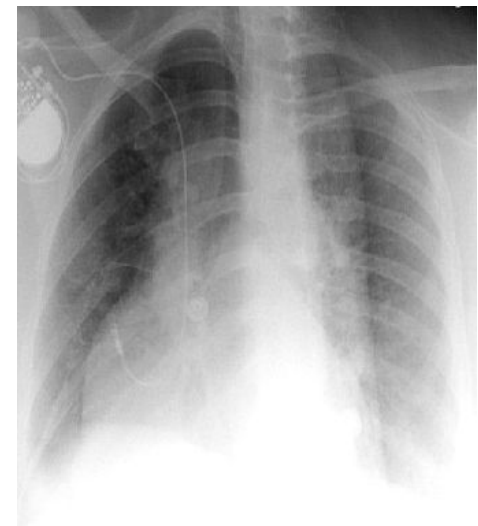
Improper positioning
Can cause: poor visualization of lung base and cardiomegaly



the distance between the blue arrows should be equal



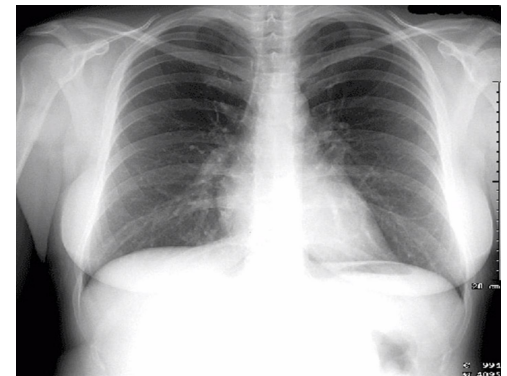
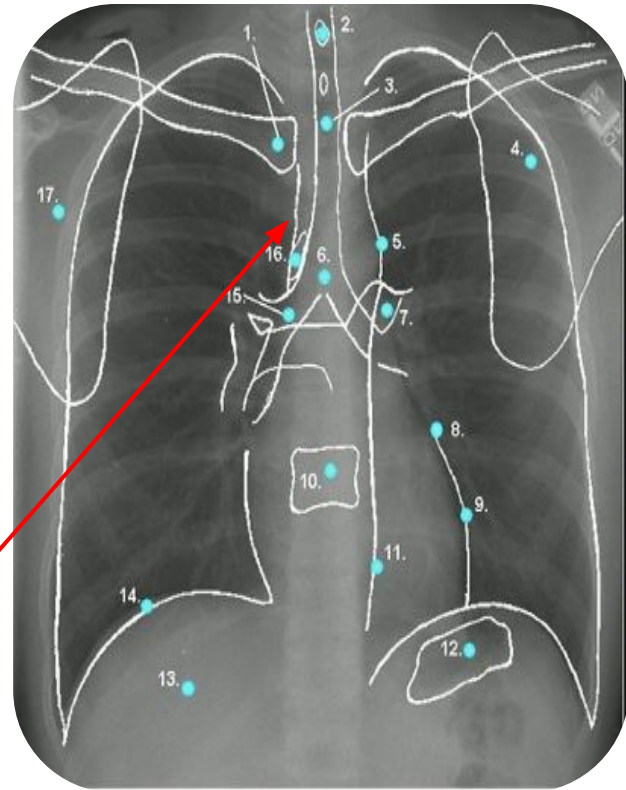
- Medial end of clavicles are far away for the spine > significant rotation
- Normally > the spinous process must be equal distance between the two medial ends of clavicle



Because of the significant rotation, the heart seems to be larger, and mediastinum looks wider, and the right lung is more lucent and larger compared to the left lung

» Chest anatomy

- | | |
|--------------------------------------|------------------------------|
| 1- Clavicle | 10- Vertebral body |
| 2- Spinous process | 11- Descending Aorta |
| 3- Trachea | 12- Gastric fundus |
| 4- Scapula | 13- Liver |
| 5- Aortic Arch (knuckle)* | 14- Rt. Hemidiaphragm |
| 6- Carina (Bifurcation) | 15- Rt. main bronchus |
| 7- Pulmonary Trunk (Pulmonary Conus) | 16- Azygos vein |
| 8- Lt. Cardiac border (atria) | 17- Scapula |
| 9- Lt. Cardiac border (ventricle) | 18 - Rt. paratracheal stripe |



★ why can't we see the right ventricle and the left atrium? Here we can only see the right atrium and the left ventricle.

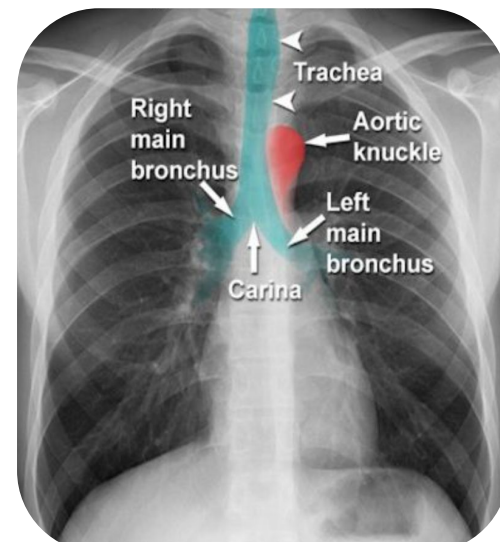
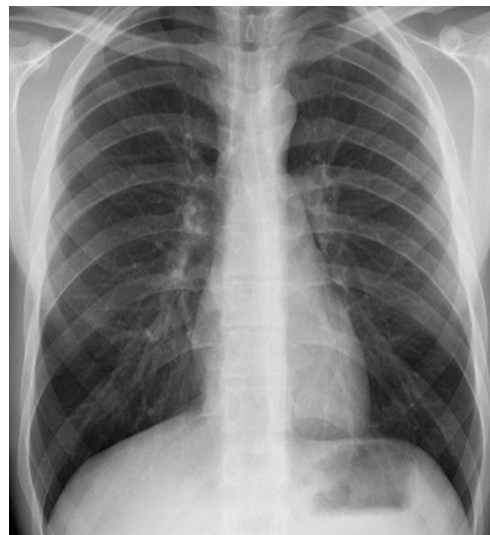Basically, the right ventricle is an anterior structure and the left atrium is a posterior structure, so their shadow merge with the rest of the chambers, how can we see them? Lateral view.

*The aortic knob or knuckle refers to the frontal chest x-ray appearance of the distal aortic arch as it curves posterolaterally to continue as the descending thoracic aorta. It appears as a laterally-projecting bulge, as the medial aspect of the aorta cannot be seen separate from the mediastinum. It forms the superior border of the left cardiomedastinal contour

» Normal Chest X Ray

Respiratory tract

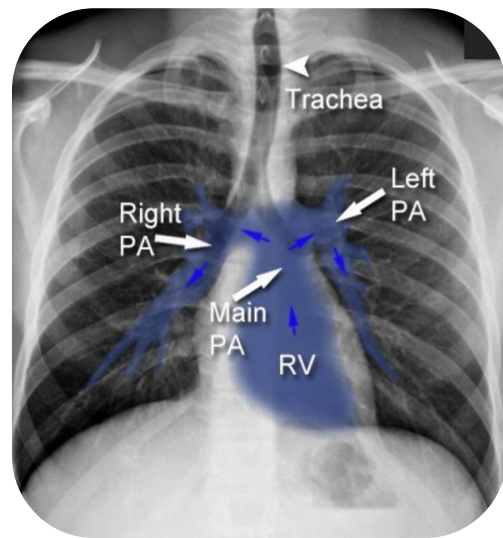
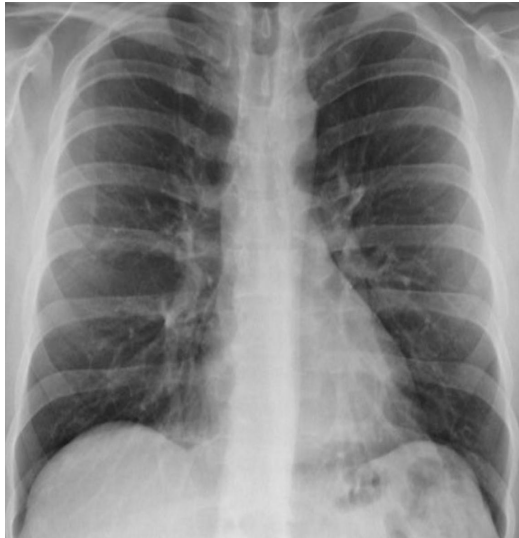The aortic arch causes slight deviation of the trachea to the right side.



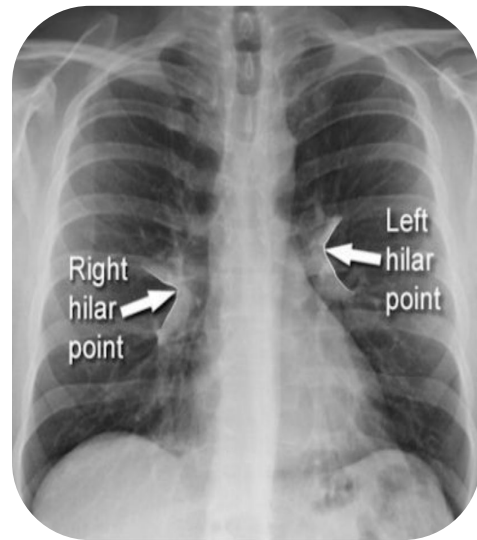
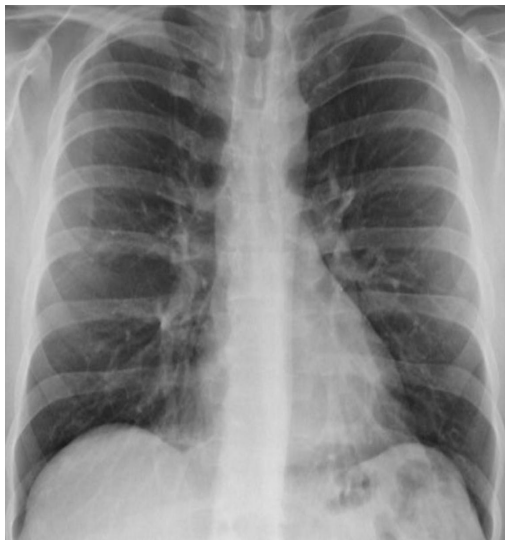Lung anatomy

⇒ Normal Chest X Ray

Pulmonary vessels



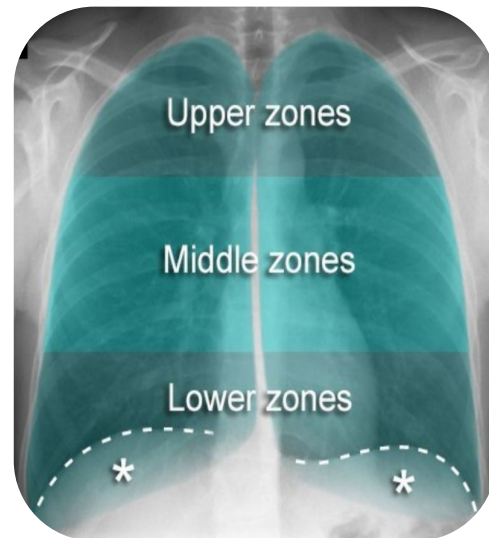
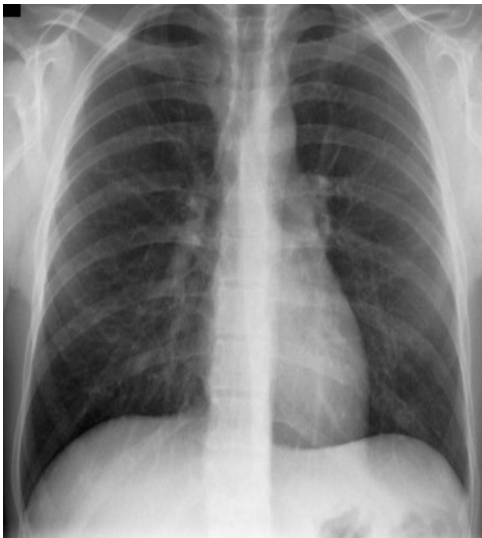hilum of the lung



- the hilum contains pulmonary vessels and the major bronchi. The hilar point is at the meeting of superior and inferior vessels, as seen below the left Hilar point is higher than the Right hilar point.
- Clinical importance? Ex. right upper lobe collapse would shrink the right lung and would raise the hilum

Lung anatomy

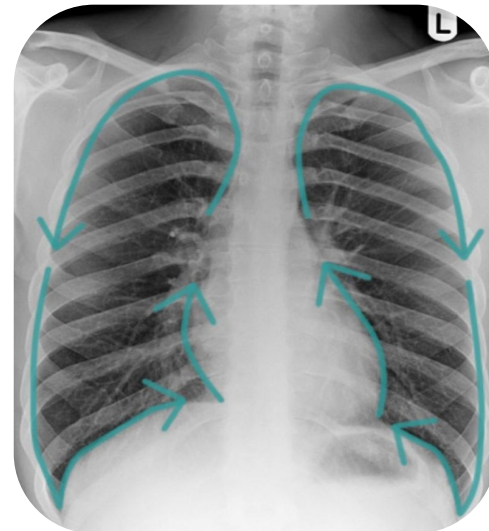
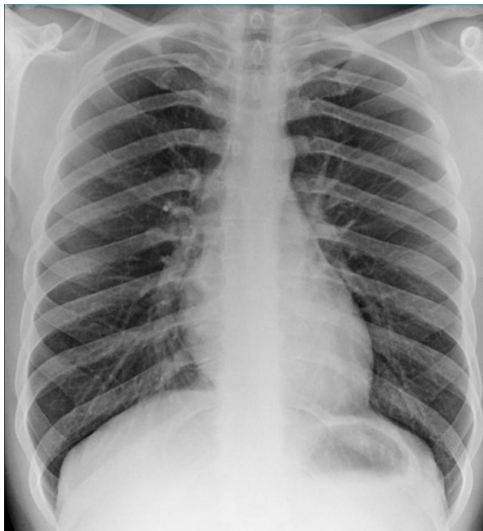radiological segments of the lung



We prefer to use zonal anatomy in x ray rather than lobar anatomy, because it's difficult to differentiate lobes on plain X ray and to differentiate we use either:

- Lateral view X ray
- CT

Plural covering



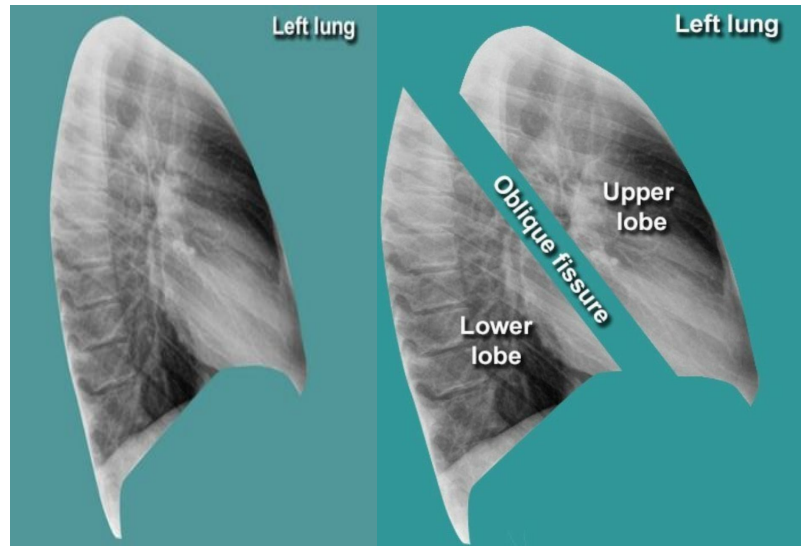
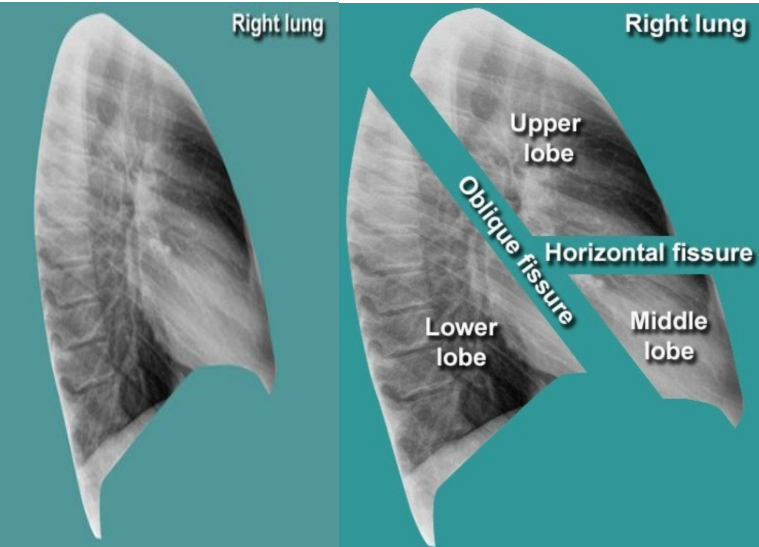
- The pleural covering runs along the peripheral aspect the thoracic and diaphragm and mediastinum.
- pleura made of 2 layers (visceral and parietal), separated via pleural space containing pleura fluid for lubrication.
- Usually we don't see the pleura in normal chest X ray except the Transverse fissure or if there is a disease causing thickening of the pleura
Ex: pleural effusion, malignant (mesothelioma)

Lung anatomy

Right lung

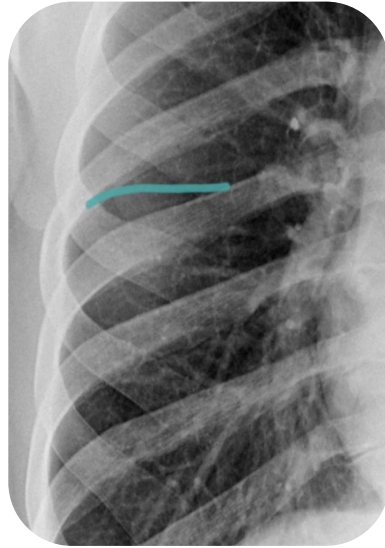
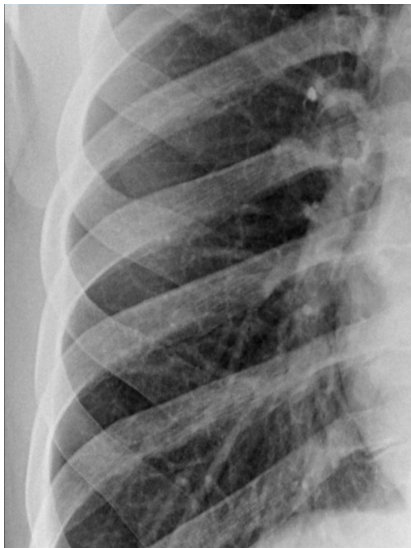Lateral View X ray

Left lung

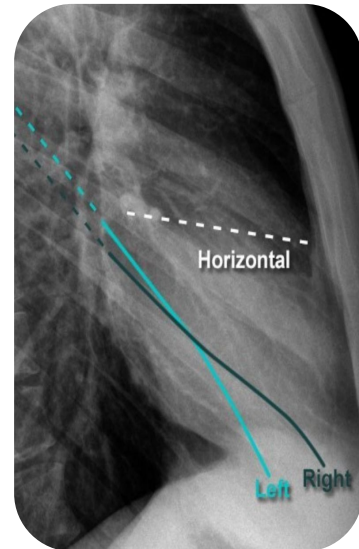
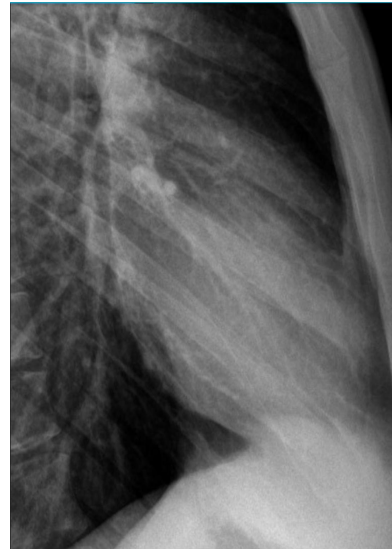

transverse fissure

oblique fissure



Common view of the Right middle zone



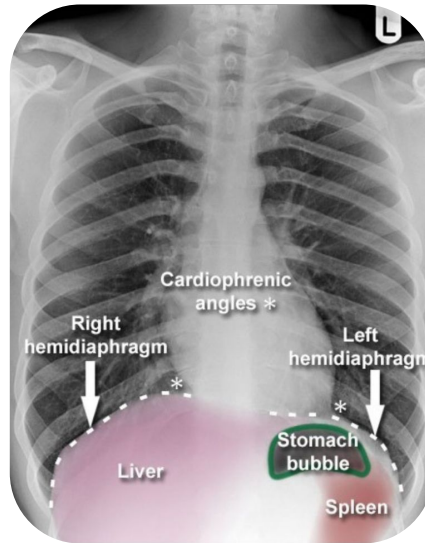
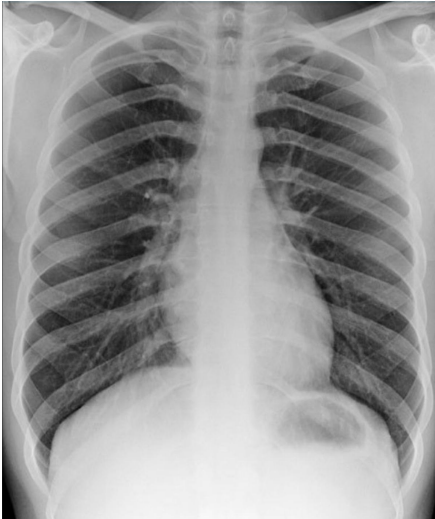Lateral view, you can see both the horizontal fissure and right and left oblique fissures as both lungs are superimposed over each other. In frontal projection we can see the horizontal fissure because the position of the fissure

Chest anatomy & Diaphragm

Diaphragm



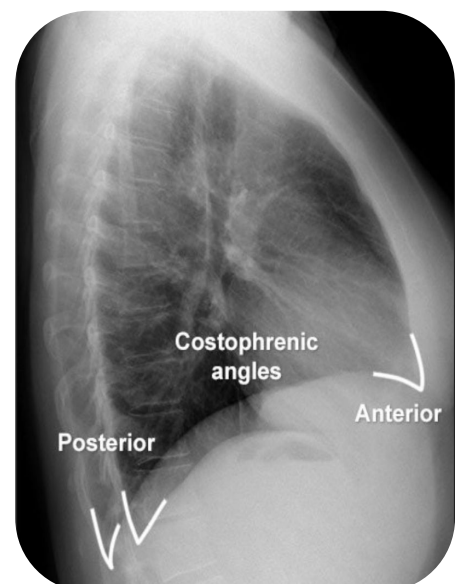
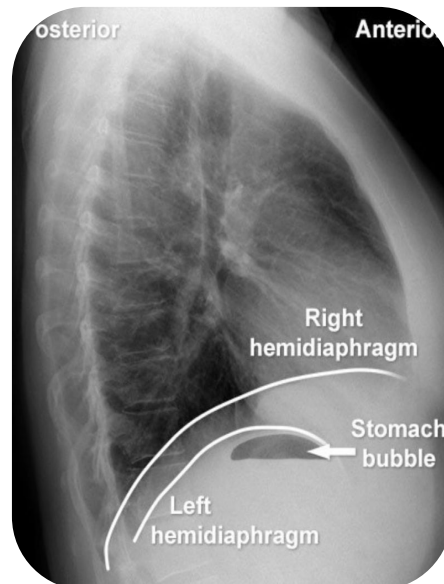
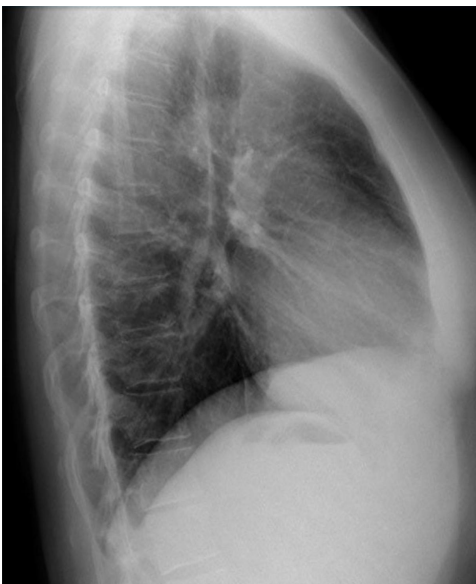
CXR Made Easy



The right hemidiaphragm is usually higher than the left

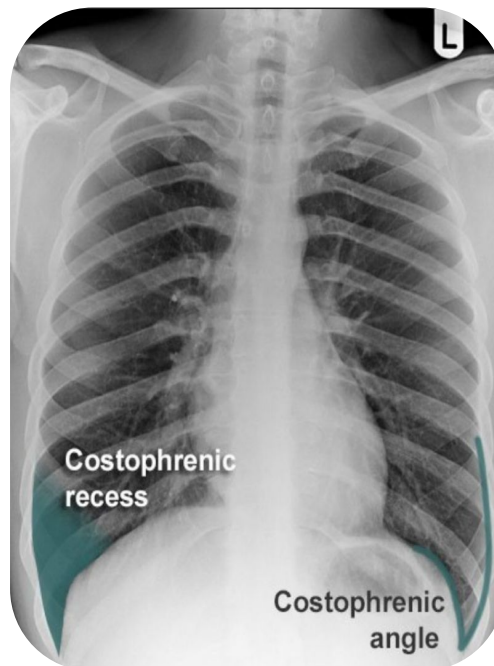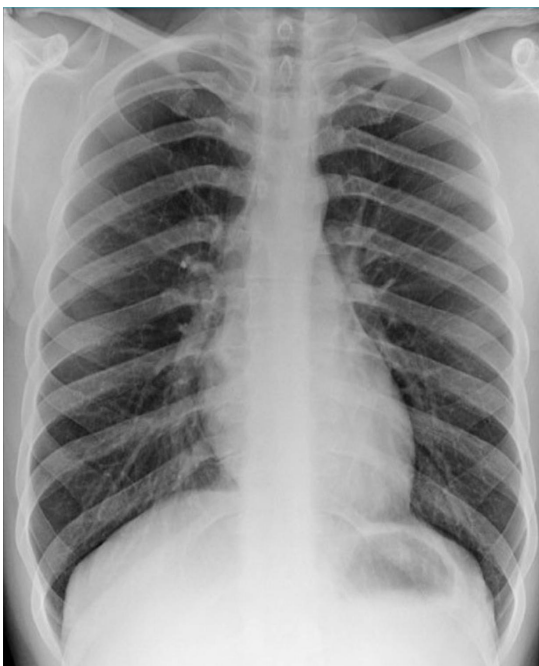The cardiophrenic angle should be very sharp, any fluid would go there due to gravity (abnormal)

Lateral view



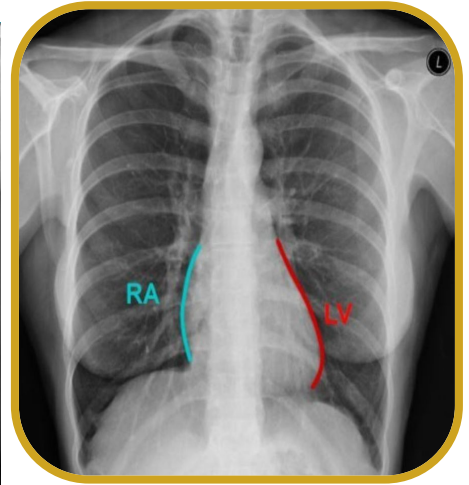
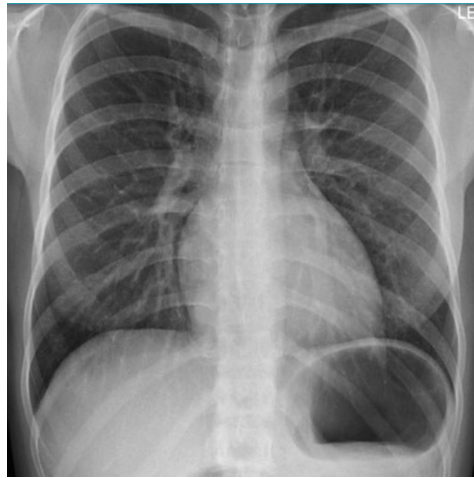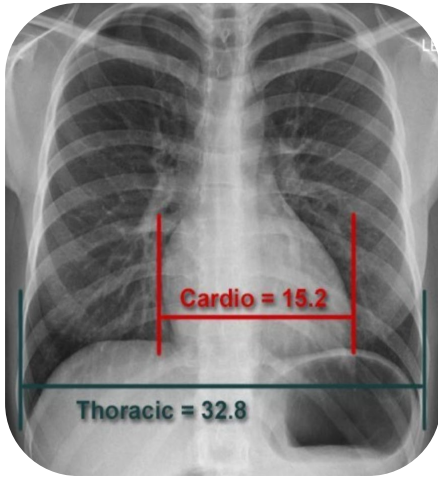
The lung extends posteriorly behind the diaphragm

We can see stomach bubble on lateral projection
If you wanna assess small volume pleural effusion, you will do lateral projection



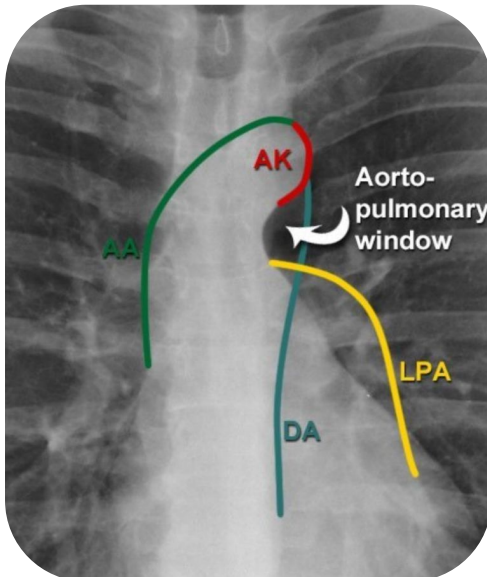
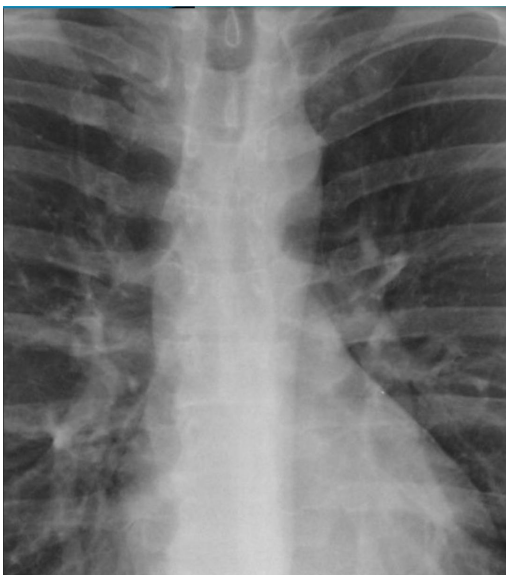
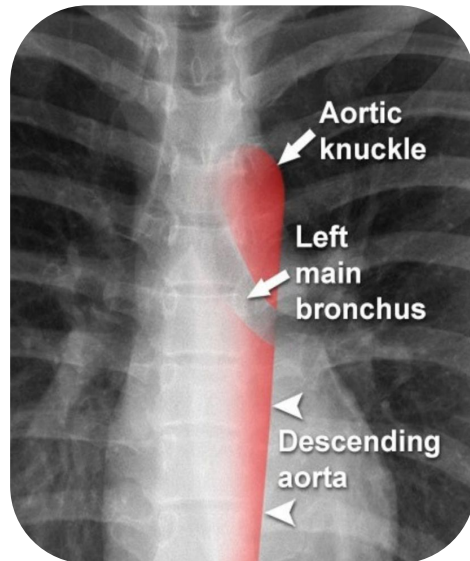
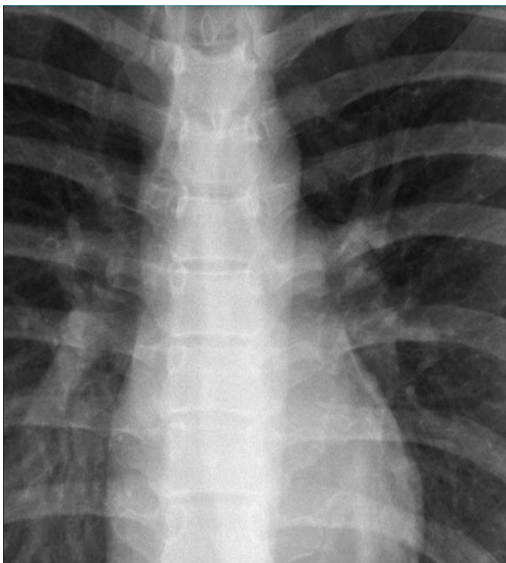
If there is blunting of costophrenic angle, it may indicate pleural effusion or hematoma

Cardiac anatomy



- **Posterior anterior view**, how to know? No magnification, no scapula
- **Cardiothoracic ratio**: if less than 50% then is normal, greater is considered cardiomegaly
- You are allowed to measure heart size here because there is no magnification

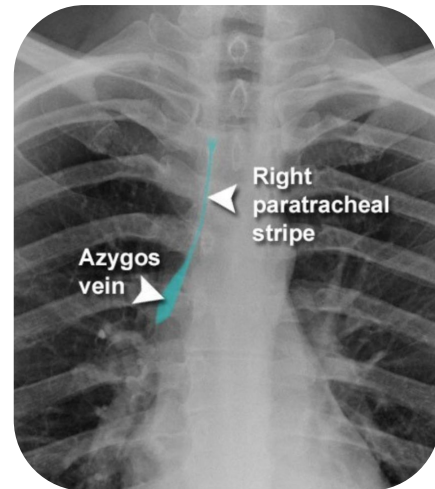
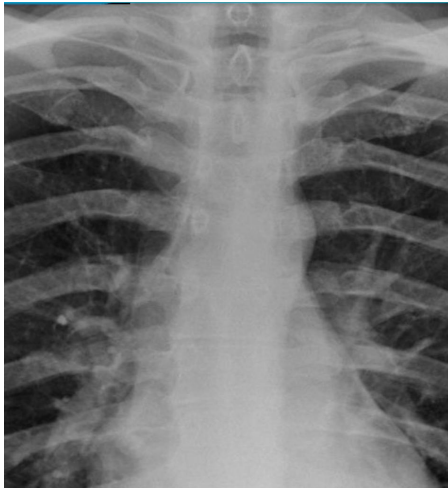RA: right atrium
LV: left ventricle



AK: aortic knuckle
AA: aortic arch
DA: descending aorta
LPA: left pulmonary artery

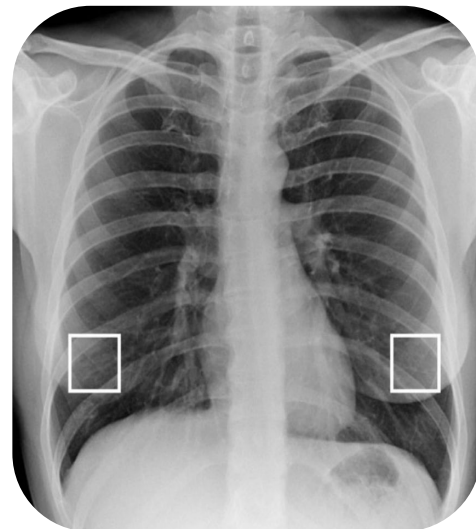
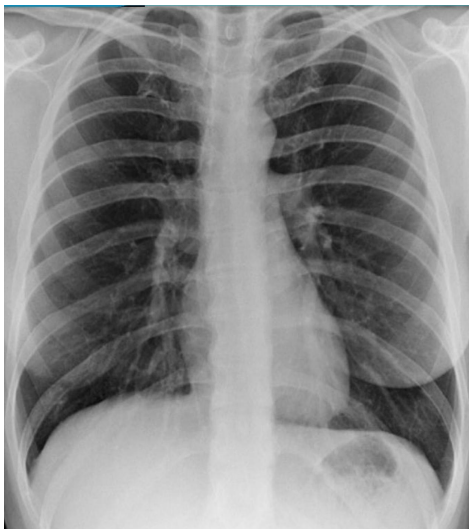Aortopulmonary window is important anatomical landmark and station for lymph node enlargement and masses (Lung cancer or lymphoma)

Right paratracheal stripe



- Right paratracheal stripe is important anatomical landmark if thickening seen it may indicate lymph node enlargement or masses
- Normally it's less than 3mm

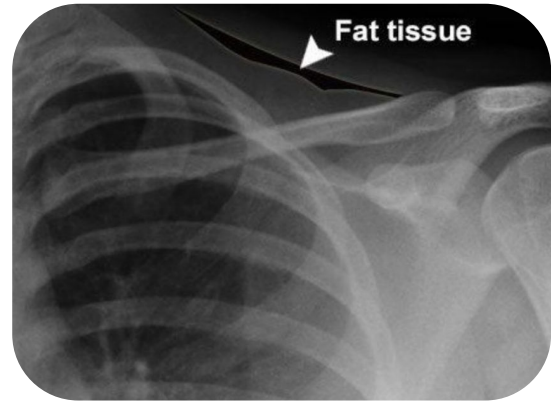
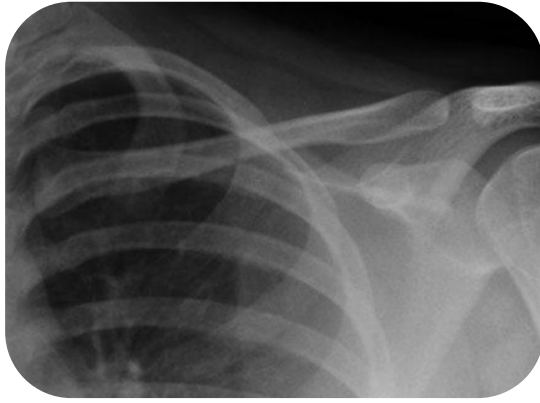
Breast shadows



Asymmetrical breast showing larger left breast shadowing which might indicate a pathology

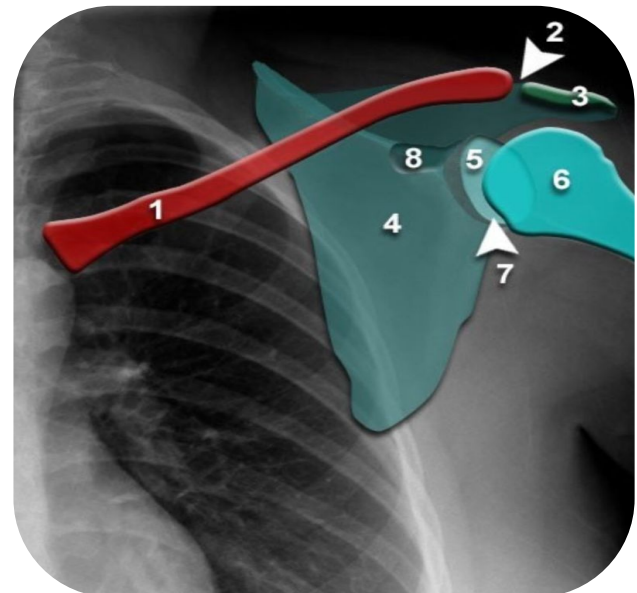
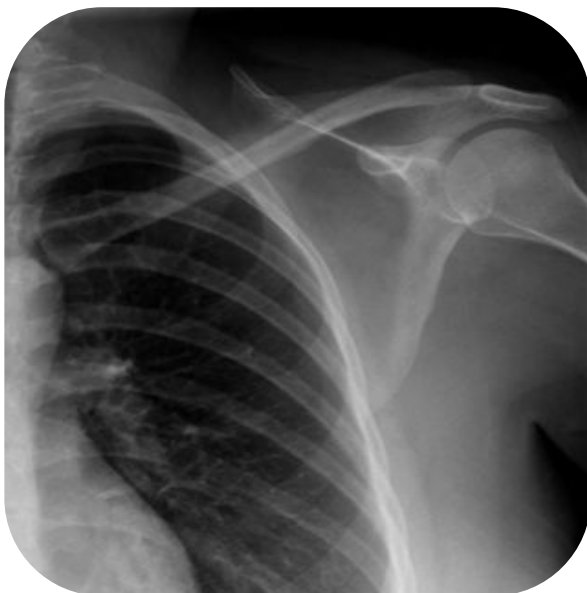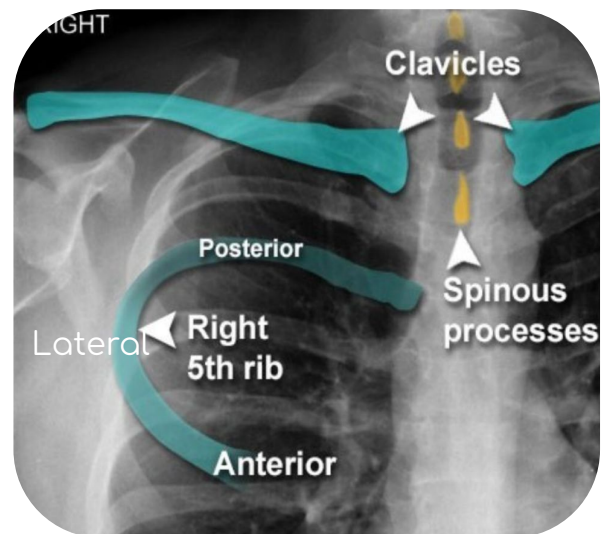
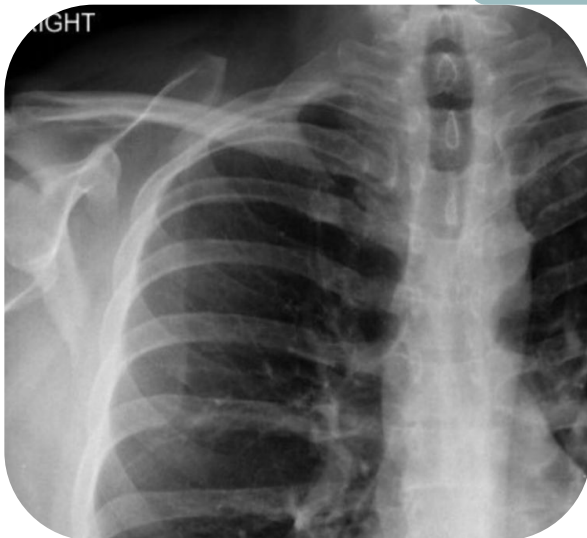
chest fat tissue & Chest bones

Fat tissue



You have above fat tissue trapezius muscle, and other muscle below it, between these two muscles there is fat line. In subcutaneous emphysema air inside these tissues, you can see the air in this space

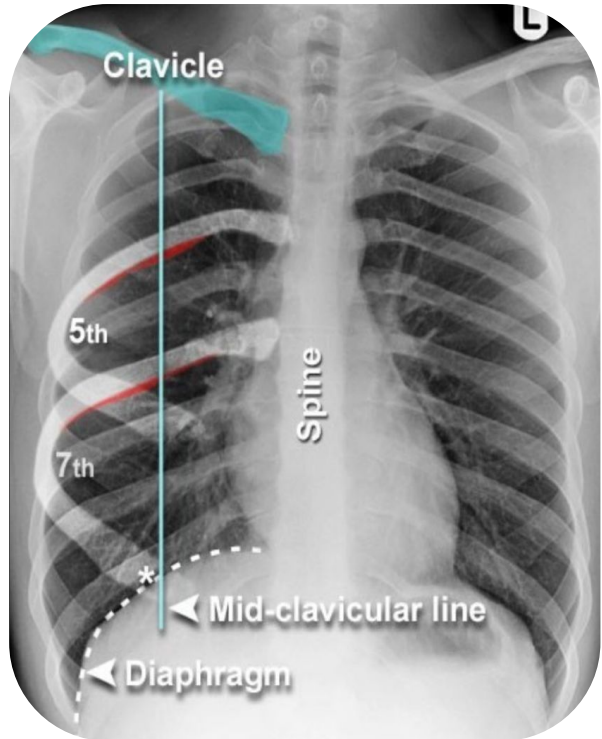
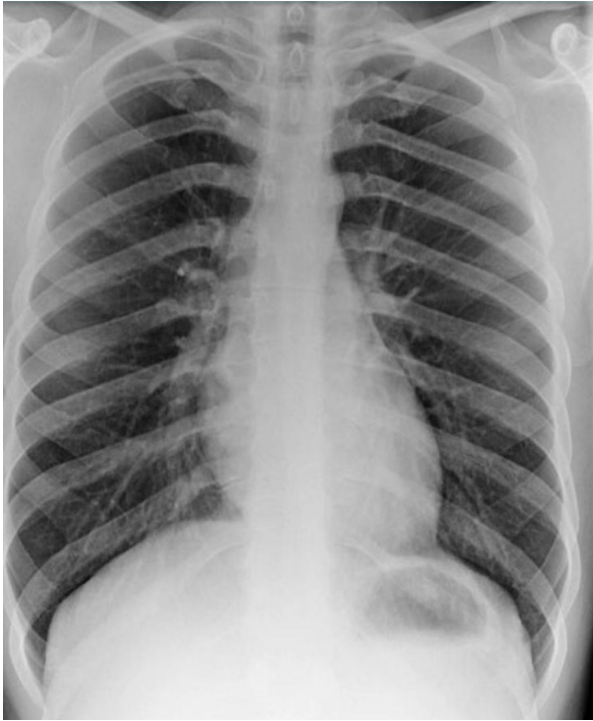Bone structures



- | | | |
|----------------------------|-------------------|-----------------------|
| 1) clavicle | 4) scapula | 7) glenohumeral joint |
| 2) acromioclavicular joint | 5) glenoid cavity | 8) coracoid process |
| 3) acromion | 6) humerus | |

Chest bones

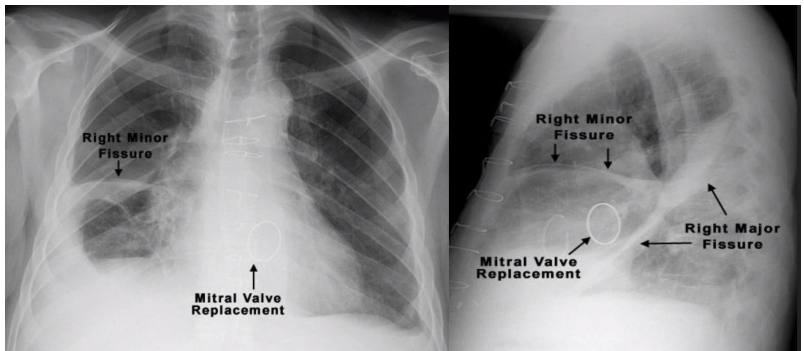
MidClavicular line



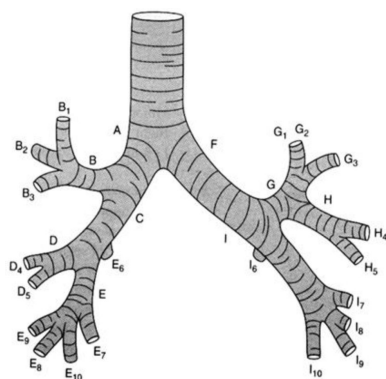
- To assess the degree of inspiration it is conventional to count ribs down to the diaphragm.
- The diaphragm should be intersected by the 5th to 7th anterior ribs in the midclavicular line. Less is a sign of incomplete inspiration
- hyperexpanded (>7th anterior rib intersecting the diaphragm at the midclavicular line). This is a sign of obstructive airways disease Ex: emphysema

- B: right upper lobe bronchus
- B1: apical
- B2: posterior
- B3: anterior
- C: right bronchus intermedius
- D4: lateral
- D5: medial
- D: right middle lobe bronchus
- E: for right lower lobe bronchus
- E9: superior
- E8: anterior
- E10: lateral
- E7: posterior
- F: left main bronchus
- G: left upper lobe bronchus
- G1: apical
- G3: posterior
- H: lingual
- H4: superior
- H5: inferior
- I: left lower lobe bronchus
- I7: superior
- I8: anterior
- I9: lateral
- I10: posterior

Lobes and fissures



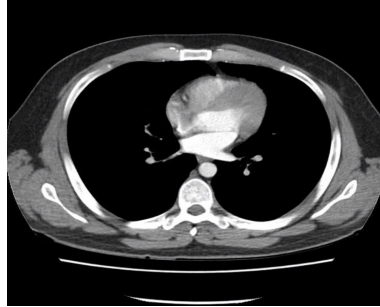
Bronchi



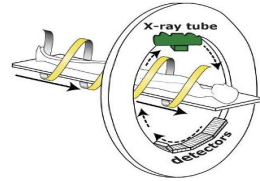
Chest CT Images

- 3 dimensional modality
- Main pulmonary artery trunk
- CT with IV contrast is the most appropriate to characterize Aortic knob
- Cardiac CT is best to assess the coronary arteries

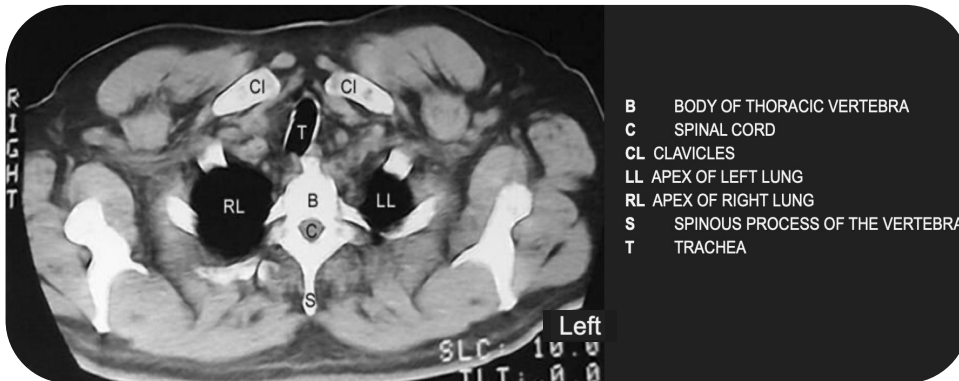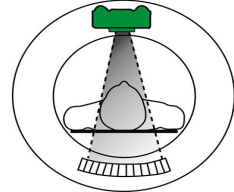
Dr: I'll leave these for you because it's pure anatomy, we don't have to talk about it, everything is labeled



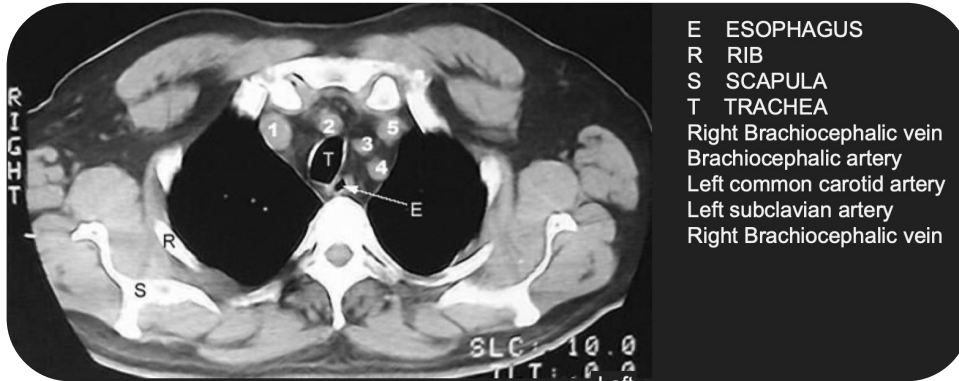Helpful video for how to read the CT scan of the chest



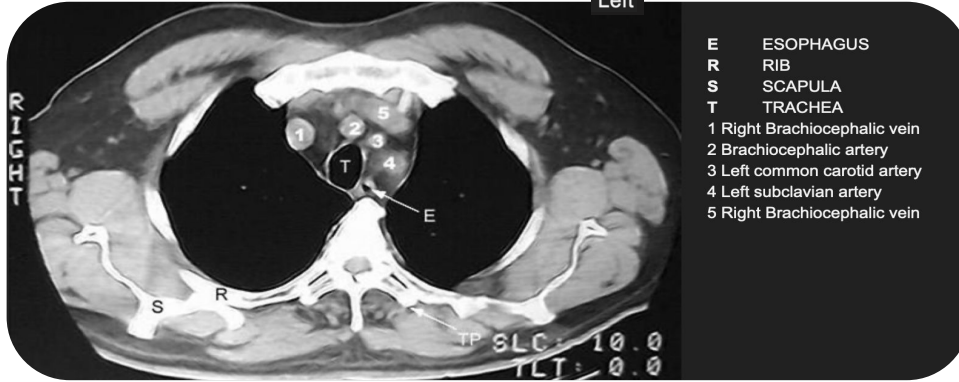third generation CT scanner



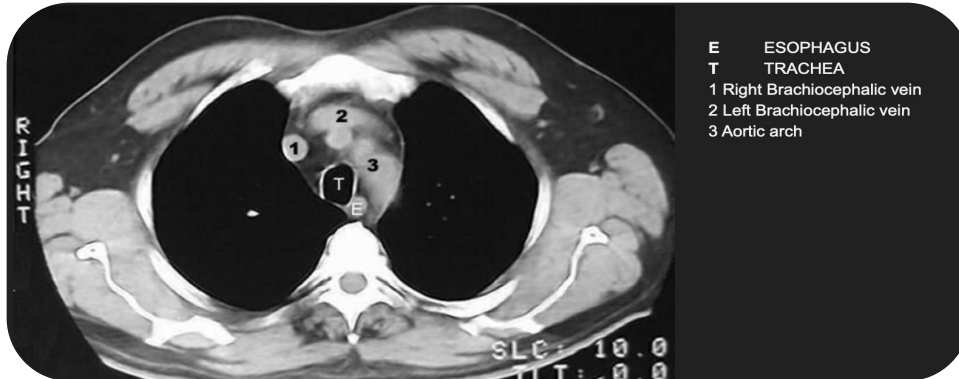
- B BODY OF THORACIC VERTEBRA
- C SPINAL CORD
- CL CLAVICLES
- LL APEX OF LEFT LUNG
- RL APEX OF RIGHT LUNG
- S SPINOUS PROCESS OF THE VERTEBRA
- T TRACHEA



- E ESOPHAGUS
- R RIB
- S SCAPULA
- T TRACHEA
- 1 Right Brachiocephalic vein
- 2 Brachiocephalic artery
- 3 Left common carotid artery
- 4 Left subclavian artery
- 5 Right Brachiocephalic vein

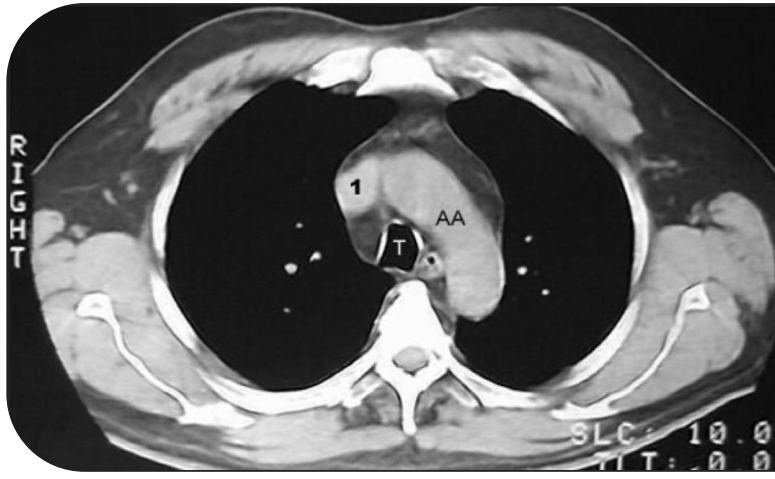


- E ESOPHAGUS
- R RIB
- S SCAPULA
- T TRACHEA
- 1 Right Brachiocephalic vein
- 2 Brachiocephalic artery
- 3 Left common carotid artery
- 4 Left subclavian artery
- 5 Right Brachiocephalic vein

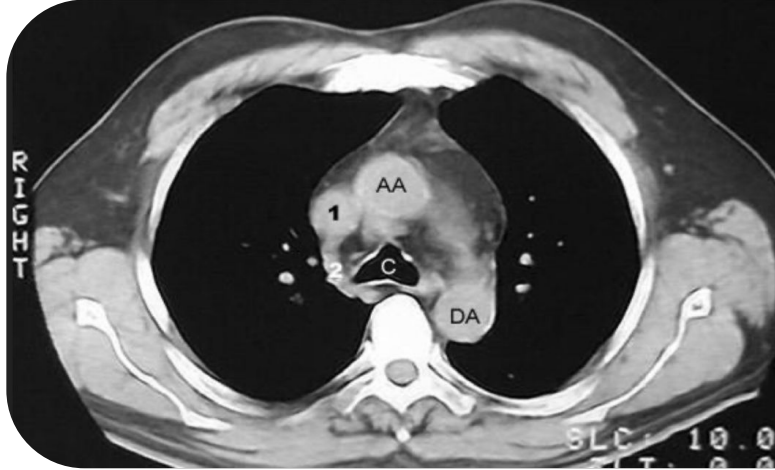


- E ESOPHAGUS
- T TRACHEA
- 1 Right Brachiocephalic vein
- 2 Left Brachiocephalic vein
- 3 Aortic arch

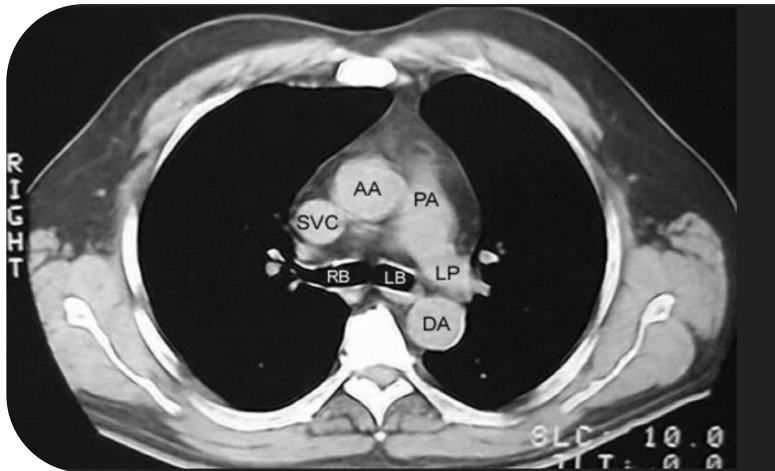
Chest CT



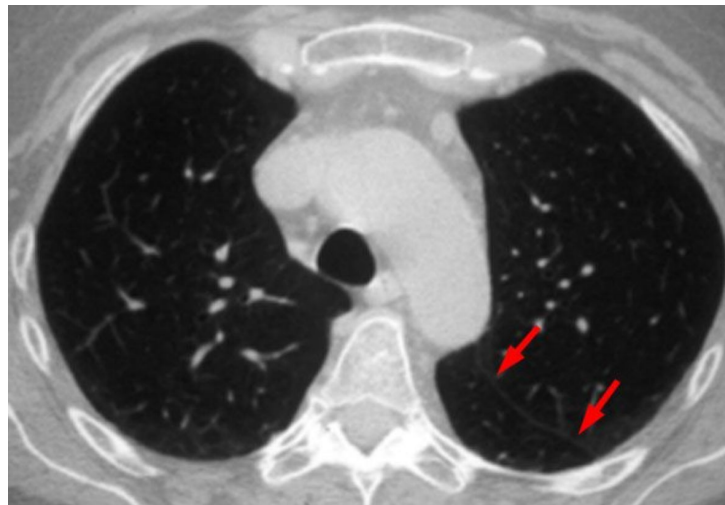
- AA Aortic Arch
- T TRACHEA
- 1 Superior vena cava



- AA Ascending Aorta
- DA Descending Aorta
- 1 Superior vena cava
- 2 Azygous Arch

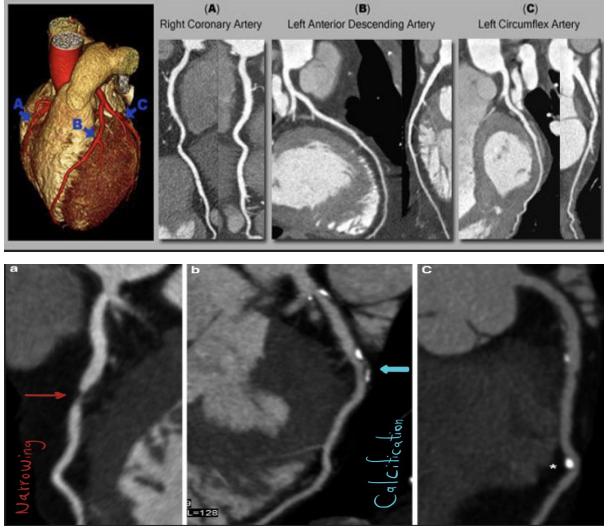


- AA Ascending Aorta
- DA Descending Aorta
- LB Left main bronchus
- LP Left pulmonary artery
- PA Pulmonary trunk
- RB Right main bronchus
- SVC Superior vena cava

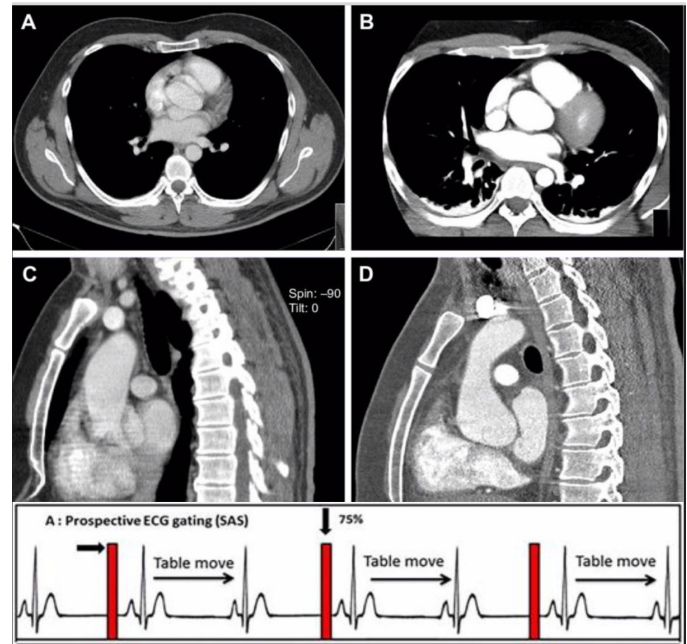


» Technical factors for cardiac imaging

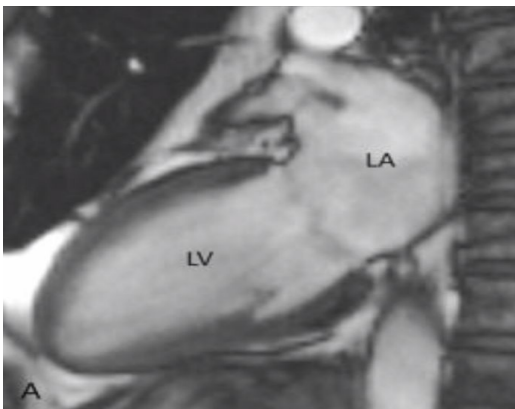
Myocardial disease? Do MRI
CAD (to assess lumen of coronary
arteries ? Do CT



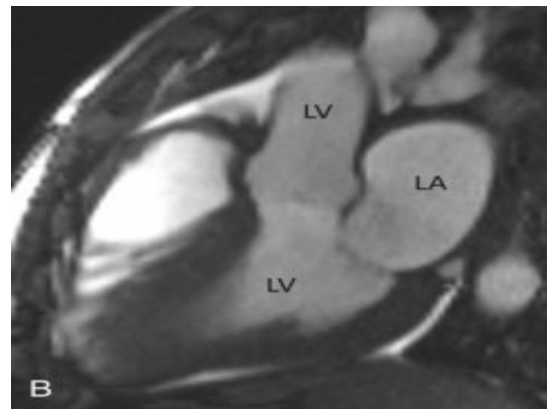
Electrocardiographic gated scan



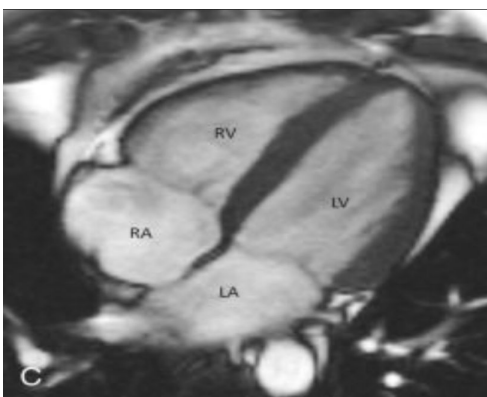
» Cardiac imaging planes No ionization (safe)



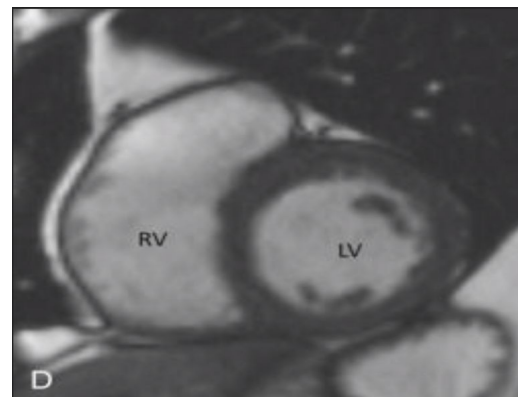
Two chamber view



Three chamber view



Four chamber view



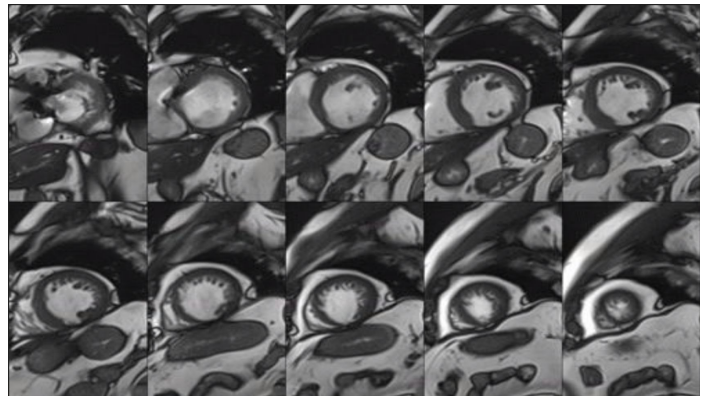
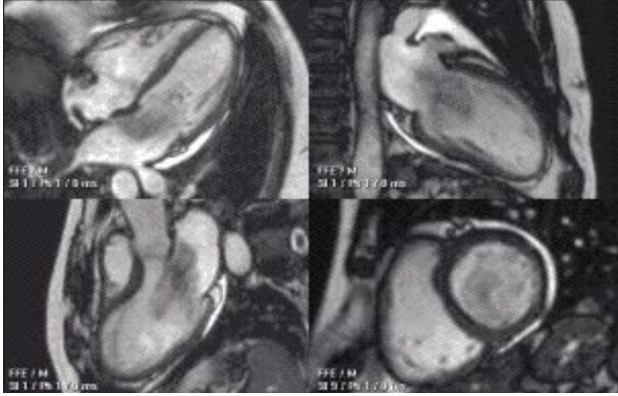
Short axis view

If you wanna size The cardiac
chambers or to know if there is
cardiomegaly. Also You can see
AV septum , assess
synchronism of contractions

Very important to assess LV
as it the most important
muscle in heart

Heart MRI

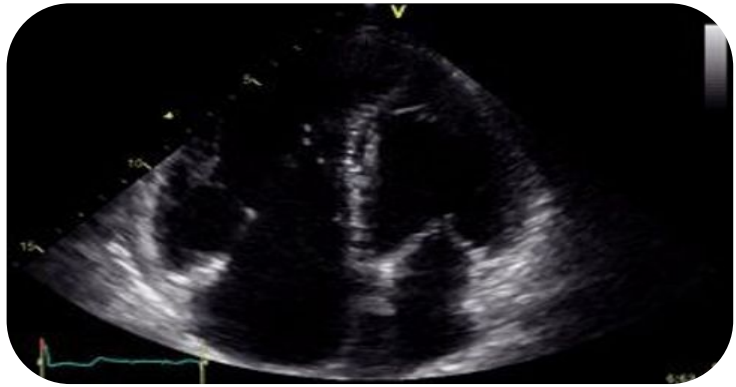[Video](#)



Myocardial infarction

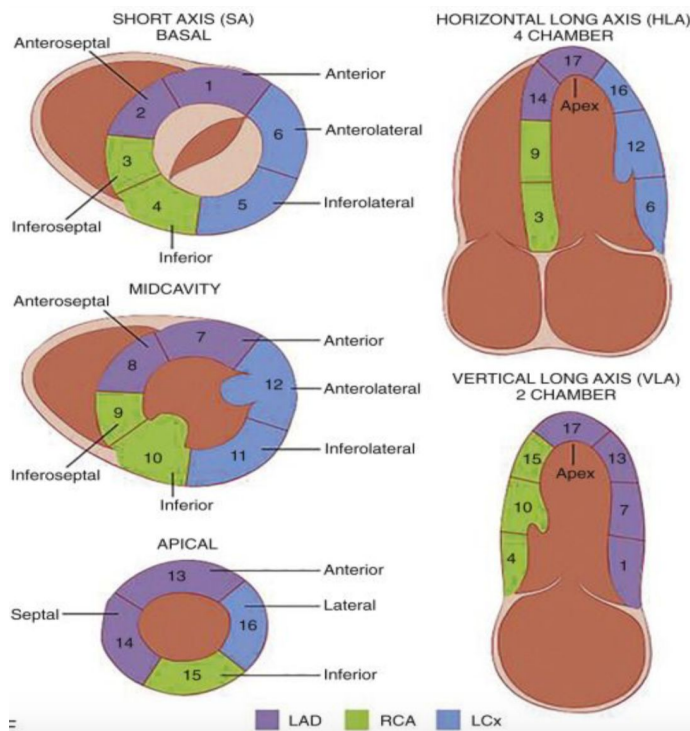
Echocardiogram

It has superior temporal resolution so if you want to assess something moving very fast like cardiac valves



[Video](#)

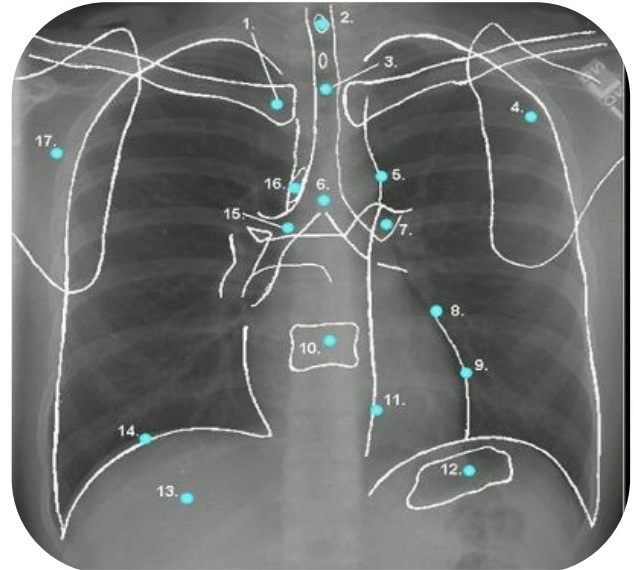
» 17 segment model



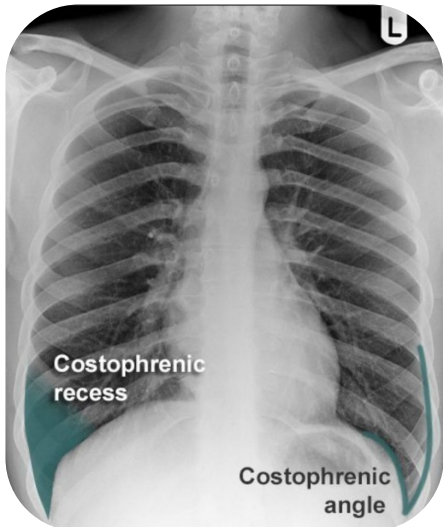
Summary

- | | |
|-----------------------------------|-----------------------|
| 1- Clavicle | 10- Vertebral body |
| 2- Spinous process | 11- Descending Aorta |
| 3- Trachea | 12- Gastric fundus |
| 4- Scapula | 13- Liver |
| 5- Aortic Arch | 14- Rt. Hemidiaphragm |
| 6- Carina (Bifurcation) | 15- Rt. main bronchus |
| 7- Pulmonary Trunk | 16- Azygos vein |
| 8- Lt. Cardiac border (atria) | 17- Scapula |
| 9- Lt. Cardiac border (ventricle) | |

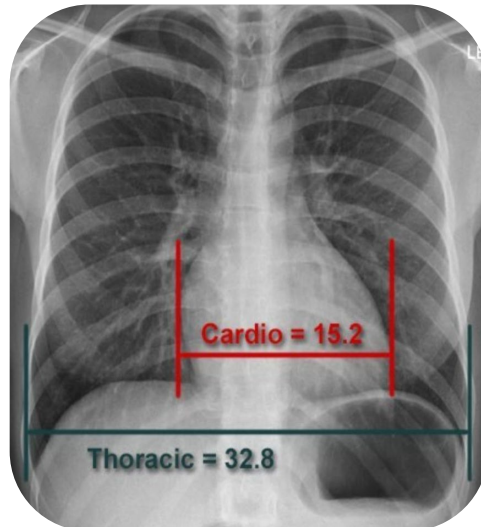
Chest X ray anatomy



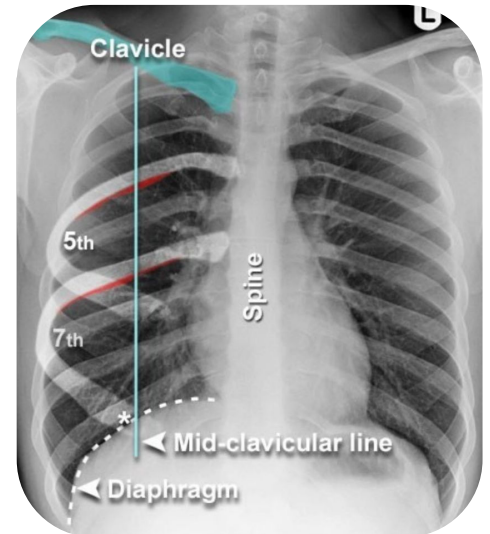
Points to consider when looking at common CVS and Chest pathologies



If there is blunting of costophrenic angle, it may indicate pleural effusion or hematoma



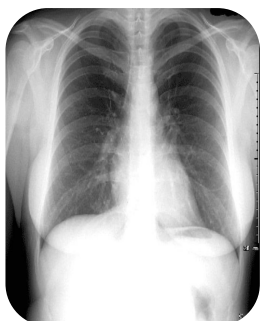
Posterior anterior (PA) view
 Cardiothoracic ratio: if less than 50% then is normal, greater is considered cardiomegaly



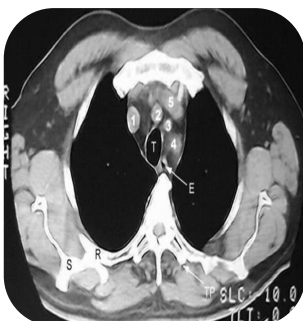The diaphragm should be intersected by the 5th to 7th anterior ribs in the midclavicular line. Less is a sign of incomplete inspiration

radiological examinations applied in chest and CVS diseases

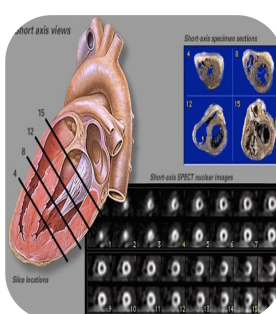
X Ray



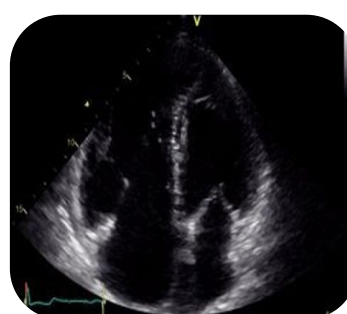CT



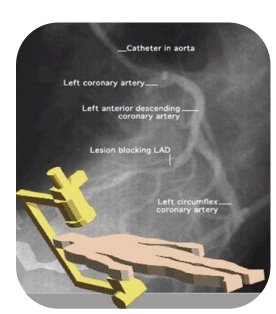
Nuclear medicine



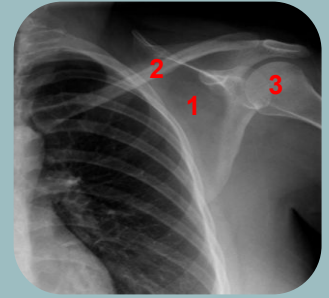
Echocardiogram



catheter angiography

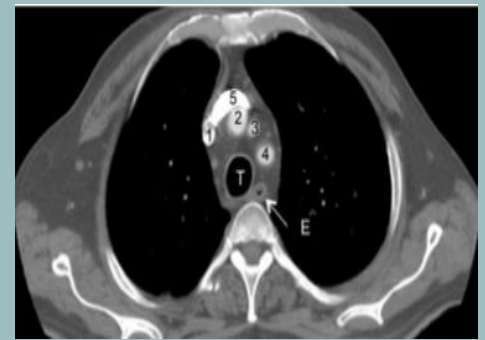


- 1- Indicate the names of the structures in order
- Clavicle, Rib, Humerus
 - Scapula, Clavicle, Humerus
 - Scapula, Rib, Humerus
 - Fat, Clavicle, Joint



- 2- Which of the following conditions can result in a doughnut appearance in cardiac heart Nuclear medicine?
- Cardiomyopathy
 - Hypertrophic Heart Disease
 - Previous MI
 - Normal Heart

- 3-Which of the following seen in this selected cut of CT scan of the chest is correct ?
- No.5 refers to the right brachiocephalic artery
 - No.1 refers to Azygos vein
 - No.4 refers to left superior vena cava
 - No.3 refers to left common carotid artery



- 4- Blunting of the costodiaphragmatic recess indicates
- Open pneumothorax
 - Pleural Effusion
 - Pleuritis
 - Pulmonary edema

- 5-Thickening of the paratracheal stripes indicates
- Bronchitis
 - Injury
 - Lymphadenopathy
 - Normal variation

- 6-Which of the following cardiothoracic ratios is the cut off point that marks cardiomegaly
- Greater than 50%
 - Greater than 40%
 - Greater than 60%
 - Greater than 30%

- 7- Which of the following is correct regarding the right and left hilar points?
- Left hilar point is higher
 - Right hilar point is higher
 - They're at the same level
 - Variations can occur