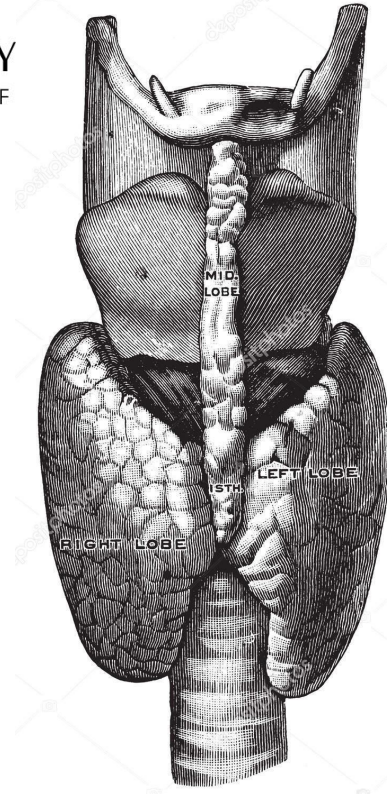


[Video link](#)

[Editing file](#)



REVIEWED BY  
ABDULAZIZ ALSAIF



# Airway obstruction I&II

Presented by Dr. Ahmed alammam

## Lecture Objectives:

- ★ Airway Obstruction I
  - Causes of airway obstruction (congenital and acquired)
  - Signs and symptoms
- ★ Airway Obstruction II
  - Investigation of airway obstruction Radiology illustration
  - Medical and surgical treatment
  - Operations ( indication, procedure and complication) tracheostomy, cricothyroidotomy, intubation, choanal atresia repair etc..

## Color Index:

Important Original content Doctor's notes<sup>439</sup> Doctor's notes<sup>441</sup> Golden Notes Extra

# Airway Obstruction

## ● Signs and symptoms:

- Respiratory distress (tachypnea, tracheal tugging, intercostal or substernal retractions) (the most worrisome).
- Choking/gagging (obstruction)
- Stridor/wheezing
- Hoarseness, dysphonia, aphonia
- Severe or barking Cough
- Cyanosis
- Neck bruising/emphysema (secondary to trauma or surgery)
- Rapid swelling in the neck or large mass

## ● History:

- 4 landmarks: breathing, swallowing, voice, sleeping)
- Onset (sudden vs gradual), duration, progression, constant vs intermittent
- **Stridor** (nature), Voice
- Positional
- Preceding infections (URTI) or trauma
- Associated symptoms (fever, cough, **dysphagia**, odynophagia, drooling, choking, dysphonia, apnea, cyanosis)
- Past medical & surgical history (including history of head & neck radiation)
- Allergies
- Medications (ACE inhibitors → they cause angioedema)
- Family history (head & neck cancer, genetic disorders)
- Social history (smoking, EtOH, drugs; alcohol + smoking are associated with an increased risk for certain types of cancer)
- Perinatal history (in children under 14 years; so ask about any complications during birth or ICU admissions)

## ● Physical examination:

- Vitals
- General appearance and breathing pattern
- Chest auscultation (some sounds can't be differentiated just by listening to it so we need to auscultate)
- Focused head and neck exam:
  - **Craniofacial anomalies, Cutaneous lesions**
  - **Cranial nerves**
  - **Nose:** we have 2 kind of examination. 1) Anterior rhinoscopy: looking for the nose externally with speculum (anterior nasal area). 2) flexible rhinoscopy: used to see deeper structures pass a flexible suction, napkin/paper test, mirror fog.
  - **Oral cavity:** Mucosa, **floor of mouth** (Ludwig angina, in which the floor of the mouth under the tongue becomes very swollen & stiff, is an emergency), tongue, tonsils and soft palate.
  - **Neck:** Cervical lymphadenopathy, masses, skin changes, edema, bruising, subcutaneous emphysema.
  - **Flexible rhinolaryngoscopy: passing scope to visualize nasopharynx, deeper oropharynx, hypopharynx and larynx.** Bilateral nasal cavities and choana, nasopharynx, oropharynx, larynx (Airway patency, supraglottis, VF mobility) and hypopharynx

# Airway Obstruction

## ● Upper airway sounds:

- **Nasal/nasopharyngeal:** stertor (a snoring sound that comes from the nose (upper source); different from stridor: sound you can hear from larynx or airway (lower source).
- **Oropharynx:** gurgly
- **Supraglottis:** inspiratory stridor (it happens when you're taking a breath in, but as you breathe out the force opens up the airway.. It usually happens when the narrowing is due to something *mobile*), feeding issues (ex: laryngomalacia)
- **Glottis:** inspiratory or biphasic (it happens when the airway obstruction is *fixed*; such as in stenosis) stridor, hoarseness
- **Subglottis:** Biphasic stridor, barking cough
- **Tracheobronchial (lower airway):** Expiratory stridor, wheezing

## ● Investigations:

- Labs: CBC, ABG, VBG, electrolytes, ESR/CRP
- CXR
- Lateral neck X-ray
- CT/MRI
- Angio
- Modified Barium Swallow (MBS)
- Barium swallow/ Esophagram
- Pulmonary function tests (PFTs)
- FNA or biopsy

MBS is more common in ENT than barium swallow. MBS allows you to look side view up until the upper esophageal sphincter while giving the patients fluids of different consistencies & you look for any leakage. Barium swallow is more common in general surgery of internal medicine, & it is performed by radiology

## ● Differential diagnosis(KITTENS Method):

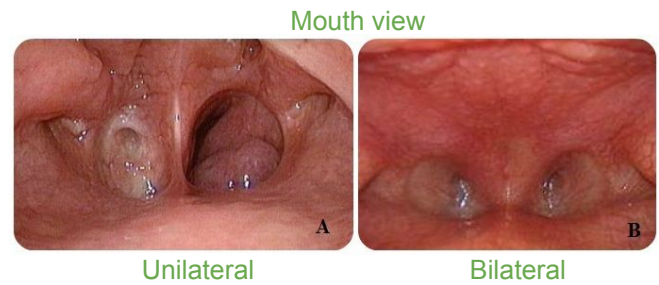
TABLE 3-3. Differential Diagnosis of Upper Airway Obstruction: KITTENS Method

	(K) Congenital	Infectious & Idiopathic	Toxins & Trauma	Tumor (Neoplasia)	Endocrine	Neurologic	Systemic/Psychiatric
<b>Above Larynx</b>	Micrognathia Macroglossia Choanal atresia Lingual thyroid Nasoseptal deformity	Retropharyngeal abscess Peritonsillar abscess Mononucleosis Diphtheria	Facial fracture Retropharyngeal hematoma	Juvenile nasopharyngeal angiofibroma Neurogenic nasal tumors	Myxedema	Posteriorly displaced tongue Central sleep apnea	Allergic rhinitis Granulomatosis with polyangiitis (Wegener's) Obesity (obstructive sleep apnea)
<b>Supraglottic</b>	Laryngomalacia	Epiglottitis	Intubation trauma	Squamous cell carcinoma			Sarcoidosis
<b>Glottic</b>	Glottic web Laryngeal atresia Vocal fold immobility	TB laryngitis Laryngeal diphtheria	Laryngeal fracture Foreign body	Respiratory papillomatosis Squamous cell carcinoma		Vocal fold paralysis	Hereditary angioedema
<b>Subglottic</b>	Vascular ring and aortic arch anomalies Tracheoesophageal fistula Subglottic stenosis	LTB (Croup)	Subglottic stenosis Thyroid or neck masses (extrinsic compression)	Subglottic hemangioma		Respiratory muscle paralysis (eg, Guillain-Barré syndrome)	Granulomatosis with polyangiitis (Wegener's)
<b>Tracheo-bronchial</b>	Tracheomalacia Vascular rings	Tracheitis Bronchitis	Foreign body	Mediastinal, tracheal, or bronchial tumors			External compression (goiter) Asthma

# Congenital

## Choanal atresia:

- Failed recanalization of the nasal fossae during fetal development. (The nasal choana is the joint in the back of the nose between the nasal cavity & nasopharynx)
- Nasal Choana occluded by bone, membrane or **mix** of both (most common)
- Unilateral (it doesn't affect the patient too much) vs bilateral (the patient will be in distress from birth)
- Associated with CHARGE syndrome
- SSx:**
  - Unilateral: (discharge, congestion)
  - Bilateral: **Emergency** (infants are obligate nasal breathers), **cyclical/paradoxical cyanosis** (the baby breathes with its nose & get cyanosed, but when they open their mouth to breath (cry), they turn pink), feeding difficulty
- Diagnosis:** Respiratory distress, fail to pass suction (if the patient had unilateral choanal atresia, most likely they will not be diagnosed early unless the nurses were trying to pass suction for any reason & weren't able to get in), CT.
- Treatment:**
  - Unilateral: elective repair in childhood (you can delay to 5 years & according to the symptoms)
  - Bilateral: secure airway (intubation vs mcgovern nipple) and repair in infancy

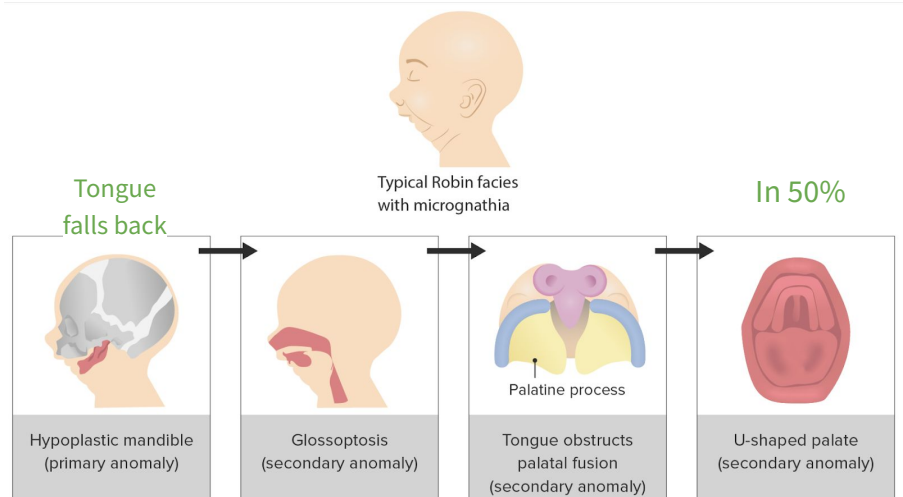


## Charge syndrome:

C	Coloboma	
H	Heart Defects	
A	Atresia Choanae	
R	Retardation of Growth/Development	
G	Genital/Urinary Abnormalities	
E	Ear Abnormalities/Deafness	

## Micrognathia:

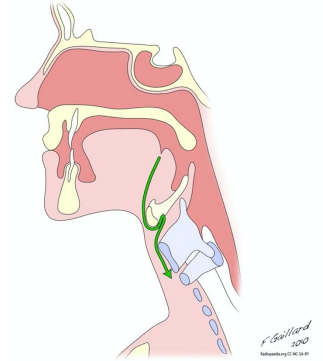
- Pierre Robin sequence
- As the baby is developing in utero, the mandible doesn't fully develop leading to:
  - Glossoptosis (tongue falls back as nothing is pushing it forward)
  - Airway obstruction
- Emergency at birth, diagnosed by US.



# Congenital

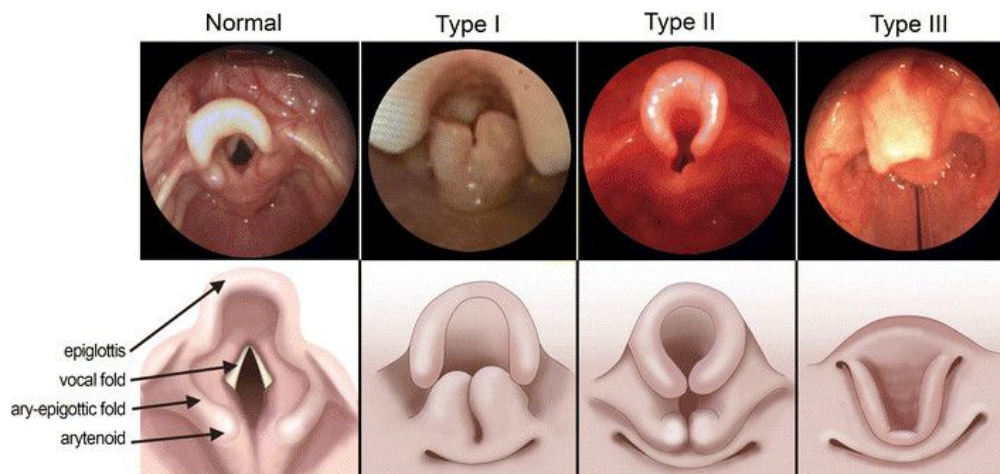
## ● Lingual thyroid:

- Rare
- Ectopic thyroid **back of the in the tongue.**
- **Pathophysiology:** lack of caudal migration from foramen cecum
- **SSx:**
  - Asymptomatic
  - Dysphagia
  - Airway obstruction (if it's large)
- **US Neck:** Usually no thyroid (it's important to do an US to check if there's a thyroid)
- **Treatment:** Surgical when symptomatic (will need thyroid supplement for life)



## ● Laryngomalacia:

- Most **common** cause of infant noisy breathing (**stridor**)
- Soft **floppy** larynx
- Associated with secondary airway lesions (subglottic stenosis, tracheomalacia)
- Develops by 2-4 weeks of age, 70% improve by **1 year** and 90% by 2 years.
- **SSx:** inspiratory stridor (maybe louder when feeding, crying or supine).
  - **Concerning symptoms:** **Failure to thrive** (poor weight gain), **apneas** or cyanosis, work of breathing.
- **Diagnosis:** with flexible rhinolaryngoscopy.
- **Treatment:** Observation mostly, may need thickeners (because it is associated with aspiration) or anti-reflux, rarely surgery if concerning symptoms (supraglottoplasty (relief the epiglottis airway or pull upward (mainly to open airway)).



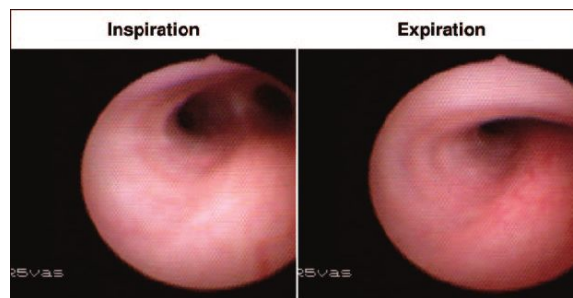
# Congenital

## ● Vocal fold paralysis:

- Second most common cause of neonatal stridor
- Unilateral (voice problems + risk of aspiration) or bilateral (breathing problems more than voice problems as the vocal cords will be close to each other)
- **SSx:** stridor, weak cry or voice, feeding difficulty, aspiration, respiratory distress
- **Etiology:** Most common idiopathic, can be from birth trauma (forceps delivery), iatrogenic (cardiac surgery left side paralysis bcs left laryngeal nerve is longer, TEF), neurological (Arnold chiari, hydrocephalus)
- **Treatment:** (No spontaneous recovery after 1-2 years)
  - **Unilateral:** thickening feeds, NG/Gtube, injection laryngoplasty (temporary), medialization, thyroplasty, arytenoid adduction, reinnervation.
  - **Bilateral:** Tracheostomy, Arytenoidectomy, lateralization suture, reinnervation.

## ● Tracheomalacia:

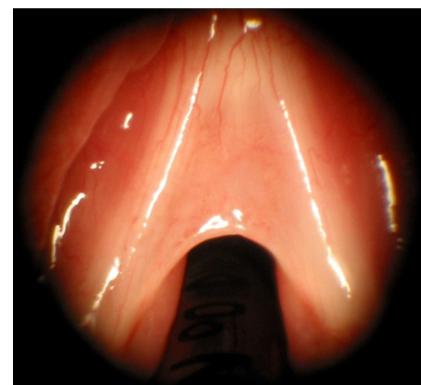
- **Pathophysiology:** Poor cartilaginous strength, low tone (soft and floppy)
- Associated with prematurity and TEF (tracheoesophageal fistula) weaken the posterior wall.
- **SSx:** Expiratory or biphasic stridor, barky cough, exacerbated with infections.
- *Self limiting* as cartilage stiffens with growth.
- **Treatment:** depends on the symptoms: observation, noninvasive ventilation, stenting, tracheostomy



In expiration, as the pressure is gone, the airway is almost completely closed off

## ● Glottic web:

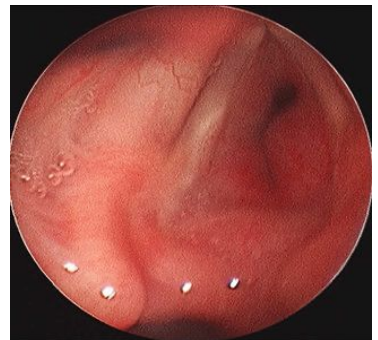
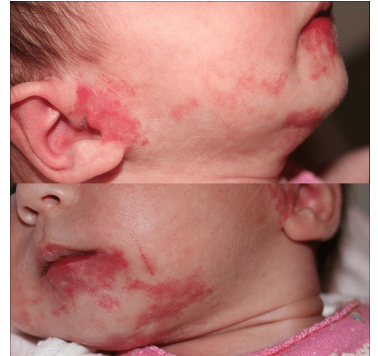- Rare
- **SSx:** the webs can be minimal or completely closing off the larynx
  - Often present as a voice problem. (ex: hoarseness)
  - Dysphonia/aphonia (because the vocal cords cant meet & produce phonation)
  - Airway obstruction (depending on grade)
- Maybe associated with subglottic stenosis
- **Treatment:** Surgical endoscopic vs open.



# Congenital

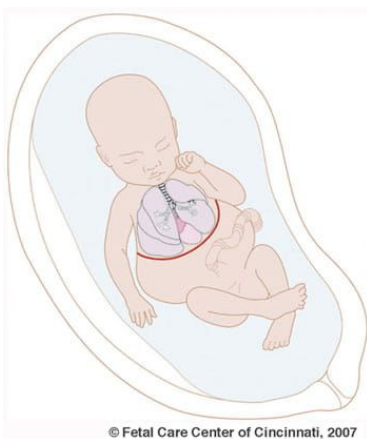## ● **Subglottic hemangioma:** (imp for SAQ)

- Benign tumor of infancy that may result in airway obstruction.
- Proliferation at 1-3 months of age then involution by 1 year of age.
- High association with **cutaneous hemangiomas** in the 'beard' distribution. (V2 & V3 maxillary and mandibular)
- **SSx:**
  - 'recurrent croup'
  - Stridor
  - Airway obstruction
- **Treatment:**
  - **Intralesional steroids** (inject steroids while you're in with endoscopy 24-48 will see progression)
  - Laser
  - systemic steroids (side effects)
  - **Propranolol**
  - rarely tracheostomy (used to be go to treatment)



## ● **Laryngeal atresia** (larynx is completely closed) or **tracheal agenesis** (trachea never formed completely) aka **congenital high airway obstruction (CHAOS):**

- Rare
- Detected on prenatal US (flat diaphragm, hydrops, hyper echogenic lungs).
- Delivery planned through **Ex-utero intrapartum procedure (EXIT)** to address airway.
- With laryngeal atresia a tracheostomy maybe life saving, endoscopic balloon dilation described.
- With tracheal agenesis high **mortality rate** (you can't do a tracheostomy)



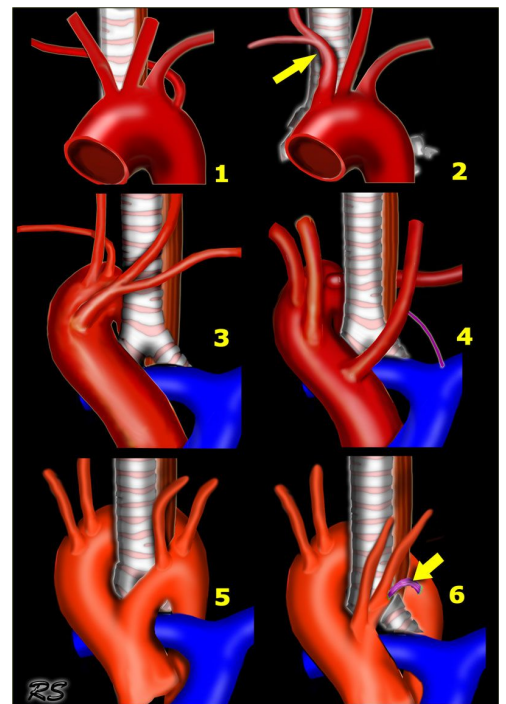
# Congenital

## ● Vascular rings:

- Rare
- **SSx:**
  - Asymptomatic (incidental finding)
  - Wheezing
  - Stridor
  - Dysphagia
  - recurrent resp infections

### Types:

1. **Aberrant Right subclavian artery (Most common arch anomaly, Not a true ring, Usually asymptomatic)**
2. **Innominate artery compression syndrome** (compresses the trachea anteriorly).  
Innominate artery malpositioned causes compression on the trachea.
3. **Right Arch Mirror Image** (Asymptomatic, Associated congenital heart disease in 98%, mostly tetralogy of Fallot).
4. **Right Arch with Aberrant left subclavian** Not true ring, subclavian goes between esophagus and trachea, that will cause dysphasia.
5. **Double Aortic Arch** (Complete ring encircles esophagus and trachea, **most common symptomatic**, Four vessel sign). Cause airway compression bc it going around trachea. It repaired by cardiac surgery.
6. **Double Arch with Atretic Segment**

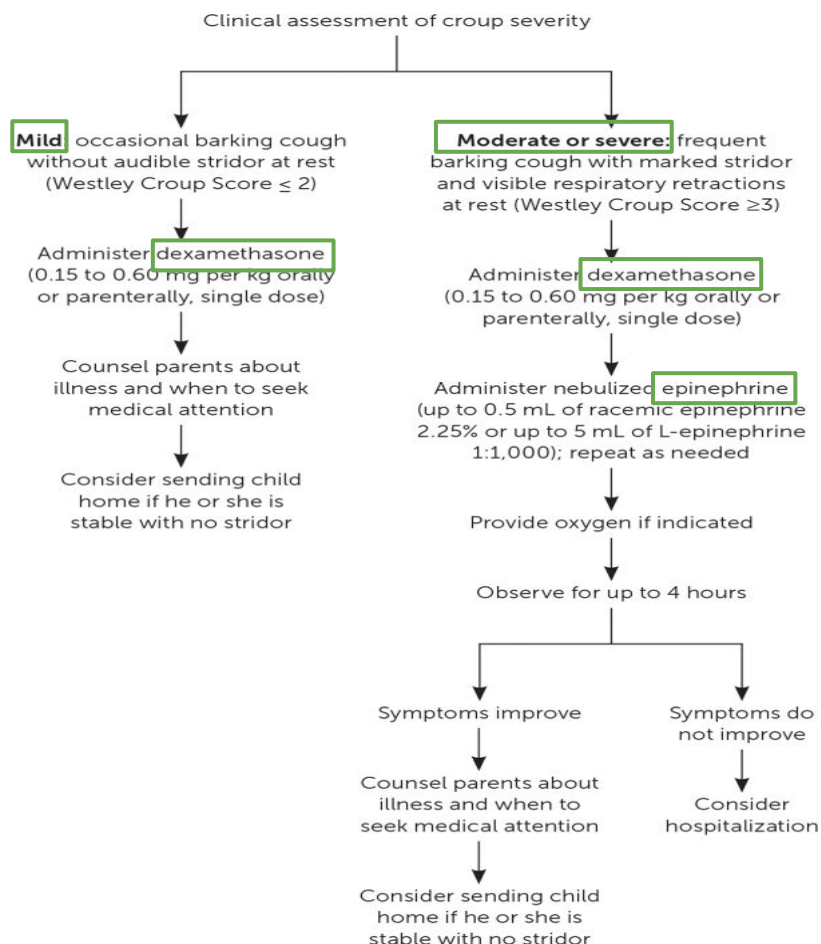




# Infectious

## ● Laryngotracheobronchitis (CROUP):

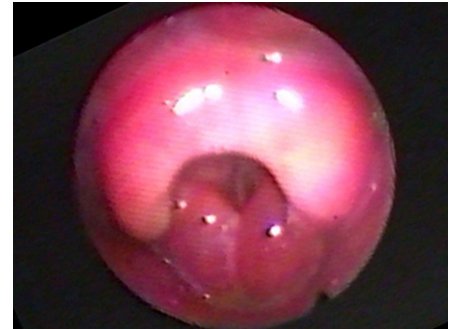
- Common respiratory illness from **6 months to 3 years** (can occur up to 6 years). - if it occurs outside of this age range it is called an atypical presentation
- **Etiology:** Most common **Parainfluenza Type 1,2**, Influenza, adenovirus, RSV, rhinovirus. Bacterial infections are possible but they're more dangerous
- **Pathophysiology:** Edema and inflammation of the larynx, trachea and bronchi (most common subsite affected subglottis).
- **SSx:**
  - Inspiratory or biphasic stridor
  - Barky cough
  - Low grade fever
  - Hoarseness
  - Dyspnea
- Can be associated with *bacterial tracheitis* (high grade fever, ill child) → patient will be very sick
- **Diagnosis:** made **clinically**, X-ray **steeple sign**. (Not specific)
- Most cases *mild self limiting* (most are managed in the ER)



# Infectious

## ● Epiglottitis/ Supraglottitis:

- Always comes in exam
- Inflammation of the epiglottis/supraglottis.
- **Etiology:** Was *haemophilus influenzae* type b but streptococcus pneumonia more common now because of vaccines
- **SSx:** Stridor, sore throat, dyspnea (sniffing position), respiratory distress, dysphagia, odynophagia, high fever, drooling, muffled voice. Can range from stridor to complete respiratory distress. Most of the time it is an emergency and the patient presents to the ER



## Diagnosis



- Flexible rhinolaryngoscopy
- Lateral neck X-ray (thumb sign)

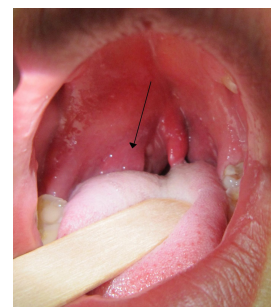
## Treatment



- ABC
- Oxygen
- Hydration
- Monitored airway setting
- Antibiotics
- May need temporary intubation
- Rarely tracheostomy

## ● Peritonsillar abscess:

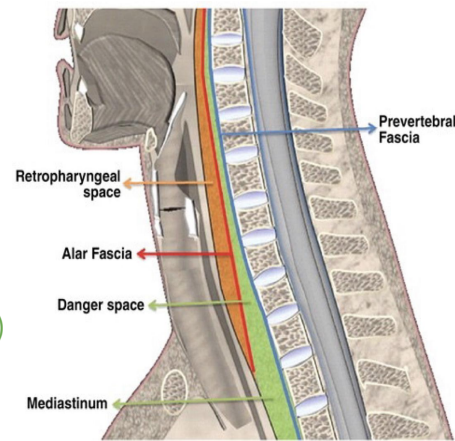
- **Pathophysiology:** Spread of infection outside tonsillar capsule into peritonsillar space vs infection of a peritonsillar minor salivary gland (weber gland).
- **SSx:** the symptoms usually worsen over time: odynophagia, trismus (locked jaw; they can't open it because the muscles are all inflamed), uvular deviation to contralateral side, pharyngotonsillar asymmetry, unilateral soft palate swelling, otalgia, drooling, hot potato voice, locked jaw.
- **Complications:**
  - Airway distress, parapharyngeal or retropharyngeal abscess
  - Internal jugular thrombophlebitis (Lemierre's syndrome)
- **Treatment:**
  - Aspiration vs I&D, antibiotics
  - Elective tonsillectomy after 2 episodes can be offered



# Infectious

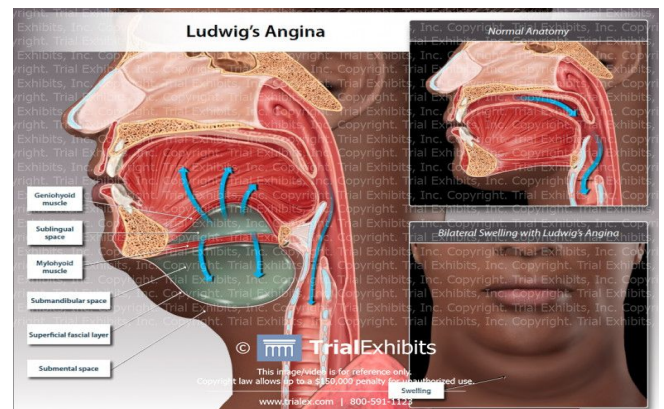
## ● Retropharyngeal abscess:

- More common in children. Can present in adult.
- In children the diagnosis is made by neck x-ray, in adult by CT scan.
- The back of the neck has 3 spaces separated by fascia:
  1. Retropharyngeal space: from *skull base to mediastinum*
  2. Danger space, behind alar fascia (it is catastrophic if infection reaches it)
  3. Prevertebral fascia
- **SSx:**
  - Odynophagia
  - Hot potato voice
  - Drooling
  - Stridor
  - Spiking fevers
  - Stiff neck (can't look up because of the inflammation affecting their muscles)
- **Complications:** (considered an **emergency** because of all the complications): mediastinitis (50% mortality), respiratory distress, aspiration pneumonia (the abscess ruptures in the mouth & gets aspirated), spread into *danger or prevertebral space*.
- **Treatment:**
  - Urgent transoral or cervical drainage



## ● Ludwig angina:

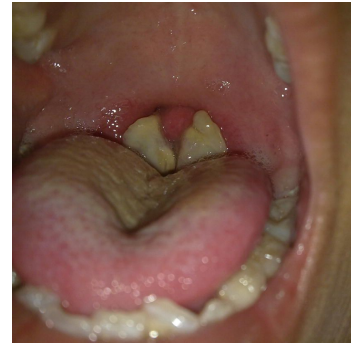- Potentially life-threatening cellulitis resulting from **bilateral infection** of the *submandibular space*, the *sublingual space* and the *submylohyoid (submaxillary) space*.
- **Etiology:** Usually from an **odontogenic** source (2nd or 3rd lower molar), other causes (peritonsillar abscess, fracture, trauma..etc.). **poor dental hygiene**
- **Organism:** Streptococcus viridans most common, staph aureus, anaerobes, mixed (polymicrobial).
- **SSx:**
  - Fever
  - Toxic appearing
  - Dysphagia
  - Pain
  - Drooling
  - muffled voice
  - neck edema
  - woody floor of mouth (**rock solid**)
  - tongue replaced *posterior superior*.
- **Treatment:**
  - **ABC** (securing the airway is the primary concern)
  - monitored setting
  - aggressive broad spectrum antibiotics



# Infectious

## ● Diphtheria:

- **Etiology:** *Corynebacterium diphtheriae*
- Highly contagious
- Rare in most countries since vaccine but still endemic in many developing nations.
- **SSx:**
  - Sore throat
  - Dysphagia
  - Low grade fever
  - **Pseudomembrane** on tonsils
  - Palate edema
  - **Neck swelling & it is hard (called bull neck)**
- **Exotoxin** released in the blood may result in cardiac and neurologic complications.
- **Treatment:**
  - Antibiotics (penicillin or erythromycin)
  - Antitoxin (depending on the severity of symptoms)



## ● Recurrent respiratory papillomatosis (RRP):

- Infection of the upper aerodigestive tract by **human papilloma virus (HPV)**.
- Larynx most common location (it can affect the voice or be more aggressive, affecting the airway & causing an airway obstruction)
- Juvenile vs adult onset, *juvenile more aggressive*.
- Transmission in utero or at birth, **risk factors** (lower SE status, first time mother, mother has condylomata acuminata at time of birth).
- Most common types **6 and 11**, rate of malignant transformation <1% (subtype 116,18).
- **SSx:** Respiratory (more urgent) vs voice.
- **Treatment:**
  - Surgical mostly (conservative high risk of scarring + webs)
  - Some role for medical and adjuvant treatments
  - Prevent by taking HPV vaccine.











# Toxins and Trauma

## ● Subglottic stenosis:

- Congenital (presents like CHAOS) vs acquired vs idiopathic (happens mostly in 30-40 year old women)
- Most commonly due to trauma (recurrent or prolonged intubation)
- **SSx:** biphasic stridor (because it is a fixed lesion), may have recurrent croup (a child might present with recurrent croup, ask for intubations in the history), dyspnea, hoarseness.
- **Treatment:**
  - Observation for mild
  - Medical supportive treatment with illnesses
  - Endoscopic balloon dilation
  - Surgical (laryngotracheoplasty, cricotracheal resection) → to expand the airways

## Cotton-Myer Classification of Subglottic Stenosis

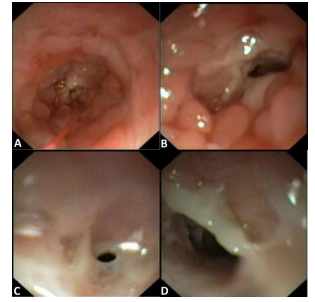
Dr said its important for exam, example question : what is diagnosis ? subglottic stenosis , what is the grading system? mention the grade and percentage **SAQ**

Grade	From	To	Examples
Grade I Mild; we mostly observe	 No Obstruction	 50% Obstruction	
Grade II Endoscopic interventions	 51% Obstruction	 70% Obstruction	
Grade III Open procedure	 71% Obstruction	 99% Obstruction	
Grade IV Open procedure	No detectable lumen An emergency, do tracheostomy		

## ● Laryngeal trauma:

- **Mechanism:** MVA, assault, clothesline injury, penetrating injury, neck injury (hockey).
- **SSx:** dysphonia, dysphagia, cough, stridor, dyspnea, hemoptysis, pain, tenderness, neck deformity or ecchymosis, subcutaneous emphysema (bcs of complete laryngeal separation).
- **Types:** 5 groups ranging from minor injury (bruising + mild dysphonia) with no fracture to complete laryngotracheal separation & airway obstruction
- **Management (depends on the grade):** ABC, Voice rest, corticosteroids, antireflux, Open reduction and repair, tracheostomy.

# Toxins and Trauma

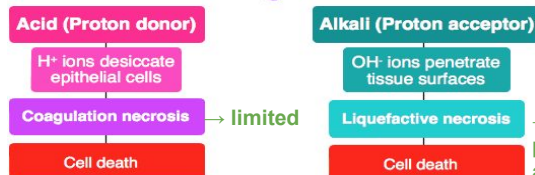


## ● Foreign bodies:

- A significant cause of death in young children <5 years old.
- **Foods**, coins, toys, balloons all constitute as foreign bodies
- Apples are the most common cause of food related fatality because they're given in big chunks & they are hard so they can completely block the airway if they fall in it, carrots, cherry tomatoes, grapes.
- **SSx:**
  - History of sudden onset choking - it is important to note that food can fall into the airway without causing the patient to choke. Little pieces of food can fall into the airway and cause obstruction only manifested by recurrent pneumonias (ex: whole nuts). If they do not get investigated properly, the child could develop and bronchoesophageal fistula & require an NG tube to be fed. All of that can happen without choking.
  - Coughing
  - Wheezing
  - Dyspnea
  - May also be *asymptomatic*.
- CXR lateral decubitus not always utilized, maybe **normal**, may show air trapping.
- If *suspicious* must have a **diagnostic bronchoscopy** to rule out aspiration.
- **Most common site: right bronchus.**
- **Caustic injection** is mostly *accidental* in young children, maybe *intentional* in older.
- Common between 1-5 years old

## Caustic ingestion

MUCH more dangerous



### Extent of injury by caustic agents determined by

- Duration of tissue contact
- Ability of substance to penetrate tissues
- Volume
- pH
- Concentration

### Clinical

#### GI tract

- Severe pain of lips, mouth, throat, chest, abdomen
- Drooling, dysphagia, odynophagia
- Vomiting, hematemesis

#### Respiratory tract

- Hoarseness, stridor
- Epiglottitis, laryngeal edema and ulceration
- Pneumonitis, Impaired gas exchange

#### Eyes

- Pain, tearing, irritation
- Clouding of cornea, decreased vision

#### Skin

- Dribble marks on the face, chest, and legs
- First, second, or third degree burns


**The presence or absence of oropharyngeal burns in children does not predict the presence of esophageal or gastric burns**

### Diagnosis

- Endoscopy
  - Should be performed within 12 hrs and not > 24 hrs post-ingestion
- Laparoscopy/Laparotomy if endoscopy cannot be performed
- X-ray
- CT scan

### Management

- Decontamination
- Airway
- Supportive
- Dilution (rare)
- Surgical intervention



# Tumors

## ● Thyroid mass:

- Benign vs malignant or multinodular goiter.
- Incidence of thyroid cancer is increasing.
- **Second** most common cancer in females in **KSA** after breast cancer.
- **SSx:**
  - Hypo/hyperthyroid symptoms sometimes they don't have symptoms.
  - Compression symptoms (breathing, swallowing)
  - **Incidental: had imaging for something else.**
- **Investigations:** Thyroid panels, thyroid US, FNA when indicated.
- **Treatment:** Medical vs surgical.

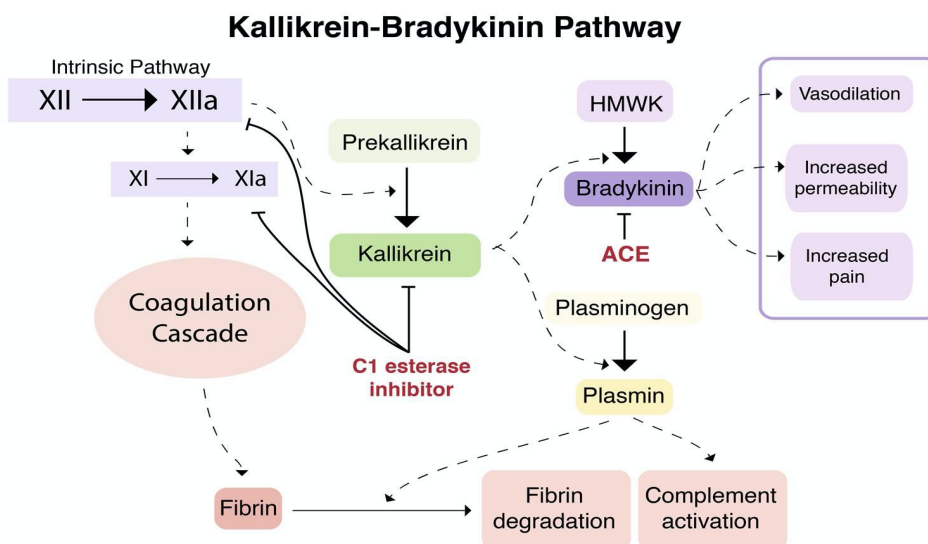
## ● Squamous cell carcinoma:

- Most common head & neck cancer (90%).
- Oral cavity (tongue) most common site → you see it as an ulcerating or fungating mass
- Arises from squamous cells in the outer layer of the skin and mucous membranes in the head and neck area.
- **HPV** contributing to cancer in younger patients.
- **Associated with smoking/alcohol**
- **SSx:** can present in any way
  - Pain
  - Bleeding
  - Trismus
  - Otagia
  - Hoarseness
  - Dyspnea
  - Dysphagia
  - **Neck mass**
- Metastasis to lymph nodes and distant.
- **Treatment:** Depends on site and stage from monotherapy to multi modality treatment.

# Systemic

## ● Hereditary angioedema:

- **Definition:** Hereditary *C1 esterase inhibitor deficiency* that leads to recurrent angioedema *without* urticaria or pruritus (so you know it's not an anaphylactic reaction)
- Autosomal Dominant.
- **Triggers:**
  - Physical: dental work, surgery, intubation
  - Medical:
    - **Angiotensin-converting enzyme (ACE) inhibitors**
    - Tamoxifenestrogen-containing medications (e.g., hormone replacement therapy and oral contraceptives)
- **Pathophysiology:**



- **SSX:**
  - Fatigue
  - Nausea
  - Flu like symptoms
- Angioedema (**skin**-face/genital/extremities, **Upper airway**- lips, tongue, soft palate, larynx, **GI**-bowel edema)
- **Labs:** decreased C4 levels, Low or normal C1 inhibitor.
- **Treatment:**
  - **ABC**
  - Plasma derived C1 inhibitor
  - Plasma kallikrein inhibitor (ecallantide)
  - Bradykinin receptor antagonist
  - FFP



# Systemic

## ● Obstructive sleep apnea:

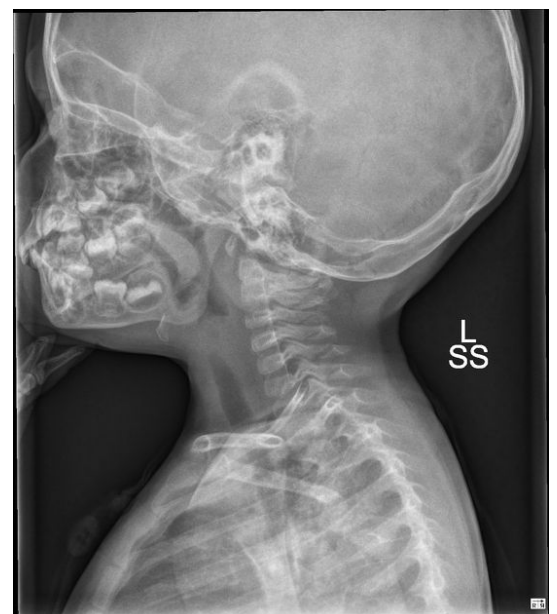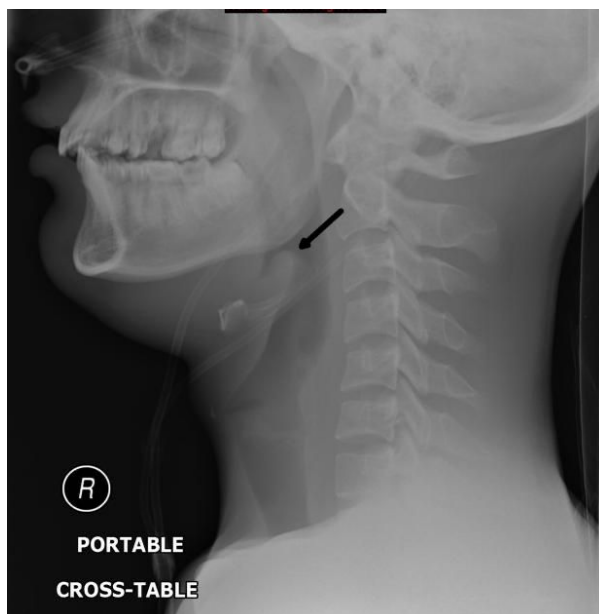
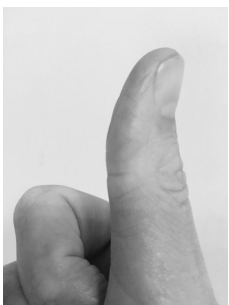
- Obstructive in nature (respiratory effort), can have central element
- Risk factors: obesity, tonsillar adenoid hypertrophy
- Severity calculated by AHI (apnea-hypopnea index) - differs adults from children.
- Calculation via polysomnography (PSG). (best way for diagnosis)
- **Treatments:**
  - Lifestyle modifications (weight loss)
  - Medical (CPAP, Bipap, APAP) most often
  - Surgical (younger)

# Imaging

## ● Epiglottitis

Thumb sign

Classic sign

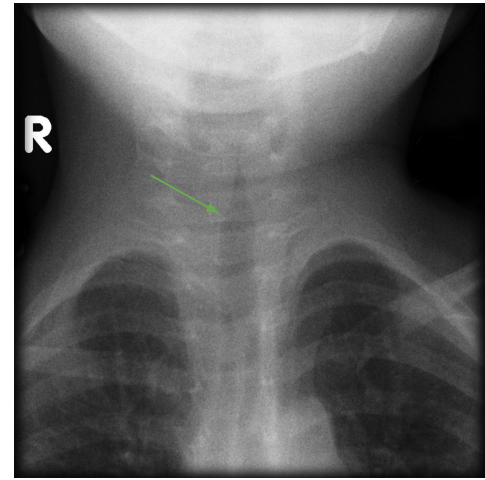
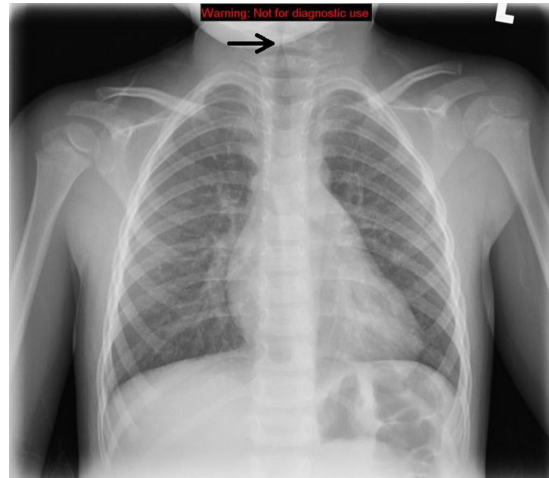


# Imaging

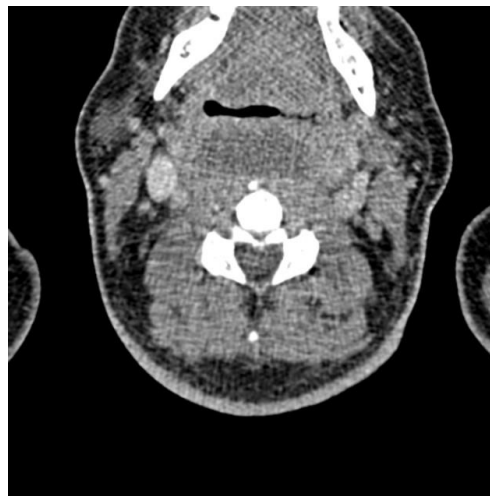
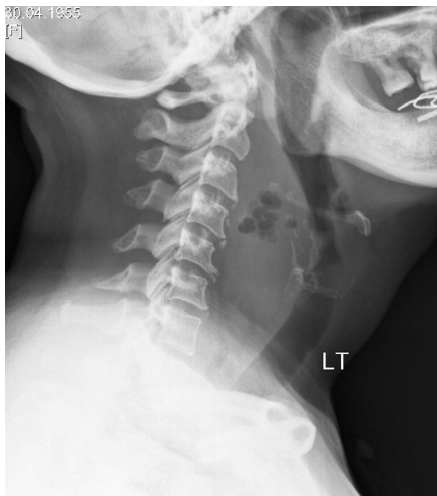## ● CROUP:



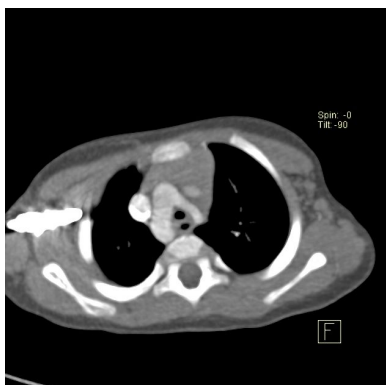
**Steeple sign** is classic for croup but can also happen in subglottic stenosis or any other narrowing in the area, that's why it is mainly a clinical diagnosis



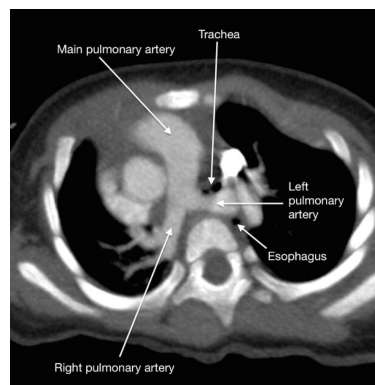
## ● Retropharyngeal abscess:



## ● Vascular ring:



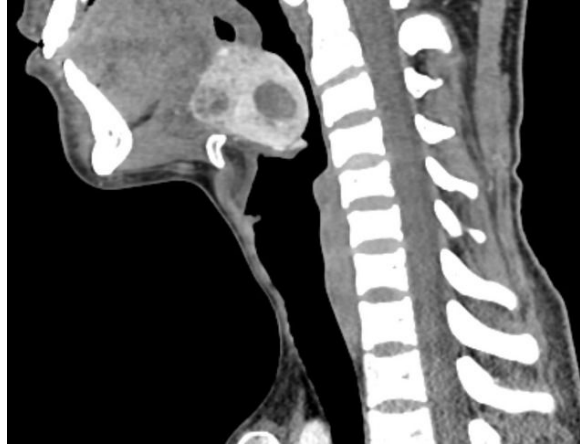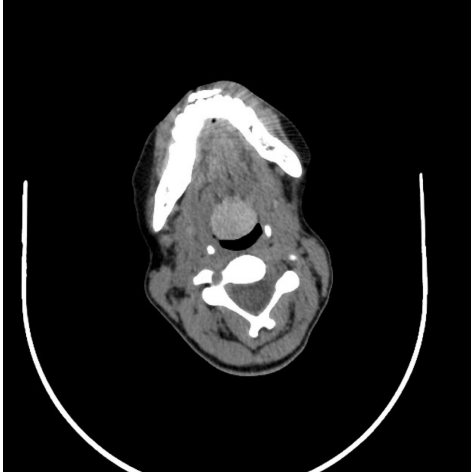
Double aortic arch



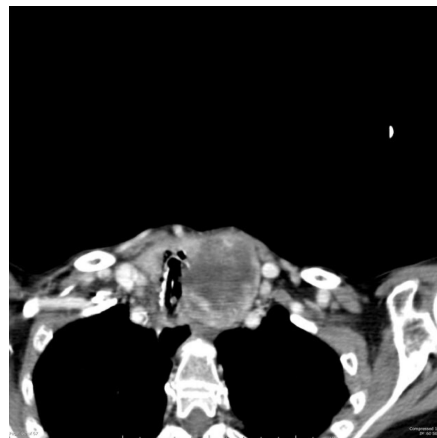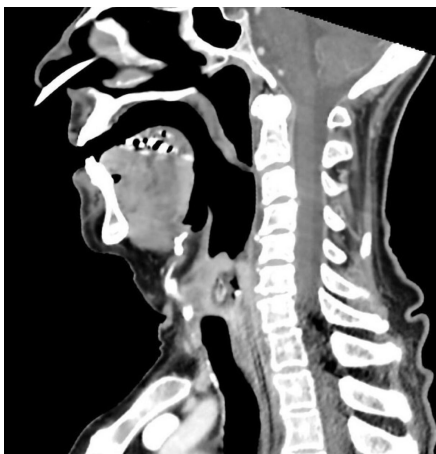Pulmonary sling (anomalous left pulmonary artery)

# Imaging

- **Lingual thyroid:**



- **Cancer:**



# Management

## ● ABC:

### A. Airway and Cervical Spine

- Anoxia can result in death in *4-5 minutes*
- Mask, oral/nasal airway, orotracheal or nasotracheal intubation, cricothyrotomy, urgent tracheostomy.

### B. Breathing

- May impede ventilation: Tension pneumothorax, hemothorax, sucking pneumothorax

### C. Circulation and Hemorrhage Control

- Identify and control
- Recognize Shock (tachycardia, hypotension, skin pallor, lethargy, decrease urine output)

## ● Medical:

- Oxygen (Nasal cannula LF or HF, simple face mask, non-rebreather mask)
- Heliox (80% helium, 20% oxygen) given when there are very narrow spaces as a temporary measure bc oxygen is too big of a molecule to bypass airway, given for 1-2 hrs only.
- Humidification
- CPAP ,BiPAP, APAP
- Corticosteroids
- Nebulized Epinephrine
- Antibiotics

## ● Supraglottic airway:

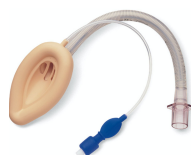- Oral airway



- Nasal trumpet



- Laryngeal mask airway (LMA)



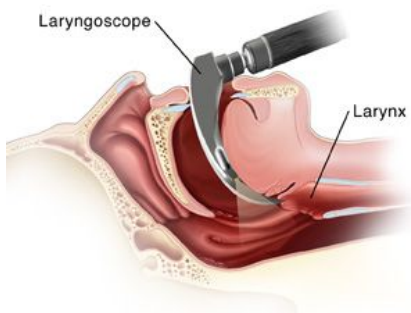
# Management

## ● Intubation:

1. **Anticipate** a difficult airway in these situations and **plan** accordingly to prevent an *airway crisis*.

- Orotracheal intubation (direct laryngoscopy, video laryngoscope)
- Nasotracheal intubation
- Fiberoptic intubation (oral or nasal, awake or sedated)
- Orotracheal intubation over Rigid endoscope
- Surgical airway

## ● Orotracheal Intubation:



Direct laryngoscopy



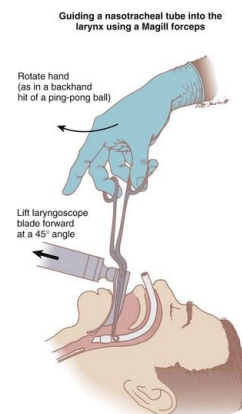
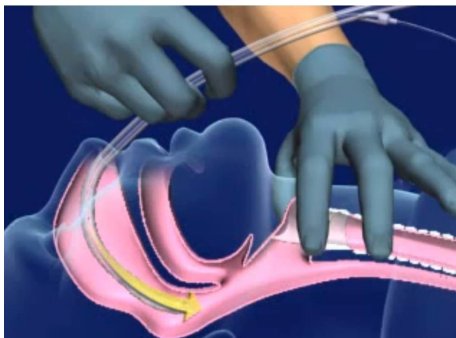
FIGURE 19-18 McGrath laryngoscope.

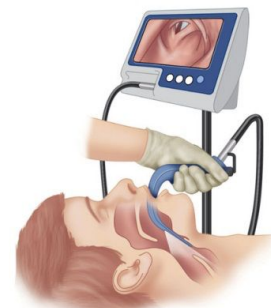

FIGURE 19-19 Glidescope.

Video laryngoscope

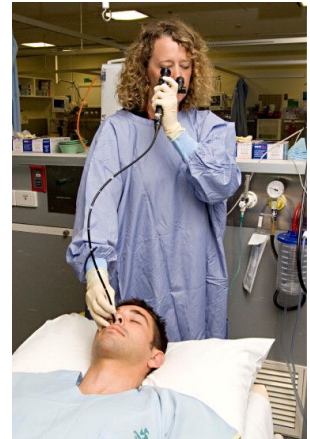
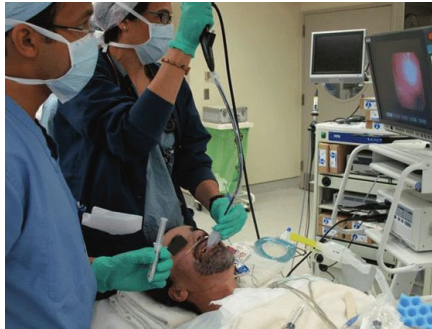## ● Nasotracheal Intubation:



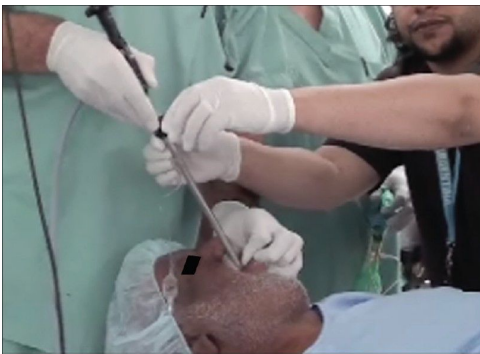# Management

## ● Fiberoptic intubation:

- Can be inserted through the mouth or the nose
- It is useful in difficult intubations
- It can be done for awake or sedated patients



## ● Orotracheal Intubation over rigid endoscope:



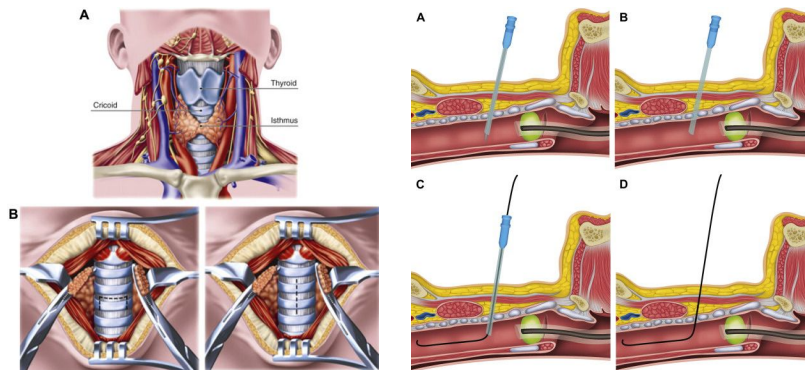
## ● Cricothyrotomy:

- **Temporary** airway in emergency settings.
- Not done in **children**. ( bc of cartilage overlap)
- 50% risk of SGS if not converted early to conventional tracheostomy.
- **Technique:** Vertical skin incision, horizontal incision into the cricothyroid membrane, spread airway open, place cricothyrotomy tube or endotracheal tube.
- **Needle cricothyrotomy:** IV catheter (12 or larger) placed through cricothyroid membrane, needle removed leaving the sheath, connected via IV tubing to O<sub>2</sub> (1 second O<sub>2</sub> injection, 4 second exhalation)- **Can be maintained a maximum of 30 minutes as this is hypoventilation.**
- **Complications:** Bleeding, tube displacement, injury to vocal folds (most common if you're in the wrong area) or posterior tracheal wall, injury to recurrent laryngeal nerves, pneumothorax or pneumomediastinum, stenosis & therefore we must convert it to a tracheostomy

# Surgical

## ● Tracheostomy:

- **Tracheotomy:** Incision (cut) in the trachea.
- **Tracheostomy:** The opening between the trachea and external world.
- **Tracheostomy Tube:** the tube placed into the tracheal opening (cuffed or uncuffed).
- **Indications:**
  - Bypass upper airway obstruction (ex: facial trauma so you can't go through the mouth)
  - Prevent complications from long-term intubations (ulceration, granuloma, stenosis)
  - Allow long term ventilation (mostly in neurological patients)
  - Pulmonary hygiene/toilet ( Tracheobronchial suctioning)
  - Protection from aspiration



Open (horizontal incision) vs Percutaneous (through a needle; not done if the patient is awake)

## ● Complications:

- **Intraoperative:**
  - Hemorrhage
  - Pneumothorax (esp in children since the apices of the lungs are high)
  - Pneumomediastinum
  - Damage to tracheoesophageal common wall (creating TEF) (posterior wall)
  - Fire
- **Early post operative:**
  - Postoperative pulmonary edema (loss of auto-peep)
  - Acute obstruction (mucus plug, blood clot) (might cause death)
  - Tube displacement (false passage) or dislodgment -May result in airway loss
  - Infection
- **Long term:**
  - Tracheal or subglottic stenosis
  - Tracheal innominate artery fistula- TIF (within first 3 weeks) innominate artery crosses the anteriorly to the trachea rubbing against it and might cause huge bleeding if not seen early.
  - Tracheitis
  - Granulation (bleeds, may result in obstruction)
  - Tracheo-cutaneous fistula

# Surgical

## ● Important points:

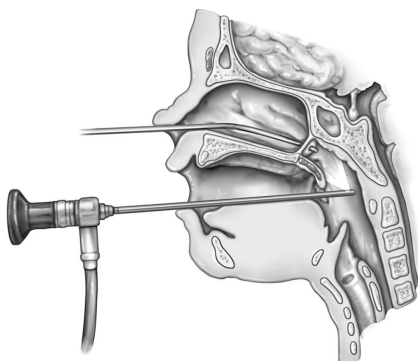
- **Cuff pressure:** should be  $<25$  cm H<sub>2</sub>O to prevent complications (pressure necrosis, TIF, subglottic or tracheal stenosis).
- **Speaking/swallowing valve** eg, Passy-Muir one way valve allows airflow through the valve with inspiration only, closes on expiration to allow airflow through vocal folds and voicing. Should be with a **cuffless tube**.
- **Capping:** preparation for decannulation, should be a **cuffless tube**, close monitoring, patient or present caregiver should be able to remove cap.

Laryngotracheoplasty & cricotracheal resection are 2 potential surgeries for subglottic stenosis repair. Cricotracheal resection is irreversible & only done for certain indications/criteria. The dr showed us videos to explain the procedures

## ● Laryngotracheoplasty


## ● Cricotracheal resection

## ● Choanal atresia repair



Can be approached through the nose or through the mouth. The most important part in a choanal atresia repair bilaterally is to remove the posterior septum as much as you can (posterior septectomy) to allow for a big space and prevent restenosis





# MALE SLIDES

# Airway Obstruction:

## ● Basic anatomy:

Airway anatomy is important because we can get a question as identify

### Endoscopic view of the Larynx:

during OR we see:

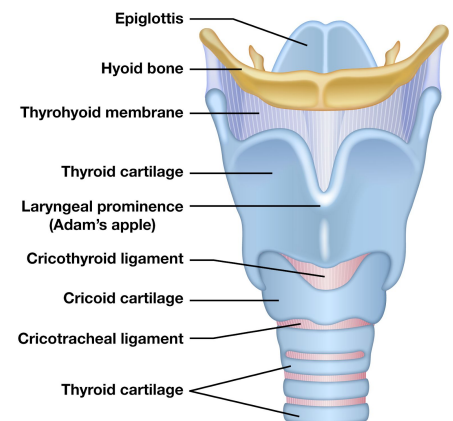
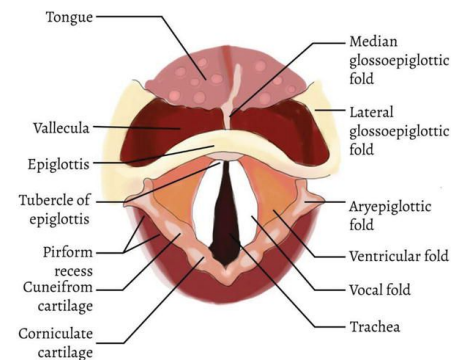
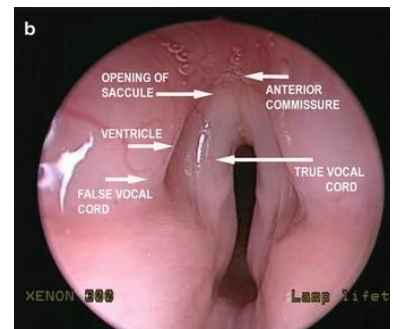
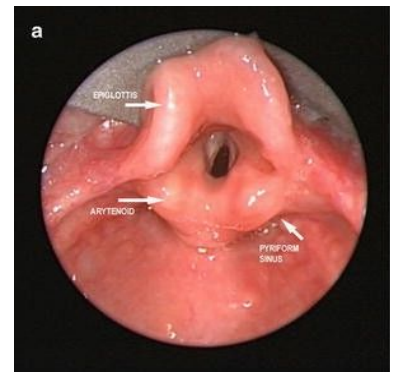
- Epiglottis
- Aryepiglottic fold (imp for cases of laryngomalacia), between epiglottis and arytenoid
- Arytenoid
- Inter-arytenoid area (posterior glottic space) \ (posterior commissure) at level of vocal cord
- Junction of the two vocal cords (anterior commissure) (imp) many student don't know where is it.
- Space between true and false vocal cords is called ventricle

In the anterior view of the larynx:

- thyrohyoid membrane (imp): between hyoid bone and thyroid cartilage.
- cricothyroid ligament (imp): between thyroid and cricoid cartilages.
- Tracheal rings
- Important to know because of procedures done in these areas (cricothyroidotomy and tracheostomy )

### Infant & Pediatric Larynx:

- Position is higher at birth compared to adults. what is the benefit? to suck "eat" and breath at the same time) (C1-C4)
- Epiglottis lying at the nasopharynx behind the soft palate: makes the neonate an obligate nasal breather for 4-6 months. any nasal pathology at this age will cause airway obstruction. (ex choanal atresia)
- Cartilage and soft tissue are soft
- Pediatric Larynx are susceptible for laryngomalacia, their soft tissue is less adherent to the underlying cartilage.
  - mild trauma leads to large submucosal edema
  - susceptible to collapse
  - Less resistant to develop submucosal edema
- Their Epiglottis is Omega shaped "curved"
- In Pediatrics: **Subglottis** is the narrowest part of AirWay and is non-expandable
- In adults: the glottis (at level of vocal cords) is the narrowest part of the AirWay.



Know the names of these structures (saq?)

## Trachea:

- Consists of 16 to 20 incomplete cartilaginous rings (muscle in the back)
- (cartilage from front and muscles behind). “Complete in pediatrics”
- The posterior wall is the membranous part.
- Length is approximately 11cm
- Diameter: 19mm male, 16mm female
- Pediatric trachea has a smaller diameter:

At Birth: 6 mm, six months: 7.2 mm, one year: 7.8 mm ○ four years: 11 mm

- **Endotracheal tubes:** For infants and children
  - <1kg: 2.5mm
  - 1-2.5kg: 3mm
  - 6m - 1year: 3.5-4mm
  - 1-2years: 4-5mm
  - **Beyond 2 years: (age in years +16) ÷4**

### ● Upper Airway Obstruction:

(from the nares and lip to the subglottic area)

Upper airway obstruction:

- Congenital
- Acquired

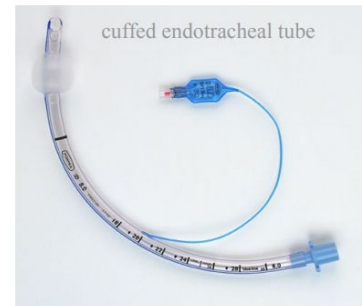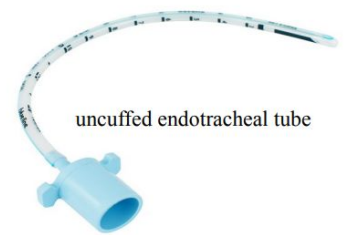
## Signs and symptoms:

- Stridor: is **harsh high pitched** musical sound produced by **turbulence** of air flow through a **partial obstruction of the airway (AW)**.
  - very important sign of UAW obstruction
  - **Dont get it mixed up with stertor: (low pitched sound associated with nasal obstruction)**
  - It indicates - pathologic narrowing of AW, potential respiratory obstruction or even death
  - **The most common cause of stridor in pediatrics is Laryngomalacia**
- **Other signs of airway obstruction:**
- flaring of the nasal alae
- retraction of the neck, intercostal and abdominal muscles
- Dyspnea
- Tachypnea
- Restlessness
- Cyanosis (**easily detected in children perioral or finger tips**)
- Subcutaneous emphysema ( **break in the continuity of airway** → air under the skin)

## Types of stridor: (IMP)

inspiratory or expiratory → **tells you the location of pathology**

- Inspiratory (extrathoracic) stridor:
  - The obstruction is supraglottic, glottic (glottis the area between the two vocal cords) e.g: Laryngomalacia the vocal cords and above (supraglottic).
- Expiratory (intrathoracic) stridor:
  - The obstruction is in the trachea (lower) (in the intrathoracic trachea)
- **Biphasic** (fixed in middle of trachea) stridor:
  - The obstruction is between the two areas: subglottic obstruction (below the vocal cord or upper trachea) **the most dangerous**



In adult we use cuffed tube (we inflate it) ,In pediatrics we usually use uncuffed tube because if we used cuffed tube we risk of irritating the subglottic area leading to subglottic stenosis.

## ● Upper Airway Obstruction:

### History:

- age
- Time of onset + speed of onset
- Possible trauma
- Characteristic of cry
- Relation of airway problem to feeding, position
  - eg: **Feeding difficulty** (this is very important for treatment decisions), **ex: laryngomalacia improve with prone position**
- History of previous intubation (AW trauma, **prolonged intubation > subglottic stenosis**)
- Questions about possible aspiration of FB
- **Characteristic of cry “reflects the status of vocal cords” imp to ask about the nature of it (forceful, weak,..)**
- **Speed and onset of precipitating event “immediately after birth or not”**

### Stridor history mnemonic (SPECRS) (extra)

- S: severity: parents subjective impression regarding the severity of the obstruction
- P: progression of the obstruction over time
- E: eating or feeding difficulties, aspiration, failure to thrive
- C: cyanotic episodes, apparent life-threatening events
- S: sleep—obstruction so severe that retractions occur even during sleep
- R: radiology—specific radiologic abnormalities

### If stridor is present since birth:

- Congenital laryngomalacia **60% (present 2-3 weeks from birth not immediately)**
- Subglottic stenosis (**can be congenital or acquired**)
- Vocal cord paralysis (**unilateral or bilateral, birth trauma or post thyroidectomy**)
- Vascular rings (**malformation can press on trachea**)

### If onset of stridor is gradual and progressing:

- Subglottic hemangioma: appears between 1-3 months of age (**the most common infant tumor in 1st year, treated medically by beta-blockers**)
- papilloma of the larynx: appears at 6 months of age (**rare**)

### Causes of stridor and respiratory distress in children :

acute stridor can be categorized as “infectious/inflammatory” such as croup (laryngotracheobronchitis) or epiglottitis or bacterial tracheitis (membranous croup) be related to foreign body most commonly in children between 1 and 3 years

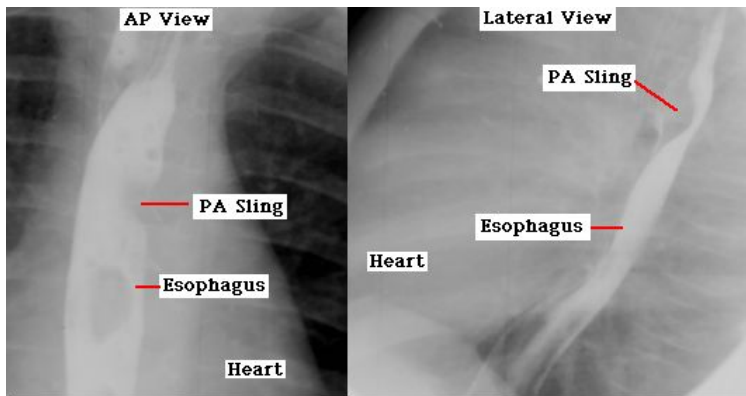
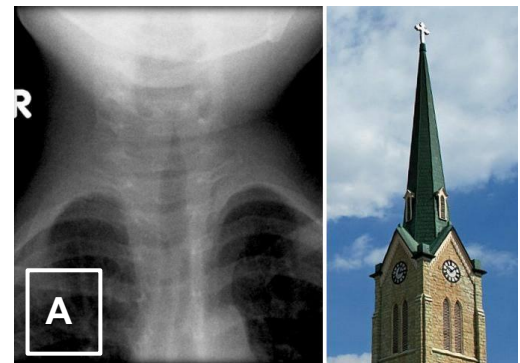
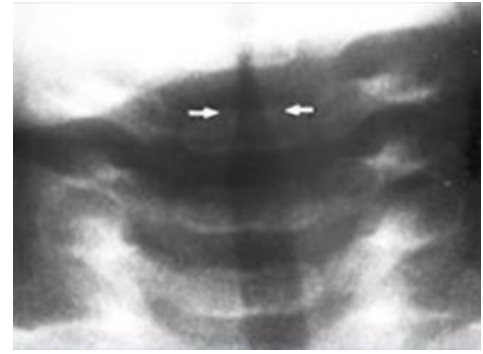
TABLE 3–3. Differential Diagnosis of Upper Airway Obstruction: KITTENS Method

	(K) Congenital	Infectious & Idiopathic	Toxins & Trauma	Tumor (Neoplasia)	Endocrine	Neurologic	Systemic/Psychiatric
<b>Above Larynx</b>	Micrognathia Macroglossia Choanal atresia Lingual thyroid Nasoseptal deformity	Retropharyngeal abscess Peritonsillar abscess Mononucleosis Diphtheria	Facial fracture Retropharyngeal hematoma	Juvenile nasopharyngeal angiofibroma Neurogenic nasal tumors	Myxedema	Posteriorly displaced tongue Central sleep apnea	Allergic rhinitis Granulomatosis with polyangiitis (Wegener's) Obesity (obstructive sleep apnea)
<b>Supraglottic</b>	Laryngomalacia	Epiglottitis	Intubation trauma	Squamous cell carcinoma			Sarcoidosis
<b>Glottic</b>	Glottic web Laryngeal atresia Vocal fold immobility	TB laryngitis Laryngeal diphtheria	Laryngeal fracture Foreign body	Respiratory papillomatosis Squamous cell carcinoma		Vocal fold paralysis	Hereditary angioedema
<b>Subglottic</b>	Vascular ring and aortic arch anomalies Tracheoesophageal fistula Subglottic stenosis	LTB (Croup)	Subglottic stenosis Thyroid or neck masses (extrinsic compression)	Subglottic hemangioma		Respiratory muscle paralysis (eg, Guillain-Barre syndrome)	Granulomatosis with polyangiitis (Wegener's)
<b>Tracheo-bronchial</b>	Tracheomalacia Vascular rings	Tracheitis Bronchitis	Foreign body	Mediastinal, tracheal, or bronchial tumors			External compression (goiter) Asthma

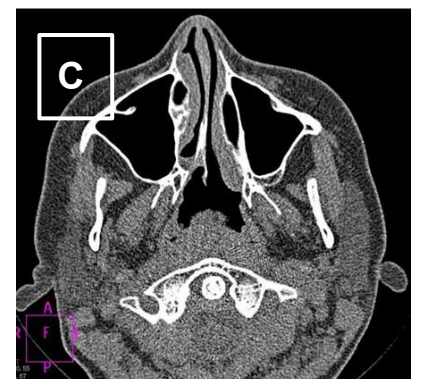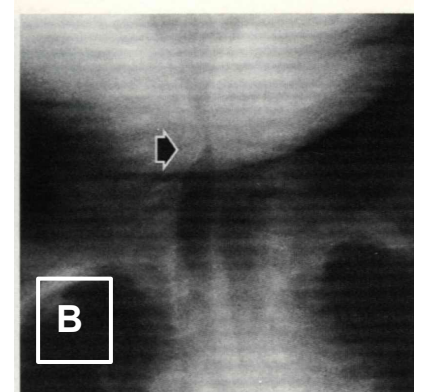
## ● Radiology investigations:

Indicated for patient without respiratory distress, **you must stabilize the patient first (and if foreign body is suspected)**

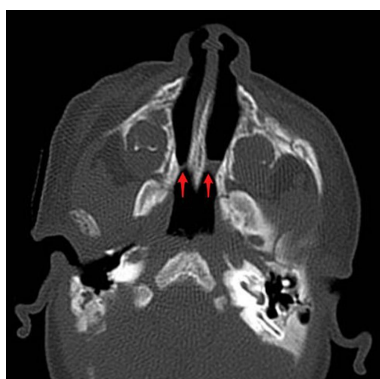1. Plain x-ray views: Mobile pharyngeal tissue may bulge during expiration in normal infants
  - soft tissue neck A.P.
  - Lateral chest
2. High-kilovoltage technique (croup series)
  - AP view assesses subglottic region
  - Look for **steeple sign** (picture A, narrow trachea) indicating acute laryngitis.
  - Picture B is for a patient with unilateral subglottic hemangioma.
3. Fluoroscopy
  - dynamic AW changes
4. Barium swallow
  - Assess swallowing
  - rule out presence of vascular rings



**Vascular Ring Barium Swallow** - This shows an example of a pulmonary artery ring or sling caused by the anomalous origin of the left pulmonary artery from the right pulmonary artery. Notice the filling defect in the barium column on the left in the AP view and anteriorly on the lateral view.



5. CT scan and MRI: good in evaluating mediastinum
  - CT scan (**Choanal atresia** in pic c, retropharyngeal abscess, tumor), nowadays we use it more than x ray. It gives more information and details for nasal, oropharyngeal or airway sometimes
  - MRI (**hemangioma, lymphatic malformation**)

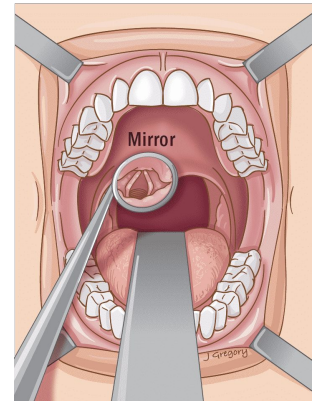


CT scan: **Bilateral choanal atresia**. Complete airway obstruction because neonate are obligate nasal breathers. Emergency intubation & relieve the obstruction in the OR

CT scan: **Axial cut, unilateral choanal atresia**, present late in life, unilateral airway obstruction. Not an emergency and can be corrected later

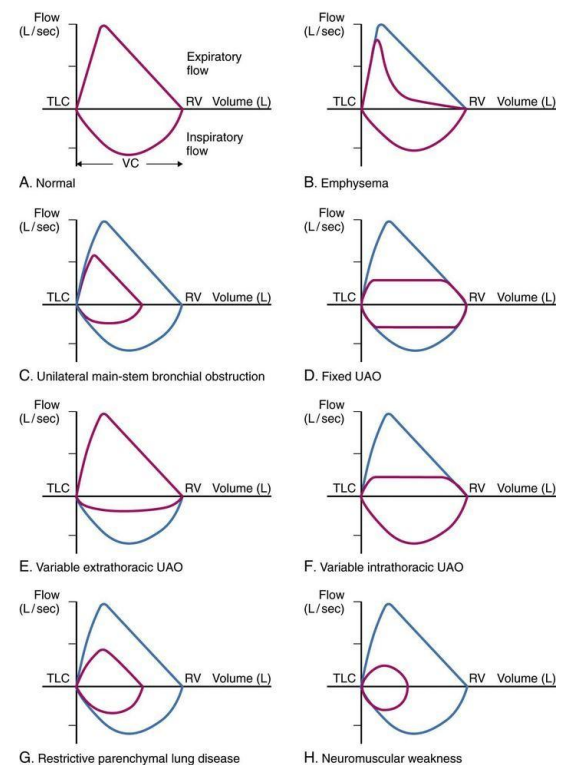
## ● Endoscopic evaluation:

- Mirror examination (useless now, we don't do it now a days):
  - Not endoscopic
  - In older children and adult can provide information about hypopharynx and larynx
- Telescopic examination:
  - Flexible Fiberoptic endoscope:
    - Excellent to assess the **movement** of vocal cord, (supraglottic lesion) (nose to larynx)
    - Done in clinic + pt awake
  - Rigid bronchoscopy:
    - Done under GA
    - May enable removal of foreign body
    - Assess the airway down to the main stem bronchi (subglottic area) and we can take culture if the case requires.
    - Diagnostic: subglottic stenosis , hemangioma
    - Therapeutic: foreign body



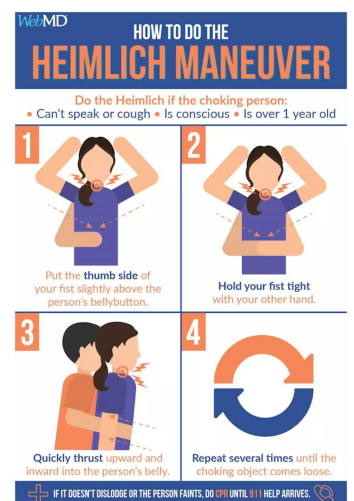## ● Other investigations:

- ABG:
  - Late indicator of airway obstruction,
  - should not be used routinely to assess degree of obstruction (ABG usually is for chronic conditions)
- Flow volume loop: can help distinguish the site of airway narrowing.



## ● Therapeutic options:

- Observation/medical support:
  - ICU
  - Airway team availability
  - Oxygenation
  - Steroid to reduce edema
  - Antibiotic
- Heimlich maneuver: when someone is choking (foreign body)
- N.P. (nasopharyngeal) airway
- Oral airway
- Esophageal airway
- Transoral intubation
- Nasal intubation
- Flexible fiberoptic intubation
- Trans-Tracheal jet ventilation
- Cricothyroidotomy
- Tracheostomy



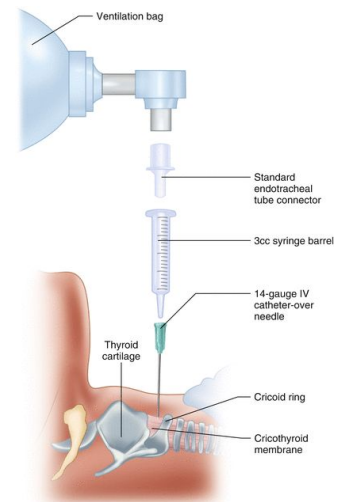
## ● Surgical techniques:

### 1-Transtracheal needle ventilation:

rarely done, (few hours only)

- Where immediate ventilation is required.
- Can support ventilation for several hours.
- Technique:
  - 12, 14 or 16 gauge cannula
  - High press ventilation system (50 p.s.i.) attached.
  - Done by emergency or ICU
- Complications:
  - Failure to establish an AW
  - Misplaced catheter in soft tissue of the neck (esp. in children):
    - Pneumomediastinum
    - Pneumothorax:
 

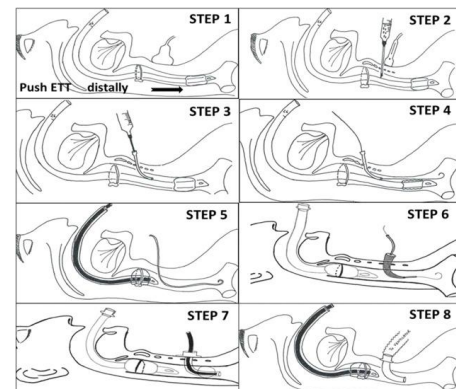
the trachea and airway is highly mobile slippery and soft in children and you find airway is slipping from you and you are passing the cannula around the trachea
  - Total obstruction of the airway prevents adequate ventilation



### 2-Percutaneous tracheostomy:

usually used in ICU

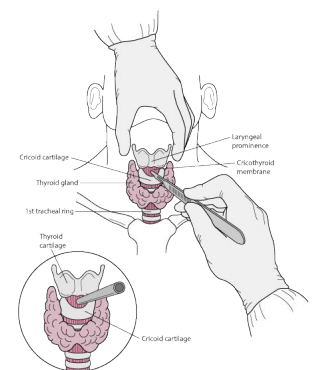
- Passing needle, guide wire, series of dilators, the tube.
- Complications:
  - Difficulty with dilatation
  - Failed intubation
  - Excessive bleeding
  - Pneumothorax
  - False passage of the tube
  - Accidental decannulation
  - Tracheoesophageal fistula



### 3-Cricothyroidotomy IMP

Cricothyrotomy (also called cricothyroidotomy) is a procedure that involves placing a tube through an incision in the cricothyroid membrane to establish an airway for oxygenation and ventilation.

- Indications:
  - **emergency** upper airway obstruction when intubation has failed or contraindicated.
  - **Elective** for head & neck or cardiovascular procedures Where access to the tracheal rings is limited. (can't do tracheostomy, because tracheostomy is usually better) (best for short period)



Other indications (from 435):

- Stenosis / epiglottis
- Intubation is not possible (difficult intubation).
- Need to avoid neck manipulation.
- Severe maxillofacial trauma.
- Edema of throat.
- Severe oropharyngeal/tracheobronchial hemorrhage.
- Foreign body in upper airway.
- Lack of equipment for endotracheal intubation.
- Technical failure of intubation.

## ● Surgical techniques cont:

### 3-Cricothyroidotomy **IMP** cont

- Procedure:
  - May utilize horizontal or vertical incision.
  - Use small tracheal tube or endotracheal tube.
- Complications:
  - Injury of anterior jugular vein (**acceptable, in the area**), great vessels (**not acceptable because it is located laterally**)
  - Injury of recurrent laryngeal nerve
  - Subglottic and laryngeal stenosis (especially in children) **contraindicated in pediatrics because the the cricoid and thyroid cartilage are overlapping and will separate over time.**
  - Subcutaneous emphysema
  - Esophageal or mediastinal perforation
  - Pneumothorax, etc..

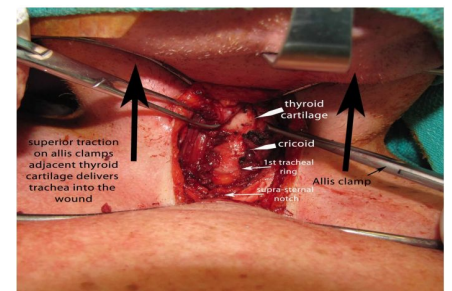
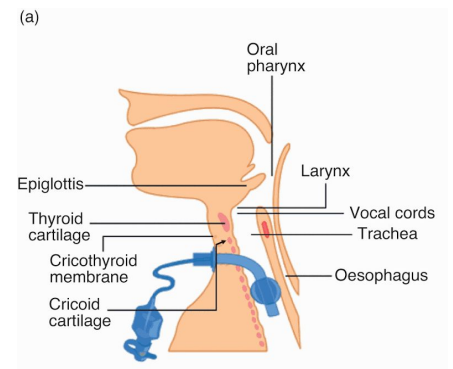
Emergency surgical cricothyrotomy has a much higher complication rate than elective cricothyrotomy. This is likely because emergency cricothyrotomy is performed on critically ill patients with difficult airways under emergency conditions.

### 4-Tracheostomy **very IMP**

**Tracheostomy is an operative procedure that creates a surgical airway in the cervical trachea. It bypass all the upper airway.**

It can be used for emergency or elective-airway obstruction, acute or chronic-airway obstruction

- Indications: (**IMP**)
  - Prolonged (**more than 2 weeks**) mechanical ventilation:
    - pulmonary dysfunction,
    - neuromuscular diseases
    - infections
  - Upper airway obstruction:
    - subglottic stenosis
    - bilateral vocal cord paralysis
    - **hemangioma**
  - Elective for major head and neck surgery **oral surgery (tongue cancer excision and reconstruction)**



From 435: every exam includes the indications and complications  
435dr notes

- Congenital anomalies like laryngeal hypoplasia.
- Upper airway foreign body.
- Supraglottic or glottis pathology like infection, neoplasm, bilateral vocal cord paralysis.
- Neck trauma results in severe injury to the thyroid or cricoid cartilages.
- Subcutaneous emphysema.
- Facial fractures that may lead to upper airway obstruction.
- Upper airway edema from trauma, burns, or anaphylaxis.

(from 437): Vertical incisions, 2 fingers from sternal notch usually between 2-3 or 3-4 tracheal rings to avoid the cricoid, high tracheostomy will cause subglottic stenosis.



## ● Surgical techniques cont:

### 4. Tracheostomy cont. **very IMP**

- In emergency tracheostomy vertical incision is preferred
  - Hemostasis after establishing airway obstruction

	Vertical incision	Horizontal incision
Advantages	<ul style="list-style-type: none"> <li>● limited injury of vascular and neural structure</li> <li>● improve access of trachea (easy retraction of soft tissue)</li> </ul>	<ul style="list-style-type: none"> <li>● improve cosmetic appearance,</li> <li>● may avoid neck dissection wound</li> </ul>
Disadvantages	<ul style="list-style-type: none"> <li>● potential scar formation</li> <li>● risk of communication with neck wound (apron flap)</li> </ul>	<ul style="list-style-type: none"> <li>● risk of neurovascular injury,</li> <li>● may limit tracheal elevation during swallowing</li> </ul>

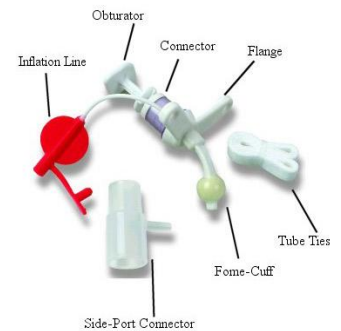
### complications

#### Immediate

- Bleeding
- Tracheal tube obstruction
- Pneumomediastinum
- Pneumothorax
- Loss of airway
- Injury to thyroid or nearby structures

#### Late

- Infection
- Granulation tissue formation
- Tracheal tube displacement or malposition
- Tracheo-esophageal fistula
- Tracheo-vascular fistula



Inflatable cuff is needed for mechanical ventilation

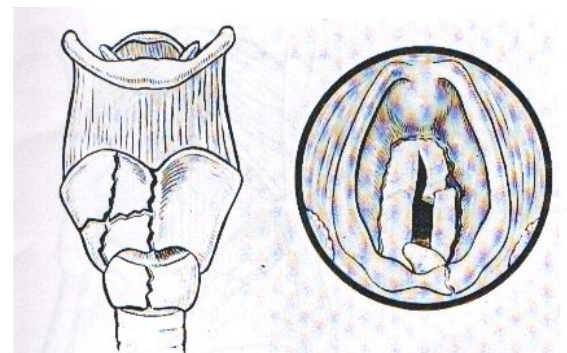
## ● Airway emergencies:

### Airway stabilization:

- organization between Surgeon and Anaesthetist is key
- avoid blind attempt of intubation
- if available, fiberoptic intubation (experience)
- percutaneous jet ventilation to stabilize patient (not common) (for patient with total obstruction, better than going blindly)

### A. Trauma:

- Presenting symptoms:
  - Hoarseness (means at the level of vocal cord)
  - Pain tenderness
  - Hemoptysis
  - Dysphagia
  - SC emphysema IMP (it is air in subcutaneous tissue)
  - Impaired respiration
  - Haematoma



Could be a laceration or blunt trauma fracturing the laryngeal skeleton

## ● Airway emergencies CONT:

### A. Trauma CONT:

- Schaefer Classification of Laryngeal Trauma & Treatment: “not imp at your level”

	Type	Management
Type-I	<ul style="list-style-type: none"> <li>● minor endolaryngeal haematoma or laceration</li> <li>● absence of detectable fracture of laryngeal skeleton</li> </ul>	<ul style="list-style-type: none"> <li>● 24 / 48 hours observation in ICU</li> <li>● Head of bed elevated</li> <li>● Humidification &amp; systemic steroids</li> </ul>
Type-II	<ul style="list-style-type: none"> <li>● edema, haematoma, mucosal disruption</li> <li>● No exposed cartilage, no displaced fracture</li> </ul>	<ul style="list-style-type: none"> <li>● CT scan to R/O displaced fracture</li> <li>● Tracheostomy under local anaesthesia</li> </ul>
Type-II I	<ul style="list-style-type: none"> <li>● Massive edema with large mucosal laceration</li> <li>● exposed cartilage</li> <li>● Displaced fracture (unstable airway)</li> <li>● Vocal cords motion impairment</li> </ul>	<ul style="list-style-type: none"> <li>● Tracheostomy</li> <li>● Laryngoscopy</li> <li>● Exploration and repair</li> <li>● No intubation b/c may cause more trauma</li> </ul>
Type-I V	<ul style="list-style-type: none"> <li>● Same as III but more severe</li> <li>● Group with disruption of anterior larynx, unstable fractures, two or more fracture lines, or massive trauma to laryngeal mucosa</li> </ul>	<ul style="list-style-type: none"> <li>● Explore and repair</li> <li>● Require endolaryngeal stent</li> </ul>
Type-V	Complete laryngotracheal separation	

### B. BURN PATIENT:

Airway management is controversial (some say intubate and some say don't.)

- Oral or Nasal **Endotracheal Tube:**
  - May exacerbate existing thermal injury
  - Inadvertent extubation is a potential disaster
  - When facial grafting is necessary tube and ties will limit the access
  - Tube obstruction occur more frequent (due to secretions and sluff)
  - Loss of airway after a failed intubation could be disastrous due to AW obstruction.
- Stabilization of airway is indicated for thermal injury of trachea, and extensive burns of the face or oropharynx. Where impending UAWO necessitates intubation
- Intubation for assisted ventilation is required for inhalation injury with: changes in ABG, O2 sat, and increase CO1
- Once decision of intubation is made:
  - ET should be attempted initially.
  - If necessary, leave X 3-4 wks.
  - Utilize this time for grafting neck burns.
  - Shift to tracheostomy after that if necessary.
- **Tracheostomy**
  - Reported to have higher mortality rate as a result of infectious complication (pulmonary sepsis, necrotizing tracheitis, mediastinitis ) so we prefer not to do it.
  - Risk of bleeding, pneumothorax, tracheal stenosis.
  - difficult procedure due to neck edema, which might lead to inadvertent tube removal (the edema takes from the length of the tube, you might have to dig throw 10cm of soft tissue).
  - Cricothyroidotomy, may establish the airway more easily.
  - Once decision of intubation is made: ET should be attempted initially
  - If necessary leave for 3-4 wks, utilize this time for grafting neck burns
  - Shift to tracheostomy after that if necessary.

## ● Airway emergencies CONT:

### C. Tumors:

- (most common adult laryngeal tumor is **squamous cell carcinoma**)
- **Smoking** is the main cause (in oropharynx and laryngopharynx) . **Epstein-Barr virus** (in nasopharyngeal).
- Commonly tumors of aerodigestive tract or thyroid. typically present with gradual airway obstruction.
- **Thyroid cancer** (direct compression on trachea or recurrent laryngeal nerve invasion cause vocal cord paralysis and airway obstruction)
- **Initial management**
  - O2
  - humidification
  - Steroids
  - IV antibiotic
- **Airway stabilization in tumor:**
  - Elective awake tracheostomy under local anesthesia is the safest method to secure the airway, **usually patients with tumors, trismus that prevents intubation.** (in cases of predicted **difficult airway**)
  - Precipitation of complete obstruction necessitates emergent cricothyroidotomy or tracheostomy

### D. Supraglottitis / Epiglottitis **imp** بالاختبارات تجي دائما

Acute inflammation of the epiglottis, very common in the past and almost eradicated but coming back.

Paediatric: by **H. influenza** type B

- Sudden onset
- Rapidly progressive course
- **More acute than adults**
- High fever, respiratory distress, and **stridor**
- Drooling, painful swallowing, **sitting on edge of seat**
- **Vaccine is available but it still causes a high number of cases**

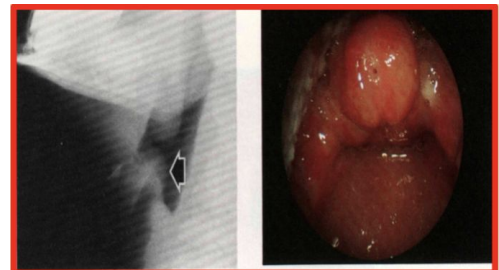
Adult: by staph aureus, **more stable**

- Dysphagia, severe sore throat
- Fever, stridor, voice change "**Hot potato voice**", **as if the patient is struggling with a mouth full of hot food.**
- may have preceding upper respiratory tract infection (URTI) symptoms

Management:

**Never examine a patient in acute epiglottitis in ER or clinic, take the patient to OR because it may precipitate complete airway obstruction.**

- Children:
  - **Secure airway** → ET tube, tracheostomy **after that give IV Abx** (2nd, 3rd Gen. Cephalosporin and steroids and do culture)
- Adult:
  - Frequently observed in an ICU, may need intubation.



**Thumb sign**

What is the diagnosis? acute epiglottitis  
What is the organism? H. influenza  
Management? Take the patient to OR for possible intubation or tracheostomy (never examine the patient in clinic or ER)

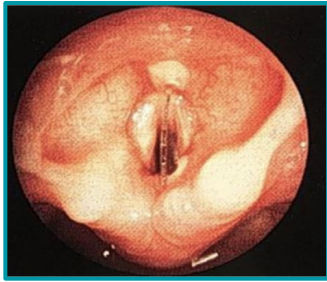
# Airway Emergency

## E. Foreign Body Aspiration

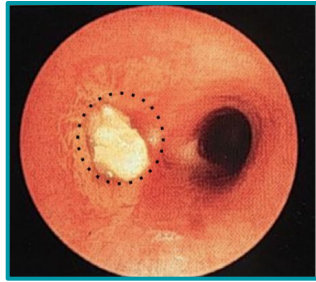
- Death from foreign body aspiration in USA is about 3000 per year for all ages.  
We see it mainly in the extreme ages: very young (children) and very old (geriatric).
- Complete airway obstruction may be recognized in the conscious child as:
  - Sudden respiratory distress
  - Inability to speak or cough
- **Types of foreign body:**
  - Vegetable matter (most common in children's airway) (peanut)/ مكسرات
  - Metal (coin)
  - Plastic (toys)
  - The most common objects aspirated by young children are food products (peanuts, seeds, Corn , فصفص , .(Most imp thing is vegetable matter because if it stay there, it will cause infections. And the most dangerous is battery because of chemical leakage which can cause erosion and perforation.
- **Clinical presentation: (Stages)**
  - Immediate stage: Usually coughing, choking, gagging, and wheezing (we mostly catch patients here)
  - The intermediate stage: No symptoms or signs
  - Third stage: Mimic different acute or chronic disease of lungs e.g. recurrent croup, bronchial asthma.
  - Stage of complications: pneumonia, obstructive emphysema and bronchiectasis. Can perforate and penetrate vessels and soft tissue.
  - Sudden choking, cyanosis, coughing
  - Chronic chest infection not resolving
  - Location of FB in the AW:
    - Commonly the final destination is one of the main bronchi → right bronchus affected more commonly than left bronchus (the right is shorter, wider and more vertical)
    - Larynx in case of sharp objects (fish bone)
    - Trachea if there is narrowing in it, might lead to death if complete obstruction
- **Diagnosis:** Medical history is the key for diagnosing (clinical)
  - Radiologic: x-ray
    - x-ray is normal most of the time because the majority of foreign bodies are plastic toys that can't be shown on x-ray).
    - Extended soft tissue neck, PA, lateral chest (most efficacious)
    - It can demonstrate: foreign body, emphysema of lung, atelectasis of the lung.
  - Bronchoscopy is the gold standard (Diagnostic + Therapeutic)
  - Fluoroscopy and CT scanning may be used as well. If the index of suspicion is high, we can proceed to bronchoscopy. (Bronchoscopy is the gold standard)
- **Management:**

Endoscopic removal is both diagnostic and therapeutic (airway foreign bodies are removed most safely under general anesthesia using the ventilating rigid bronchoscope). Optical Telescopic forceps can be used for foreign bodies removal and biopsy.

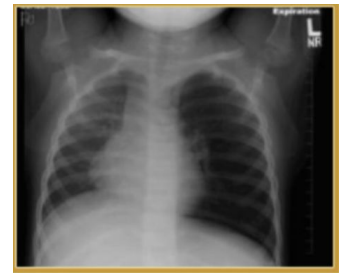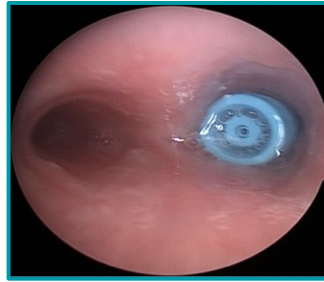
# Airway Emergency



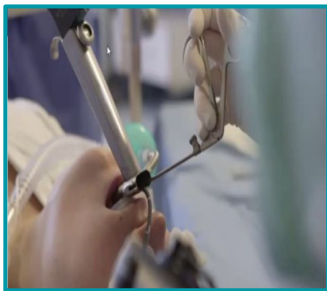Fish bone in glottic area



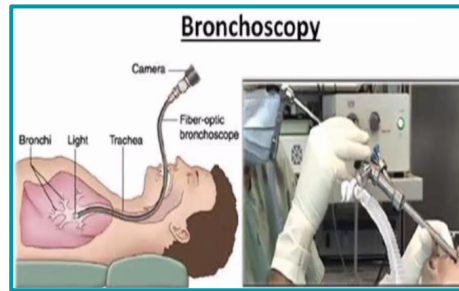
Complete right main bronchus obstruction



X-ray shows: hyperinflation of the left lung which is clearly more lucent than the right and shift of mediastinum and flattening of the hemidiaphragm are signs secondary to air trapping.



Laryngoscope: in case of foreign body in larynx



Bronchoscopy

the FB is in the left lung and one way to know where is the FB is to do inspiratory and expiratory x-rays to know the location

## F. Thermal injury

- It is caused by aspiration of hot liquid or caustic fluid.
- **Alkali is more dangerous than acids.**
- Because of the risk of rapidly developing airway edema, the patient's airway and mental status should be immediately assessed and continually monitored.
- The treatment starts with securing the airway "intubation", tracheostomy and IV antibiotics.

## G. Peritonsillar abscess (Quinsy) (from 435)

- Common deep infection in late childhood
- Symptoms: low grade fever, Severe sore throat, Muffled voice, Drooling, Trismus
- Diagnosis: Clinical diagnosis, CT scan
- Treatment:
  - Aspiration
  - Excision and drainage
  - Later **tonsillectomy**
- Case: child had tonsillitis and treated with antibiotic for 3 days then stopped, after 2 days he started getting worse drooling of saliva, can't open the mouth (trismus) and hot potato voice?  
**Peritonsillar abscess (quinsy) (one of the indications of tonsillectomy) IV ABX**

# Congenital upper airway obstruction

## 1. Laryngomalacia:

- Accounts for 60% of laryngeal problems in newborn.
- Due to flaccidity or incoordination of supra laryngeal cartilages which are pulled inside the lumen during inspiration leading to Upper Airway (UAW) obstruction.
- Characterized by stridor in the first few week, commonly associated with reflux. The most common cause of inspiratory stridor in infancy (1st is laryngomalacia, 2nd is bilateral vocal cord paralysis, and 3rd subglottic stenosis)
- In laryngomalacia, the epiglottis or the arytenoids that are soft and floppy. This floppy tissue gets pulled into the airway during inspiration, causing temporary partial blockage of the airway. This tissue is pushed back out when the infant exhales, opening the airway again.

### Cause is unknown:

- Edema of the Aryepiglottic folds and loose suspension of the epiglottis, fall inside airway with inspiration.
- Embryologically: rapid growth of the third branchial arch causes the epiglottis to curl open itself forming an omega shape.
- Neurological immaturity of brainstem & vagus > infolding of the arytenoids in the AW

### Diagnosis:

- Symptoms: snoring is low pitch sound caused by tissue vibration of the nasopharynx pharynx and soft palate due to obstruction above the larynx. Stridor inspiratory phase worse with crying, feeding and respiratory tract infection, improved in prone position.
- Can only be confirmed by direct observation of movement of supraglottis during respiration.
- Fiberoptic evaluation (imp) is the most appropriate method of visualization.
- Radiologic evaluation (not done anymore, done to exclude other causes in case of severe symptoms not explained by laryngomalacia) (By high voltage X-ray PA lateral) may help in excluding the presence of associated AW problem: e.g. - Subglottic stenosis.
- Innominate artery compression.

### Complication of laryngomalacia:

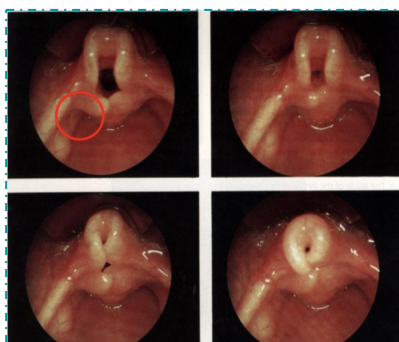
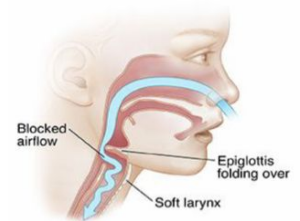
- Feeding difficulty
- Failure to thrive sensitive indicator for severe chronic airway obstruction

### Endoscopic finding (types of laryngomalacia):

- Tall, omega shaped epiglottis arytenoid mucosa (epiglottis is collapsing)
- Inward forward movement of (sucked) = floppy epiglottis
- Short aryepiglottic fold

**Treatment:** depending on severity of symptoms, if stridor is improved in prone position, if child is thriving

- Reassurance + treat GERD (95% associated with GERD)
  - 85% will recover spontaneously by one year of age
- Infant can outgrow this problem:
  - They could reach 18 month - 2 years and their problem would resolve
- Tracheostomy for severe cases.
  - Rarely done. Not good in pediatrics, high mortality rate up to 5%
  - This only done if we did the supraglottoplasty and the child is cyanotic, so we perform the tracheostomy and leave it temporarily until the child gets better.
- Epiglottoplasty, For severe cases → supraglottoplasty 'the best for severe cases'
  - Cut of the aryepiglottic fold, or trimming of arytenoid mucosa, or fix the epiglottis to the tongue to decrease falling inside
  - Usual management for severe cases/pt present with complications.



Short aryepiglottic fold starting to collapse during inspiration > Blocking the airway "airway obstruction" > Stridor

# Congenital upper airway obstruction

## 2. Subglottic Stenosis (imp)

- A narrowing of the subglottis; in newborn subglottic diameter of less than 3.5 mm is abnormal.
- Two types:
  - Congenital pt born with complete narrowing of cricoid
  - Acquired - the commonest
  - We rarely see Congenital Subglottic Stenosis, it is mostly acquired due to prolonged intubation (EXAM). Also in pediatric with inappropriate ETT size.

### Risk Factors of Acquired (from 435)

- Prolong / incorrect intubation duration and size of tube are important.
- Size of the tube
- Care of intubated patient.
- High pressure cuffs tube.
- Difficult intubations.
- Multiple intubation.
- GERD.
- Tracheobronchial infection.

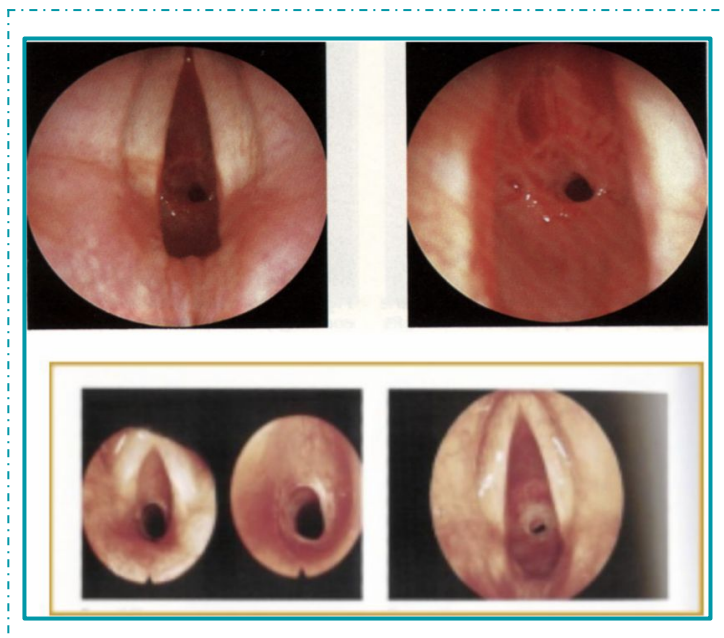
Edema and inflammation progress to ulceration and granulation tissue formation. When the source of irritation is removed, healing occurs with fibroblast proliferation, scar formation, and contracture, leading to stenosis or complete occlusion of the airway

### Presentation:

- Mild cases may present as recurrent croup secondary to URTI.
- Generally present with symptoms and signs of URT obstruction.
- Symptoms: dyspnea (may be on exertion or rest depending on the degree of stenosis), stridor, hoarseness, brassy cough, recurrent pneumonitis, cyanosis.

### Diagnosis:








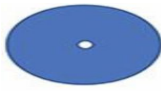

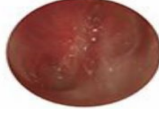
- Plain film of the neck (high KV) - not done anymore.
- Confirm the diagnosis by rigid endoscopy under GA (check a picture of the rigid bronchoscope they love to bring it in the exam).
- CT-scan
- MRI - for difficult cases.



# Congenital upper airway obstruction

## Cotton-Myer Classification of Subglottic Stenosis:

Dr said its important for exam, example question : what is diagnosis ? subglottic stenosis , what is the grading system? mention the grade and percentage **SAQ**

Classification	From	To	Endoscopic appearance
Grade I	 No Obstruction	 50% Obstruction	
Grade II	 51%	 70%	
Grade III	 71%	 99%	
Grade IV	No detectable lumen Complete obstruction		

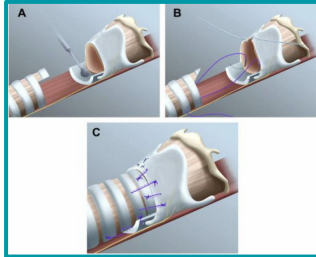
## Management:

- Endotracheal intubation: usually it is difficult
- Emergency situations:
  - **Tracheotomy** the best to secure airway because it is under stenosis level
  - Cricothyroidotomy
- Endoscopic techniques: (grade 1, 2)
  - Dilation (insert balloon)
  - Laser
- Open surgical technique: (grade 3, 4), through the neck
  - Cricoid split (Congenital subglottic stenosis)
  - Laryngotracheoplasty + rib graft + stent
  - Cricotracheal Resection and primary anastomosis (remove stenotic part and reanastomose the rest)



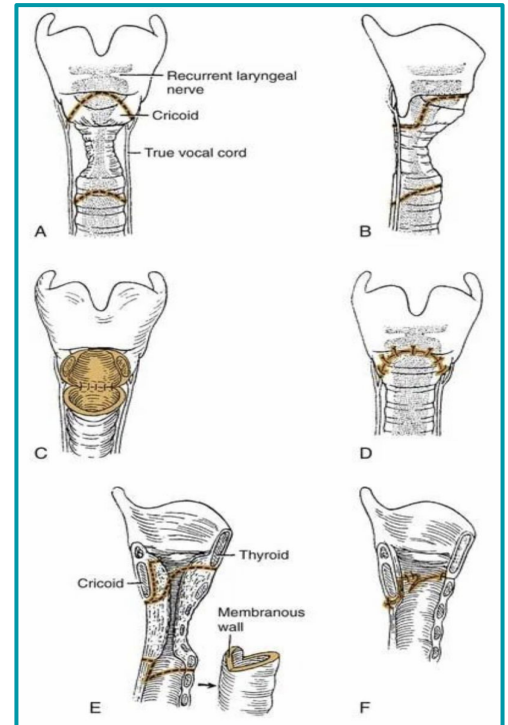
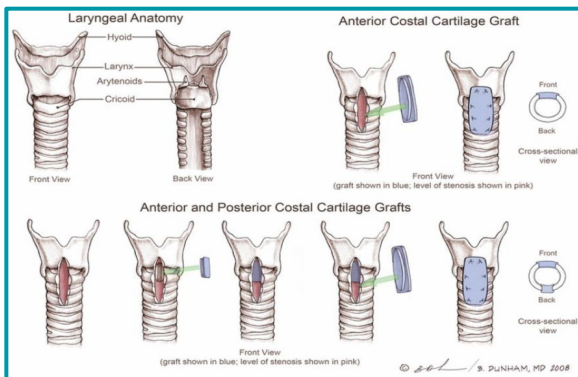
# Congenital upper airway obstruction

## Cricotracheal resection



Cricotracheal resection resect the stenotic part then reanastomose

Laryngotracheoplasty + Rib graft open larynx and expand narrowing part by rib cartilage.



## 3. Choanal Atresia

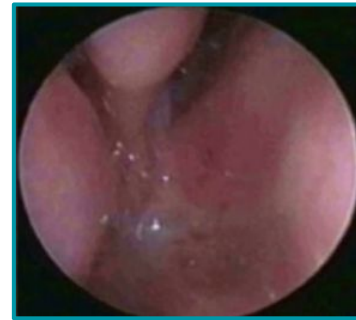- Uncommon anomaly 1 / 5000 - 8000.
- Lack of patency of posterior nasal aperture (complete closure)
- Bilateral atresia → **birth emergency!** Presents soon after birth with severe respiratory distress “because neonates are obligate nasal breathers” The first thing to do is oral tube then do a CT scan and any other thing you would like to do (emergency).
- **Stridor improves when the baby cry**
- Unilateral atresia present late (may be undiagnosed until later in childhood w/ rhinorrhea). Note 431: **The commonest cause for unilateral obstruction is foreign body (purulent, foul smelling discharge)**
- Mixed bone-membranous choanal atresia account for 90%, remaining bony CA
- Choanal atresia may be associated with other anomalies in 20-50% of cases:
  - **CHARGE syndrome 'Important MCQ'**
    - **C**-coloboma (a hole in one of the structures of the eye, such as the iris, retina, choroid, or optic disc.) **cranial nerves anomaly**
    - **H**-heart disease
    - **A**-atresia
    - **R**-retarded growth
    - **G**-genital hypoplasia
    - **E**-ear deformity

This is why we need to do a chromosomal analysis to look for everything.
  - VATER “VACTERL” syndrome
    - “Vertebral anomalies, Anal atresia, Cardiac defects, Tracheoesophageal fistula and/or Esophageal atresia, Renal & Radial anomalies and Limb defects”
  - Craniofacial anomalies

# Congenital upper airway obstruction

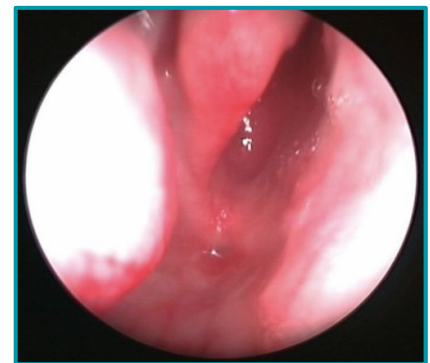
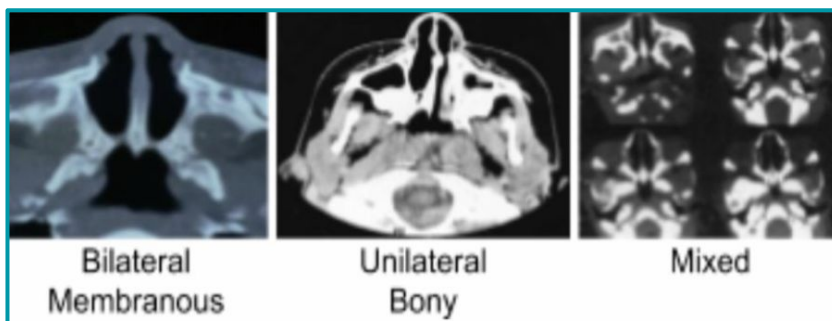
- **Types:** do CT to differentiate between the types

- Membranous
- Bony
- Mixed (**commentest**) accounts for 90%.

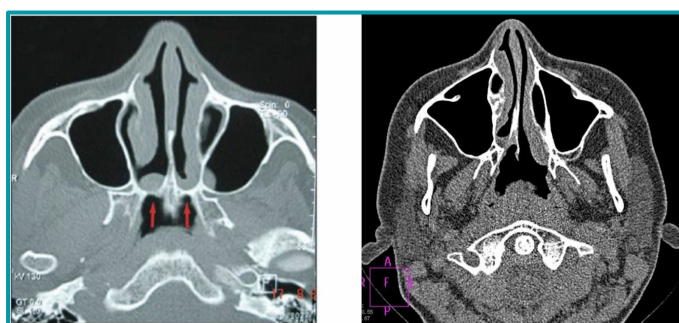


- **Diagnosis:**

- Cyanosis improves with crying.
- Infants: failure to pass #6 - 8 catheter: (**usually size 7**)
- Pyriform aperture stenosis
  - if you can't pass the catheter beyond 1 cm
  - at nasal entry, rare
- Choanal atresia
  - if you can't pass the catheter beyond 3.5 cm
- Fiberoptic nasoscope



**CT scan** choanal atresia: for knowing the types



- **Treatment (surgical repair):**

- If bilateral: done within 10 days. Unilateral: postponed to one year
- Emergency treatment is by insertion of oral tube.
- Many surgical approaches:
  - Transpalatal, Transnasal, Transantral, Transseptal.
  - Surgical treatment is by either transnasal or transpalatal choanal atresia repair.
- Endoscopic repair is the commonest
  - Outcome is variable
  - Success rates reported to range between 20-80%, It is the favorable method
  - With the scope if it is membranous → cut it. if it is bony → drill it

# Congenital upper airway obstruction

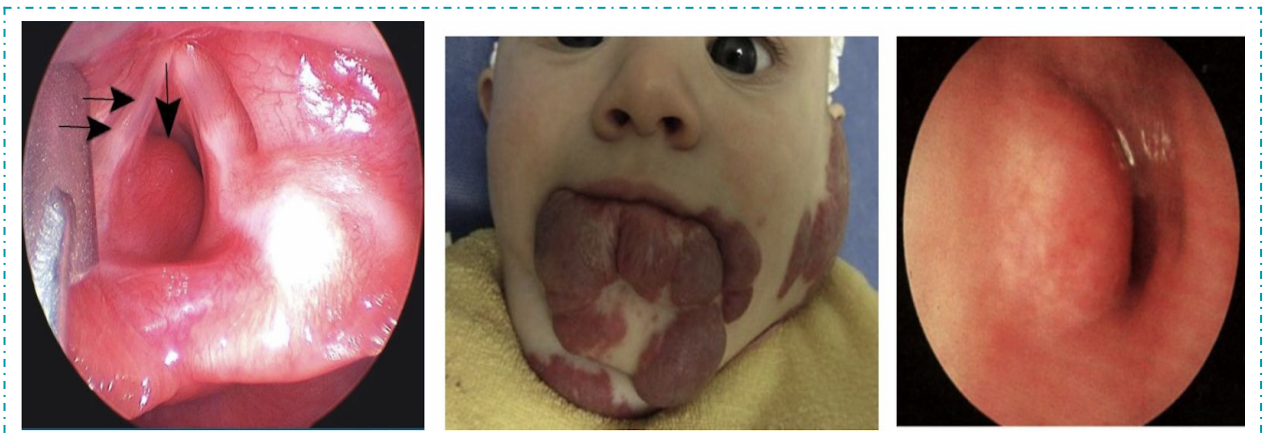
## 4. Subglottic Haemangioma (imp for SAQ)

- Congenital vascular lesion
- Not present at birth but grow rapidly over the first few months of life.
  - Progress > plateau > regress
- Hemangioma is **the most common tumor in the pediatric** can be anywhere in the body.
- Common in subglottic region
- **50% of subglottic hemangiomas associated with cutaneous involvement.**
- **Symptoms:**
  - Biphasic stridor.
  - You want to insert a scope, and it is inserted while the child is awake because you want to observe the dynamic movement which will help you with the diagnosis. so you will see the vocal cords moving ok but there is a mass that is reddish or purplish in color.
  - Tend to involute slowly after one year.
  - 50% of the patients have cutaneous haemangioma in the head and neck
  - Present at age of 3 months with progressive dysphonia

**Question:** a 2 years old boy with history of progressive stridor, patient is having **cutaneous discoloration**, looks like vascular malformation, what is the possible diagnosis? Subglottic hemangioma

**Treatment:** management depend on severity

- Observation if no symptoms
- Tracheostomy if causing airway obstruction
- Steroids
- Beta blockers- propranolol **main management nowadays**
  - The **first line of treatment is Propranolol** (beta blocker) but it needs to be **administered under the guidance of a pediatric cardiologist.**
- Surgical excision

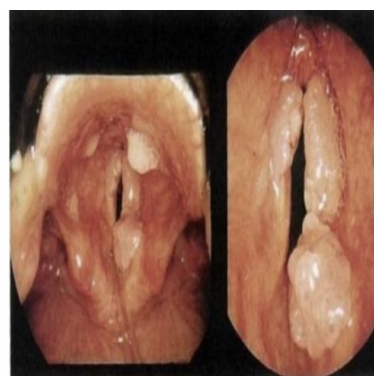
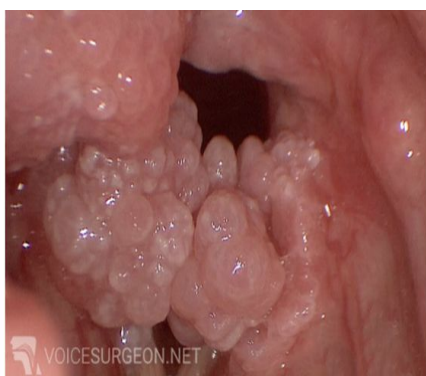
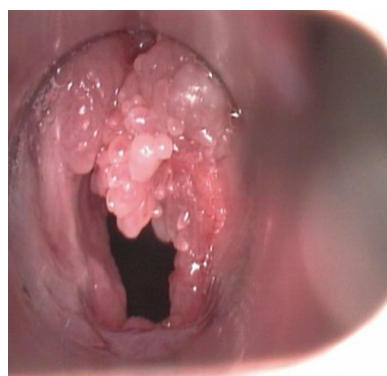# Congenital upper airway obstruction

## 5. Recurrent respiratory papillomatosis (common question)

- It is a disease caused by **Human papillomavirus (HPV) type 6,11 (Non cancerous)**
- Two-thirds before the age of 15 years.
- Rare risk of malignancy type 16,18
- **Types:** Juvenile and senile
- **Risk factor: Mother having genital warts**
  - Of juvenile-onset respiratory papillomatosis are firstborn child, vaginal delivery, and the mother being younger than 20 years + the presence of genital warts “condyloma acuminata”.
- **Symptoms: presentation depend on involvement (nasopharynx, oral cavity, hypopharynx, larynx, trachea, lung)**
  - Symptoms of upper airway obstruction predominate because the larynx is usually affected in both types.
  - **Recurrent respiratory distress**
  - Hoarseness and voice changes (dysphonia). Initially they come with only dysphonia
  - When obstruction happens the other symptoms starts to appear.
    - Choking episodes.
    - Foreign body sensation in the throat.
    - Cough.
    - Dyspnea.
    - Inspiratory wheeze.
    - Stridor
- **Investigation:** Laryngoscopy or bronchoscopy.
- **Treatment:**
  - Surgical **debulking** and cidofovir injection if needed
    - Laser excision or microdebrider (Debulking)
    - Cidofovir, Acyclovir, Interferon.

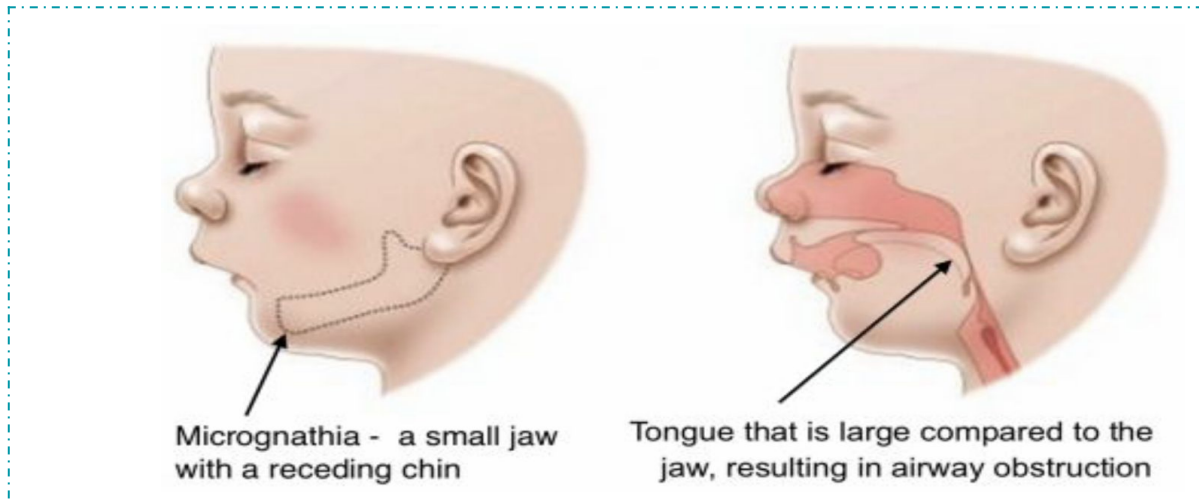
Adjunctive therapy in severe cases where there are areas we cannot remove the papillomas from. Such as anterior commissure > if you touch this area will lead to hoarseness)
  - **Avoid tracheostomy**, papilloma might grow around it (spread to skin)



# Congenital upper airway obstruction

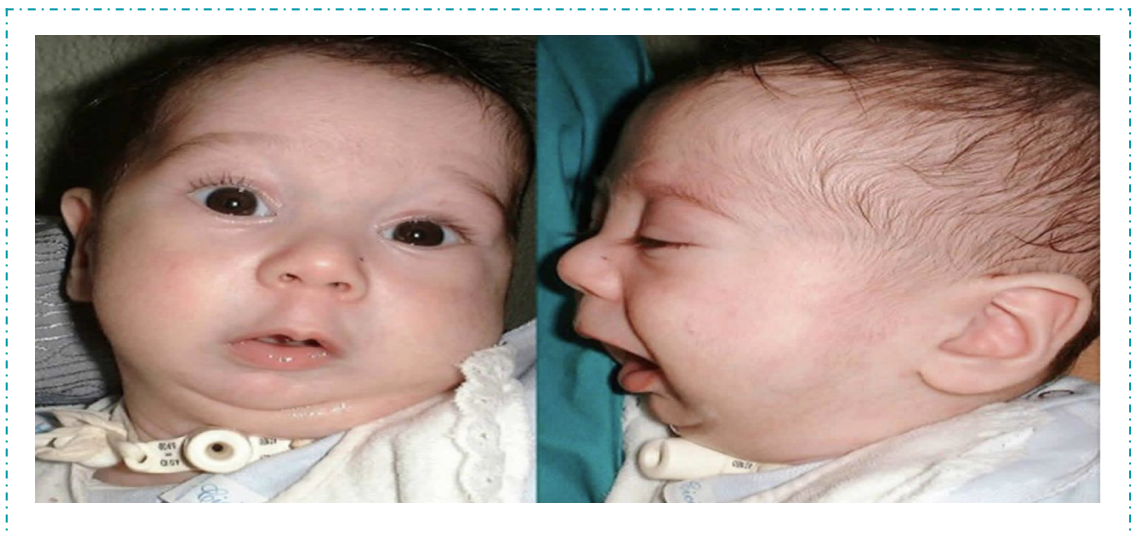
## 6. Micrognathia - difficult intubation:

- Small jaw + receding chin > tongue will be up > compress oropharynx > block airway > chronic airway obstruction
- Difficult intubation
- Severe case needs elective tracheostomy



## 7. Pierre robin syndrome:

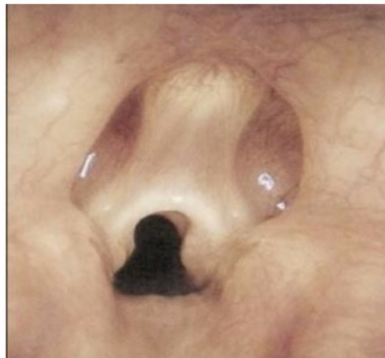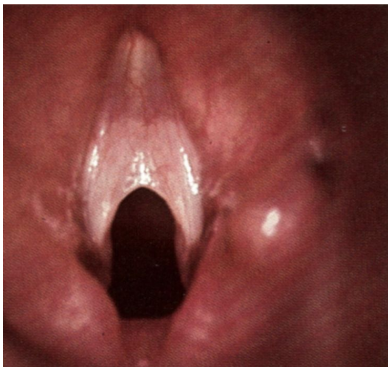- Small jaw
- Large tongue
- Cleft palate
- Grade: mild, moderate, severe
- Need elective tracheostomy after growing jaw (improve)



# Congenital upper airway obstruction

## 8. **Glottic web** Usually present as voice problem (weak voice)

- Adhesion of the two vocal cords (congenital)
- **Hoarseness** and difficulty breathing
- Small web just has **dysphonia**.
- **Weak cry**
- Stridor (more common with posterior webs)
- Sometimes associated with subglottic stenosis
- Treatment: Endoscopic release of vocal cords (put sometimes stent)
- Tracheostomy (any airway obstruction first thing to do is secure the airway).
- Resection
- Laser excisions
- Laryngofissure for high grade with subglottic stenosis



Endoscopy showing Adhesion of the two vocal cords

*An area for your notes*

## GOLDEN NOTES MCQs from 437

1. A child was playing with his toys when he suddenly started choking and coughing and cyanosed. His airway is patent. His parents took him to the hospital. What is the best management?  
A. Bronchoscope.  
B. Cricothyroidotomy.  
C. Tracheostomy.  
D. Observe
2. 27-years old male had road traffic accident with history of intubation at that time in the ICU for two months. Multiple trials of extubation were done but they failed. A tracheostomy was done for him. What is the most likely underlying cause for failure of intubation?  
A. Laryngomalacia.  
B. Subglottic stenosis.  
C. Tracheomalacia.  
D. Vocal cord paralysis.
3. A New born child had cyanosis and difficulty breathing immediately after delivery. The cyanosis improves with crying. Which of the following is the most likely diagnosis?  
A. Enlarged Adenoid  
B. Laryngomalacia  
C. Laryngeal web  
D. Bilateral choanal atresia
4. A 3 months old baby brought to the emergency department by his parents because of noisy breath (stridor) which is not affected by position. No cyanosis, no history of previous intubation and the voice is normal. Systemic review revealed cerebral palsy. What's most likely diagnosis?  
A. Laryngeal web  
B. Laryngomalacia  
C. Subglottic stenosis  
D. Bilateral vocal cords paralysis.
5. A young patient presented with sore throat for which he took antibiotics and it did not work. Examination showed temperature of 38.9c and swollen tonsillar lymph nodes. CBC showed lymphocytosis. What is the diagnosis?  
A. Infectious mononucleosis  
B. Acute diphtheria  
C. Vincent's angina  
D. Quinsy abscess
6. A 28 year old female complaining of right neck mass. Clinically euthyroid, on examination 4 cm right solid nodule, 3 cm left nodule. FNA shows follicular carcinoma, What is the recommended treatment?  
A. Thyroid replacement therapy  
B. Thyroidectomy  
C. Repeated aspiration  
SAQs
7. Case: picture of baby with skin rash "hemangioma" and history of stridor?  
A. What is the diagnosis?  
B. How would you investigate it?
8. Picture of tracheostomy tube:  
1. Identify it?  
2. Indications?
9. Foreign body (dysphagia, odynophagia)  
A. Site in the pic?  
B. Management?
10. Bilateral choanal atresia  
A. Diagnosis?  
B. Management?

- |      |      |
|------|------|
| 1. C | 3. D |
| 2. B | 4. A |
| 5. A | 6. B |

# THANK YOU!

*This work was done by:*

Naif AlFahed

*Team Leaders:*

Naif AlFahed

Nawaf AlGhamdi

Abdullah AlQarni

*Special Thanks to*

439 Team

