



PLEASE CHECK [Editing file](#) BEFORE!



GLOMERULAR DISEASES

★ Objectives:

- 1- To understand the pathophysiology of Glomerular Diseases.
- 2- To correlate the clinical findings with the underlying renal pathology.
- 3- To recognize the important features of Nephrotic syndrome.
- 4- Learn the most common causes of NS in adults.
- 5- To recognize the most important Glomerular diseases that cause Nephritic pattern (Glomerulonephritis).

★ Resources Used in This lecture:

Class note – Davidson - [step up to medicine](#) – [master the board](#)

Introduction.



*Normal urine will have:

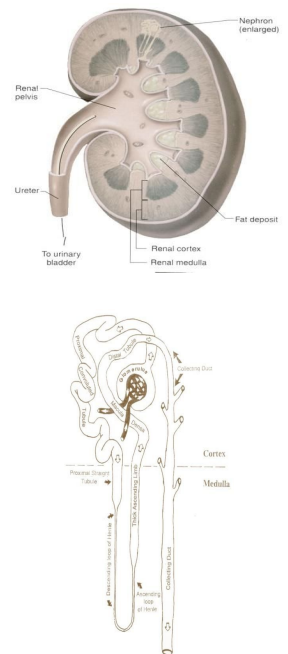
- NO Protein. **But in healthy individuals, less than 150 mg of protein is excreted in the urine each day.** Include 4-7 mg/day of Albumin.
- NO Red Blood Cells (Accept: up to 12 500 cells/mL is normal).
- NO Cellular Casts.
- No fat
- No sugar

***Renal cortex is the most important functional part of the kidney, because it has the Glomeruli.**

***Healthy kidneys contain approximately 1 million individual nephrons.**

***Each nephron consists of a glomerulus, which is responsible for ultrafiltration of blood.**

***The glomerulus comprises a tightly packed loop of capillaries supplied by an afferent arteriole and drained by an efferent arteriole covered by an extension of the tubules called Bowman's capsule.**



Normal Glomerular structure is needed to:

- Keep the glomerular filtration normal, thus maintains normal kidney function.
- keeps the urine volume maintained, so preventing fluid retention in the body which causes edema and high blood pressure.
- Prevents the blood components (cells, proteins) from leaving the blood stream and appearing in the urine.

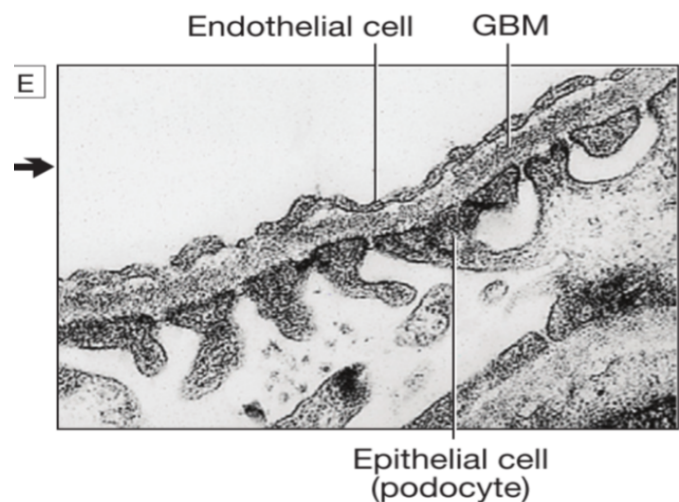
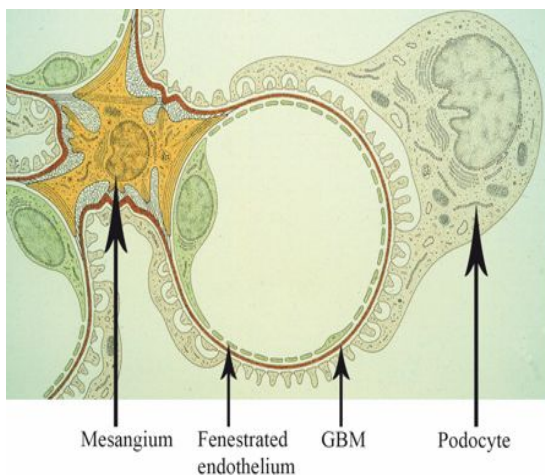
Layers of Glomerulus.

The ultrafiltrate must pass has 3 layers, through which filtration occurs:

1-Fenestrated endothelium	through which circulating molecules can pass to reach the underlying GBM.
2- Glomerular basement membrane	is the fusion of 2 basement membranes of capillary endothelium and tubular epithelium of bowman's capsule Blood that enters the glomerulus undergoes ultrafiltration across the glomerular basement membrane (GBM), If there is something targeting the endothelium or the basement membrane and because it's coming from blood component it's going to distract the barrier as a result the blood component will appear in the urine.
3- Podocyte	Podocytes of bowman's capsule have multiple long foot processes which interdigitate with those of the adjacent epithelial cells, it keeps protein out only low weight (20 KDa) can pass also it has negative charge which keeps albumin out because of the negative charge and because it's sitting outside, If there is autoantibody it might have a chance to escape because it's very fine and make the podocyte and the foot process abnormal but blood component will remain inside.

*Meningeal cells has also contractile and immunological properties.

***Any abnormality in structures mentioned above can lead to one of glomerular diseases.**



*Glomerular Diseases:

- ❖ can be primary (intrinsic renal pathology) or secondary (to a systemic disease).

Primary glomerular diseases: mostly caused by immune system dysfunction, Auto-antibodies targeting glomerular structure or immune-complexes (antigen-antibody) depositing and traumatizing the glomerular components.

The manifestations of a glomerular disease are usually indicative of which components of glomerular capillary wall was affected most.

Podocytes

mainly *proteinuria* (at large amount) will manifest; thus Nephrotic Syndrome will be the main finding.

endothelial cells, Mesangial cells or GBM

mainly *hematuria and abnormal renal function* with proteinuria will manifest because of disruption in glomerular filtration wall; thus Nephritic pattern of renal disease will manifest

*Diagnosis of glomerular Diseases.



1. Urinalysis (hematuria, proteinuria, RBC casts).
 2. Blood tests (renal function tests).
 3. Needle biopsy of the kidney (is the most accurate test to establish a diagnosis (though not always needed)).
- ❖ Glomerular diseases are named based on their histopathological characteristics seen under the microscope.
 - ❖ Glomerular diseases can be presented clinically as: A) **Nephrotic syndrome** B) **Nephritic syndrome**.

1. Nephrotic Syndrome (NS).

Nephrotic syndrome is a measure of the severity of proteinuria in association with any form of glomerular disease. Nephrotic syndrome occurs when proteinuria is so massive that the liver can no longer increase the production of albumin to compensate for urinary losses.

- **Podocytes abnormality** is the primary finding in Nephrotic syndrome.
- Podocytes will sustain a structural dysfunction; making them lose their Foot-processes, but the cells bodies are intact → This will lead to significant amount of protein appearing in the urine (Proteinuria).

Features of Nephrotic syndrome

Hypoalbuminemia:

serum Albumin <30 g/L while the normal between 35-55g/L

Heavy proteinuria:

> 3.5 g/24 hours of urine collection

Peripheral or generalized edema

Hyperlipidemia: Why the liver make lipoprotein? It's a false compensation of the low albumin try to maintain the oncotic pressure. But the lipoprotein going to be abundant they will be more available to carry LDL that's why they develop hypercholesterolemia

*Complications of Nephrotic Syndrome.

- Infections & sepsis : Because they lose immunoglobulin.
- Thrombosis : Low anticoagulant factors because they lost in the urine.
- Acute kidney injury : Because of the treatment.
- ESRD if heavy proteinuria does not resolve : Too much protein inside the renal tubules damages the renal tubules and make them fibrosis then develop end stage renal disease but is not fast.

17.14 Consequences of the nephrotic syndrome and their management			
Feature	Mechanism	Consequence	Management
Hypoalbuminaemia	Urinary protein losses exceed synthetic capacity of liver	Reduced oncotic pressure Oedema	Treat underlying cause
Avid sodium retention	Secondary hyper-aldosteronism Additional poorly characterised intrarenal mechanisms	Oedema	Diuretics and a low-sodium diet*
Hypercholesterolaemia	Non-specific increase in lipoprotein synthesis by liver in response to low oncotic pressure	High rate of atherosclerosis	Statins, ezetimibe
Hypercoagulability	Relative loss of inhibitors of coagulation (antithrombin III, protein C and S) and increase in liver synthesis of procoagulant factors	Venous thromboembolism	Consider prophylaxis in chronic or severe nephrotic syndrome
Infection	Hypogammaglobulinaemia due to urinary loss of immunoglobulins	Pneumococcal and meningococcal infection	Consider vaccination

*Severe nephrotic syndrome may need very large doses of combinations of diuretics acting on different parts of the nephron (e.g. loop diuretic plus thiazide plus amiloride). In occasional patients with hypovolaemia, intravenous salt-poor albumin infusions may help to establish a diuresis, although efficacy is controversial. Over-diuresis risks secondary impairment of renal function through hypovolaemia.

*Clinical Presentations of Nephrotic Syndrome.

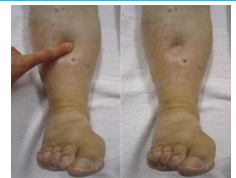
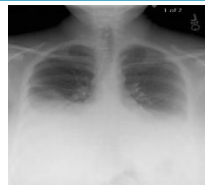
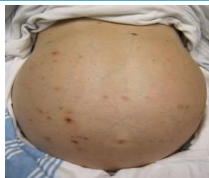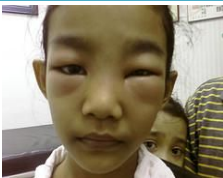➤ Generalized Edema due to:

- 1- Low serum Albumin (Low oncotic pressure).
- 2- Increase Renal sodium retention.

Because of uncontrolled activation of the epithelial sodium channels (ENaC channels in the renal tubules).

- **Fatigue.**
- **Frothy urine** (froth persists for long time after voiding and is due to the large amount of proteins in urine).
- **Anorexia.**
- **Nausea & vomiting.**
- **Abdominal pain.**
- **Weight gain due to fluid retention.**
- **Shortness of breath if having pleural effusion.**
- **Signs & symptoms of DVT, PE.**



Periorbital edema :

Is characteristic of nephrotic syndrome and happens in the morning because it's with gravity when they start walking during the day it disappear

Ascites

Pleural effusion

Pitting edema



Why not develop pulmonary edema? in pulmonary circulation for fluid to exchange between the alveolar interstitium and alveolar capillaries based on hydrostatic pressure not the oncotic pressure

***Diagnostic Tests of nephrotic Syndrome.**

1. The best initial test is a urinalysis, however since renal function varies with the time of day, as well as posture (flat or upright), the UA is not sufficiently accurate
2. The urine albumin/creatinine ratio: gives a measure of the average protein produced over 24 hours
3. The urine albumin/creatinine spot urine ratio is equal to a 24-hour urine
4. Renal biopsy is the most accurate test

Urine Analysis in Nephrotic Syndrome will show :

- Proteinuria or called Nephrotic range proteinuria (>3.5 g/24h urine)
- No RBCs (some times few are occasionally seen).
- No RBCs casts
- Fat (Lipiduria)(Fatty casts, oval fat bodies & fat droplets).
- No WBCs (few may be seen).

***Glomerular Diseases that present as Nephrotic Syndrome:**

1-Focal Segmental GlomeruloSclerosis (FSGS)

2- Minimal Change Disease (MCD)

3- Membranous Nephropathy (MN)

- **Secondary causes :** Diabetes Mellitus
- Amyloidosis
- IgA Nephropathy
- MPGN

1-Focal Segmental Glomerulosclerosis (FSGS)

Primary FSGS

- can occur in all age groups. In some patients, FSGS can have specific causes, such as HIV infection, podocyte toxins and massive obesity, but in most cases the underlying cause is unknown.
- A common cause of Nephrotic syndrome in adults..
- Has sudden onset of heavy proteinuria and other manifestations of nephrotic syndrome.
- Usually **first line** treatment with corticosteroids , **second**: immune suppressing medications such as ciclosporin, cyclophosphamide and mycophenolate mofetil
- Progression to CKD is common in patients who do not respond to steroids.

Secondary FSGS

- Proteinuria is less heavy than other causes of nephrotic syndrome.
- Serum Albumin is not very low like the primary type.
- Hematuria and HTN are often present.
- Renal impairment is commonly seen and this is not a good prognostic sign.
- not typically treated with Immunosuppression, treat the primary cause and add supportive measures to protect the kidneys, e.g. keeping blood pressure well controlled with ACEi.

Possible causes of Secondary FSGS:

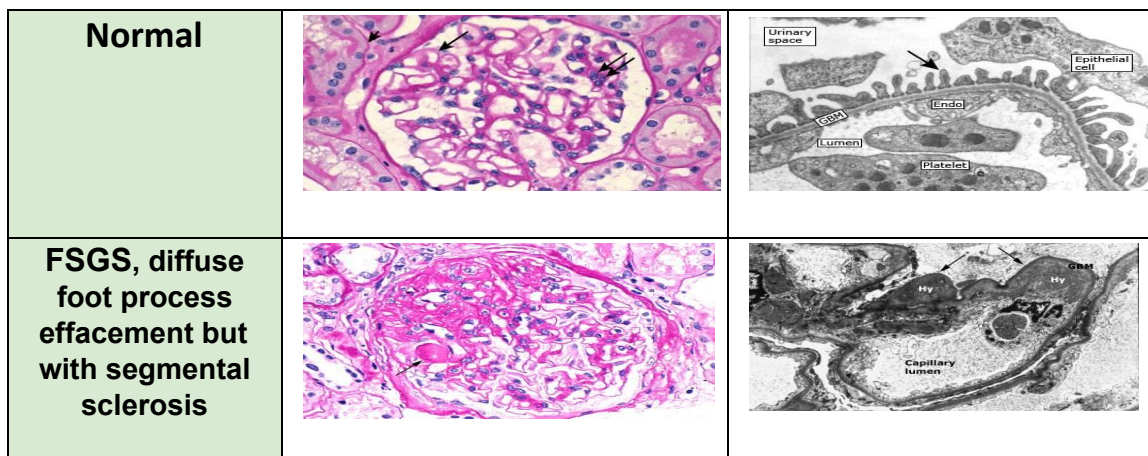
- Obesity.
- Nephron loss (> 75% of renal mass) e.g renal agenesis.
- Reflux nephropathy.
- Healing of prior GN (example IgA).
- Anabolic steroid abuse.
- Severe preeclampsia.
- Drugs: Interferon, Pamidronate, Heroin
- the focal scarring may reflect healing of previous focal glomerular injury, such as Haemolytic uraemic syndrome, cholesterol embolism or vasculitis. These examples of secondary FSGS.

FSGS Seen on light microscopy as:

Focal: some glomeruli are affected by sclerosis (the rest of them look normal)

Segmental: sclerosis only involves a segment of each glomerulus that is affected.

But most important; all glomeruli (the ones affected by sclerosis and the ones that are not affected) will have a diffuse foot processes effacement (thus Nephrotic syndrome appears).



2-Minimal Change Disease (MCD)

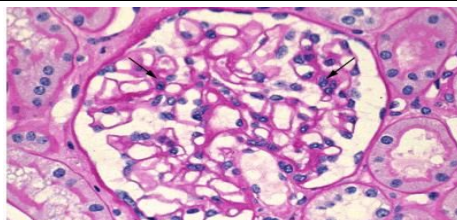
<u>Primary MCD</u>	<u>Secondary MCD</u> (much less common)
Idiopathic	<ul style="list-style-type: none"> ▪ Drugs (NSAIDs, Lithium, Sulfasalazine, Pamidronate, D-penicillamine, some antibiotics) ▪ Neoplasm (Hodgkin Lymphoma, non-Hodgkin lymphoma, and leukemia). ▪ Infections (TB, syphilis). ▪ Allergy.

- It is the **main cause** of Nephrotic syndrome **in children**, 90 % of cases in children < 10 years old.
- It is caused by reversible dysfunction of podocytes.
- The presentation is with proteinuria (nephrotic syndrome), BP may be normal or slightly elevated and creatinine is always within the normal range or slightly elevated and normalizes with remission.
- does not progress to CKD but can present with problems related to the nephrotic syndrome and complications of treatment, **Excellent prognosis**.
- In children; typically is corticosteroid responsive in > 90%, thus kidney biopsy is commonly not done and treatment is given empirically for such cases. So, usually nephrotic syndrome in a child < 10 years old is MCD until proven otherwise.

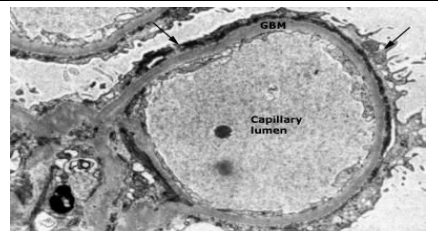
Histopathology:

Called **minimal** because:

- light microscopy: is typically showing normal glomeruli So called: nil disease.
- electron microscopy: shows diffuse effacement of the epithelial cells' foot processes only.
- So the most important difference between MCD and the FSGS is the presence of glomerular sclerosis in FSGS
- Here there is no sclerosis i.e. in MCD.



basically no abnormality is seen on light microscopy



EM shows the diffuse foot process effacement

3-Membranous Nephropathy (MN)

*also known as membranous nephropathy, is the **most common** cause of Primary nephrotic syndrome in **adults**.

*Presentation: slowly developing nephrotic syndrome gradually within a month not like the minimal within week or five days.

Primary MCD

*It is caused by antibodies (usually autoantibodies) directed at antigens) expressed on the surface of podocytes. **but most are idiopathic.**

*glomerular capillary walls are thickened.

*Approximately one third of patients with idiopathic membranous glomerulonephritis undergo spontaneous remission; one third remain in a nephrotic state, and one third go on to develop CKD.

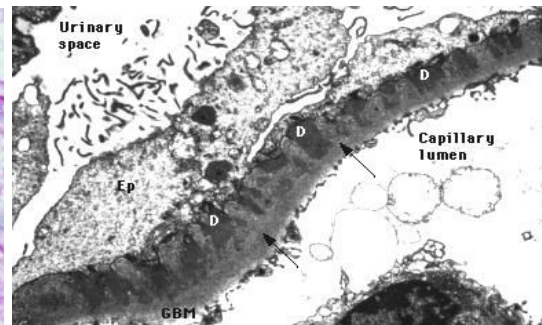
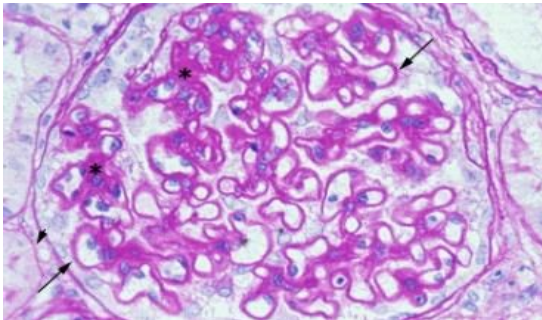
Secondary MCD

*The secondary form is due to infection (hepatitis C virus, hepatitis B virus, syphilis, malaria), drugs (gold, captopril, penicillamine), neoplasm (prostate, lung, or GI tract), or lupus (Class V Lupus Nephritis).

*Treatment of Primary MN :Corticosteroids plus Cyclophosphamide or cyclosporine and May be Rituximab

*Secondary MN: Mainly target the primary disease that caused MN, and treat the Nephrotic syndrome manifestations.

Histopathology:



Diffuse thickening of the glomerular capillary wall throughout all glomeruli (IgG and C3 deposition)

17.39 Glomerulonephritis: types, associations and causes				
Histology	Immune deposits	Pathogenesis	Associations	Comments
Minimal change Normal, except on electron microscopy, where fusion of podocyte foot processes is seen (a non-specific finding)	None	Unknown	Atopy HLA-DR7 Drugs	Acute and often severe nephrotic syndrome Good response to corticosteroids Dominant cause of idiopathic nephrotic syndrome in childhood
Focal segmental glomerulosclerosis (FSGS) Segmental scars in some glomeruli No acute inflammation Podocyte foot process fusion seen in primary FSGS with nephrotic syndrome	Non-specific trapping in focal scars	Unknown; in some, circulating factors increase glomerular permeability Injury to podocytes may be a common feature	Healing of previous local glomerular injury HIV infection Heroin misuse Morbid obesity	<i>Primary FSGS</i> presents as idiopathic nephrotic syndrome but is less responsive to treatment than minimal change; may progress to renal impairment, can recur after transplantation <i>Secondary FSGS</i> presents with variable proteinuria and outcome
Focal segmental glomerulonephritis Segmental inflammation and/or necrosis in some glomeruli ± crescent formation	Variable according to cause, but typically negative (or 'pauci-immune')	Small-vessel vasculitis	Primary or secondary small-vessel vasculitis	Often occurs in systemic disease. Responds to treatment with corticosteroids and immunosuppressants Check ANCA, ANA
Membranous glomerulonephritis Thickening of GBM Progressing to increased matrix deposition and glomerulosclerosis	Granular subepithelial IgG	Antibodies to a podocyte surface antigen, with complement-dependent podocyte injury	HLA-DR3 (for idiopathic) Drugs Mercury, heavy metals Hepatitis B virus Malignancy	Usually idiopathic; common cause of adult idiopathic nephrotic syndrome One-third progress; may respond to corticosteroids and immunosuppressants

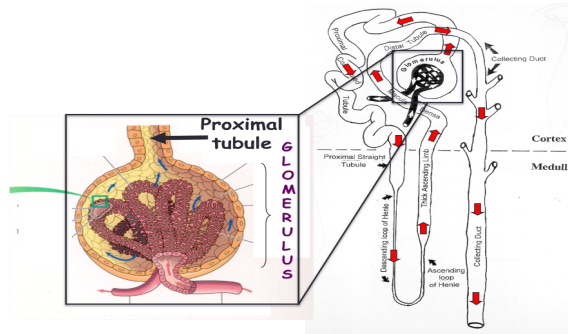
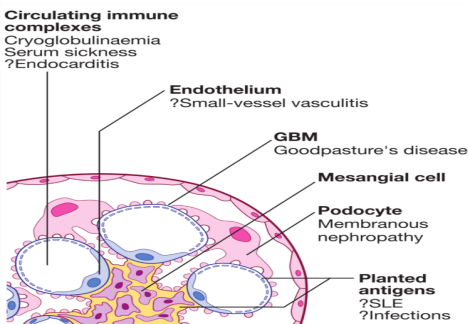
2. Nephritic Syndrome.

*Glomerulonephritis literally means 'inflammation of glomeruli' what why it's called nephritic as in nephritis.

Nephritic; it means a clinical pattern of presentation for a group of GNs, and not a syndrome like what we saw in Nephrotic causes.

The **Nephritic** pattern is always indicative of underlying **inflammatory process in the glomeruli**; causing inflammatory modulators attraction, cellular proliferation and eventually glomerular permanent dysfunction if left untreated.

The Glomerular mesangium, endothelium and GBM components of the Glomerulus are likely going to be targeted because of their proximity to blood circulation.



Nephritic urine analysis shows:

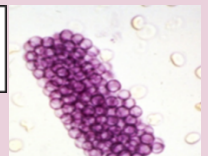


- Red Blood Cells (RBCs)
- RBCs casts : RBCs usually don't pass through if they pass due to an inflamed glomerulus , in the ascending convoluted tubules and collecting duct there is a mucoprotein called *Tamm-Horsfall* which is very sticky collect RBCs forming the casts.
- Dysmorphic RBCs (RBCs lose their smooth surface passing through the cracks in inflamed glomerular basement membrane – they get pushed through the cracks which Deform them).
- Protein (at variable amount from mgs to grams per day).

Those are called **Active Urinary Sediments**.

(Active = is indicative of underlying glomerular inflammatory process; requiring medical attention)

RBCs cast



*Clinical manifestations of Nephritic Syndrome



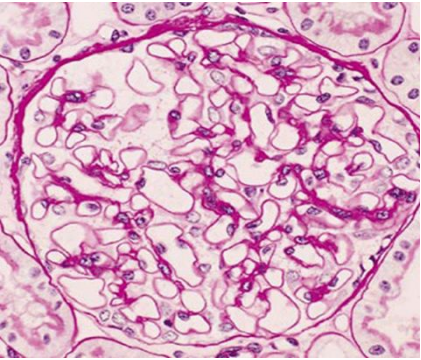
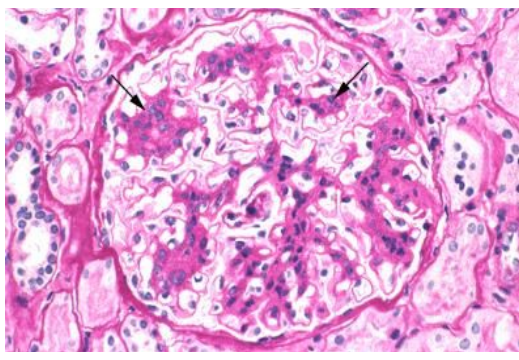
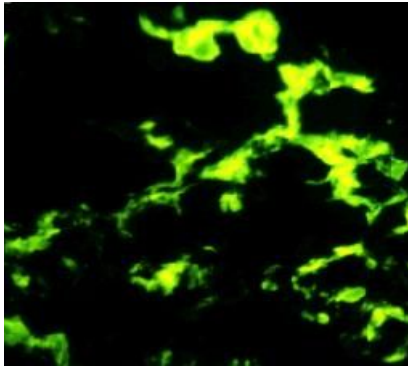
- **AKI** (Acute Kidney Injury) =Acute Renal impairment or Failure= elevated Creatinine).
- **Decreased Urine output.**
- **Edema.**
- **High Blood Pressure.**
- May have other manifestations of systemic vasculitis since some GN types are actually vasculitis (e.g. skin rash, pulmonary hemorrhage, etc).
- Positive immune markers: ANA, Anti-DNA, low complements, +ve ANCA (depends on the cause).

3. Glomerulonephritis (GN).

Renal Diseases that can present with **Nephritic** picture:

- IgA Nephropathy / HSP (Henoch-Schönlein purpura)
- Post streptococcal glomerulonephritis (PSGN)
- Lupus Nephritis
- Anti-GBM (Goodpasture's disease)
- ANCA vasculitis (e.g. Wegener's Granulomatosis)
- Membranoproliferative GN (MPGN)

1-IgA Nephropathy (Berger diseases).	
<p style="text-align: center;">*Most common type of Primary GN in adults in developed countries also Asian race.</p> <p style="text-align: center;">*Used to be called benign hematuria but changed due to it begin one of the common causes of ending on dialysis due to progression to ESRD, it has Good prognosis in children bad in adults and older children</p>	
<u>Pathophysiology</u>	<p>*The IgA antibody get stuck because it's too big to pass cause immune reaction in the site immunoglobulin in the Glomeruli, it elicits a local inflammatory response in the Glom mesangium (mesangial expansion).</p> <p>*It is thought to be secondary to altered mucosal immunity that leads to excessive IgA synthesis followed by deposition in the gloms.</p>
<u>Presentation</u>	<p>*Can present as dark urine (hematuria) 1-3 days and hypertension after upper respiratory tract infection. (< one week of URT infection).</p> <p>*picked up incidentally by finding abnormal urine analysis (Hematuria+/- Proteinuria) done for other reasons with no symptoms.</p>
<u>Diagnosis</u>	<ul style="list-style-type: none"> • Needs kidney biopsy to reach the diagnosis. • The diagnosis is made by finding abnormal deposition of IgA
<u>Treatment</u>	<ul style="list-style-type: none"> • Most important treatment is to control the blood pressure which also decreases the proteinuria. • Treated in severe diseases with ACE inhibitors and steroids <p>There is really no effective immunosuppressing therapy except in severe cases where it can be tried.</p>
<u>Prognosis</u>	<p>*Asymptomatic presentations dominate in older adults, with hematuria, hypertension and loss of GFR. Occasionally, IgA nephropathy progresses rapidly and crescent formation may be seen.</p>
<u>Related diseases</u>	<ul style="list-style-type: none"> • HSP (Henoch-Schönlein purpura) in children is a systemic vasculitis caused by immune deposition of IgA in different organs; typically: <p>*Skin(rash typically affecting buttocks and lower legs)</p> <p>*bowel (abdominal pain due to vasculitis involving the gastrointestinal tract) and kidneys.</p>

		
Normal Glomerulus	IgA nephropathy	IgA immune Floreence

2-Post streptococcal glomerulonephritis (PSGN).

Common in children than adults

Pathophysiology	<p>*Typically caused by throat infection with Gram positive cocci (Group A beta-hemolytic Streptococcus (GAS) . But also can be caused by Staphylococcus soft tissue or bone infection in adults.</p> <p>*Bacterial Antigen cross react with Glom antigens, or may be an immune-complex (Antigen-antibody) response that is responsible.</p>
Presentation	<ul style="list-style-type: none"> • frank hematuria usually after one week and up to 3 weeks from the start of infection. Dark smoky appearance due to hematuria and proteinuria. • The difference between PSGN and IgA is timing of hematuria IgA present 3 days after infection PSGN 1wk. • Periorbital edema. • Hypertension.
Diagnosis	<ul style="list-style-type: none"> • Serum will show positive Antistreptolysin (ASO) titer.also anti-DNAse antibodies. • Low C3, Normal or slightly low C4 in the serum. • No need for biopsy. • May have positive throat culture.
Treatment	fluid and sodium restriction with diuretic and hypotensive agents is usually adequate antibiotic might be added depending on case.
Prognosis	<ul style="list-style-type: none"> • Children have better and faster recovery than adults. • Treatment is usually supportive= wait and see. • renal lesion in almost all children and many adults seems to resolve completely, despite the severity of the glomerular inflammation.

3-Lupus Nephritis.

The Disease with a Thousand Faces Kidneys can be affected by SLE like other organs.

Pathophysiology	Some anti-DNA antibodies also bind to glomerular Targets cause inflammation.
Presentation	*Symptoms of SLE most commonly (malar rash , arthritis , Discoid rash etc...) *It can present systematic or just renal nephritic manifestations*Most important in dealing with these cases is having high suspicion of its presence and to start immediate workup & referral for diagnosis and treatment.
Diagnosis	*Kidney biopsy is mandatory to make the diagnosis. *Low complements (C3, C4) level along with the positive Lupus marker (Antinuclear antibody ANA), abnormal urine analysis & abnormal renal function should make you think of its presence.
Treatment	*Lupus Nephritis treatment depends on the findings in renal biopsy. It usually involves high degree of immunosuppressing medications.
Prognosis	*The degree of involvement can be from mild (or even not visible to the physician) to a very severe one causing ESRD in few months.

4-ANCA vasculitis.

- Autoimmune disease that involves the presence of Neutrophils adhesion enhancing molecule called **ANCA=Anti-neutrophil cytoplasmic antibody.**

Two types of ANCA:

1- C-ANCA= Cytoplasmic type, more commonly causing Granulomatous Polyangiitis = old name *Wegener's Granulomatosis* (so a **granuloma forming disease**)

Angiitis: means small vessels vasculitis

2- P-ANCA= Perinuclear type, more commonly associated with Microscopic Polyangiitis & Churg-Strauss syndrome

Presentation	<ul style="list-style-type: none"> Upper airways and lung involvement is common and patients can present with renal and pulmonary manifestations (GN + Pulmonary hemorrhage: hemoptysis)
Diagnosis	<ul style="list-style-type: none"> Diagnosis is made by kidney biopsy and positive ANCA titer in the serum. Hemoptysis , SOA, chest x-ray abnormal , hematuria , increase PB, increases carnitine in blood (whiter ANCA or goodpasture)
Treatment	immunosuppression that includes corticosteroids and cyclophosphamide.

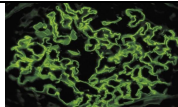
5-Anti-GBM antibody disease, (also called: Goodpasture's Syndrome).

- Due to autoantibody against (alpha-3 chain) of type IV Collagen that is found in Glomerular & alveolar (lungs) basement membrane.
- So the manifestations will be:
 - 1- GN (can be the only presenting finding) &
 - 2- Pulmonary hemorrhage (if with GN; is called Goodpasture's disease = Lungs + renal involvement.
 - 3- positive test for Anti-GBM antibodies in the serum
 - 4- Kidney biopsy shows the diagnostic Immunofluorescence pattern : Linear stain of IgG and C3.

*it present with renal and lung only with NO involvement no upper respiratory , present with anemia due to hemoptysis (blood loss through urine and cough). *it's diagnosed by : anti- basement membrane antibodies .

Treatment

If Linear Anti-GBM positive always started immediately to remove the antibodies by **Plasmapheresis** and preventing further antibodies production by giving heavy immunosuppression that includes corticosteroids and cyclophosphamide.



Linear Anti-GBM staining by Immunofluorescence is a *Diagnostic test*

6-Membranoproliferative GN (MPGN).

- Also called Mesangiocapillary glomerulonephritis
- characterized by an increase in mesangial cellularity with thickening of glomerular capillary walls and subendothelial deposition of immune complexes and/or components of the complement pathway

It is a pathological description & has multiple causes It may present with Nephritic picture or Nephrotic syndrome The primary (idiopathic) MPGN is mainly seen in children.

The secondary type is seen in adults due to:

- Hepatitis B and C
- Endocarditis
- Lupus and Sjogren's syndrome
- Cancer
- Complement deficiency

*Extra ones not mentioned by doctor.

Polyarteritis nodosa	*it's a systemic vasculitis ,similar to ANCA vasculitis but ANCA is usually not present. *spare the lungs but affect GI , neuro , skin , cardiac , hint: it cause stroke in a young person
Inherited glomerular diseases	-
Alport syndrome	*X-linked recessive mutation in type 4 collagen leading to thinning of GBM processes from hematuria to ESKD, *Associate with: sensorineural deafness and ocular abnormalities.

Summary.

TABLE 7-5 Nephritic Versus Nephrotic Syndrome

	Nephritic Syndrome	Nephrotic Syndrome
Pathogenesis	Inflammation of glomeruli due to any of the causes of glomerulonephritis	Abnormal glomerular permeability due to a number of conditions
Causes	Poststreptococcal glomerulonephritis is the most common cause, but may be due to any of the causes of glomerulonephritis	Many conditions. Membranous glomerulonephritis is the most common cause in adults. Other causes include diabetes, SLE, drugs, infection, glomerulonephritis (focal segmental and others) Minimal change disease is the most common cause in children
Laboratory findings	Hematuria AKI—azotemia, oliguria Proteinuria, if present, is mild and not in nephrotic range	Urine protein excretion rate >3.5 g/24 hr Hypoalbuminemia Hyperlipidemia, fatty casts in urine
Clinical findings	HTN Edema	Edema Hypercoagulable state Increased risk of infection

Histology	Immune deposits	Pathogenesis	Associations	Comments
Goodpasture's disease Usually crescentic nephritis	Linear IgG along GBM	Autoantibodies to α 3 chain of type IV collagen in the GBM	HLA-DR15 (previously known as DR2)	Associated with lung haemorrhage but either may occur alone Treat with corticosteroids, cyclophosphamide and plasma exchange
Lupus nephritis Almost any histological type	Always positive and often profuse Pattern varies according to type	Some anti-DNA antibodies also bind to glomerular targets	Complement deficiencies Complement consumption	Variable presentation, sometimes as renal disease alone without systemic features Responds to cytotoxic therapy in addition to prednisolone
(ANCA = antineutrophil cytoplasmic antibodies; ANA = antinuclear antibody; HLA = human leucocyte antigen)				
IgA nephropathy Increased mesangial matrix and cells Focal segmental nephritis in acute disease	Mesangial IgA	Unknown	Usually idiopathic Liver disease	Common disease with a range of presentations, usually including haematuria and hypertension
Mesangiocapillary glomerulonephritis <i>Immunoglobulin type</i>	Immunoglobulins	Deposition of circulating immune complexes or 'planted' antigens	Infections, autoimmunity, or monoclonal immunoglobulin-related	Most common pattern found in association with subacute bacterial infection, but also with Cryoglobulinaemia \pm hepatitis C virus, and others In dense deposit disease, intramembranous deposits No proven treatments
<i>Complement type</i>	Complement components	Complement abnormalities, inherited or acquired. Dense deposit disease is associated with abnormal activation of the alternative complement pathway	Complement gene mutations C3 nephritic factor and partial lipodystrophy	
Post-infection Diffuse proliferation of endothelial and mesangial cells Infiltration by neutrophils and macrophages \pm crescent formation	Subendothelial	Immune response to streptococcal infection with presumed cross-reactive epitopes	Streptococcal and other infections	Now rare in developed countries Presents with severe sodium and fluid retention, hypertension, haematuria, oliguria Usually resolves spontaneously