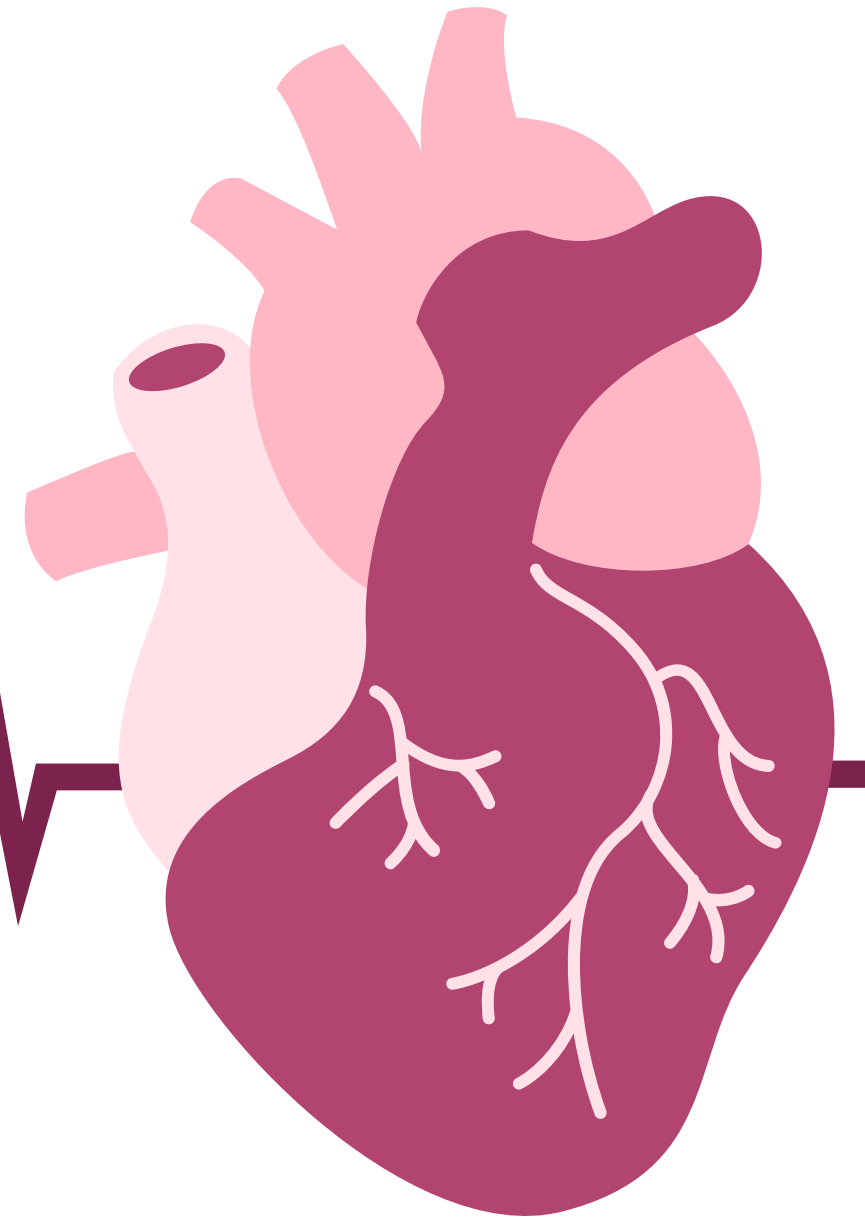

Lecture 2

MEDIASTINUM



OBJECTIVES

- Define the Mediastinum.
- Differentiate between the divisions of the Mediastinum.
- List the boundaries and contents of each division.
- Describe the relations between the important structures in each division.

Color Index:

- Main text
- Boys' Slides
- Girls' Slides
- Important
- Dr's Notes
- Extra

 Editing File

The Mediastinum

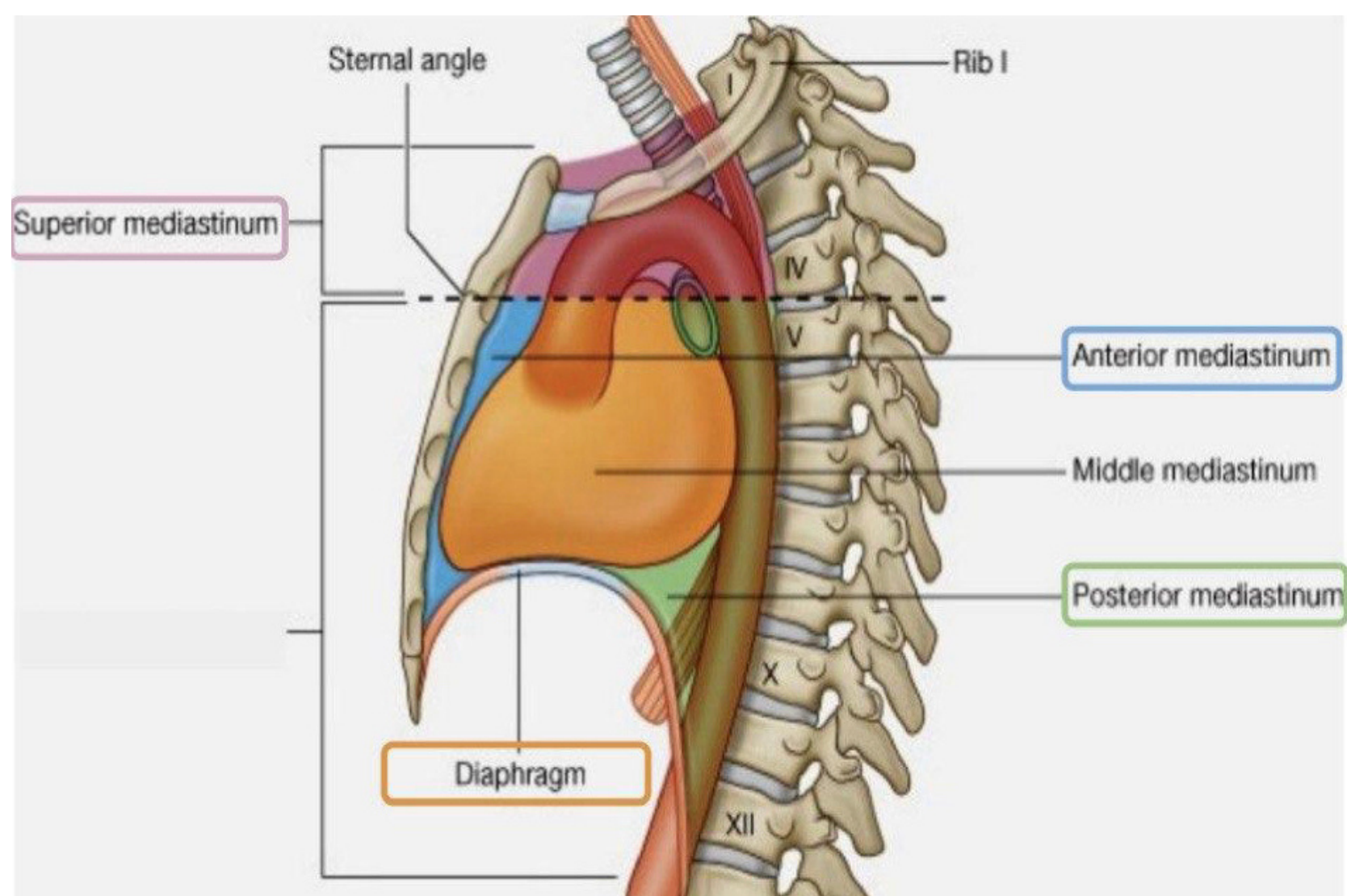
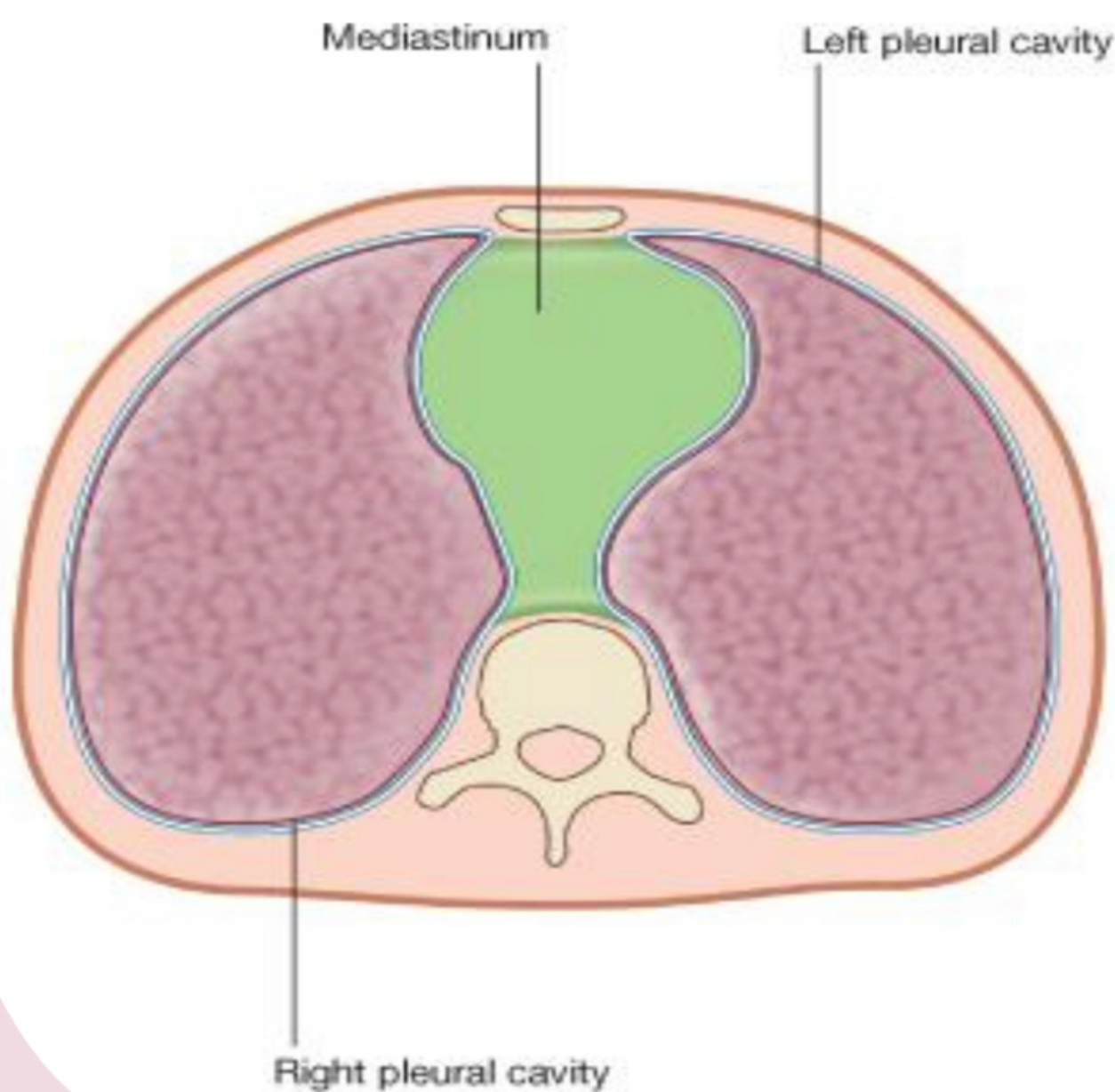
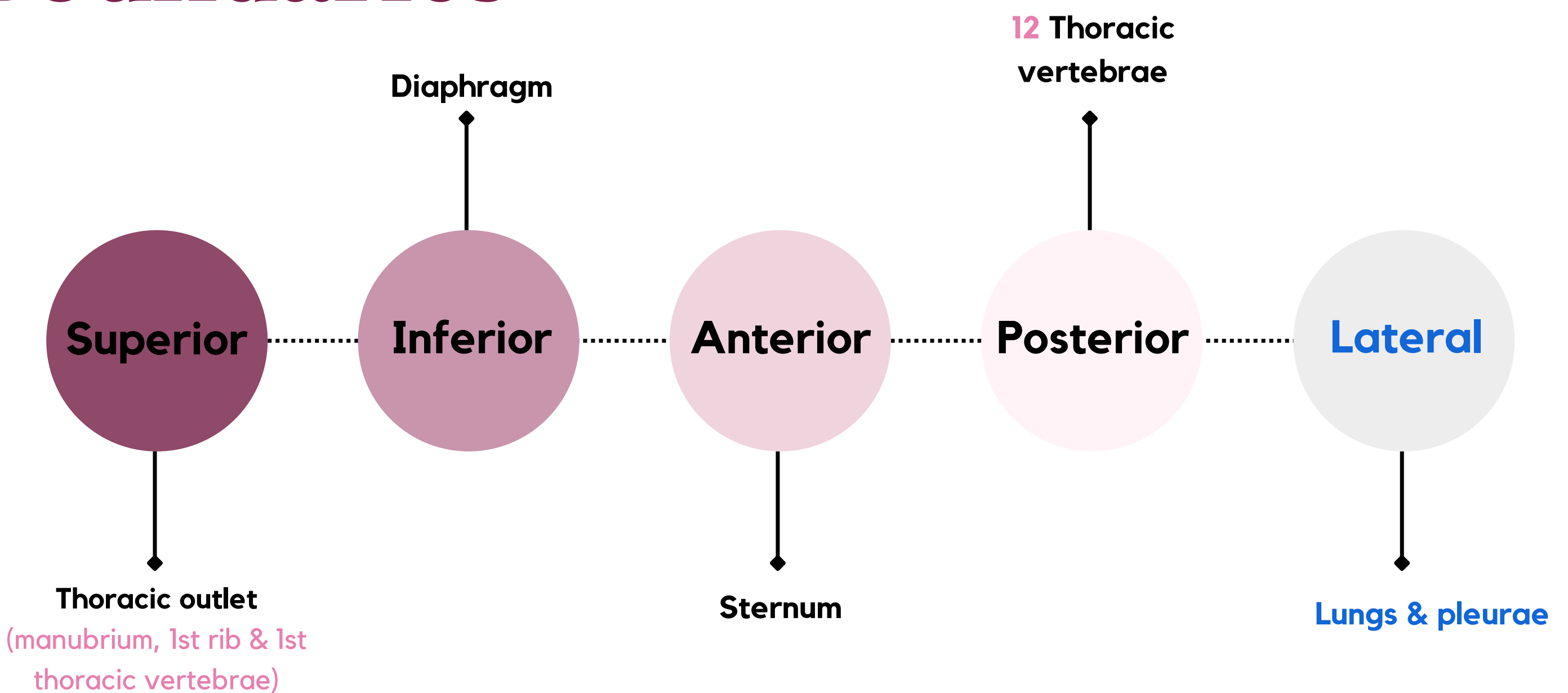
1

It is a **thick movable** partition between the two pleural (Right & Left) sacs & lungs.

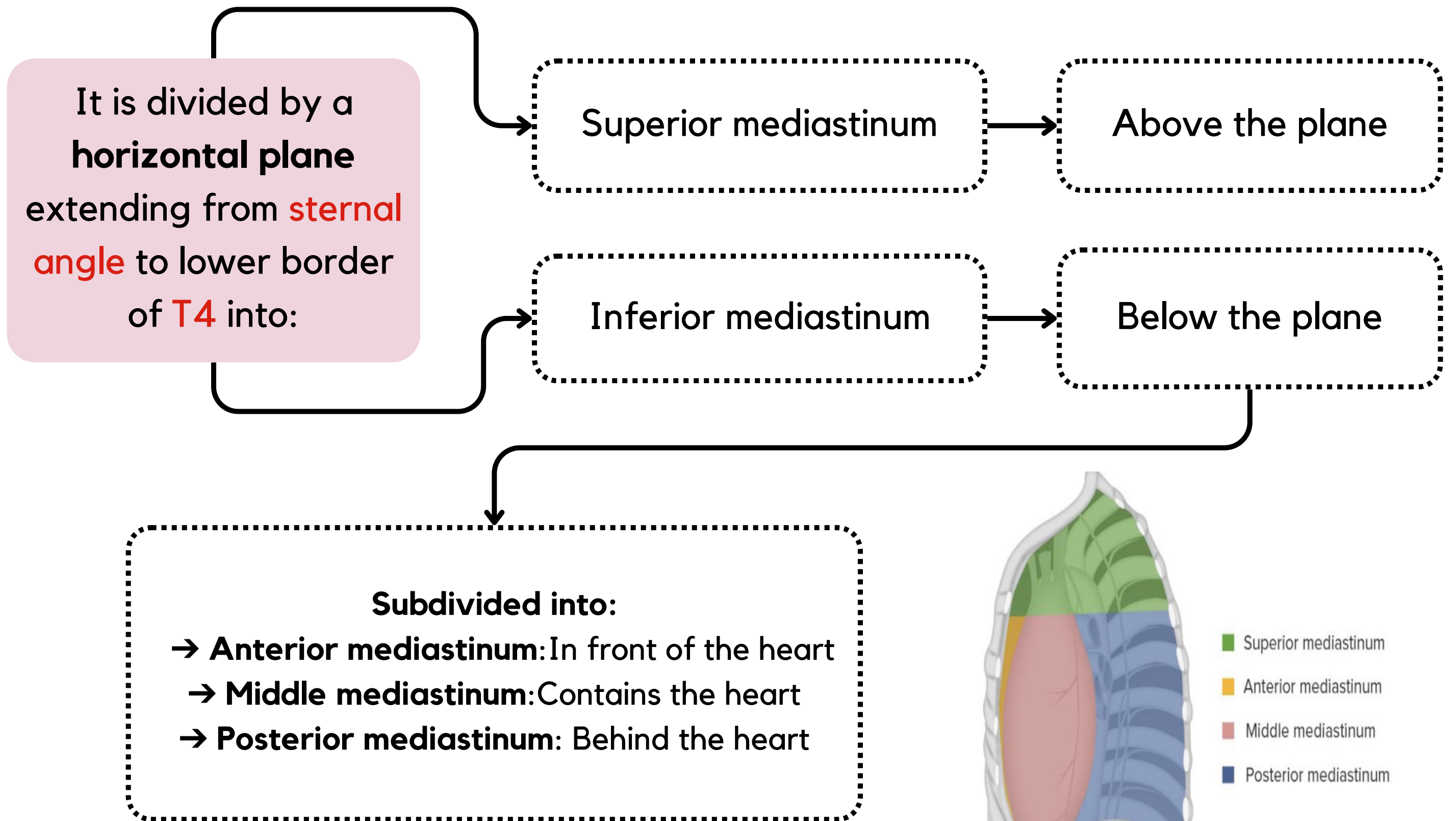
2

It contains all the structures which lie in the intermediate compartments of the thoracic cavity.

Boundaries



Divisions of Mediastinum



Level of T4

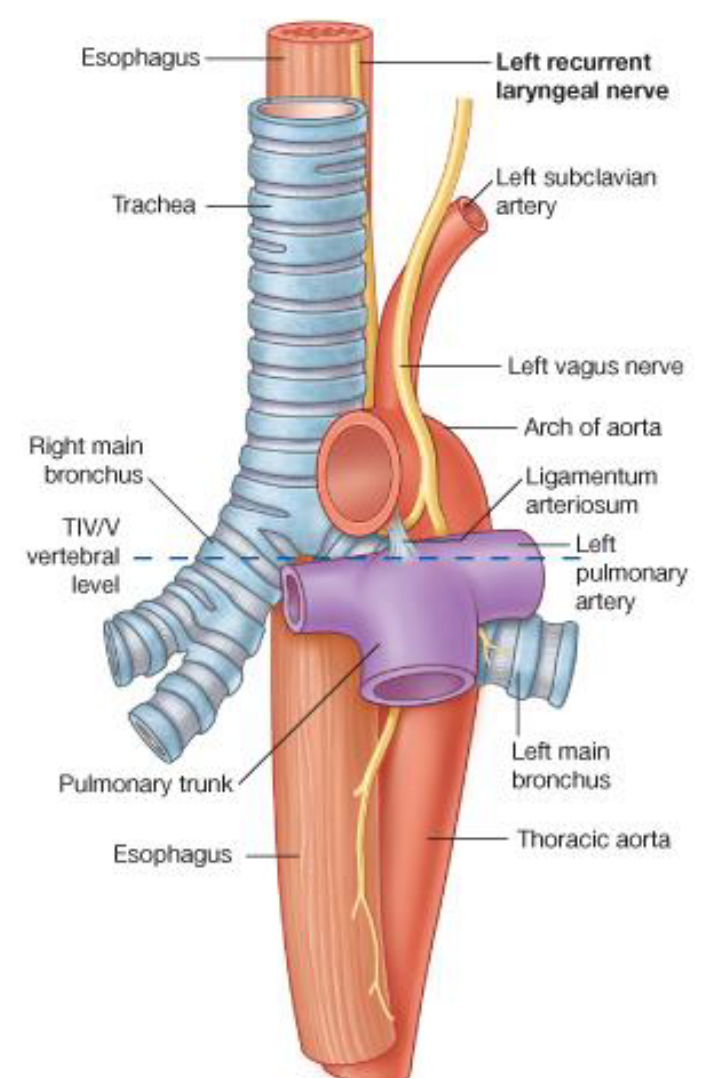
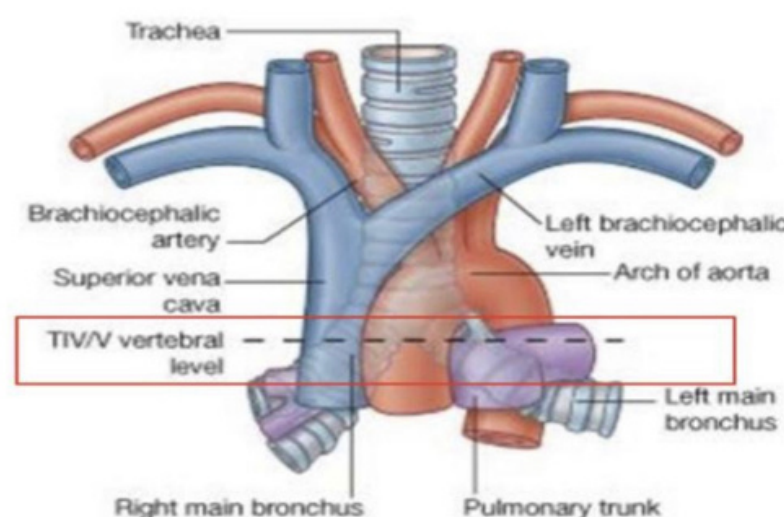
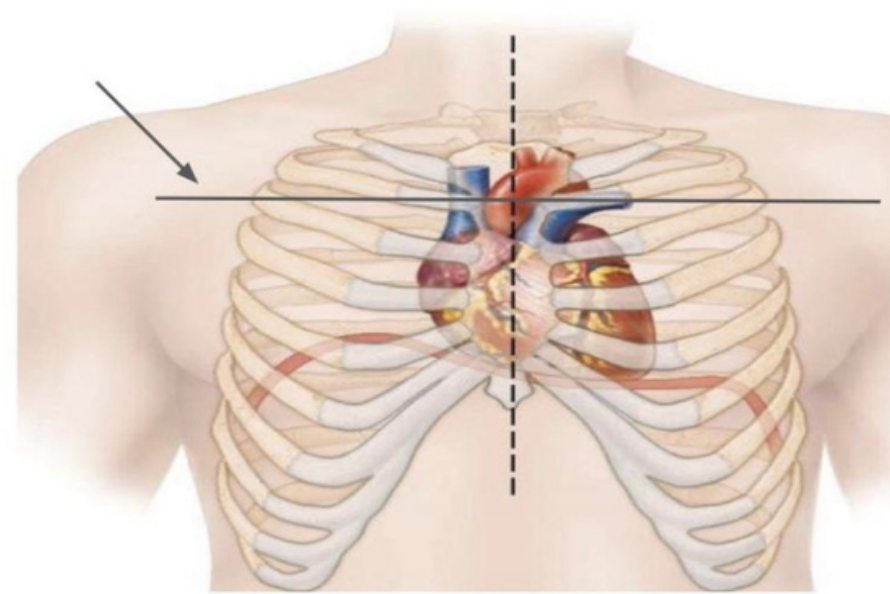
It is at the level of:

- ◆ 1. Sternal angle
- ◆ 2. Second costal cartilage

Why is this level important?

◆ It is the level of:

1. Bifurcation of trachea
2. Bifurcation of pulmonary trunk
3. Beginning & termination of arch of aorta
4. Termination of arch of azygos vein into SVC



Superior Mediastinum

Boundries

Anterior

Manubrium of sternum

Not very distinguishable in this picture but it's located here

Lateral

Lungs & pleurae

Superior

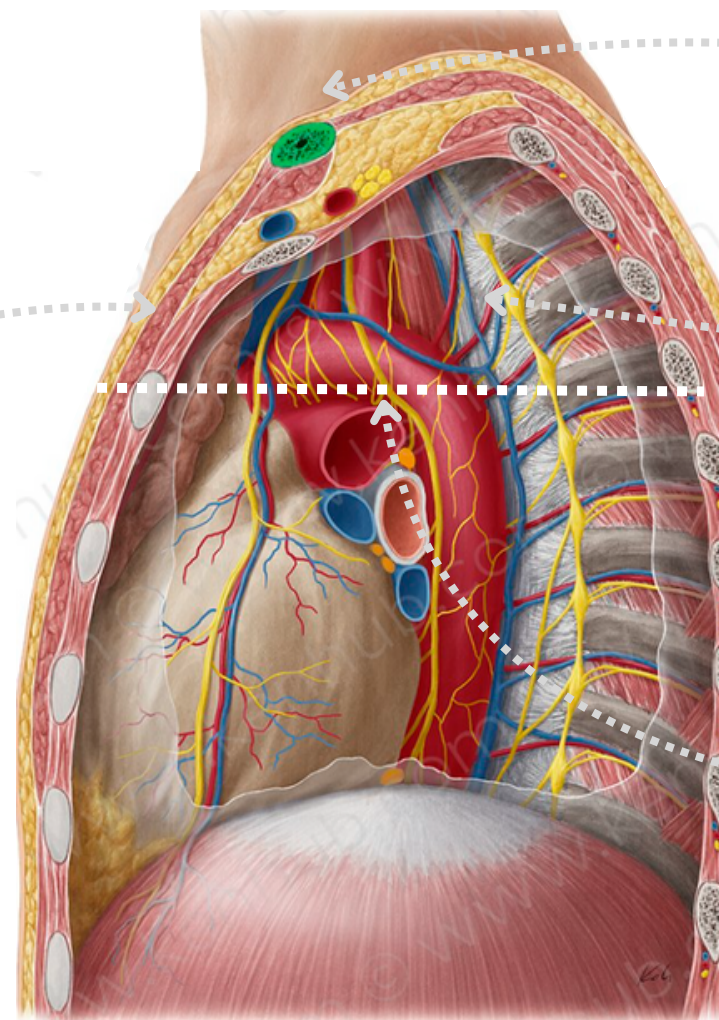
Thoracic outlet

Posterior

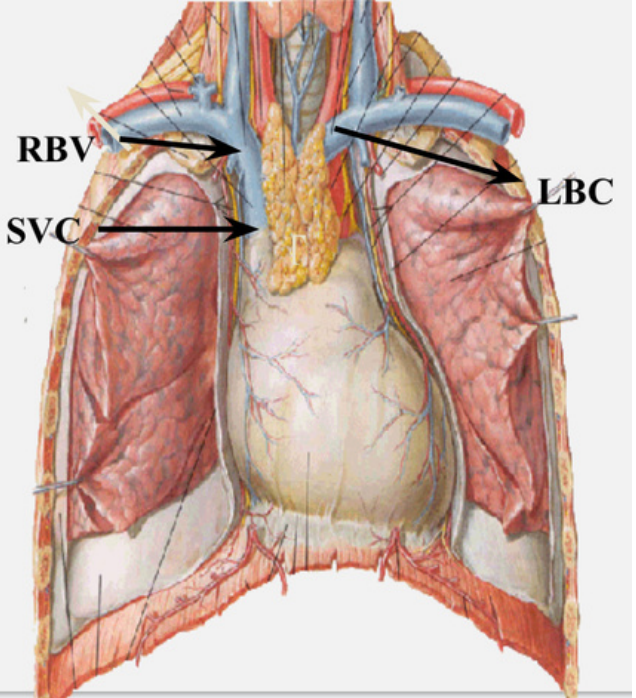
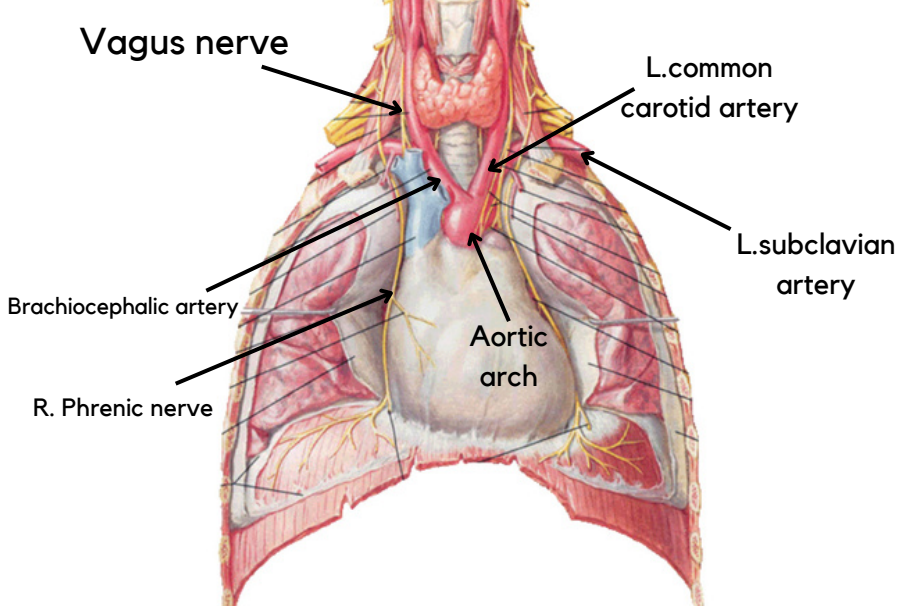
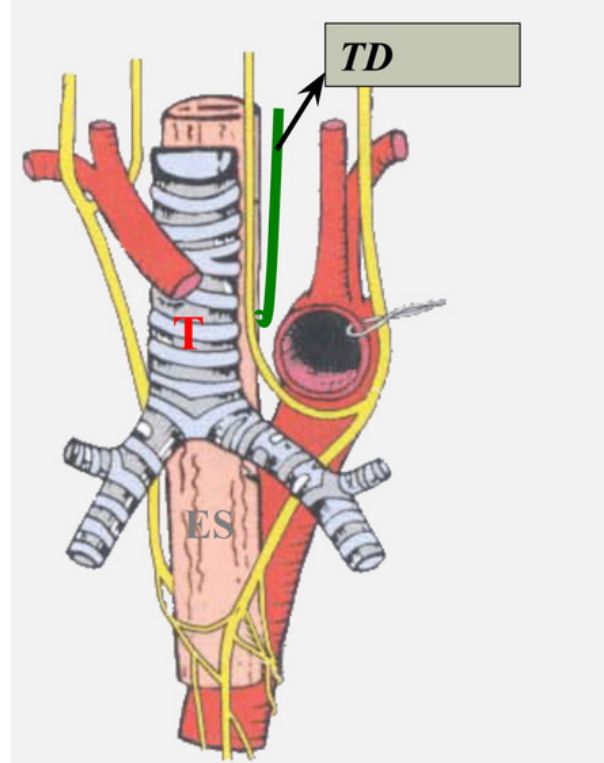
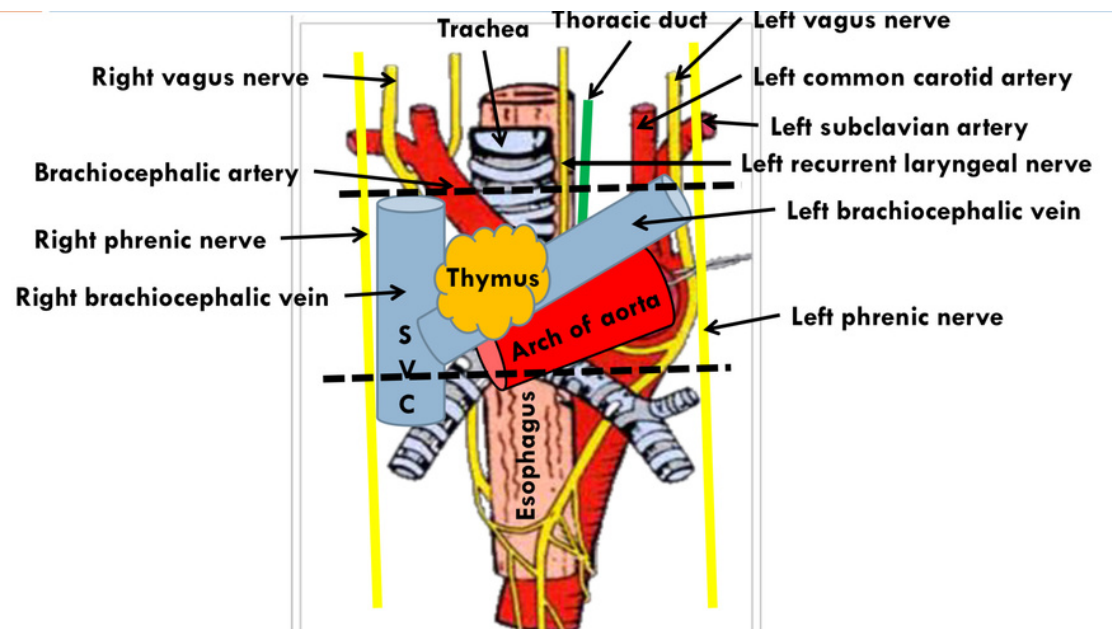
Upper 4 thoracic vertebra

Inferior

Horizontal plane



Contents

Superficial	Intermediate	Deep
<p>1 Gland: - Thymus gland</p> <p>3 Veins: - Right brachiocephalic vein - Left brachiocephalic vein - Superior vena cava</p> 	<p>4 Arteries: - Arch of aorta & its 3 branches: - Brachiocephalic artery - Left common carotid artery - Left subclavian artery</p> <p>4 Nerves: - Right & left Vagus nerve - Right & left Phrenic nerve</p> 	<p>- Lymph node</p> <p>2 Tubes: - Trachea - Esophagus</p> <p>1 Duct: - Thoracic duct</p> 
<h2>All contents</h2>		<p>Note that: Left recurrent laryngeal nerve Left common carotid artery Left subclavian artery</p> <p>Located in the superior mediastinum</p> <p>But: Right recurrent laryngeal nerve Right common carotid artery Right subclavian artery</p> <p>Not located in all divisions of the mediastinum</p>

Inferior Mediastinum

3 Inferior mediastinum subdivisions

Anterior Mediastinum

Middle Mediastinum

Posterior Mediastinum

Boundaries

Anterior

Body and xiphoid process of sternum

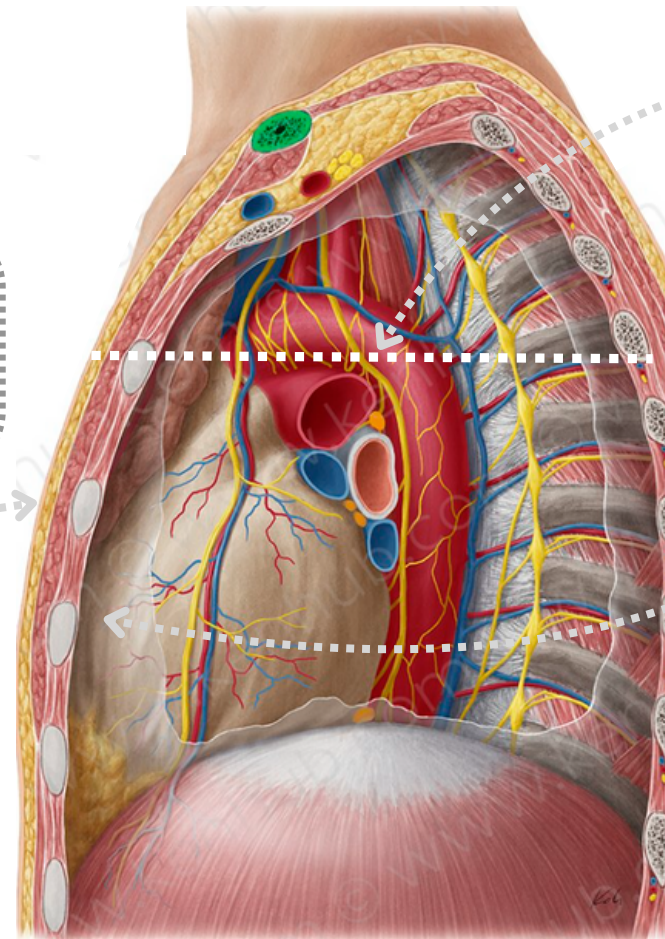
Not very distinguishable in this picture but they're located here

Lateral

Lungs & pleurae

Inferior

Diaphragm



Superior

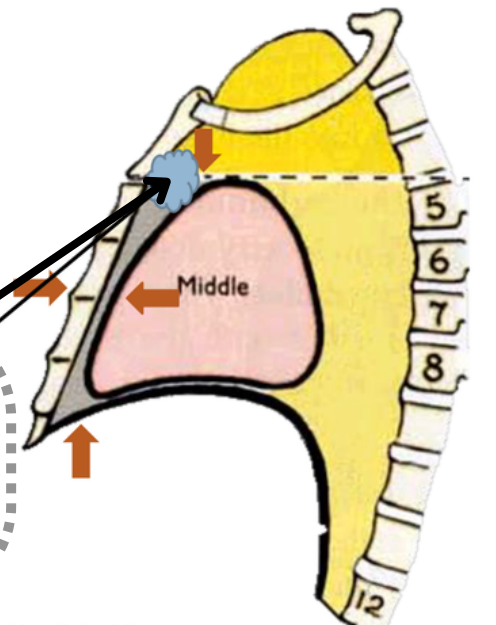
Horizontal plane

Posterior

Heart

Contents

1. Thymus gland
2. Lymph nodes



3 Inferior mediastinum subdivisions

Anterior Mediastinum

Middle Mediastinum

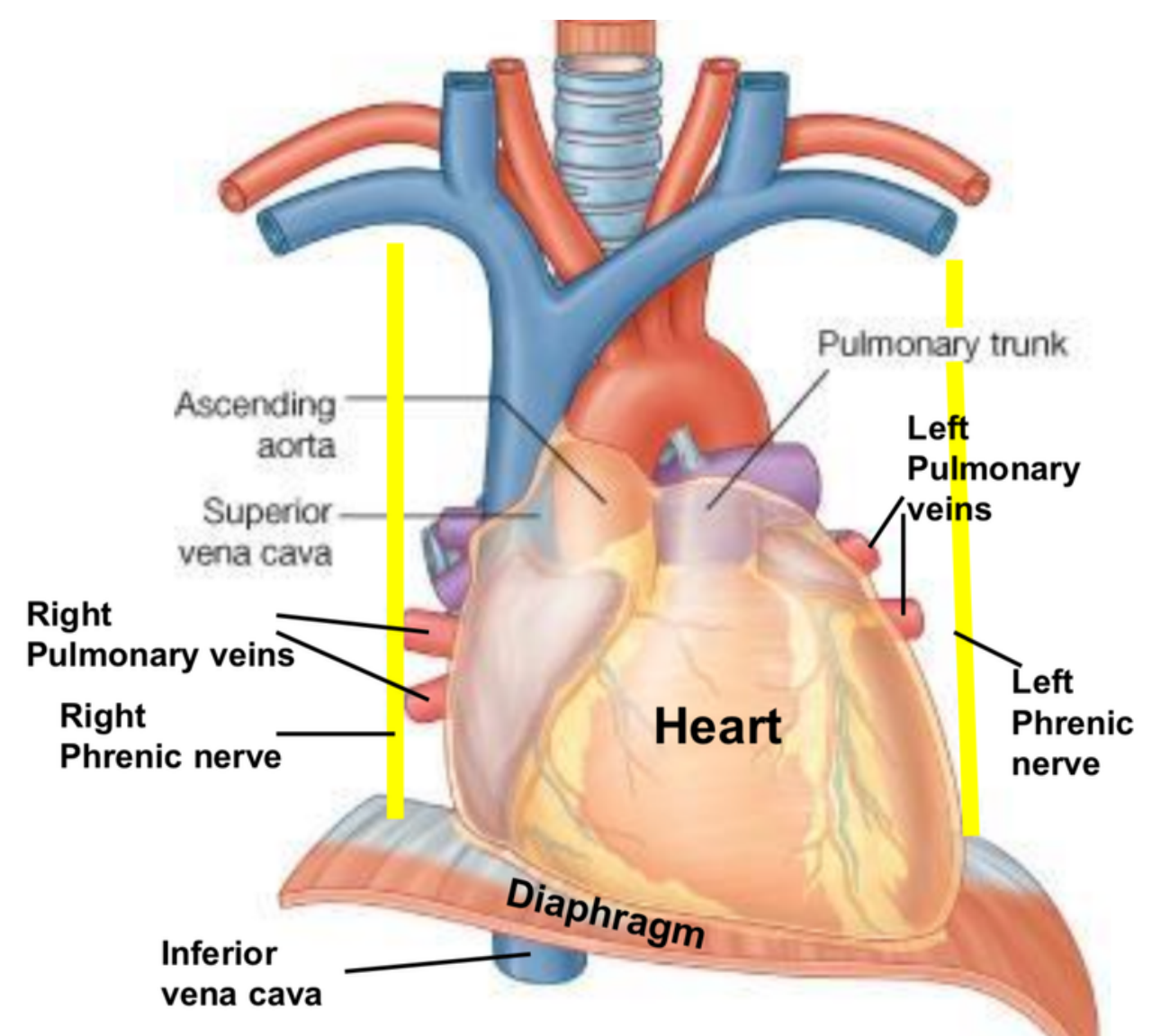
Posterior Mediastinum

Site

Between anterior & posterior mediastina

Contents

1. Heart and pericardium
2. Ascending aorta
3. Pulmonary trunk
4. Superior and inferior vena cava
5. Right and left pulmonary veins
6. Right and left phrenic nerves
7. Lymph nodes



Inferior Mediastinum

3 Inferior mediastinum subdivisions

Anterior Mediastinum

Middle Mediastinum

Posterior Mediastinum

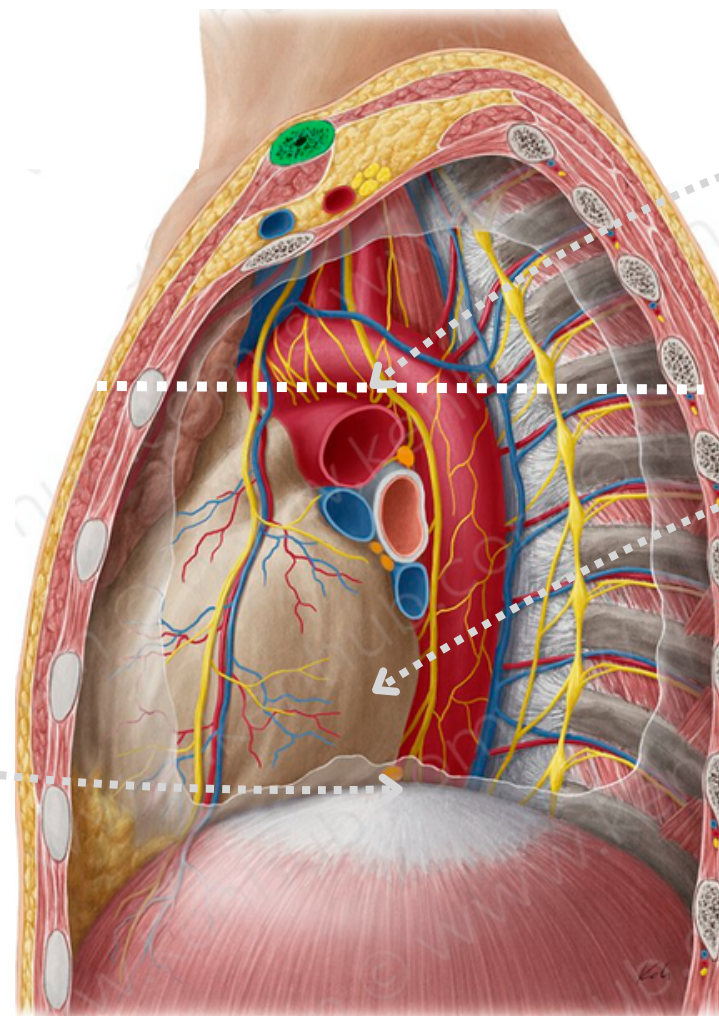
Boundaries

Inferior

Diaphragm

Lateral

Lungs & pleurae



Superior

Horizontal plane

Anterior

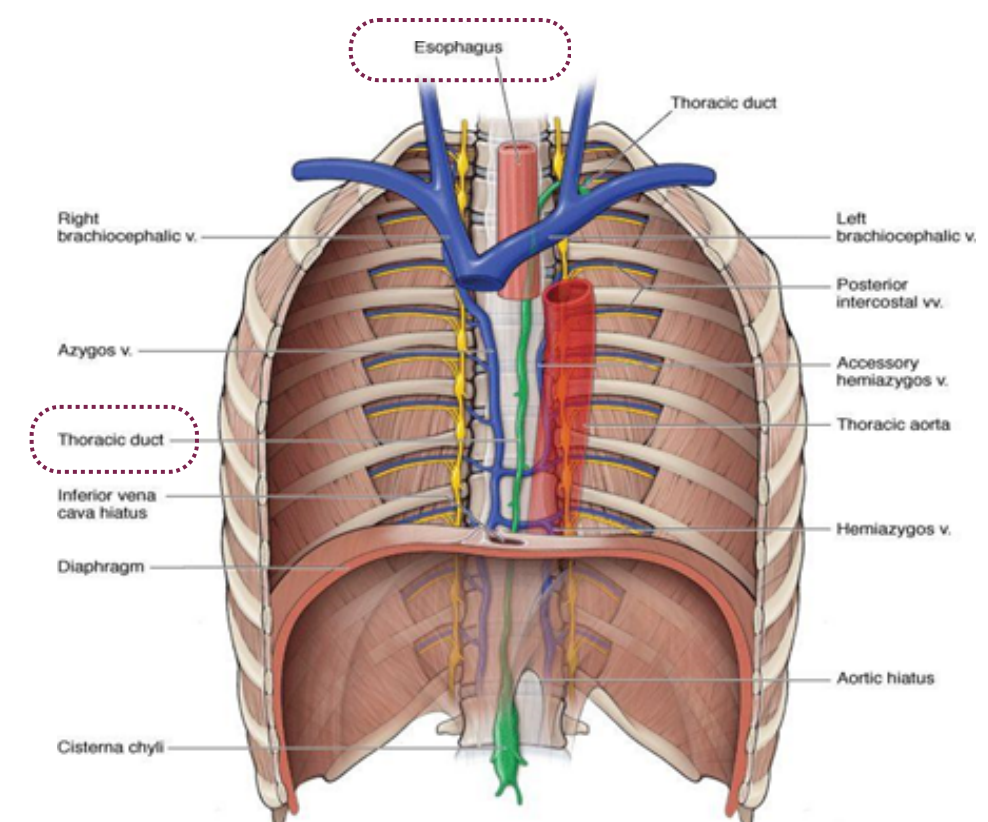
Heart

Posterior

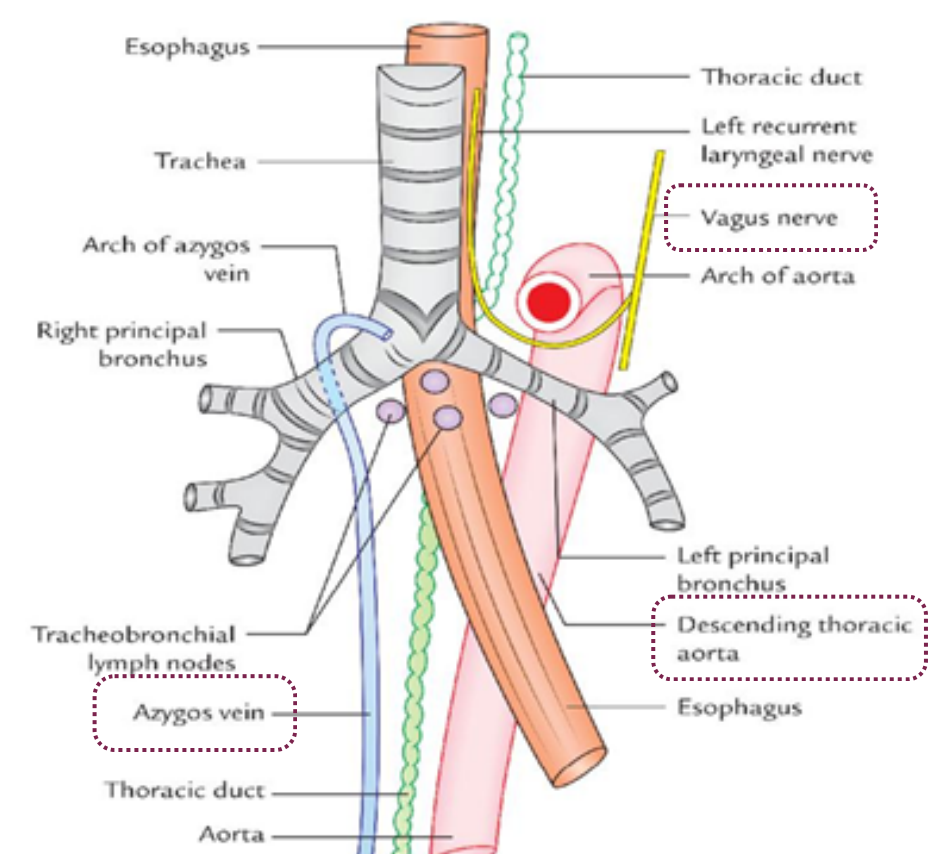
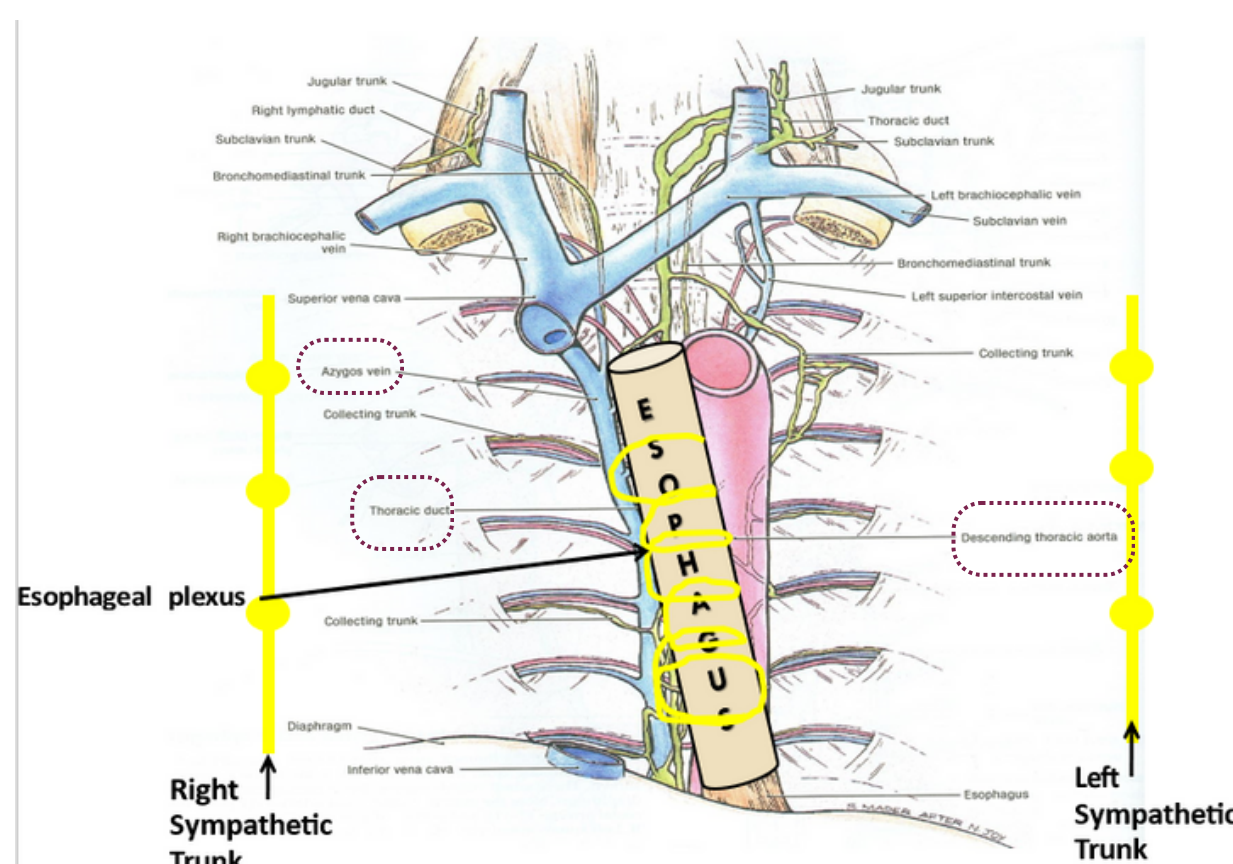
Thoracic vertebrae from T5 to T12

Contents

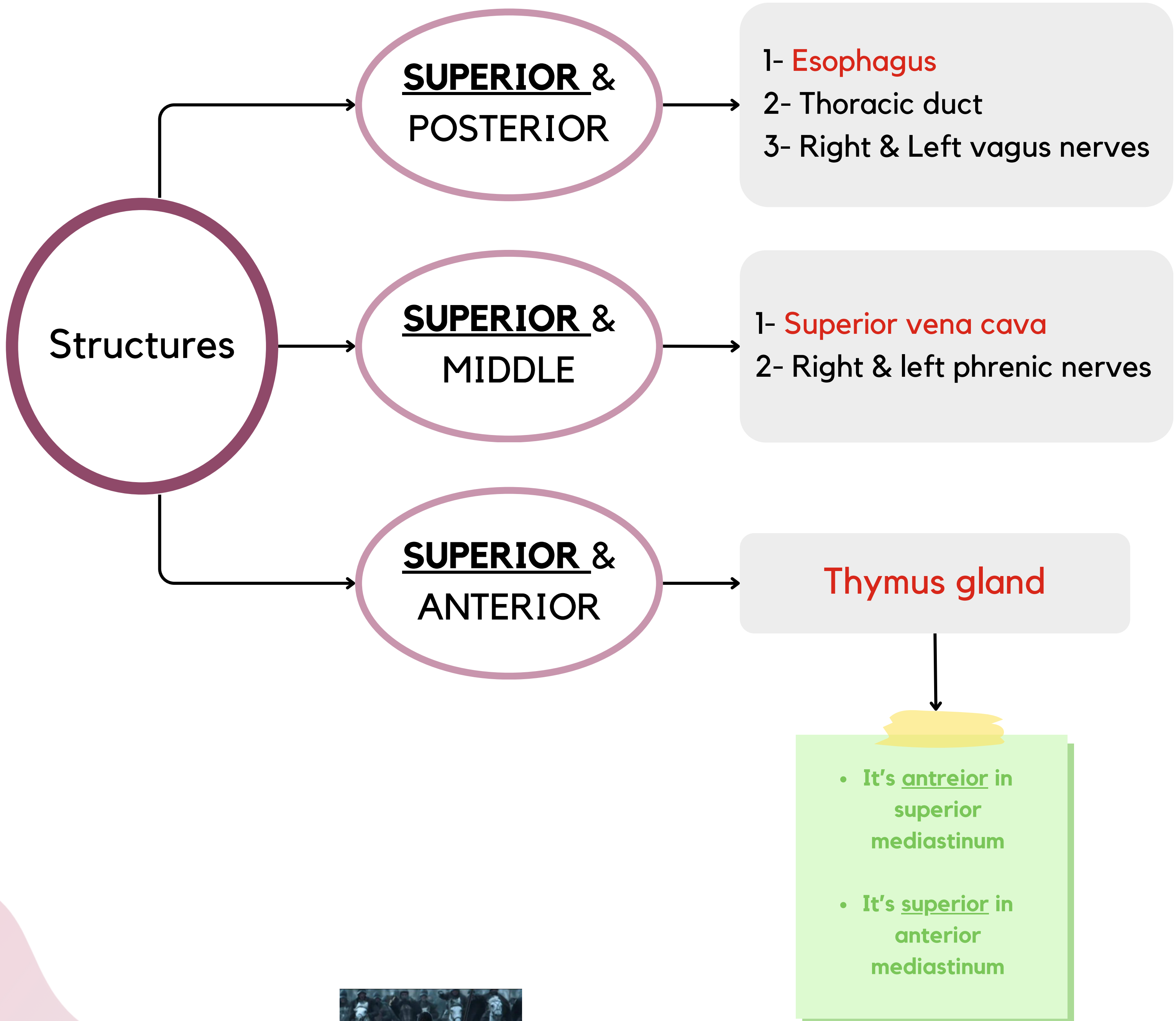
1. **Esophagus**
2. Vagus nerves is: **Around esophagus**
3. **Thoracic duct** is: Posterior to esophagus
4. **Azygos system of veins**: Posterior and to the right of esophagus
5. **Descending aorta**: Posterior and to the left of esophagus
6. Right and left **thoracic sympathetic trunks**
7. **Mediastinal lymph nodes**



Source: Morton DA, Foreman KB, Albertine KH: *The Big Picture: Gross Anatomy*; www.accessmedicine.com
Copyright © The McGraw-Hill Companies, Inc. All rights reserved.



Structures present in more than one mediastinum IMPORTANT!



Important Structures in Mediastinum

In thorax: the right phrenic descends on the right side of SVC & heart then passes through IVC opening.

Phrenic nerve:
Root value is
C3,4,5

They pass through the Superior and Middle mediastina

In thorax: the left phrenic descends on the left side of heart then pierces the left cupola of diaphragm.

2 and 3 are the phrenic nerve course in thorax

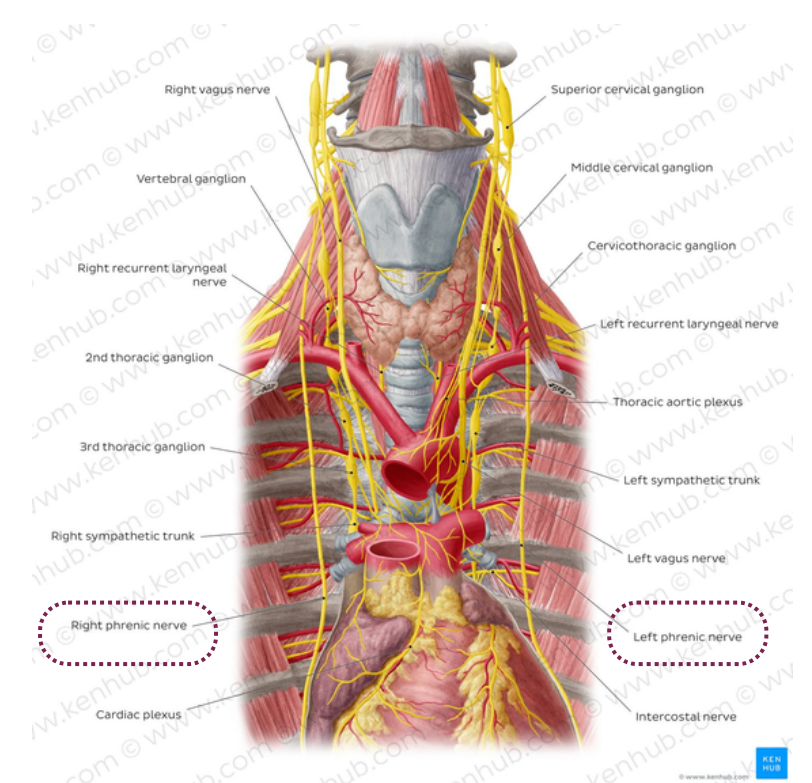
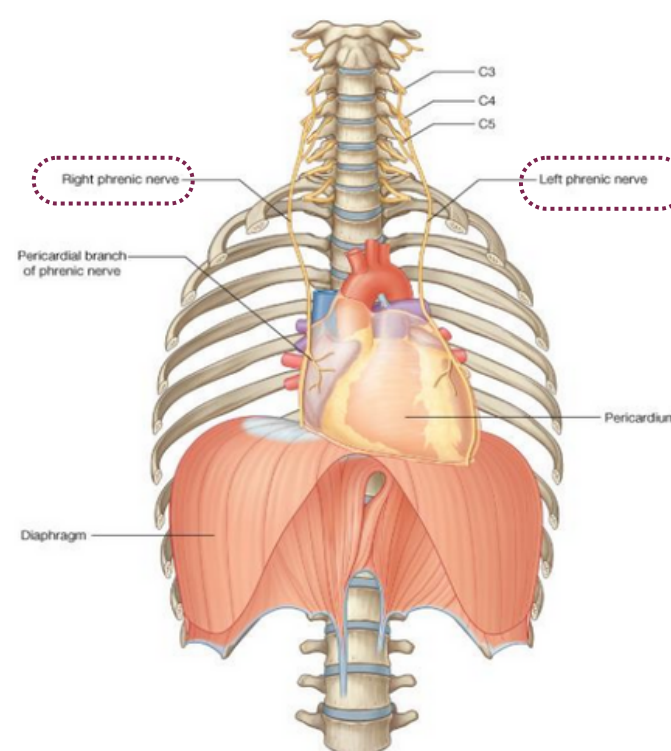
Both nerves terminate in the abdominal surface of diaphragm.

Branches (supply):

- 1- Sensory fibres to pleurae* and pericardium**
- 2- Motor and sensory fibres to diaphragm

*(Mediastinal and central part of diaphragmatic pleura)

** (Fibrous and parietal layer of serous pericardium)

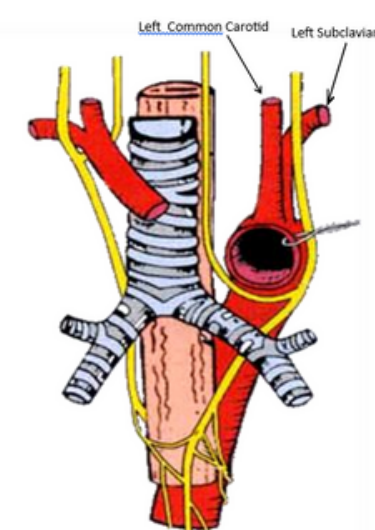


-The **right** vagus descends to the right side of trachea, forms the **posterior esophageal plexus** and continues in abdomen as **posterior gastric nerve**.

Vagus nerve:
It is the 10th cranial nerve.

It descends through the Superior and Posterior mediastinum.

The **left** vagus descends between left common carotid and left subclavian arteries, forms the **anterior esophageal plexus** & continues in abdomen as **anterior gastric nerve**.



Thoracic Duct



Beginning: It is the continuation of **Cisterna Chyli**

Course:

- Passes through the **aortic opening** of the diaphragm.
- Ascends in **posterior** mediastinum (posterior to esophagus)
- Ascends in **superior** mediastinum (to the left of esophagus)

Tributaries: (it receives): Lymphatics from all body.

EXCEPT: 1- Right side of the thorax.

2- Right upper limb.

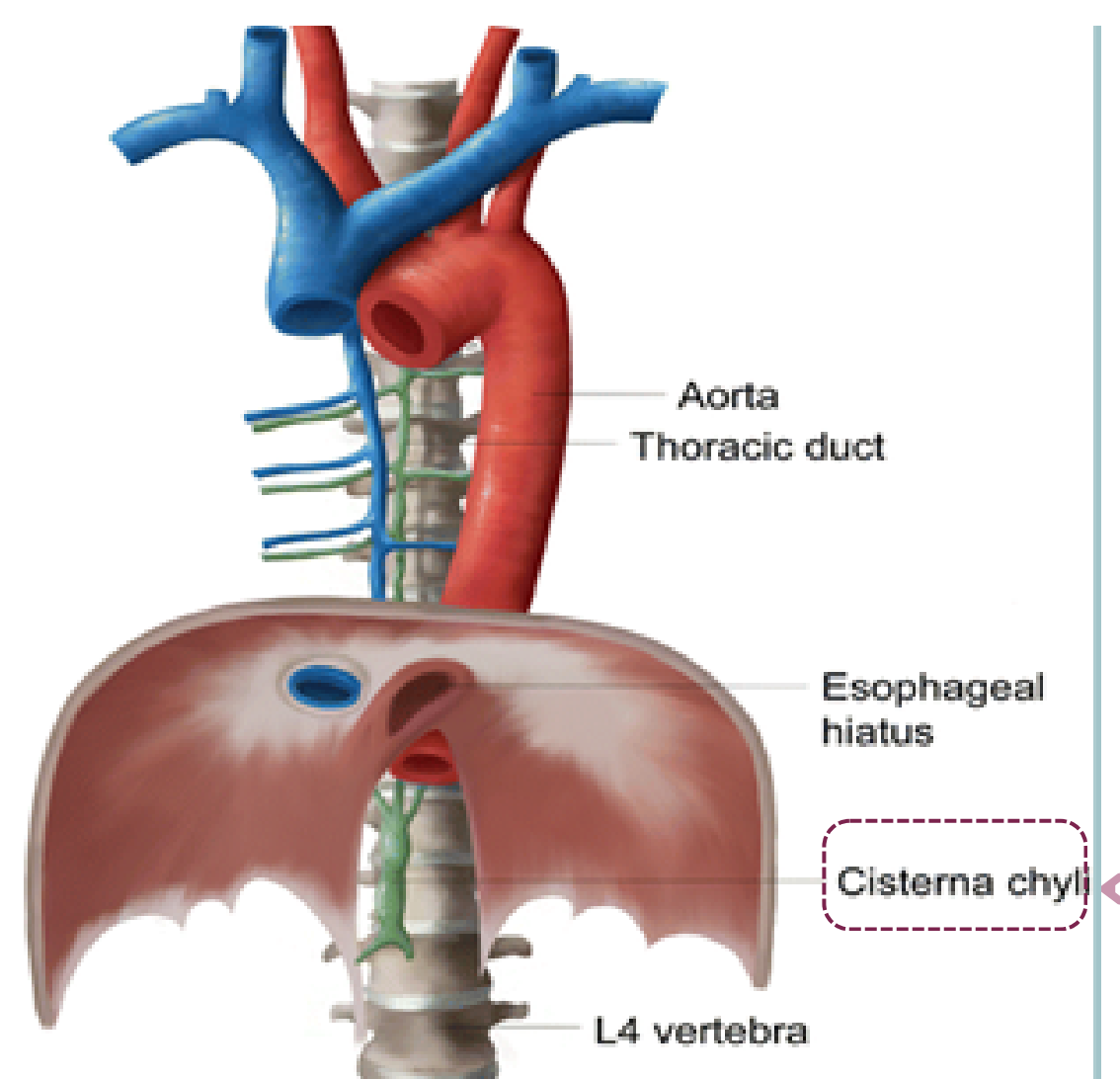
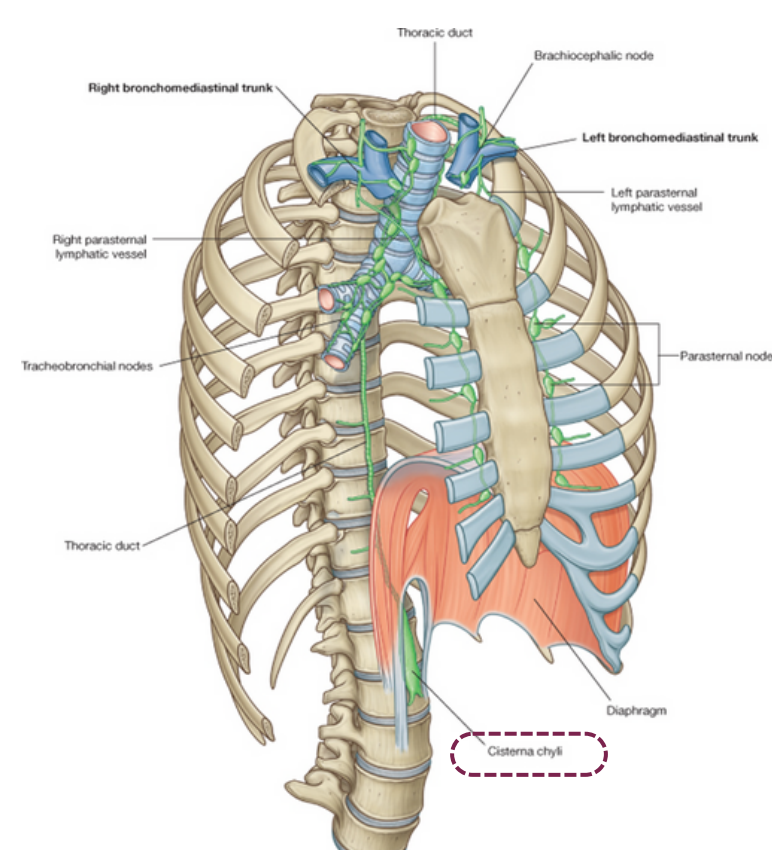
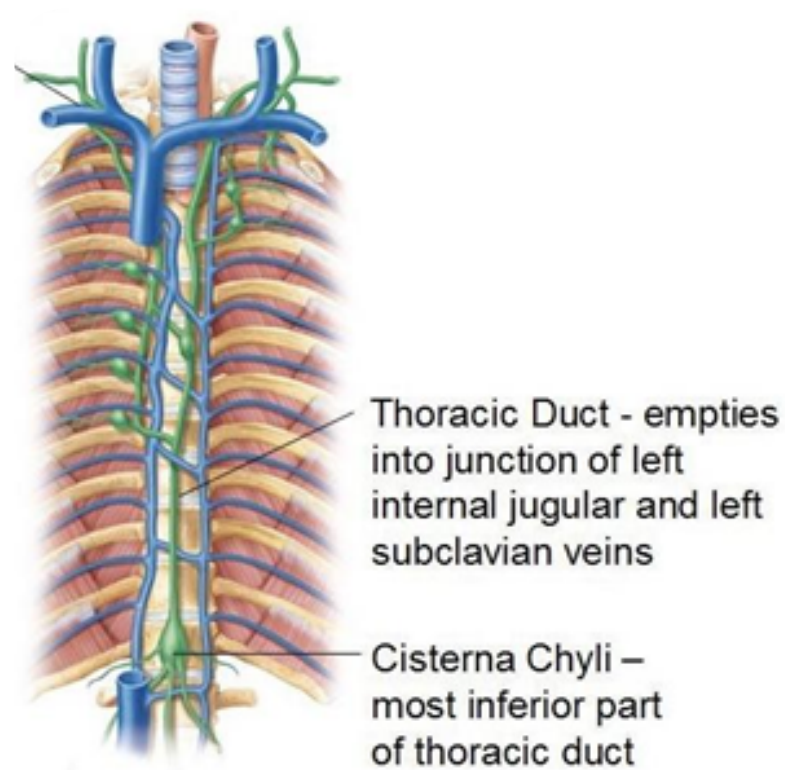
3- Right side of the head and neck.

End :It opens (ends) in the left brachiocephalic vein.

N.B: the right lymphatic duct receives lymphatic from right side of the thorax, right upper limb, and right side of the head and neck. It ends in the right brachiocephalic vein.

Function :

While the arteries are passing between the tissue, they filtrate some fluids, those fluids may accumulate and cause damage to the tissue. So, the thoracic ducts pass between those tissue and remove the excessive fluids.



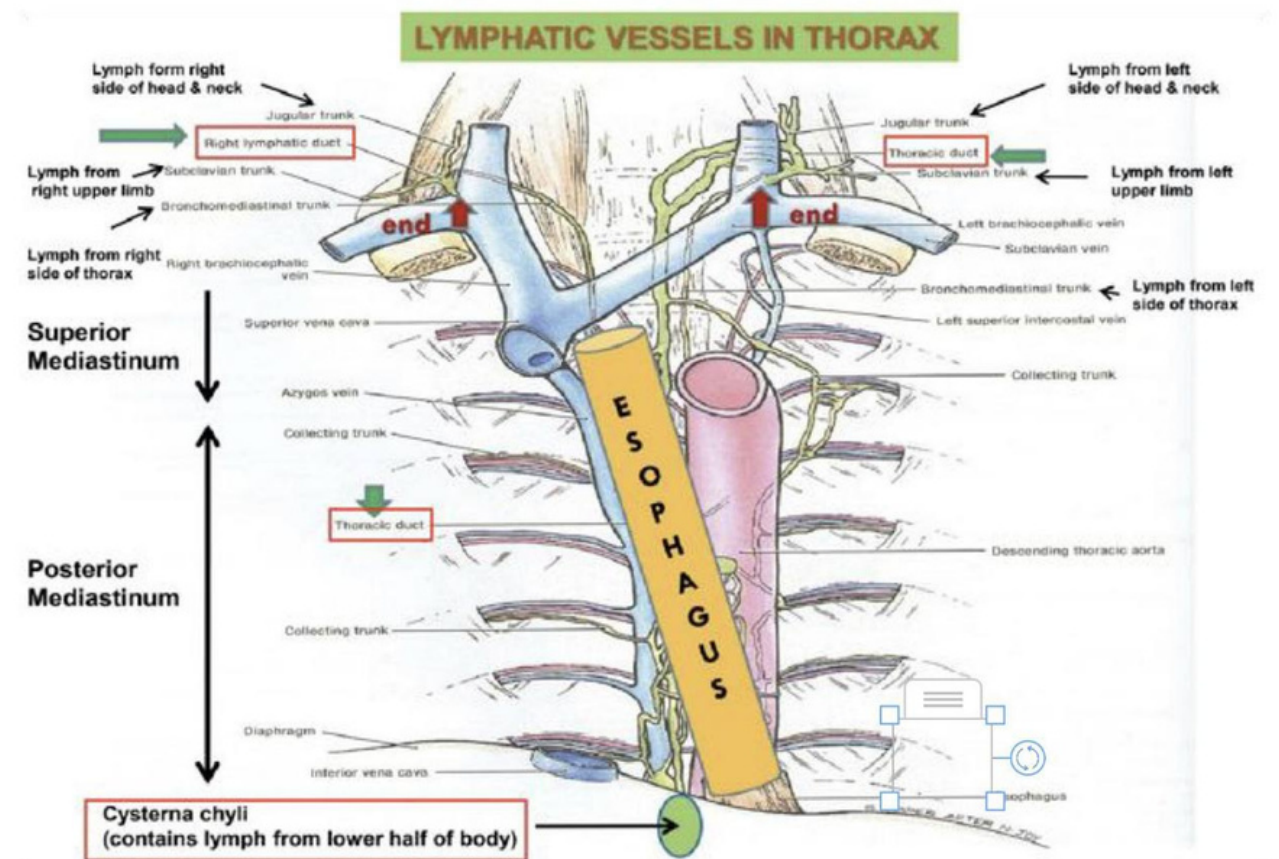
It is the abdominal origin of the thoracic duct

Lymphatic Vessels In Thorax

Lymph from the right side of the head, neck, thorax, & upper limb drains into the **Right lymphatic duct** and ends in the **right brachiocephalic vein**

Lymph from the left side of the head, neck, thorax, & upper limb drains directly into the **Thoracic duct**.

Lymph from the lower half of the body drains into the **Cisterna chyli** then to the **Thoracic duct**.



Aorta

Content

Ascending Aorta:

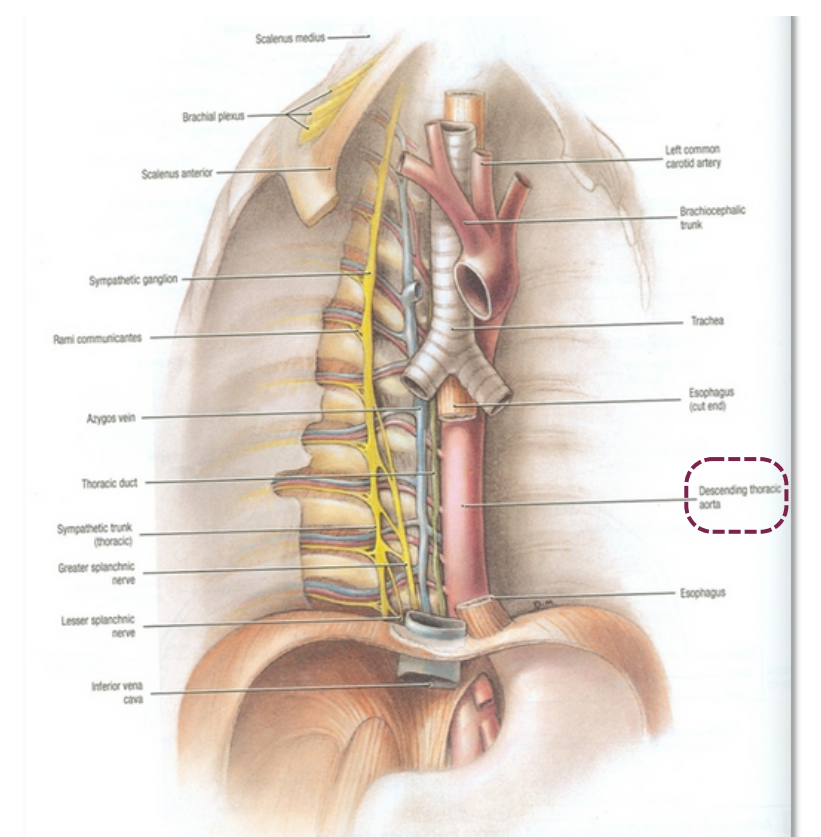
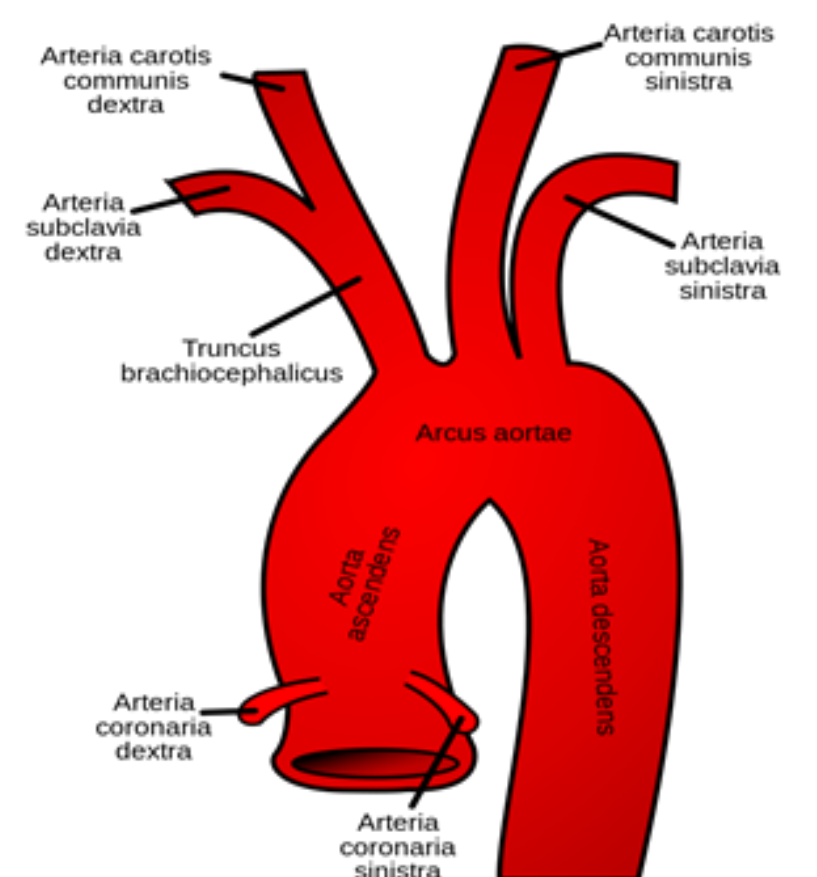
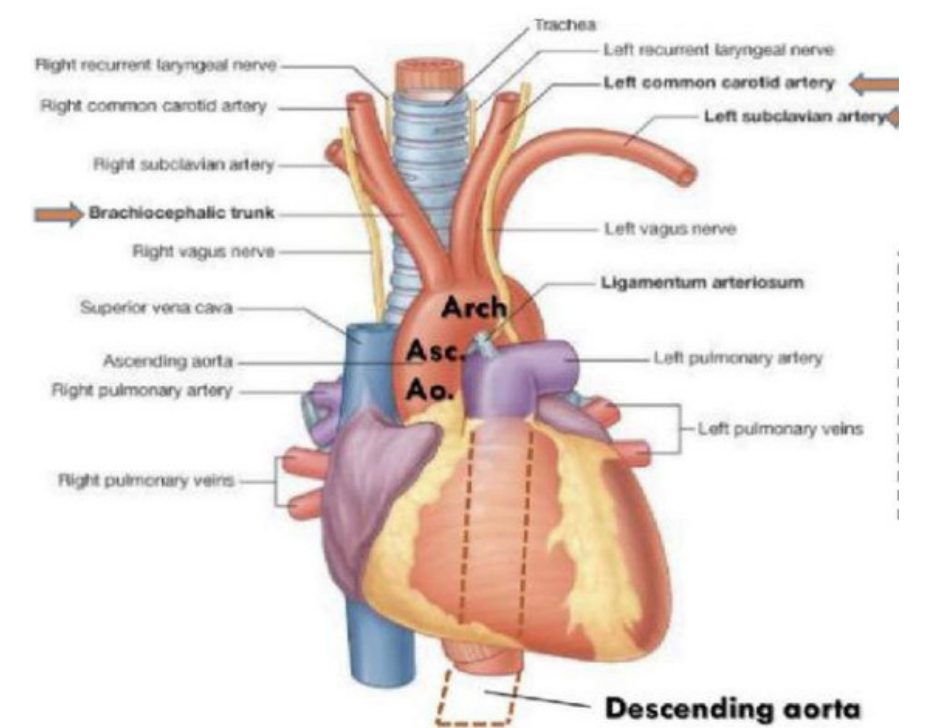
- Beginning: at aortic orifice of left ventricle
- Course: in **middle** mediastinum
- End: continues as **arch of aorta** (at level of T4)

Arch of Aorta:

- Course: in **superior** mediastinum
- End: continues as **descending thoracic aorta** (at level of T4)

Descending Aorta:

- Course: in **posterior** mediastinum
- End: continues as **abdominal aorta** after it passes through diaphragm



Branches of the Aortic arch: **ABC'S**

- Brachiocephalic
- Left Common Carotid
- Left Subclavian

Summary

Posterior Mediastinum

Boundaries

Superiorly	Inferiorly	Anteriorly	Posteriorly	Laterally
Horizontal plane	Diaphragm	Heart	Thoracic vertebra T5-T12	Lungs and pleura

Contents:

- Esophagus
- Descending Aorta
- Azygos system of veins
- Mediastinal lymph nodes
- Right and left Vagus nerve
- Right and left thoracic sympathetic trunks
- Thoracic duct

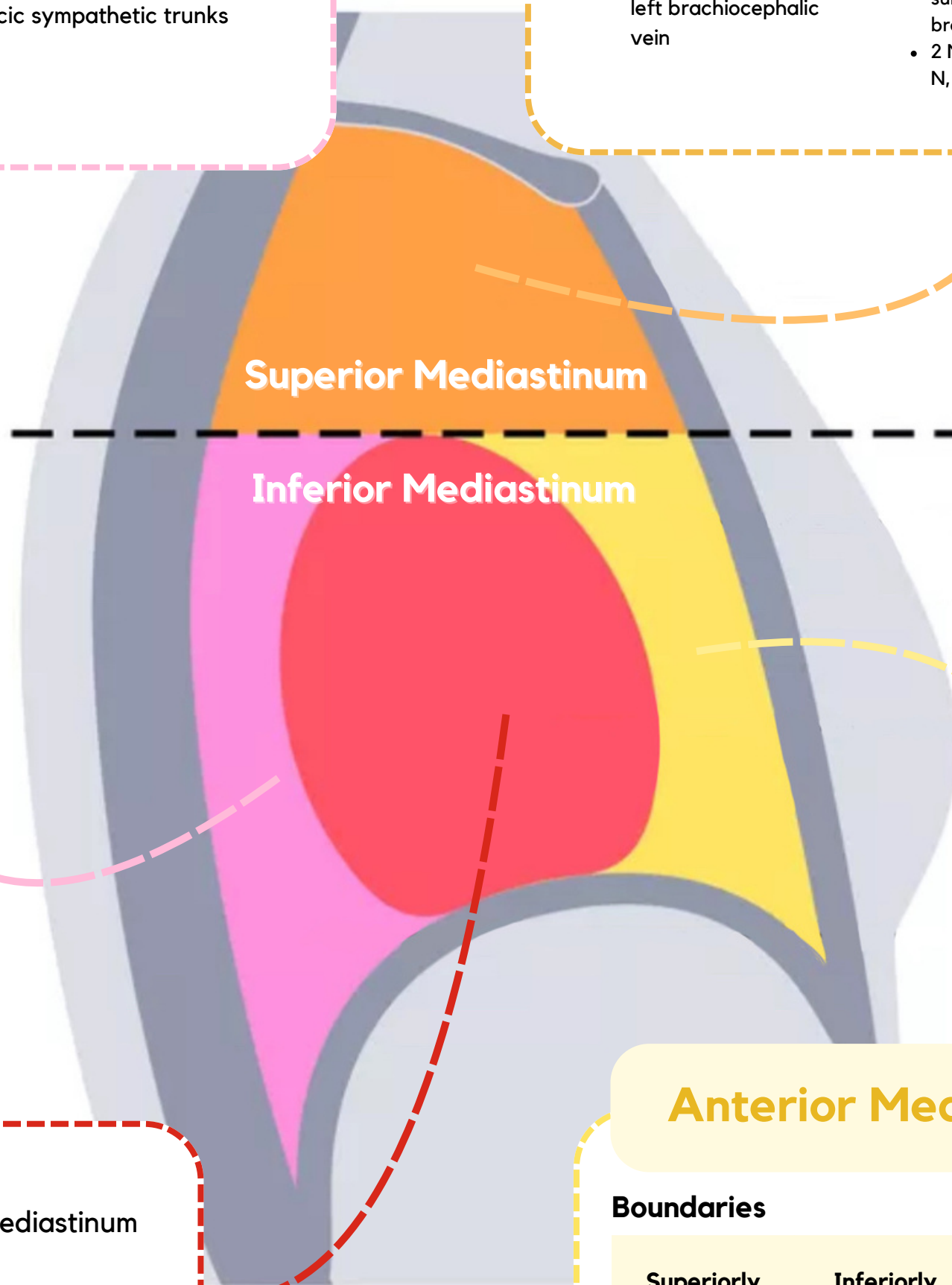
Superior Mediastinum

Boundaries

Superiorly	Inferiorly	Anteriorly	Posteriorly	Laterally
Thoracic outlet	Horizontal plane	Manubrium of sternum	First 4 thoracic vertebra (T1-T4)	Lungs and pleura

Contents

Superficially	Intermediate	Deep
<ul style="list-style-type: none"> • Thymus gland • 3 Veins: SVC, right brachiocephalic vein, left brachiocephalic vein 	<ul style="list-style-type: none"> • 4 Arteries: Arch of aorta, left common carotid A, left subclavian A, brachiocephalic A • 2 Nerves: R&L Vagus N, R&L Phrenic N 	<ul style="list-style-type: none"> • Trachea • Esophagus • Thoracic Ducts



Middle Mediastinum

Boundaries: between anterior and posterior mediastinum

Contents:

- Heart and pericardium
- Ascending aorta
- Pulmonary trunk
- SVC and IVC
- Pulmonary veins
- Right and left Phrenic nerve
- Lymph nodes

Anterior Mediastinum

Boundaries

Superiorly	Inferiorly	Anteriorly	Posteriorly	Laterally
Horizontal plane	Diaphragm	Body and xiphoid process of sternum	Heart	Lungs and pleura

Contents:

- Thymus Gland
- Lymph nodes

Structures present in more than one mediastinum

Superior and posterior	Superior and middle	Superior and anterior
<ul style="list-style-type: none"> • Esophagus. • Thoracic duct. • Right & Left vagus nerves 	<ul style="list-style-type: none"> • Superior vena cava • Right & left phrenic nerves 	<ul style="list-style-type: none"> • Thymus gland

MCQs

1

Which one of the following structures is present in both superior & posterior mediastinum?

A) Superior vena cava	B) Pulmonary trunk	C) Trachea	D) Esophagus
-----------------------	--------------------	------------	--------------

2

Thoracic duct ends in?

A) Right brachiocephalic vein	B) Cysterna chyli	C) Superior and anterior mediastinum	D) Left brachiocephalic vein
-------------------------------	-------------------	--------------------------------------	------------------------------

3

The phrenic nerve gives motor innervation to?

A) External intercostal muscles	B) Central part of diaphragmatic pleura	C) Diaphragm	D) Internal oblique muscle
---------------------------------	---	--------------	----------------------------

4

Which one of the following structures is not present in the superior mediastinum?

A) Arch of aorta	B) Thoracic duct	C) Vagus nerve	D) Pulmonary vein
------------------	------------------	----------------	-------------------

5

Which one of the following is a superficial component of the superior mediastinum?

A) Left brachiocephalic vein	B) Inferior vena cava	C) Left subclavian artery	D) Trachea
------------------------------	-----------------------	---------------------------	------------



1)D 2)D 3)C 4)D 5)A

SAQs

Enumerate Two structures present in both Superior and Middle mediastinum?

1

- 1. Superior vena cava.
- 2. Right & left phrenic nerves

Fill the information about ascending aorta:

2

- Beginning: at aortic orifice of left ventricle
- Course: in middle mediastinum
- End: continues as arch of aorta (at level of T4)

What happens at the level of T4?

3


- 1. Bifurcation of trachea
- 2. Bifurcation of pulmonary trunk
- 3. Beginning & termination of arch of aorta
- 4. Termination of arch of azygos vein into Superior vena cava.

Enumerate 3 contents of the Middle Mediastinum?

4

- 1. Heart and pericardium
- 2. Ascending aorta
- 3. Pulmonary trunk

More questions? [Click here!](#)



TEAM LEADERS

Nisreen Alotaibi

Ziyad Alenazi

TEAM MEMBERS

- **Aleen Almutairi**
- **Shaden Alotaibi**
- **Lama Alrasheed**
- **Layal Alkhalifah**
- **Jenan Alsayari**
- **Nouf Alotaibi**
- **Aljory Alqahtani**
- **Lubna Alamri**
- **Ward Alanazi**
- **Elaf Alshamlan**

- **Omar Albaqami**
- **Fawaz Almadi**
- **Faris Alturaiki**
- **Nasser Alabdulsalam**
- **Abdullah Alzoom**
- **Waleed Alanazi**
- **Sulaiman Abdulkarim**
- **Odai AlJarawneh**
- **Rakan Alarifi**
- **Ali Al-Abdulazem**
- **Omar Alattas**