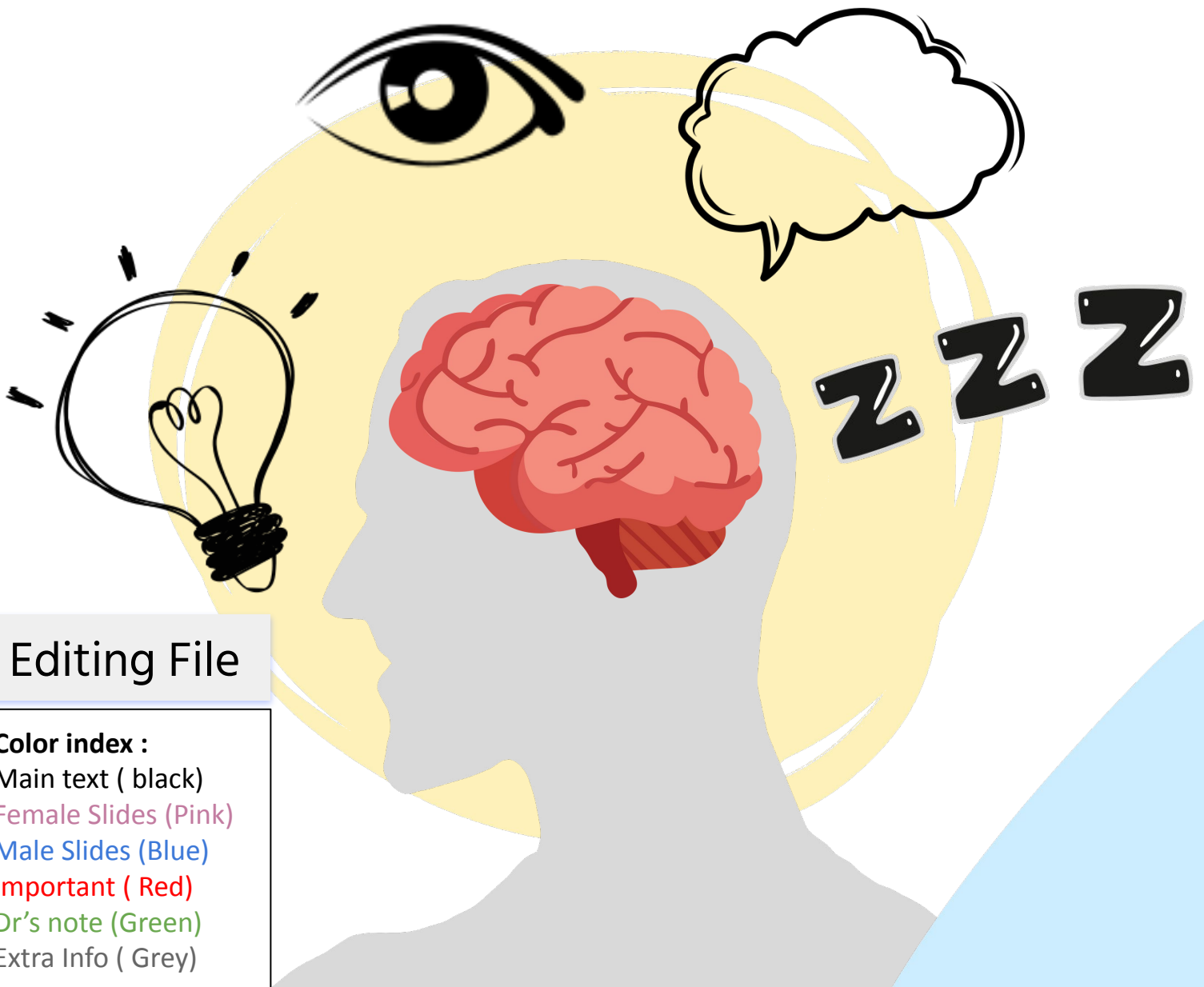




Pathology and pathogenesis of multiple sclerosis



Editing File

Color index :

Main text (black)

Female Slides (Pink)

Male Slides (Blue)

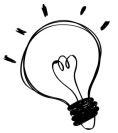Important (Red)

Dr's note (Green)

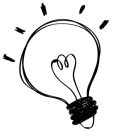Extra Info (Grey)



Objectives



Appreciate the critical role of myelin in maintaining the integrity of the CNS system .



Understand the pathogenesis and the clinic-pathological features of multiple sclerosis as the classical and the commonest example of CNS demyelinating diseases .

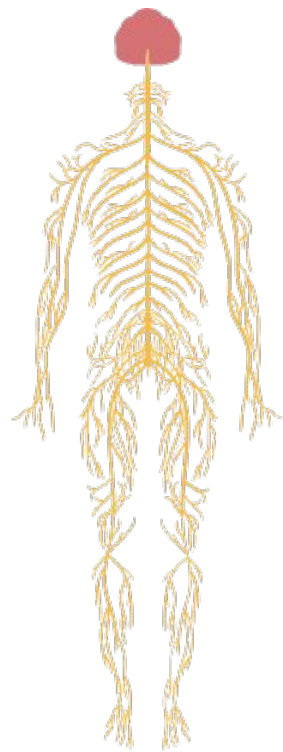


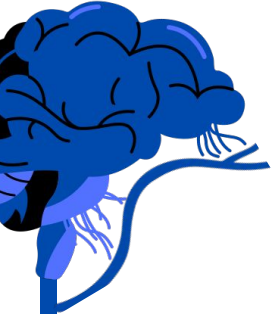Key principles :

- Myelin function
- The differences between CNS and PNS Myelin .
- Primary Demyelinating disease classification Multiple sclerosis: definition, epidemiology, pathogenesis and clinicopathological features; with special emphasis on CSF analysis findings, morphology and distribution of MS plaques .



If you want to read the lecture from Robbins [click here](#)





Introduction



[helpful video](#)

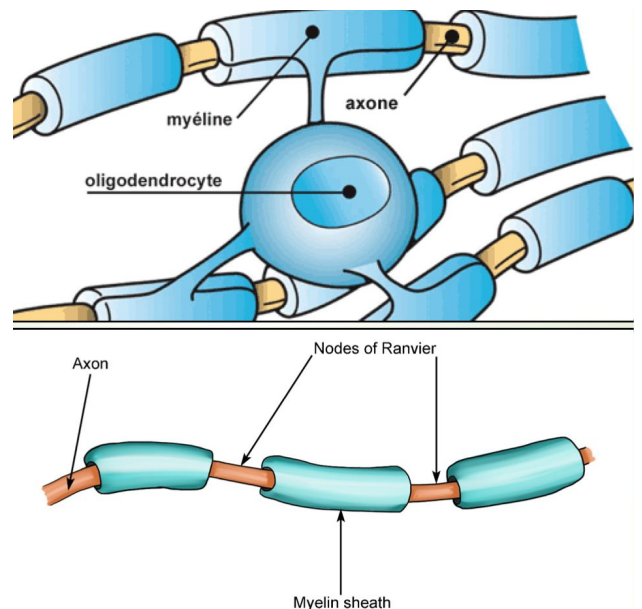
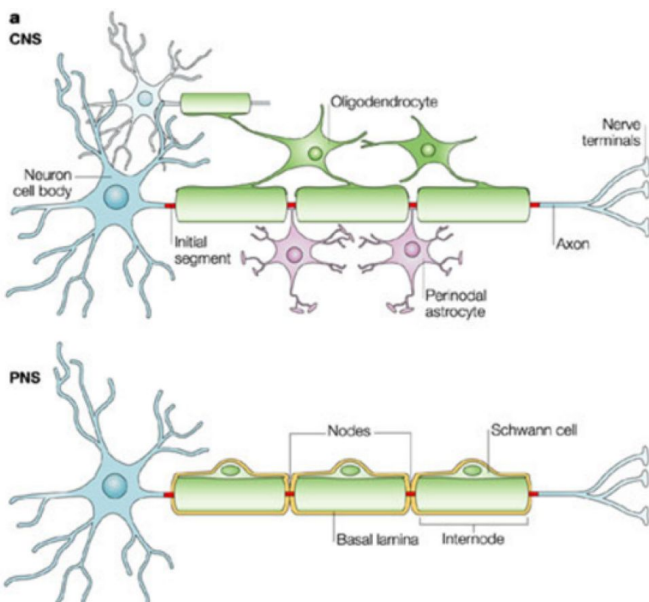
What is the function of myelin ?

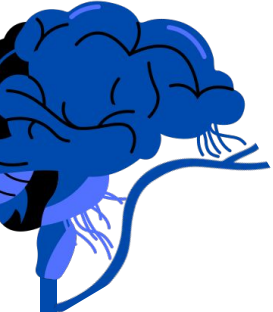- Myelin consists of multiple layers of highly specialized, closely apposed plasma membranes of that are assembled by oligodendrocytes (in the CNS), with most of the cytoplasm excluded .
- Myelin is an electrical insulator that allows rapid propagation of neural impulses .
- Although myelinated axons are present in all areas of the brain, they are the dominant component in the white matter; therefore, most diseases of myelin are primarily white matter disorders .

Thats why its the most common area to get MS

What Produce Myelin ?

- An oligodendrocyte extends its processes toward many different axons and wraps a segment of roughly a few hundred microns of an axon .
- Each of these segments is called an internode, and the gaps between internodes are known as nodes of Ranvier .





Introduction



[helpful video](#)

The differences between CNS and PNS

- The myelin in peripheral nerves is similar to the myelin in the CNS but:
 1. peripheral myelin is made by Schwann cells, not oligodendrocytes.
 2. Each cell in the peripheral nerve contributes to only one internode, while in the CNS, many internodes comes from a single oligodendrocyte.
 3. The specialized proteins and lipids are also different
- Most diseases of CNS myelin do not significantly involve the peripheral nerves, and vice versa .

What is "natural history of a disease"?

- The natural history of demyelinating diseases is determined, in part, by the limited capacity of the CNS to regenerate normal myelin and by the degree of secondary damage to axons that occurs as the disease runs its course .



Clinical Note

Patients with MS mostly present with :

- Blurred vision/loss of colour vision due to optic nerve demyelination.
- Vertigo and incoordination due to cerebellar demyelination.
- Eye movement disorders due to brainstem demyelination.
- Patchy numbness and tingling in a limb with progression to paraplegia, incontinence, and sexual dysfunction due to spinal cord demyelination.
- **Prognosis Of MS :** Most patients suffer progressive disease and complications related to disability (pneumonia, urinary tract infections, pressure sores, etc.).



Demyelinating diseases

Classification

Demyelinating diseases of CNS

They are **acquired** conditions characterized by a preferential damage to previously normal myelin.

They commonly result from:

- An **immune-mediated injury**(MS)
- Viral infections to oligodendrocytes (as in progressive multifocal leukoencephalopathy)
- Drugs and other toxic agents.

Dysmyelinating diseases of CNS (leukodystrophies)

Myelin is not formed properly or has abnormal turnover kinetics.

They are associated with:

- Mutations affecting the proteins required for the formation of normal myelin.
- Mutations that affect the synthesis or degradation of myelin lipids.
- **the other general term for these diseases is leukodystrophy.**

Deep Focus Question



Which statement is TRUE regarding the localization of multiple sclerosis?

- It typically affects only one peripheral nerve.
- It may affect multiple locations in the CNS.
- It usually manifests solely in the spinal cord.
- It may affect multiple peripheral nerves.

Answer: B

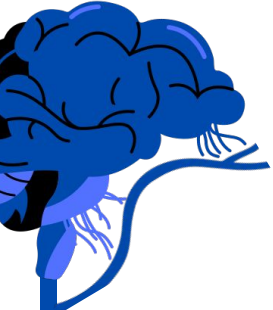Deep Focus Question



How can an evoked potential test help make a diagnosis of multiple sclerosis (MS)?

- It can help rule out antibodies associated with another disease.
- It will reveal biomarkers specific to the disease.
- It measures the speed of a nerve impulse in response to stimuli.
- It highlights lesions that can indicate a disease in an active state.

Answer: C



Multiple sclerosis

an Autoimmune demyelinating disorder



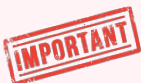Characteristics

- MS is an autoimmune demyelinating disorder characterized by distinct episodes of neurologic deficits & disease activity
- Episodes are separated in time, that produce (attributable to) white matter lesions that are separated in space.

Epidemiology

- Age: **Any age** (although onset in childhood or age of 50 is rare)
- Gender: **Women** (Twice as often as Men)
- Prevalence: It is the most common demyelinating disorder, having a prevalence of approximately 1 per 1000 individuals in the United States and Europe, and its incidence appears to be increasing.

Markers



- In most individuals with MS the illness shows a **relapsing and remitting** episodes of neurologic deficits. The frequency of relapses tends to decrease during the course of the illness, but there is a steady neurologic deterioration in a subset of patients.
- The incidence of MS is 15-fold higher when the disease is present in a first-degree relative and **roughly 150-fold higher with an affected monozygotic twin.**
- The **concordance rate for monozygotic twins** is approximately 25%, with a much lower rate for dizygotic twins

MALES SLIDES

Experimental Autoimmune Encephalomyelitis

- Is an **animal model of MS** in which demyelination and inflammation occur after immunization of animals with myelin protein, (mice are injected with myelin).
- In this model, the lesions are caused by a **T cell-mediated delayed type hypersensitivity (type 4)** reaction to myelin proteins, and the same immune mechanism is thought to be central to the pathogenesis of MS.

Multiple sclerosis

Pathogenesis

- The lesions of MS are caused by an autoimmune response directed against components of the myelin sheath.
- As in other autoimmune diseases, the development of MS is related to genetic susceptibility and largely undefined environmental triggers. (combination of environmental and genetic factors that result in a loss of tolerance to self proteins)

*
FEMALES
SLIDES

01

IMPORTANT

02

03

HLA-DRB1*1501

There is a strong effect of the major histocompatibility complex; **HLA-DR 2 variants**, each copy of the **HLA-DRB1*1501** allele an individual inherits brings with it a roughly 3-fold increase in the risk for MS.

TH1 & TH17 Role

The available evidence indicates that the disease is initiated by **TH1** and **TH17** T cells that react against myelin antigens and secrete cytokines.

IFN- γ Role

TH1 cells secrete IFN- γ , which activates macrophages, and TH17 cells promote the recruitment of leukocytes. The demyelination is caused by activated leukocytes and their injurious products

- While MS is characterized by the presence of demyelination out of proportion to axonal loss, some injury to axons does occur.
- Toxic effects of lymphocytes, macrophages, and their secreted molecules have been implicated in initiating the process of axonal injury, sometimes even leading to neuronal death.



Embryology Note

- Monozygotic twins are formed by one sperm and one egg. Dizygotic twins are formed by two different sperm and two different eggs.



Multiple sclerosis

Morphology

01

MS is primarily a multifocal white matter disease.

02

Grossly, the characteristic lesions, termed plaques, are well-circumscribed discrete, slightly depressed, glassy appearing, and gray-tan in Color & irregularly shaped

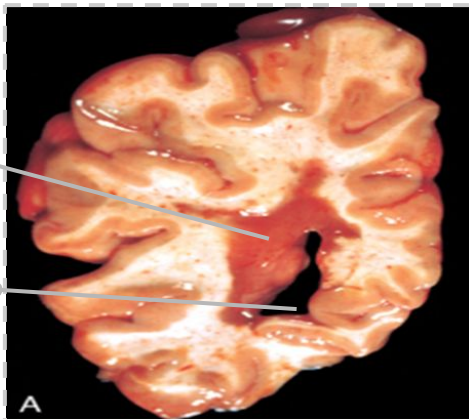
03

The lesions have sharply defined borders at the microscopic level.

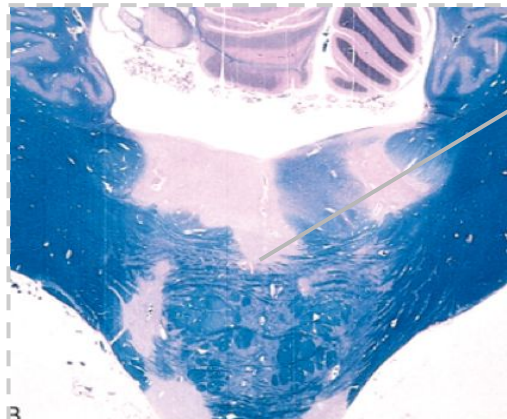
Plaques are common near the ventricles and also frequently occur in the optic nerves and chiasm, brain stem, ascending and descending fiber tracts, cerebellum, and spinal cord.

Plaques

4th ventricle



Section of fresh brain showing a plaque around occipital horn of the lateral ventricle.



Loss of stain = loss of myelin

Unstained regions of demyelination (MS plaques) around the fourth ventricle. Luxol fast blue-periodic acid-Schiff stain for myelin.



Multiple sclerosis

Morphology

At the microscopic level :

Types of plaques

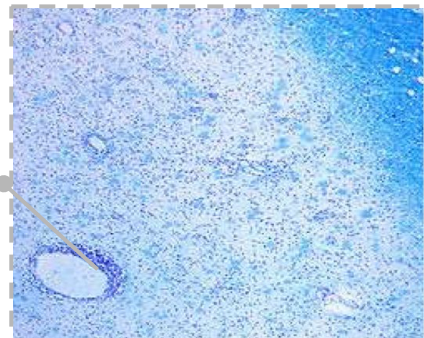
ACTIVE PLAQUE

- contain abundant macrophages stuffed with myelin debris, evidence of ongoing myelin breakdown.
- Lymphocytes also are present, mostly as perivascular cuffs.
- Small active lesions often are centered on small veins.
- Axons are relatively preserved but may be reduced in number.

INACTIVE PLAQUE

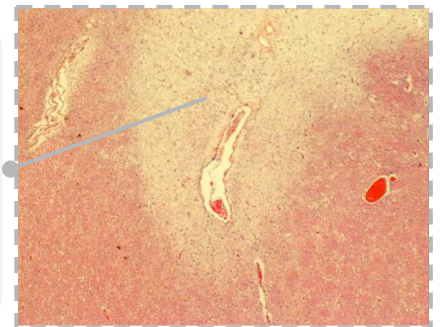
- When plaques become quiescent (inactive plaques), the inflammation mostly disappears, leaving behind little to no myelin, **astrocytic proliferation, and gliosis.**
- Loss of myelin can be seen even without special stains (it is lighter pink than the normal white matter around it).

Vein surrounded by inflammatory cells



-This is a myelin stain (luxol fast blue/PAS) of an early lesion.
-The lesion is centered around a small vein which is surrounded by inflammatory cells.

Loss of myelin



-H&E stained section from a patient with a long-standing MS.
-An old (inactive) lesion is centered around a vein with very little inflammation.
-Loss of myelin can be seen even without special stains (it is lighter pink than the normal white matter around it).



Multiple sclerosis

Clinical Features of MS

01 The course of MS is variable MS lesions can occur anywhere in the CNS > may induce a wide range of clinical manifestations, but commonly there are multiple episodes of new symptoms (relapses) followed by episodes of recovery (remission); typically, recovery during remissions is not complete.

02 Over time there is usually a gradual, often stepwise, accumulation of neurologic deficits.

The consequence of this pattern of relapsing remitting disease is the gradual, often stepwise,

accumulation of increasing neurologic deficits

03 Changes in cognitive function can be present, but are often much milder than the other deficits.

04 Imaging studies have demonstrated that there are often more lesions in the brains of patients with MS than might be expected from the clinical examination, and that lesions can come and go much more often than was previously suspected.

05 In any individual patient, it is difficult to predict when the next relapse will occur; most current treatments, which are intended to control the immune response, aim at decreasing the rate and severity of relapses rather than recovering lost function.

06 Certain patterns of neurologic symptoms and signs are commonly observed:

Unilateral visual impairment occurring over the course of a few days is a frequent initial manifestation of MS (due to involvement of the **optic nerve** "optic neuritis").
->When this occurs as the first event, only a minority (10% to 50%) go on to develop full-blown MS

Involvement of the brain stem produces cranial nerve signs and ataxia, and can disrupt conjugate eye movements.

Spinal cord lesions give rise to motor and sensory impairment of trunk and limbs, spasticity, and difficulties with the voluntary control of the bladder function.

Multiple sclerosis

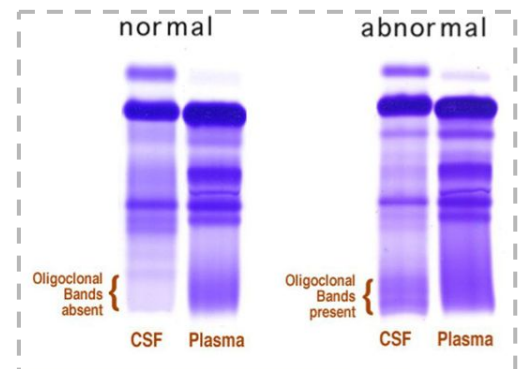
Laboratory Findings

The CSF shows mildly **elevated** protein levels with an **increased proportion of γ -globulin** (IgG) on electrophoresis.

In one-third of cases there is moderate pleocytosis(**abnormal increase in the amount of lymphocytes in the CSF**).

When the immunoglobulin is examined further, **most MS patients show oligoclonal bands**, representing antibodies directed against a variety of antigenic targets.

These antibodies constitute a marker for disease activity.



Summary

FEMALES SLIDES

Because of the critical role of myelin in nerve conduction, diseases of myelin can lead to widespread and severe neurologic deficits.

Multiple sclerosis, an autoimmune demyelinating disease, is the most common disorder of myelin, affecting young adults.

It often pursues a relapsing-remitting course, with eventual progressive accumulation of neurologic deficits.

Other, less common forms of immune-mediated demyelination often follow infections and are more acute illnesses.

Leukodystrophies are genetic disorders in which myelin production or turnover is abnormal.

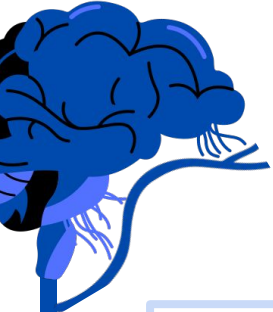Keywords

Multiple Sclerosis

- Plaques
- Active plaque : Abundant macrophages containing myelin debris & perivascular inflammatory cuffs -> seen by luxol fast blue/PAS myelin stain
- Inactive: no inflammation, gliosis -> seen by H&E stain
- Visual impairment: optic nerve involvement
- Elevated γ -globulin
- Oligoclonal bands
- Attacks followed by remission
- T cell mediated autoimmune disorder
- Lesion of Periventricular cerebral white matter



Need a SUMMARY ? [Click here](#)



MCQ

a 27 male diagnosed with Multiple sclerosis the CSF shows a high oligoclonal band. What does that finding indicate ?

A- Active multiple sclerosis

B- Latent multiple sclerosis

C- Astrocytes

D- Medulloblastoma

What gene attributes to the genetic risk of Multiple sclerosis?

A- EGFR

B- HLA DR7

C- HLA-DR2

D- p53

Which of the following form Myelin in CNS?

A- schwann cells

B- Renshaw cells

C- Oligodendrocytes

D- NONE

Which one of the following is characteristic of Multiple sclerosis?

A- Does Not progress

B- Decline and eventual recovery

C- Gradual increase in symptoms without remission

D- Attacks followed by remission



1- A \ 2- C \ 3- C \ 4- D



MCQ

Which one of the following immune cell has principal role in pathogenesis of Multiple sclerosis?

A- Th1 & Th17

B- B. Cells

C- Regulatory cells

D- Macrophages

A patient with Multiple Sclerosis had a visual impairment. What is the most common site that would be affected in this condition?

A- Retina

B- Thalamus

C- Cerebral cortex

D- Optic nerve

A 32 years old woman diagnosed with Multiple sclerosis, which of the following is the common site for demyelinating plaques?

A- Gray matter

B- White matter

C- Cerebellum

D- Basal nuclei

Which of the following is true regarding Multiple sclerosis?


A- No oligoclonal band

B- Reduced protein levels

C- In an active plaque, astrocytic proliferation and gliosis are prominent

D- Elevated γ -globulin (IgG)

1- A \ 2- D \ 3- B \ 4- D



Cases

1-A 35-year-old woman complains of urinary incontinence and blurred vision for 2 months. A fundoscopic examination shows no abnormalities. Two months later, the patient develops double vision and numbness in the fingers of her left hand. MRI shows scattered plaques in the patient's brain and spinal cord. Over the next several months, some of these plaques diminish in size, while others appear in new locations. These plaques would most likely show selective loss of which of the following proteins?

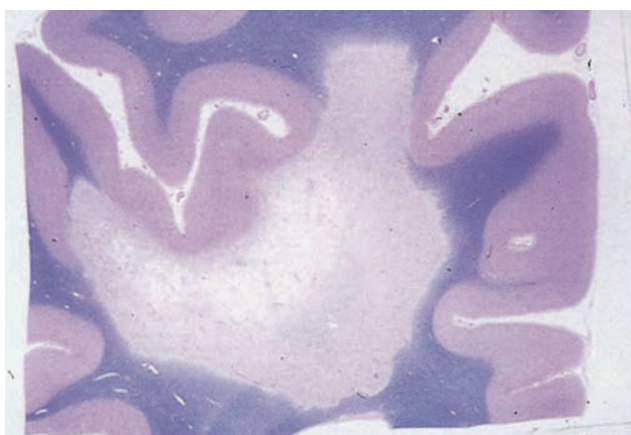A. β -Amyloid

B. Myelin

C. Synaptophysin

D. α -Synuclein

2-A 30-year-old woman presents with an 8-day history of mild tremor in her arms and impaired balance when walking. Vital signs are normal. Her symptoms disappear the following week. About 18 months later, the patient experiences another episode of weakness and requires assistance when walking. Neurologic examination reveals ataxia, dysarthria, decreased vibratory sensation in her legs, absent abdominal reflexes, increased deep tendon reflex. Fifteen years after the onset of symptoms, the patient becomes bedridden and dies. A coronal section of the patient's brain at autopsy is stained for myelin with luxol fast blue (shown in the image). Which of the following histopathologic findings would be expected in these plaques?



A. Astrogliosis

B. Lewy bodies

C. Negri bodies

D. Neurofibrillary tangles



1- B \ 2- A



NEED EXPLANATION ? [CLICK HERE](#)



Cases

EXTRA CASES REQUIRE EXTRA INFO

1-A 36-year-old woman comes to the physician with a 2-day history of blurry vision in the left eye and pain with eye movement. She had an episode of urinary incontinence several months ago that resolved spontaneously. The patient does not use tobacco or illicit substances. Vital signs are within normal limits. Physical examination reveals mild sensory loss in both legs below the knees. The left foot shows an extensor plantar reflex. Which of the following pathologic brain lesions is most likely present in this patient?

A.Extracellular senile plaques and intracellular neurofibrillary tangles

B.Necrosis of rapidly proliferating, anaplastic glial cells

C.Accumulation of nuclear viral inclusions within enlarged oligodendrocytes

D.Focal areas of demyelination with macrophages containing myelin debris

2-A 24-year-old woman comes to the primary care physician complaining of urinary urgency for the past week with occasional involuntary voiding, which has been causing the patient significant distress at work. She states this has never happened before, but that several months ago, she went to the emergency department for an episode of intense right eye pain with movement and loss of color vision. These symptoms gradually improved over 2 weeks. She has no other past medical history. Vital signs are within normal limits. Ophthalmologic examination reveals no visual field defects. Physical examination reveals upgoing plantar reflexes bilaterally. A head MRI shows multiple hyperintense periventricular ovoid lesions. Which of the following best describes the likely disease course in this patient?


A.Fully functional in all neurologic systems 15 years after the disease onset

B.Rapidly progressive disease course with neurologic disability in 5 years

C.Symptom exacerbations with near complete recovery between episodes

D.Continuous worsening from the onset of the disease





PATHOLOGY TEAM

Leader

لمى العتيبي

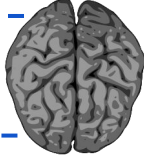


Leader

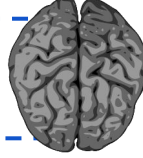
زياد العتيبي



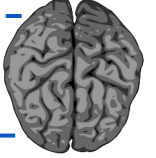
هياء العجمي



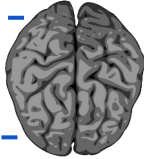
شوق الخليفة



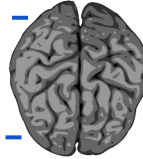
عبدالله الكودري



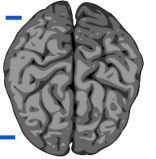
عمر المقرن



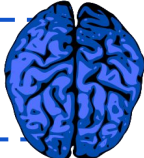
محمد العرفج



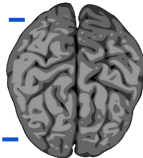
رند ابا الخيل



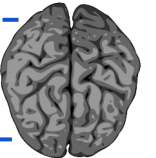
محمد معشي



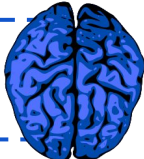
ريما المطيري



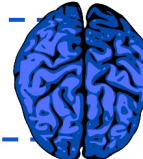
ساره العجاي



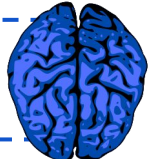
أفنان الأحمري



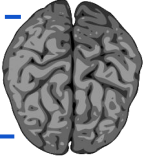
وعد العززي



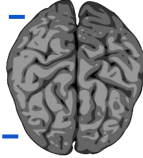
نوره المحيميد



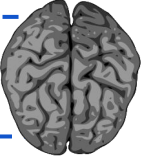
عائشة ابراهيم



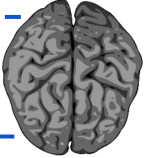
منصور العتيبي



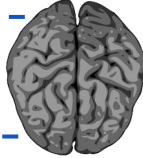
فيصل الشويعر



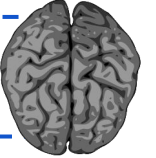
ريماس المحمود



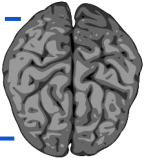
معاذ الحضيف



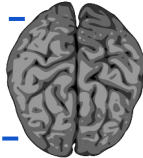
رغد المصاح



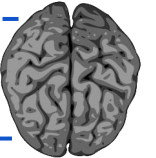
ليان الرويلي



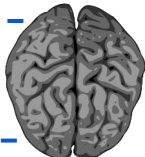
الحوراء العوامي



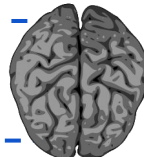
عروب المحمود



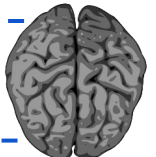
نوره المالك



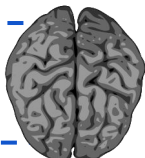
لؤي الحديثي



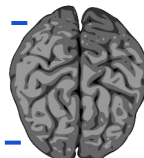
يزيد ال طلحه



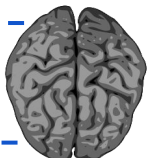
الجوهرة الوهبي



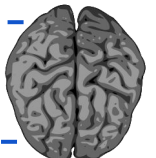
يزيد المطيري



سلطان البقمي



رزان السطحي



CONTACT US :

Pathologyteam443@gmail.com