

Abnormal Liver Enzymes

[Editing file](#)

No.27



Objectives :

- ★ Describe and interpret abnormal liver enzymes.
- ★ Develop a differential diagnosis for abnormal liver enzymes & jaundice.
- ★ Approach clinically patients with abnormal liver enzymes & jaundice.
- ★ Illustrate the management algorithm for a patient with abnormal liver enzymes & jaundice.
- ★ Know common liver diseases: pathophysiology, clinical presentation, work up and management.

Original text

Color index

Males slides

Doctor's notes ⁴³⁸

Doctor's notes ⁴³⁹

Doctor's notes ⁴⁴²

New text in slides ⁴⁴²

Text book

Important

Golden notes

Extra

Abnormal Liver Enzymes

Liver Enzymes¹

Short case scenario:

- when a patient have a fever or pain he usually use NSAIDs. Specially Diclofinac (commonly use in rheumatology) which is strong NSAIDs that induce liver injury (the safest NSAIDs is ibuprofen)
- patient presented with jaundice and severe liver injury due to a previous history of antibiotic use (Augmentin: amoxicillin and clavulanic acid) for viral sore throat

01

Aminotransferases- Alanine aminotransferase (ALT) and aspartate aminotransferase (AST): Parameters of hepatocellular damage

- ALT is found in cytoplasm of **hepatocyte**, and AST is found in cytoplasm & mitochondria of **hepatocytes**.
- There levels are **increased in hepatocellular damage**, ALT is **more specific²** for hepatocellular damage than AST. (But a greater increase of AST relative to ALT indicates severe hepatocellular injury because the mitochondria are only affected in cases of severe damage)
- **AST & ALT normal range: 0-35 U/L.**

02

Alkaline phosphatase (ALP): Parameter of cholestasis

- ALP includes enzymes that are widely distributed in the body e.g. liver, GIT, bone, placenta and kidney, It's elevated in liver diseases, pregnancy and bone diseases (not specific).
- In the liver they are located in cell membranes of the hepatic sinusoids and the **biliary canaliculi (bile ducts)**. Accordingly, levels rise with intrahepatic and extrahepatic biliary obstruction and with sinusoidal obstruction (as in infiltrative liver disease).
- If the GGT is also abnormal, the ALP is presumed to come from the liver.
- **ALP normal range: 36-92 U/L. Dr.note ~normal around 40**

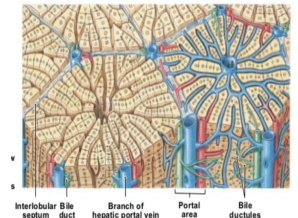
03

γ -glutamyl transferase (GGT):

- Microsomal enzyme found in many cells and tissues of the body, but the highest concentrations is in the liver.
- It is produced by **hepatocytes** and by the epithelium lining small bile ducts
- ★ Large increases in ALP and GGT activity favours biliary obstruction and is described as 'cholestatic' or 'obstructive'.
- Isolated elevation of GGT is common and occur during ingestion of microsomal enzyme-inducing drugs, including alcohol, but also in Non-alcoholic fatty liver disease.
- Used to confirm hepatic origin of elevated ALP levels

When ALP is elevated it indicates

- 1-bone fracture (bone)
- 2-pregnancy
- 3-growth in teenager etc... so we check GGT level to confirm that the cause is hepatic



Approach to liver enzymes

Hepatocellular causes

VS

Cholestatic causes: Isolated ALP and rule of GGT

VS

Mixed³

You need to memorize the numbers

→ Hepatocellular picture (Hepatitis):

- ◆ ALT and AST are elevated more than ALP and GGT e.g. If the upper limit of normal for AST and ALT is 30⁴ and the upper limit of normal ALP is 150 and the results of LFT were as followed:
 - AST and ALT = 100 (That's triple the normal level)
 - ALP = 180 (Not increased much compared to the normal level)
- ◆ So this case has a hepatocellular dominant picture

→ Cholestatic picture:

- ◆ ALP elevated more than ALT and AST; apply the same concept here as well (because it's a problem in the bile duct)

1: Measurement of liver enzymes provide biochemical evidence of liver cell damage and are not truly 'function' tests, given that they are released by injured hepatocytes. Liver function per se is **best assessed by the serum albumin, PT and bilirubin** because of the role played by the liver in synthesis of albumin and clotting factors and in clearance of bilirubin.

2: Because ALT only present in the liver but AST present in the liver, heart, muscles and erythrocyte

3: Mixed is not imp at ur level (it basically means you can't tell which enzyme is dominant)

4: It depends on the sex but generally speaking = 30

Abnormal Liver Enzymes

Approach to liver enzymes cont'

The degree of transaminases elevation could be a useful indicator as well¹:

Minor elevation (<100 U/L)	<ul style="list-style-type: none"> Chronic hepatitis (B,C) Haemochromatosis Fatty liver disease
Moderate elevation (100-300 U/L)	<ul style="list-style-type: none"> Alcoholic hepatitis Non-alcoholic steatohepatitis Autoimmune hepatitis Wilson's disease
Major elevation (>300 U/L) (Thousand range (>1000))	<ul style="list-style-type: none"> Acute viral hepatitis (A ,B) (The first differential diagnosis) Drugs: Tylenol, anticonvulsants, and paracetamol, cocaine (even <ul style="list-style-type: none"> We have to check every drug the patient has taken in the past 6 months because he could have elevated liver enzymes for a few months then suddenly present with jaundice) Toxins: amanita phalloides poisoning. Autoimmune liver disease (hepatitis) Hypotension (ischemic hepatitis) Vascular injury e.g. hypotension in ICU pts

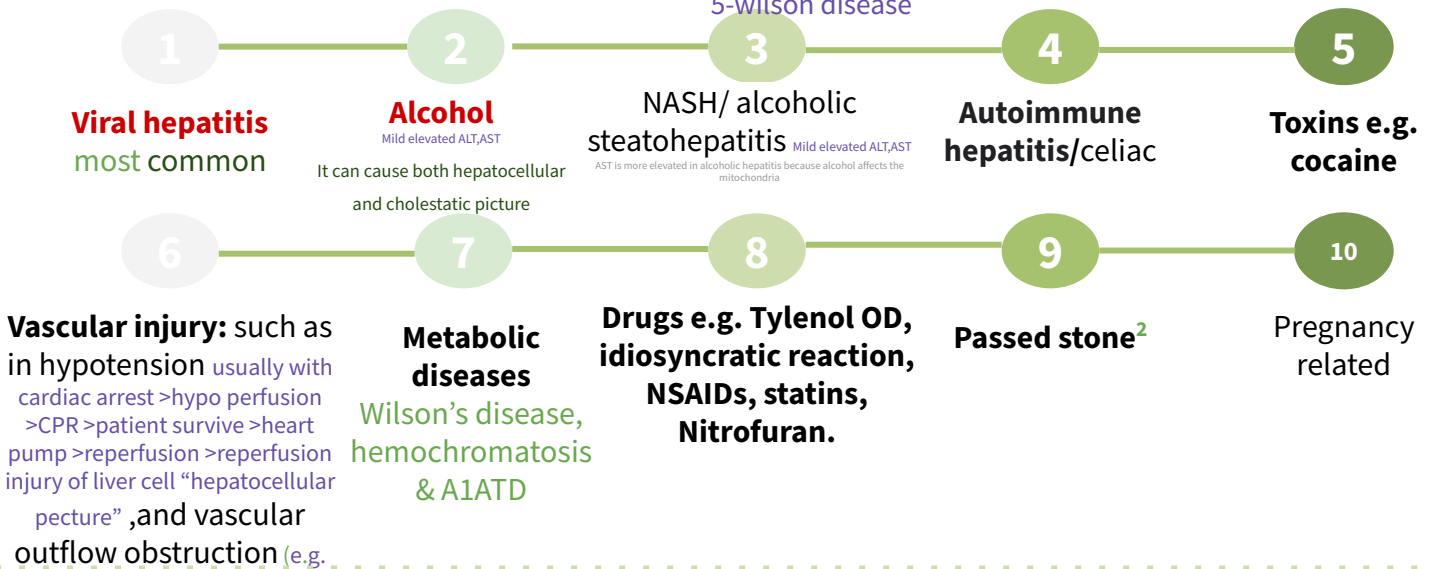
- Typical cases are:

- Ischemia, shock liver (prolonged hypotension or circulatory collapse; Liver is so sensitive to hypoxia)
- Acetaminophen toxicity
- Severe viral hepatitis.

When aminotransferase(ALT,AST) is markedly elevated (thousands):

- 1-viral hepatitis
- 2-Drugs,toxin
- 3-vascular injury
- 4-AIH
- 5-wilson disease

Hepatocellular causes



1: The Budd-Chiari Syndrome (Thrombosis of the hepatic vein). In viral hepatitis, ALT > AST unless cirrhosis is present. In alcoholic liver disease and steatohepatitis the AST is often greater than ALT. Thus in patients with viral hepatitis, an AST/ALT ratio >1 indicates cirrhosis, and in patients without cirrhosis in whom AST > ALT, alcohol or obesity should be considered the most likely cause. Note that liver transaminases are often normal or even low in patients with cirrhosis (without any active cell necrosis) or metastatic liver disease, because the number of healthy functioning hepatocytes is markedly reduced.

2: When there's obstruction, there will be backflow of bile into the liver. In case the obstruction was temporary (only hepatitis will be present). In cases of prolonged obstruction there will be cholestatic picture. (Pregnancy is an exception, it may present with cholestatic picture or fatty liver). In the early phase: Hepatocellular picture. In the late phase: Cholestatic picture

Abnormal Liver Enzymes

◀ Cholestatic causes

Cholestasis is a liver disease. It occurs when the flow of bile from your liver is reduced or blocked. Bile is fluid produced by your liver that aids in the digestion of food, especially fats. When bile flow is altered, it can lead to a buildup of bilirubin

Extrahepatic = Obstructive

- Obstruction of the biliary ducts between the liver and duodenum
- **Biliary stone**
- **Stricture:**
 - **Malignant:** Periampullary tumors, comprises four different cancer types: pancreatic ductal adenocarcinoma (PDAC), distal cholangiocarcinoma (DC), ampullary cancer (AC), and duodenal adenocarcinoma (DA).
 - Primary sclerosing cholangitis, AIDS cholangiopathy

Intrahepatic = Non-obstructive

- Impaired bile formation or secretion
- Primary biliary cholangitis
- Primary sclerosing cholangitis: small duct
- Cystic fibrosis
- **Sepsis, Total parenteral nutrition, Drugs usual cause**
- **Infiltrative:**
 - **Granulomatous diseases** such as TB, sarcoidosis, and lymphoma
 - **Amyloidosis**
- Intrahepatic cholestasis of pregnancy

◀ DDX of jaundice^{1,2}

Direct Hyperbilirubinemia (Hepatic³, Post-hepatic⁴)	<ul style="list-style-type: none"> ● Hepatobiliary disease ● In hepatocellular jaundice the concentrations of both unconjugated and conjugated bilirubin in the blood increase. ● In obstructive (cholestatic) jaundice conjugated bilirubin is increased the blood, and associated with pale stools⁵ and dark urine⁶.
Indirect Hyperbilirubinemia (pre-hepatic)	<ul style="list-style-type: none"> ● Characterised by an isolated raised bilirubin level (unconjugated). ● Gilbert: The most common form of non-haemolytic hyperbilirubinemia is Gilbert's syndrome⁷, an inherited disorder of bilirubin metabolism. (Dr: Gilbert is hepatic, not pre-hepatic) ● Hemolytic anemia ● Hematoma, Massive t/f, Rifampin
Pseudo-Jaundice due to Carotenemia	<ul style="list-style-type: none"> ● In which case the sclera is intact. (The jaundice is only present on the skin) ● If you check bilirubin level it will be normal ● It happens to those who eat too much mango or carrot because it is due to deposition of carotene "A Vitamin A precursor"

- Normal total bilirubin <20
- If the total bilirubin = 100 (5 times the normal), the direct bilirubin (Conjugated bilirubin) was 20. what's the dominant pattern?
 - Indirect Hyperbilirubinemia

1: Jaundice is not itself a diagnosis and the cause should always be sought. The two most useful tests are the **viral markers** for HAV, HBV and HCV (in high-risk groups), with an US, **Liver biochemistry** confirms the jaundice and may help in the diagnosis.

2: Acute jaundice in the presence of an ALT of > 1000 U/L is highly suggestive of an infectious cause (e.g. hepatitis A or B), drugs (e.g. paracetamol) or hepatic ischaemia.

3: Jaundice due to parenchymal liver disease is associated with increases in transaminases (AST, ALT). but also there maybe increase in other LFTs, including cholestatic enzymes (GGT, ALP).

4: Cholestatic jaundice is characterised by a relatively greater elevation of ALP and GGT than the aminotransferases.

5: Direct "conjugated bilirubin" metabolized in multiple steps to stercobilin in the colon this may lead to discolored stool

6: Excess direct bilirubin in the serum is therefore excreted in the urine which may become dark

7: An abnormal gene you inherit from your parents causes Gilbert's syndrome. The gene normally controls an enzyme that helps break down bilirubin in your liver. When you have an ineffective gene, your blood contains excess amounts of bilirubin because your body doesn't produce enough of the enzyme.



◀ Hepatocellular pattern

If Hepatocellular pattern
(work up)

- Viral Hepatitis serologies
- Alcohol level
- US-for fatty liver or cirrhosis
- Drug level for Tylenol, phenytoin
- Urine toxins: cocaine <vomiting alot>
- Doppler US (To check vascular injury e.g. Budd-Chiari syndrome)
- ANA, ASMA, IgG, AMA, celiac screen
- Serum ceruloplasmin (For Wilson's disease)
- Liver biopsy to be considered if needed¹
- Fibroscan²

If you get this scenario;
6 hr of severe RUQ pain³ with ALT 400 & AST 300 & ALP 140 (you suspect stone in the biliary system) (classic presentation of stones). Recurrent +self resolving +spontaneous

US abdomen

◀ Cholestatic pattern

If Cholestatic pattern

US or CT*

*as a student don't choose CT
US—initial
CT—confirm

Dilated duct

Yes

No

Likelihood of obstruction

Low

Obstructive cause
likely Malig → ?ERCP
- CT chest/abdo/pelvis
- EUS/FNA
Likely stones → ?ERCP

- **High likelihood of obstruction**⁶: ERCP⁷
(US: stone in CBD, cholangitis> triad:(-pain-jaundice-fever)
- **Intermediate likelihood**⁸:
MRCP/EUS
(mild elevated ALT/AST or Bili)

Intrahepatic cause
work up for hepatocellular & intrahepatic cholelsthisic
AMA, MRCP, Liver Bx

If -ve

1: Liver Bx is used If no cause can be identified, as last resort.
 2: Fibroscan is an alternative non-invasive test for Liver Bx, it tells u if there's fibrosis but it's not helpful if diagnosis isn't known
 3: Ddx for RUQ pain with normal liver enzymes: biliary colic (stone at the neck of the bile duct)
 4: When you see cholestatic pattern the first thing you should do is rule out obstructive jaundice by **US as the best initial** bc we usually suspect stones to be the cause. Better to avoid CT scan
 5: Dilated ducts are an indirect way of looking for an **obstruction**, if dilated means there's a stone
 6: **Example of High likelihood**: If a pt presents with cholestatic pattern, fever, abdominal pain and jaundice. US is normal. This picture fits more with ascending cholangitis (**Best next step is ERCP** bc of high likelihood of obstruction)
 7: Endoscopy to bring the stone out
 8: Example for intermediate likelihood: If a pt presents with mildly elevated ALT and AST. Mild elevation is usually attributable to stones. (Do MRCP/EUS in this case)



Isolated elevated ALP

- Isolated ALP and role of GGT:** If ALP is elevated alone (normal AST,ALT), look at the GGT, if it is elevated as well then it's probably a liver problem, if not (GGT is normal) then the elevated ALP is probably due to another cause (Pregnancy, Bone disease, etc.). So, When testing for ALP levels measure GGT as well **to make sure the elevation is hepatic (obstructive) in origin (rather than bone or intestinal).**

Alcohol

→ Alcohol can cause hepatic or cholestatic picture but usually hepatocellular



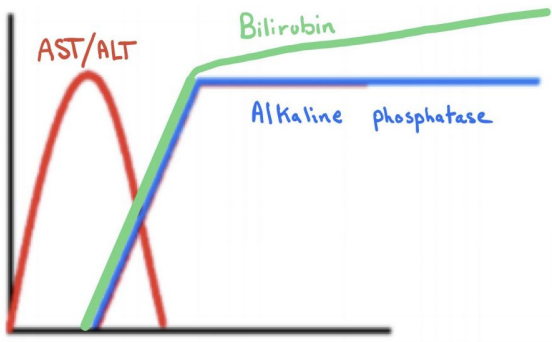
Don't ask the patient in front of people. You have to know how to ask in the right way. do not jump directly to the question

In alcoholic liver disease and steatohepatitis, the AST is often greater than the ALT leading to a reversed AST:ALT ratio to 2:1 (characteristic feature)

Elevated out of proportion of liver enzymes.*

→ *e.g. If the bilirubin = 100 (5 times the upper limit), ALT=80, AST 70, ALP 300

Bile duct stone



Expected liver enzymes pattern:

ALT and AST get elevated first (in the 1st six hours) then they go down. then:

- if the stone persists long enough thereafter (~24hrs) ALP will elevate (500-thousands) as well as direct bilirubin (obstructive jaundice)
- if the stone passes early (before ALP elevation) ALP will not get elevated. (the patient usually has multiple tiny stones that pass down the gallbladder, they severe pain that lasts for 5 minutes or hours)

Management of abnormal LFTs in asymptomatic patients

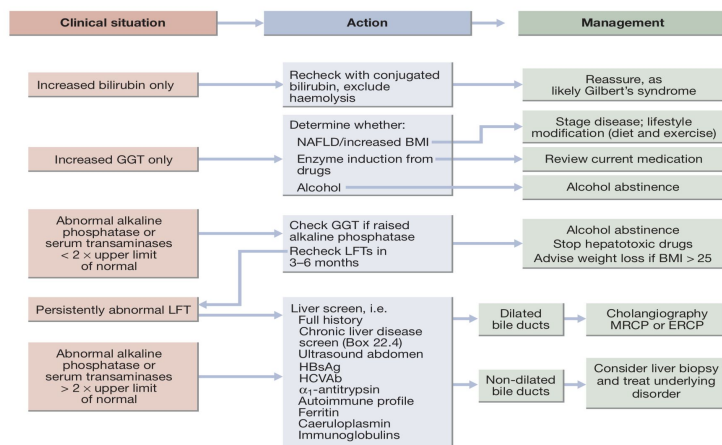


Fig. 22.14 Suggested management of abnormal liver function tests in asymptomatic patients. *No further investigation needed. (α₁AT = alpha₁-antitrypsin; BMI = body mass index; ERCP = endoscopic retrograde cholangiopancreatography; GGT = γ-glutamyl transferase; HBsAg = hepatitis B surface antigen; HCVAb = antibody to hepatitis C virus; MRCP = magnetic resonance cholangiopancreatography; NAFLD = non-alcoholic fatty liver disease)

◀ Hepatitis A virus Hygiene -self limited

The primary **route of transmission** of HAV is the **fecal-oral route**, by either:

- 1 Person-to-person contact
- 2 Ingestion of contaminated food or water

- Infection with HAV **does not result in chronic infection**, only in **acute self-limited** episode of hepatitis¹.
- Complete clinical recovery is achieved in 2-6 months for almost everyone.

◀ Clinical presentation

Adults

usually present with one of the following five clinical patterns:

- Asymptomatic
- Symptomatic with jaundice and self-limited after approximately 8 weeks.
- Rarely Cholestatic with jaundice lasting 10 weeks or more.
- 10% of symptomatic patients, relapsing, with two or more bouts of acute HAV infection occurring over a 6- to 10 week period.
- Rarely Fulminant Hepatic Failure (FHF)

Children

- If younger than 2 years → are usually asymptomatic (80%).
- If 5 years or older → symptoms develop in most children (80%).

History (Hx)	<ul style="list-style-type: none"> • Prodromal symptoms in patients with acute hepatitis A include: fatigue, weakness, anorexia, nausea, vomiting, diarrhea, and abdominal pain • Less common symptoms are fever, headache, arthralgias, myalgias, and diarrhea. • Symptoms may last from a few days to 2 week, and usually decrease with the onset of clinical jaundice.
Physical examination	<ul style="list-style-type: none"> • Right upper quadrant tenderness and mild liver enlargement are found on physical examination in 85% of patients. • Splenomegaly and cervical lymphadenopathy are each present in 15%
Investigation	<ul style="list-style-type: none"> • HAV antigen (the only antigen) • Anti-HAV: IgM type is diagnostic for acute HAV infection (Active infection), and IgG type marker of previous infection and indicates immunity • Transaminases: hundreds
Prescription¹ (Rx)	<ul style="list-style-type: none"> • Treatment is symptomatic. • Neither the cholestatic variant nor relapsing hepatitis A is associated with an increase in mortality. • Pregnancy: Unlike hepatitis E, Acute hepatitis A is not associated with a higher mortality rate in pregnant women

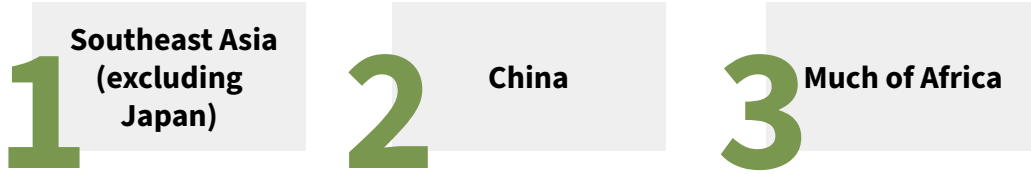
1: Vaccine should be given to travelers to endemic area prevent infection.

2: There is no role for antiviral drugs in the therapy of HAV infection. the Infection is best prevented by improving social conditions, especially overcrowding and poor sanitation.

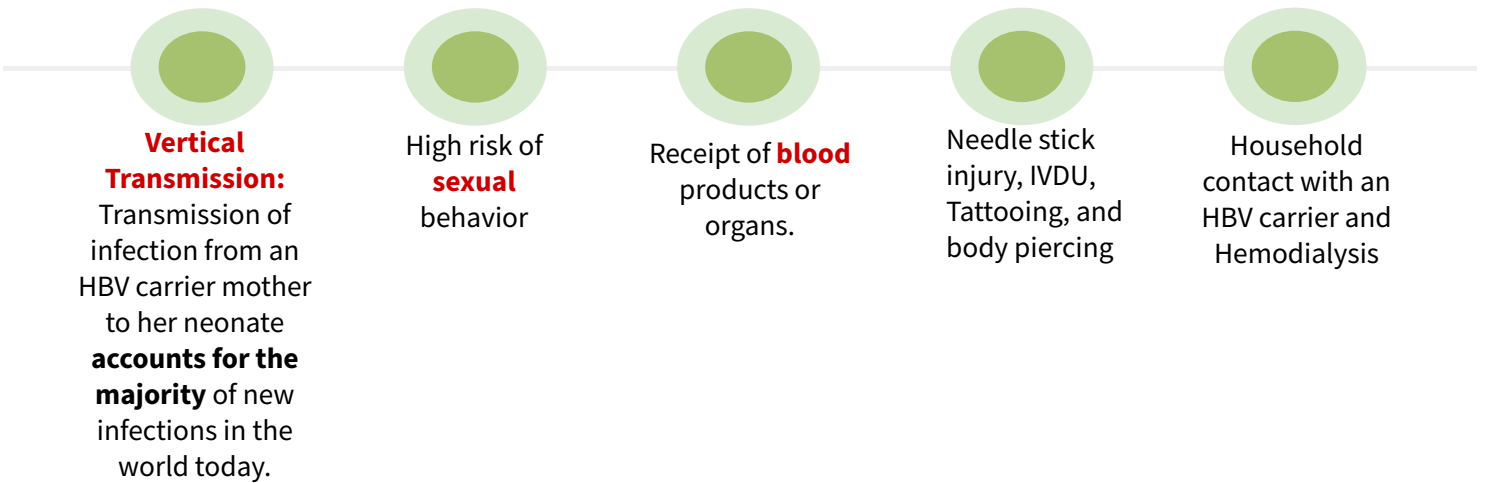
◀ Prevalence

It is now reduced with vaccine

- The prevalence of hepatitis B varies markedly around the world.
- Highly endemic regions (**8% or more of the population are chronic HBV carriers**), such as:



◀ Transmission



If HbeAg +ve:

- 80% of HbsAg-positive mothers who are HBeAg-positive transmit the disease to their offspring.
- Whereas mothers who are positive for antibody to HBeAg (anti-HBe) transmit the disease less frequently (20%)

◀ Acute vs Chronic

- The **age** at which a person becomes infected with HBV is a principal determinant of the clinical outcome.

Adult

- Full recovery occurs in 90–95% of adults following acute HBV infection.
- Only **1% to 5%** of these persons become **chronically** infected when get HBV infection
- Fulminant liver failure cause by acute hepatitis B occurs in **less than 1%** of cases.

Children

- **95%** of infected neonates become **chronic** HBV carriers and recovery is rare because of immunologic tolerance to the virus.

Natural history in chronic HBV

[Click here for book figures on natural history & phases of chronic HBV](#)

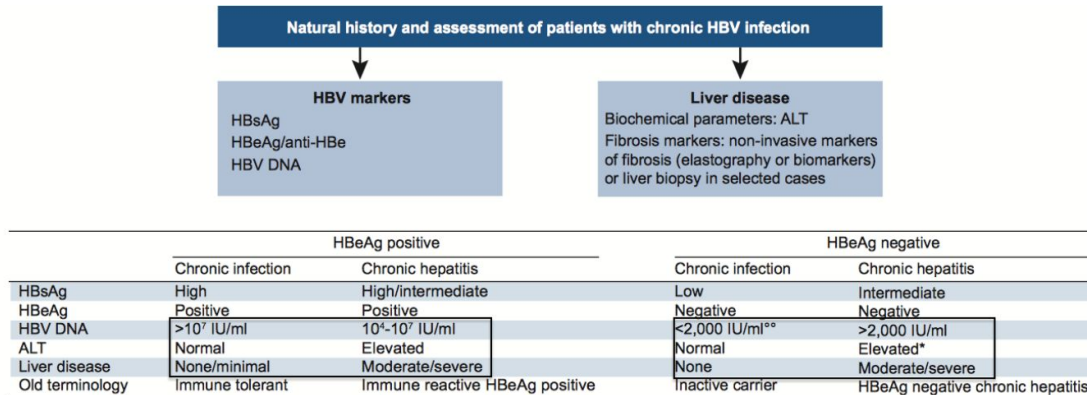


Fig. 1. Natural history and assessment of patients with chronic HBV infection based upon HBV and liver disease markers. *Persistently or intermittently. **HBV DNA levels can be between 2,000 and 20,000 IU/ml in some patients without signs of chronic hepatitis.

- **Resolved CHB infection is defined by clearance of HBsAg with acquisition of antibody to HBsAg.**
 - Approximately 0.5% of persons with inactive CHB will clear HBsAg yearly; and most will develop antibody to HBsAg (anti-HBs).
 - Low levels of HBV DNA are transiently detected in the serum in the minority of persons achieving seroclearance.

Clinical presentation

Acute Hepatitis B in Adult

- Acute infections are **heralded by a serum sickness-like prodrome** of fever, arthralgia or arthritis, and rash, which is most commonly maculopapular or urticarial, in 15% of patients.
- These features generally abate **before the manifestations of liver disease** which include jaundice and peak serum aminotransferase elevations are observed.
- Clinical symptoms and jaundice generally **disappear after one to three months**. In general, elevated serum ALT levels and serum HBsAg titers decline and disappear together, and in approximately 80% of cases.

Chronic Hepatitis B in Adult

- Asymptomatic or fatigue
- Symptoms and signs of CLD
- Extrahepatic Manifestations: arthritis, dermatitis, glomerulonephritis, polyarteritis nodosa, cryoglobulinemia, papular acrodermatitis, and polymyalgia rheumatica.

Acute Flares in Chronic Hepatitis B:

- Spontaneous Flares
- Immunosuppressive Therapy-Induced Flares

◀ Diagnosis

- 1 **HbsAg¹**
- 2 **HbcAB⁴:**
IgG vs IgM
- 3 **HbsAB²**
- 4 **Tests for co-infection:**
HCV, HDC, and HIV

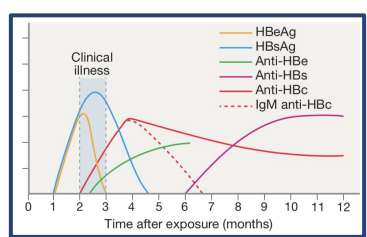
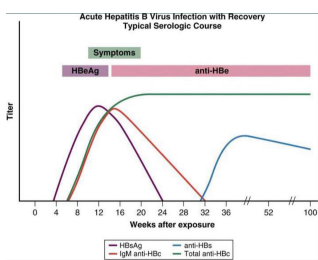
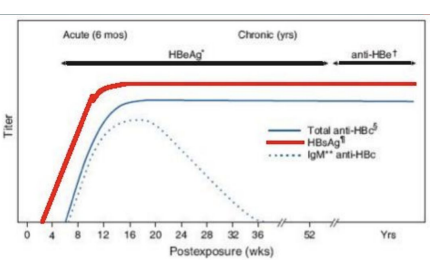


HBsAg

- Appears in serum **2 to 10 weeks**.
- Persistence of **HBsAg for >6 months** implies progression to chronic HBV infection.
- In self-limited acute hepatitis, HBsAg usually becomes undetectable after **4-6 months**.
 - The disappearance of HBsAg is followed by **several weeks later by the appearance of anti-HBs**.
 - **Anti-HBs may not be detectable during a window period of several weeks to months after the disappearance of HBsAg.**

HBcAB

- During the window period, the diagnosis of **acute** HBV infection is made by the detection of **IgM anti-HBc** in serum. IgM class is usually detectable for 4 to 6 months after an acute episode of hepatitis or during exacerbation of chronic hepatitis B and arrelly for up to two years.
- **IgG Anti-HBc** persists in persons who recover from acute hepatitis B and CHB.
- **The accurate diagnosis of acute hepatitis B require testing with immunoglobulin (Ig) M antibody to hepatitis B core antigen (HBcAg) (IgM anti-HBc)**



22.38 How to interpret the serological tests of acute hepatitis B virus infection

Interpretation	HBsAg	Anti-HBc IgM	Anti-HBc IgG	Anti-HBs
Incubation period	+	+	-	-
Acute hepatitis				
Early	+	+	-	-
Established	+	+	+	-
Established (occasional)	-	+	+	-
Convalescence				
(3-6 months)	-	±	+	±
(6-9 months)	-	-	+	+
Post-infection	-	-	+	±
Immunisation without infection	-	-	-	+

+ = positive; - = negative; ± = present at low titre or absent.
 (anti-HBc IgM/IgG = antibody to hepatitis B core antigen of immunoglobulin M/G type; anti-HBs = antibody to HBsAg; HBsAg = hepatitis B surface antigen)

Acute or CHD

- **Coexistence of HBsAg and anti-HBs** in serum has been reported in approximately 25% of HBsAg-positive persons and occurs more commonly in persons with chronic hepatitis B than in those with acute hepatitis B.
- **Persistence of HBeAg³ three or more months** after the onset of illness indicates a high likelihood of transition to chronic HBV infection
- The finding of HBeAg in the serum of an **HBV carrier indicates greater infectivity**, a high level of viral replication, and the need for antiviral therapy.

1: **HBsAg** indicates active infection, and a negative test for it makes HBV infection very unlikely.
 2: **Anti-HBs** marker of immunity implies either a **previous infection**, in which case anti-HBc is also present, or **previous vaccination, in which case anti-HBc is not present**.
 3: **HBeAg** indicates of viral replication (*patient is highly infectious*) its appearance is followed by the production of antibody (**anti-HBe**) Marker of low infectivity.
 5: **Anti-HBc** is Markers of exposure to hepatitis B infections, Hepatitis B core antigen (**HBcAg**) is not found in the blood
 6: Measurement of **viral load** is important in monitoring antiviral therapy and identifying patients with pre-core mutants

HBV scenarios

[Click here for a very organized figure on antigens and antibodies interpretation](#)

1

- HBsAg +ve
- HbcAb +ve
- HBsAb -ve

→ Patient has a **Chronic active HBV** and requires further work up

2

- HBsAg -ve
- HbcAb +ve
- HBsAb +ve

→ Had HBV and (Immune, due to previous infection)

3

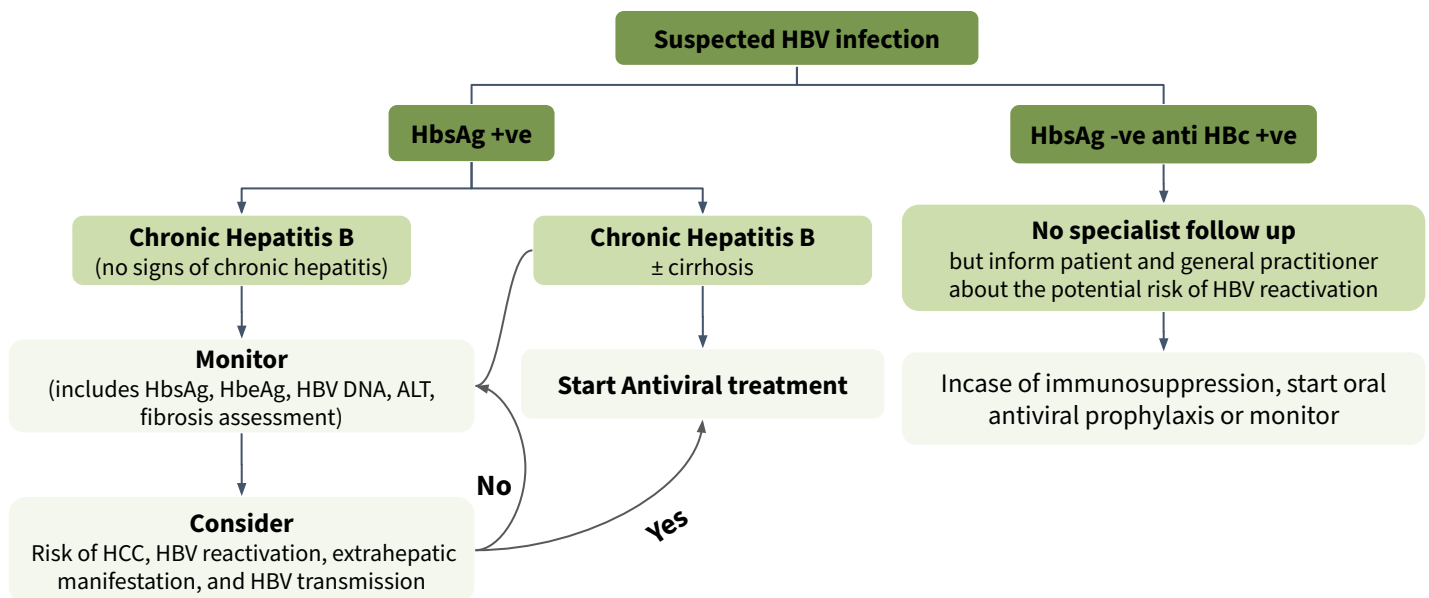
- HBsAg -ve
- HbcAb -ve
- HBsAb +ve

→ Immunity due to vaccination

Chronic HBV: Monitoring & Rx

- The measurement of **serum HBV DNA** is commonly used to evaluate a patient's candidacy for antiviral therapy and to monitor response during treatment.
- Owing to the fluctuating nature of CHB, the accuracy of one high HBV DNA level at a single time point in predicting prognosis is poor and regular monitoring of disease status is imperative to determine need for antiviral therapy.

Fibroscan	<ul style="list-style-type: none"> • Noninvasive methods to assess fibrosis severity.
Liver biopsy	<ul style="list-style-type: none"> • Provides an assessment of the severity of necroinflammation and fibrosis, and may be especially useful for persons who lack clear-cut indications for treatment. Whereas liver biopsy is regarded as the best method to assess the severity of inflammatory activity and fibrosis, noninvasive methods to assess fibrosis severity are also useful.
US	<ul style="list-style-type: none"> • HCC screening
Pegylated interferon (Peg-IFN)	<ul style="list-style-type: none"> • Short duration of therapy • Before pregnancy • Side effects
Liver enzyme	<ul style="list-style-type: none"> • ALT
Nucleos(t)ide analogs (NAs) therapy	<ul style="list-style-type: none"> • Overall, all NAs have an excellent safety profile across a wide spectrum of persons with CHB, including those with decompensated cirrhosis.



1: Chronic HBV infection is marked by the presence of HBsAg and anti-HBc (IgG) in the blood. Usually, HBeAg or anti-HBe is also present. the exception is HBeAg-negative chronic hepatitis B (also called 'pre-core mutant' infection), in patients who have a mutation in the pre-core protein, which means they cannot secrete E antigen into serum. they will have high levels of viral replication, serum HBV-DNA and hepatic necroinflammation are seen, despite negative HBeAg.

◀ Treatment:

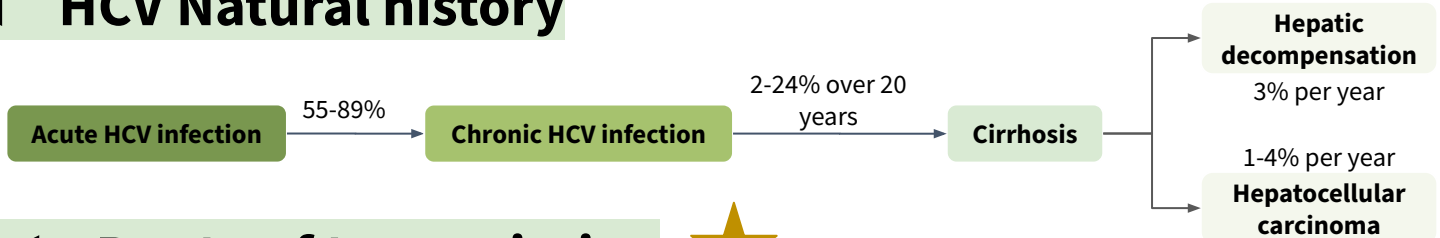
- Management of acute hepatitis B:
 - Treatment is **supportive with monitoring**. There is no definitive evidence that antiviral therapy reduces the severity or duration of acute hepatitis B.
- Management of chronic hepatitis B:
 - Treatments are still limited, as no drug is able to eradicate hepatitis B infection completely. (i.e. render the patient HBsAg-negative).
 - The goals of treatment are **HBeAg seroconversion, reduction in HBV-DNA and normalisation of the LFTs**.

Features	Pegylated interferon alfa (PegIFN α)	Nucleos(t)ide analogs: Entecavir, tenofovir disoproxil fumarate, tenofovir alafenamide
Route of admin	Subcutaneous injection	Oral and
Treatment duration	48 weeks	first-line agents: long-term until HBsAg loss (stopping NA after some years might be considered in selected cases)
Tolerability	Low	High
Long term safety concern	Very rarely persistence of on treatment adverse event (psychiatric, neurological, endocrinological)	Probably not (uncertainties regarding kidney function, bone disease for some NA)
Contraindications	Many (i.e. decompensated disease, comorbidities etc.) contraindicated in cirrhosis, as it may cause a rise in serum transaminases and precipitate liver failure.	None (dose adjustment according to eGFR)
Strategy	Induction of a long term immune control by finite treatment	Stopping hepatitis and disease progression by inhibiting the viral replication
Level of viral suppression	Moderate (variable response pattern)	Universally high
Effect on HBeAg loss	Moderate, depending on baseline characteristic	low in the first year, increase to moderate during long term treatment
Effect of HbsAg levels	Variable, depending on the baseline characteristic (overall higher as compared to NA)	low: slowly increase with treatment time in HBeAg +ve patient; usually very low in HBsAg -ve patient
Risk of relapse after treatment cessation	low for those with sustained response 6-12 months after therapy	Moderately in consolidation treatment provided after HbeAg seroconversion. High for HbeAg -ve disease
Early stopping rules	Yes	No
Risk of viral resistance	No	Minimal to none

Definition

- Hepatitis C virus (HCV) infection is one of **the main causes of chronic liver disease** worldwide.
- The long-term impact of HCV infection is highly variable, ranging from minimal histological changes to extensive fibrosis and cirrhosis with or without hepatocellular carcinoma (HCC).

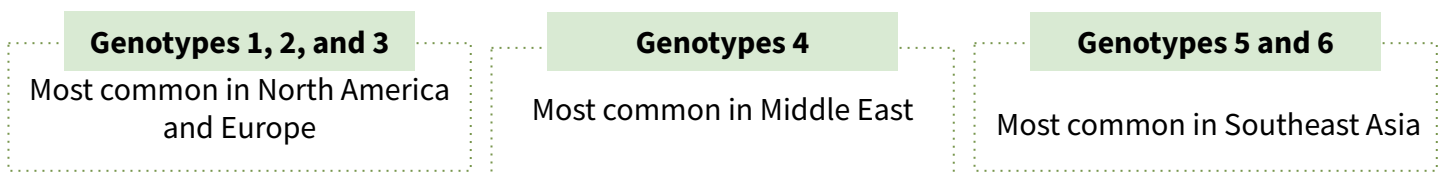
HCV Natural history



Route of transmission

- Modes of transmission of HCV can be divided into:
 - 1 Percutaneous (blood transfusion and needle stick inoculation, dental procedures).
 - 2 Non-percutaneous (sexual contact and perinatal exposure).
- The risk of **sexual transmission** is negligible in monogamous couples that do not engage in high-risk sexual practices. However, epidemiologic studies have shown that persons with multiple sex partners have a higher prevalence of HCV infection.
- The risk of **perinatal transmission of HCV infection is low**, averaging 5.1% to 6.7% for HCV monoinfected patients.
- The Centers for Disease Control and Prevention have concluded that breastfeeding by HCV-infected mothers is generally safe.

Genotypes




Clinical features

Acute Hepatitis C

- Rarely seen in clinical practice because nearly all cases are **asymptomatic** until progression to cirrhosis occurs.
- The rate of viral persistence after acute infection varies, ranging from 45% to more than 90%.
- Younger and female patients having the lowest rates of chronicity. Other factors that may play a role include the source of infection and size of inoculum.
- **Anti-HCV** will be detected between week 2 and month 3.
- **HCV RNA** is detectable **within 2 to 3 weeks** of exposure, in patients whom the infection resolves spontaneously, loss of HCV RNA from serum usually occurs within 3 to 4 months of the onset of clinical disease.

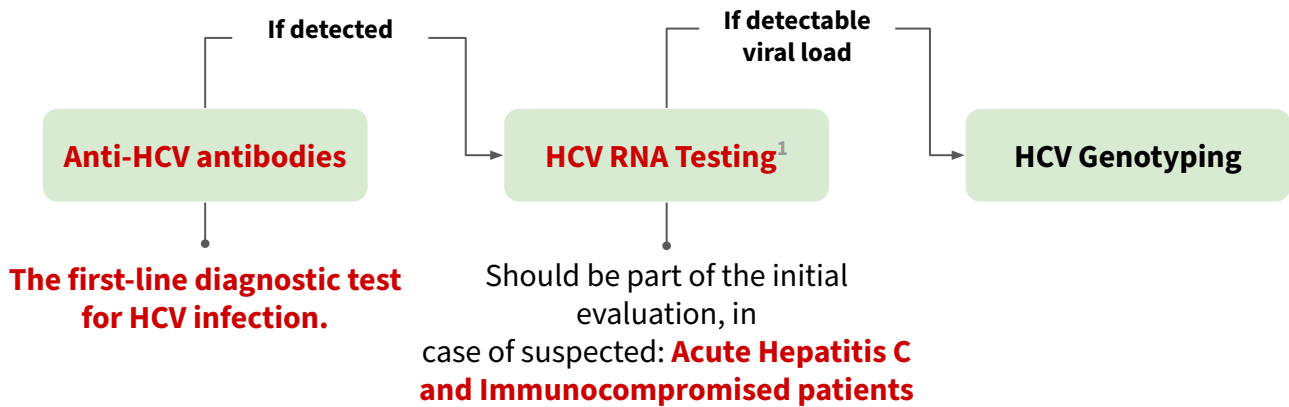
1: This virus is over, as we have very good treatment options.

◀ Extrahepatic Manifestation:



- Among HCV-infected patients 19% to 50% have cryoglobulins in serum, but clinical manifestations of **cryoglobulinemia** are reported in only 5% to 10% of these patients and are more common in patients with cirrhosis.

◀ Diagnosis



- The diagnosis of acute and chronic HCV infection is based on the **detection of HCV RNA** by a sensitive molecular method limit of detection <15 international units [IU]/ml)
- In patients with acute Hepatitis C, HCV RNA should be retested 3 to 4 months after clinical presentation.

◀ Treatment

- Researcher have recently made significant advances in treatment for hepatitis C using new, "direct-acting" antiviral medications, sometimes in combination with existing ones.

- **As a result, people experience:**

1. Better outcomes
2. Fewer side effects
3. Shorter treatment times

- **The choice of medications and length of treatment depends on:**

1. Presence of Cirrhosis and HCV genotype
2. Prior treatments
3. Renal function

i 22.41 Direct-acting antiviral agents for hepatitis C		
Drug class	Therapeutic target	Selected drugs
Protease inhibitors (PIs)	Non-structural viral protein NS3/4A (protease that cleaves the HCV polyprotein)	Telaprevir Boceprevir Simeprevir Paritaprevir Grazoprevir
Nucleoside polymerase inhibitors (NPIs)	Non-structural viral protein NS5B (RNA-dependent RNA polymerase needed for viral replication)	Sofosbuvir
Non-nucleoside polymerase inhibitors (NNPIs)	Non-structural viral protein NS5B (RNA-dependent RNA polymerase needed for viral replication)	Dasabuvir
NS5A replication complex inhibitors	Non-structural viral protein NS5A (assembly of viral replication complex)	Daclatasvir Velpatasvir Ledipasvir Ombitasvir Elbasvir
Host-targeting antiviral drugs (HTAs)	Cyclophilin (pharmacological inhibitor targets host cell functions involved in the HCV life cycle)	Alisporivir

1: +ve test indicates active HCV, and -ve test indicates no infection.

Autoimmune hepatitis

Definition

Female, young, (ANA, ASMA, IgG are the most important)

AIH is a chronic liver disease that affects mainly **young women** but can also affect males and may present at any age and in all ethnic groups. If untreated, often leads to **cirrhosis, liver failure** and **death**.

Characteristics

1

Hypergammaglobulinemia (IgG in particular)

3

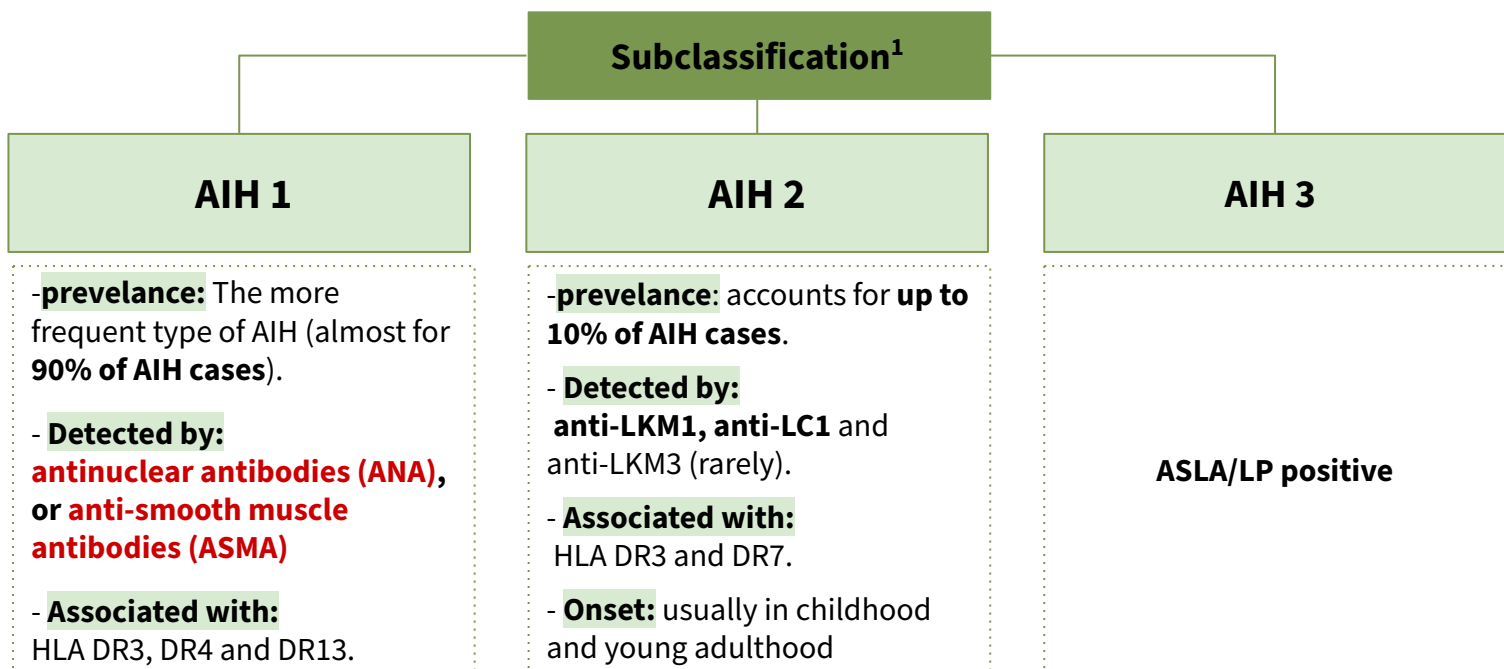
Interface hepatitis on liver histology

2

Circulating autoantibodies (ANA, ASMA, IgG are the most important)

4

A favorable response to immunosuppression



Clinical presentation²

Insidious onset is the most common clinical phenotype of the disease (two thirds of patients):

- either without any apparent symptom
- with one or more of the following non-specific symptoms:

- Fatigue (General ill health).
- Right upper quadrant pain
- Anorexia, Weight loss, Nausea.
- Amenorrhea is also common.
- Fluctuating jaundice
- polyarthralgia involving the small joints **without arthritis**



Symptoms

Broad range from asymptomatic to acute/severe or even fulminant

Any age

Both sexes

(female-male 3:1)

Onset

Acute³ (25%) or **insidious**

1: AIH 1 is the most important one, the doctor focused on it and skipped 2 and 3 (not Subclassification clinically important)

2: often Associated with other autoimmune disease, such as Hashimoto's thyroiditis or rheumatoid arthritis

3: resembling viral hepatitis, but resolution does not occur. And can lead extensive liver necrosis and liver failure

◀ Laboratory findings

Bilirubin & Aminotransferases

The typical biochemical profile of the disease is a predominantly hepatitis pattern:

- **bilirubin concentrations and aminotransferases:** from just above the upper limits of normal to >50 times these levels (Degree of ALT/AST elevations does not reliably reflect severity of AIH at the histological level)
- usually normal or only moderately elevated cholestatic enzymes.

Acute presentation

In some patients with acute presentation of AIH:

- **immunoglobulin G (IgG) levels:** may be within the normal range
- **antinuclear (ANA) and/or smooth muscle antibodies (SMA):** first screening may be negative.

Immunoglobulins

- **high IgG levels:** very distinctive feature
- **IgA and IgM levels: usually normal** (Increased IgA or IgM levels suggest different diseases such as alcoholic steatohepatitis and PBC, respectively).

It is important to underline that the range within which c- globulins and IgGs are considered normal is wide. This may explain why a proportion of patients may show apparently “normal” IgG levels at diagnosis. Many, if not most of these patients have IgG levels in the upper range of normal, and show a marked fall upon initiation of therapy, sometimes even to levels below the normal range .

The level of immunoglobulins is an important and useful marker in monitoring the response to treatment and the achievement of remission.



◀ Diagnosis

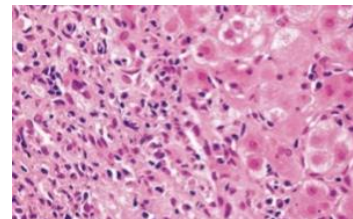
The diagnosis of AIH relies particularly on the presence of:

- 1 **Hypergammaglobulinemia** (A selectively elevated IgG in the absence of IgA and IgM elevation is particularly suggestive of AIH)
- 2 **Autoantibodies:**
Indirect immunofluorescence: the test of choice for all auto-antibodies **except ASLA**.
Immunoassays (ELISA/Western blotting): the tests of choice for the detection of SLA/LP.
 Methods and cut-off values should be reported by the laboratory.
- 3 **Typical or compatible histology.** (Discussed in the [next page](#))

- **Adult patients with AIH and cholestatic lab changes:** should be considered for **MRCP** to recognize sclerosing cholangitis.
- **In severe coagulopathy:** **transjugular** approach can be used (in particular, in acute fulminant onset of the disease).
- The simplified criteria for AIH are user-friendly and a good tool for daily clinical practice but **without a diagnostic “gold standard”** the clinicians must regard any diagnostic score only as an aid to diagnosis of AIH and the criteria should be used alongside clinical judgment.

Histology

- There are **no morphological features that are pathognomonic of AIH**, but some features could be suggestive of AIH, such as:
 - **interface hepatitis:**
 - not disease specific (patients with drug-related, viral or immune-mediated disease may show similar features).
 - **with dense plasma cell-rich lymphoplasmacytic infiltrates, is the typical hallmarks of AIH.**
 - periportal necrosis
 - rosetting of hepatocytes
- **Plasma cells:** typically abundant at the interface and throughout the lobule, but their paucity in the inflammatory infiltrate does not preclude the diagnosis.



Treatment¹

Treatment of AIH should be aimed to obtain:

01

Complete biochemical (ALT/AST & IgG) resolution

02

Histological resolution of the disease

- **In mild asymptomatic older patients with mild necroinflammatory activity on liver biopsy:**

1. is there any benefits of immunosuppressive therapy?
2. Treatment related side effects should be counterbalanced to the risk of subclinical disease.

- **Points to support observation:**

1. Ten-year survival in untreated patients with mild disease was reported to be 67–90% and in an uncontrolled study untreated asymptomatic patient had similar survival to those receiving immunosuppression. Thus, a decision not to treat might be justified, especially if there are relative contraindications to the use of steroids.
2. spontaneous resolution of AIH may occur.

- **Points to support treatment:**

1. As AIH is a lifelong disease, and progressive fibrosis may take many years to become clinically apparent, the observational studies published may have been too short and may have included too few patients in order to demonstrate the benefit of immunosuppressive therapy in milder disease.
2. AIH has a fluctuating, unpredictable disease behaviour and a substantial proportion of asymptomatic patients become symptomatic during the course of their disease follow-up, and progression towards end-stage liver disease with liver cirrhosis.
3. **Treatment options: glucocorticoids** is life-saving in autoimmune hepatitis, particularly **during exacerbations** of active and symptomatic disease:
 - a. **prednisolone:** 30 mg is given daily for at least 2 weeks, followed by a slow reduction and then a maintenance dose of 10–15 mg daily.
 - b. **Azathioprine** should be added, 1–2 mg/kg daily, as a steroid-sparing agent and in some patients as sole long-term maintenance therapy. Levels of thiopurine methyltransferase should be obtained.
 - c. **Mycophenolate, ciclosporin and tacrolimus** have been used in resistant cases.
 - d. **Budesonide:** 3 mg × 2 or 3 daily has fewer side-effects than prednisolone and is now the preferred treatment.

Definition

a chronic cholestatic liver and biliary tract disease, defined as the **presence of beading and stricture formation of the intra and/or extrahepatic bile ducts that cannot be ascribed to another cause** (The cause of PSC is unknown), thus differentiating PSC from secondary sclerosing cholangitis.

General information



Association: Many, if not most cases of PSC are **associated with IBD**, particularly **ulcerative colitis**.



Prevalence: in UC has been estimated to be ~5%. PSC was also **more common in young men** and those with pancolitis.

Signs and symptoms

Asymptomatic

01

- A large number of patients present without symptoms and come to attention simply by a finding of persistently abnormal liver tests.
- PSC may be asymptomatic for long periods but **may also have an aggressive course**, leading to:
 - Recurrent biliary tract obstruction
 - Recurrent episodes of cholangitis
 - Cirrhosis/ESLD

Symptomatic

02

1. **Fatigue:** When symptoms occur, **fatigue** maybe the most commonly noted finding.
2. **pruritus:** Sudden onset of pruritus should signal the possibility of **obstruction of the biliary tree**.
3. other patients may experience **chronic right upper quadrant discomfort**.
4. **Other Common symptoms:** intermittent jaundice, weight loss.

Diagnostic criteria

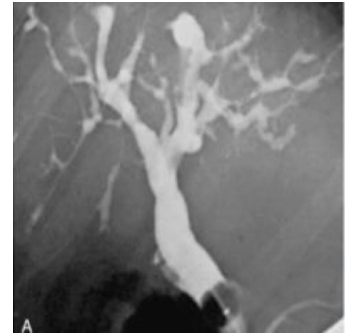
The generally accepted diagnostic criteria are:

- generalised beading and stenosis of the biliary system on cholangiography
- absence of choledocholithiasis (or history of bile duct surgery)
- exclusion of bile duct cancer,

Investigations

1 Chronic cholestatic **liver test abnormalities**, in particular elevations of serum ALP level

2 **Cholangiographic¹ (MRCP or ERCP):** evidence of multifocal strictures and saccular dilatation of the intrahepatic and extrahepatic bile ducts, which may lead to a **“beaded” appearance**



3 **Liver biopsy:** if performed:
1- characteristic **“onion skin”** fibrosis, which is almost pathognomonic for the disease, is seen infrequently²
2- Small duct PSC makes up 5% of cases

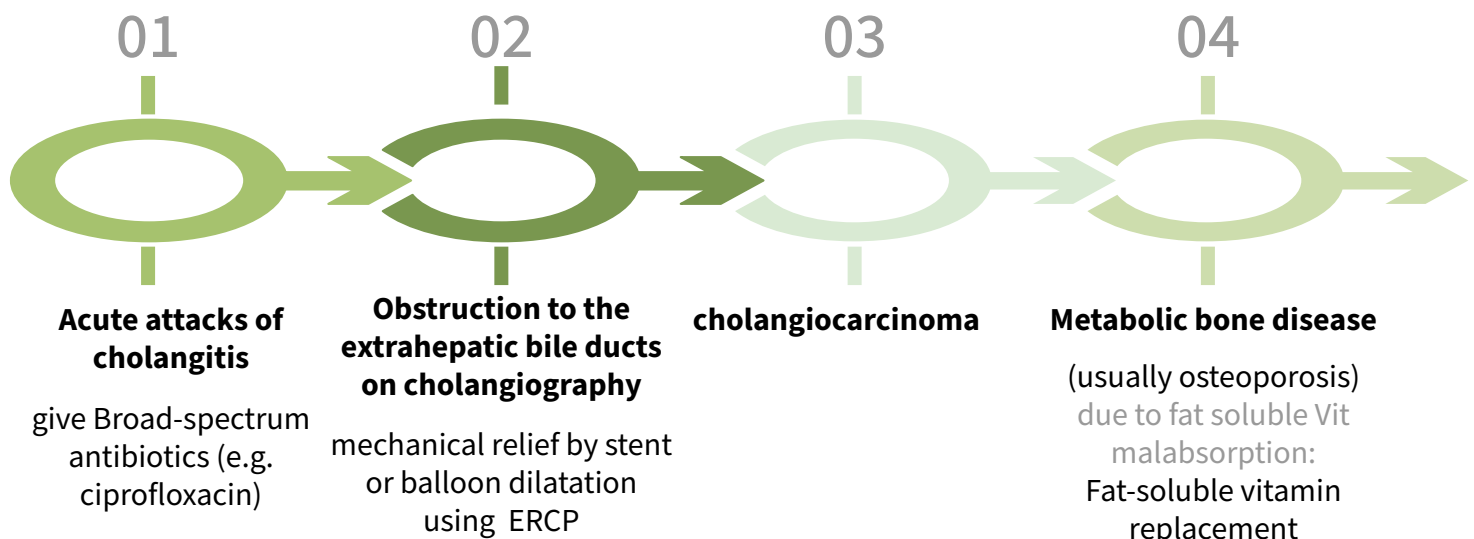
4 **GGT:** will be elevated and the aminotransferases are often times only modestly elevated.

5 **Bilirubin and albumin levels:** often normal at the time of diagnosis.

Treatment

- At this time, there is **no established medical treatment for patients with PSC.**
- We treat complications of the disease:
 - MRCP & CA19-9 annually
 - Annual colonoscopy if known to have UC

complications



1: The key and usually diagnostic investigation

2: Later, fibrosis spreads, progressing inevitably to biliary cirrhosis; obliterative cholangitis leads to the so-called 'vanishing bile duct syndrome'.

Primary biliary cirrhosis

Definition

PBC is a chronic cholestatic disease with a progressive course characterised by a **granulomatous inflammation of the portal tracts**, leading to progressive damage and eventually loss of the small and middle-sized bile ducts. In turn, leads to fibrosis and cirrhosis of the liver.

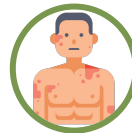
◀ Epidemiology & etiology

- **Strongly associated with:** the presence of **antimitochondrial antibodies (AMA)**, which are **diagnostic**.
- predominantly affects **women** aged 30 and over (F:M = 9:1). also more common among **cigarette smokers**.
- **Etiology**¹: thought to be due to a combination of genetic predisposition (**HLA-DR8**) and environmental triggers.

◀ Clinical manifestations²



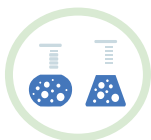Fatigue (the most common symptom).



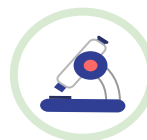Pruritus (a more specific symptom of PBC).

◀ Diagnosis

- The diagnosis of PBC should be suspected in the setting of chronic cholestasis after exclusion of other causes of liver disease, based on:



cholestatic serum liver tests (largely confirmed with tests for AMA)



Liver biopsy

can be used to further substantiate the diagnosis if needed.

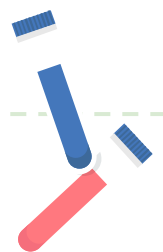
◀ 1st: Serum findings

1 LFTs

Most patients with PBC have abnormal liver tests including:

- **ALP: elevated** → The degree of elevation in ALP is strongly related to the severity of ductopenia and inflammation
- **aminotransferases activity: mild elevations**
- **immunoglobulins: increased** (mainly immunoglobulin M [**IgM**]).

The increase in aminotransferase activity and IgG levels reflects mainly the degree of periportal and lobular necrosis and inflammation.

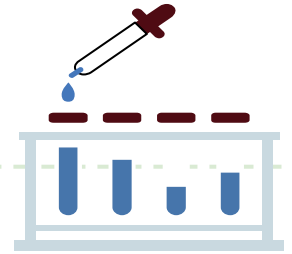


1: Immune mechanisms are clearly involved. The condition is closely associated with other autoimmune non-hepatic diseases, such as thyroid disease, connective tissue diseases, particularly the sicca syndrome, systemic sclerosis, coeliac disease.

2: Hypercholesterolaemia is common and worsens as disease progresses. there may be right upper abdominal discomfort. Bone pain or fractures result from osteomalacia (fat-soluble vitamin malabsorption) or osteoporosis (hepatic osteodystrophy).

3: when it is absent, the diagnosis should not be made without obtaining histological evidence and considering cholangiography (typically, MRCP)

2 Autoantibodies



- **AMA17:** is found in nearly 95% of patients with PBC.
- **ANA18 & ASMA:** found in nearly 50% of patients with PBC.
- In approximately 5%-10% of the patients, AMA antibodies are Autoantibodies absent or present only in low titer (1/80), when immunofluorescent techniques are used³

2nd: Histology

PBC is characterized by:

- **chronic, nonsuppurative cholangitis:** mainly affects interlobular and septal bile ducts.
- **florid duct lesion:** focal lesions show intense inflammatory changes and necrosis around bile ducts.
- Bile duct paucity or ductopenia
- The size of the liver biopsy specimen is important. The probability of observing cholangitis and bile duct destruction increases with the number of portal tracts because of the typical patchy distribution of the lesions. **At least 10-15 portal tracts should be present.**

→ The diagnosis of PBC can be established when two of the following three criteria are met:



- 01 Biochemical evidence of cholestasis based mainly on alkaline phosphatase elevation.
- 02 Presence of AMA.
- 03 Histologic evidence of nonsuppurative destructive cholangitis and destruction of interlobular bile ducts .

◀ Treatment

- **hydrophilic bile acid ursodeoxycholic acid (UDCA)**¹ in a dose of 13-15 mg/kg/day is the only therapy for PBC approved by the U.S. Food and Drug Administration.
 - The drug is initiated gradually and generally given in two divided doses.
- **Pruritus** is the main symptom requiring treatment. First-line treatment is **colestyramine** (which binds with potential pruritogens in the intestine and increasing their excretion). Colestyramine may bind other drugs in the gut (most obviously UDCA) and adequate spacing should be used between drugs.



1: improves bile flow, replaces toxic hydrophobic bile acids in the bile acid pool, and reduces apoptosis of the biliary epithelium.

Alcoholic hepatitis

	Alcoholic hepatitis generally occurs after years of heavy drinking and may coexist with cirrhosis.
Clinical features	The cardinal sign of alcoholic hepatitis is a rapid onset of jaundice . Other symptoms and signs are nausea, anorexia, right upper quadrant pain, encephalopathy, fever, ascites and tender hepatomegaly.
Investigations	<ul style="list-style-type: none"> • CBC:leukocytosis, elevated MCV and often thrombocytopenia • Electrolytes are frequently abnormal with hyponatraemia. • Liver biochemistry shows elevated AST and ALT with a disproportionate rise in AST (usually AST : ALT ratio >2), the absolute values for AST and ALT usually <500 IU/L; higher values suggest acute hepatitis due to another cause. The bilirubin may be markedly elevated, 300–500 μ mol/L, reflecting the severity of the illness. Serum albumin is low and prothrombin time prolonged. • Diagnosis is usually made on the basis of clinical presentation, neutrophilia, elevated INR and liver biochemistry profile.
Management	<ul style="list-style-type: none"> • Patients with severe alcoholic hepatitis require supportive treatment and adequate nutritional intake must be maintained, if necessary, via a nasogastric tube. • Corticosteroids (40 mg per day for 4 weeks) reduce the inflammatory process. Steroids are contraindicated if renal failure, infection or bleeding is present. • Pentoxifylline, a phosphodiesterase inhibitor with many effects also reduces mortality

Paracetamol poisoning

Pathophysiology	90% of paracetamol ingested undergoes conjugation before being excreted in the urine. A small fraction is catalysed by the cytochrome P450 to form a toxic metabolite, N-acetyl-p-benzoquinoneimine (NAPQI). In normal circumstances, detoxification of NAPQI occurs through conjugation with reduced glutathione to form non-toxic conjugates that are then excreted in the urine. Following paracetamol overdose, stores of glutathione are depleted, allowing a build up of NAPQI, which binds covalently with sulphhydryl groups on liver cell membranes leading to hepatic necrosis.
Clinical features	Clinical features of paracetamol poisoning are often non-specific and may include nausea, vomiting and abdominal pain . Conscious level is preserved unless another drug has been co-ingested. The predominant danger of a paracetamol overdose is liver failure, which usually only becomes apparent 72–96 hours after the initial ingestion. Acute kidney injury may also occur, with or without concomitant liver failure, and is usually apparent 3–5 days after ingestion.
Management	<ul style="list-style-type: none"> • Intravenous N-acetylcysteine (NAC) • The decision as to whether or not NAC should be administered depends on the quantity of paracetamol ingested, the time interval since ingestion, and whether the overdose was a single acute ingestion (all tablets ingested in a period of less than 1 hour), or staggered ingestion (tablets ingested over a period of greater than 1 hour)

Wilson's disease	
Overview	This is a rare, recessively inherited disorder. Mutations in the ATP7B gene on chromosome 13 result in decreased secretion of copper into the biliary system and reduced incorporation of copper into procaeruloplasmin, the precursor of caeruloplasmin.
Clinical features result of copper accumulation	<ul style="list-style-type: none"> • Liver: Fulminant hepatic failure and cirrhosis • Basal ganglia: Parkinsonism and eventually dementia • Cornea: greenish-brown rings called Kayser–Fleischer rings
Diagnosis	<ul style="list-style-type: none"> • Low total serum copper and caeruloplasmin • Increased 24-hour urinary copper excretion • Increased copper in a liver biopsy specimen
Treatment	<ul style="list-style-type: none"> • Penicillamine or trientine (to chelate copper) or zinc (reduces copper absorption) • Liver transplantation is offered to those with end-stage liver disease or fulminant hepatic failure • First-degree relatives are screened and homozygotes should be treated.

◀ Vascular diseases that could cause liver injury

- Portal vein thrombosis
- Hepatic artery diseases (aneurysm, thrombosis)
- Sinusoidal obstruction syndrome
- Radiation-induced liver disease
- Peliosis hepatis and sinusoidal dilatation
- Budd-Chiari syndrome
- Congenital vascular malformations

Budd-Chiari syndrome	
Overview	Occlusion of the hepatic vein obstructs venous outflow from the liver and the resulting congestion within the liver lead to hypoxic damage and necrosis of hepatocytes.
Aetiology	<p>Clinical manifestations depend on the extent and rapidity of the hepatic vein occlusion and whether a venous collateral circulation has developed.</p> <ul style="list-style-type: none"> • RUQ pain, hepatomegaly, jaundice and ascites are typical features • Acute disease may also present with fulminant hepatic failure. Cirrhosis may develop in the chronically congested liver, resulting in portal hypertension and the development of varices and other features of portal hypertension.
Investigations	<ul style="list-style-type: none"> • Doppler US is the initial investigation of choice. This will show abnormal flow in the major hepatic veins or inferior vena cava, thickening, tortuosity, and dilatation of the walls of the hepatic veins. • If the US is normal but clinical suspicion is high, CT or MRI may demonstrate abnormalities. • Liver biopsy is often unnecessary in making a diagnosis but it will show centrilobular congestion, necrosis and haemorrhage.
Treatment	<p>The goals of therapy are three-fold:</p> <ul style="list-style-type: none"> • To restore hepatic venous drainage. This is usually only feasible in the acute state and it entails thrombolysis, angioplasty and stent insertion or TIPS. • Treatment of complications related to ascites and portal hypertension. • Detection of the underlying hypercoagulable disorder and prevention of further clot formation.

◀ Non-alcoholic steatohepatitis (Discussed in another lecture)

Case study 1:

- ❖ A 24-year-old woman presents with acute onset of right upper quadrant pain, and increased abdominal girth. She has no known past medical history. She has no risk factors for liver disease. Family history is unremarkable. Her only medication is a birth control pill. Exam reveals **tender hepatomegaly** and **obvious ascites**.
Labs: mildly increased bilirubin and alkaline phosphatase only.
Imaging studies: hepatomegaly (especially the caudate lobe) and ascites.

- **What is your diagnosis?**
 - **Acute Budd-Chiari syndrome** (in the presence of a sudden onset of ascites, suggests venous outflow obstruction as the cause (Budd-Chiari syndrome))

Case study 2:

- ❖ You see in consultation a 43-year-old man because of **jaundice**. He has been drinking 1 pint a day (sometimes more) of whiskey for the past 4 months. He denies other risk factors for liver disease.
Examination: BP 110/80, pulse 110; RR 16, temperature 37°C. He is jaundiced, has multiple spider telangiectasias, and parotid gland swelling, but no muscle wasting.
Abdominal examination: reveals a liver 4 finger breadths below right costal margin, a palpable spleen tip, but no shifting dullness.

Test	Value	comment
Bilirubin	150 mmol/l	Mostly direct
AST	212 U/L	
ALT	63 U/L	normal: 0-35 U/L
ALP	140 U/L	normal: 36-92 U/L
INR	1.5	
Ferritin	480 ng/mL	

- **What is the pattern?**
 - **Direct hyperbilirubinemia with hepatocellular pattern**
- **Do you need to do work up?**
 - **Viral hepatitis, Fibroscan**

Case study 3:

- ❖ A 35-year-old woman is referred to you for elevated liver enzymes. She has mild tenderness over her right upper quadrant. She is otherwise healthy, with the exception of being treated intermittently with nitrofurantoin for recurrent urinary tract infections. **Viral serologies against hepatitis A, B, C, and E are all negative.**
ultrasound: a heterogeneous echotexture of a normal-sized liver.
- ❖ Her albumin and INR are at normal levels. The rest of her labs are shown below.

- **What is the pattern?**
 - **Hepatocellular** (similar to case 2, AST and ALT are significantly raised) **with normal bilirubin**
- **What should you do next for the diagnosis or treatment of this patient?**
This pattern is consistent with an **autoimmune hepatitis-like presentation** induced by nitrofurantoin. Simply stopping the offending medication will usually result in normalization of her liver enzyme values. Of note, an ANA that is positive at 1:80 dilution is fairly non-specific, and may be seen in 30% of adults, especially women, without disease

Test	Value	comment
Bilirubin	18 mmol/l	
AST	205 U/L	
ALT	255 U/L	normal: 0-35 U/L
ALP	121 U/L	normal: 36-92 U/L
ANA	1:80	+ve
IgG	Elevated	

Case study 4:

- ❖ A 45-year-old woman presents for evaluation of elevated liver tests. She has a past medical history of diabetes, & hypertension. **She does not drink alcohol** or use tobacco. Her medical regimen consists of insulin, metformin, & lisinopril.
physical exam: BMI is 39, BP 160/98.
Abdominal exam: an obese abdomen without hepatosplenomegaly, masses, hernias, or ascites.
Abdominal ultrasound: mild echogenic liver of 14 cm with normal spleen size and no focal masses or ascites
liver biopsy: shows 50% macrovesicular steatosis, interface hepatitis comprised of lymphocytes, prominent plasma cells, and periportal fibrosis Metavir stage 2.
- **AMA negative, Hepatitis A IgM negative, HbsAg negative, HCV antibody negative,** the rest of her labs are shown below.

- **What is the pattern?**
 - **Hepatocellular with normal bilirubin**
- **What is the diagnosis?**
 - **AIH & NASH** (NASH is strongly associated with obesity, dyslipidemia, insulin resistance, type 2 diabetes mellitus and hypertension, and so may be considered to be the hepatic manifestation of the 'metabolic syndrome')

Test	Value	Test	Value
Bilirubin	Normal	ANA	1:640
AST	330 U/L	ASMA	1:160
ALT	380 U/L	IgG	Elevated
ALP	80 U/L		

Case study 5:

- ❖ A 53-year-old woman presents for evaluation of elevated liver tests. She has a past medical history of diabetes mellitus treated with insulin and hyperlipidemia treated with atorvastatin, 20 mg daily. **She does not drink alcohol** and does not use tobacco.
- ❖ **PE:** BMI is 32, weight is 90 kg, BP is 130/80, heart rate is 88.
- ❖ **abdominal exam:** no hepatosplenomegaly, ascites, masses, or hernias.
- ❖ **US:** normal
- ❖ ASMA is negative, IgG, is mildly elevated Hepatitis C antibody negative, Hepatitis B surface antigen negative, Hepatitis A IgM negative, The rest of her labs are shown below.

Test	Value
Bilirubin	Normal
AST	90 U/L
ALT	221 U/L
ALP	220 U/L
ANA	1:160

- **What is the pattern?**
 - Hepatocellular (may be mixed with normal bilirubin)
- **What is the most appropriate next step in her management?**
 - Liver biopsy +/- MRCP

Up to 20% of patients with nonalcoholic fatty liver disease may have positive autoantibodies, and **autoantibodies alone should not be used to establish the diagnosis of autoimmune hepatitis.**

Case study 6:

- ❖ An 66-year-old man is found collapsed at a home. He is found to be in asystole. After CPR and other emergency treatments, a pulse is restored and she is taken to the hospital. His only known medications are furosemide, and insulin.
On admission: LFTs are normal.
Twenty-four hours later: her **AST is 12,500 U/L and ALT is 7,450 U/L.**

- **What is the pattern?**
 - Hepatocellular
- **What is the diagnosis?**
 - Shocked liver¹
- **Treatment ?**
 - Supportive

1- Ischemic hepatitis, also known as ischemic hepatopathy or shock liver, is a condition defined as an acute liver injury caused by insufficient blood flow (and consequently insufficient oxygen delivery) to the liver. The decreased blood flow (perfusion) to the liver is usually due to shock or low blood pressure.

Case study 7:

- ❖ A 65-year-old woman presents with malaise of 2 weeks and is found to have elevated ALT/AST. Her past medical history is significant for hypertension, hypothyroidism, and osteoarthritis.

medications: lisinopril 10 mg daily, levothyroxine 100 micrograms daily, diclofenac 75 mg daily, and acetaminophen 500 mg, twice a day.

PE: her sclera are icteric, abdomen is soft with mild right upper quadrant tenderness, no hepatosplenomegaly, masses, or ascites.

Labs: AST 350 U/L, ALT 480 U/L Total bilirubin 45 mmol/L, Alkaline phosphatase 180 U/L (normal: 36-92 U/L) • ANA 1:640 (positive: titer of $\geq 1:160$), ASMA -ve & IgG normal • Hepatitis C antibody negative, Hepatitis B surface antigen negative, Hepatitis A IgM negative

- **What is the pattern?**

- Hepatocellular

- **What is the diagnosis?**

- Drug induced liver injury (DILI).

Diclofenac is the most common NSAID associated with DILI. The most immediate intervention is to **stop the diclofenac** and monitor the patient for resolution of the injury. Half the cases of diclofenac hepatotoxicity present with an autoimmune phenotype characterized by the presence of serum autoantibodies with or without typical histologic features on liver biopsy. Liver biopsy and abdominal ultrasound may be indicated and provide important information if stopping diclofenac does not normalize the LFTs. Steroids can also be considered if there is no improvement after discontinuation of the offending drug.

Case study 8:

- A 33-year-old woman with acute liver failure. The patient has no prior history of liver disease and was well until 1 month ago. There is no family history of liver disease.

PE: jaundice and ascites; Grade 2 encephalopathy is present.

Labs: ALT 500 U/L AST 1,220 U/L, Total bilirubin 50 mmol/l that is mostly direct Alkaline phosphatase 40 U/L • INR 1.7 Hb 9 with evidence of hemolysis but Coombs test negative Ceruloplasmin 24 mg/dL (normal: 20-40 mg/dL) Ferritin 1,200 ng/mL (normal: 15-200 ng/mL)

- **What is the pattern?**

- Hepatocellular

- **What is the diagnosis?**

This is a classic presentation for **acute fulminant Wilson's disease**. The constellation of a Coombs- negative hemolytic anemia, acute liver failure and the age of the patient all point to this diagnosis. A positive slit lamp exam would confirm the diagnosis of Wilson disease, however, if negative does not rule out the disease. **The ceruloplasmin is falsely elevated into the low normal range due to an acute phase response.** The serum iron studies are increased because of release of iron from the liver. Liver biopsy may demonstrate increased copper concentration because of the relatively high serum bilirubin level.

◀ Case study 9:

- ❖ A 53-year-old woman underwent hysterectomy and oophorectomy for stage 2 ovarian cancer which was complicated by a colonic perforation with intra-abdominal infection and abscess requiring drainage and broad-spectrum antibiotics. She was treated initially piperacillin-tazobactam and vancomycin for 2 weeks and then amoxicillin clavulanate for an additional 2 weeks. She was discharged home following completion of the antibiotics and is readmitted for mild jaundice and pruritus 1 week later. A recent abdominal/pelvic CT scan shows normal appearing liver without biliary duct dilatation and improved intra-abdominal abscess.

Time	AST (U/L)	ALT (U/L)	ALKP (U/L)	Total bilirubin (mg/dl)
28 days	30	40	119	0.9
14 days	40	50	199	0.8
7 days	55	65	243	1.9
3 days	68	74	398	3.3
today	70	83	488	3.9

- **What is the pattern?**
 - Cholestatic with direct hyperbilirubinemia
- **What is the diagnosis?**

Amoxicillin/clavulanate may be associated with hepatotoxicity, typically with a cholestatic (ALP predominant increase in liver enzymes). A mixed hepatocellular and cholestatic pattern of liver injury may also be observed. The onset of drug-induced liver injury from amoxicillin/clavulanate may be as little as a few days to as long as 8 weeks post-exposure. Treatment for antibiotic associated drug-induced liver injury is withdrawal of the drug and supportive care.

◀ Case study 10:

- A 58 year-old **overweight** Hispanic man with **diabetes** has been referred to you for evaluation of persistently mildly elevated liver enzymes with his ALT/AST ranging between 60 and 140 over the last year. As part of the evaluation, you are able to rule out viral, autoimmune, and metabolic liver diseases. **He drinks alcohol occasionally.** He is not on medications. US showed evidence of fatty liver. **Normal liver function tests & CBC**

- **What is the most likely diagnosis?**
 - **NASH or ASH**
- **What is the next step?**
 - Fibroscan Liver biopsy reveals moderate steatosis, hepatocellular ballooning, Mallory bodies, and both lobular and portal-septal inflammation, consistent with steatohepatitis.

◀ Case study 11:

- ❖ You are asked to see a 14-year-old boy who suddenly developed itching and jaundice. He started taking **minocycline for acne** about 6 weeks ago. This is now stopped. Serum albumin is normal.

- **What is the pattern?**
 - **Cholestatic with direct hyperbilirubinemia**
- **What is the next step?**
 - **US:** The liver and biliary tree appeared normal on ultrasound.
- **What should you tell the parents about their child?**
 - Pure cholestatic drug reactions almost always resolve within 6 weeks of stopping the medication. We just need to monitor.

Test	Value
Bilirubin	90 mmol/l
AST	13 U/L
ALT	15 U/L
ALP	620 U/L
ANA	Normal

◀ Case study 12:

- ❖ You are asked to see a 45-year-old woman who developed elevations in liver transaminases after initiating a statin. Over the past 3 months:
- ❖ AST has been 65 U/L, 75 U/L, and 85 U/L (normal: 0-35 U/L)
- ❖ ALT has been 86 U/L, 88 U/L, and 95 U/L (normal: 0-35 U/L).
- ❖ Alkaline phosphatase and total bilirubin were normal.
- ❖ The primary care physician was concerned that the liver transaminases were rising and so he **stopped the statin. The AST is now 45 U/L and ALT 50 U/L.**

- **What would you recommend?**

Adaptation phenomena vs True hepatotoxicity:

- **Adaptation phenomena :** In these patients the liver transaminases elevate to values **under 3 times the ULN** and then remain stable for variable periods of time before declining back to the normal range. This process is referred to as adaptation and is commonly seen with many medications.
- **True hepatotoxicity:** associated with **progressive stepwise elevations** in liver transaminases to values **greater than 3 times the upper limit of normal**. When this occurs, the risk of liver toxicity is significant, medications must be stopped and not restarted.

Although statins can cause hepatotoxicity this is relatively uncommon. However, it is not unusual for statins to cause mild elevations in liver transaminases when first initiated. **In this patient, the mild fluctuations in AST and ALT are not significant step-wise elevations.**

Approach to liver enzymes

Hepatocellular causes	VS	Cholestatic causes: isolated ALP and rule of GGT	VS	Mixed
Hepatocellular causes	Cholestatic causes			
	Extrahepatic = Obstructive	Intrahepatic = Non-obstructive		
<ul style="list-style-type: none"> - viral hepatitis - Alcohol - NASH - AIH/celiac - Toxins - Vascular injury - Metabolic disease - Drugs - Passed stone - Pregnancy related 	<ul style="list-style-type: none"> - Biliary stone - Stricture: <ol style="list-style-type: none"> 1. Malignant: Periampullary tumors 2. PSC, AIDs cholangiopathy 	<ul style="list-style-type: none"> - PBC - PSC: small duct - Cystic fibrosis - Sepsis, TPN, Drugs - Infiltrative: <ul style="list-style-type: none"> - Granulomatous diseases such as TB, sarcoidosis, lymphoma - Amyloidosis - Intrahepatic cholestasis of pregnancy 		

DDx of jaundice

Direct Hyperbilirubinemia (Hepatic, Post-hepatic)	Indirect Hyperbilirubinemia (pre-hepatic):	Pseudo-Jaundice due to Carotenemia
- Hepatobiliary disease	<ul style="list-style-type: none"> - Hemolytic anemia - Hematoma - Massive t/f - Rifampin - Gilbert 	In which case the sclera is intact.

HBV	Mode of transmission is mainly through Vertical transmission	
	clinical presentation of Acute	clinical presentation of Chronic
	<ul style="list-style-type: none"> - <u>serum sickness-like prodrome</u> - later on liver disease manifestations (jaundice) appear <p>Clinical symptoms and <u>jaundice disappear after one to three months.</u></p>	<ul style="list-style-type: none"> - Asymptomatic - Fatigue - Symptoms and signs of CLD - Extrahepatic Manifestations
Diagnosis/investigations : HBsAg / tests for co-infections / HBcAg / HBsAg		
HCV	Modes of transmission of HCV can be divided into : Percutaneous (blood transfusion and needle stick inoculation). + Non-percutaneous (sexual contact and perinatal exposure).	
	Clinical presentation : mostly asymptomatic , if symptomatic : fatigue , arthralgia , arthritis , raynaud phenomenon , vasculitis , nephropathy , peripheral neuropathy	
	Diagnosis/investigations : Anti-HCV antibody / HCV RNA testing / HCV genotyping	

Lecture Quiz

Q1: You see a 54-year-old woman, referred to accident and emergency through her GP, with a week's history of jaundice and right upper quadrant abdominal pain. Associated symptoms include dark urine and pale stools. There is no history of weight loss and the patient does not consume alcohol. Her liver function tests reveal a bilirubin of 40 $\mu\text{mol/L}$, ALT of 40 iu/L , AST 50 iu/L and ALP of 350 iu/L . The most likely diagnosis is:

- A- gallstones
- B- viral hepatitis
- C- alcoholic hepatitis
- D- carcinoma of the head of pancreas
- E- autoimmune hepatitis

Q2: A 46-year-old woman presents to your clinic with a week's history of jaundice. Her past medical history includes long standing atrial fibrillation and hypertension. Physical examination reveals hepatomegaly. You assess her liver function which shows a bilirubin of 41 iu/L , AST 111 iu/L , ALT 55 iu/L and ALP 98 iu/L . There is no history of travel. You have a look at the patient's medication history. Which of the following drugs below is likely to have caused the derangement in the patient's liver function?

- A- aspirin
- B- ramorol
- C- amiodarone
- D- bendroflumethiazide
- E- amlodipine

Q3: You see a 52-year-old woman with rheumatoid arthritis in your clinic. She was referred by her GP after her ALP levels were found to be abnormally high at 300 iu/L . In addition, she was also found to be serum anti-mitochondrial antibody (AMA) positive. The most likely diagnosis is:

- A- Primary biliary cirrhosis
- B- Wilson's disease
- C- Hereditary haemochromatosis
- D- Primary sclerosing cholangitis
- E- Alcoholic liver disease

Q4: A 68-year-old man presents to his GP with signs of drastic weight loss. He is known to have PSC. The GP suspects an underlying malignancy. Which of the following tumours would a patient with primary sclerosing cholangitis be more at risk of developing?

- A- Hepatocellular carcinoma
- B- Cholangiocarcinoma
- C- Hepatic fibroma
- D- Hepatic haemangioma
- E- Pancreatic carcinoma

Q5: You see a 56-year-old woman who presents with a two-month history of jaundice. Associated symptoms include lethargy and polyarthralgia. Her LFTs reveal a bilirubin of 46 iu/L , AST 200, ALT 175, ALP 104. On examination, the patient is jaundiced and has finger clubbing. There are several spider naevi on the front and back of the trunk. Her abdomen is soft and there is a smooth hepatomegaly. Prior to her onset of symptoms, the patient has been fit and well. Viral serology is normal and anti-soluble liver antigen (SLA) is detected. You decide to start this patient on treatment. The most appropriate treatment is:

- A- Liver transplantation
- B- Methotrexate
- C- Prednisolone
- D- Cyclosporin
- E- Antivirals

Our Team

This work was originally done by **438 Medicine team.**

Edited by **439 Medicine team:**

Team Leaders

- *Shaden Alobaid*
- *Ghada Alabdi*

- *Hamad Almousa*
- *Naif Alsulais*

Member : Banan Alqady

Note taker : Mohammed Alquhidan

Edited for the second time by **442 Medicine team:**

Team Leaders

- *Mohammed Alrashoud*
- *Maha Alzahrani*
- *Shatha Alshabani*

- *Mohammed Alzeer*
- ***Refal Alamry***
- *Arwa Alghamdi*

Members:

- *Hoor Aloraini*
- *Wafa Alqahtani*



Medicine.med442@gmail.com

Special thanks to Mohammed Alorayidh and Arwa Alghamdi for the amazing first page theme!