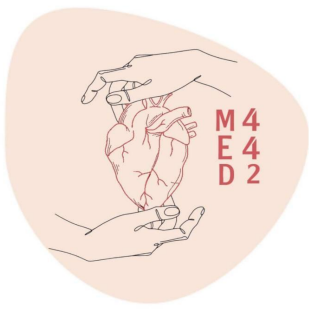

Radiology of Urinary System Diseases

Lecture 8

Objectives

- To know the principle disease entities of the urinary system organs and how they look in imaging.
- To correlate the clinical manifestations with radiological images.

Color Index:

Main text Males slides Female slides Dr's notes Important Golden note Extra

Team Leaders:



Rahaf Almotairi



Mayssam Aljaloud



Sultan Alshehri

Done by:



Hend Almogary



Mishal Alsuwayegh

Editing File

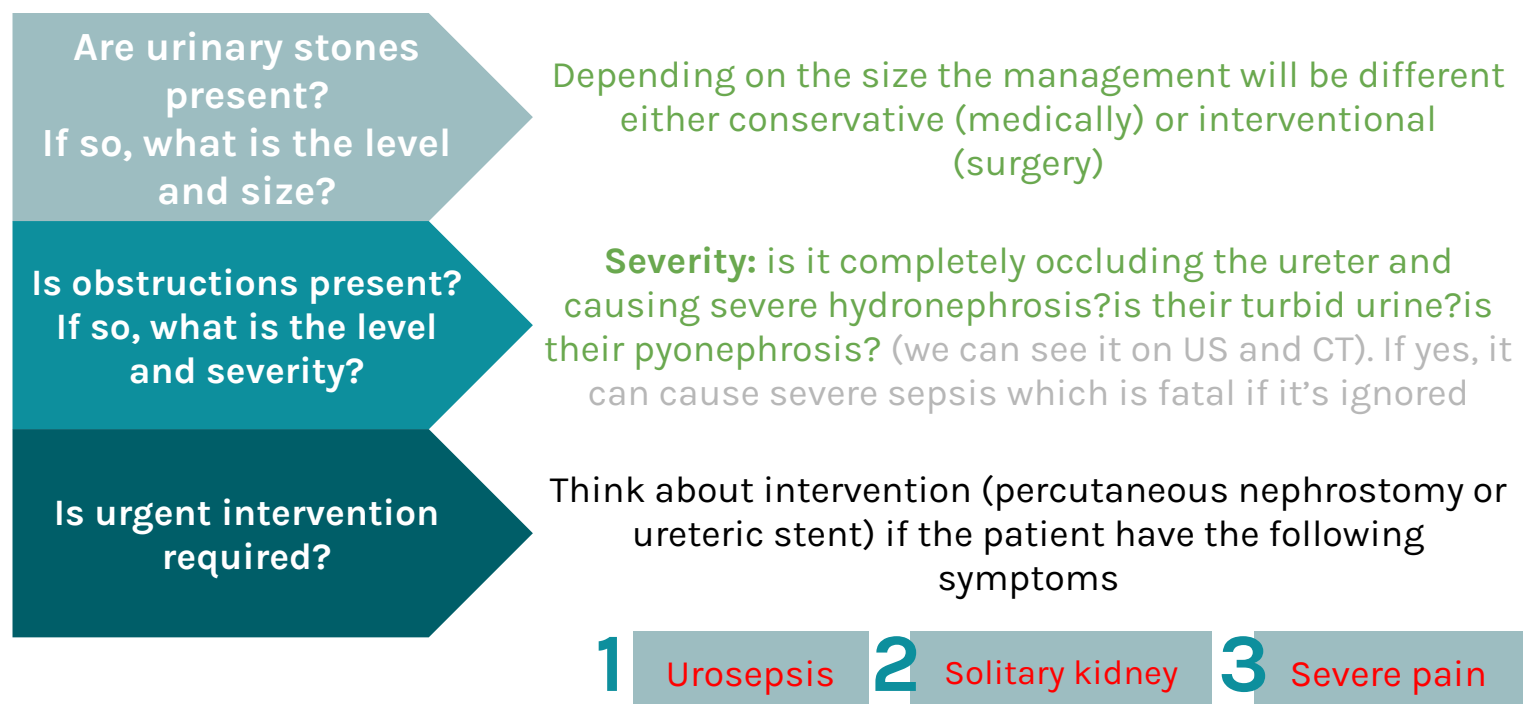
» Categories

1. Renal colic (KUB for ER then CT without contrast)
2. Infections (US then CT)
3. Urosepsis (CT with contrast)
4. Masses (US then CT with contrast)
5. Renal failure (different causes Have different imaging modalities)
6. Trauma (CT with contrast)

» Renal colic

- Caused by urinary stones (renal calculi) calcium oxalate stones
- Most urinary calculi are calcified
- **Classic presentation:** (sudden onset of severe flank pain radiating inferiorly and anteriorly to the groin, +/- nausea and vomiting colicky type, radiates to the groin area and to the penis in men)
- Diagnosis often made clinically
- **Imaging:** to confirm and evaluate calculi

» Questions to ask

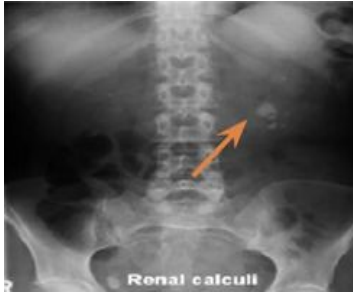

Renal Calculus

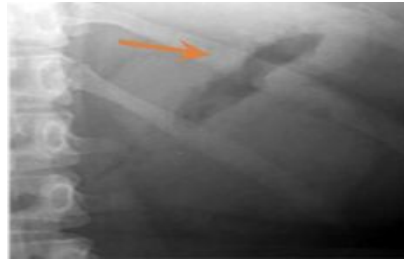
Best initial test: Xray (+ to monitor the pathway of the stones)

Best confirmatory test: CT scan

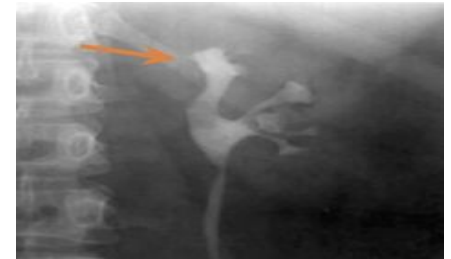» Renal Calculi (KUB, IVP "x ray with contrast")



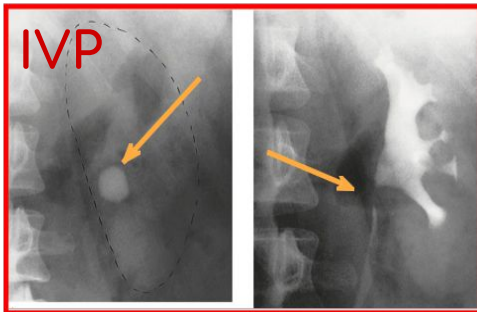
- **KUB:** to assess total stone burden, size, shape, location.
- Often US or CT is required in conjunction. **multiple renal stones** on left pelviureteric junction



Radiolucent uric acid stones are not seen. Here you only see the bowel gas (air=black)



Radiolucent uric acid stones
Here in the **IVP** we see **filling defect** due to mild obstruction and dilation of the superior calyces (arrow) causing mild hydronephrosis

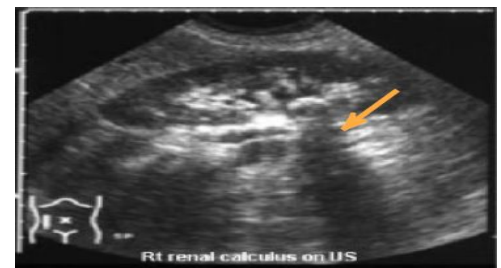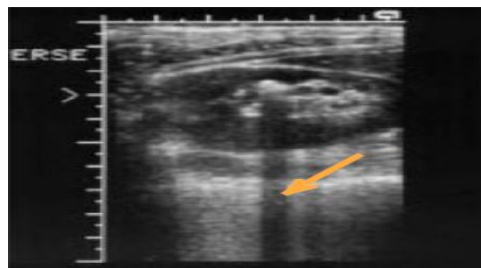
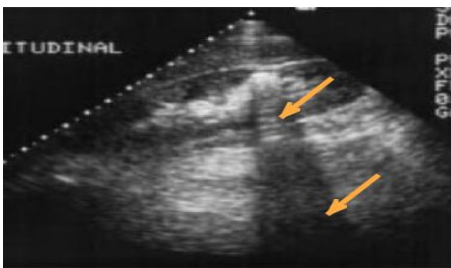


A) rounded calcification is seen overlying the left kidney in the anteroposterior plain film.

B) Post contrast film in the same patient. As the contrast medium and the calculus have the same radiographic density, the calculus is hidden by the contrast medium

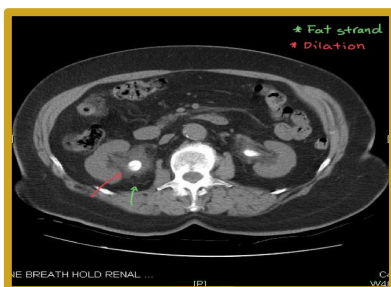
Calcification has the same density of contrast so it is **important** to start study with non contrast first

» Renal Calculus (US)

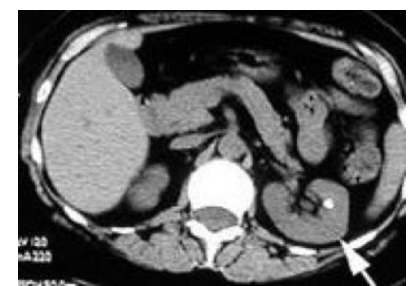

Renal stones in US (hyperechoic structure) with a **shadow behind**.
The shadow is important because we can't say its stone without the shadow.
NO signs of obstruction = No dilation

» Renal Calculus (CT)



Bilateral pelvic ureteral obstruction caused by hyperdense structure (stone) with dilatation of pelvicalyceal system and fat strands around caused by inflammation



Non obstructive renal stone with no dilatation of renal calyceal system "pelvicalyceal"

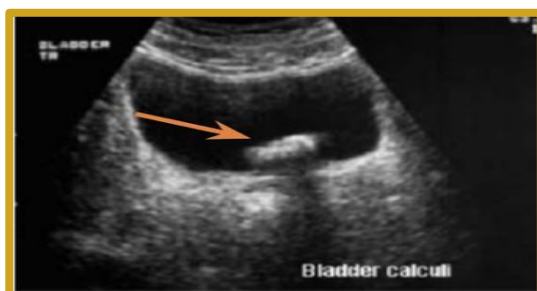» Hydronephrosis

Causes of dilated calyces= hydronephrosis VERY Important!

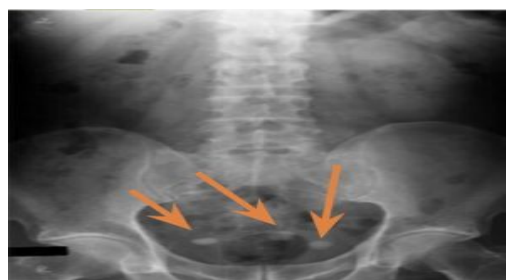Due to obstruction, with dilatation down to a specific point of hold-up

Within the lumen =ducts	<ul style="list-style-type: none"> • Calculus (NOT all cases of stones cause hydronephrosis, some are just causing obstruction of the collecting system) • Blood clot • Sloughed papilla
Within the wall of the collecting system =attached to the wall	<ul style="list-style-type: none"> • Intrinsic pelviureteric junction obstruction • Transitional cell tumour • Infective stricture (e.g. tuberculosis or schistosomiasis)
Extrinsic compression =from outside	<ul style="list-style-type: none"> • Retroperitoneal fibrosis • Pelvic tumour (e.g. cervical, ovarian or rectal carcinoma) • Aberrant renal artery or retrocaval ureter
Due to papillary atrophy or destruction	<ul style="list-style-type: none"> • Reflux nephropathy • Papillary necrosis • Tuberculosis

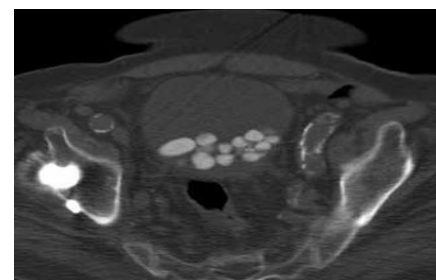
» Bladder Calculus



US: hyperechoic structure with shadow behind
bladder stone



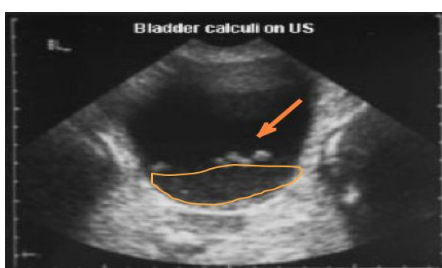
Multiple radiopaque opacities in the bladder. An example of bladder calculi in KUB



In CT: axial section; multiple bladder stones

Causes of multiple bladder stones:

nonfunctional neurogenic bladder (common in patients with cerebral palsy or spinal cord injury (leading to problems in controlling the bladder -> stasis of urine-> stone formation))



- 1- Bladder stone with some **turbulent urine** that could be infected due to inflammation
- 2- Stones will appear **white=hyperechoic**, The reason of the absence of shadow is (the urine in the bladder is dark and the shadow is dark).
- 3- Fluid (urine) will appear black

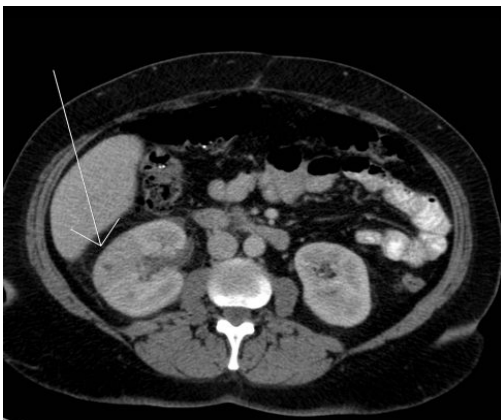
» Urinary Tract Infections

Urinary tract infections categorized as:

- Lower urinary tract infections (e.g. **cystitis**) clinical symptoms are irritative in nature (dysuria, burning sensation, etc.) +/- fever
- Upper urinary tract infection (e.g. **pyelonephritis**) clinical symptoms are same as lower UTI + **almost always severe FEVER & FLANK PAIN**

» Acute Pyelonephritis

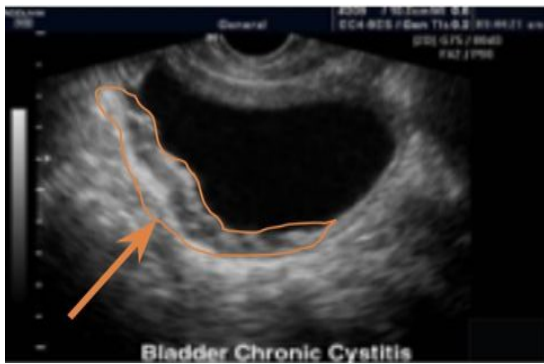
- Life threatening infection & medical emergency, it cause **urosepsis** and septic shock.
- Ascent through lower urinary tract.
- Early diagnosis and management has significant impact on patient outcome.
- **Presentation:** (Fever “high grade”, loin pain, nausea/vomiting), Diagnosed mainly clinically. **Colicky pain in lumbar region**
- **Predisposing factor:**
 - Stones
 - Reflux
 - Obstruction “any obstruction cause infection”
 - Diabetes “Due to reduced immunity”
 - Pregnancy “hormone of pregnancy have direct effect on smooth muscle of ureter so it will be relax and the reflux will be more than normal person”
 - Obesity, female anatomy (short urethra).
- Pregnant women are more prone to acute pyelonephritis, why? because they have short urethra.
- the changes in the hormones slows the flow of the urine, as a result, bacteria have more time to grow in the urine before being flushed out. Also, as the uterus grows, the increased weight can block the flow of urine from the bladder, causing an infection.
- The diagnosis of pyelonephritis is based on clinical diagnosis but we do CT just to confirm the diagnosis and to exclude other diseases.
- In case of Acute Pyelonephritis, the functions of the kidney are decreased; that's why it doesn't take the contrast and we can confirm that the patient has pyelonephritis. The correlation always with clinical picture will rule out other infections.



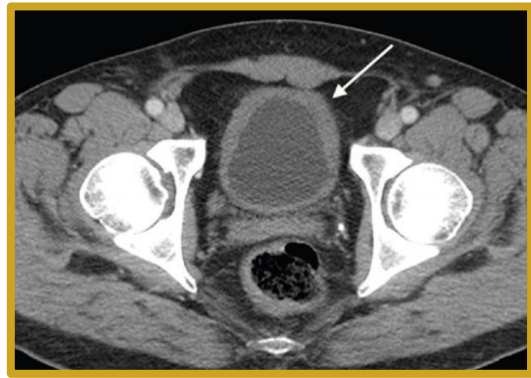
CT with contrast injection: pyelonephritis
Wedge shape hypoperfused lesion (striated nephrogram)
with perinephric fat stranding
 (the area of infection is edematous thus causing delayed contrast perfusion to the area)
 Congested right kidney with fat strands appearing grey in color (clear strands should be almost black), there is no differentiation between cortex and medulla cause the area is not taking the contrast as it is a hypofunctional hypoperfused lesion

» Cystitis

- Presentation: (+/- Fever, suprapubic pain, frequent urination, In addition to lower urinary tract infection symptoms(frequency, burning, foul smell urine, turbid)
- As upper UTI, more common in females because of short urethra
- E-coli is the most common causative organism
- Usually the diagnosis is based on the clinical symptoms



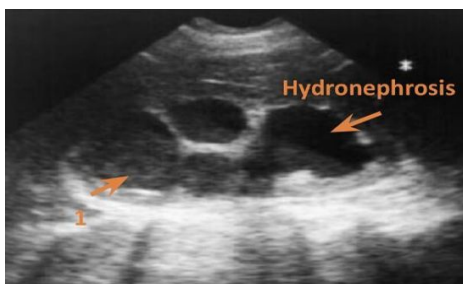
US showing thick bladder wall with little turbid urine.(normally bladder is thin with echogenic content and the urine should be black in both US and CT)



CT with contrast showing Thickening of the bladder wall (Normally it's 3mm here it's 5-6mm) and stranding of the surrounding fat Fat strands in general indicate inflammation

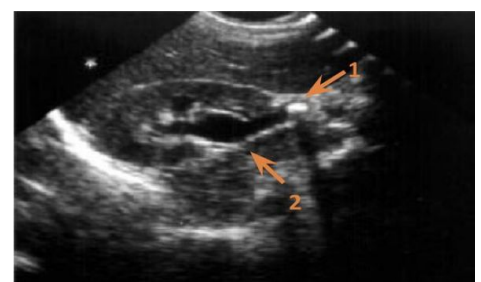
» Urosepsis

- Risk factors: if the UTI(pyelonephritis, cystitis, prostatitis) left untreated and immunocompromised patients
 - Establish a clinical diagnosis: Pyelonephritis, cystitis, prostatitis.
 - Urosepsis and obstructed ureter is **urologic emergency** ,so we have to relieve obstruction by treating the underlying cause and insert jj stent (in case of stones or tumor) and if failed: pigtail catheter, or perform nephrostomy
 - Symptoms: tachycardia, fever, systemic inflammatory response
 - Renal US is performed to rule out:
- Renal obstruction ➤ Renal or perirenal abscess which has to be evacuated or drained



Left pyonephrosis

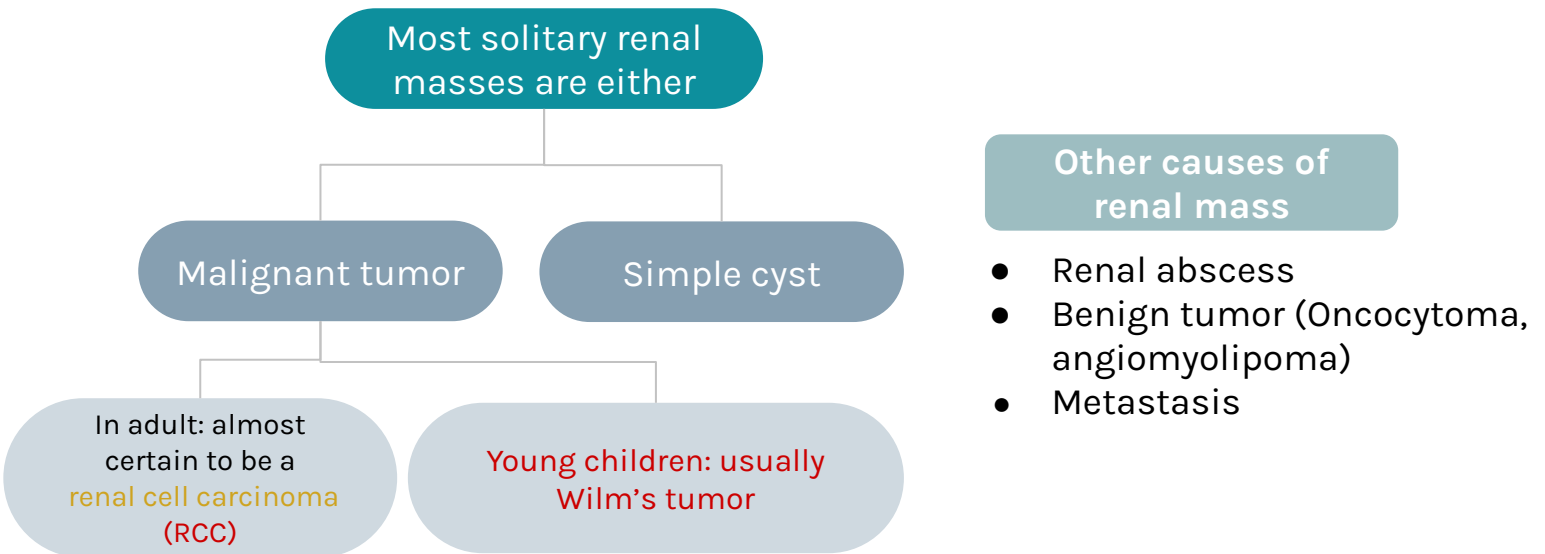
We see severe dilated pelvic calyces with echogenic turbid content which should be black., but here the echogenicity (not completely black) means there is pus
“ if urine transforms into pus inside the collecting system of the kidney= pyonephrosis”




right UPJ stone causing hydronephrosis

1=stone
2=showing dilated calyces

» Renal Masses



» Multiple renal masses include:



Approach to renal mass

Most renal masses are simple cysts

We find them by coincidence when we do the US for other reasons And we usually ignore them and dont follow up

Use US to characterize the mass:

- Simple cyst: next step? **STOP.**
- Solid mass or atypical cyst: next step? **CT with IV contrast Or MRI**

-US and CT characterize > 90% of masses > 1.5 cm

-Biopsy is rarely warranted

Renal Cyst

US will determine if the lesion is cystic or solid

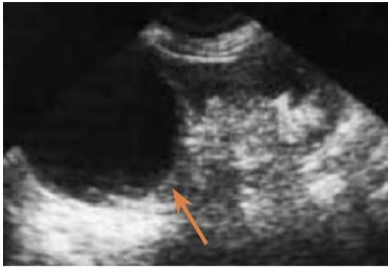There are **two types of renal cysts**:

★ Simple cyst:

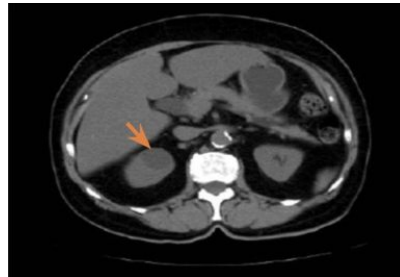
- Spherical, **Echo-free** fluid collection within a thin surrounding wall and will show good sound wave transmission.
- **No thickening, no calcification, no septation**
- Regular in US= anechogenic structure inside = black

★ Complicated cyst:

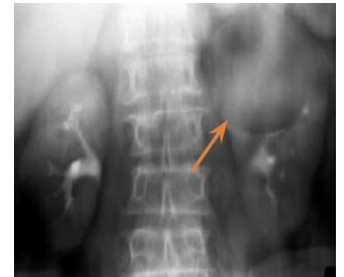- Will show the presence of echoes within the cyst,
- Will have a thick wall, And/or calcification in the wall.
- **May contain septation, calcification, soft tissue components, mural nodularity, not only a simple fluid**
- **You've found soft tissue components within a cyst on US, what is the next step?**
Contrast enhanced CT or MRI



Simple Cyst on US
Anechoic content no thickening



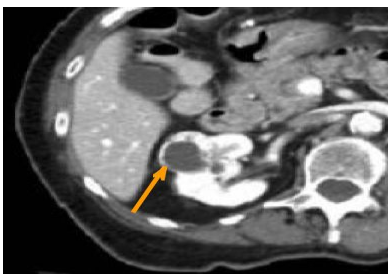
Simple cyst, CT with contrast showing round hypodense lesion Of anterior part of the right kidney, no calcification or thickening of the wall, density is about 0-15 Hf units.



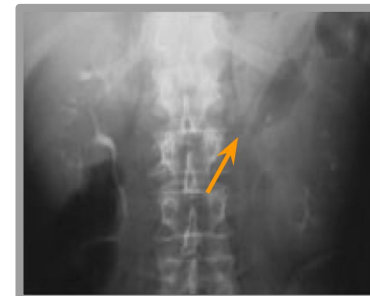Left renal mass on IVP
Regular round mass in upper pole of left kidney

Renal Carcinoma

- If US indicates that the mass is solid=**serious indication**, we must do CT with IV contrast can characterize the tumor in greater details.
- Delineate extent will show
 1. Degree of the vascularity.
 2. Presence/absence of the necrotic tissue center.
 3. Presence/absence of local invasion of adjacent structures

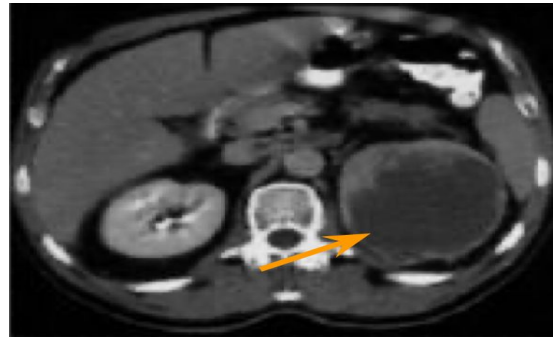
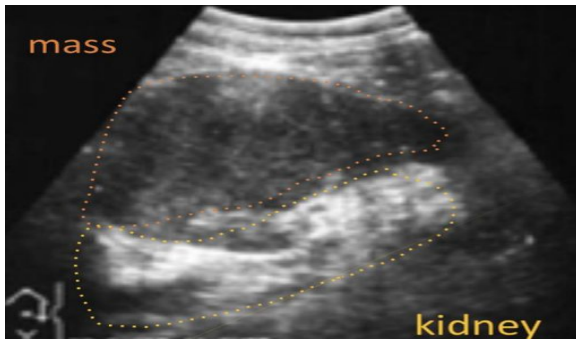


CT with IV contrast in the corticomedullary phase showing mass occupying the anterior part of right kidney with anterior thickened wall and necrotic center. malignant renal tumor



Distortion of left Pelvicalyceal System in IVP. Completely irregular, contrast filling some of the calyces, no smooth passage of contrast in proximal ureter

»» Cont.. Renal Carcinoma



- Solid left renal mass in a patient with micro hematuria.
- US shows echogenic structure in the left kidney with hypoechoic on the center
- CT with contrast shows in left kidney a mass with cystic content, and thick irregular wall enhanced with contrast and necrotic center.

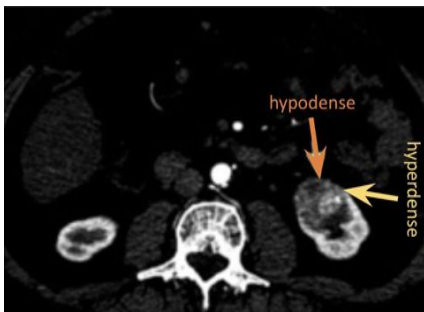
»» Renal adenocarcinoma

- 90% of all renal malignancies.
- 15-30% metastatic at diagnosis.
- Hematogenous and lymphatic spread.
- 10% have venous invasion so there is thrombosis either in renal vein or IVC

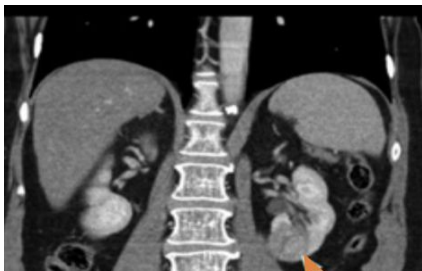Treatment:

- Radical Nephrectomy. Mostly it's the treatment of choice
- Partial Nephrectomy.
- Percutaneous ablation. (rarely)

Case: 70 y/o female presented with painless hematuria:



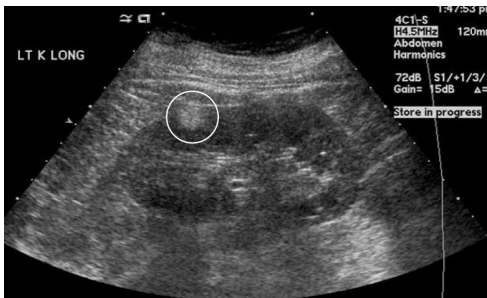CT with contrast showing Upper pole malignant mass lesion of the Left anterior part of the Kidney with heterogeneous enhancement. Right kidney is well differentiated, no fat strands and check lymph nodes for metastasis



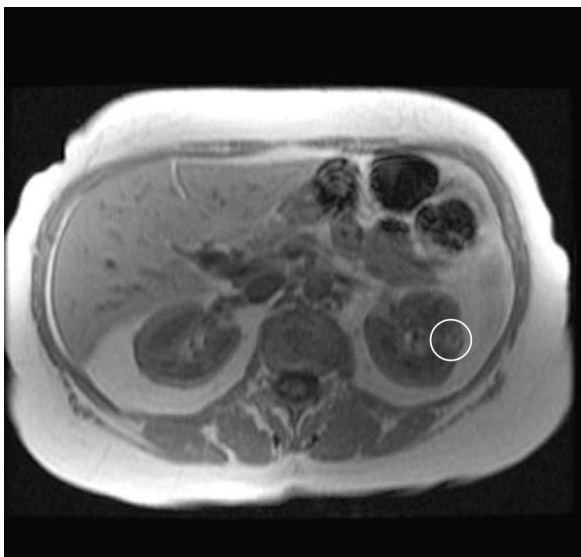
On the frontal section of CT we see the heterogenous mass with bulging and fat strands around

» Renal Angiomyolipoma

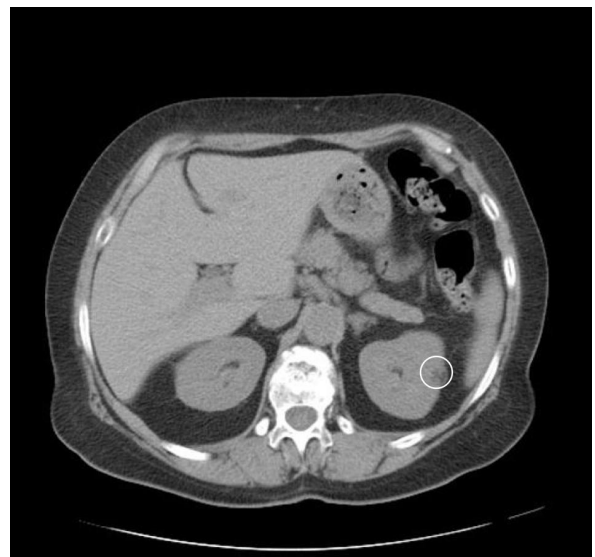
- Benign hamartomatous tumor composed of **fat**, smooth muscle and vessels.
hamartoma: multiple tissue components in wrong location
- Usually asymptomatic.
- Occasionally present with hemorrhage when large or multiple happens when the “angio” part of the tumor is big, and we have to embolize it to control this hemorrhage, if it’s small:do nothing
- **Fat detected in 96% by CT ,MRI and US.**
- Diagnostic key to angiomyolipoma is detection of fat surrounding the kidney.
- Angio= vessels, myo= muscle, lipo= fat & oma= benign tumor.
- Embolization is a minimally invasive treatment that occludes, or blocks, one or more blood vessels or vascular channels of malformations (abnormalities).



Example of angiomyolipoma in US showing sagittal section of kidney showing Round hyperechogenic mass in the upper pole of the cortex of the left kidney. (fat is hyperechoic)



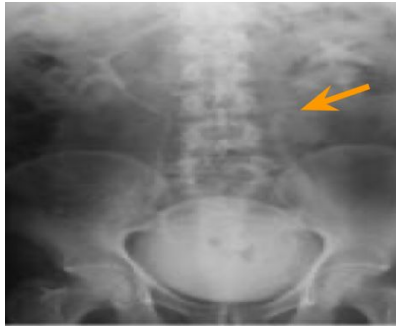MRI: hypersignal (white) lesion (contains fat)



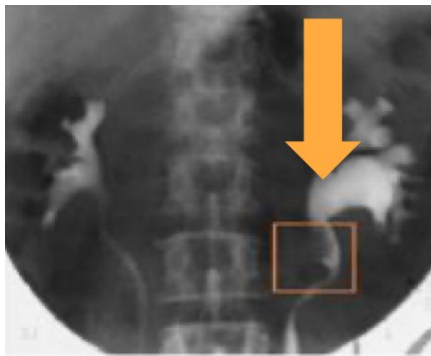
CT: Hypodense lesion (so contains fat) of the left kidney on the cortex

» Transitional Cells Carcinoma (TCC)

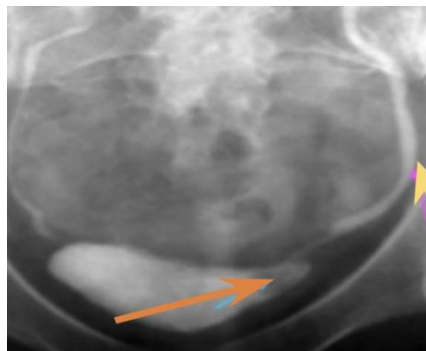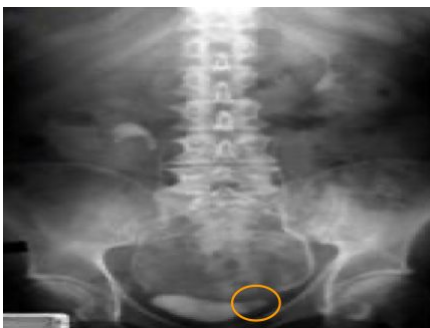- Most common malignancy of ureter and bladder.
- <10% of renal malignancies.
- Typically present with gross hematuria.
- CT for staging and surgical planning and diagnosis
- **Treatment:** radical nephrectomy.



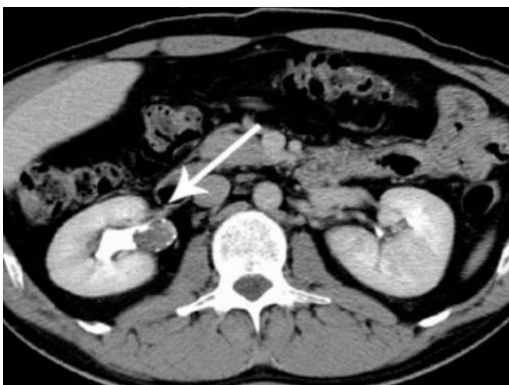IVP (left radiograph) and retrograde pyelogram (right radiograph) TCC proximal left ureter.



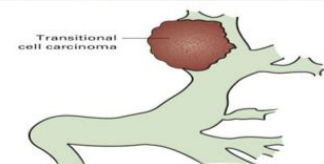
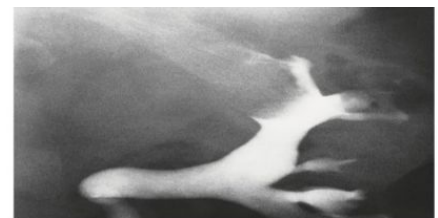
IVP shows distortion of part of the ureter with ureteropelvic junction obstruction and dilatation. TCC was discovered here in left proximal ureter as filling defect. We did IVP and we saw the right kidney is ok but on the left kidney we can see ureteropelvic junction obstruction and dilatation, so we inject the contrast retrograde pyelogram and we saw there is filling defect in left proximal ureter, so this is Transitional Cells Carcinoma.



Small TCC of bladder in patient with hematuria
Small bladder mass with dilation of the ureter



CT + contrast in the excretion phase Large TCC on the right renal pelvis seen as filling defect (the arrow) of proximal ureter caused by the tumor preventing the passage of the contrast. remember the phases(arterial 30-40s, venous 80s, corticomedullary 3m, excretory 8-10m)

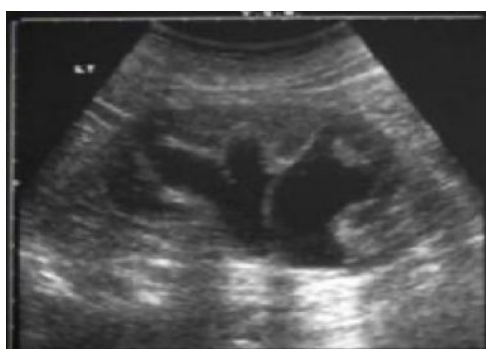

Filling defect in the margins and not obstruct the lumen so CT urography is done to see contrast in collecting system.
TTC

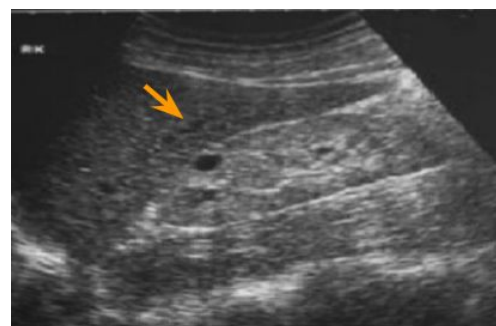
» Renal Failure

Acute and Chronic Renal Failure

Clinical categories	Prerenal (dehydration, shock, cardiac failure)	Renal (parenchyma, diabetes, GN, drugs, renovascular e.g. chronic renal artery stenosis, renal vein thrombosis).	Postrenal (obstruction)
	Diagnosis is based on the clinical presentation		Imaging is useful for the diagnosis of the post renal type
	Contraindicated if creatinine >200 mmol/dl (Patient will go into ARF so if needed dialysis is organized after the session)		
IV contrast			
Use US to assess:	Renal size (If kidney is less than 7 cm=atrophic kidney)	Parenchymal thickness Thickness should be more than 1.5-2 cm, if there is cortical thinning than suggests loss of renal function	US guided renal biopsy is important to establish diagnosis If patient comes with high creatinine and low creatinine renal clearance. by taking part of the kidney with biopsy needle percutaneously under ultrasound guidance.



Hydronephrosis post-renal AKI
Caused by long standing obstruction.
if prostate enlargement is the cause of obstruction: bilateral hydronephrosis is suspected



Chronic renal failure

- Atrophic (shrunk) less than 7 cm, echogenic (white) kidney
- No differentiation between the cortex and medulla (Undifferentiated kidney = non functioning kidney).
- The arrow is pointing at a simple cyst.

» Penetrating Trauma (gunshot, stab)

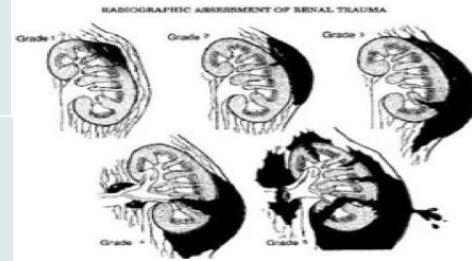
Unstable

Do surgery or angiography to stop the bleeding


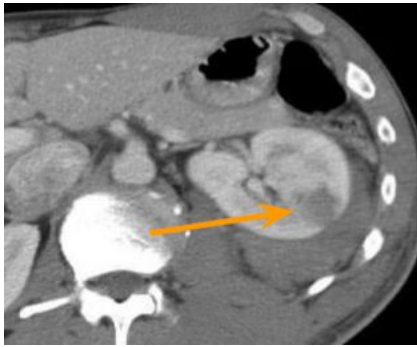



Stable

Do CT with IV contrast
(used to grade the trauma)

Management: surgery or interventional radiology

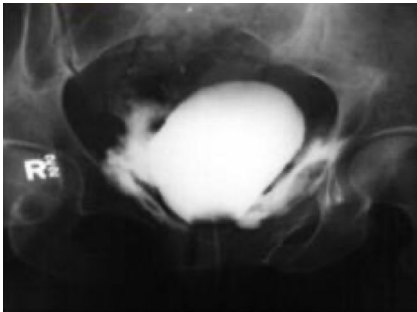


» Radiographic assessment of renal trauma

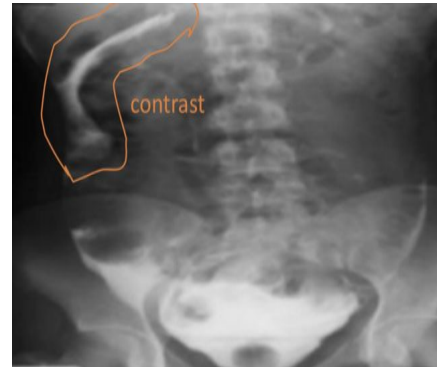
Grade 1	Subcapsular Hematoma, only contusion (a bruise) of the kidney		Grade 1-2 injury CT showing some hematoma
Grade 2	laceration in the cortex <1cm		
Grade 3	>1 cm but not extending into collecting system		Grade 3 injury Laceration Not extending to the collecting system, discontinuation of renal cortex
Grade 4	Laceration with hematoma Extend to pelvicalyceal system the patient will have hematuria		Grade 4 injury Deep laceration with perirenal hemorrhage, hematoma around kidney
Grade 5	Shattered kidney completely around the kidney	 	Grade 5 injury Thrombosed renal artery In CT scan, the kidney is non enhanced at all, there is thrombosis of the right renal artery which completely cut down. In angiography, we don't see the right kidney at all

» Bladder Injury

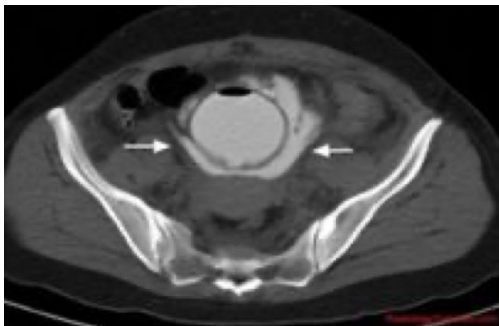
Bladder injury is either extraperitoneal or intraperitoneal. In trauma patient we see blood at urethral meatus we should do retrograde cystography "Inject contrast by retrograde catheter" then can see whether the contrast extra or intra peritoneal.



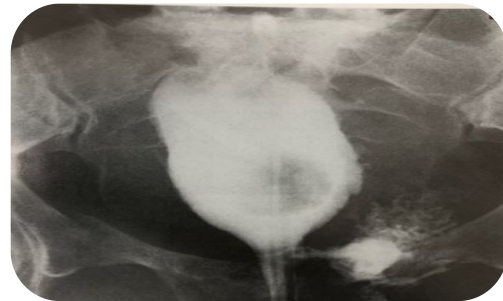Extraperitoneal bladder rupture
Contrast around urinary bladder.
The treatment is simple, insert
Foley catheter and wait



Intraperitoneal bladder rupture
contrast in peritoneum.
It needs surgical fixation

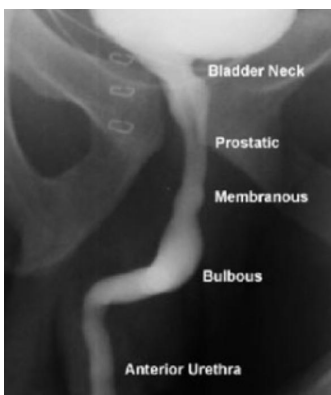

CT showing extraperitoneal bladder rupture
with contrast extravasation around the
urinary bladder

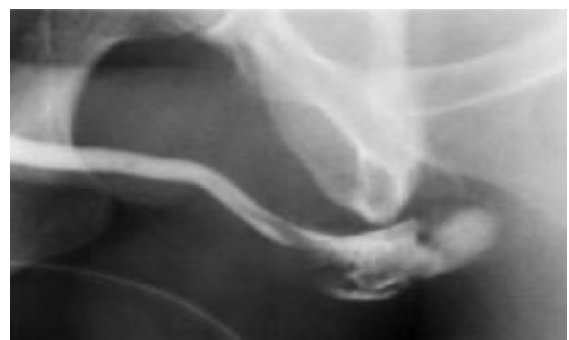

Rupture of the base of the bladder.
Cystogram showing extravasation of
contrast into the extraperitoneal space on
the left, and deformity of the bladder due to
surrounding hematoma and urine.

» Urethral Injury



Normal retrograde urethrogram
The best modality for evaluating the urethra
You don't need to memorize the part of the
urethra



Traumatic rupture of bulbous urethra
Urethral injury is suspected from pelvic trauma
due to blood in the urethral meatus, what is the
best modality to evaluate urethra? Retrograde
urethrogram

★ Q: A patient with pelvic injury and bleeding inside the meatus. What is the next step?
Retrograde urethrogram. Never insert Foley catheter before retrograde urethrogram

Summary

Renal calculi

- The diagnosis of renal calculi is often made clinically, common symptoms of renal calculi include: sudden onset of flank pain radiating to the ipsilateral groin and sometimes associated with hematuria, nausea and vomiting.
- The diagnosis of renal calculi is confirmed and evaluated using various imaging techniques (KUB, CT, US)
- Renal calculi can be radiopaque (visible on x-ray and CT) or radiolucent (invisible)

Infections

- Acute pyelonephritis: Mainly due to an ascending bacterial infection (eg. E.coli, enterococcus and proteus), Individuals are usually presented with fever, loin pain, nausea and vomiting, on CT with contrast a wedge shaped hypoperfused lesion is seen in acute pyelonephritis.
- Cystitis: Infection of the urinary bladder, symptoms include fever, suprapubic pain and polyuria, More common in females, The wall of urinary bladder is thick and regular on CT and US
- Urosepsis: sepsis due to UTI, Renal US is performed to rule out renal obstruction or renal/perirenal abscess.

Renal masses

Most solitary renal masses are either malignant tumor or simple cyst (benign), US and CT characterise >90% of renal masses >1.5cm (biopsy is rarely warranted), US will determine if the lesion is cystic or solid. If solid, CT with IV contrast can characterise the mass in greater detail.

- Renal cysts
- There are two types of renal cysts
 - Simple cyst: Spherical, anechogenic, no thickening wall, regular wall
 - Complicated cyst: Echogenic, thick wall +/- calcification in the wall
- Renal Adenocarcinoma
 - 90% of all renal malignancies, Exophytic renal mass with cystic content and irregular wall, Treatment: radical or partial nephrectomy
- Renal Angiomyolipoma
 - Benign hamartomatous tumor composed of fat, smooth muscle and vessels, Usually asymptomatic, Detected by CT.
- Transitional cell carcinoma
 - Most common malignancy of ureter and bladder, Usually seen as filling defect, CT for staging and surgical planning, Treatment: Radical nephrectomy.

Acute and chronic renal failure

Acute	Kidney is enlarged in size	Oedematous	Obstruction	
Chronic	Kidney is small in size	No darkness in the cortex	Bright echo pattern	cysts can be seen

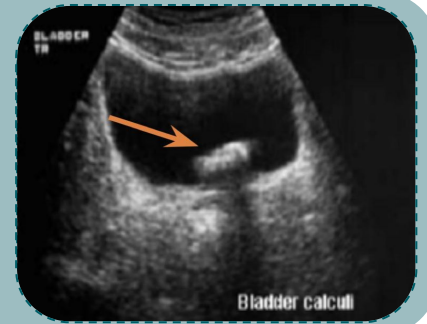
GU trauma

- Unstable: Surgery or angiography
- Stable: CT with contrast to grade the trauma

Quiz

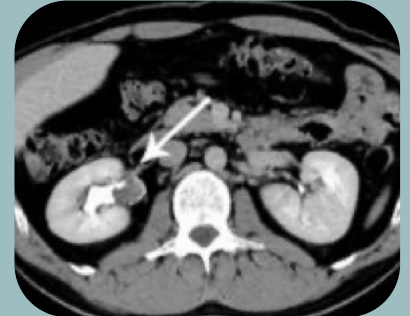
1- Young adult presented with right flank pain and blood in urine . Ultrasound exam was performed.
Which of the following is most likely the diagnosis:

- a. Bladder calculi
- b. normal US
- c. Hydronephrosis
- d. renal cyst



2- 60 years old male presented to the emergency with gross hematuria CT was done which of the following is correct:

- a. TTC
- b. Renal stone
- c. Pyelonephritis
- d. Normal CT



3-which level of creatinine is contraindicated to give IV contrast in renal failure patient?

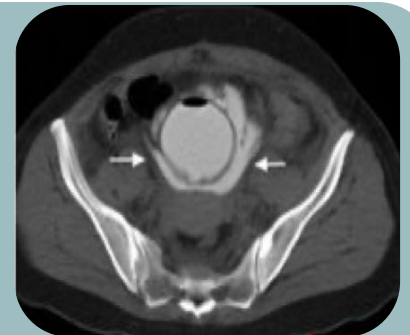- a. >200 mmol/dl
- b. 133 mmol/dl
- c. 150 mmol/dl
- d. 50 mmol/dl

4- Which of the following is a common site of urinary stone obstruction?

- a. Junction of mid-distal ureter
- b. Vesicoureteric junction
- c. Proximal ureter
- d. Mid ureter

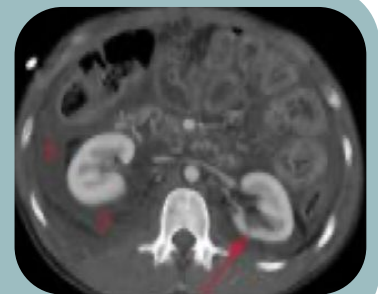5- A CT was done to a patient after transurethral resection of bladder tumor and the CT shows:

- a. Renal injury
- b. Bladder injury
- c. TCC
- d. Renal mass



6- A 43 years old Pakistani gentleman came to the ER with a stab wound to the right kidney. A CT was performed. What's most likely the diagnosis

- a. Grade 1-2 injury
- b. Renal calculi
- c. Grade 4 injury
- d. Normal CT



Answers
1) A
2) A
3) A
4) B
5) B
6) A

Special thanks for 38 & 39 teams