Urinary Tract Infections

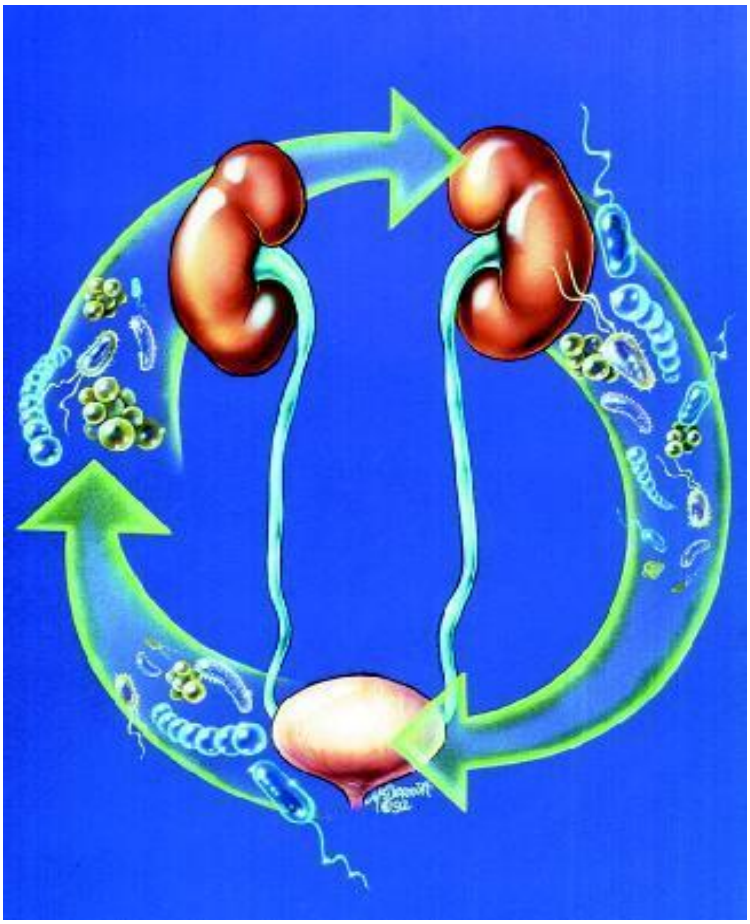

This is a Handout made by The Pathology Team – 429 Including:

Mohammed Al-Harbi - Raed Al-Faraj

Dona Barakah - Arwa Al-Madani - Nourhan Al-Shamma'

Dina Al-Kuhaimi - Afnan Al-Tamimi - Mashail Al-Towairiqi

Rana Al-Khelaif - Reham Al-Henaki - Najla Al-Ghabban

Sara Al-Hussain - Maha Balharith

It is the 1st and MAIN Source for Studying This Lecture
(Revised With Dr.Kfouri And Dr.Al-Suhaibani)

INFECTIONS OF THE URINARY TRACT

1. Upper Urinary Tract
   Pyelonephritis (inflammation of the kidney and its pelvis)
   - **Acute** → Presence of Neutrophils
   - **Chronic** → presence of lymphocytes, macrophages and monocytes
   - **Xanthomatous** → means there are Foamy Cells

2. Lower Urinary Tract
   - Ureteritis
   - Cystitis
   - Uretheritis

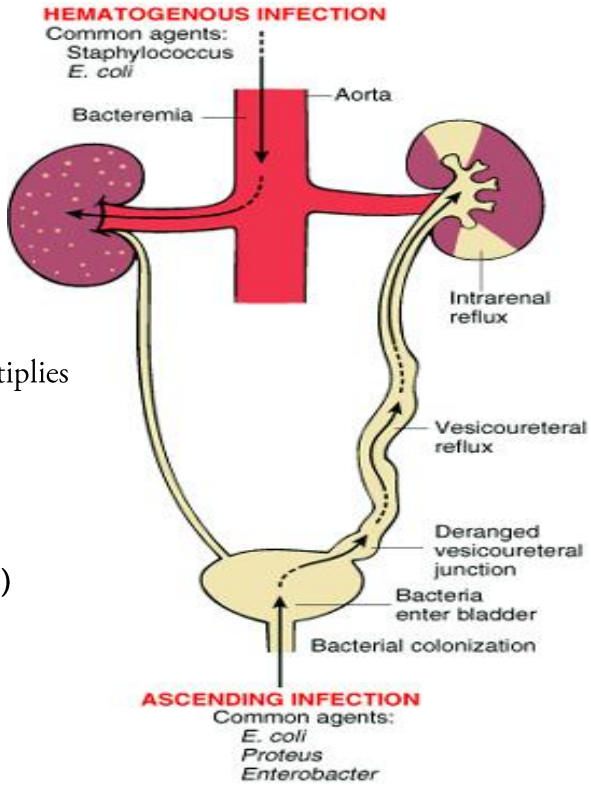

ROUTE OF INFECTION

❖ **Ascending infection**
- Bacteria in *Perineal Area*
  ascends through the urethra, enters the urinary bladder and multiplies
- This is the most common route of infection
- e.g. E.coli to the bladder

❖ **Hematogenous infection**
through the bloodstream (e.g. septicemia or infective endocarditis)
- In a patient with *Bacteremia*
  → bacteria may be "seeded" into the kidneys from the blood
- It is rare to occur
- e.g. S.aureus , T.B

ETIOLOGY AND PATHOGENESIS OF URINARY TRACT INFECTION

The principal causative organisms: the gram –ve bacilli**:**
1. **E.coli** most common.
2. **Other:** Proteus, Klebsiella, Enterobacter, and Pseudomonas
3. **Staphylococci and Streptococcus faecalis** may also cause pyelonephritis, but they are uncommon.

❖ Ascending infection**: (comes from the lower urinary tract --- MOST IMPORTANT AND COMMON)**

Predisposing factors:
- **urethral instrumentation :** catheterization and cystoscopy
- **trauma to the urethra during sexual intercourse**
- ***vesicoureteral reflux (VUR) :*** *congenital* - spinal cord injury
- **outflow obstruction & stasis of urine (prone to bacteria multiplication)**
  - Benign Prostatic Hyperplasia ((In Older Men Patients))
  - Uterine Prolapse.
  - Diabetes (Neurogenic Bladder Dysfunction).
  - *Pregnancy*
- **intrarenal reflux**
- **immunosuppression and insufficiency (in kidney transplant)**
  Women are more commonly affected than men.

❖ Descending infection

PYELONEPHRITIS

ACUTE PYELONEPHRITIS

Caused by bacterial infection
(renal lesion is associated with urinary tract infection)

Acute ***Suppurative Inflammation*** **of the kidney, bacterial and sometimes viral**

HALL MARKS OF IT:

- **Patchy interstitial** in between tubules.
  we call it **Suppurative** when it includes:
  the interstitial + the lumen of the tubules
- **Intratubular aggregation of *neutrophils*** → infection
- **Tubular necrosis**
  epithelial cells in the tubules are necrotic (due to infection)

COMPLICATIONS:

1. **Papillary Necrosis:**
   mainly in Diabetic & those with urinary tract obstruction
2. **Pyonephrosis:**
   when there's total or almost complete obstruction (rare when not treated)
3. **Perinephric Abscess:**
   extension of suppurative inflammation through renal capsule and into the *Perinephric Tissue*

OUTCOME:

Acute Phase →BECOMES → Healing occurs

Neutrophilic infiltrate →→ infiltrate exposed <u>of</u>
Macrophages
Plasma Cells - Lymphocytes

Inflammatory foci →→ irregularly scars (seen in cortical surface as fibrous depressions)

Tubules are AFFECTED MORE than Glomerulus (they're more resistant to it)

Irregular Scars' Characteristics:
Patchy jigsaw pattern with intervening preserved parenchyma
<u>Microscopically by:</u>
Tubular atrophy - interstitial fibrosis - lymphocytic infiltrate (in native & transplant kidneys)

Metastatic Pyelonephritis:
comes from blood and is localized in kidneys

CHRONIC PYELONEPHRITIS

More complex
Caused by bacterial infections and other predisposing factors (vesicourethral reflux, obstruction –with a stone/tumor)
An important cause of "End-Stage kidney disease"

Chronic *Tubulo-Interstitial Inflammation* and *Renal Scarring* associated with pathologic involvement of the calyces and pelvis.

<u>Divided into</u>:
1.Chornic Reflux associated 2.Chronic obstructive

HALL MARKS OF IT:

irregularly scarred and involvement is asymmetric

- Coarse, Discrete, Corticomedullary **SCARS**
- Dilated, blunted, or deformed **CALYCES**
- Flattening of the **PAPILLAE.**

HISTOLOGICAL CHARACTERISTICS

<u>Involves</u> tubules and interstitium.

- Neutrophils in the **Interstitium**
  Pus Casts in the **Tubules.**
- The tubules show *Atrophy* in some areas and *Hypertrophy* or *Dilation* in others.
- Dilated tubules with flattened epithelium may be filled with colloid casts **(Thyroidization).**
- Varying degrees of chronic interstitial inflammation and fibrosis in the cortex and medulla.

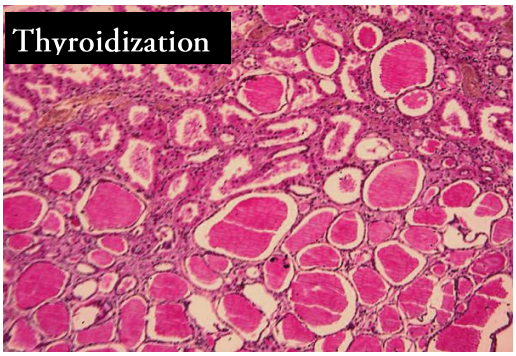

It MUST be PREVENTED or??
The patient will have to make Dialysis 3 times a week

Thyroidization: resembles thyroid tissue

Papillary Necrosis: (Acute Pyelonephritis- associated)

Mainly occurs in diabetic patients
associated with urinary tract obstruction.

- It's Coagulative Necrosis.
- Affect one or more pyramids and it's yellow or white in color.
- It may be associated with ***Pylonephritis.***

Drug-induced interstitial nephritis: (Chronic –Associated)

"An Immune Reaction" involves: type I or type IV hypersensitvity.

1- ***Most of the time***, the disease is induced with a drug called "METHICILLIN"
→ with this drug ((most of the time)) we will see non-necrotizing granulomas containing giant cells

2- ***And sometimes,*** it is induced with "RIFAMPIN, NSAIDS, THIAZIDE"
→ we will see the same cells that we found with methicillin effects
also DIURETICS and the H2 BLOCKER CIMETIDINE.

occur in the interstitium
it shows variable but frequently pronounced *Edema* and *Infiltration*
by mononuclear cells, principally lymphocytes and macrophages
You can find in large amounts → Eosinophils and Neutrophils
in small amount of → Plasma Cells and Basophils

❖ **Infections of the kidney are Mainly divided into**

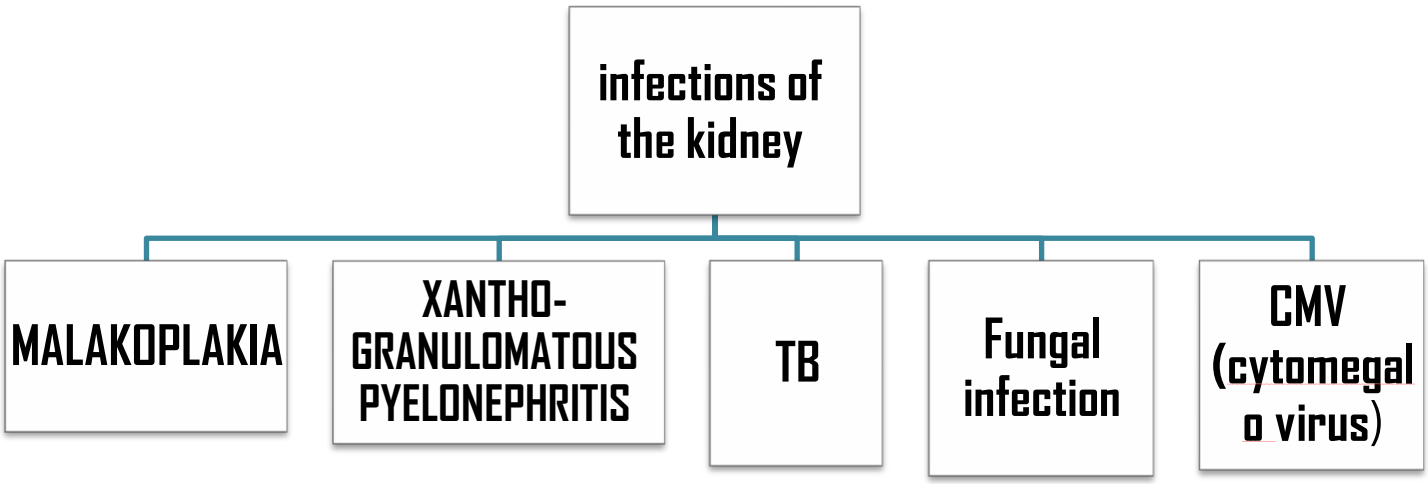

MALAKOPLAKIA

A) **Definition:**

it is a peculiar (specific) pattern of vesical inflammatory reaction

- Characterized macroscopically by soft, yellow, slightly raised mucosal plaques 3 to 4 cm in diameter.
- Related to bacteria.

B) **Site:** mainly occur in the **bladder** and **the kidney.**

C) **Microscopically:**

- Infiltration with large, **foamy macrophages** mixed with occasional multinucleate giant cells and interspersed lymphocytes.
- *Laminated Mineralized Concretions* resulting from deposition of calcium in enlarged lysosomes, known as **Michaelis-Gutmann bodies**

are **typically present within the macrophages** and can present out of the macrophages in **different stages of maturatic** have **dark appearance in the center** and **some still more gray in the center.**

Very important:

The **most important characteristic for *Malakoplakia* is** *Michaelis-Gutmann Bodies* (it will be your mark), but not the foamy macrophages.

Cystitis with malakoplakia:

Michaelis Gutman bodies

"dark in the center surronded by a hollow"

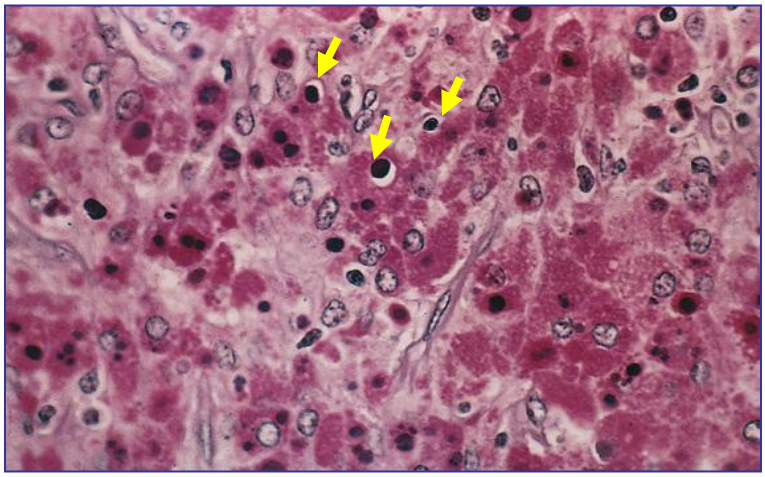

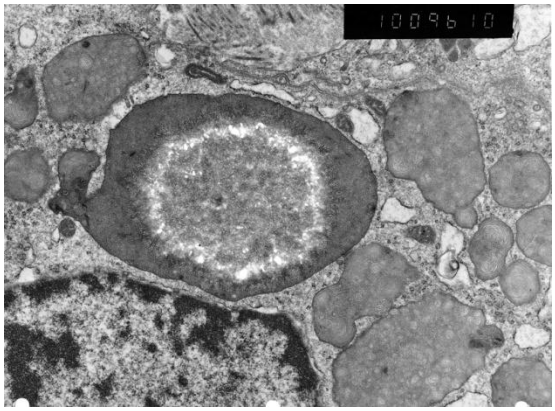

-Gray in the center

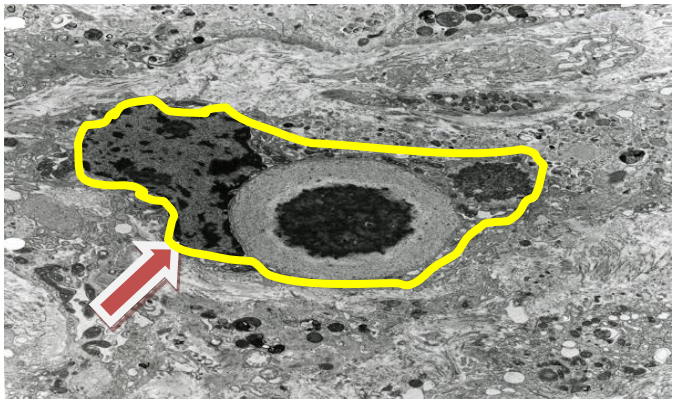

-dark in the center (inside the macrophage)

XANTHOGRANULOMATOUS PYELONEPHRITIS: XGP

Xantho **means** Yellow

An unusual and relatively rare form of chronic pyelonephritis
characterized by:

- Accumulation of **foamy macrophages** mixed with **plasma cells** (you can know it by its *Exentric Nucleus*).
- Lymphocytes (BECAUSE IT IS CHRONIC)
- Polymorphonuclear Leukocytes.
- *Occasional* Giant Cells.
- The lesions sometimes produce large, yellowish orange nodules (when it is hemorrhagic) that **may be grossly confused with** renal cell carcinoma.

Associated with *Proteus* infections and **obstruction** (obstruction due to "Stones")

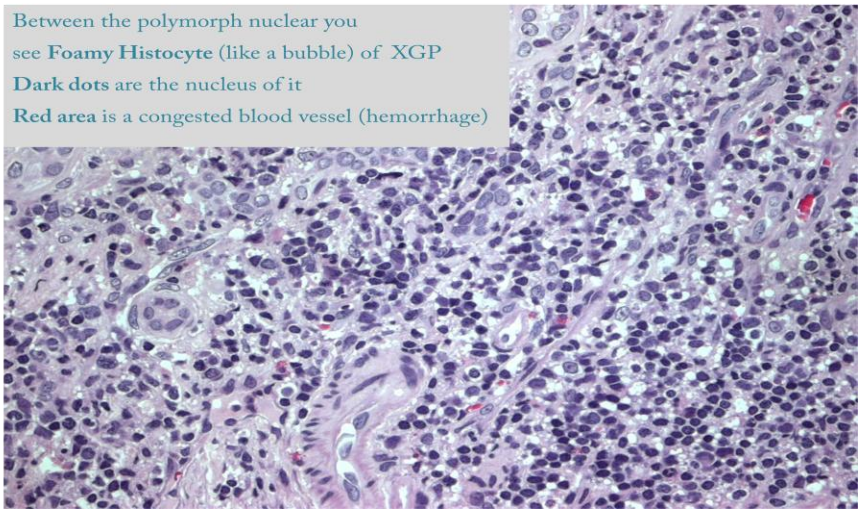

The MOST CHARACTERISITC of it:
is FOAMY MACROPHAGES

	definition	Macroscopically	Microscopically	associated with
MALAKOPLAKIA Kidney & bladder	designation refers to a peculiar pattern of vesical inflammatory reaction	soft, yellow, mucosal plaques 3 to 4 cm in diameter .	infiltration with large, foamy macrophages mixed with occasional multinucleate giant cells and interspersed lymphocytes. Michaelis-Gutmann bodies (present within the macrophages): **laminated mineralized concretions resulting from deposition of calcium in enlarged lysosomes,**	
XANTHO-GRANULOMATOUS PYELONEPHRITIS	an unusual and relatively rare form of chronic pyelonephritis		accumulation of foamy macrophages mixed with plasma cells, lymphocytes, polymorphonuclear leukocytes, and occasional giant cells	[Proteus Infections And Obstruction] **The Lesions** *Sometimes* Produce Large, Yellowish Orange Nodules That May Be Grossly Confused With Renal Cell Carcinoma

Urolithiasias

Types of stones in urinary tract
- **CALCIUM OXALATE and PHOSPHATE (70%) (White in x-ray)**
- **URIC ACID & URATE (5-10%) (not seen in x-ray)**

◆ **Promotors:**
Most commonly, Bacterial Infection

◆ **Etiology, stone formation:**
"Supersaturation of urine is" **the key to stone formation**

◆ **Symptoms of urolithiasis:**
- Pain in the lower back part
- Nausea, vomiting
- Blood in urine

ADULT AND CHILDREN POLYCYSTIC KIDNEY DISEASE

These are what we call ***family autosomal dominant*** disease, it means that:
Patient whom is **born with genetic mutation** that leads to formation of polycystic kidney disease.

In adults → you will see an **Enlarged Kidney full of the cysts** (it is staged)
((it induces infection – due to the formation of cysts - sometime they cause stagnant in it → lead to destruction of kidney))

- it increases the size of the kidney
- Multiple grossly visible stones
- Associated with "**Polycystic Liver Disease**".
-

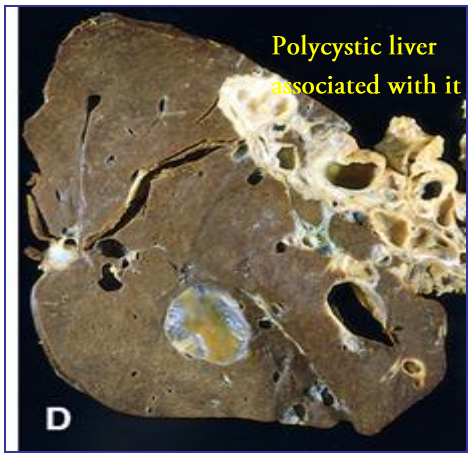

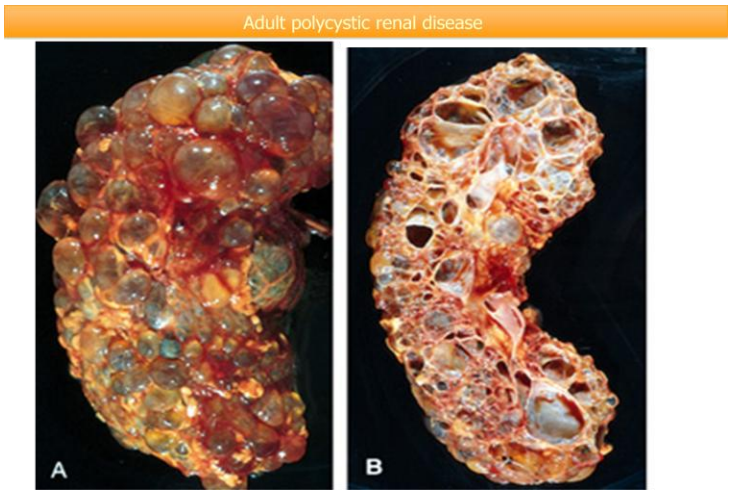

In childhood ((autosomal recessive – congenital – disease)) →
Patient will be born with **Genetic Infection** in the formation of kidney → **NO INCREASE IN THE SIZE**

- Manifestation is at birth or infantile period
- Associated with **Congenital Hepatic Fibrosis** (NOT polycystic liver disease – unlike the adult's).

Microscopic appearance of recessive polycystic kidney disease (RPKD):
The cysts ***fill most of the parenchyma***, and it is hard to find glomeruli.

URINARY BLADDER

Anatomy of the Urinary Bladder

The urinary bladder lies:
within the pelvic cavity - behind the "symphysis pubis" - **below the parietal peritoneum.**

Histology of the Urinary Bladder

The bladder wall has the same tissue layers as the renal pelvis and ureter.
The layers are: Mucosa - Muscularis - Serosa/Adventita.

❖ Mucosa

- **The innermost portion of the urinary bladder.**
- It is composed of transitional epithelium and connective tissue.
- **The transitional epithelium**, expands when there is an increase in the volume, has domed shaped binucleated cells on the apical surface; called ***"Facet Cells"***.
  The epithelial layer contains *no blood vessels or lymphatics.*
  The basement membrane is *a single layer of cells* and it is *thick* to protect tissues from urine.
  The basement membrane separates the epithelium from the connective tissue.
- **The epithelium** lies upon connective tissue called the lamina propria.
  The lamina propria is composed of areolar connective tissue.
  It contains blood vessels: metarterioles and venules, nerves, and, in some regions, glands.
  It is *loose "not fibrotic"* because of the ability to *expand.*

❖ Muscularis

- **Underneath the mucosa** of the bladder is a layer of **smooth muscle** called the muscularis.
  It is subdivided into three layers of smooth muscle:
  inner longitudinal - middle circular - outer longitudinal (smooth muscle runs in random directions except at neck)
- **Contraction of this muscle** expels urine from the bladder.
- The smooth muscle of the bladder is called the "***detrusor muscle.***"

❖ Serosa/Adventita

- **A serosal covering** on the upper region of the bladder.
  Composed Of a simple squamous epithelium overlying a small bit of connective tissue. It is *Peritoneum.*
- In all other regions of the bladder, the outer layer of the bladder is **Adventita.** It is composed of connective tissue.
- Beyond the serosa/adventitia covering of the bladder is **Perivesical Fat** (a layer of fat surrounding bladder).

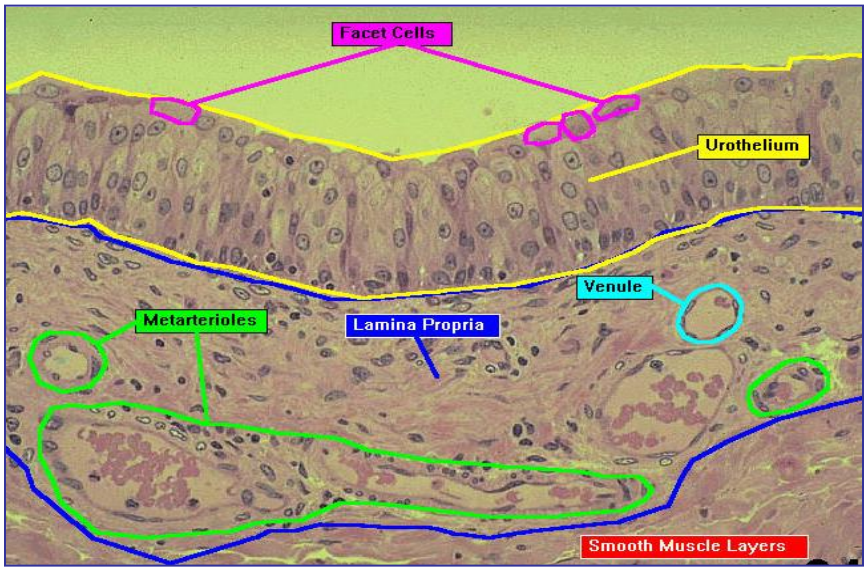

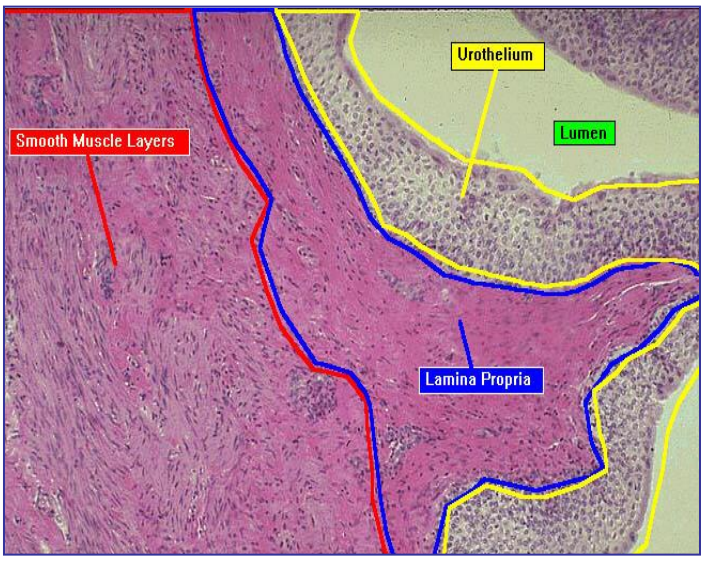

INFECTIONS OF THE LOWER URINARY TRACT

Definition:
The finding of microorganisms in the Urinary Bladder with/without *Clinical Symptoms* and with/without *Renal Diseases*

Most Causative Agent: E.coli

Significant Bacteruria:
The number of bacteria in the voided urine exceeds the number that can be expected from *Contamination* (i.e. ≥ 10^5 cfu/ml)

Clinical Feature: (mostly in Cystitis)
Frequency - Urgency - Dysuria (painful voiding) - Suprapubic Pain - Cloudy/Foul smelling urine

Investigation:
Midstream Urine for: **1.** Dipstick (to detect nitrite) **2.** Look for WBCs and RBCs by microscopy **3.** Do a urine culture

****if we had a "Sterile" (no bacteria) and a "Pyuria" sample,** then the most probable Differential Diagnosis is → TB

	Ureteritis	Urethritis
Definition	It is the **ureteral** inflammation **associated with** inflammation **not associated with** infection **is of little clinical consequence.**	It is the **urethral** inflammation
Morphology and Types	➢ **accumulation or aggregation of Lymphocytes forming** → germinal centers in the subepithelial region may cause slight elevations of the mucosa produce a fine granular mucosal surface (Ureteritis Follicularis). ---------- * the **mucosa** may become **sprinkled** with fine cysts varying in diameter from 1 to 5 mm lined by flattened urothelium (Ureteritis Cystica)	Its divided to : 1- ***Gonococcal urethritis*** one of the earliest manifestations of this venereal infection. 2- ***Nongonococcal urethritis:*** **Common.** caused by a variety of bacteria, e.g. *E. coli* and other enteric organisms predominate. ---------- ***Mycoplasma (Ureaplasma urealyticum)*** also accounts for the symptoms of urethritis in many cases. ***Reiter syndrome*** comprises the clinical triad of arthritis, conjunctivitis, and urethritis

CYSTITIS

inflammation of the urinary bladder

- It is more common in women → because of their short urethra.
- It may be Acute OR Chronic

❖ CAUSES (ETIOLOGY):

1- **Tuberculos Cystitis:** Sequel to Renal TB.
2- **Candida Albicans:** when Candida can go to the urethra & bladder even if the patient sometimes isn't immunosupressed.
3- **Schistosomiasis** (Schistosoma Hematobium).
4- **Chlamydia And Mycoplasma.**

❖ RISK (PREDISPOSING) FACTORS:

1- Bladder Calculi. 2- Urinary Obstruction.
3- Diabetes Mellitus. 4- Instrumentation. 5- Immunodeficiency.

****cystitis is very annoying and painful to the patient.*

❖ MORPHOLOGY:

- Form non-specific (acute or chronic) inflammation of the bladder.
- Gross appearance → mucosa hyperemia + exudates.
- Persistence of infection leads to chronic cystitis.
- chronic cystitis differ from acute one only in character of the inflammatory infiltrate, as:
  Acute → Neutrophils **Chronic** → Lymphocytes, Fibrosis And Others.

❖ TYPES OF CYSTITIS:

1. follicular cystitis:

Characterized by*:* Aggregation of lymphocytes into lymphoid follicles in the bladder mucosa and underlying wall

- not necessary associated with infection, e.g. ureteitis

2. Eosinophilic Cystitis:

Manifested by: Infiltration with submucosal eosinophils (It is a manifestation of systemic allergic disorder and parasite).

- Represent nonspecific subacute inflammation.

3. Interstitial Cystitis (Chronic Pelvic Pain Syndrome):

Persistent and painful. Most frequently occurs in women.

Characterized by: Intermittent, often severe supra pubic pain, Urinary frequency, urgency, Hematuria and dysuria.-

- Without evidence of bacterial infection
- **Mast cells** are characteristic for this disease, but there is no uniformity about their specificity and diagnostic utility.
- ***Later in the disease:*** "Transmural Fibrosis" may ensue leading to contracted bladder.

4. Polypoid cystitis:

Inflammatory condition resulting from irritation to the bladder mucosa.

Caused by*:* indwelling catheters, other reason ((any injurious agent may give rise to this lesion)).

- Marked *Submucosal Edema* resulting in → thrown of urothelium into broad bulbous polypoid projection.
- ***Polypoid cystitis*** may be confused with ***papillary urothelial carcinoma*** (Clinically and histologically)).

	Follicular cystitis	Eosinophilic cystitis	Interstitial Cystitis (Chronic Pelvic Pain Syndrome)	Polypoid cystitis
			persistent, painful form of chronic cystitis occurring most frequently in women	It is an inflammatory condition resulting from irritation to the bladder mucosa
characterized by		infiltration with *Submucosal Eosinophils*, + *Nonspecific Subacute Inflammation*	▪ Intermittent ▪ severe supra-pubic pain ▪ urinary frequency ▪ urgency ▪ hematuria ▪ dysuria ▪ without evidence of bacterial infection.	
Comment	not associated with infection.	It's a manifestation of *A Systemic Allergic Disorder*	Late in the disease, transmural fibrosis may occur, leading to a contracted bladder.	▪ any injurious agent may give rise to this lesion (& commonly catheters) ▪ it may be confused with *Papillary Urothelial Carcinoma* both clinically and histologically
Morphology	aggregation of lymphocytes into lymphoid follicles within the bladder mucosa and underlying wall		*Mast Cells* are characteristic of this disease, there is no uniformity in the literature about their specificity and diagnostic utility.	