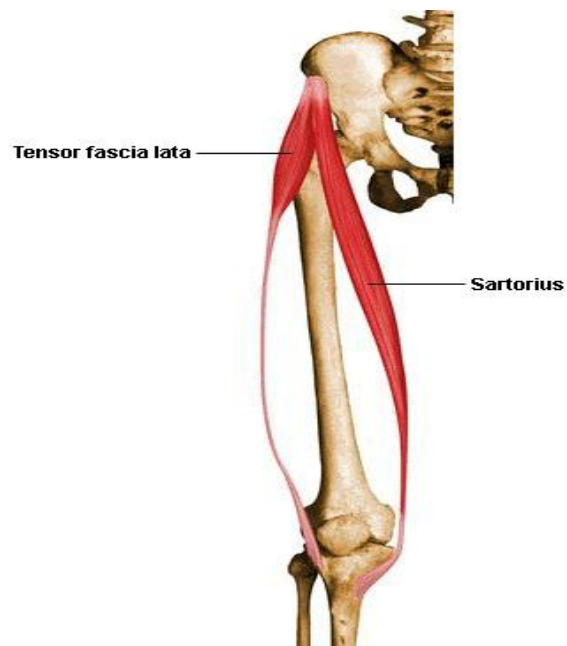


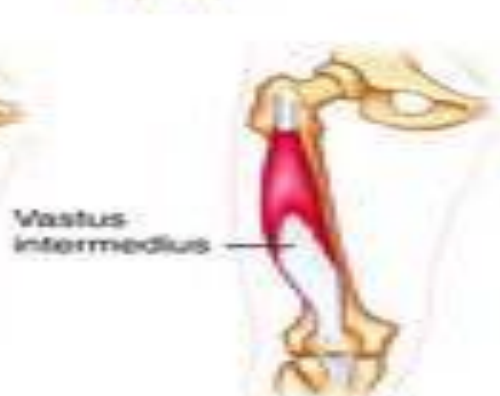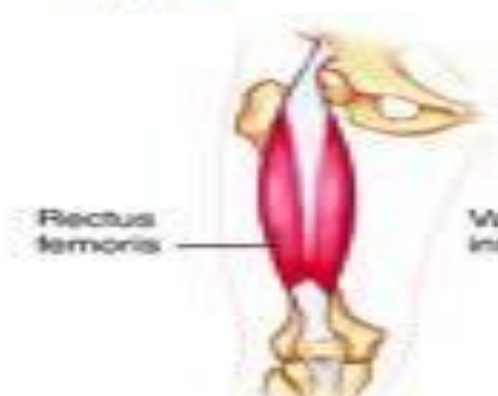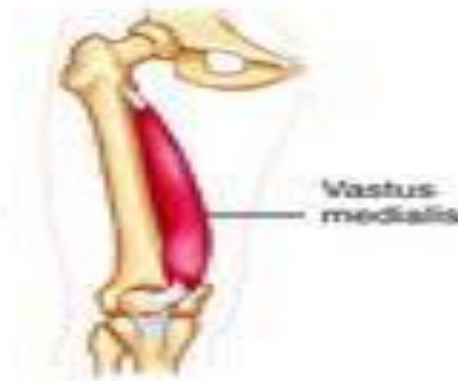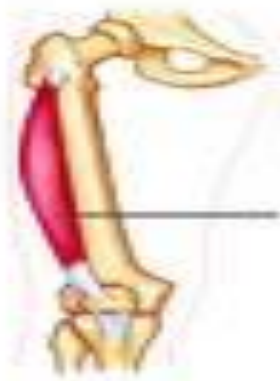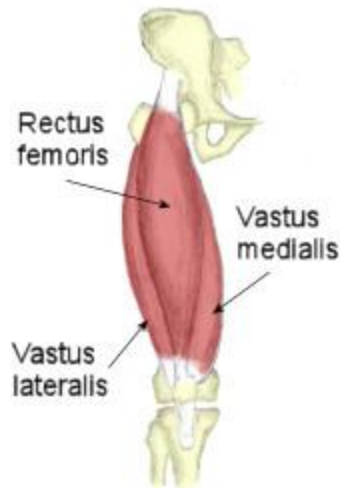
# Muscles of anterior compartment of the thigh



Muscle	Origin	Insertion	Nerve Supply
Sartorius	anterior superior iliac spine	upper part of medial surface of tibia	Femoral nerve

## Quadriceps Femoris

**Consists of:** Rectus Femoris and Three Vasti(Lateral, Medial and Intermedius)



## Quadriceps Femoris

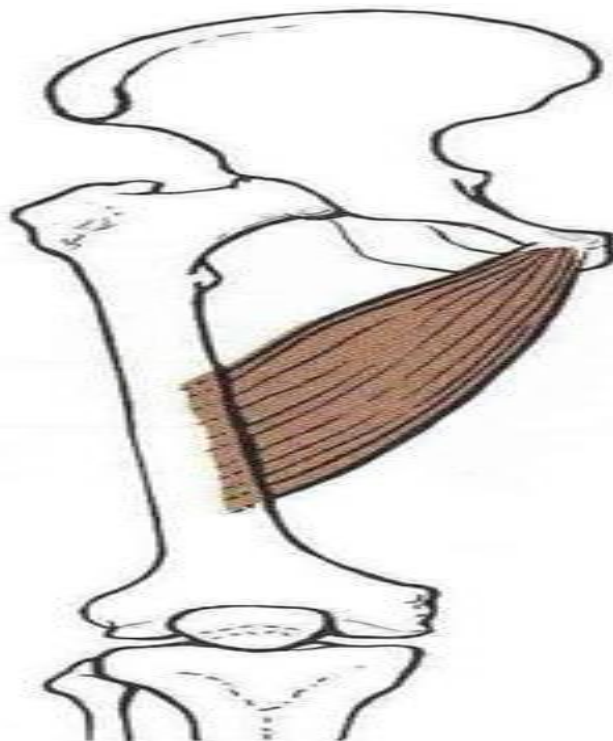
**Consists of:** Rectus Femoris and Three Vasti(Lateral, Medial and Intermedius)

Muscle	Origin	Insertion	Nerve Supply
Rectus Femoris	Has two heads: 1. Straight head from anterior inferior iliac spine 2. Reflected head from ilium above the acetabulum	Into patella and then through ligamentum patella into the tibial tuberosity	Femoral nerve
Vastus lateralis	Posterior border of femur	Into patella and then through ligamentum patella into the tibial tuberosity	Femoral nerve
Vastus medialis	Posterior border of femur	Into patella and then through ligamentum patella into the tibial tuberosity	Femoral nerve
Vastus intermedius	Front of shaft of femur	Into patella and then through ligamentum patella into the tibial tuberosity	Femoral nerve

## Medial Compartment of Thigh

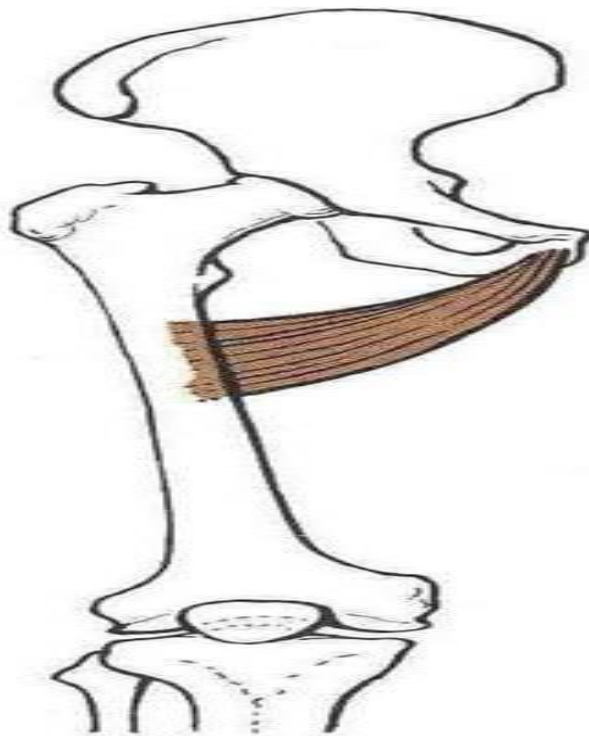
### Adductor Longus

Muscle	Origin	Insertion	Nerve Supply
Adductor Longus	Posterior border of femur (Linea Aspera)	Body of pubis	Obturator nerve



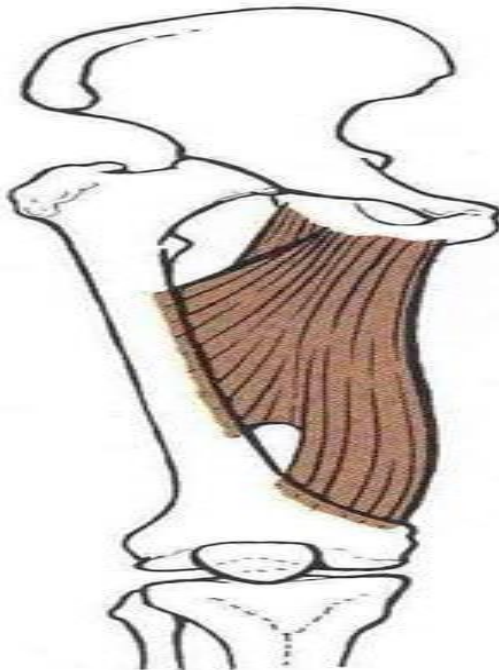**Adductor Brevis**

Muscle	Origin	Insertion	Nerve Supply
Adductor Brevis	Posterior border of femur .	Posterior border of femur	Obturator nerve



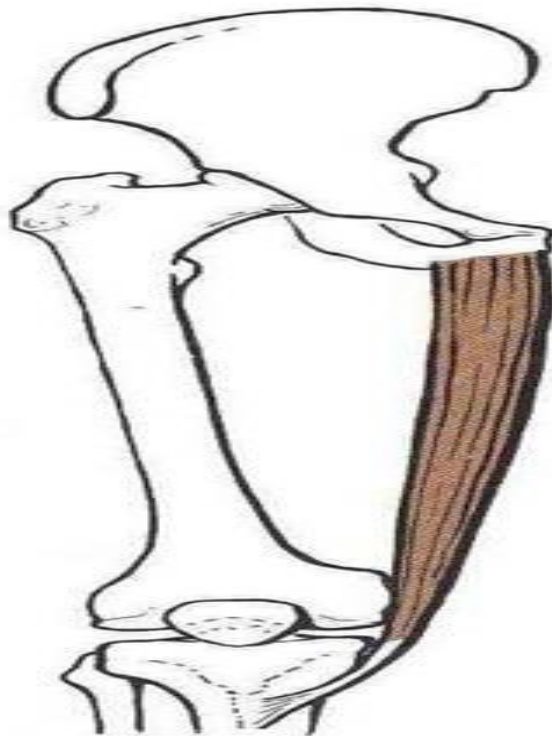**Adductor Magnus (adductor pt.)**

Muscle	Origin	Insertion	Nerve Supply
Adductor Magnus (adductor pt.)	Adductor pt.: linea aspera of femur	Inferior pubic ramus + ischial ramus	Obturator nerve



**Gracilis**

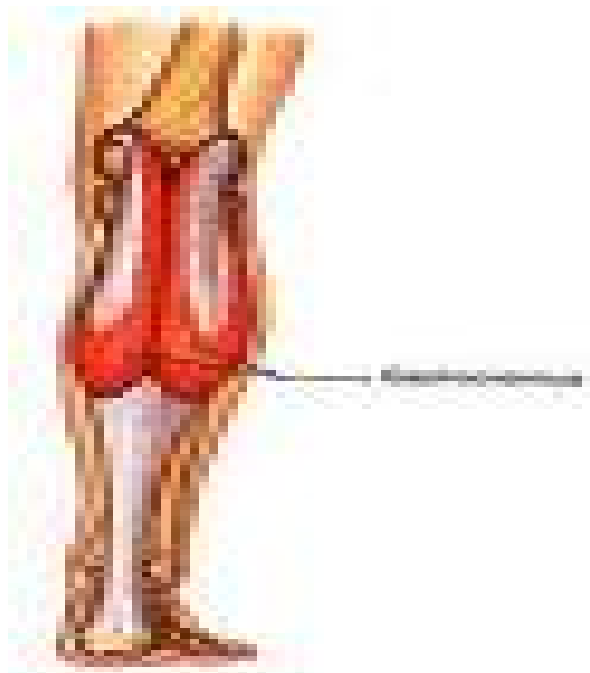
Muscle	Origin	Insertion	Nerve Supply
Gracilis	Upper part of medial surface of tibia (behind sartorius)	Inferior pubic ramus + ischial ramus	Obturator nerve



## *\*Muscles of the leg (back)\**

### *SUPERFICIAL GROUP:*

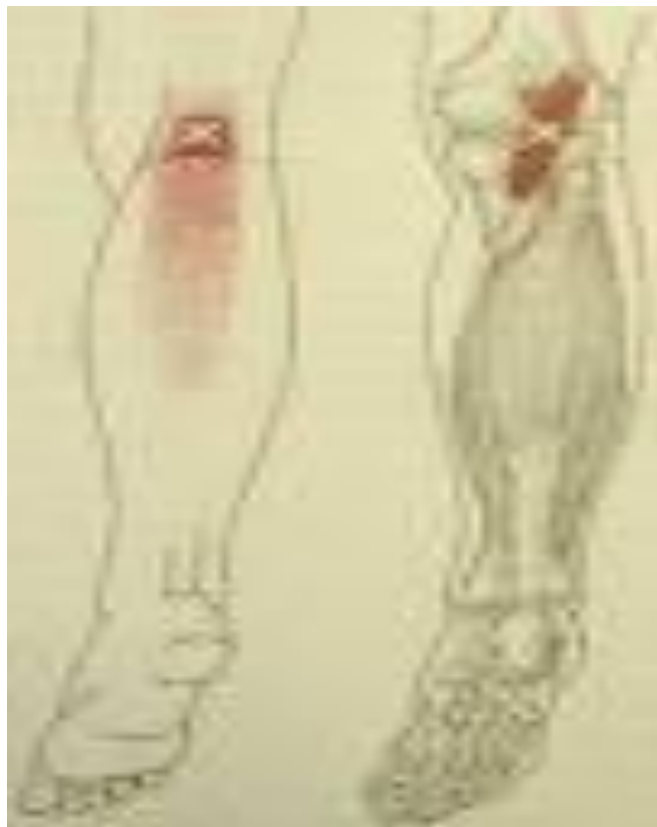Muscle	Origin	Insertion	Nerve Supply
Gastrocnemius	1-lateral head lateral condyle of femur. 2-medial head popliteal surface of femur above medial condyle	Via tendo- calcaneus into posterior surface of calcaneum	Tibial nerve





plantaris

Muscle	Origin	Insertion	Nerve Supply
<i>plantaris</i>	Lateral supracondylar ridge.	Posterior surface of calcaneum	Tibial nerve



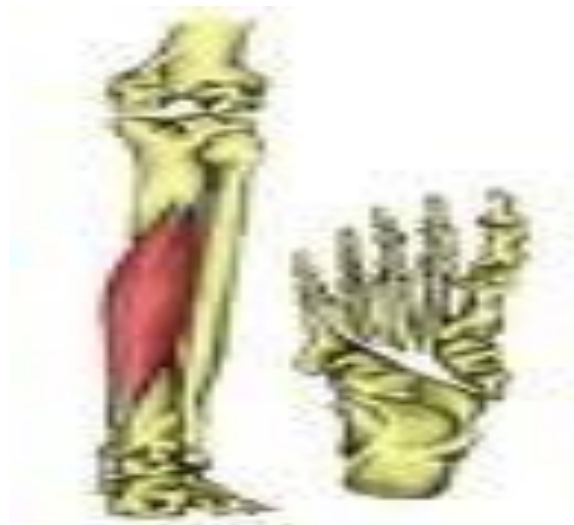## soleus

Muscle	Origin	Insertion	Nerve Supply
<i>soleus</i>	Shaft of tibia & fibula.	Via tendo-calcaneus into posterior surface of calcaneum	Tibial nerve



*Flexor digitorum longus*

Muscle	Origin	Insertion	Nerve Supply
<i>Flexor digitorum longus</i>	Posterior surface of shaft of tibia.	Bases of distal phalanges of lateral 4 toes.	Tibial nerve



*Flexor hallucis longus*

Muscle	Origin	Insertion	Nerve Supply
<i>Flexor hallucis longus</i>	Posterior surface of shaft of fibula.	Base of distal phalanx of big toe.	Tibial nerve



*Tibialis posterior*

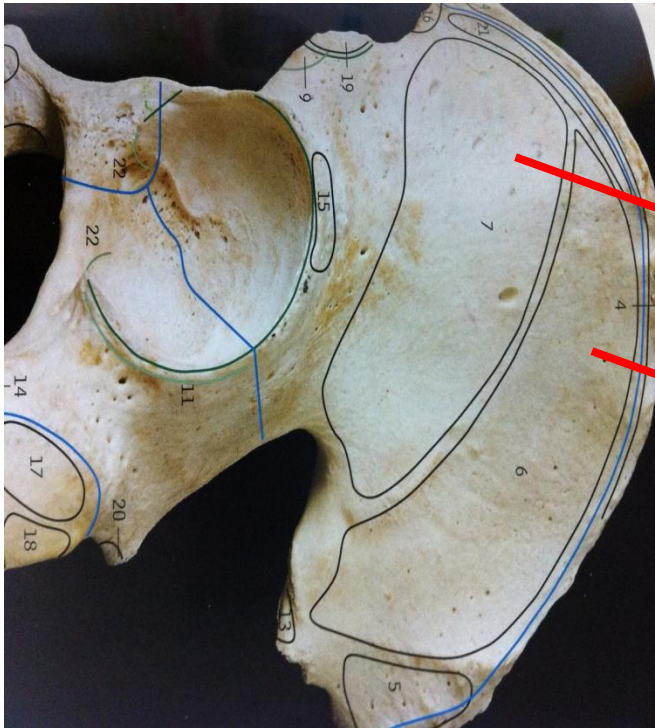
Muscle	Origin	Insertion	Nerve Supply
<i>Tibialis posterior</i>	Posterior surface of tibia & fibula +I.M. .	All tarsal bones EXCEPT talus	Tibial nerve



## Gluteal Region

Gluteus minimus & Gluteus medius

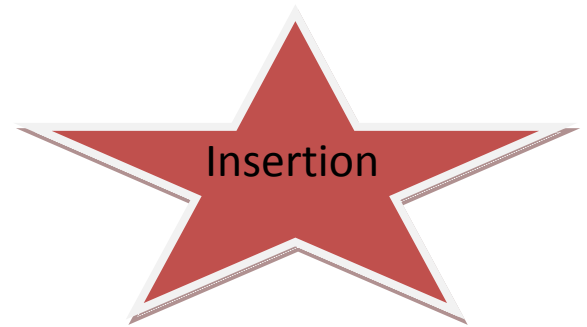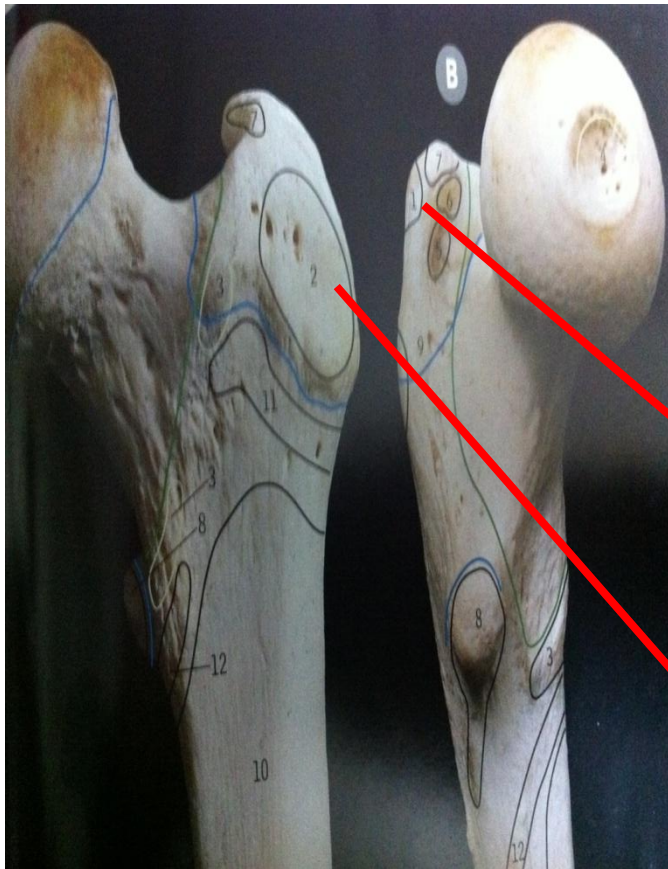Muscle	Origin	Insertion	Nerve Supply
Gluteus minimus	Anterior part of gluteal surface of ilium	Anterior surface of the greater trochanter	Superior gluteal nerve
Gluteus medius	Middle part of gluteal surface of ilium	lateral surface of the greater trochanter	Superior gluteal nerve



Origin

Gluteus minimus

Gluteus medius



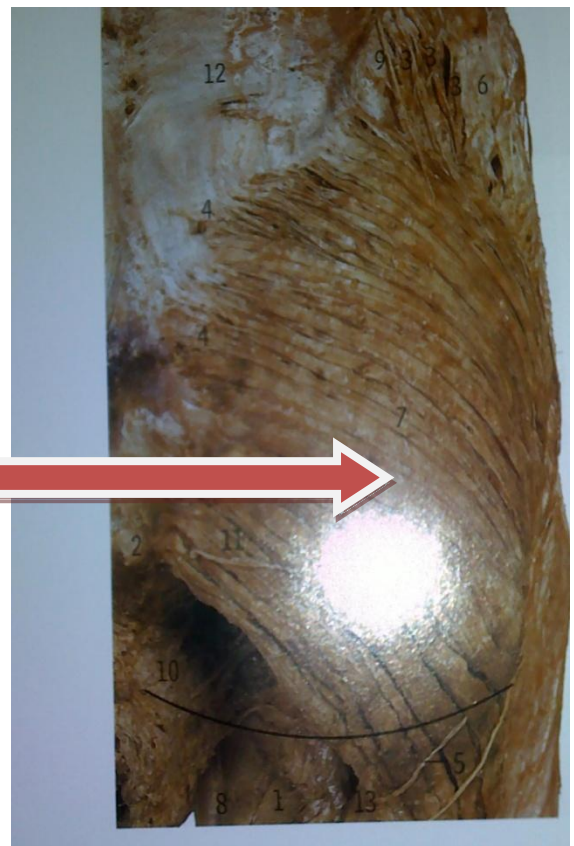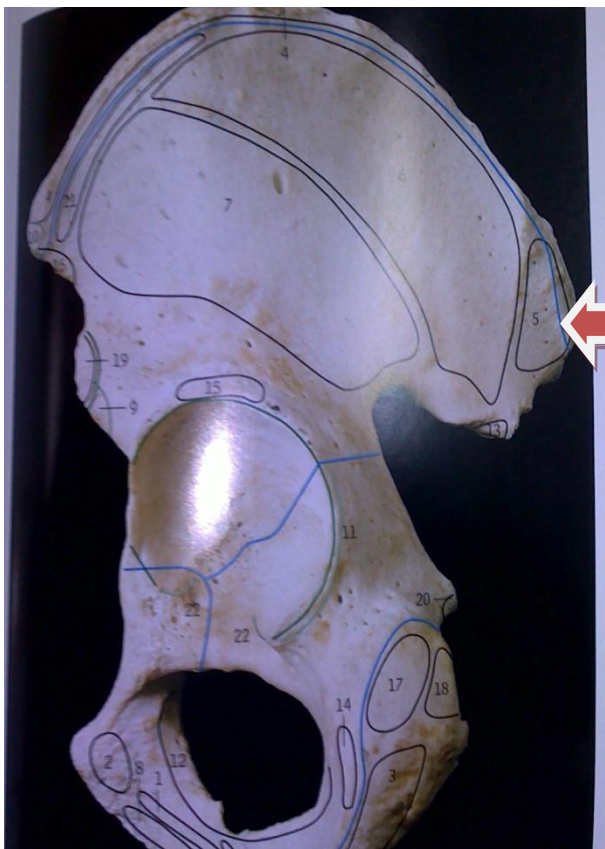
Gluteus medius

Gluteus minimus



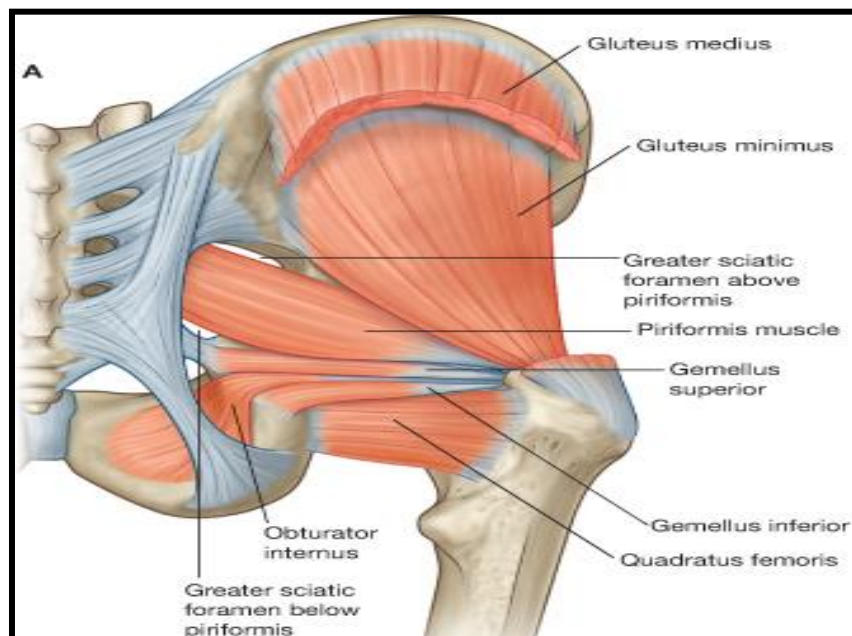
**Gluteus maximus**

Muscle	Origin	Insertion	Nerve Supply
<b>Gluteus maximus</b>	<b>Posterior part of the gluteal surface of ilium,</b>	<b>Iliotibial tract</b> <b>Other insertion: gluteal tuberosity of femur.</b>	<b>Inferior gluteal nerve</b>



## Small Muscles ( Piriformis, Quadratus femoris, Obturator Internus, Superior gemellus, Inferior gemellus)

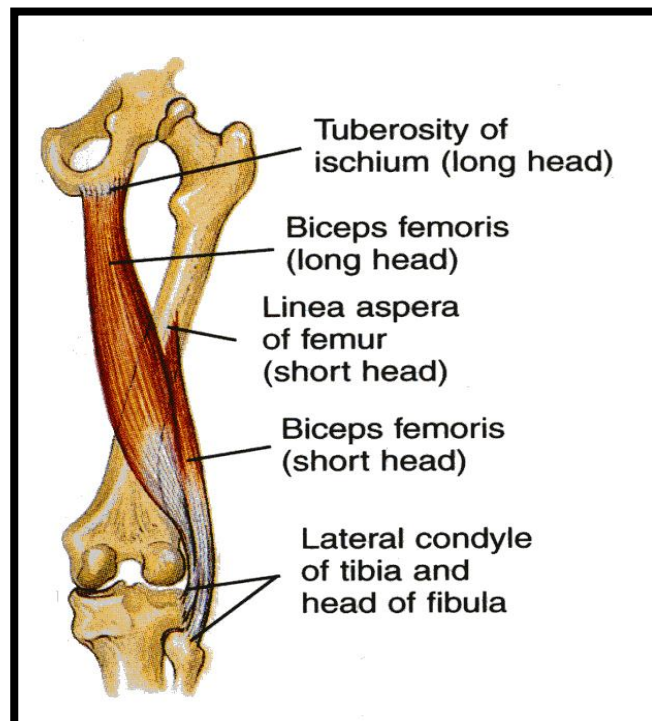
Muscle	Origin	Insertion	Nerve Supply
Piriformis	Pelvic surface of middle 3 sacral vertebrae.	Pelvic surface of middle 3 sacral vertebrae.	Anterior rami of S1,2
Quadratus femoris	Lateral border of the ischial tuberosity.	Quadratus tubercle & intertrochanteric crest	Nerve to quadratus femoris.
Obturator Internus	Inner surface of the side wall of the pelvis.	Into the upper border of greater trochanter.	Nerve to obturator internus
Superior gemellus	upper part of lesser sciatic notch	Upper & lower parts into tendon of obturator internus	nerve to obturator internus
Inferior gemellus	lower part of lesser sciatic notch.		nerve to quadratus femoris.



# Posterior Compartment of Thigh

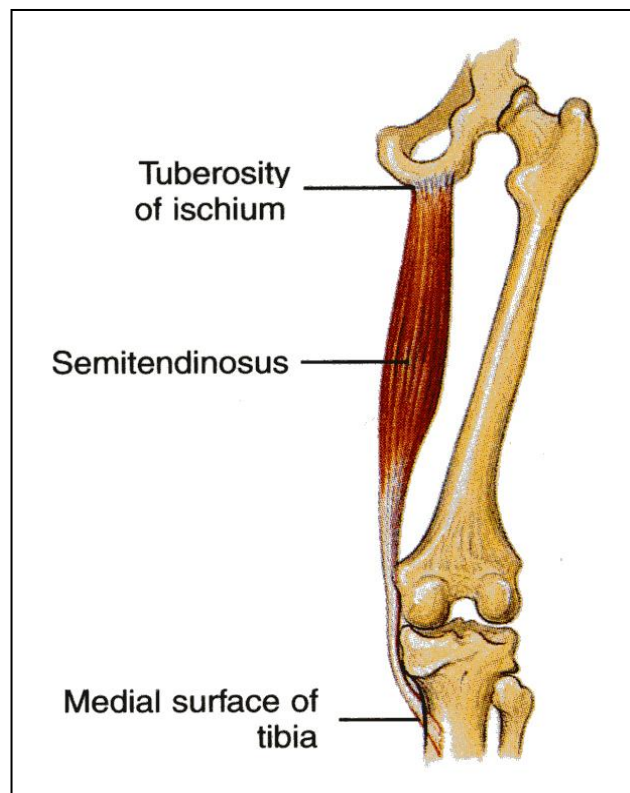
## Hamstring muscles

Muscle	Origin	Insertion	Nerve Supply
<b>Biceps Femoris</b>	<p>-The long head from the ischial tuberosity. By common tendon with semitendinosus.</p> <p>-The short head from the linea aspera</p>	the head of the fibula	<p>-The long head is supplied by the tibial part of the sciatic;</p> <p>-the short head is supplied by the common peroneal part of the sciatic</p>



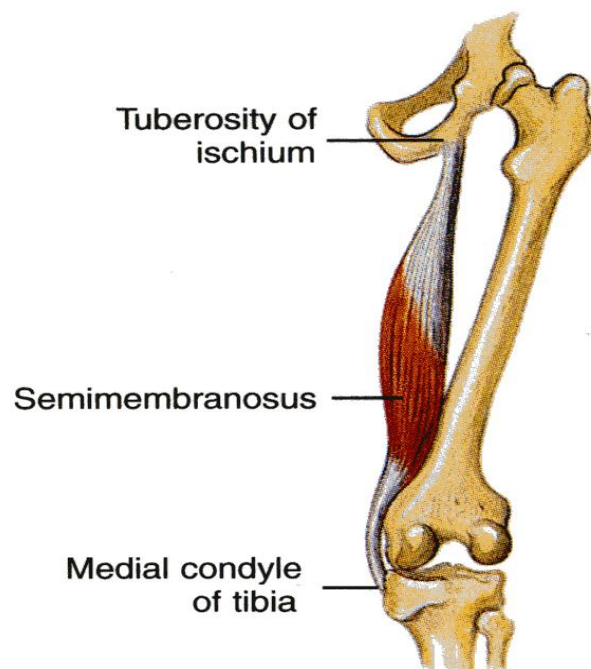
**SEMITENDINOSUS**

Muscle	Origin	Insertion	Nerve Supply
SEMITENDINOSUS	From the ischial tuberosity	upper part of the medial surface of the shaft of the tibia (SGS) < سنة (= جدي سعيدة)	Tibial portion of the sciatic



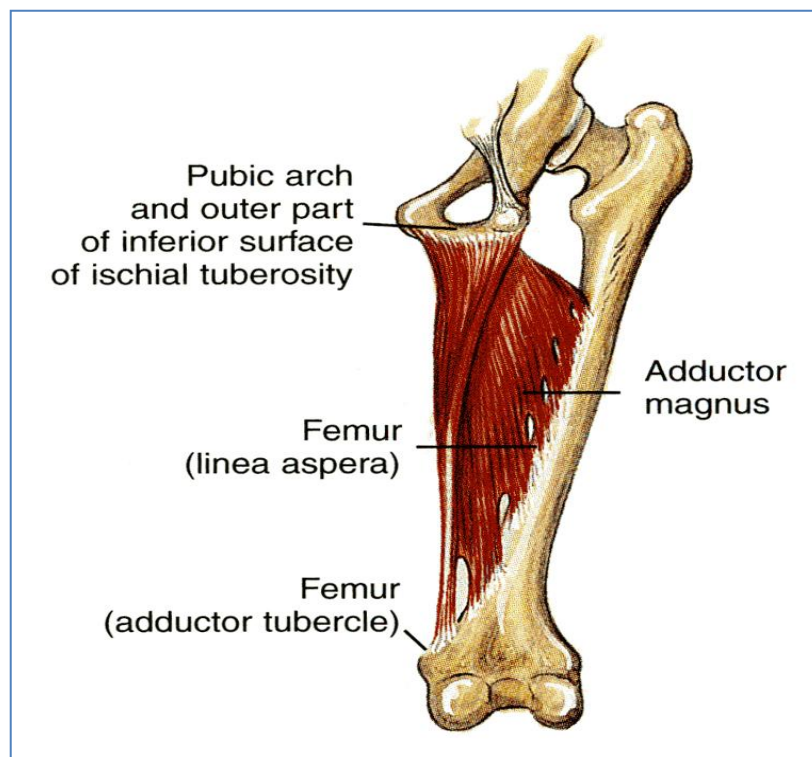
**SEMIMEMBRANOSUS**

Muscle	Origin	Insertion	Nerve Supply
<b>SEMIMEMBRANOSUS</b>	<b>From the ischial tuberosity</b>	<b>Into the posteromedial surface of the medial condyle of the tibia</b>	<b>The tibial portion of the sciatic</b>



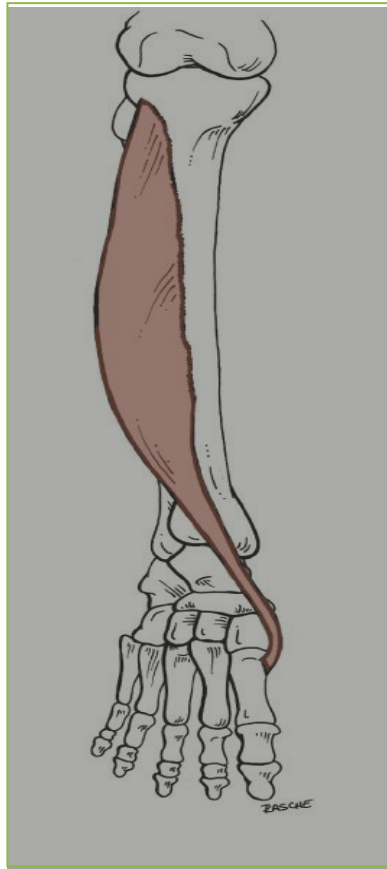**ADDUCTOR MAGNUS (HAMSTRING PART)**

Muscle	Origin	Insertion	Nerve Supply
<b>ADDUCTOR MAGNUS</b>	From the ramus of the ischium and the ischial tuberosity	Adductor tubercle of the medial condyle of the femur.	Tibial portion of the sciatic



## Anterior compartment of Leg

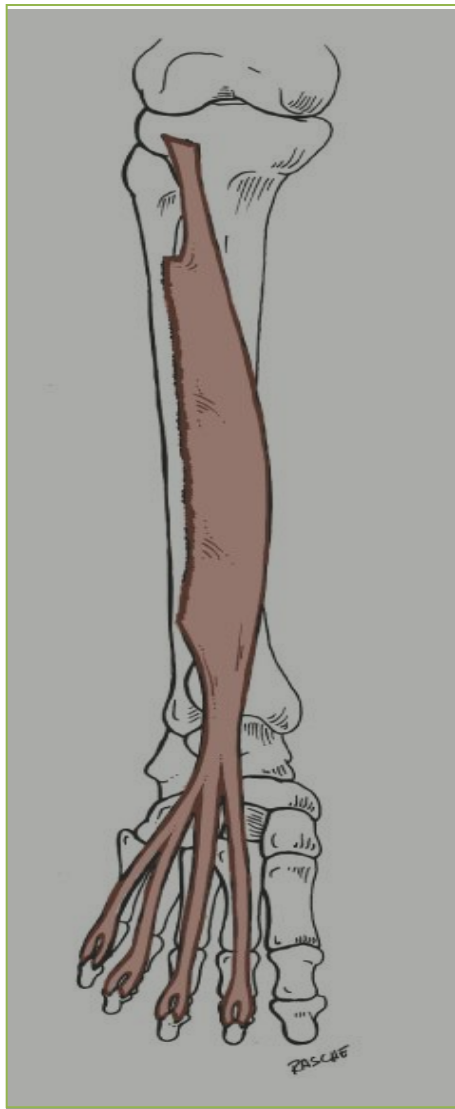
### TIBIALIS ANTERIOR



Muscle	Origin	Insertion	Nerve Supply
<b>TIBIALIS ANTERIOR</b>	Lateral Surface of Shaft of Tibia & Interosseous Membrane	Medial Cuneiform & Base of First Metatarsal Bone	Deep Peroneal Nerve



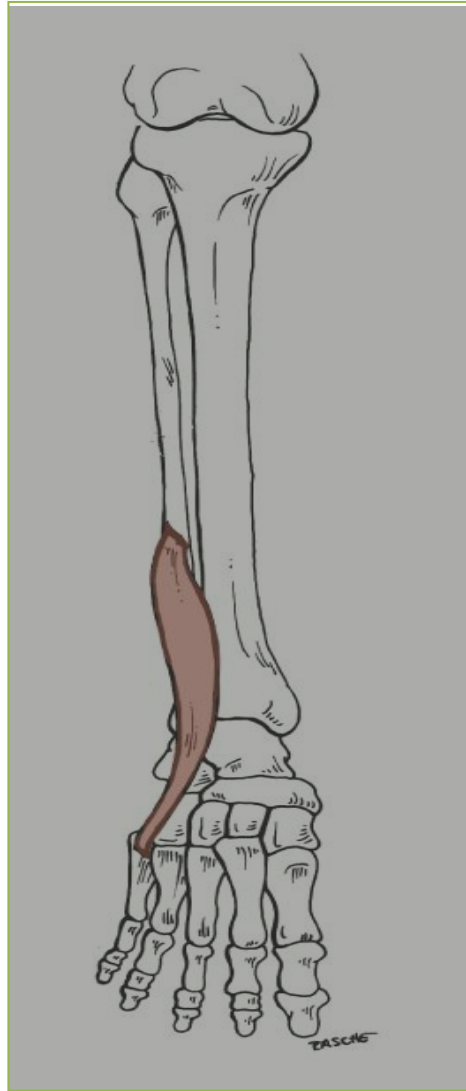## EXTENSOR DIGITORUM LONGUS



Muscle	Origin	Insertion	Nerve Supply
<u>EXTENSOR DIGITORUM LONGUS</u>	Anterior Surface of Shaft of Fibula	Extensor Expansion of Lateral Four Toes	Deep Peroneal Nerve

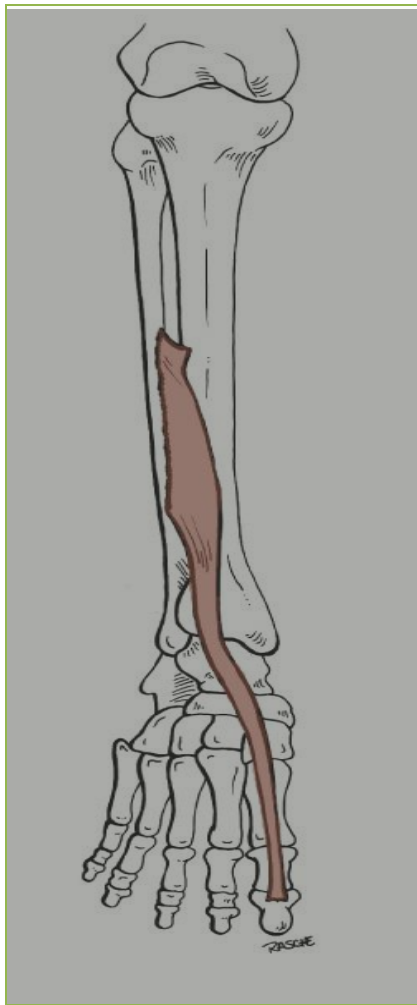

## PERONEUS TERTIUS



Muscle	Origin	Insertion	Nerve Supply
Peroneus tertius	Anterior Surface of Shaft of Fibula	Base of 5 <sup>th</sup> Metatarsal Bone	Deep Peroneal Nerve

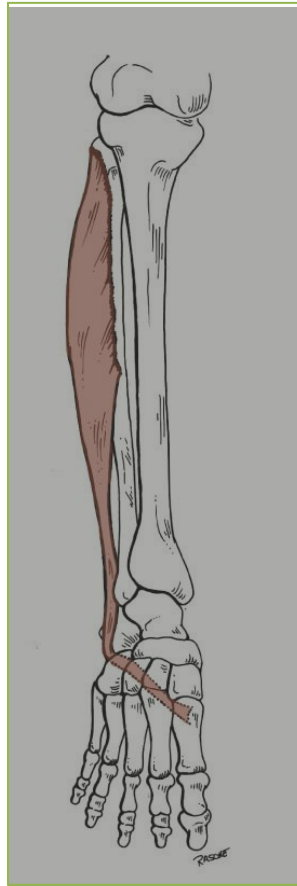
## EXTENSOR HALLUCIS LONGUS



Muscle	Origin	Insertion	Nerve Supply
Extensor hallucis longus	Anterior Surface of Shaft of Fibula	Base of Distal Phalanx of Great Toe	Deep Peroneal Nerve

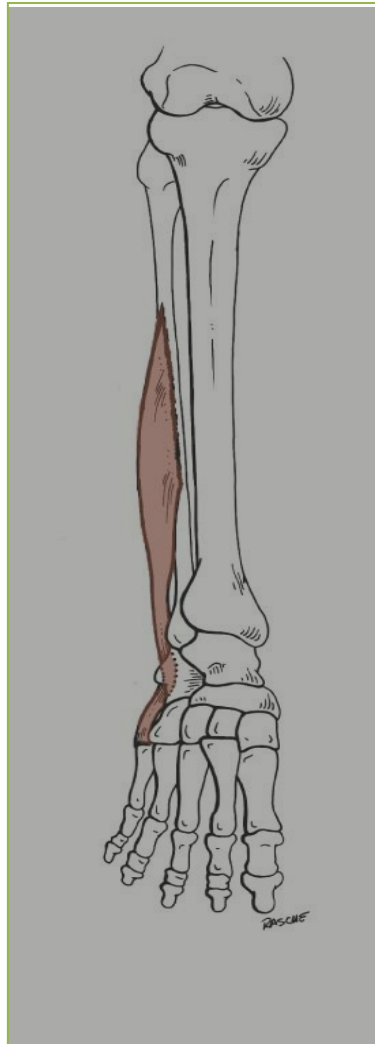
## Lateral Compartment of Leg

### PERONEUS LONGUS



Muscle	Origin	Insertion	Nerve Supply
Peroneus Longus	Lateral Surface of Shaft of Fibula	Base of First Metatarsal & The Medial Cuneiform	Superficial Peroneal Nerve

## PERONEUS BREVIS



Muscle	Origin	Insertion	Nerve Supply
Peroneus Brevis	Lateral Surface of Shaft of Fibula	Base of Fifth Metatarsal Bone	Superficial Peroneal Nerve

Done by :

The anatomy team:

*Samar Shetawe.      Mohanned Al Essa.*

*Ayan Hussain.          Aos Aboabat.*

*Mayyadah Al-Abdely.    Haya Al-Otaibi.*

*Hanan Al.salman.*