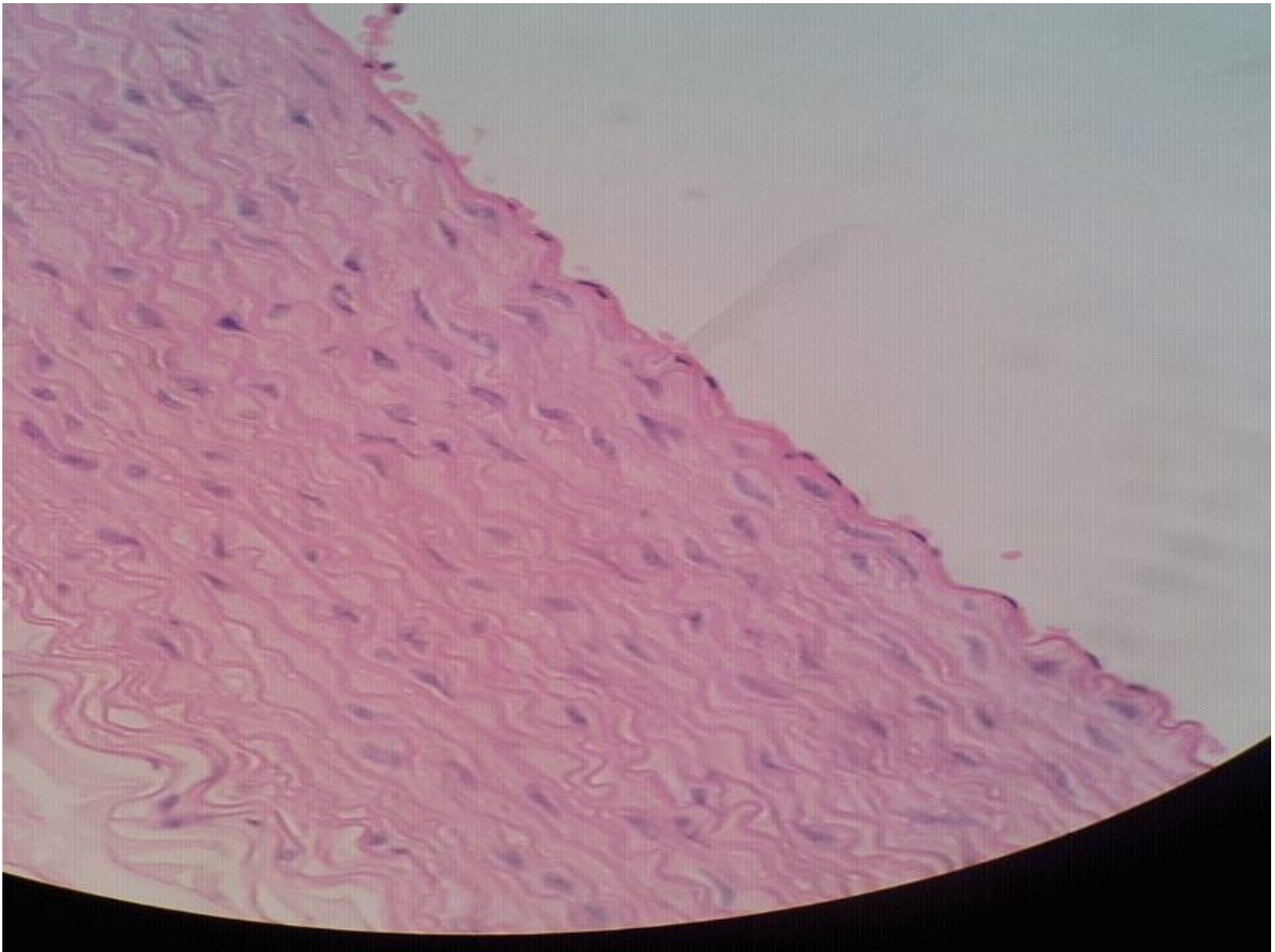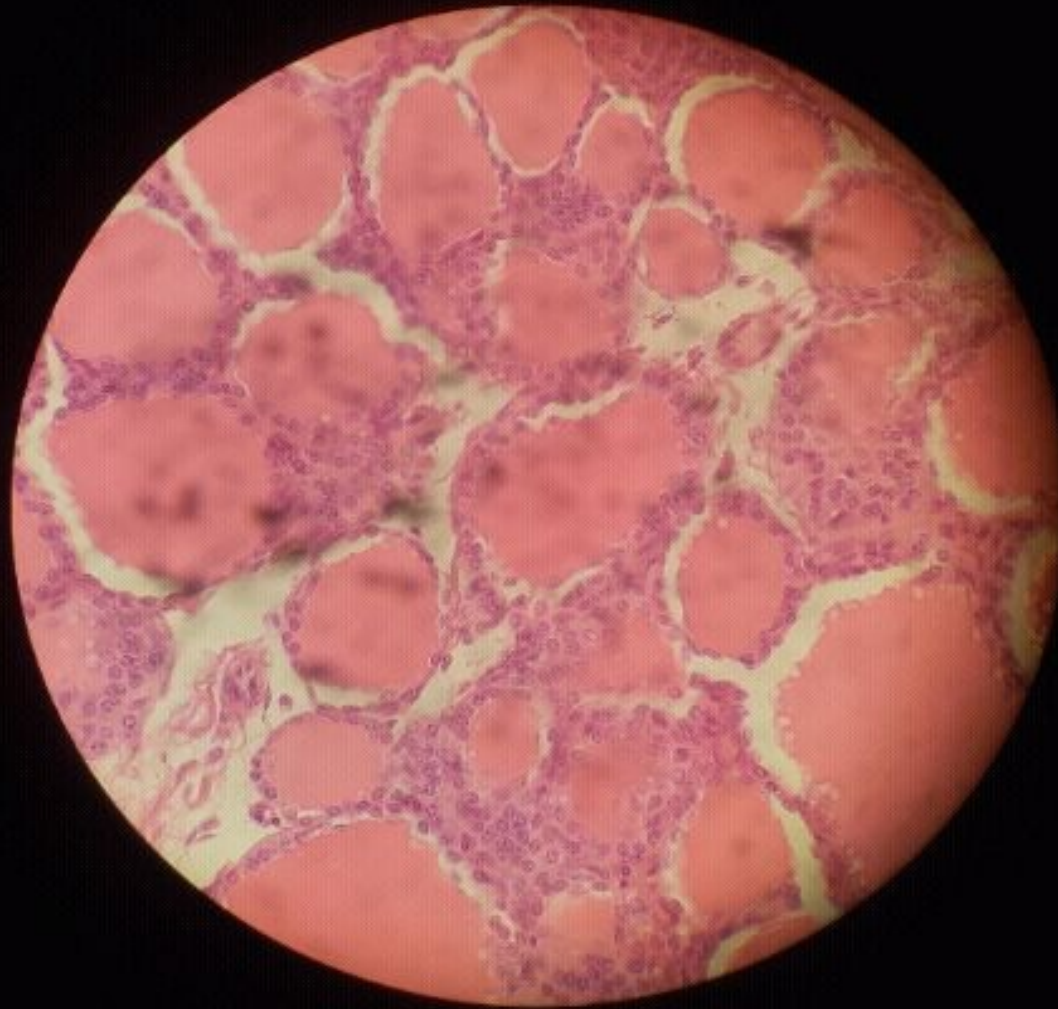
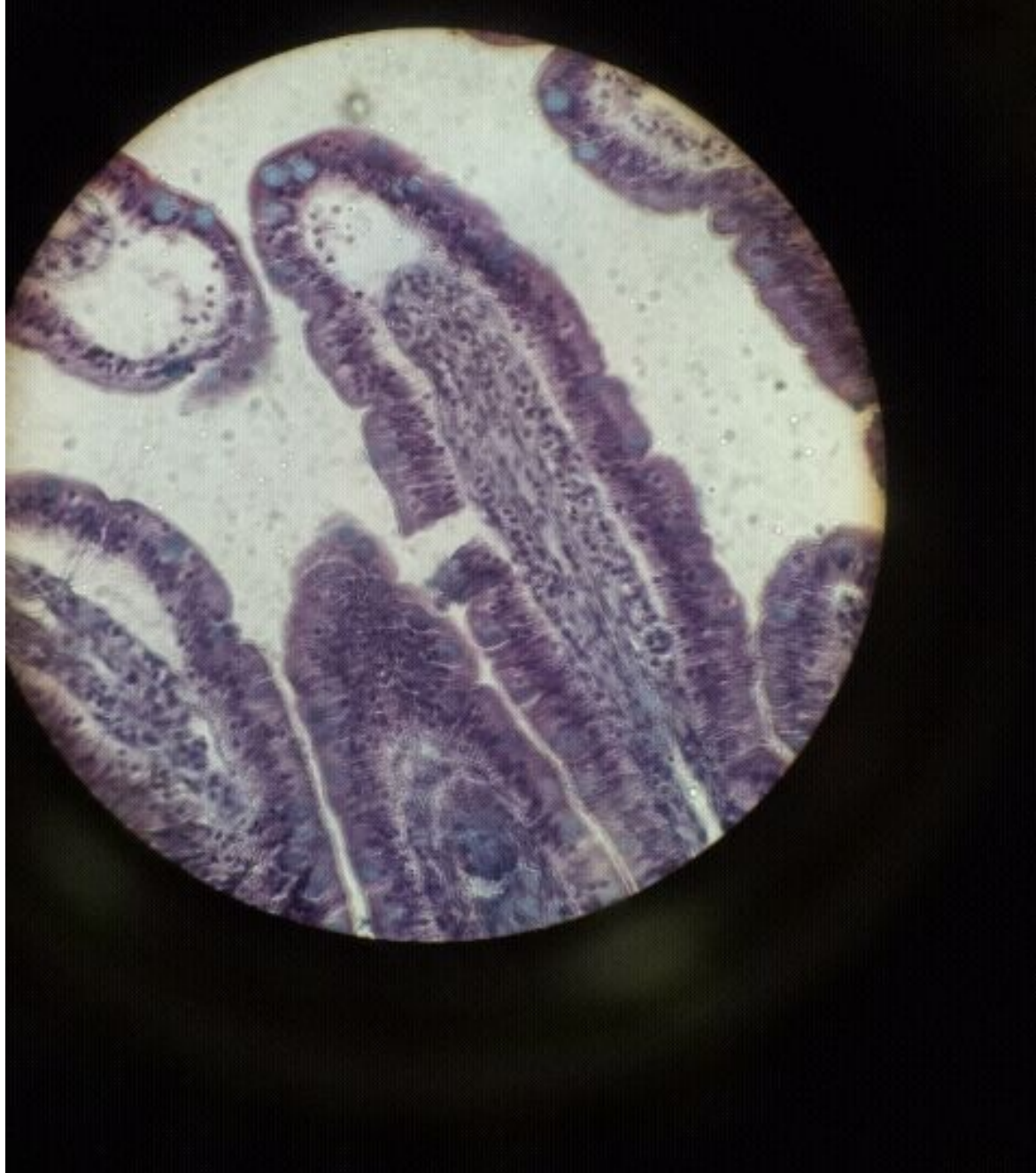


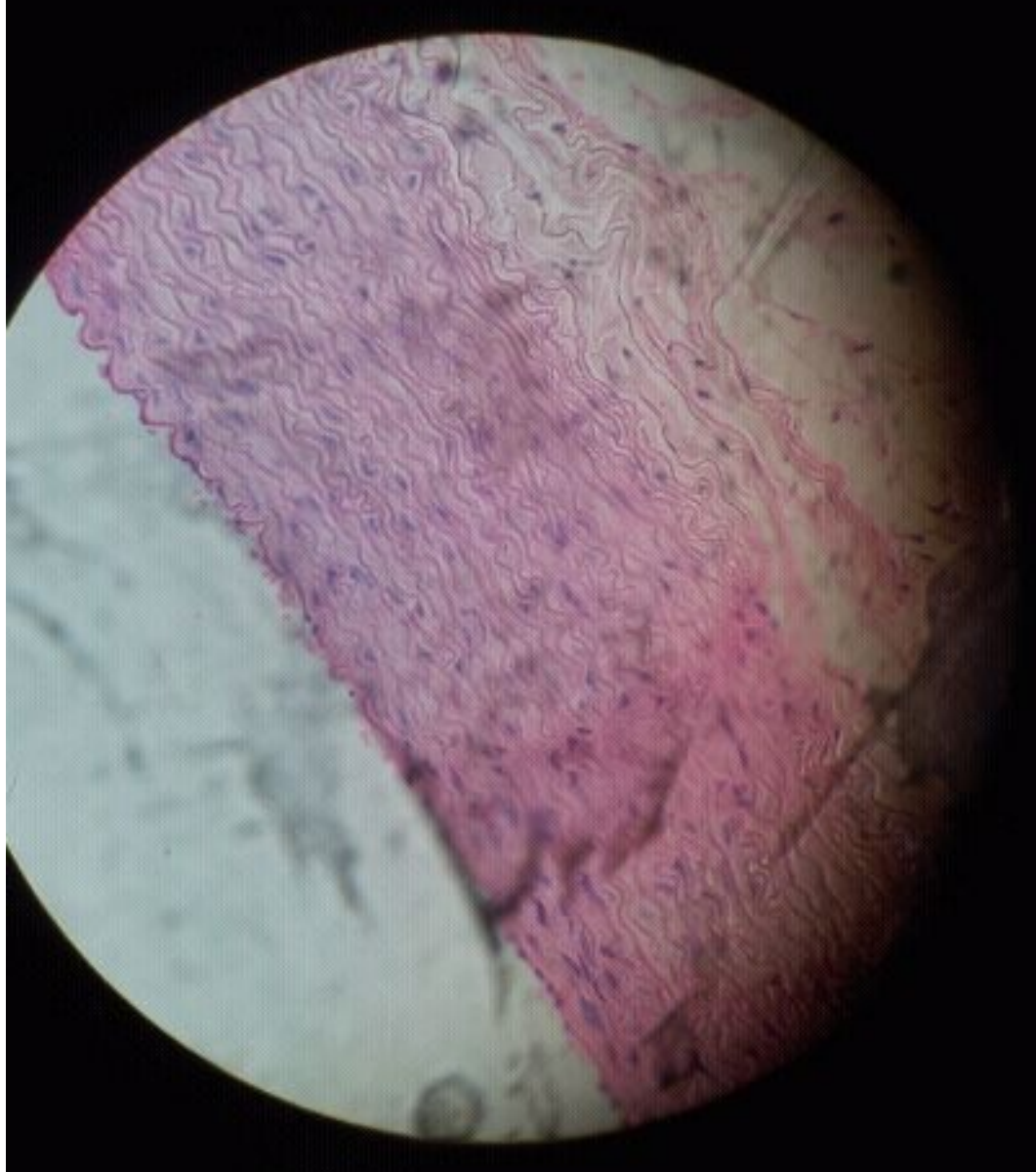
**Simple squamous epithelium**



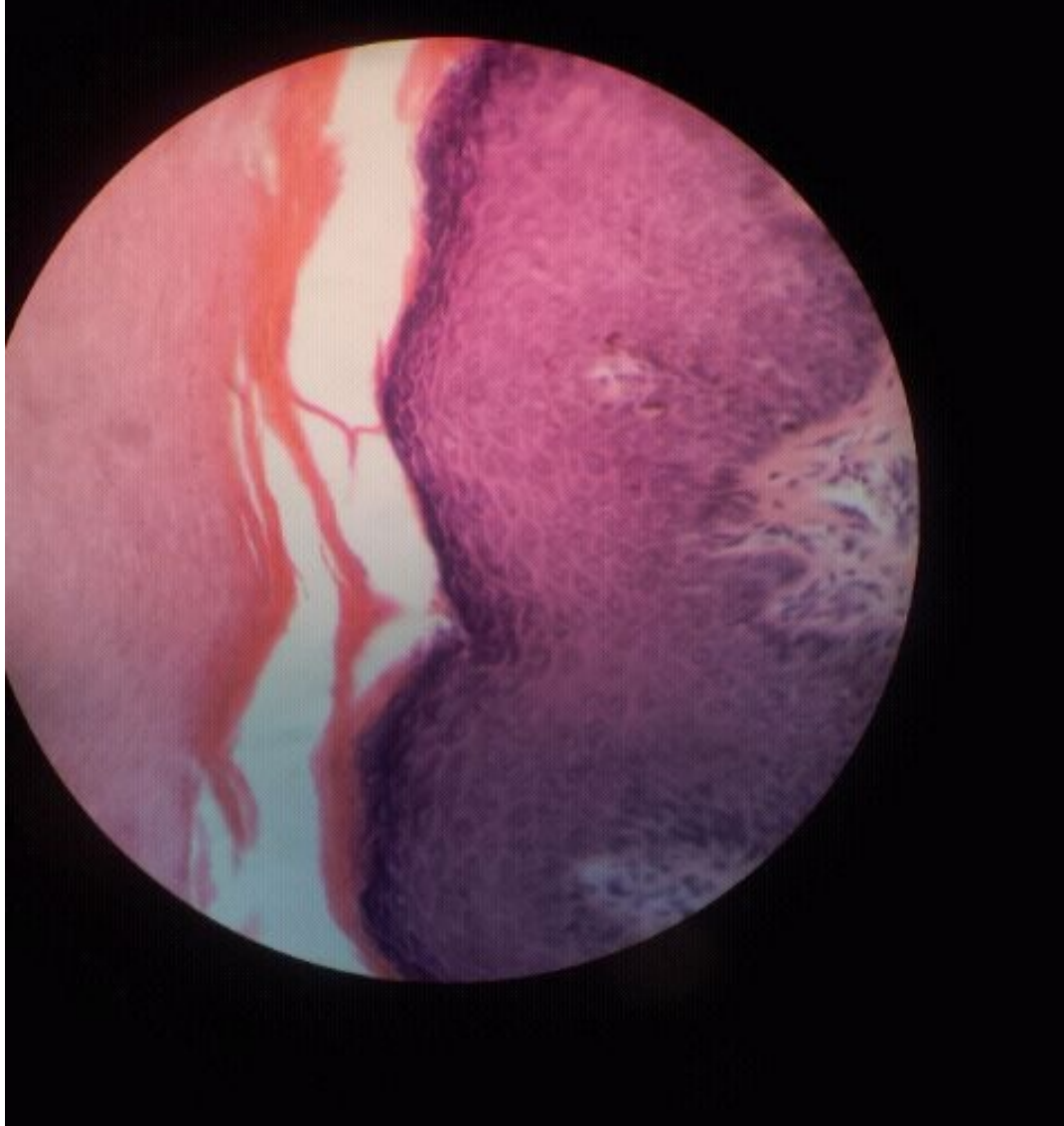**Simple cuboidal epithelium**



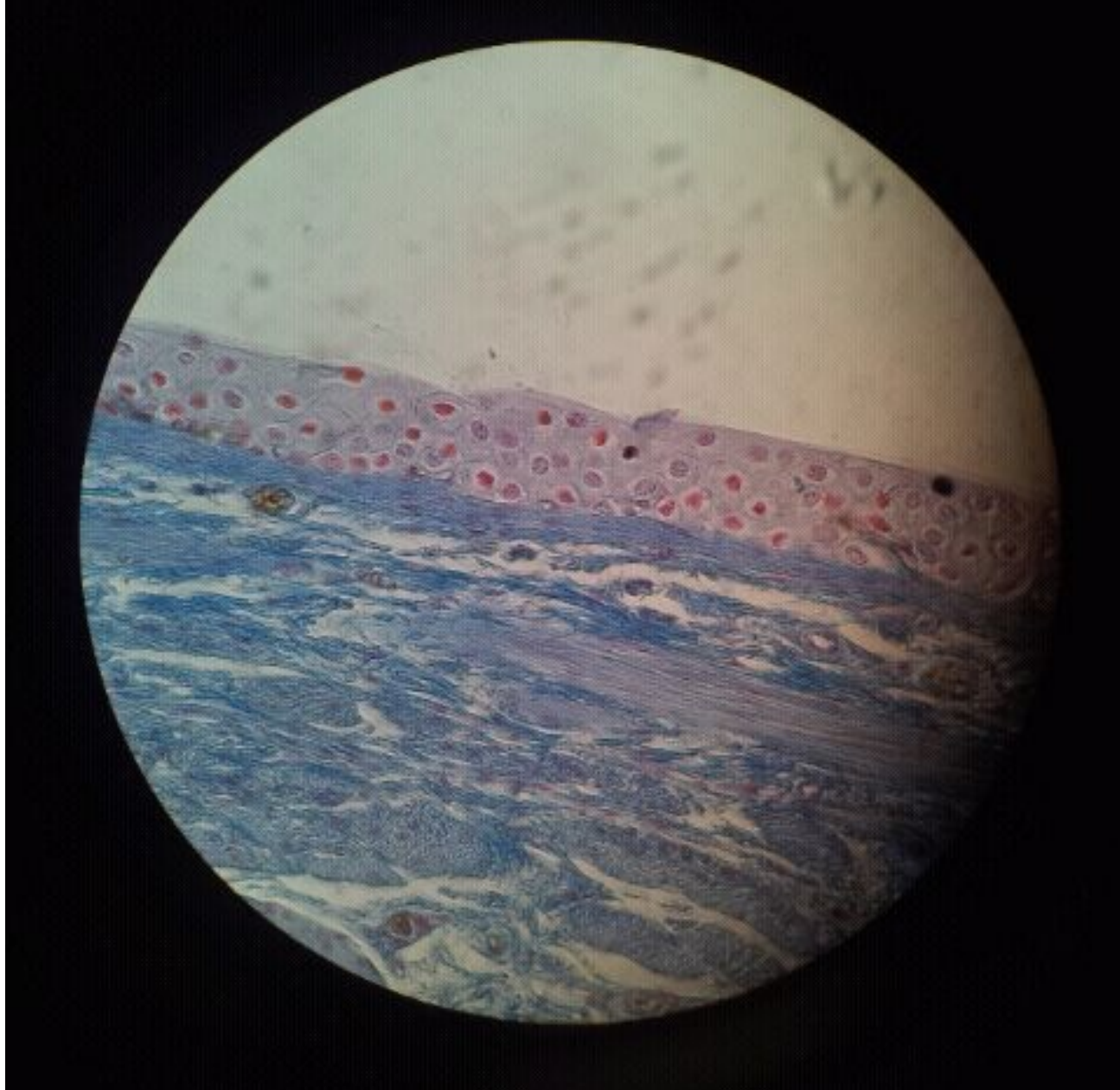
**Simple columnar epithelium**



**Non-keratinized stratified squamous epithelium**



**Keratinized stratified squamous epithelium**



**Transitional epithelium**