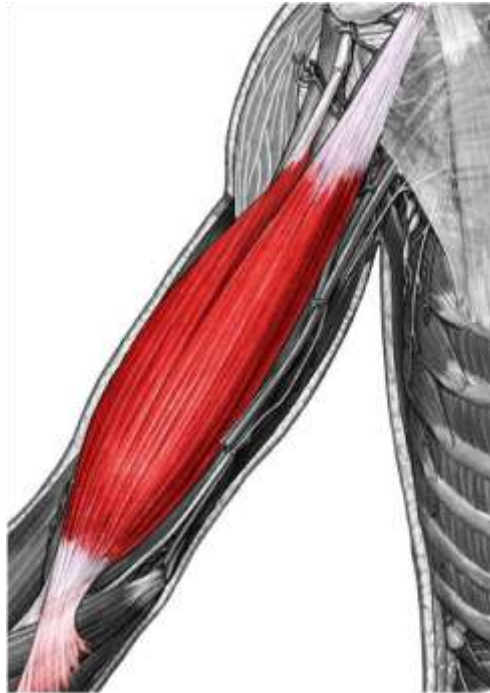




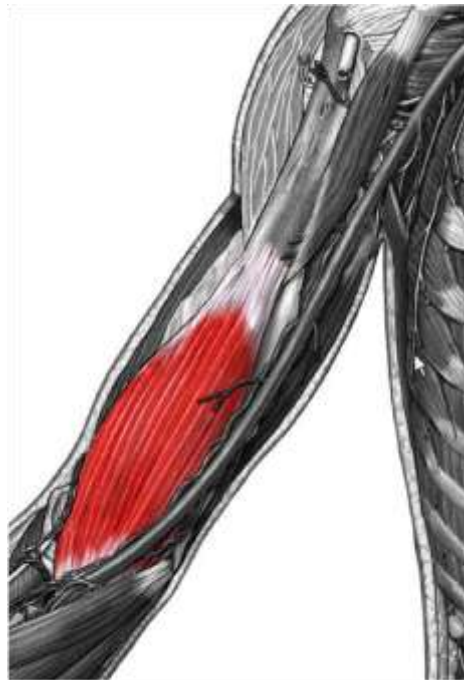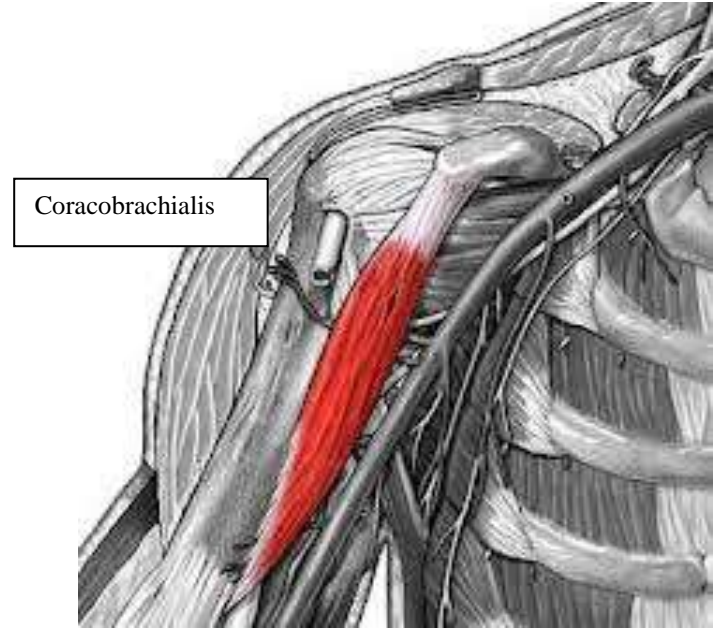
Anatomy team
Upper limb muscles practical

Ethar Ali Alqarni

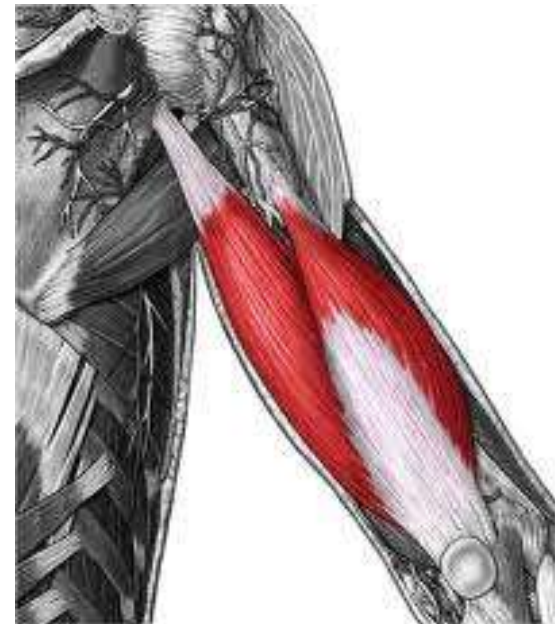Region	Muscle	Function	Origin	Insertion
Anterior Arm	Biceps brachii	Flex shoulder Flex elbow Supinate when elbow is flexed	Long head: supraglenoid tubercle Short head: coracoid process	Bicipital aponeurosis and radial tuberosity
	Coracobrachialis	Flex shoulder Adduct shoulder	Coracoid process	Upper medial humerus
	Brachialis	Flex elbow	Distal anterior humerus shaft	Coronoid process
Posterior Arm	Triceps brachii	Extend elbow	Long head: infraglenoid tubercle Short and medial head: posterior humerus shaft	Olecranon process of ulna
Superficial flexor forearm	Pronator teres	Pronation Flex elbow	Medial condyle humerus, coronoid process of ulna	Middle lateral radius
	Flexor carpi radialis	Flex wrist Abduct wrist	Medial epicondyle humerus	Base metacarpal 2
	Palmaris longus	Flex wrist	Medial epicondyle humerus	Palmar aponeurosis
	Flexor carpi ulnaris	Flex wrist Adduct hand	Humeral head: Medial epicondyle humerus Ulnar head: Olecranon/posterior ulna	Pisiform Hamate hook Metacarpal 5
	Flexor digitorum superficialis	Flex metacarpo-phalangeal and prox. interphalangeal 2-5	Medial epicondyle humerus, coronoid process, upper anterior radius	Middle phalanges 2-5



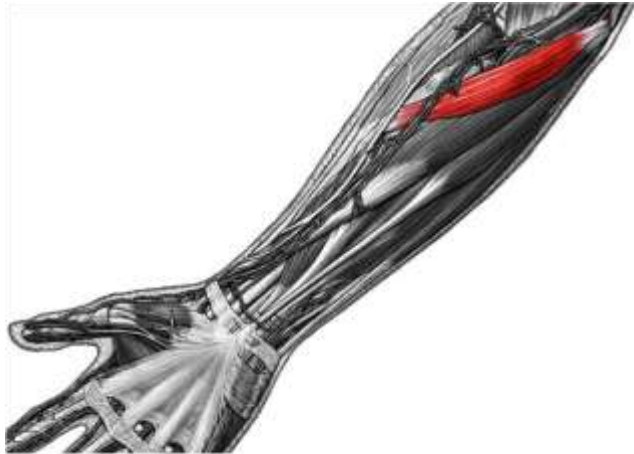biceps brachii



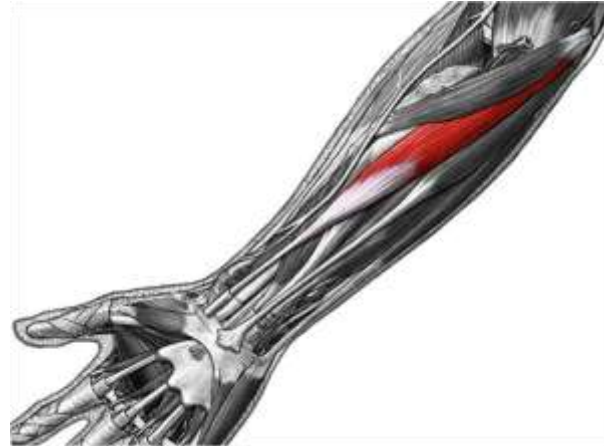brachialis



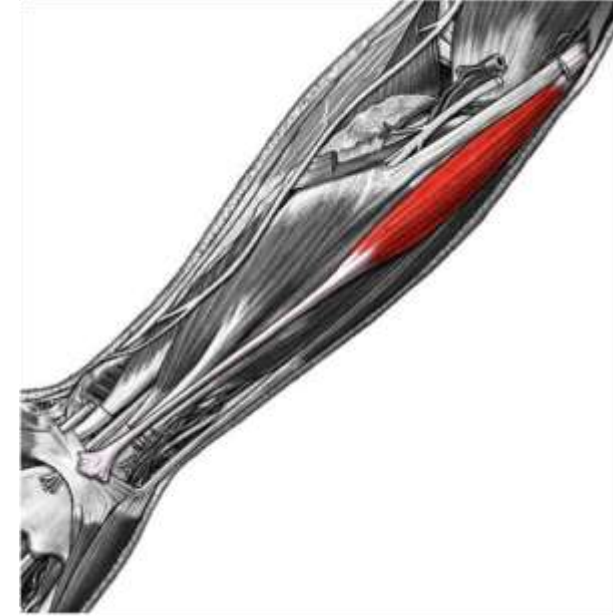triceps brachii



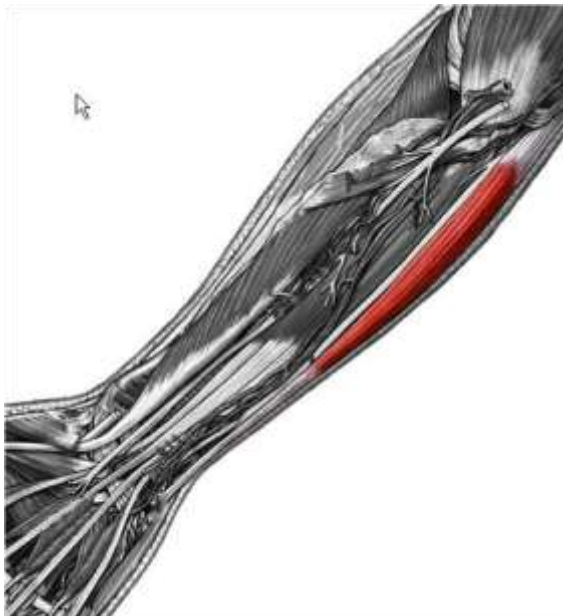Pronator teres



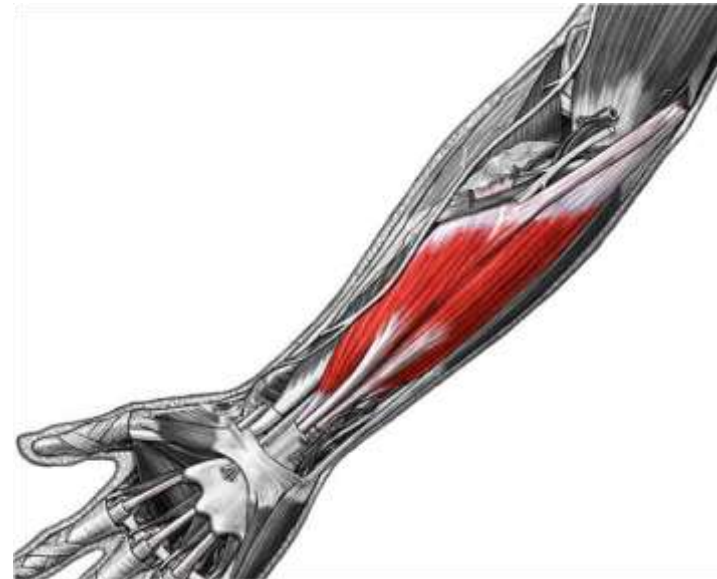flexor carpi radialis



Palmaris longus

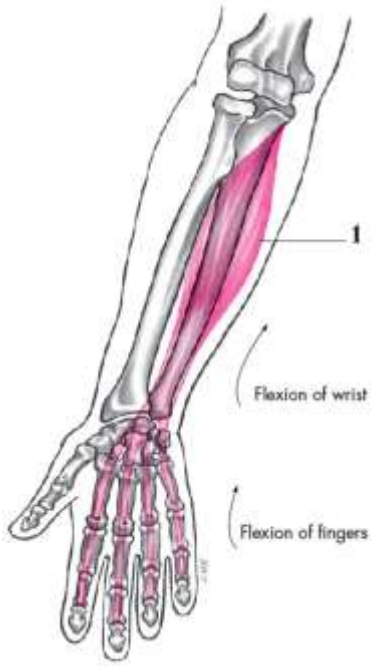

Flexor carpi ulnaris (anterior view)

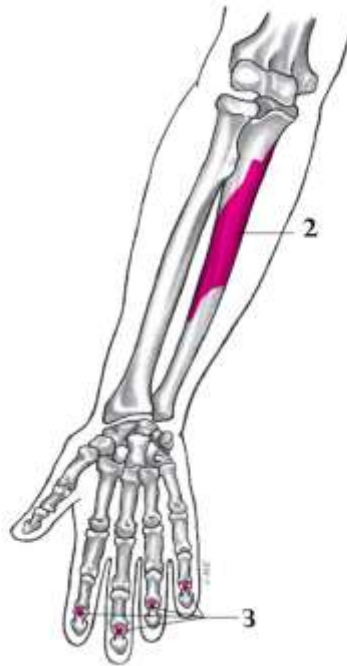


flexor digitorum superficialis

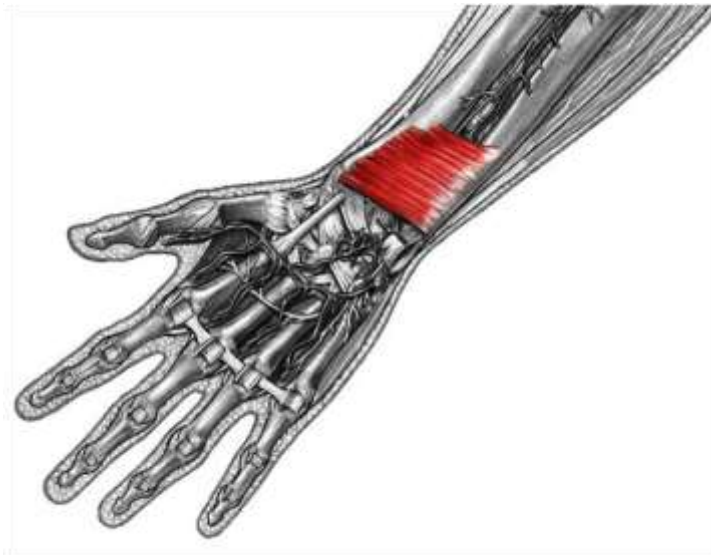
Region	Muscle	Function	Origin	Insertion
Deep flexor forearm	Flexor digitorum profundus	Flex entire fingers 2-5	Proximal 3/4 anteromedial ulna	Body middle phalanges 2-5
	Flexor pollicis longus	Flex metacarpo-phalangeal 1	Anterior radius	Base distal phalanx 1
	Pronator quadratus	Pronation	Distal anterior ulna	Distal anterior radius
Superficial extensor forearm	Extensor carpi ulnaris	Extend wrist Adduct wrist	Lateral epicondyle humerus Posterior ulna	Base metacarpal 5
	Extensor digiti minimi	Extend entire finger 5	Lateral epicondyle humerus	Extensor expansion digit 5
	Extensor digitorum	Extend entire fingers 2-5 Extend wrist	Lateral epicondyle humerus	Extensor expansion digits 2-5
Deep extensor forearm	Supinator	Supination	Lateral humerus and elbow ligaments	Wraps around radius shaft
	Abductor pollicis longus	Abduct thumb	Middle posterior radius and ulna	Base metacarpal 1
	Extensor pollicis brevis	Extends thumb carpometacarpal	Posterior radius	Proximal phalanx 1
	Extensor pollicis longus	Extend entire thumb	Middle posterior ulna	Base distal phalanx 1
	Extensor indicis	Extend index finger Help extend wrist	Posterior ulna	Extensor expansion digit 2
	Anconeus	Assist triceps in elbow flexion	Lateral epicondyle humerus	Olecranon



Flexor digitorum profundus

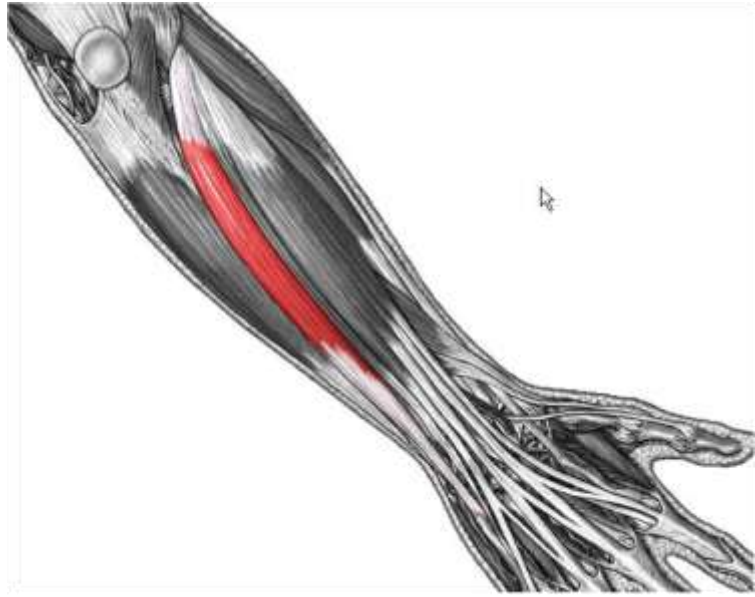


Flexor pollicis longus

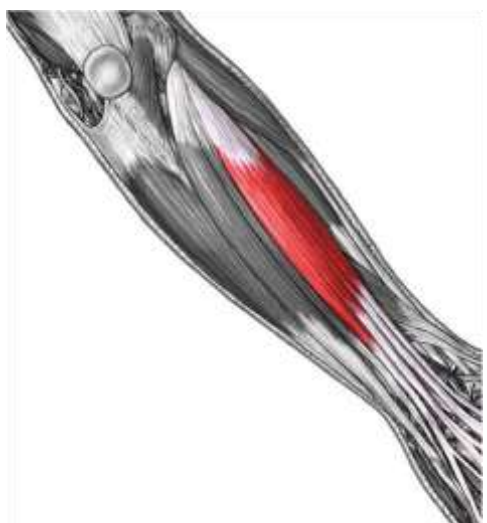
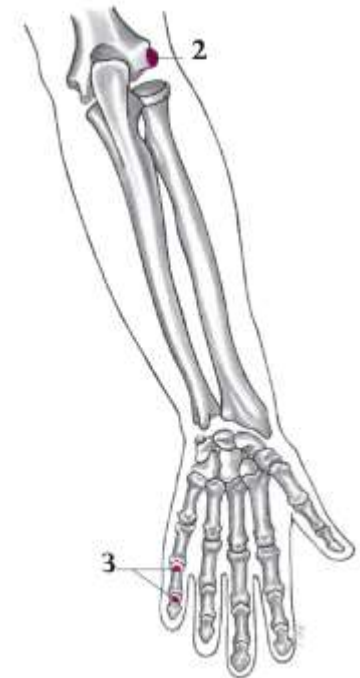
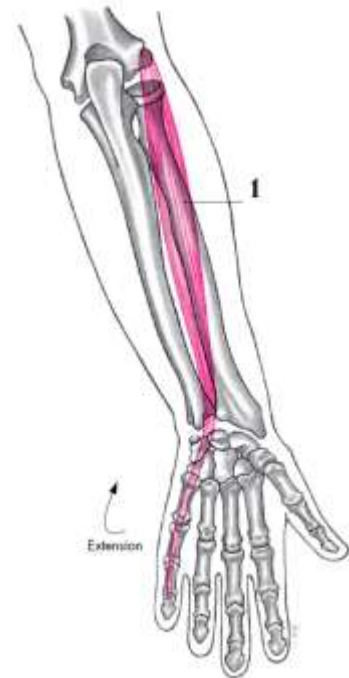


Pronator quadratus

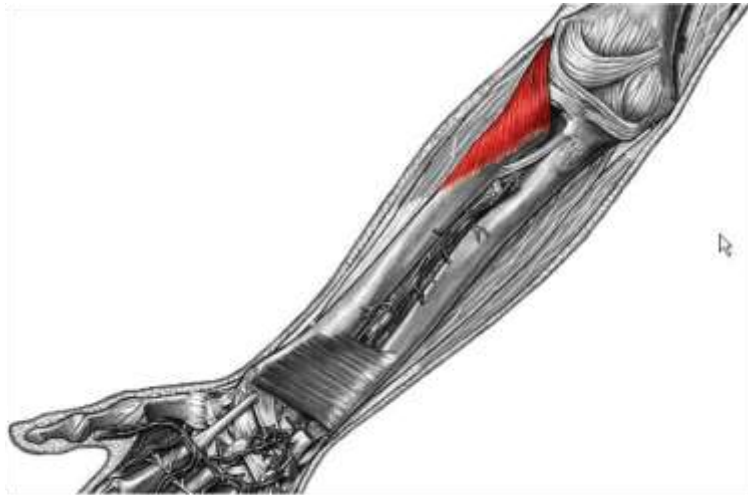Extensor digiti minimi



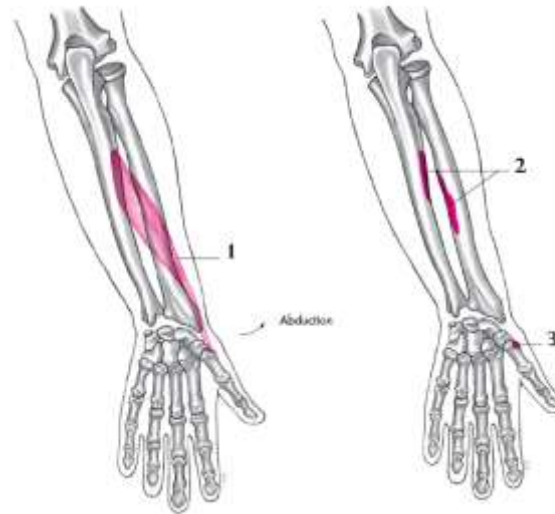extensor carpi ulnaris



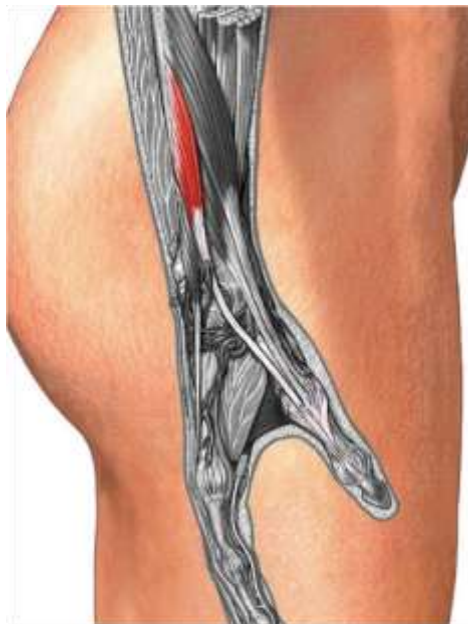extensor digitorum



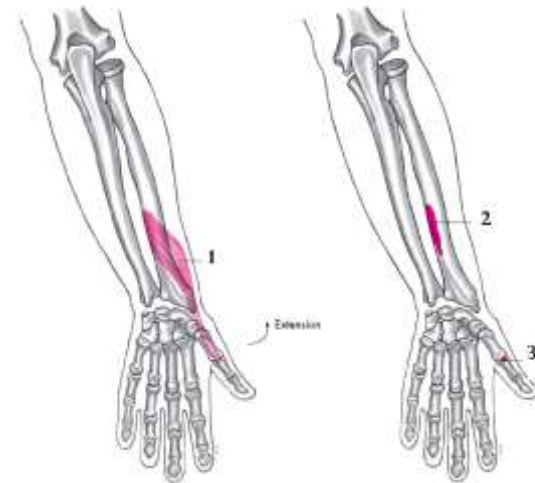
supinator



Abductor pollicis longus

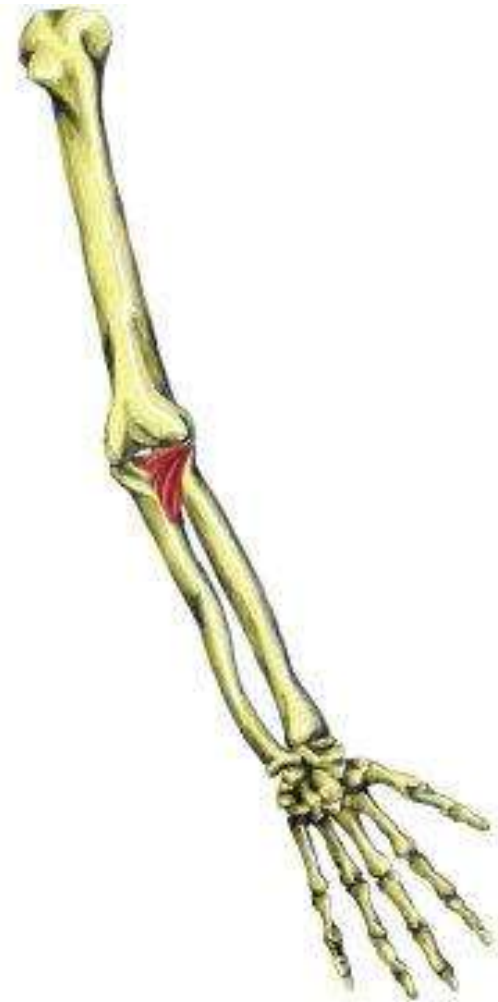

extensor pollicis longus (medial view)



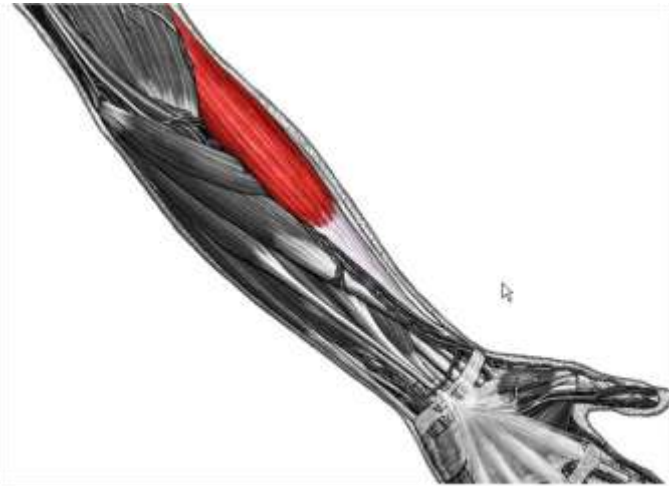
Extensor pollicis longus

X Extensor Indicis

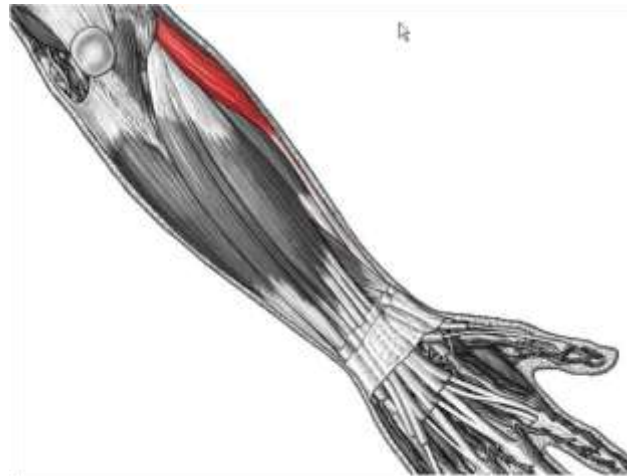


Anconeus

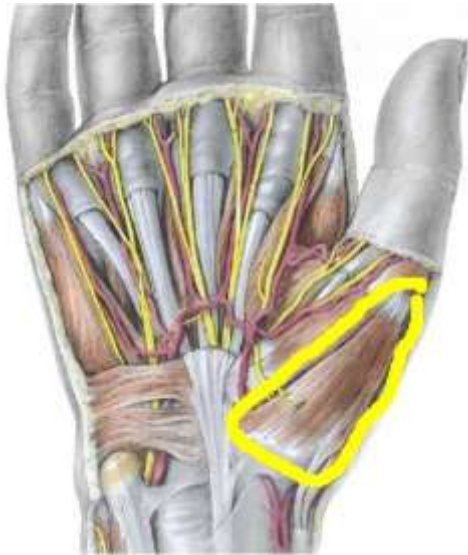Region	Muscle	Function	Origin	Insertion
Lateral extensor forearm	Brachioradialis	Flex elbow*, esp. if semiprone	Distal lateral humerus	Distal lateral radius
	Extensor carpi radialis longus	Extend wrist Abduct wrist	Distal lateral humerus	Base metacarpal 2
	Extensor carpi radialis brevis	Extend wrist Abduct wrist	Lateral epicondyle humerus	Base metacarpal 3
Thenar	Abductor pollicis brevis	Abduct thumb Oppose thumb	Flexor retinaculum	Lateral base phalanx 1
	Flexor pollicis brevis	Flex thumb	Flexor retinaculum	Lateral base phalanx 1
	Opponens pollicis	Oppose thumb	Flexor retinaculum	Lateral metacarpal 1
Hypothenar	Abductor digiti minimi brevis	Abduct digit 5	Pisiform	Medial base phalanx 5
	Flexor digiti minimi brevis	Flex metacarpo-phalangeal 5	Hamate hook Flexor retinaculum	Medial base phalanx 5
	Opponens digiti minimi	Oppose digit 5	Hamate hook Flexor retinaculum	Medial base phalanx 5
Hand	Adductor pollicis	Adduct thumb	Metacarpals 2, 3 Capitate	Medial base proximal phalanx 1
	Palmaris brevis	Draw medial skin of palm to center	Hypothenar fascia	Skin of medial palm
	Lumbricals	Flex metacarpo-phalangeal, extend interphalangeal	Flexor digitorum profundus tendons	Proximal phalanx, lateral side
	Dorsal interossei (4)	Abduct fingers	Adjacent metacarpals	Proximal phalanx, on side closer to midline
	Palmar interossei (3)	Adduct fingers	Metacarpals, on side away from midline	Proximal phalanx, on side away from midline



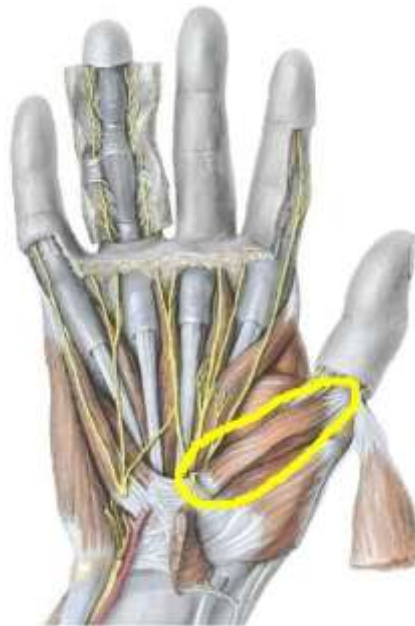brachioradialis



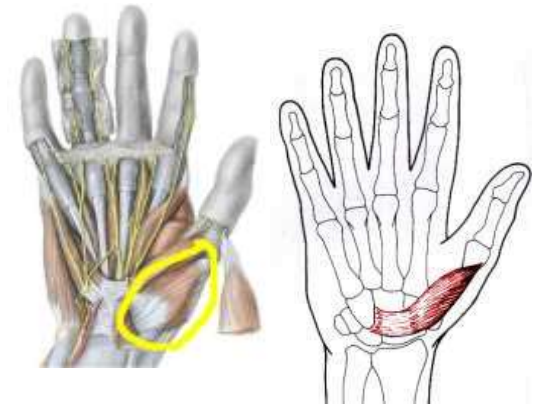
extensor carpi radialis longus



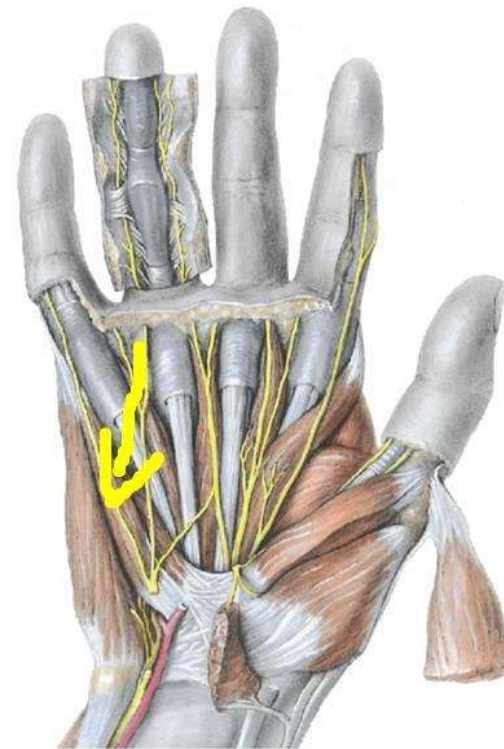
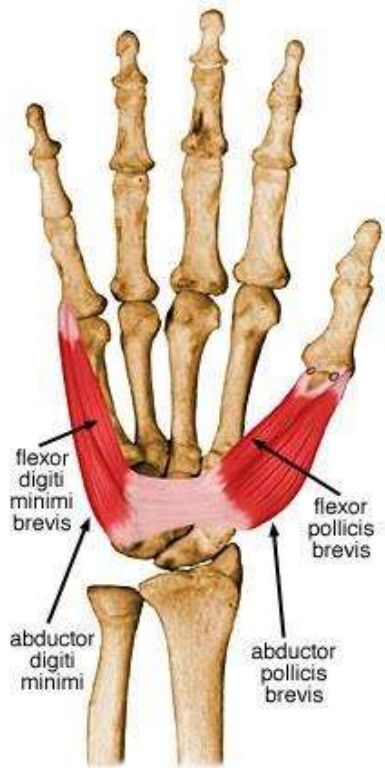Abductor pollicis
brevis



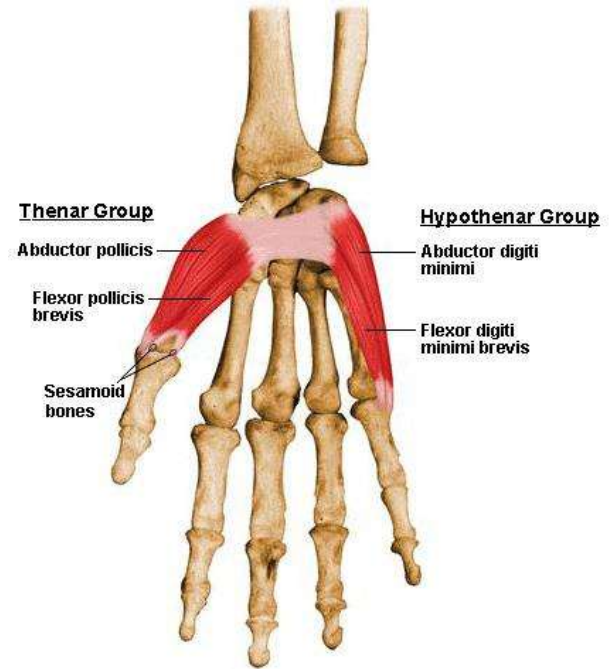
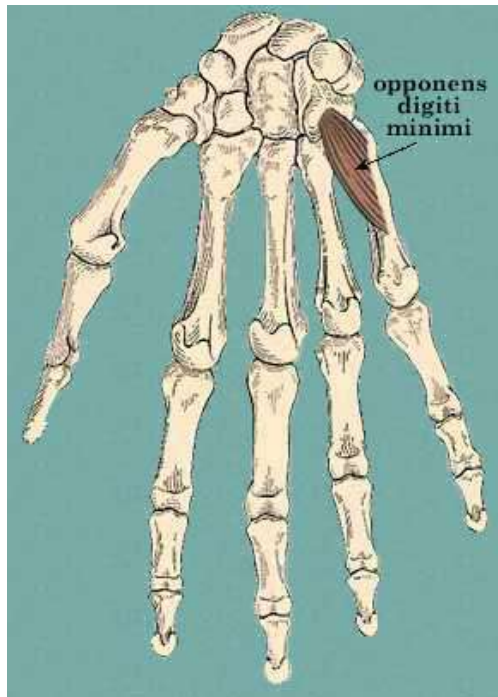
flexor pollicis
brevis



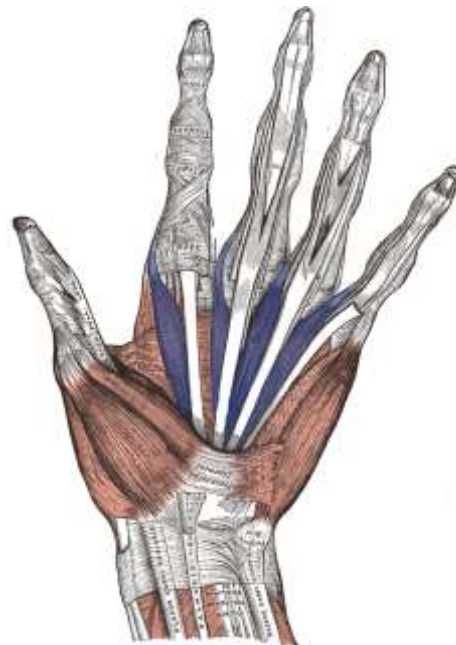
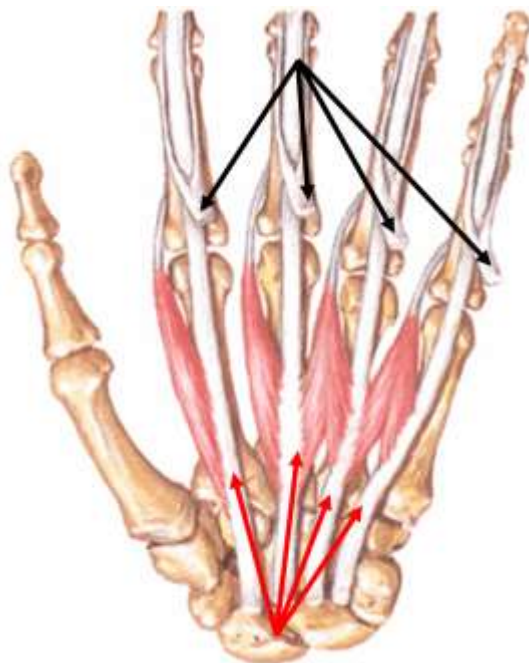
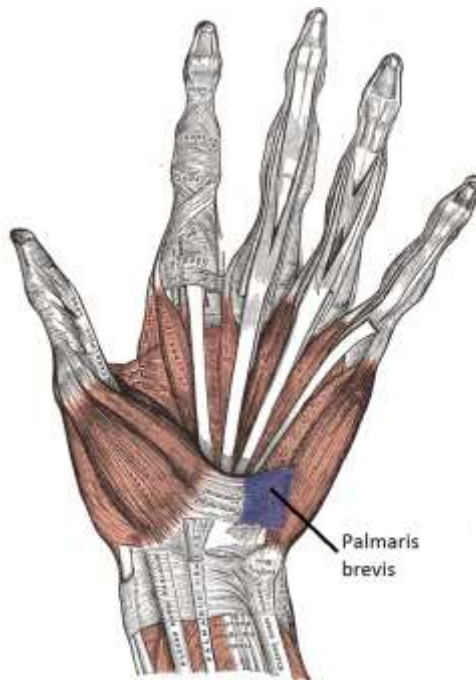
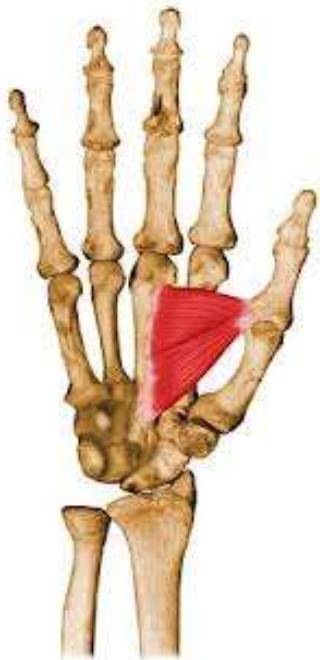Opponens pollicis

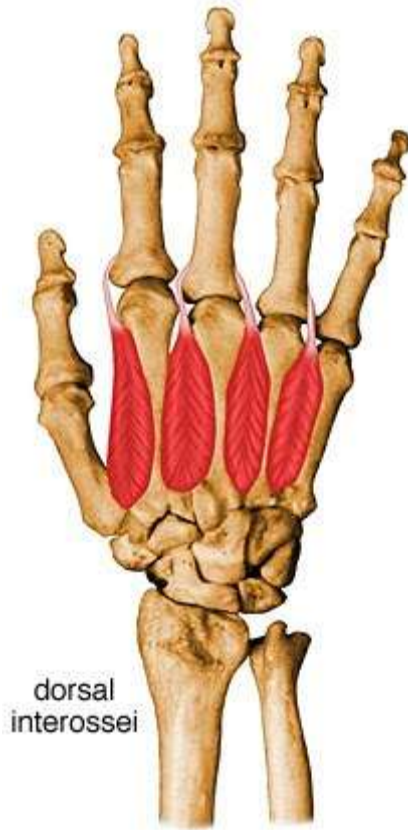

flexor digiti minimi brevis

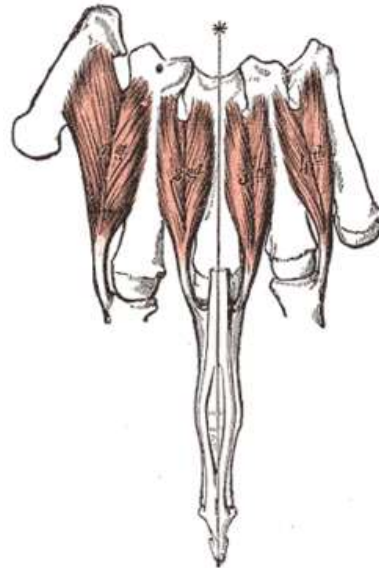


Adductor pollicis

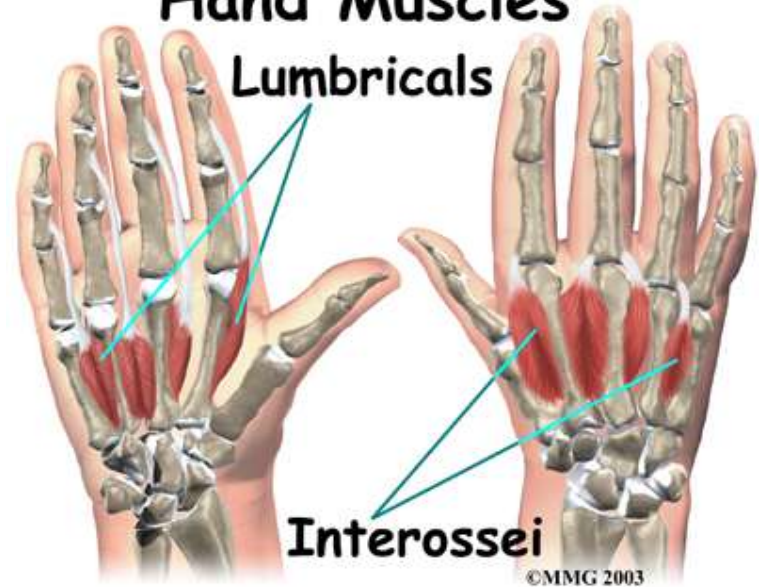



dorsal
interossei

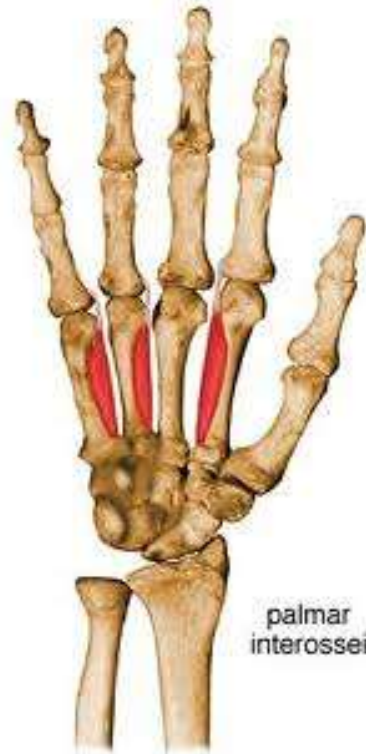

Hand Muscles Lumbricals

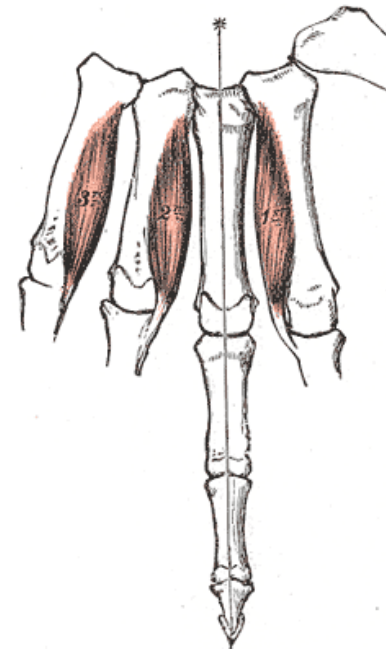


Interossei

©MMG 2003



palmar
interossei



Very useful links:

<http://www.studyblue.com/notes/n/structural-kinesiology-ch-7/deck/2088806>

It helps you to memorize the origins & insertions in better way