

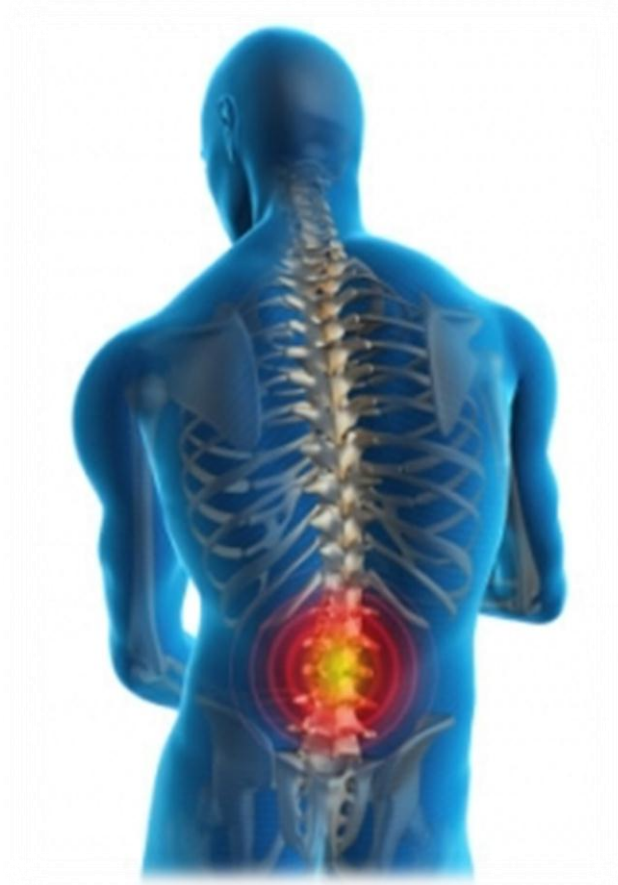


بِسْمِ اللَّهِ الرَّحْمَنِ الرَّحِيمِ



COLLEGE OF MEDICINE

432



Prolapsed disc

1st Case

By: Mohammed Alghammass

Learning objectives:

- Discuss the anatomy and function of the musculoskeletal system of the back ((please see the anatomy lecture about this part))*
- Use knowledge learnt from anatomy to discuss the possible causes of back pain*
- Discuss the pathophysiological consequences of disc injury and the mechanism of pain in these patients*
- Use basic sciences to explain the patient symptoms and signs*
- Discuss the principles of myotomes and dermatomes of lower limb and trunk*
- Discuss main differences between X-rays, CT scans and MRI*
- Discuss the pharmacology and mechanism by which NSAIDs and paracetamol work as analgesics*

❖ Slipped Disk (Herniated, Ruptured .Prolapsed Disk):

Overview:

The disks are protective shock-absorbing pads between the bones of the spine (vertebrae). The disks of the spine are also referred to as intervertebral disks. Although they do not actually "slip," a disk may move, split, or rupture. This can cause the disk cartilage and nearby tissue to fail (herniate), allowing the inner gel portion of the disk to escape into the surrounding tissue. This leaking jelly-like substance can place pressure on the spinal cord or on an adjacent nerve to cause symptoms of pain, numbness, or weakness either around the damaged disk or anywhere along the area supplied by that nerve.

❖ Causes of back pain:

- Pathological causes.
- Lumbar Muscle Strain
- Ruptured Disc or Herniated discs (our case)
- fibromyalgia (is a rheumatic condition)
- Discogenic Back Pain (damage to the intervertebral disc)
- Spinal Stenosis (tight spinal canal because of old age)
- Spondylolisthesis
- Lumbar Spine Arthritis
- Osteoporosis
- Cauda equina syndrome
- Infections to the spines
- Daily activities such as:

Bending awkwardly, Pushing something, Pulling something, Carrying something, Lifting something, Standing for long periods, Bending down for long periods, Twisting, Coughing, Sneezing, Muscle tension and Over-stretching.

❖ Pathophysiology of herniated disc.

PATHOPHYSIOLOGY

An intervertebral disk has two parts: the soft center called the *nucleus pulposus* and the tough, fibrous surrounding ring called the *anulus fibrosus*. The nucleus pulposus acts as a shock absorber, distributing the mechanical stress applied to the spine when the body moves.

Physical stress, usually a twisting motion, can tear or rupture the anulus fibrosus so that the nucleus pulposus herniates into the spinal canal. When this happens, the extruded disk may impinge on spinal nerve roots as they exit from the spinal canal or on the spinal cord itself, resulting in back pain and other signs of nerve root irritation. The vertebrae move closer together and in turn exert pressure on the nerve roots as they exit between the vertebrae. Pain and possibly sensory and motor loss follow. A herniated disk can also follow intervertebral joint degeneration; minor trauma may cause herniation.

Herniation occurs in three steps. During the first step, *protrusion*, the nucleus pulposus presses against the anulus fibrosus. Next, the nucleus pulposus bulges forcibly through the anulus fibrosus, pushing against the nerve root. This is called *extrusion*. In the last step, *sequestration*, the anulus fibrosus gives way as the disk's core bursts and presses against the nerve root. (See *How a herniated disk develops*.)

❖ Symptoms and signs:

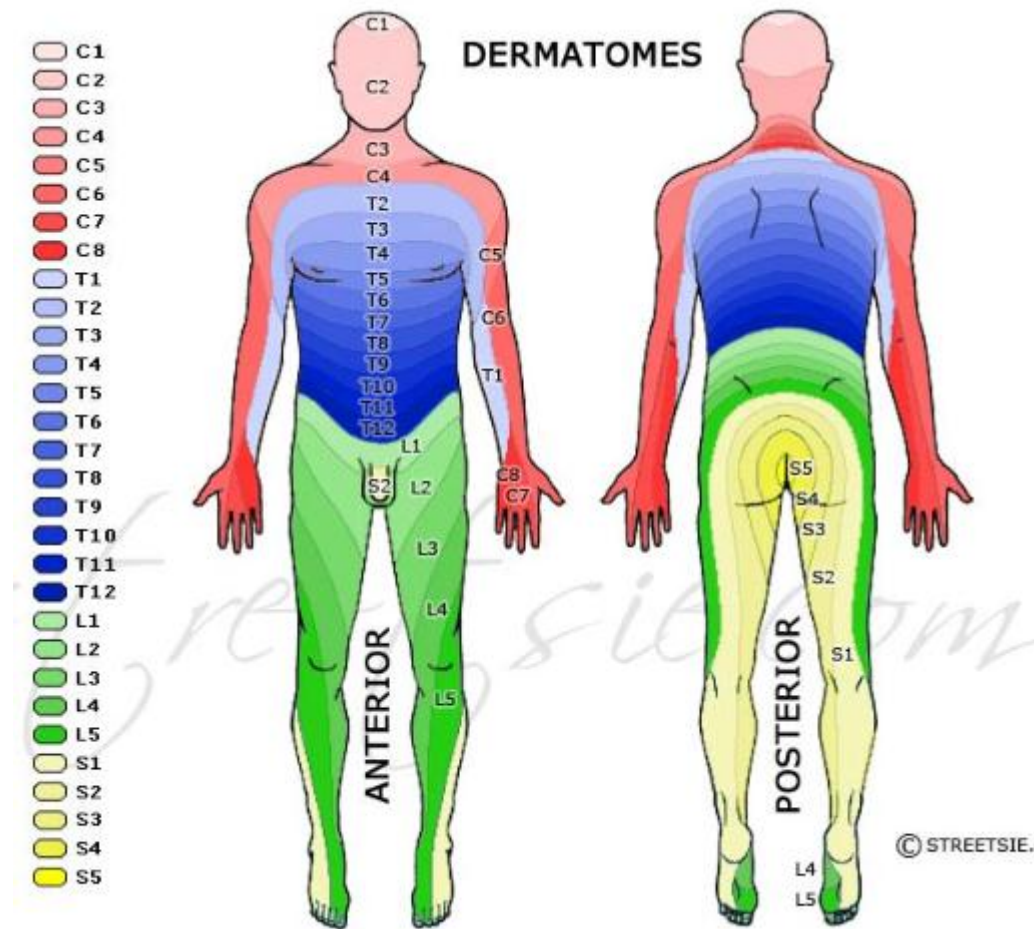
- Thigh and or leg pain
- Numbness or tingling
- Weakness of muscles
- Sciatica
- Electric Shock Pain

-

❖ Main differences between MRI,CT scan and X-rays

	MRI	CT SCAN	X-rays
Initialism for:	Magnetic Resonance Imaging	Computed (Axial) Tomography	----
Cost	1 200\$-4000\$	1 200\$-3200\$	Cheap
Time	30 minutes	5 minutes.. 30 secons for actual scan	Few secons
Details of bone structure	Less detailed compared to CT scan	Provides good details about bony structures	----
Effects on the bone	No biological hazards have been reported with the use of the MRI.	Despite being small, CT can pose the risk of irradiation. Painless, noninvasive.	The powerful rays have the ability to create birth defects and diseases and can also alter the DNA.
Image specifics	Demonstrates subtle differences between the different kinds of soft tissues.	Good soft tissue differentiation especially with intravenous contrast. Higher imaging resolution and less motion artifact due to fast imaging speed.	Demonstrates the difference between bone density and soft tissue.

❖ Dermatomes and Myotomes:



Spinal nerves have motor fibres and sensory fibres. The motor fibres innervate certain muscles, while the sensory fibres innervate certain areas of skin. A skin area innervated by the sensory fibres of a single nerve root is known as a dermatome. A group of muscles primarily innervated by the motor fibres of a single nerve root is known as a myotome.

Main differences

Lower limb:

- lumbar plexus, T12/L1 - L4, innervates the thigh
- sacral plexus, L4 - S4, innervates the leg and foot

In details:

Dermatomes:

Around inguinal region: L1 .. Front of knee: L3 .. Over tibia: L4

Over fibula: L5 .. Medial side of foot: L5 .. Lateral side of foot: S1

Myotomes:

Hip Joint:

Flexion: L2-3 (also adduction and medial rotation)

Extension: L4-5 (also abduction and lateral rotation)

Knee Joint: Extension: L3-4 .. Flexion: L5-S1

Ankle Joint and Foot: Dorsiflexion: L4-5 .. Plantarflexion: S1-2

Inversion: L4 .. Eversion: L5-S1

❖ Treatment :

NSAIDs have multiple mechanisms of action, including inhibition of cyclo-oxygenase, competition with prostaglandin at receptor sites, and inhibition of WBC migration and of lysosomal enzymes from WBCs.

For more information about mechanism of action of NSAIDs, go throw this link:

http://en.wikipedia.org/wiki/Non-steroidal_anti-inflammatory_drug#Mechanism_of_action