

The important points are highlighted by red color, surrounded by red boxes or in a box like this one !

CARDIOVASCULAR PRACTICALS-1

HEART SOUNDS

OBJECTIVES

1. To understand why the different heart sounds are produced.
2. To know the sites at which heart sounds are best recorded.
3. To recognize the value of phonocardiography.

HEART SOUNDS USING AN AUSCULTATORY METHOD

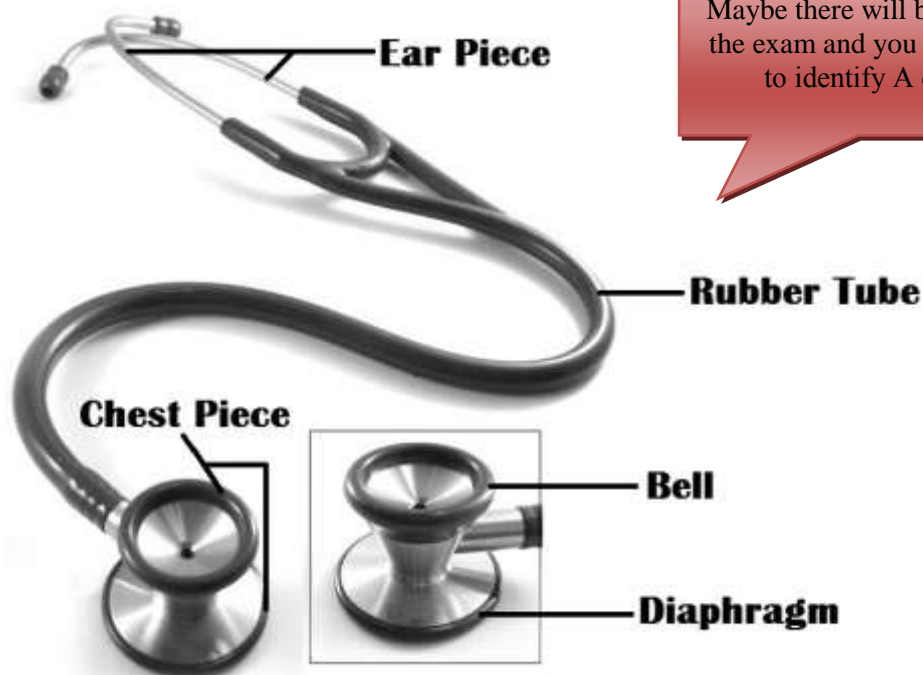
1. THE STETHOSCOPE

You should know how to spell the word

The stethoscope consists of:

- A. Earpiece.
- B. Rubber tubing.
- C. Chest piece - consists of diaphragm (larger circle) and bell (smaller circle).

The bell is used with light skin contact and pressure to hear low frequency sounds like murmurs, and the diaphragm is used with firm skin contact to hear high frequency sounds. Both the first and second heart sounds are of high frequency and the murmurs are low frequency sounds. A one-way valve system prevents sounds being transmitted by the bell when the diaphragm is being used and vice versa.



Maybe there will be a picture in the exam and you will be asked to identify A or B

2. THE POSITION OF THE PATIENT

The heart should be auscultated when the patient is in the following positions:

- Supine.
- Left lateral.
- Sitting.

Location

3. AUSCULTATION

The following areas should be auscultated for both normal and abnormal (added) sounds:

1st

I. **The mitral area:** *the site of the apex beat.* This is found in the left 5th intercostal space, approximately 1 cm medial to the mid-clavicular line.

1st

II. **The tricuspid area:** This is found just to the left of the lower border of the sternum.

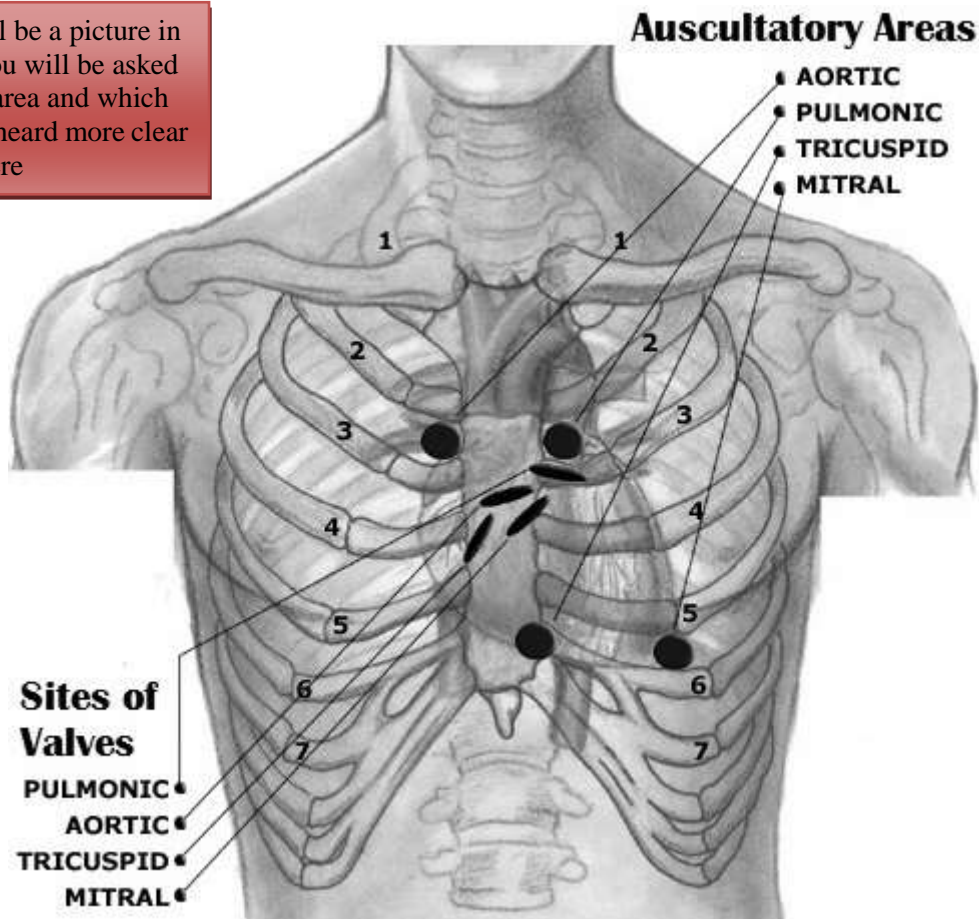
2nd

III. **The pulmonary area:** This is found in the left 2nd intercostal space at the sternal border.

2nd

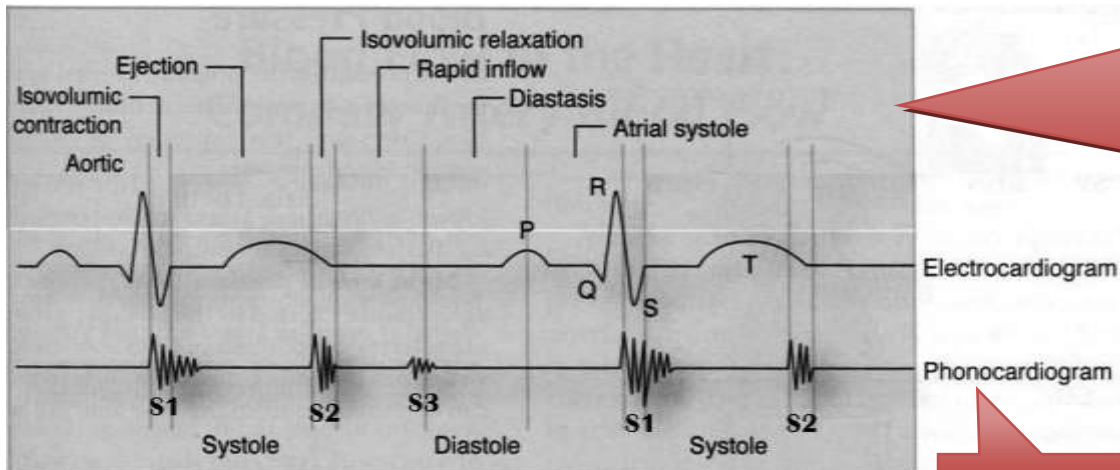
IV. **The aortic area:** This is found in the right 2nd intercostal space at the sternal border.

Maybe there will be a picture in the exam and you will be asked to identify the area and which sound is usually heard more clear there



HEART SOUNDS USING PHONOCARDIOGRAPHY

Phonocardiography is the sensitive technique, by which a recording can be made of all four heart sounds by placing a transducer on specific areas of auscultation.



Identify the short period → systole
Beginning of it is your 1st heart sound

Identify the long period → diastole
Beginning of it is your 2nd heart sound

Notice the correlations.

You should know how to spell the word

First heart sound:

- ❖ It is always **normal**. It sounds as “**lub**”. It is also called **S₁**.
- ❖ It is usually prolonged, but dull in nature.
- ❖ It is caused by the closure of AV valves.
- ❖ It is best heard when auscultated at mitral and tricuspid areas.
- ❖ It occurs at the **beginning of ventricular systole** in relation to cardiac cycle.
- ❖ It occurs **just after QRS complex** if we relate it to **ECG**.

Second heart sound:

- ❖ It is always **normal**. It sounds as “**dub**”. It is also called **S₂**.
- ❖ It is usually short and sharp in nature.
- ❖ It is caused by the closure of semi-lunar valves.
- ❖ It is best heard when auscultated at aortic and pulmonary areas.
- ❖ It occurs at the **beginning of ventricular diastole** in relation to cardiac cycle.
- ❖ It occurs **just after T wave** if we relate it to **ECG**.

Third heart sound:

- ❖ It may be heard **normally in children, thin adults, and pregnant women or after exercise**. It is also called **S₃**.
- ❖ It is caused by the striking of the blood to the wall of ventricles during rapid filling phase of ventricular **diastole**.
- ❖ It occurs in the **early diastole** in relation to cardiac cycle.

Fourth heart sound:

- ❖ It may be heard **normally in older people**. It is also called **S₄**.
- ❖ It is caused by the forceful contraction of atria.
- ❖ It occurs **just before the first heart sound** during late **diastole** in relation to cardiac cycle.

IDENTIFICATION OF HEART SOUNDS IN A PHONOCARDIOGRAM

We can identify the first and second heart sounds in a phonocardiogram by locating the periods of the ventricular systole and diastole.

- 1) As we know that the first heart sound (S₁) occurs at the beginning of systole and the second heart sound (S₂) occurs at the beginning of diastole, so the period between (S₁) and (S₂) should be systole and the period between (S₂) and the next (S₁) should be diastole.
- 2) Since the period of ventricular diastole is longer than that of ventricular systole in a cardiac cycle of a healthy individual, hence we can label the longer interval between the heart sounds as “diastole” and the shorter interval as “systole”.
- 3) Once systole and diastole are located, we can easily label the heart sound occurring at the beginning of systole as “S₁” and the heart sound occurring at the beginning of diastole as “S₂”.

So to recap, we can identify the heart sounds based on their character and time interval of separation.

PHYSIOLOGICAL SPLITTING OF THE SECOND HEART SOUND

- ❖ If either the first or second heart sound has two distinct components, they are said to be split. First Heart sound splitting is a pathological condition
- ❖ Indeed, **second heart sound splitting is a normal physiological phenomenon that may occur during deep inspiration.**
- ❖ As a person takes a deep breath, the chest wall expands and the intra-thoracic pressure falls due to which superior and inferior venae cavae becomes dilated and more blood returns to the right atrium. Because of more filling of the right ventricle as compared to the left ventricle during deep inspiration, the right ventricle takes more time to contract and empty during systole, so the pulmonary valve will close a little later than aortic valve that will cause splitting of the second heart sound.
- ❖ **We can hear a clear “dub, dub” when we auscultate the heart at either aortic or pulmonary areas during deep inspiration.** This is what we call physiological splitting of the second heart sound. Although this splitting can only be appreciated by the human ear only if the two components of the sound are separated by more than 0.2 seconds.

CARDIOVASCULAR PRACTICALS-2

THE ELECTROCARDIOGRAPHY (ECG)


OBJECTIVES

To understand and record normal electrocardiogram

EQUIPMENT AND METHODS

I. ECG PAPER

The ECG is recorded on graph paper and the lines are 1mm apart. On the vertical axis changes of voltage are recorded while on the horizontal axis time is measured in seconds. On the horizontal axis, the graph paper has large squares of 5 mm length and then each large square contains 5 small squares of 1 mm length. Normally the ECG machine is calibrated to move or pull the paper at a rate of 25 mm/sec. Therefore, horizontally, one small square of 1 mm length represents 0.04 seconds.



II. BEFORE RECORDING

- ❖ The subject should be supine and relaxed.
- ❖ The temperature of the room should be neither too hot nor too cold i.e. it should be comfortable (neutral).
- ❖ Sweating and muscle movements should be avoided so as to minimize artifacts.

III. DEFINITION OF ECG

Because the body fluids are good conductors of electricity, fluctuations in electrical potential during a cardiac cycle can be recorded extracellularly by placing recording electrodes on the surface of the human body. These electrical potentials represent the algebraic sum of the action potentials of myocardial fibers and when these are recorded by placing electrodes on the skin of human body, it is called electrocardiography or ECG. Hence we can define the ECG as: **“the algebraic sum of all the electrical potentials of the heart recorded from the body surface”**

IV. LEADS OF ECG

- ❖ A lead is a pair of electrodes joined together to record the potential difference between the two electrodes.
- ❖ There are 12 standard leads to record ECG.
- ❖ Each lead looks at heart from a **different angle** so as to locate an **abnormality** in the heart that can be detected by ECG.
- ❖ Out of 12 leads, 6 are limb leads and 6 are chest leads.
- ❖ Three of the limb leads are bipolar limb leads (Leads I, II and III) and three of them are unipolar (aVR, aVL and aVF), whereas, all the chest leads are unipolar.

Type of Lead	Limb Leads	Precordial or Chest Leads
Bipolar	I, II, III (standard limb leads)	-
Unipolar	aVR, aVL, aVF (augmented limb leads)	V₁ - V₆

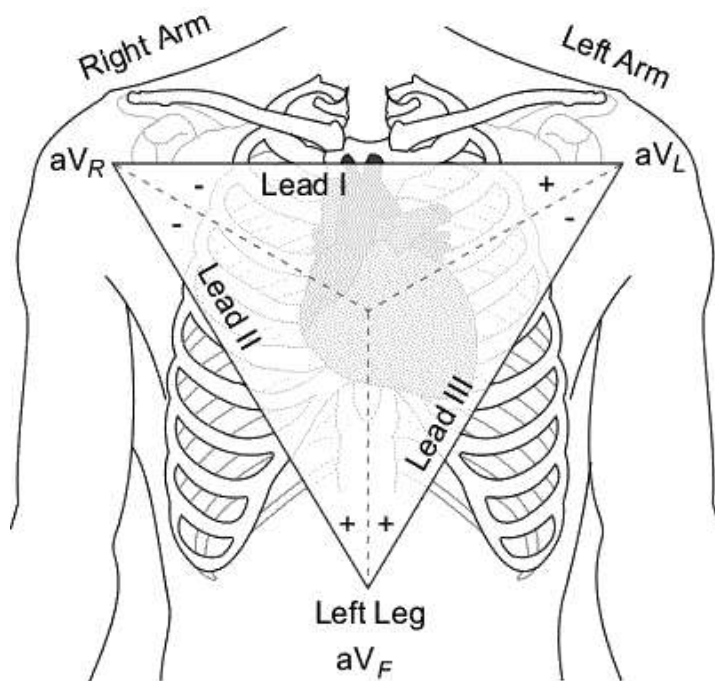
- ❖ A bipolar lead records the potential difference between two active electrodes and a unipolar lead records the potential of one active electrode as compared to the other inactive electrodes, as it provides resistance to the inactive electrodes making their potential zero.
- ❖ **Lead – I** is a standard bipolar limb lead that records potential difference between right arm and left arm, with its positive electrode being on the left arm.
- ❖ **Lead – II** is a standard bipolar limb lead that records potential difference between right arm and left foot, with its positive electrode being on the left foot.
- ❖ **Lead – III** is a standard bipolar limb lead that records potential difference between left arm and left foot, with its positive electrode being on the left foot.
- ❖ **aVR** is an augmented unipolar limb lead in which the active electrode is placed on the right arm while the other electrodes are made inactive.
- ❖ **aVL** is an augmented unipolar limb lead in which the active electrode is placed on the left arm while the other electrodes are made inactive.
- ❖ **aVF** is an augmented unipolar limb lead in which the active electrode is placed on the left foot while the other electrodes are made inactive.

- You should know the position of each lead ?

e.g. which lead is between right arm and left arm? Lead I

- Know each abbreviation stands for what?

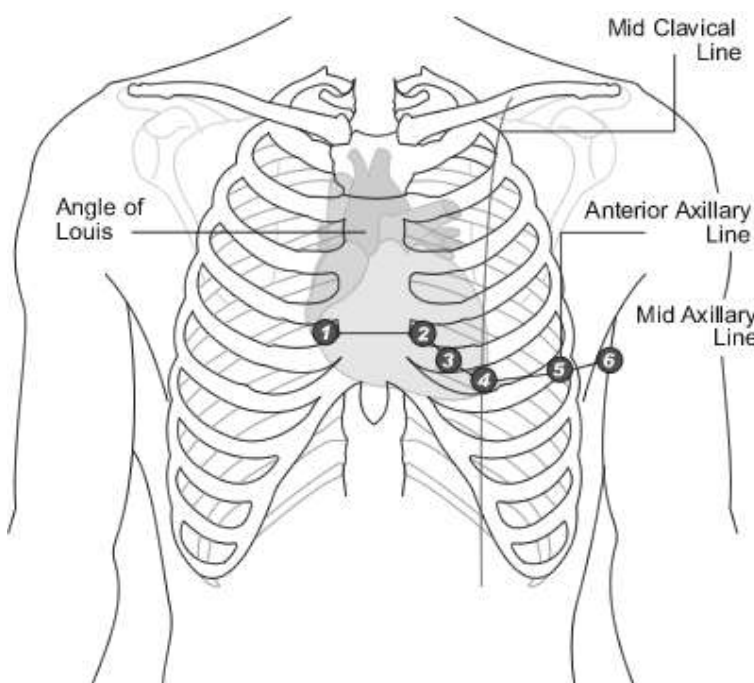
aVR – aVL - aVF



The 6 precordial or chest leads are named V1, V2, V3, V4, V5 and V6.

- ❖ **V1** - placed in the 4th intercostal space, right of the sternum
- ❖ **V2** - placed in the 4th intercostal space, left of the sternum
- ❖ **V3** - placed between V2 and V4
- ❖ **V4** - placed in the 5th intercostal space and the mid-clavicular line. (In women official recommendations are to place V4 under the breast).
- ❖ **V5** - placed in the anterior axillary line horizontal to V4.
- ❖ **V6** - placed in the mid-axillary line horizontal to V5.

The same as aortic and pulmonary areas but different level



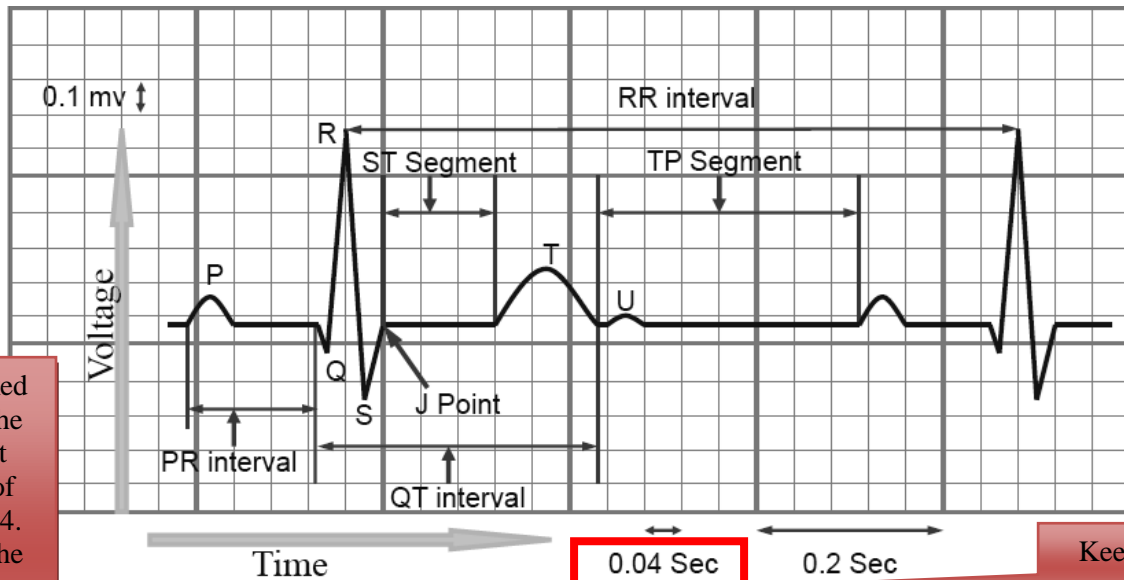
Know the Position of each lead.

They are very easy to memorize !

1-2
3
4 5 6

V. WAVES & INTERVALS OF ECG AND THEIR CALCULATIONS

- ❖ **P - wave** represents **atrial depolarization**.
- ❖ **QRS complex** represents **ventricular depolarization**.
- ❖ **T - wave** represents **ventricular repolarization**.
- ❖ **U - wave** is sometimes present due to repolarization of hypertrophied papillary muscles.



If you are asked to calculate the interval, just count the # of squares x 0.04. Then check the normal values and compare! (Memorize them). Your results will be in **Seconds**.

PR interval	0.12 – 0.20 sec
• QRS duration	0.08 – 0.10 sec
• QT interval	0.4 – 0.43 sec
• RR interval	0.6 – 1.0 sec

Keep in mind this Value **

- ❖ In order to calculate various intervals in an ECG recording, we have to always keep in mind that the small square in an ECG paper = **0.04 seconds** and then multiply it by the **number of small squares** in an interval to get its value.
- ❖ **PR interval** is from the “beginning of p-wave to the beginning of Q-wave” (R-wave in case if Q-wave is absent). Its normal value ranges from 0.12 – 0.21 seconds (3 – 5 small squares). In the above example, the number of small squares in the PR interval is approx. = 3, so the value of PR interval = 3 x 0.04 = 0.12 seconds. **If the PR interval exceeds from 0.2 seconds, it is said to be prolonged and it occurs in the first degree heart block.**
- ❖ **QRS duration** is from the beginning of Q-wave to the end of S-wave. Its normal value ranges from 0.08 – 0.1 seconds (less than 3 small squares). In the above example, the number of small squares in the QRS duration = 2, so the value of QRS duration = 2 x 0.04 = 0.08 seconds.
- ❖ **QT interval** is from the beginning of Q-wave to the end of T-wave. Its normal value ranges from 0.4 – 0.44 seconds (10 – 11 small squares). In the above example, the number of small squares in the QT interval = 8, so the value of QT interval = 8 x 0.04 = 0.32 seconds. **In this case, the QT interval is short, which can be associated with hypercalcaemia. Vice versa, hypocalcaemia can prolong the QT interval more than the normal range.**

It is easy "The Opposite"
Short ~ Hyper
Long ~ Hypo

- ❖ **ST interval** is from the end of S-wave to the end of T-wave. Its normal value ranges from 0.28 – 0.36 seconds (7 – 9 small squares). In the above example, the number of small squares in the ST interval = 6, so the value of ST interval = 6 x 0.04 = 0.24 seconds.

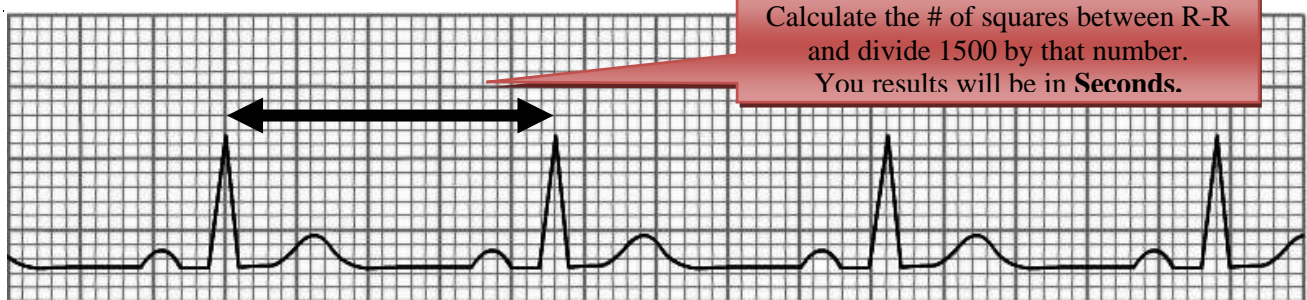
VI. CALCULATION OF HEART RATE

We can calculate the heart rate from the ECG by using the following formula:

$$\text{Heart Rate} = \frac{1500}{\text{Number of small squares between R - R}}$$

Keep in mind this Value **

Where 1500 = the total number of small squares pulled by the machine every minute (60 sec) when the speed of ECG machine is calibrated at 25 mm/sec (60 x 25) and R-R interval = 1 heart beat.



In the above ECG tracing, the arrow is indicating the R-R interval and if we count the number of small squares between R-R, they are 23. So if we fit this number in the above given formula for the heart rate calculation, the heart rate will be calculated as **1500/23 = 65 beats / minute.**

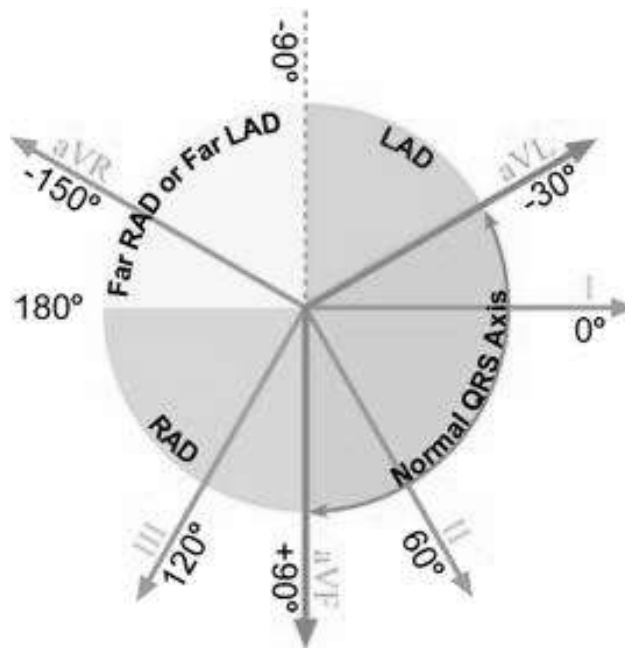
- ❖ The normal range of heart rate is between **60 – 100** beats/minute.
- ❖ If the heart rate **exceeds from 100** beats/minute, it is called **Tachycardia**.
- ❖ If the heart rate goes **below 60** beats/minute, it is termed **Bradycardia**.

VII. DETERMINATION OF HEART RHYTHM

- ❖ The heart rhythm refers to the regularity with which the heart beats.
- ❖ If the heart beats regularly, the rhythm is said to be normal.
- ❖ If the heart beats irregularly, it is called arrhythmia.
- ❖ Usually, the heart beats **faster during inspiration and slower during expiration**, showing a pattern of arrhythmia, but because it is purely physiological due to the different firing rate of SA node during inspiration and expiration, it is not considered pathological and is called **Sinus Arrhythmia**.

VIII. DETERMINATION OF AXIS

The electrical axis is the average direction of the current flow in the heart during a cardiac cycle. The normal axis is between -30° to 90°. In certain pathological conditions, it will deviate to the left (between -30° to -90°) and is called left axis deviation (LAD) and in some other pathological condition, it will deviate to the right (90° to 180°) and it is called right axis deviation (RAD). Beyond these values, it will be extreme or far right /left axis deviation, as shown in the following diagram:



- ❖ We have to apply rule of thumb on the direction of R-wave in the Leads I and III/aVF of the ECG in order to determine the electrical axis of the heart.
- ❖ If the direction of R-wave is upwards in both the leads I and III, then the electrical axis of the heart will be normal.
- ❖ If the direction of R-wave is upwards in the lead-I and is downwards in the lead-III, then the electrical axis of the heart would be deviated to the left.
- ❖ If the direction of R-wave is downwards in the lead-I and is upwards in the lead-III, then the electrical axis of the heart would be deviated to the right.
- ❖ If the direction of R-wave is downwards in both the leads I and III, then the electrical axis of the heart will be deviated to the extreme left/right.

R-deflection		Axis
Lead-I	Lead-III or aVF	
Positive	Positive	Normal
Positive	Negative	LAD
Negative	Positive	RAD
Negative	Negative	Extreme RAD or Extreme LAD

Thumbs are up!

Husband left his wife

Right way to do

Extremely Bad
Thumbs are down!

CARDIOVASCULAR PRACTICALS-3

CAROTID ARTERIAL AND JUGULAR VENOUS PULSES

OBJECTIVES

To be able to identify and understand the events causing the different waves of the jugular venous and carotid arterial pulse tracings.

HOW A VENOUS PULSE IS DIFFERENT FROM AN ARTERIAL PULSE

- ❖ *Multiphasic* - the venous pulse "beats" twice (in quick succession) in a cardiac cycle. The first beat represents that atrial contraction (termed 'a') and second beat represents venous filling of the right atrium against a closed tricuspid valve (termed 'v'), where as an artery only has one beat in a cardiac cycle.
- ❖ *Non-palpable* - the venous pulse cannot be palpated.
- ❖ *Varies with respiration* - the venous pulse usually decreases with deep inspiration.

A. THE CAROTID ARTERIAL PULSE

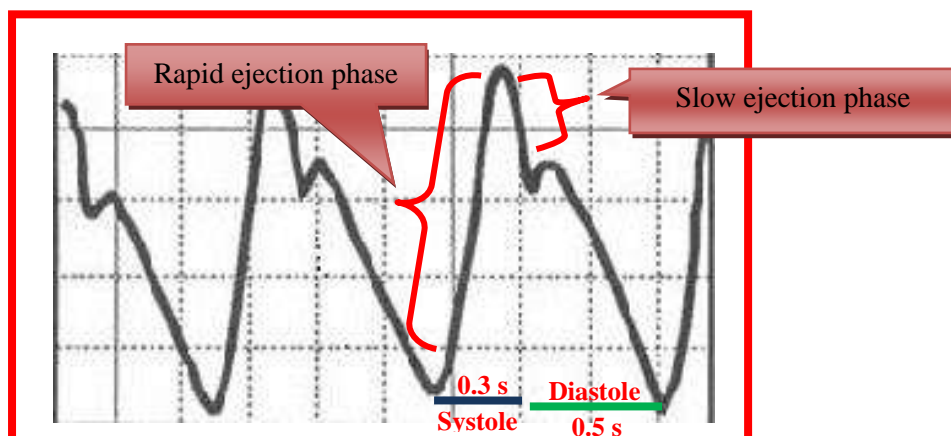
METHOD OF RECORDING

- The subject is asked to lie quietly on a couch.
- Feel the carotid arterial pulse on the medial side of the sternocleidomastoid muscle.
- Apply the transducer over the carotid artery using a soft rubber band and connect it to the recorder.

WHAT IS AN ARTERIAL PULSE

When blood is forced into the aorta during ventricular systole, two things happen:

- Blood is moved forwards.
- A pressure wave is set up which travels along the wall of arteries (faster than the flow of blood). The pressure wave expands the arterial walls as it travels. The expansion of the arterial wall is palpable as the pulse.



When we record the carotid arterial pulse, we get a tracing like above, which has the following features:

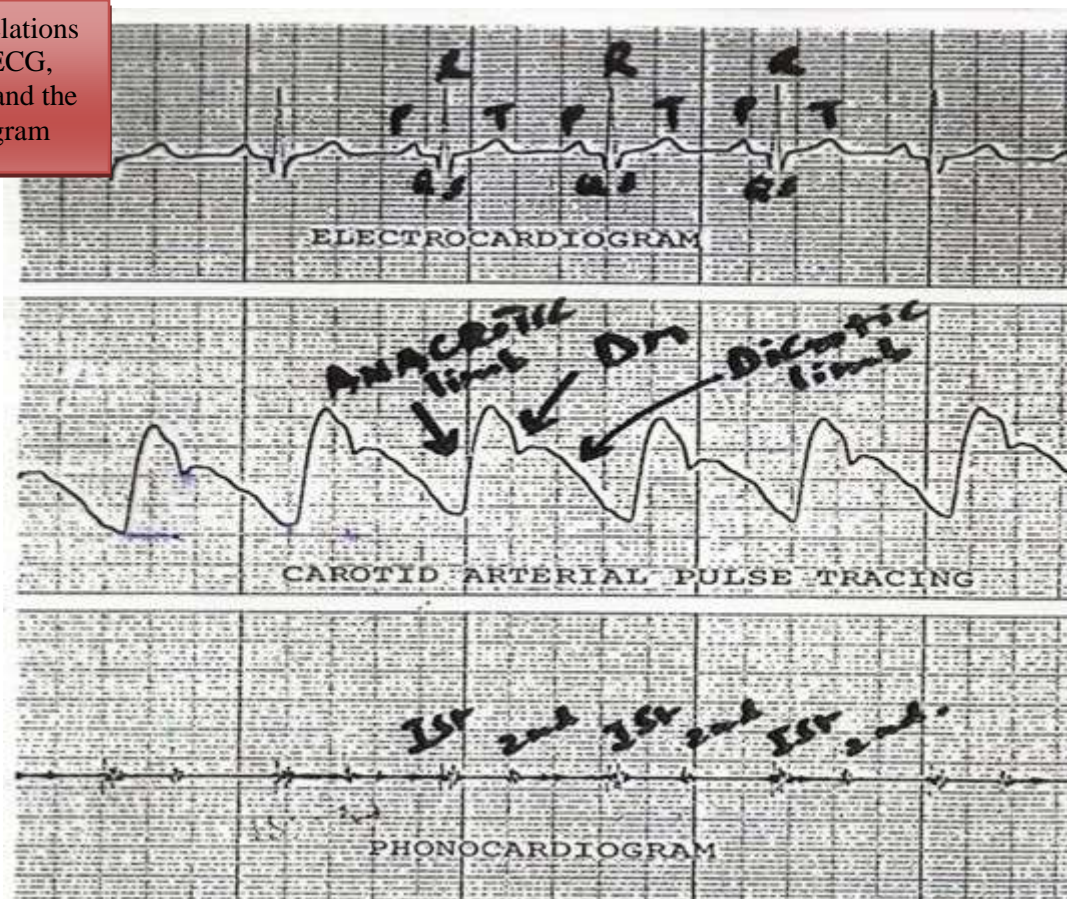
1) Anacrotic limb (ANA means up):

- ❖ It is an upward deflection recorded in the carotid arterial pulse tracing representing continuously **increasing pressure** in the carotid artery during the **maximum ejection phase of ventricular systole**.
- ❖ In healthy individuals, the arterial pressure recorded at the peak of the **anacrotic limb is 120 mmHg**.

2) Dicrotic Notch (Dn) or Incisura:

- ❖ It is recorded in the carotid arterial pulse tracing when the continual fall in the arterial pressure **is interrupted by the closure of the aortic valve at the end of ventricular systole**.
- ❖ It marks the **beginning of ventricular diastole**.
- ❖ We can easily find that it coincides **with the second heart sound** when we relate it to a phonocardiogram and occurs **just after the T-wave** when we relate it to an ECG, as can be seen in the following figure:

Notice the correlations between the ECG, Carotid Pulses and the Phonocardiogram



3) Dicrotic limb:

- ❖ It is the **falling phase after Dn (Incisura)** of the carotid arterial pulse tracing.
- ❖ It is caused by the continual **decreasing pressure** in the carotid artery during the ventricular diastole, but the pressure does not fall all the way to 0 mmHg, but stops falling further when it reaches **80 mmHg due to the elastic recoil of the arterial wall**.

B. THE JUGULAR VENOUS PULSE (JVP)

METHOD OF RECORDING

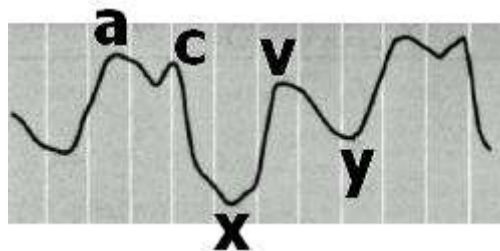
- 1) The subject is positioned at 45° on a couch or bed so that the pulsation of the internal jugular vein can be visualized.
- 2) The subject is asked to perform a Valsalva maneuver (a deep inspiration followed by a forced expiration against a closed glottis). As a result, the internal jugular vein becomes prominent.
- 3) Choose a position on the internal jugular vein away from the carotid artery.
- 4) Place the pulse transducer over the vein and keep it in position with a self-adhesive plaster and connect to the recorder.

WHY DO WE PREFER INTERNAL JUGULAR VEIN TO RECORD JVP?

Pressure changes in the right atrium are transmitted directly to the internal jugular vein as there are no valves between this vein and the right atrium. The external jugular vein cannot be relied upon because this vessel:

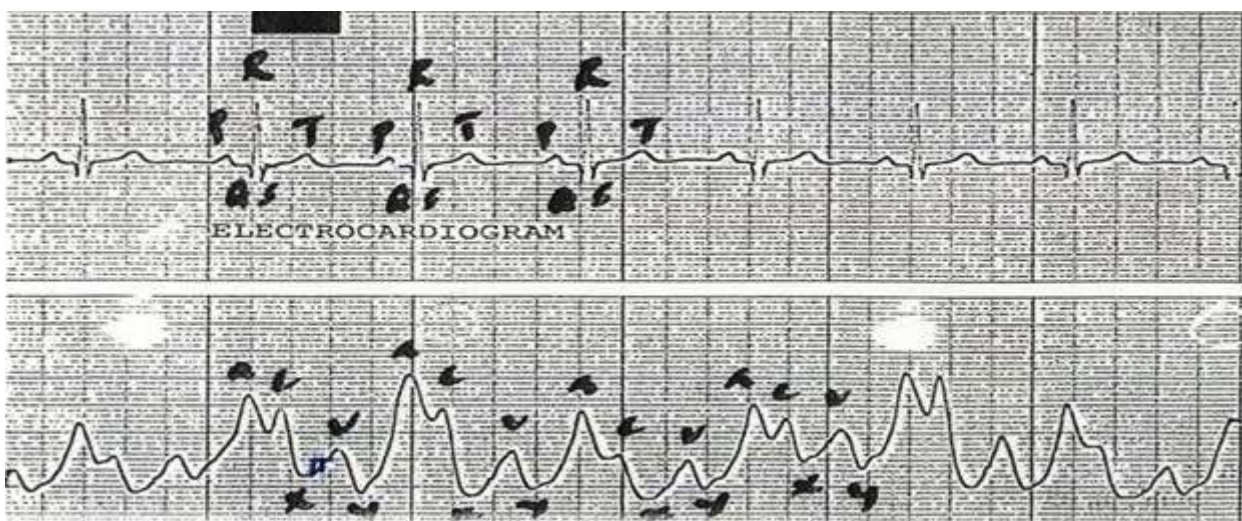
- a) Has valves, and
- b) May be obstructed by the fascial and muscular layers through which it passes.

It is important to know the cause of each wave. "See the Next Page"



When we record the jugular venous pulse, we get a tracing like above, which shows three positive waves or upward deflections labeled as "a", "c" and "v" representing an increased right atrial pressure and two downward deflections or descents labeled as "x" and "y" representing a decreased right atrial pressure during a cardiac cycle.

The following tracing shows the Jugular Venous Pulse tracing along with an ECG:



In the above comparison of JVP and ECG, we can clearly see that P wave in the ECG occurs just before the 'a' wave of JVP, thus showing atrial depolarization (P wave) precedes the atrial contraction ('a' wave).

CAUSES OF THESE WAVES

- 'a' wave:** It is due to the **right atrial contraction** at the end of the ventricular diastole, which in turn will lead to increased right atrial pressure.
- 'c' wave:** It is due to the increased right atrial pressure by the **bulging of tricuspid valve into right atrium during isovolumetric contraction phase of ventricular systole** because of a continually increasing right ventricular pressure in the early systole when all the valves are closed. **OR** another explanation is that it is just a **Carotid Artifact**.
- 'x' descent:** It is due to the downward displacement of the tricuspid valve by the **contraction of papillary muscles** during ventricular systole, thus decreasing the right atrial pressure.
- 'v' wave:** It is due to the increase in right atrial pressure, **when right atrium continues to fill with the blood** returning from great veins **against the closed tricuspid valve**.
- 'y' descent:** It is due to the fall in right atrial pressure, when the blood flows out of the right atrium into the right ventricle as soon as the tricuspid valve opens.

CLINICAL APPLICATION OF JVP:

The most important clinical Apps are:

- Prominent 'a' Wave
 - Absent 'a' Wave
- } **Focus on them**

PROMINENT 'a' WAVE:

In any of the following conditions, 'a' wave will become large in amplitude due to the increased right atrial pressure caused by a forceful right atrial contraction:

- ❖ Right heart failure
- ❖ Tricuspid stenosis
- ❖ Pulmonary stenosis
- ❖ Pulmonary hypertension

CANNON 'a' WAVE:

When the amplitude of 'a' wave becomes too high, it is called a Cannon Wave and it happens when the right atrium contracts against a closed tricuspid valve. The following conditions are few examples in which these cannon waves are seen:

- ❖ Atrial flutter
- ❖ Third degree heart block (Complete heart block)
- ❖ Ventricular Tachycardia

ABSENT 'a' WAVE:

When the right atrium pressure cannot be increased by right atrial contraction, the 'a' wave will not be formed and will be absent such as in **atrial fibrillation**.

LARGE 'v' WAVE:

'v' wave can become large or more prominent in "**tricuspid regurgitation**" when the right atrial pressure is increased too high by the leaking blood into the right atrium from the right ventricle through the incompetent tricuspid valve during the ventricular systole.

CARDIOVASCULAR PRACTICALS – 4

ARTERIAL BLOOD PRESSURE

OBJECTIVES

1. To be able to measure arterial blood pressure using a sphygmomanometer.
2. To recognize the effects of exercise on the arterial blood pressure.

EQUIPMENT AND METHODS

1. EQUIPMENT

- a) A stethoscope
- b) A sphygmomanometer
- c) A bicycle ergometer and/or a treadmill

2. METHODS FOR MEASURING ARTERIAL BLOOD PRESSURE

A. PALPATORY METHOD

This method only gives an estimate of the systolic blood pressure.

- 1) The subject's arm should be resting comfortably so that it does not need to be actively supported while the blood pressure is being taken.
- 2) A standard cuff (12 x 24 cm) is applied like a bandage about 4cm above the elbow joint.
- 3) Inflate the cuff until the radial pulse cannot be felt. By compressing the brachial artery, the pulse or pressure wave can no longer be transmitted to the radial artery.
- 4) Deflate the cuff slowly. Note the pressure at which the radial pulse can be felt again for the first time. This will be the systolic blood pressure.

B. AUSCULTATORY METHOD

This method measures both systolic and diastolic blood pressures.

- 1) Inflate the sphygmomanometer cuff until there is no radial pulsation.
- 2) Place the diaphragm of the stethoscope over the brachial artery just above and on the medial side of the elbow joint.
- 3) Deflate the cuff slowly. A series of sounds are usually heard. These are called the “**Korotkov**” sounds. They have been classified as follows:

Phase-1: The appearance of a clear tapping sound. This is the first sound that is heard and it represents the Systolic Pressure.

Phase 2: Blowing or swishing sounds.

Phase 3: The sounds become sharper and crisper.

Phase 4: An abrupt muffling of sounds.

Phase 5: All sounds disappear. The point where the sound disappears is the diastolic blood pressure.

3. PROCEDURE

- ❖ Practice the above two methods while the subject is resting in a supine position and then in the sitting position.
- ❖ Repeat each measurement at least three times to establish the reproducibility of the results.
- ❖ After about 10 minutes of exercise on either a bicycle ergometer or a treadmill, the blood pressure of the subject should be determined both immediately and 5 minutes after the exercise.

IMPORTANT
Memorize 3 or 4

4. PRECAUTIONS FOR MEASURING ARTERIAL BLOOD PRESSURE

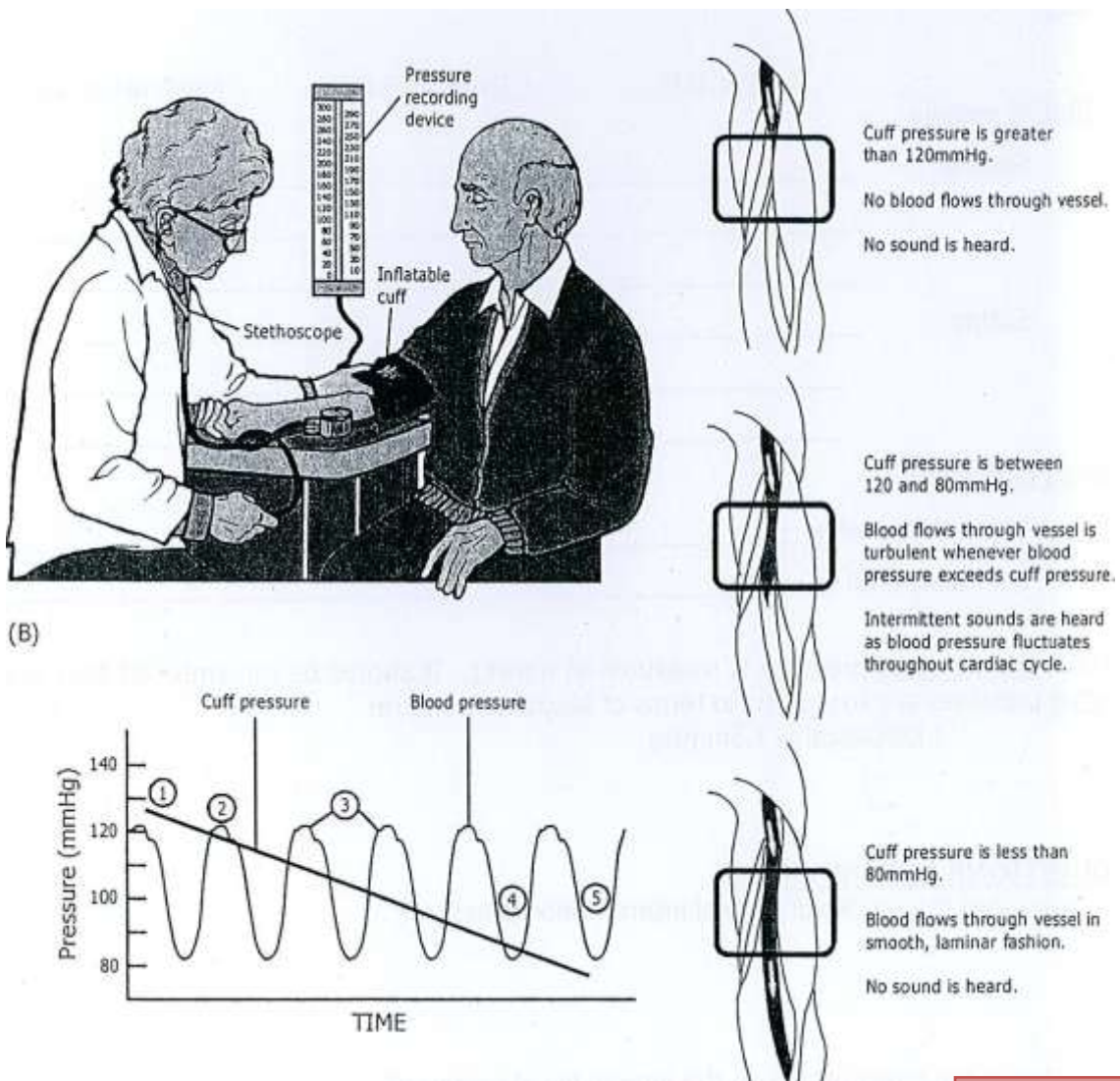
- ❖ The cuff size should be appropriate for the age and built of the subject. A large cuff is recommended for obese subjects while a smaller one is available for use with children.
- ❖ The cuff must be applied snugly (not too tight and not too loose) about 4 cm above the cubital fossa.
- ❖ Take care that the free margin of the cuff is not on the course of brachial artery i.e. to make sure that the rubber bag within the cuff is on the medial side so that it can occlude the brachial artery when the cuff is inflated.
- ❖ It is important that the manometer should be at the same level as the heart to exclude the effect of gravity while measuring the blood pressure.
- ❖ The mercury manometer should be in the vertical position.
- ❖ Check that there is an adequate amount of mercury in the bulb of the instrument. This can be done by seeing whether the mercury level is at the zero position of the manometer.
- ❖ The subject must be physically and mentally relaxed and in a comfortable environment.

5. AN EXAMPLE OF BLOOD PRESSURE READING BEFORE & AFTER EXERCISE

CONDITION	BLOOD PRESSURE READING
BEFORE EXERCISE	120/80 mmHg
AFTER MILD TO MODERATE EXERCISE	140/80 mmHg
AFTER HEAVY (SEVERE) EXERCISE	160/60 mmHg

Don't memorize these values. They are just examples to show you the different conditions. Notice in which period these changes occur: Systole or diastole

In the above example, we can observe that after mild to moderate exercise, the systolic blood pressure increases and the diastolic blood pressure remains more or less the same; while after severe exercise, the systolic pressure increases tremendously and the diastolic pressure drops.



QUESTIONS AND PROBLEMS

1. What are the ranges of normal blood pressure?

Systolic BP : 100 – 140 mmHg

Diastolic BP : 60 – 90 mmHg

2. Explain how Korotkov sounds are produced?

When the brachial artery is partially occluded, the blood flow through it becomes turbulent, which produces vibrations that are heard during auscultation.

3. What is the pulse pressure?

It is the difference between systolic and diastolic blood pressures.

Systolic pressure = 120 mmHg and Diastolic pressure = 80 mmHg; then Pulse Pressure = Systolic – Diastolic pressure i.e. 120 – 80 = 40 mmHg.

4. What is the mean arterial blood pressure? What is its significance?

It is the average blood pressure within the arteries during a whole cardiac cycle and it is the force responsible for maintaining a continuous forward flow of the blood in the circulation during the whole cardiac cycle.

If you can correctly answer the following Questions, you have covered everything in this ABP

5. How can we calculate the mean arterial blood pressure? Give an example.

Because the diastole phase of a cardiac cycle is longer than its systole phase, that is why we cannot apply mathematical average to determine the mean arterial blood pressure; instead we can calculate the mean arterial blood pressure (M.A.B.P.) by applying the following formula:

$$M.A.B.P. = \text{Diastolic Blood Pressure} + \frac{1}{3} \text{ Pulse pressure}$$

Let us suppose that a subject's blood pressure is measured to be 120/90 mmHg, then we can calculate the mean arterial blood pressure in the following 3 steps:

- 1) Determine the pulse pressure : 120 - 90 = 30 mmHg
 - 2) Divide the pulse pressure by 3 : 30/3 = 10 mmHg
 - 3) Add the above answer to the diastolic blood pressure: 10 + 90 = 100 mmHg
- So 100 mmHg will be the mean arterial blood pressure in this example.

6. What are the effects of exercise on the systolic & diastolic blood pressures? What happens to the pulse pressure? Explain why these changes occur.

MILD TO MODERATE EXERCISE	SEVERE OR HEAVY EXERCISE
Systolic BP increases, while Diastolic BP remains the same.	Systolic BP increases further and Diastolic BP decreases
Because of sympathetic stimulation, the cardiac output increases, which in turn increases the systolic BP, but no effect on diastolic BP.	More sympathetic stimulation will increase the Systolic BP further and the Diastolic BP drops because of a net decrease in the total peripheral resistance due to the more vasodilatation effect on the arterioles supplying the exercising skeletal muscles than the vasoconstriction effect on the arterioles supplying the other tissues.

Keep in Mind:
 - Systole depends on CO
 - Diastole depends on TPR

We have tried to highlight the information which Dr. Mustafa focused on. Go through the other information if you have time.

Done By:
 Khulood Al-Raddadi & Mohammed Jameel
 "Physiology Team Leaders"

Good Luck!