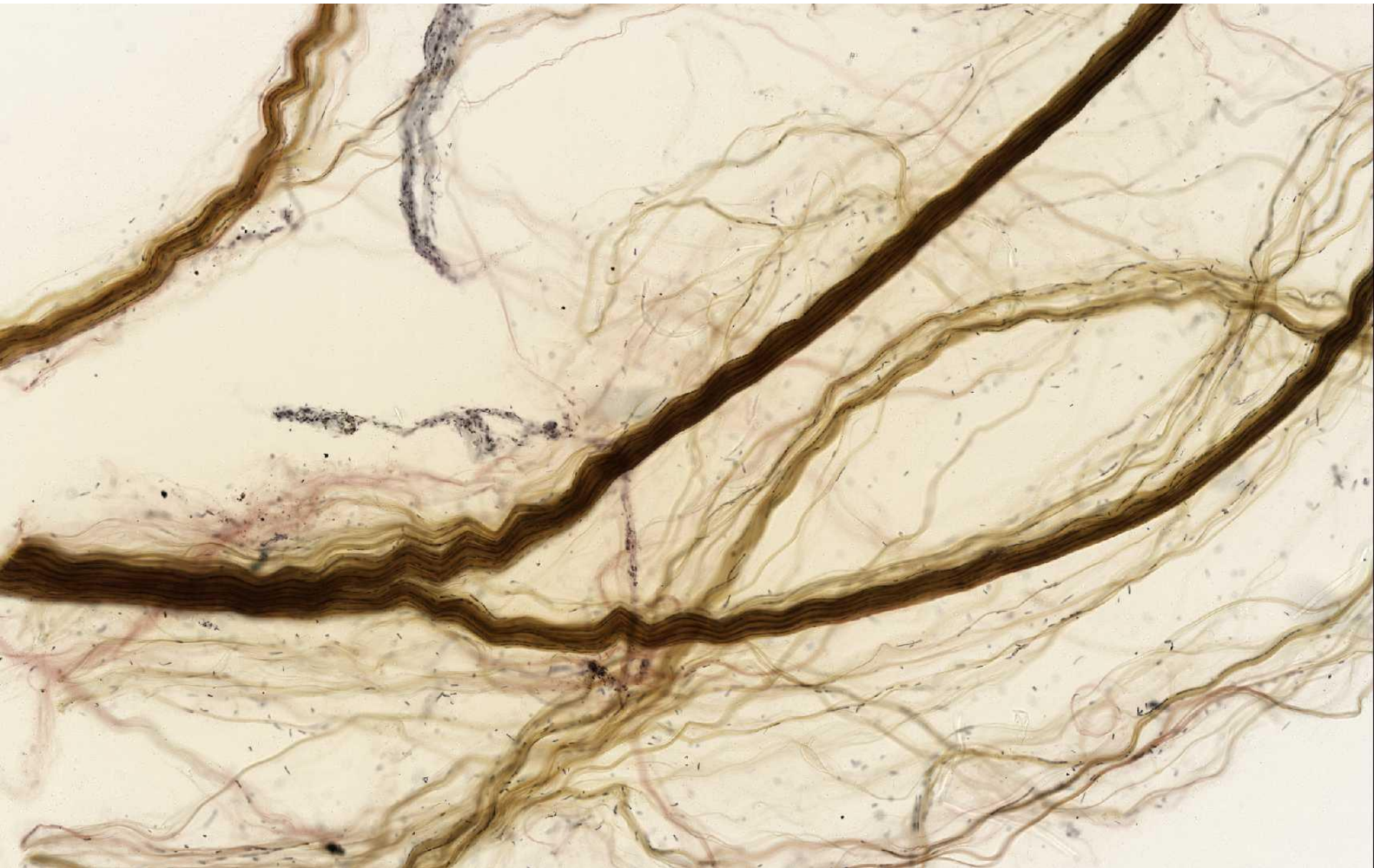


Connective Tissue

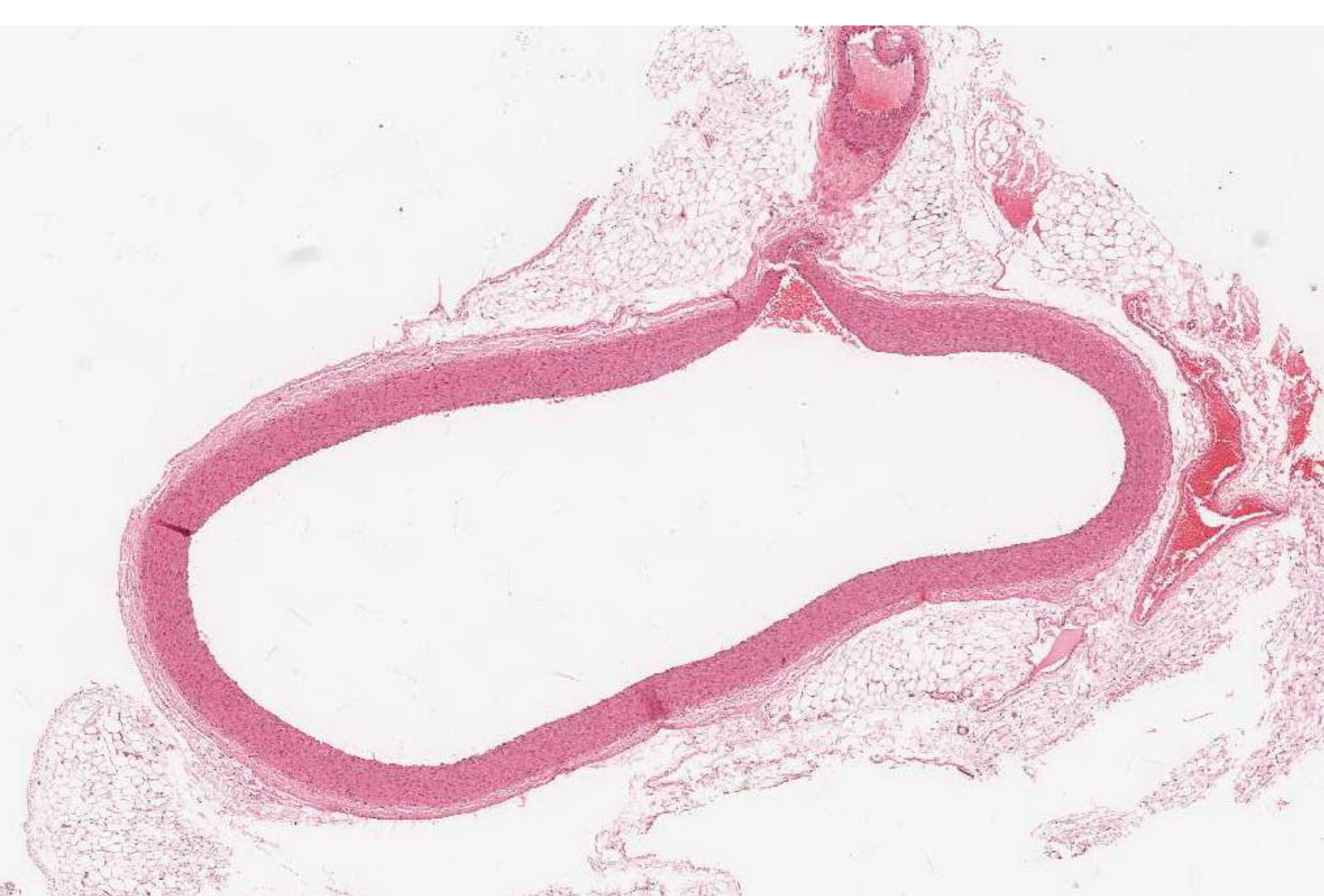Practical Pictures



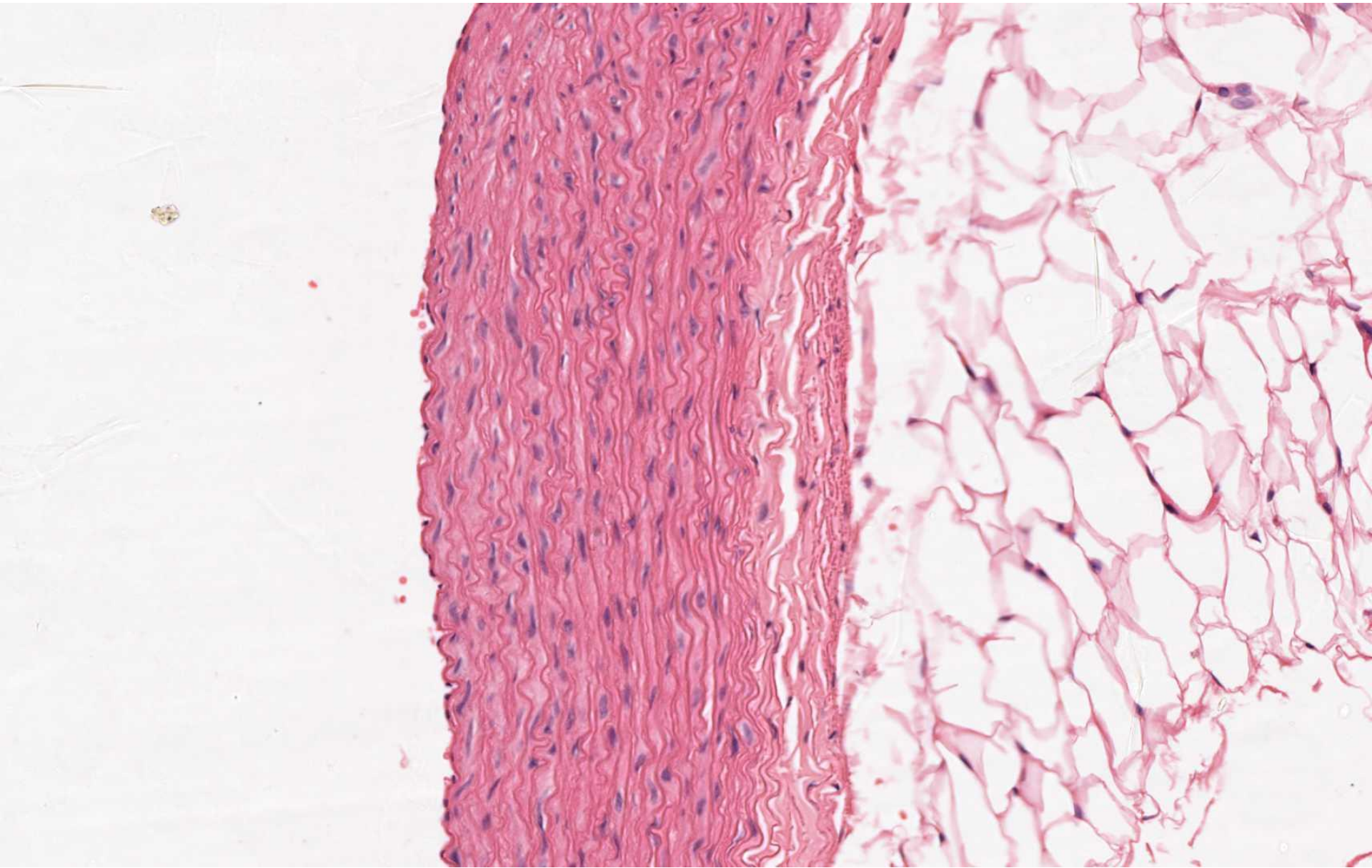
Dense collagenous connective tissue (e.g. in tendon)



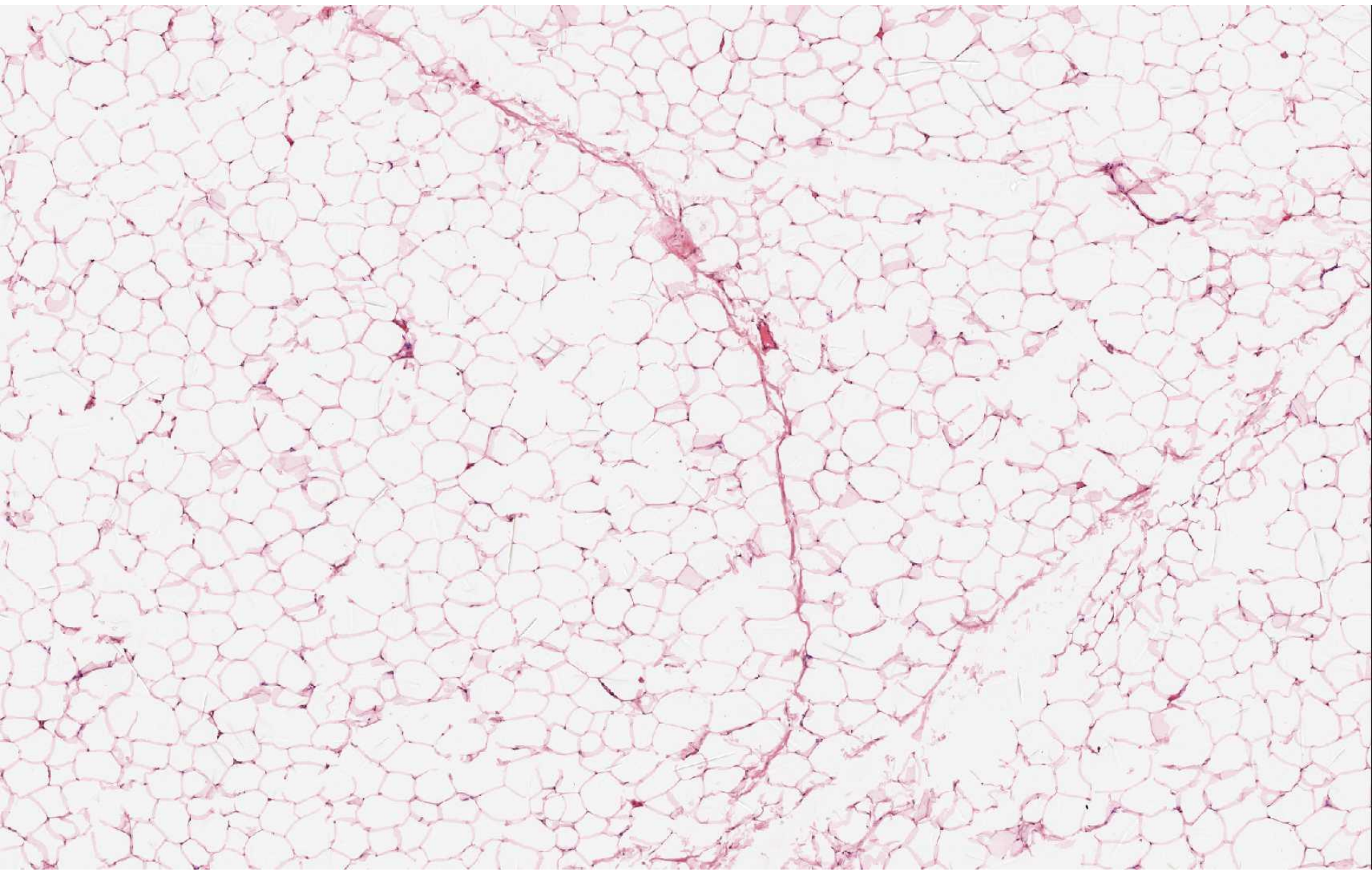
Dense collagenous connective tissue (e.g. in tendon)



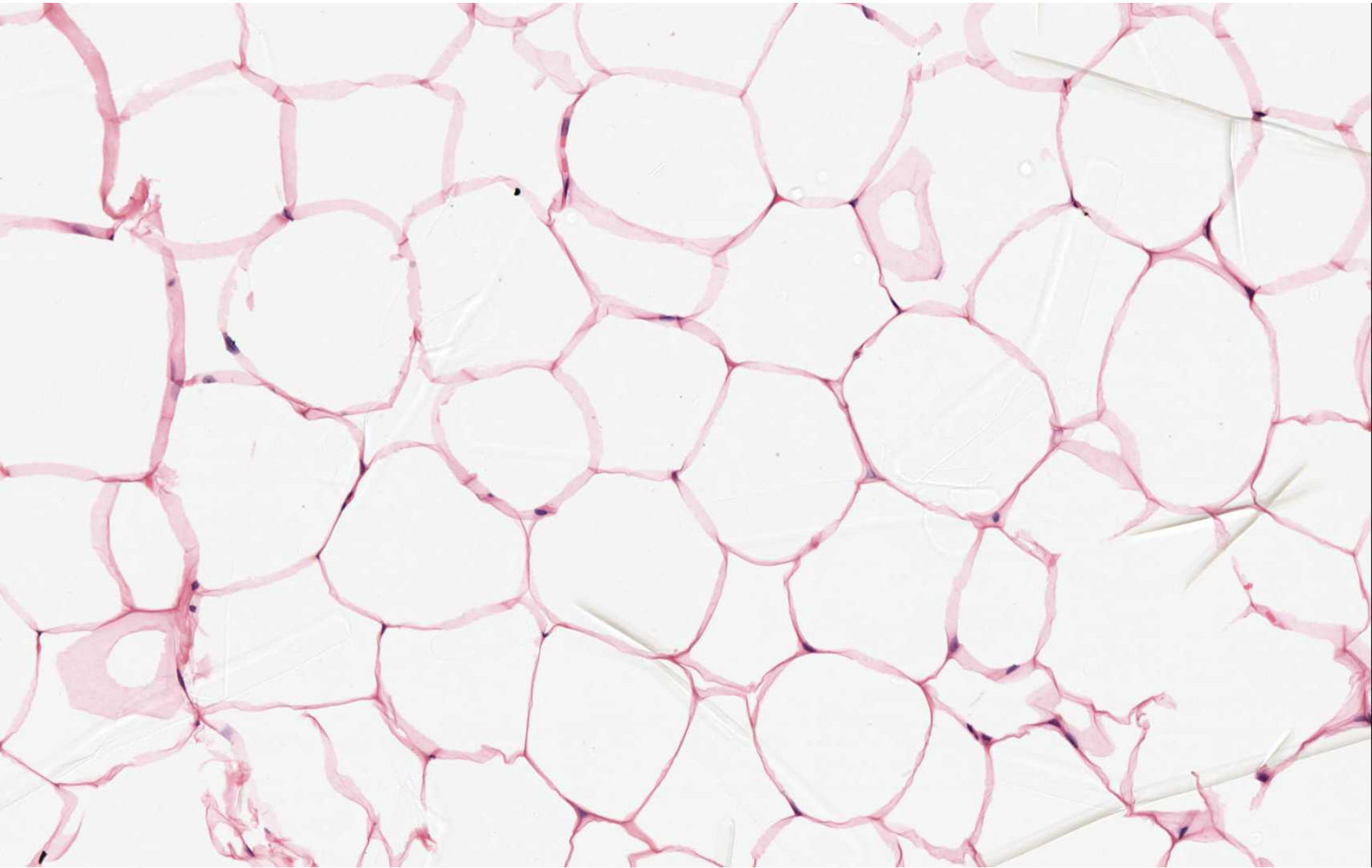
Elastic connective tissue (e.g. in wall of aorta)



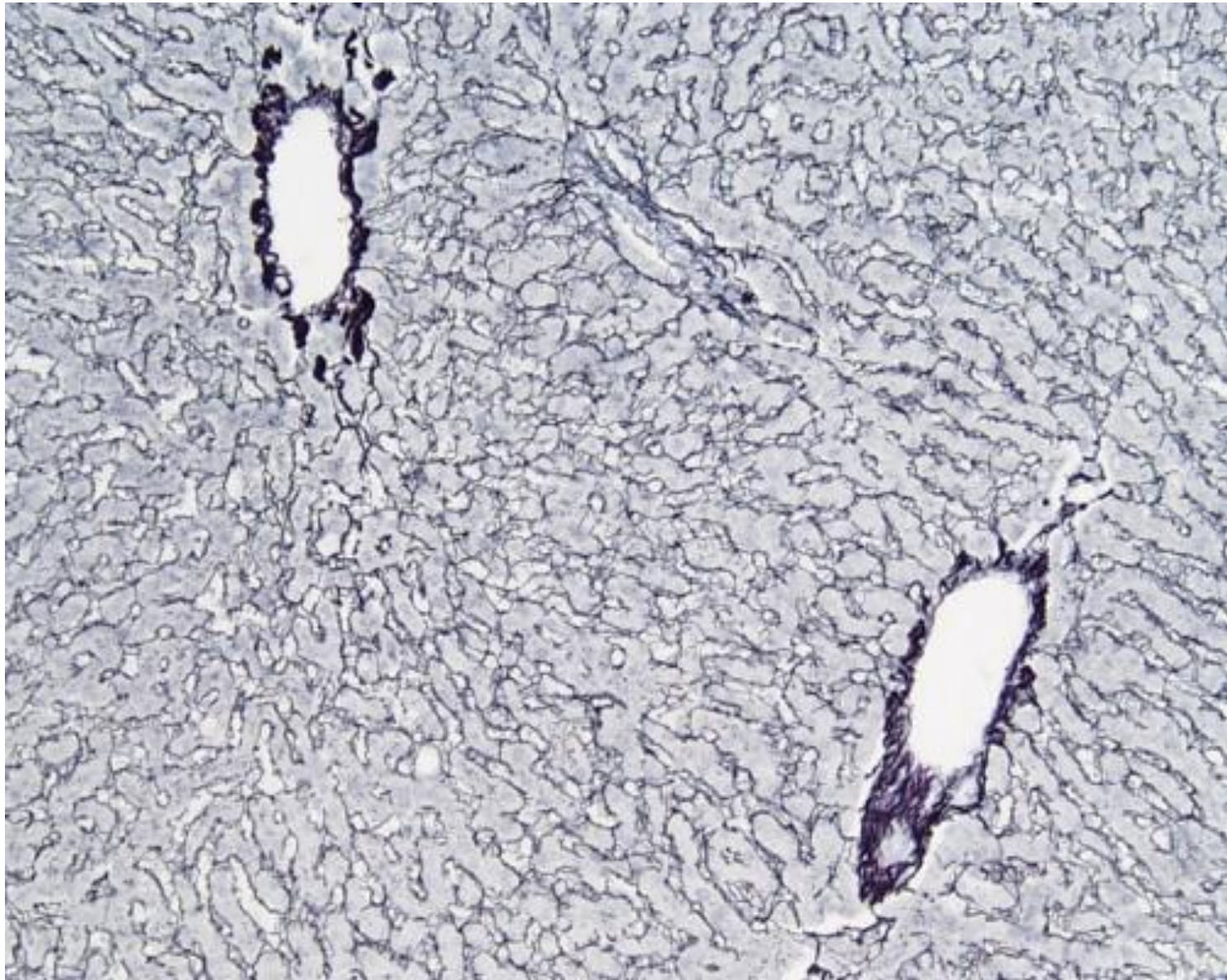
Elastic connective tissue (e.g. in wall of aorta)



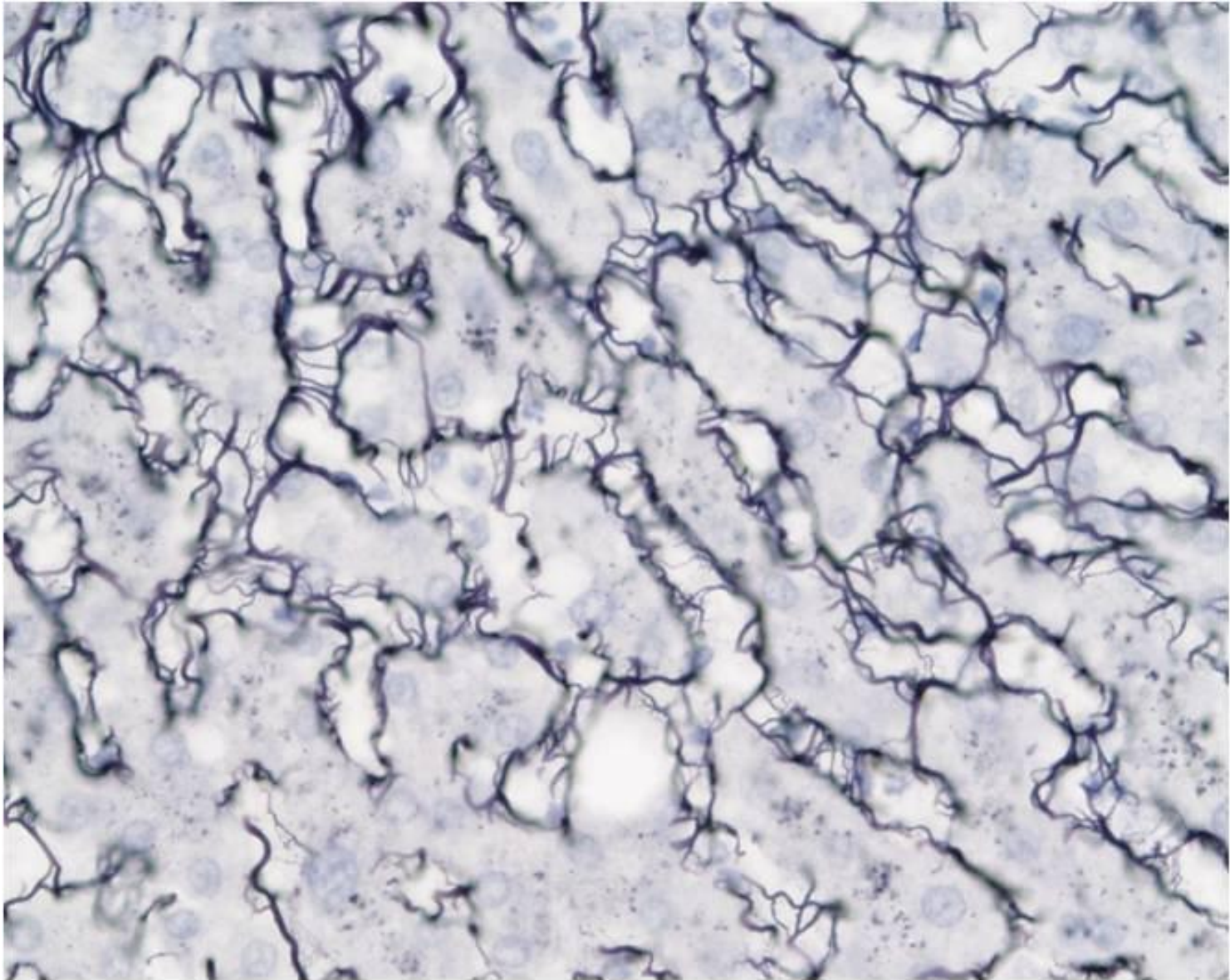
Adipose connective tissue



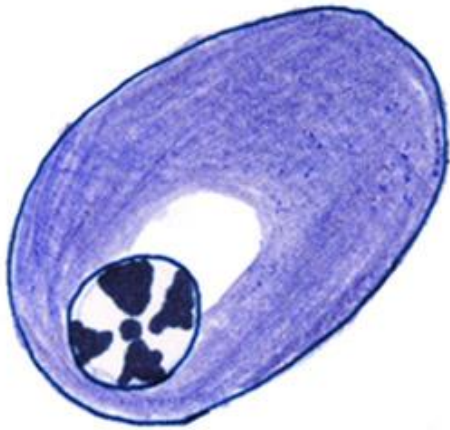
Adipose connective tissue



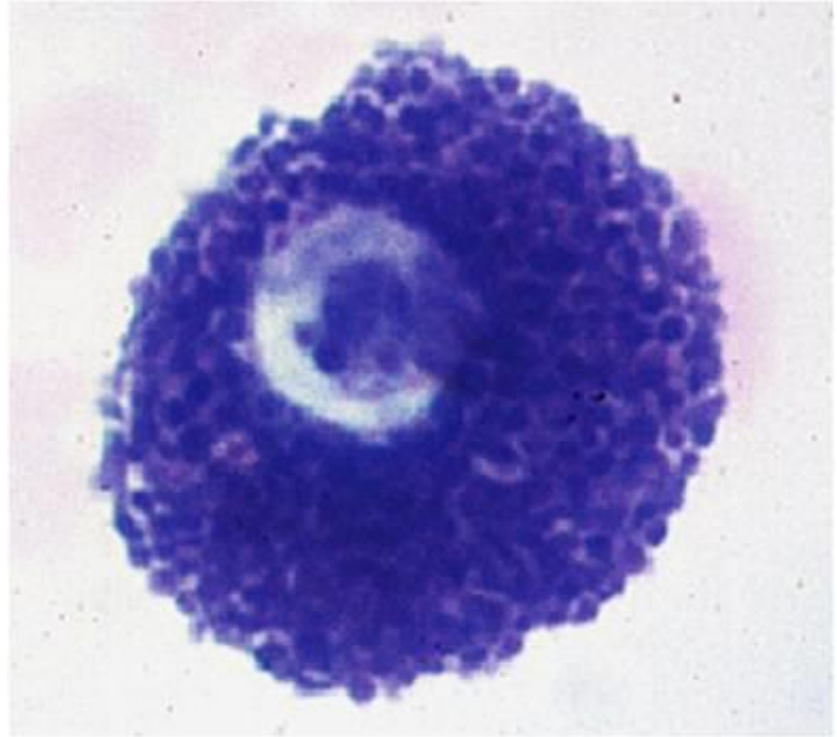
Reticular connective tissue (e.g in liver)



Reticular connective tissue (e.g in liver)



Plasma cell



Mast cell