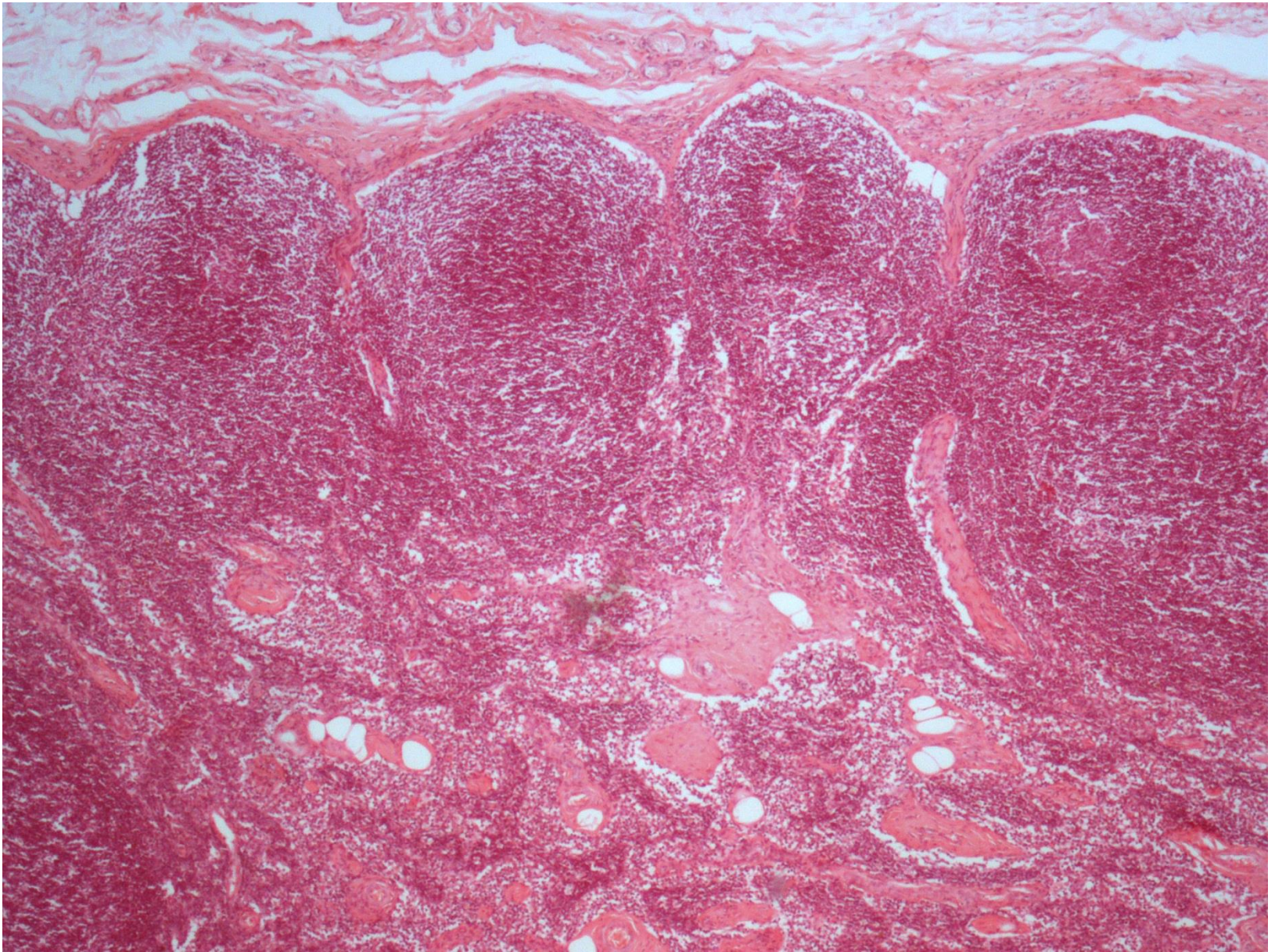
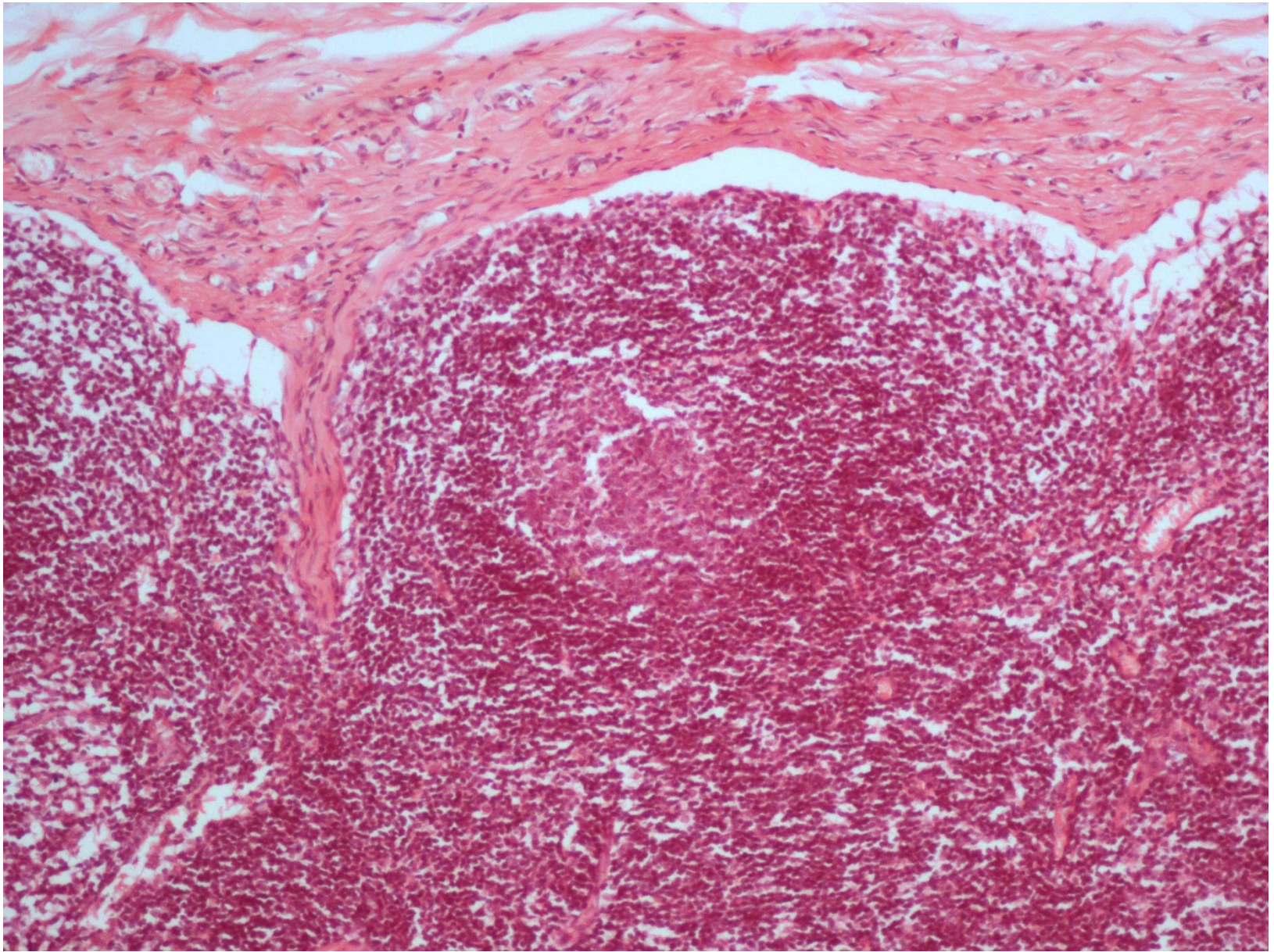


Lymphoid Tissue

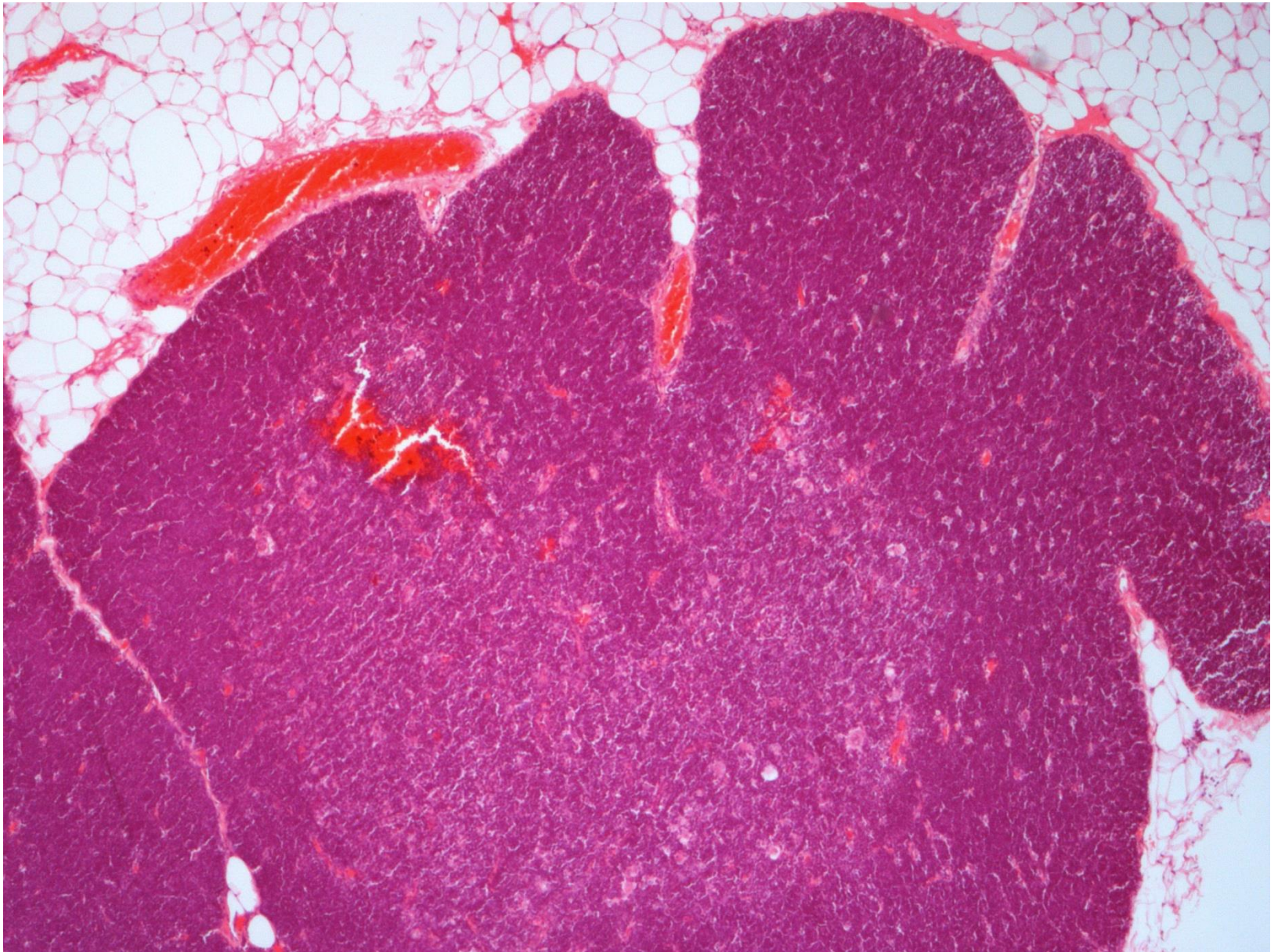
Practical Pictures



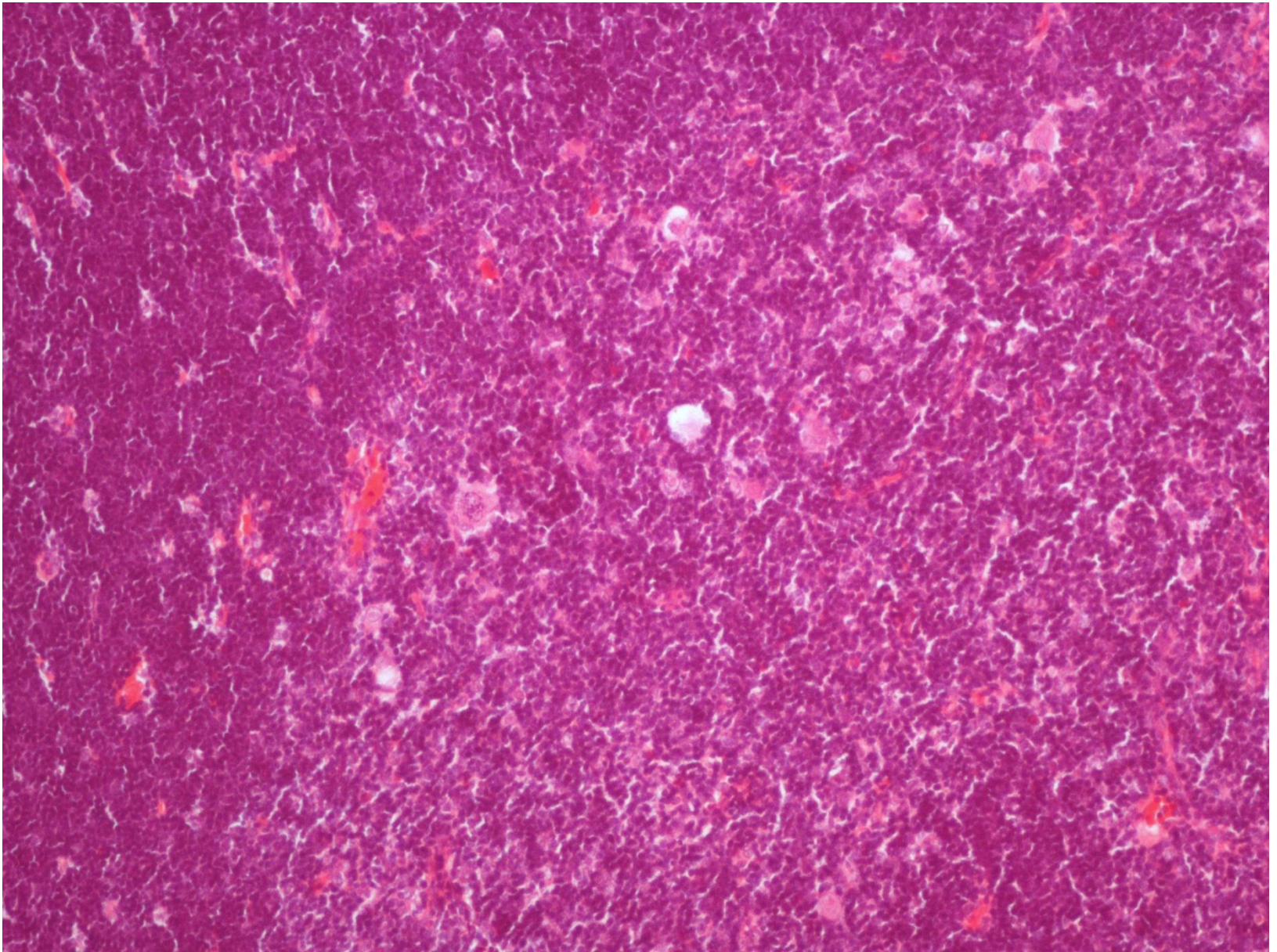
Lymph Node



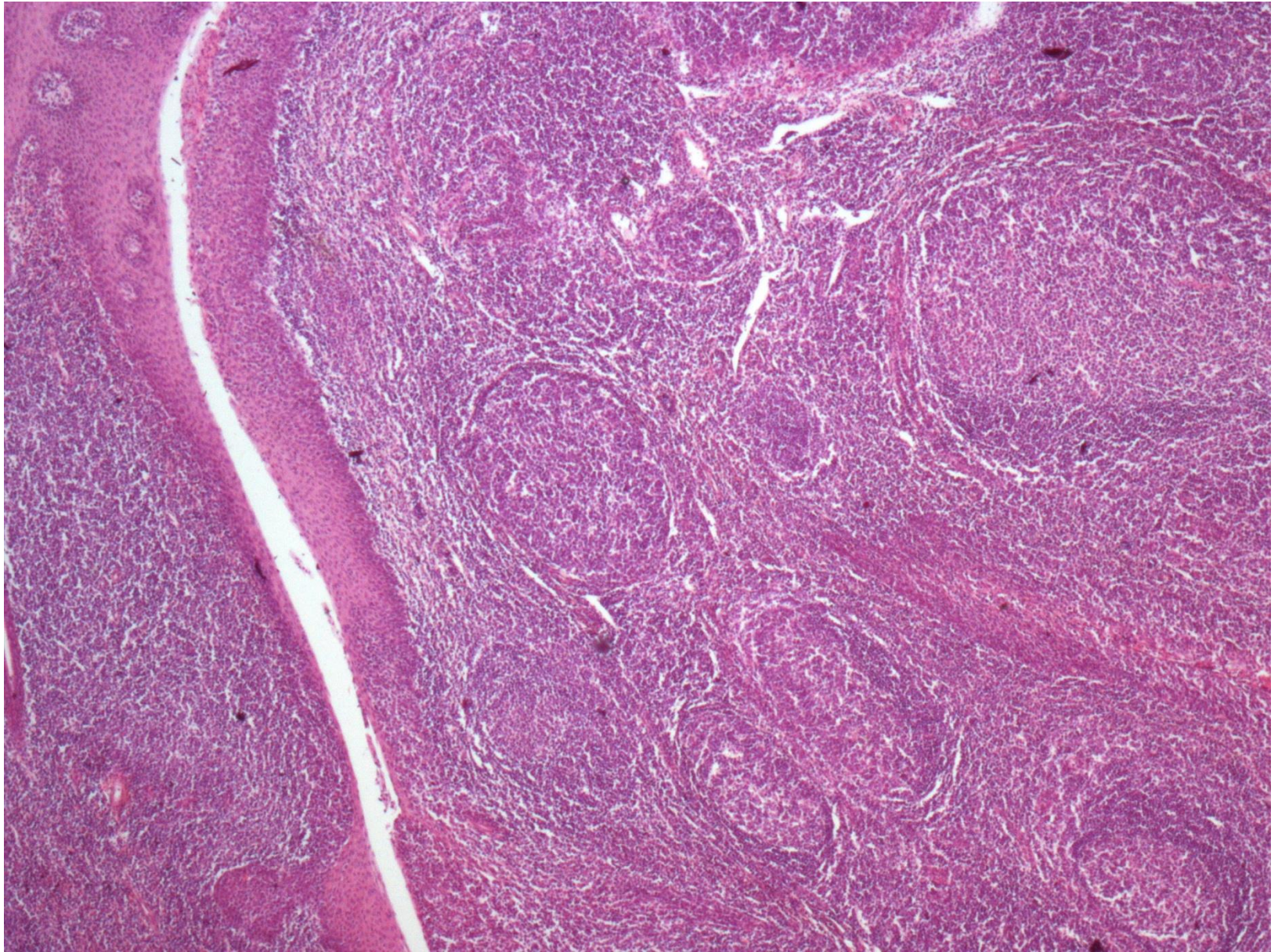
Lymph Node



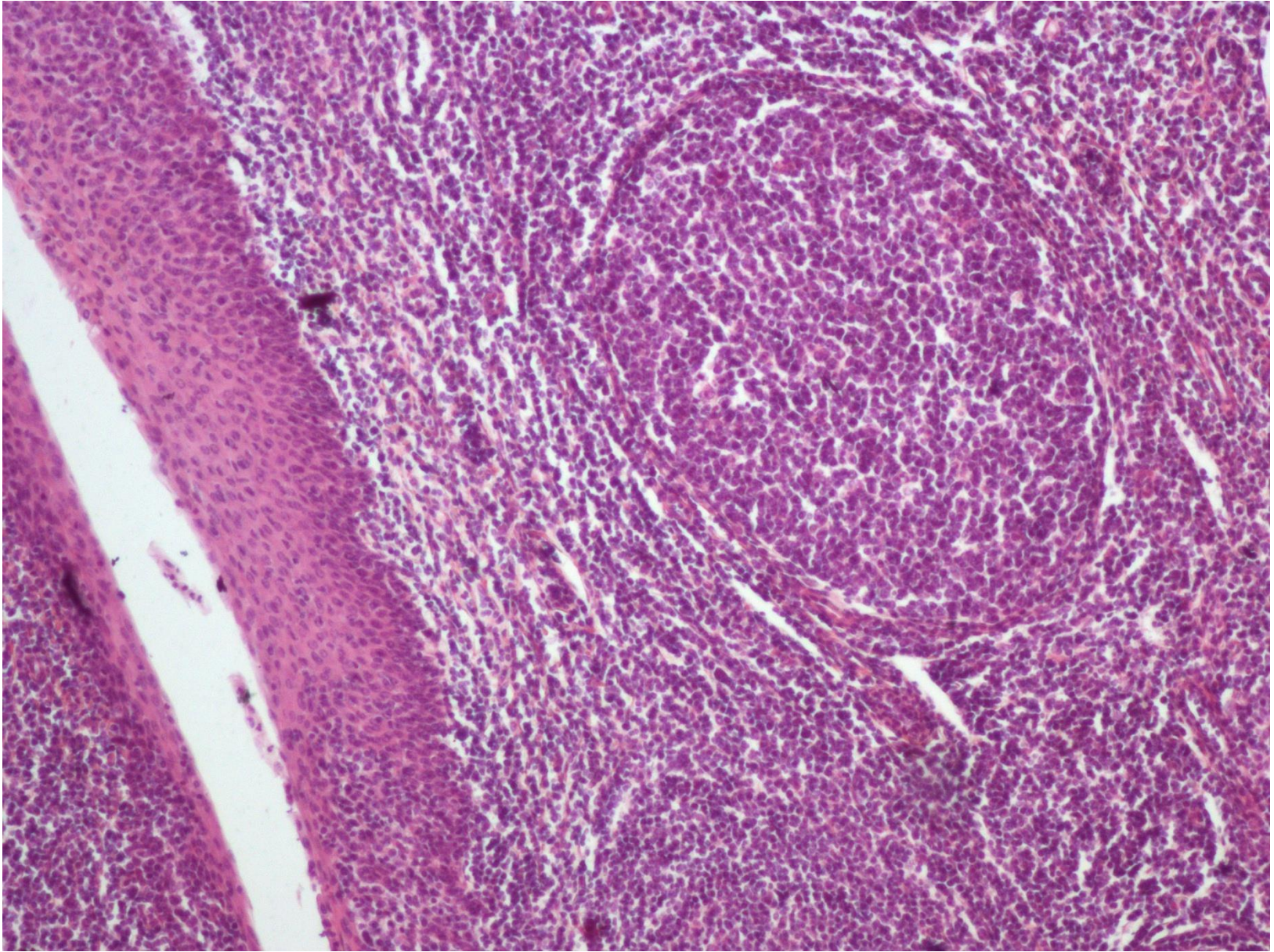
Thymus



Thymus



Palatine Tonsil



Palatine Tonsil