


Anatomical Terminology

هذا الملف غير مطالبين فيه لكن سيساعدكم كثير في فهم الدروس
الجاية وهو اجتهاد منا

Thanks for 434's Team

Musculoskeletal Block
ANATOMY
team 435

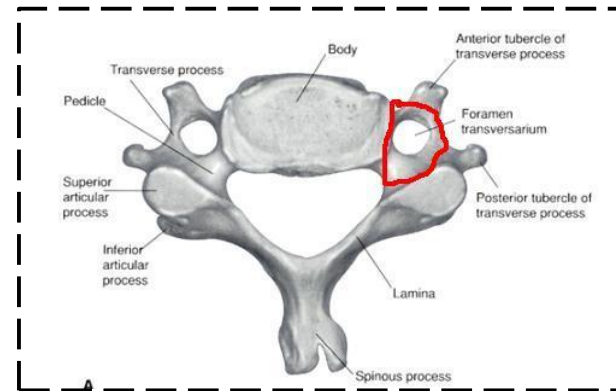


C O L O R C O D E S

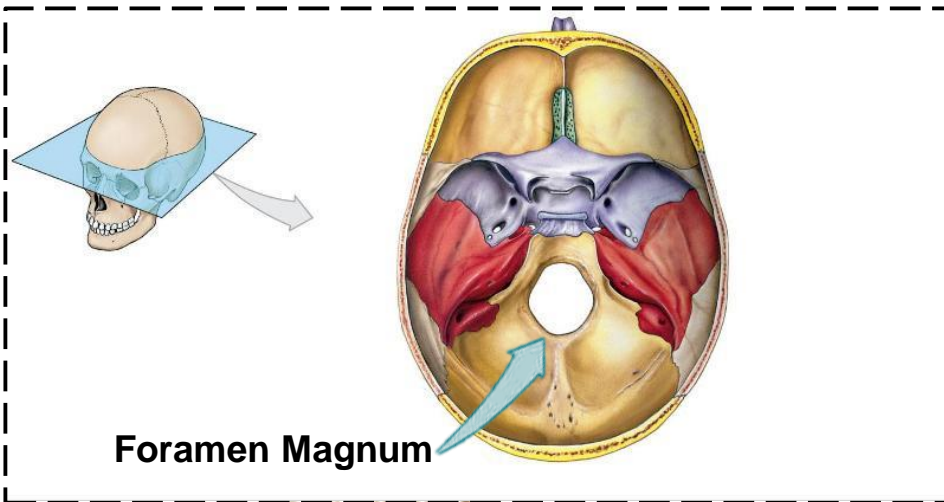
- IMPORTANT NOTES
- EXTRA NOTES
- DEFINITION

Foramen

a natural opening
or passage,
especially one into
or through a bone



باختصار مثل النفق بالضبط
عبارة عن منفذ لاي شي ممكن
يمر داخله



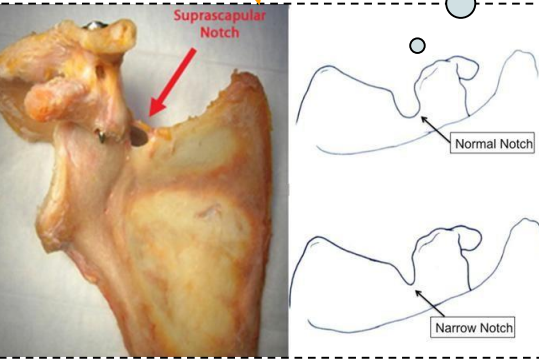
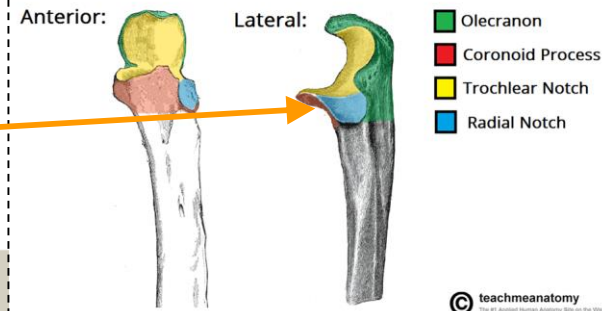
Notch

An indentation, (incision) on an edge or surface.

acts as the lock of the joint.

Indentation = تسنن

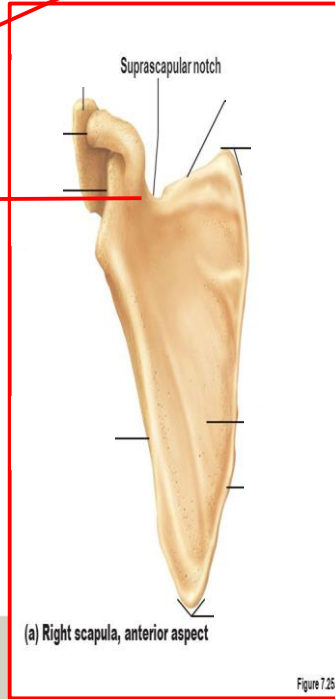
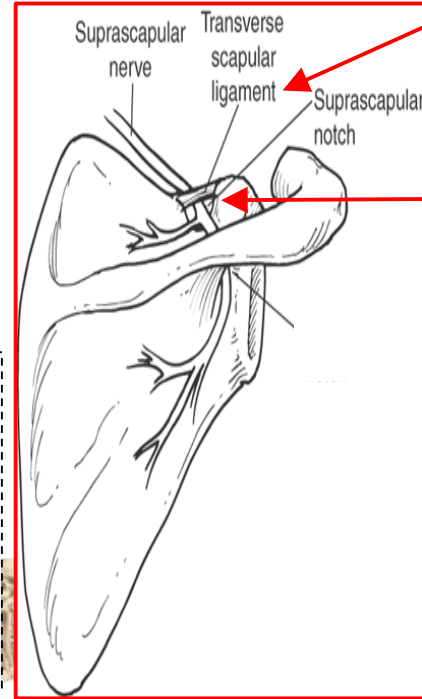
Example:
Radial notch in the ulna



في هذي الصورة في مثال على مرض
مو معكم
بس عشان تعرفون النوتش

2D
(next slide)

A notch is simply an incomplete foramen, usually along the border of the bone. The notch is usually along the border of the bone. It can be a bridge between two bones or a hole in the bone. It is called a foramen.

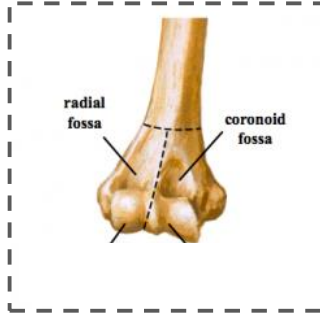


Fossa

انخفاض في مكان ما = hollow

A hollow place

acts as the lock of the joint.



Example:
Radial and Coronoid fossae(plural of fossa) in the humerus

اللي قبلها أنه (نوتش) الفرق بينها وبين :

(fossa)

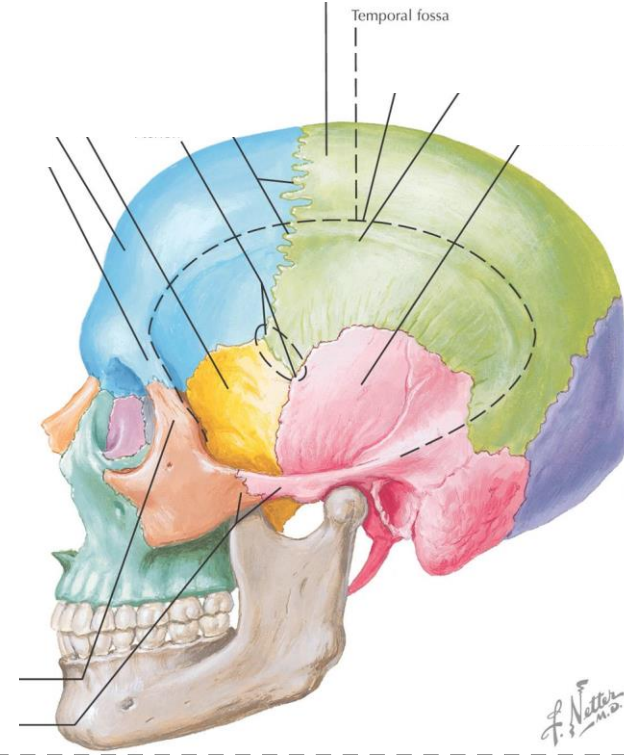
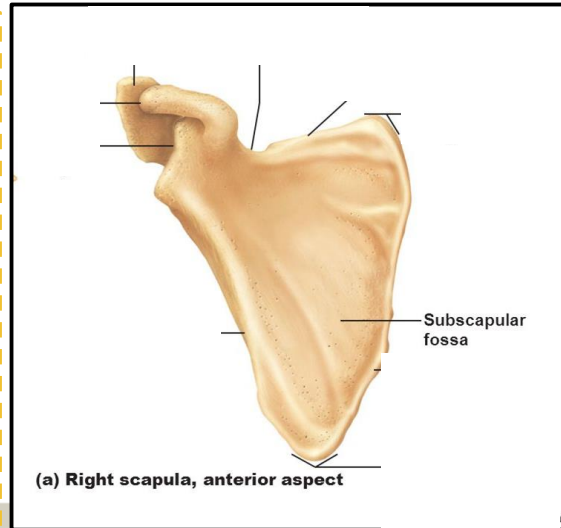
عبارة عن انخفاض في العظم ما راح تشوفها

الا اذا شفتها (3D)

اما (notch)

في حدود "نزلة" تكون في الغالب زي العظم

(2D)



Groove

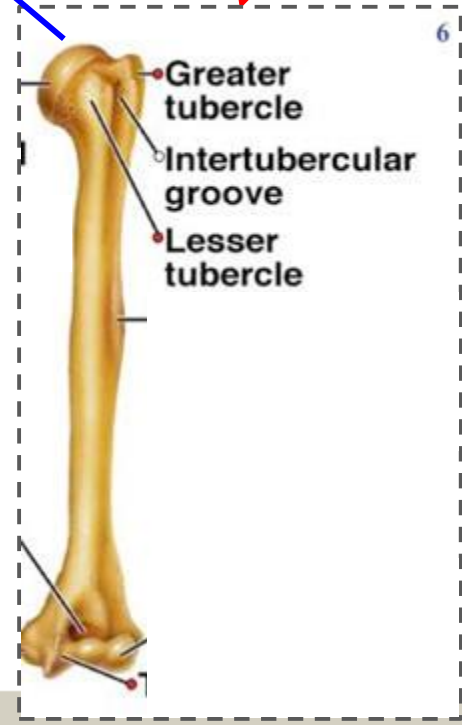
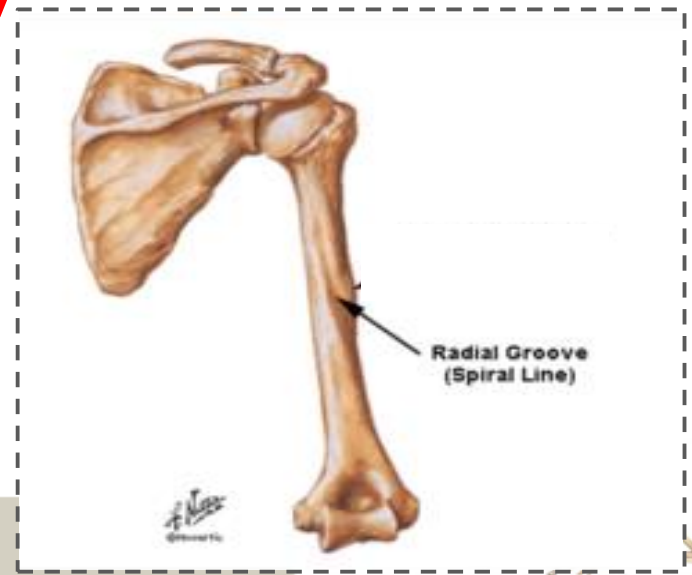A channel, a narrow, linear hollow or depression.

GROOVE = أخدود
Channel = قناة

اضيق واعمق من
Fossa



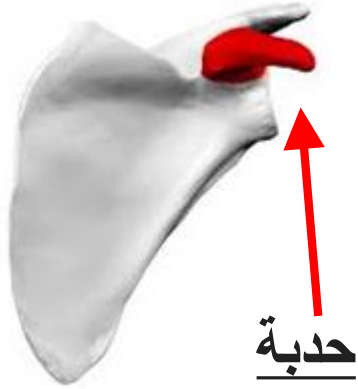Example:
Intertubercular groove in the humerus



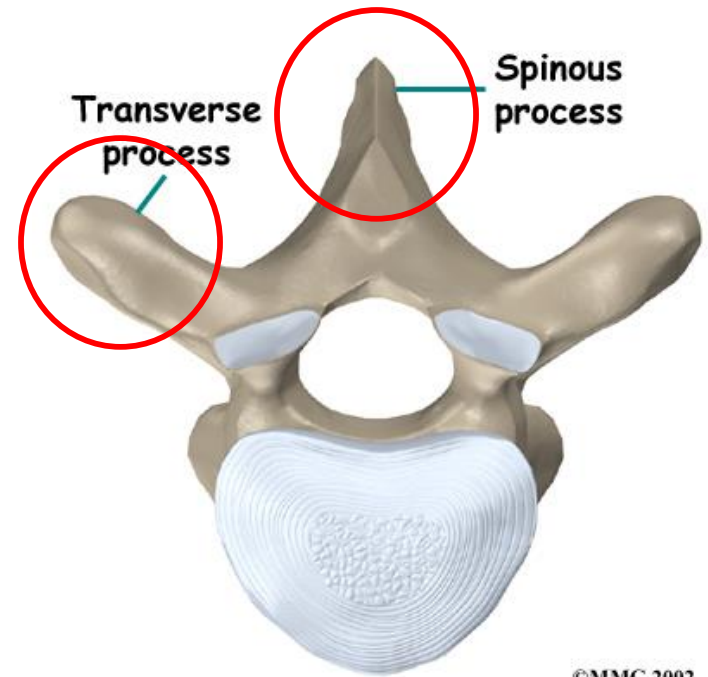
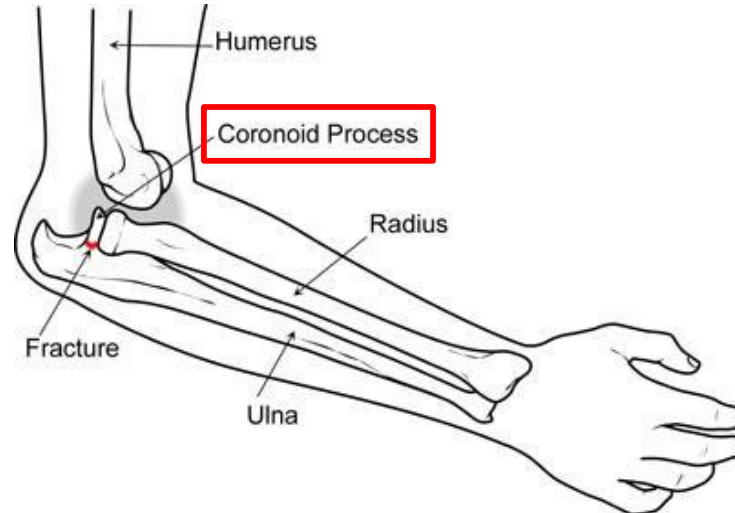
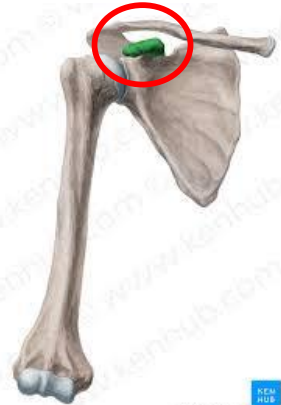Process

A V - shaped indentation
(Acts like the key of the joint.)

In the scapula we have 3 processes:
1- spine.
2- acromion
3- coracoid



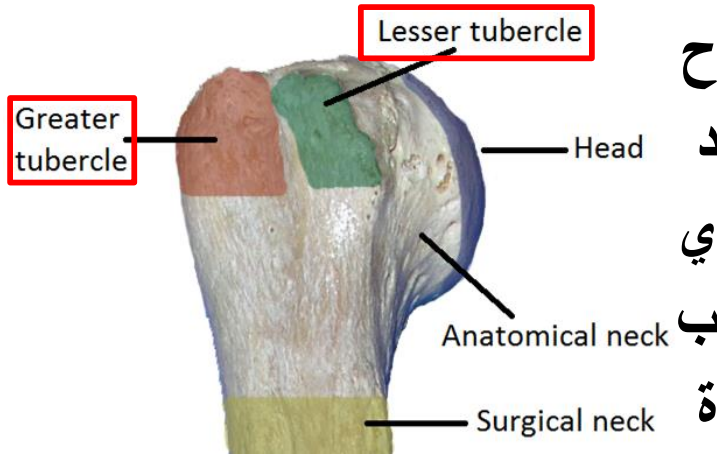
حذبة



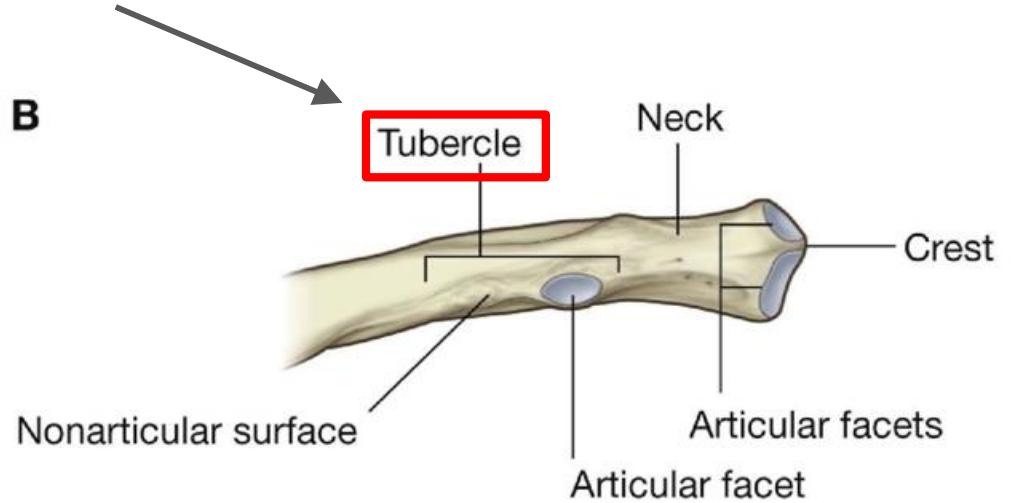
©MMG 2002

Tubercles

A nodule or a small rounded projection on a bone.

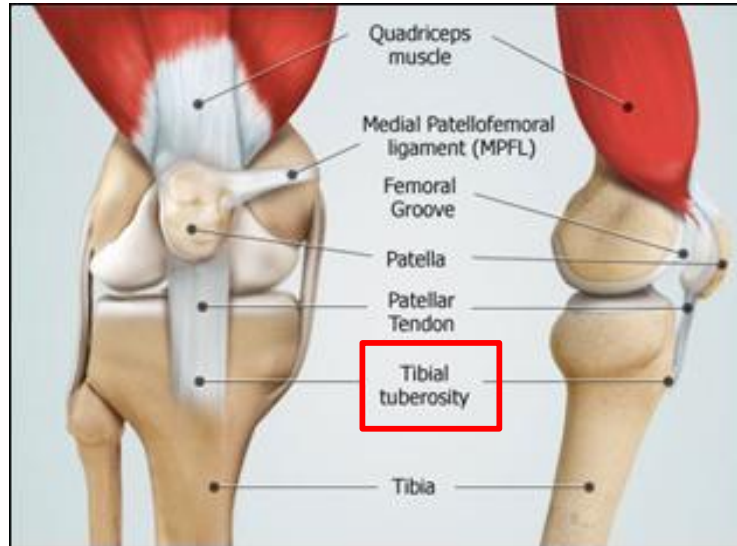
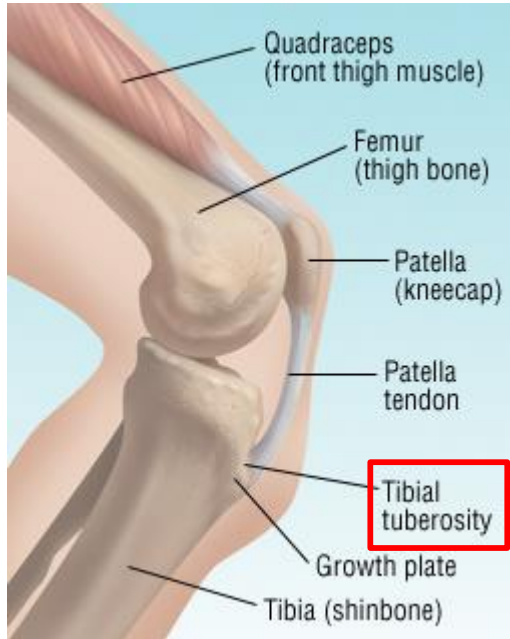


B



Tuberosity

a large prominent on a bone usually serving for the attachment of muscles or ligaments



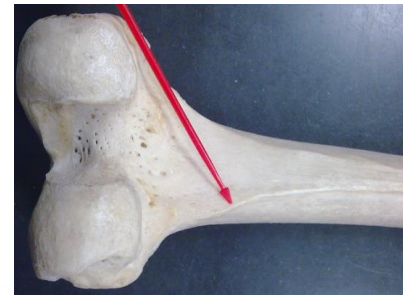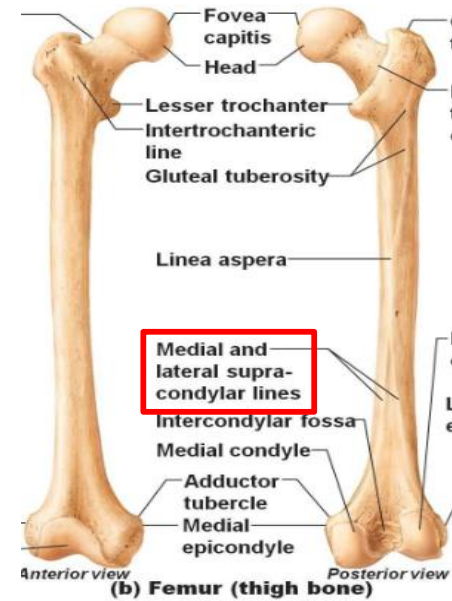
Ridge

meaning

- The long and narrow upper edge, angle, or crest of something

Example

- The lateral supracondylar ridge in the femur



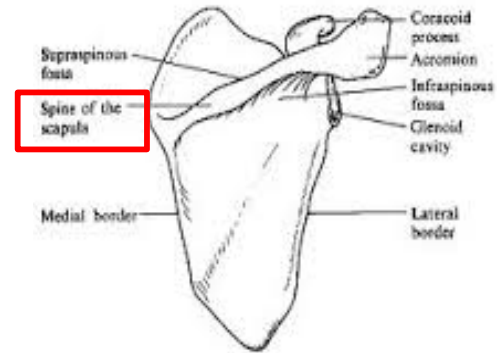
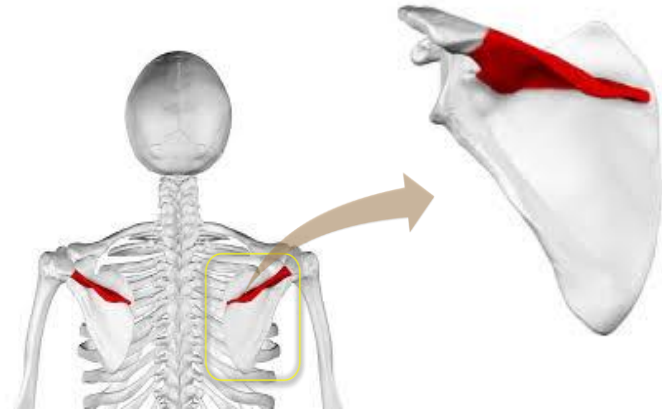
Spine

meaning

- Thick projecting ridge of bone

Example

- Spine of the scapula



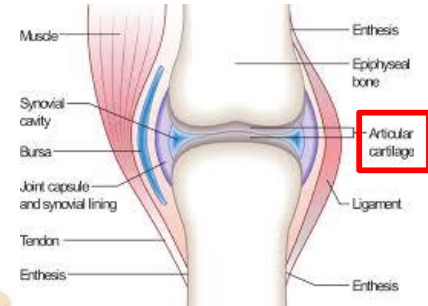
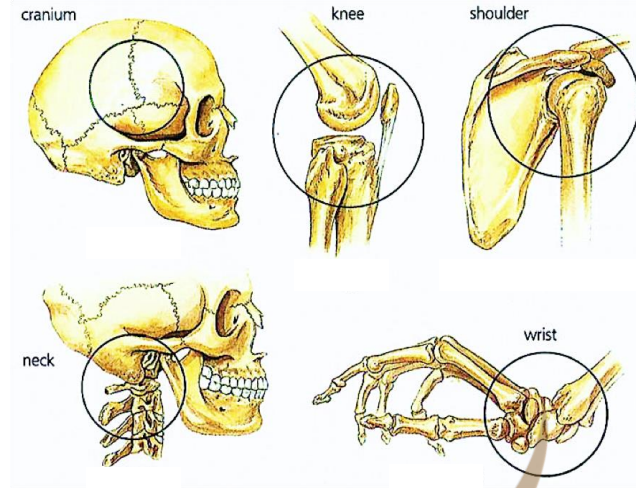
Articulation

meaning

- Meeting of two bones to make the joints

Example

- Any type of joints



interosseous border

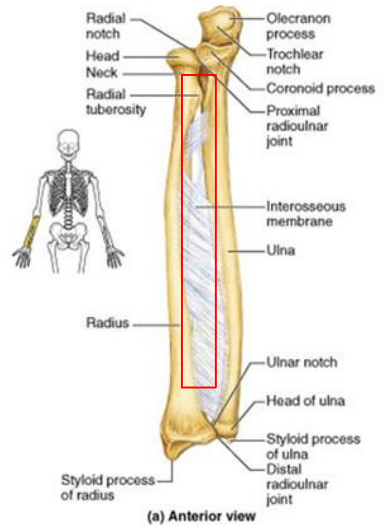
Between bones (the place where the two parallel bones attach together by the interosseous membrane)

هو عبارة عن غشاء في المنطقة التي تتحد فيها عظمتان متوازيتان

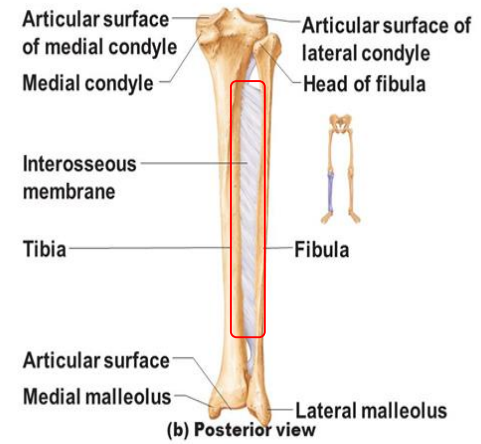
“is a broad and thin plane of fibrous tissue that separates many of the bones of the body.”

Examples of Interosseous membrane:

The **interosseous membrane** in the **forearm** extends between the **radius** and the **ulna**.



In the **leg**, the **interosseous membrane** extends between the **tibia** and the **fibula**.

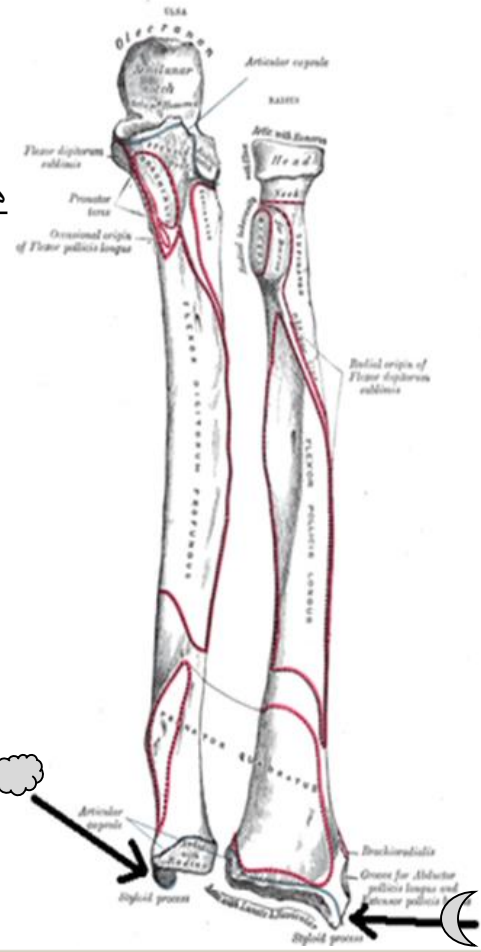


Styloid process: It's slender, pointed process that usually serves as **point of attachment for muscles, ligaments**, and might form **joints**.

هي عبارة عن حدبة نحيلة وبارزة، تُستخدم كنقطة ارتباط للعضلات والأربطة ومن الممكن أن تُكوّن مفاصل

Examples of styloid process:

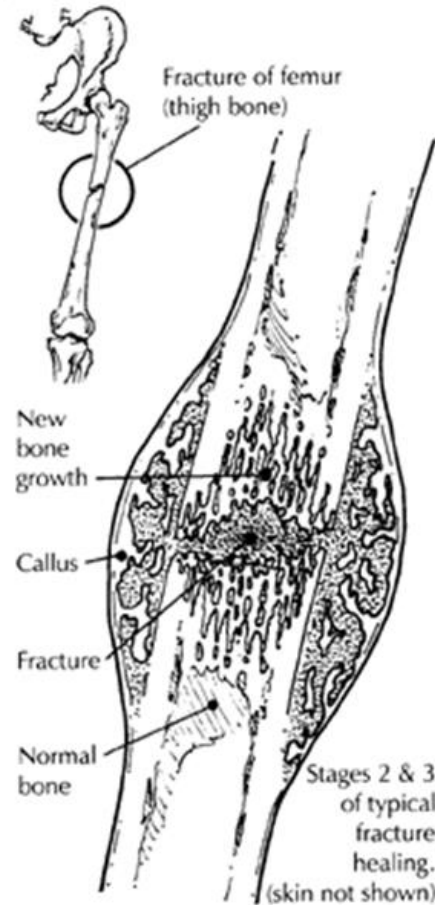
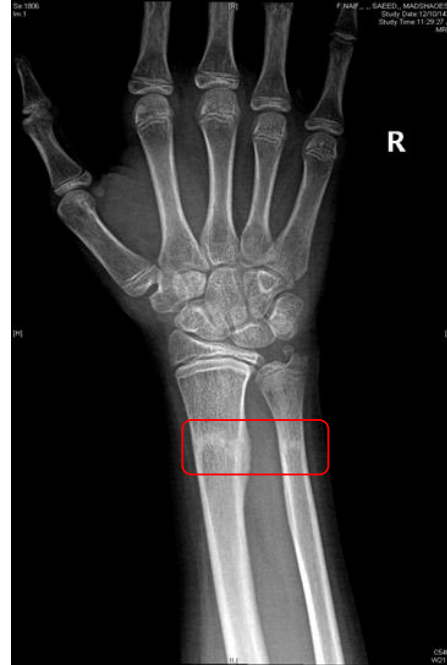- radius bone of the forearm - Radial styloid process ☾
- ulna bone of the forearm - Ulnar styloid process ☁



Union of the bone: is a **proliferative** physiological process in which the body facilitates the **repair of a bone fracture**. (growing of tissues of the fractured ends of a bone). هي عملية فسيولوجية تكاثيرية، حيث أن الجسم يسهّل عملية إصلاح العظم المنكسر.

Examples of union of the bone:

- union of **femur** bone fracture
- union of **radius** and **ulna**



Term	Meaning	Example
Processes	A V-shaped indentation (act as the key of the joint)	Coracoid process in the scapula
Notch	An indentation, (incision) on an edge or surface	Radial notch in the ulna
Fossa	A hollow place (The Notch is not complete but the fossa is complete and both of them act as the lock of the joint)	Radial fossa in the humerus
Tubercles	A nodule or a small rounded projection on a bone	Dorsal tubercle in the radius
Tuberosity	A large prominence on a bone usually serving for the attachment of muscles or ligaments (is a bigger projection than the Tubercle)	Tibial tuberosity in the tibia
Groove	A channel, a long narrow depression sure	Intertubercular groove in the humerus
Interosseous border	Between bones (the place where the two parallel bones attach together by the interosseous membrane)	Sharp medial interosseous in the radius
Ridge	The long and narrow upper edge, angle, or crest of something	the lateral supracondylar ridge in the femur
Spine	Thick projecting ridge of bone	Spine of the Scapula
Articulation	Meeting of two bones to make the joints	Any type of joint
Styloid process	usually serves as point of attachment for muscles, ligaments, and might form joints	Radial styloid process (wrist joint)
Union of the bone	إعادة إلتحام العظام ببعضها عشان ترجع للحالة الطبيعية	union of scaphoid bone fracture

هذا العمل إجتهد من طلاب و طالبات
إن أصبنا فمن الله وإن أخطانا فمن أنفسنا ومن الشيطان

TEAM LEADERS:

Ghaida Aljamili
Elham Alzahrani
Abdullah Alfuraih
Boudor Julaidan

- For questions and suggestions
you can contact us on
Anatomy435@gmail.com

