

Radial & Ulnar Nerves

Dr. Jamila & Dr. Vohra

Objectives

- **At the end of the lecture, students should be able to:**
- **Describe the anatomy of the radial & ulnar nerves regarding: origin, course & distribution.**
- **List the branches of the nerves.**
- **Describe the causes and manifestations of nerve injury.**

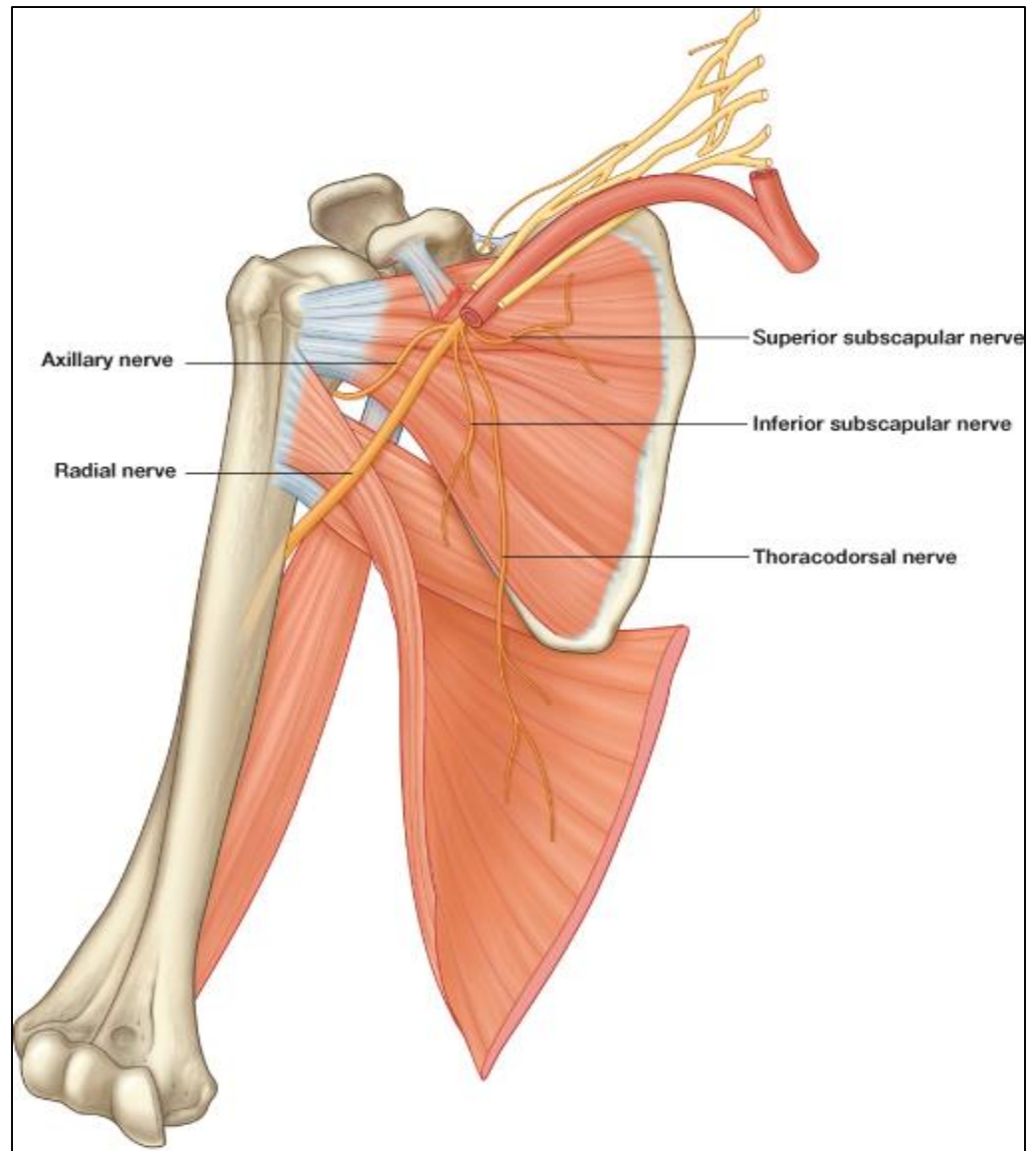
Radial Nerve

Origin:

Posterior cord of the brachial plexus in the axilla (the largest branch)

Supplies:

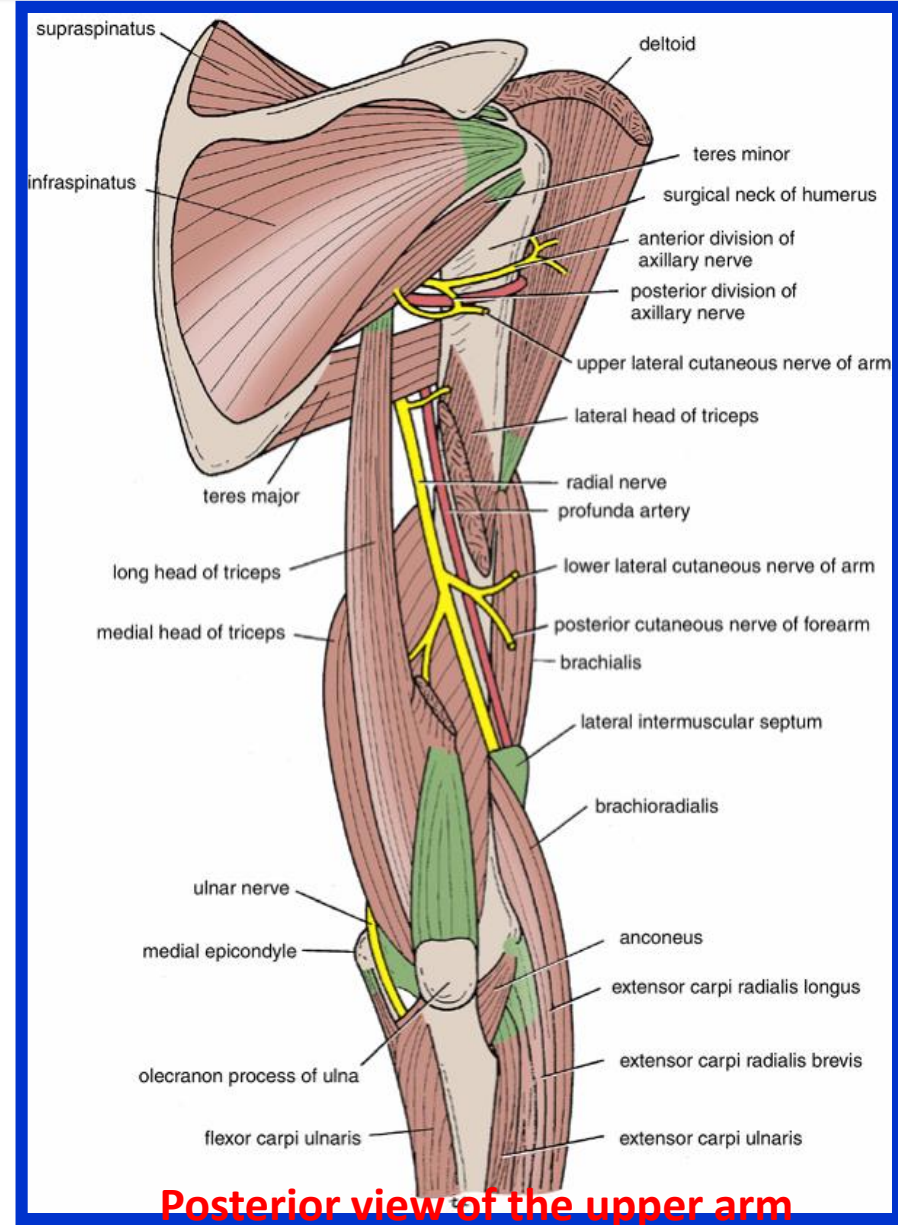
All Muscles of the posterior compartment of the arm & fore arm



Course & Distribution In the Arm

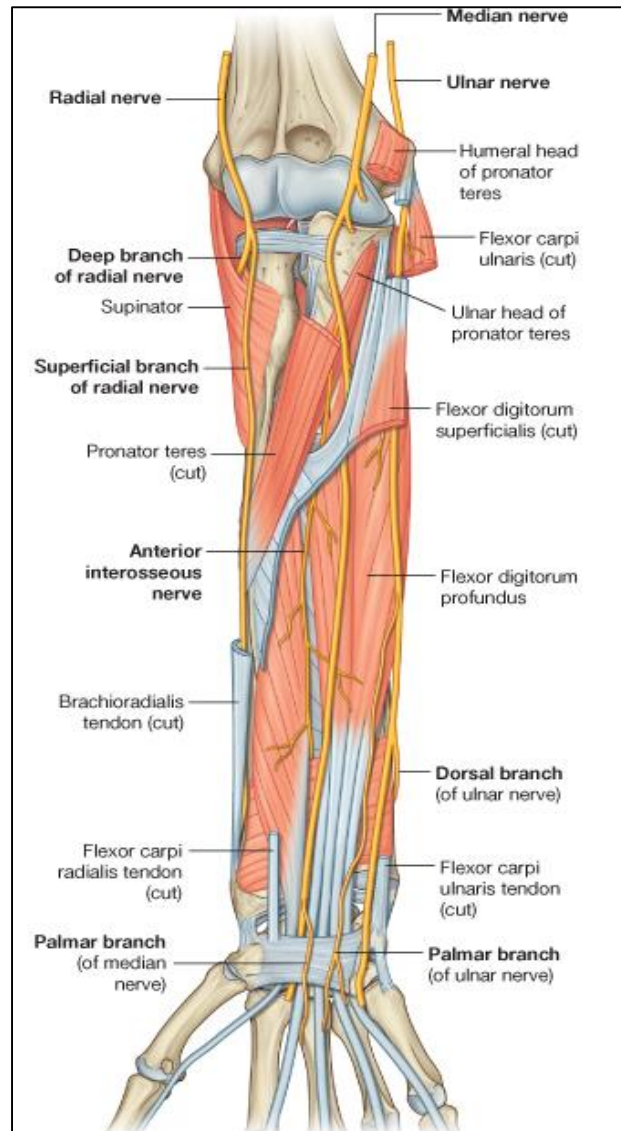
It winds around the back of the arm in the **Spiral Groove** on the back of the humerus between the heads of the triceps.

In the **spiral groove**, the nerve is accompanied by the **Profunda Vessels**, and it lies directly in contact with the shaft of the humerus (**Dangerous Position**).



Course In the Forearm

It pierces the Lateral Intermuscular septum.
Descends in front of the Lateral Epicondyle.
Passes forward into the Cubital Fossa
Divides into Superficial & Deep branches.



Branches

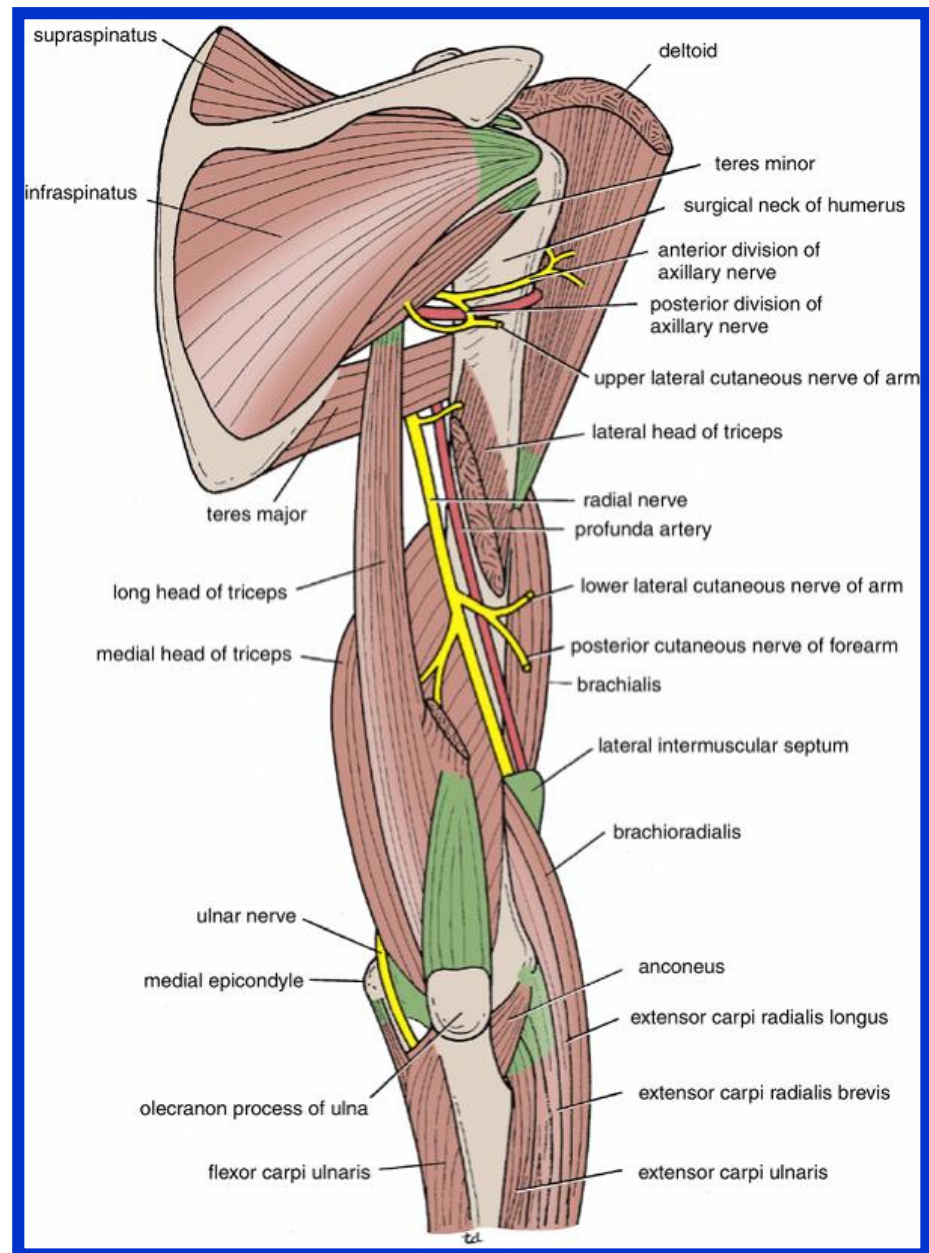
Arising In The
Axilla:

Cutaneous:

**Posterior
cutaneous nerve of
arm.**

Muscular to:

**Long & Medial
Heads of Triceps.**



Branches

Arising In the Spiral Groove:

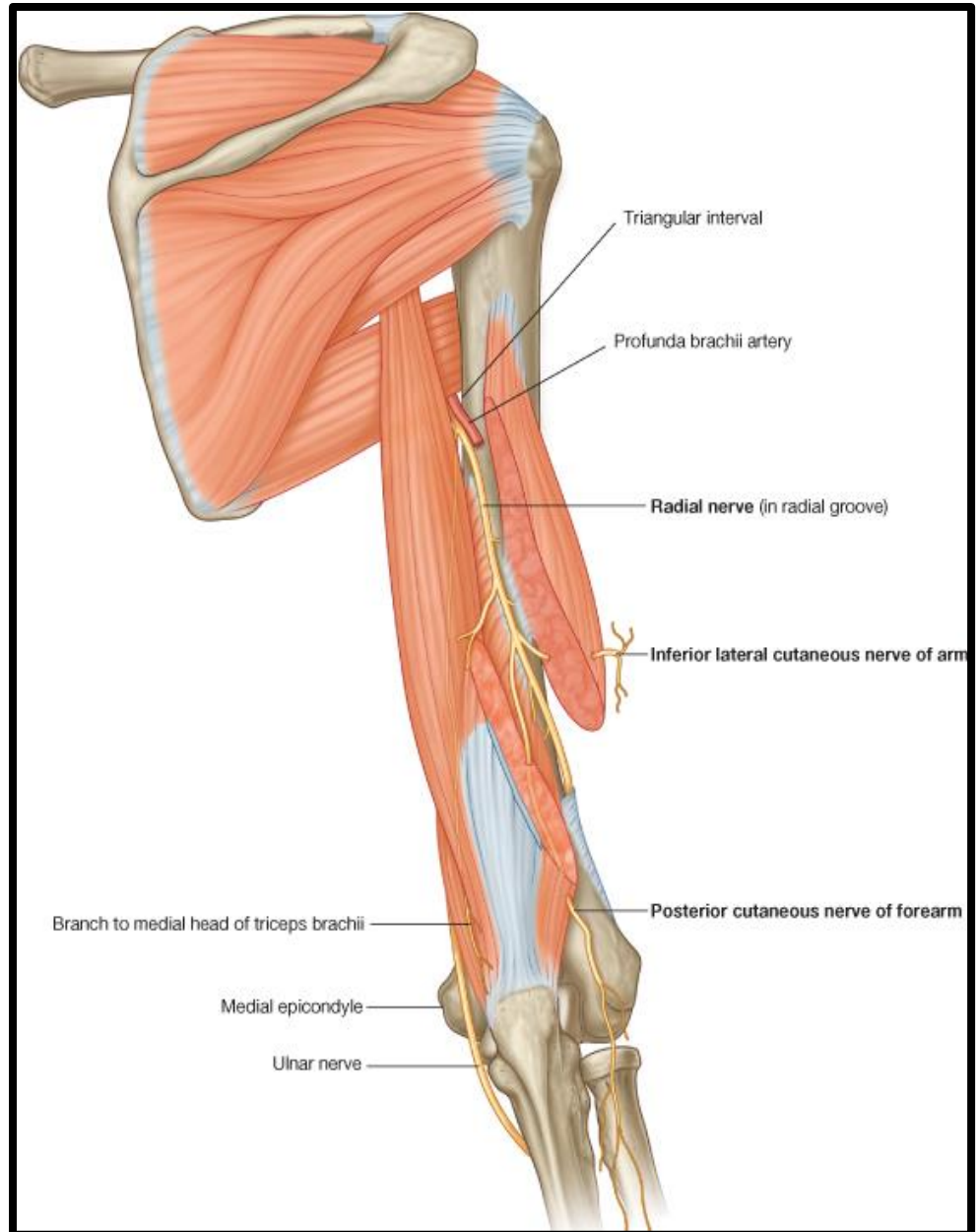
Cutaneous:

- 1. Lower lateral cutaneous nerve of arm.**
- 2. Posterior cutaneous nerve of forearm.**

Muscular to:

Lateral & Medial heads of triceps.

Anconeus.



Branches

Arising Close to Lateral Epicondyle:

1. Muscular to :

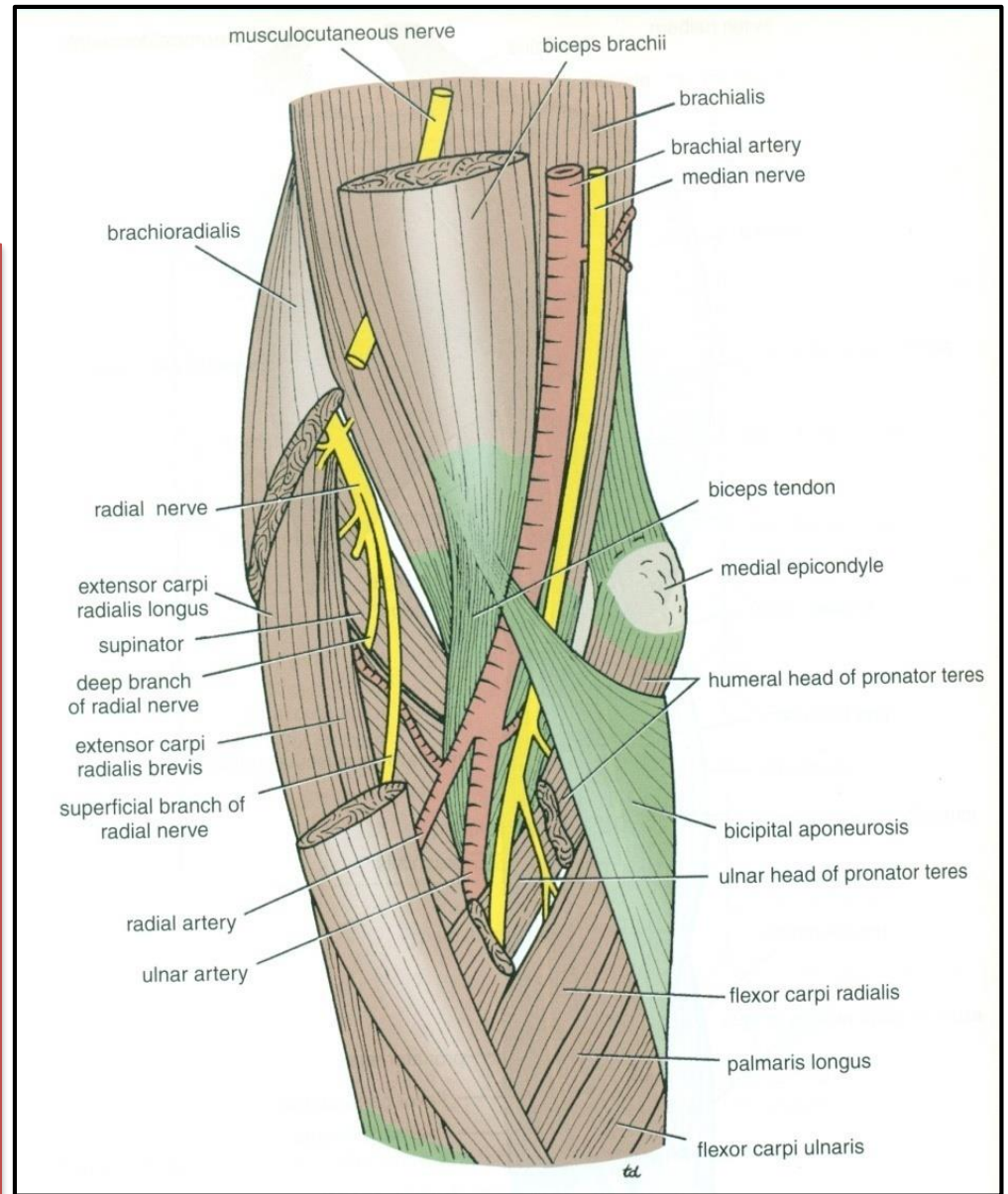
Brachioradialis.

Extensor carpi radialis longus.

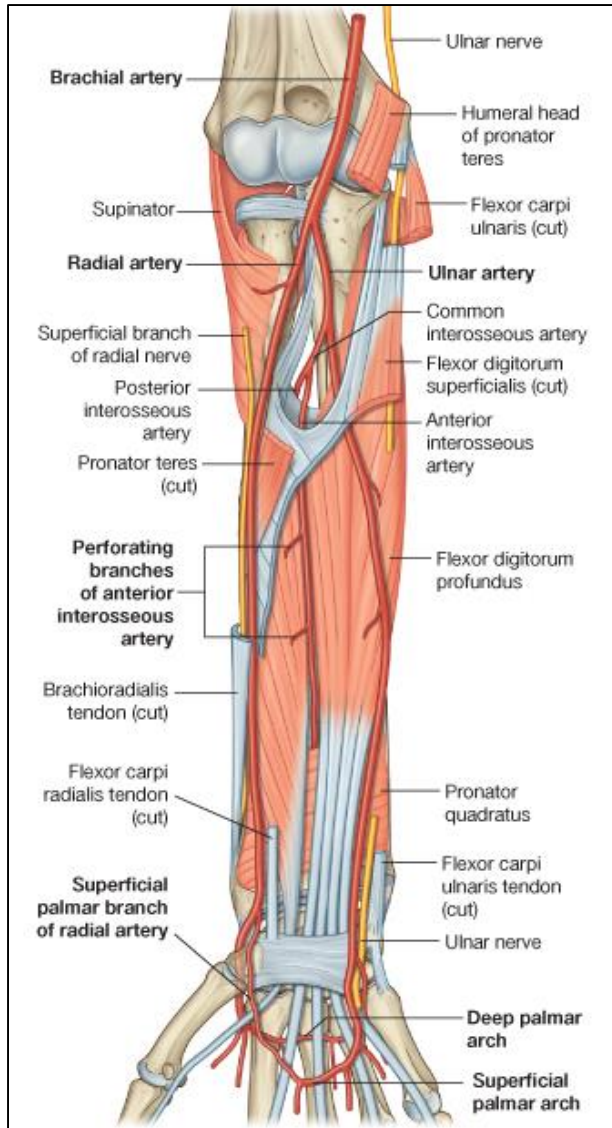
Brachialis.

2. Articular to:

Elbow joint



Superficial Branch

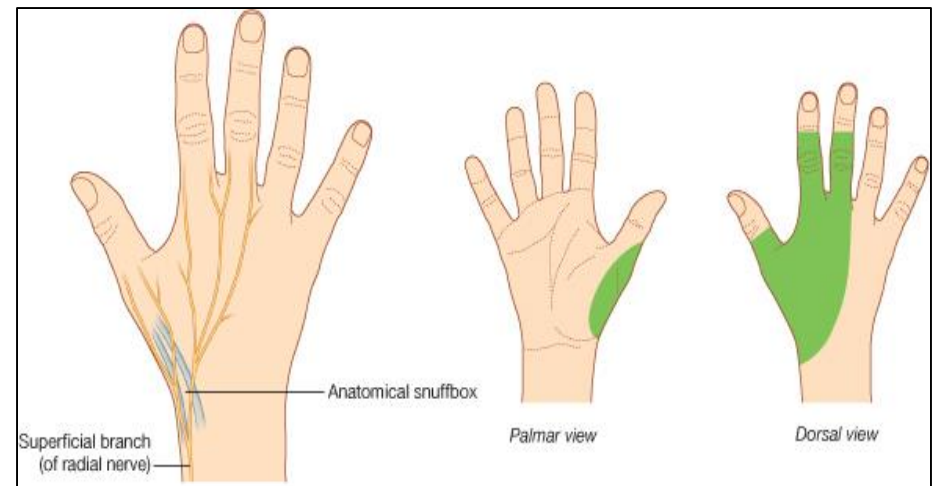


- It descends under cover of Brachioradialis
- Lateral to radial artery.
- It emerges beneath the brachioradialis tendon.

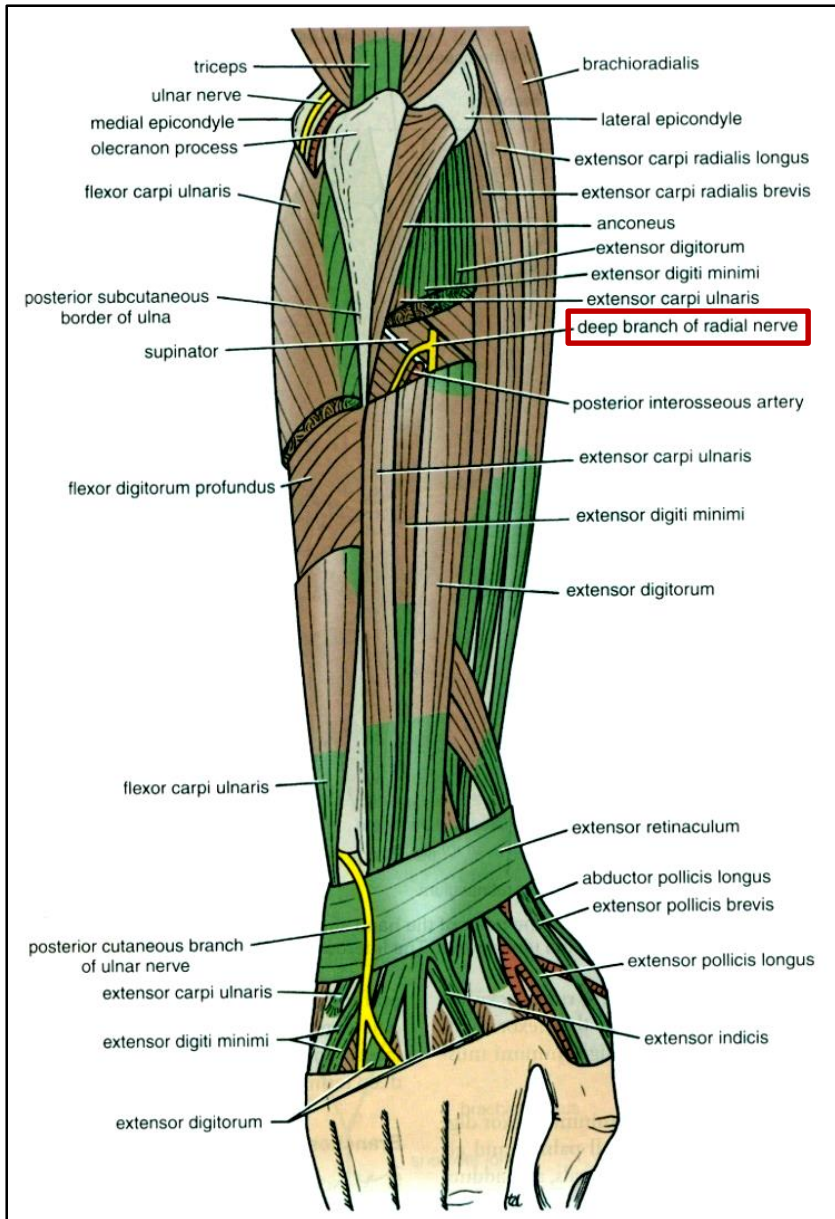
Termination of Superficial Branch

It reaches the posterior surface of the wrist, where it divides into terminal branches that supply the skin on ***the lateral two thirds of the posterior surface of the hand and the posterior surface over the proximal phalanges of the lateral three and half fingers.***

The area of skin supplied by the nerve on the dorsum of the hand is variable.

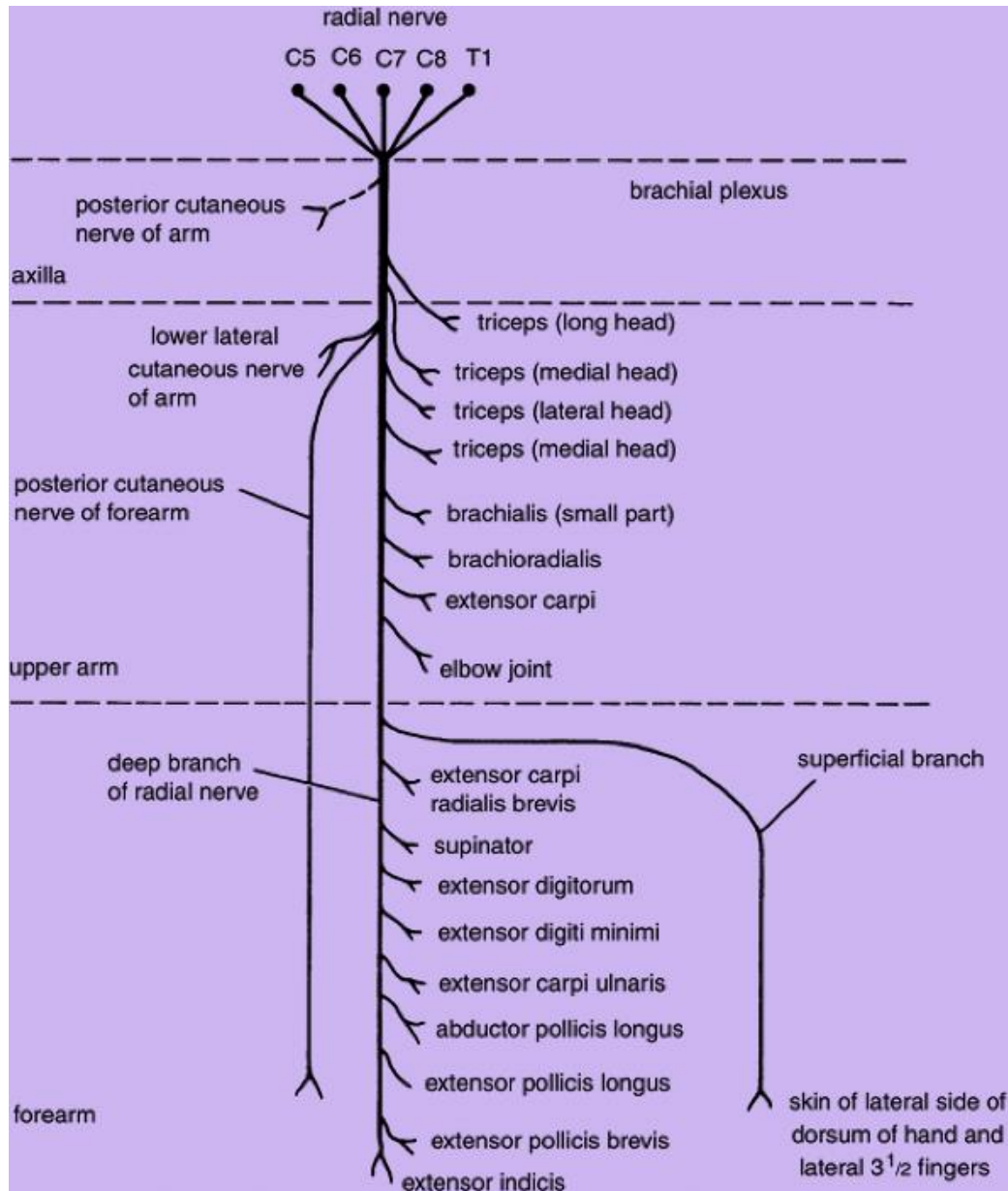


Deep Branch



- ***It winds around the neck of the radius, within the supinator muscle, and enters the posterior compartment of the forearm.***
- ***It supplies :***
- ***Extensor carpi radialis brevis.***
- ***Extensor carpi ulnaris.***
- ***Supinator.***
- ***Abductor pollicis longus.***
- ***Extensor pollicis brevis.***
- ***Extensor pollicis longus.***
- ***Extensor indicis.***
- ***Extensor digitorum.***
- ***Extensor digiti minimi.***

Summary of branches of radial nerve



Injuries to the Radial Nerve

In the Axilla:

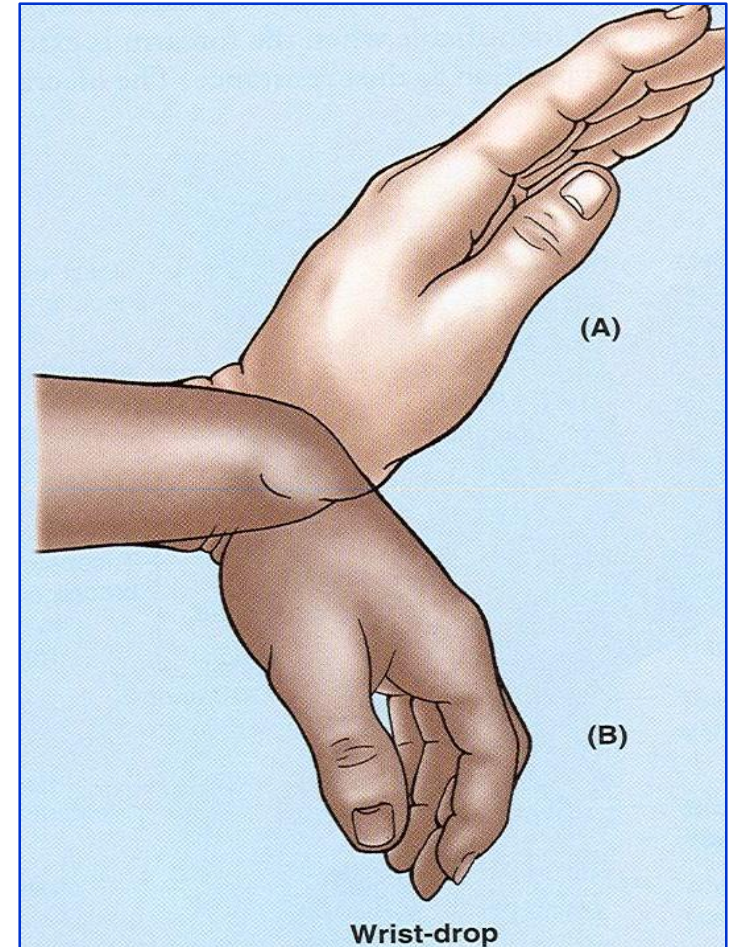
The nerve can be injured by a drunkard falling asleep with one arm over the back of a chair, also by fractures and dislocations of the proximal end of the humerus.

The triceps, the anconeus, and the long extensors of the wrist are paralyzed.

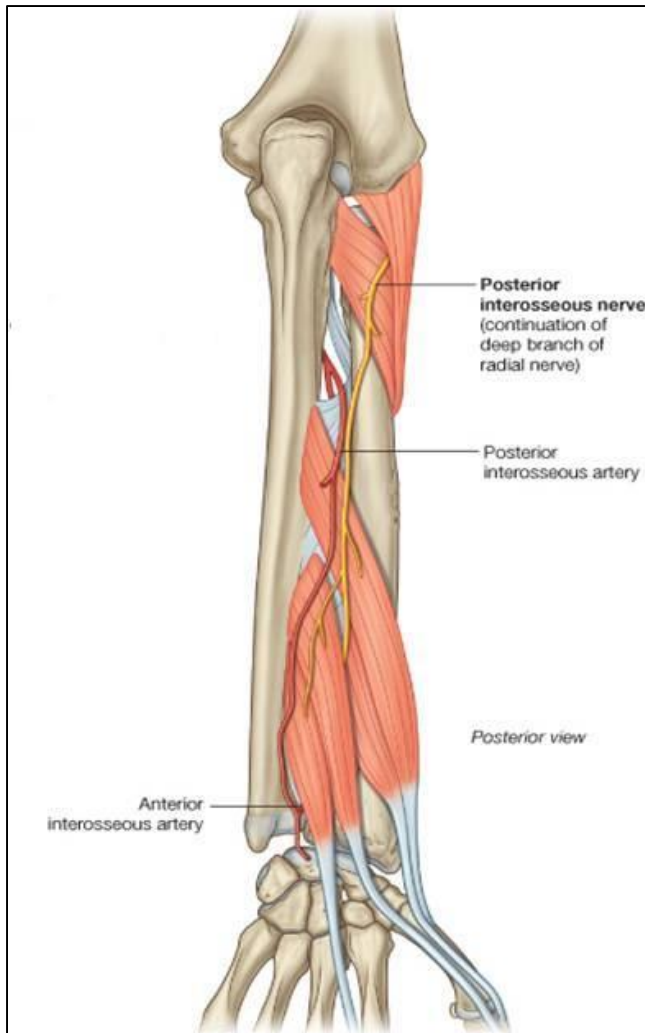
The patient is unable to extend the elbow & the wrist joints, and the fingers (**Wrist Drop**)

In the Spiral Groove:

Injury or fracture of the spiral groove of the humerus, the patient is unable to extend the wrist and the fingers (**Wrist Drop**).



Injuries to the Deep Branch of the Radial Nerve

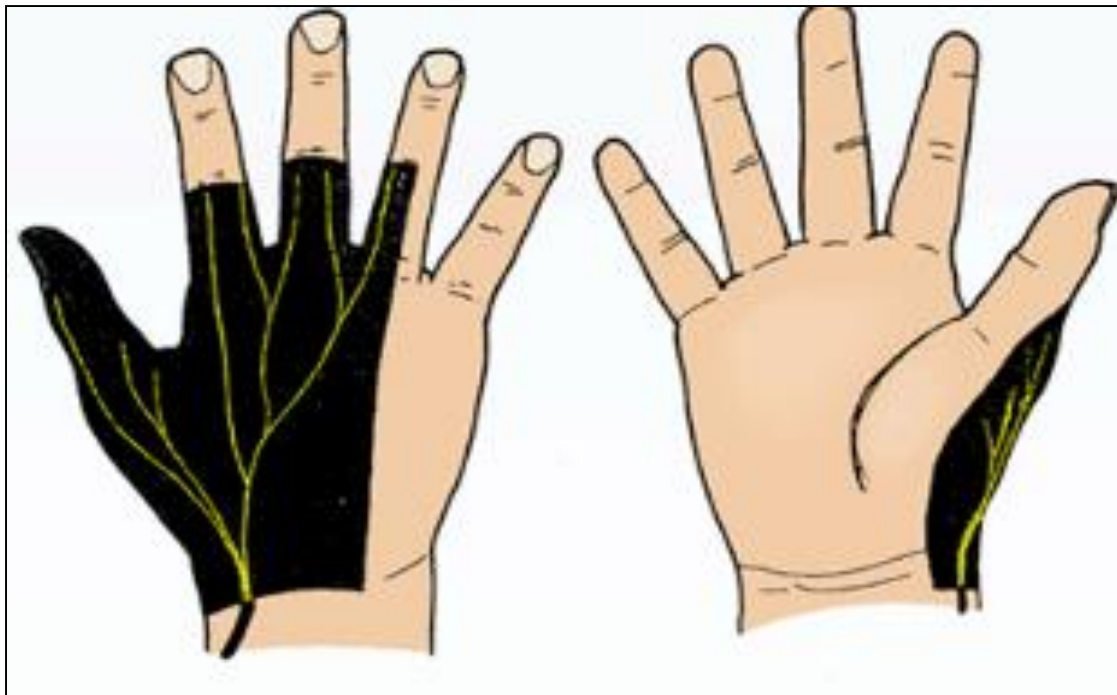


- The deep branch of the radial nerve is **PURELY Motor** (It supplies the extensor muscles in the posterior compartment of the forearm).
- It can be damaged in fractures of the proximal end of the radius or during dislocation of the radial head.
- **The nerve that supply the supinator and the extensor carpi radialis longus will be undamaged**, and because the latter muscle is powerful, it will keep the wrist joint extended,
- **(No wrist Drop)**
- **No sensory loss**

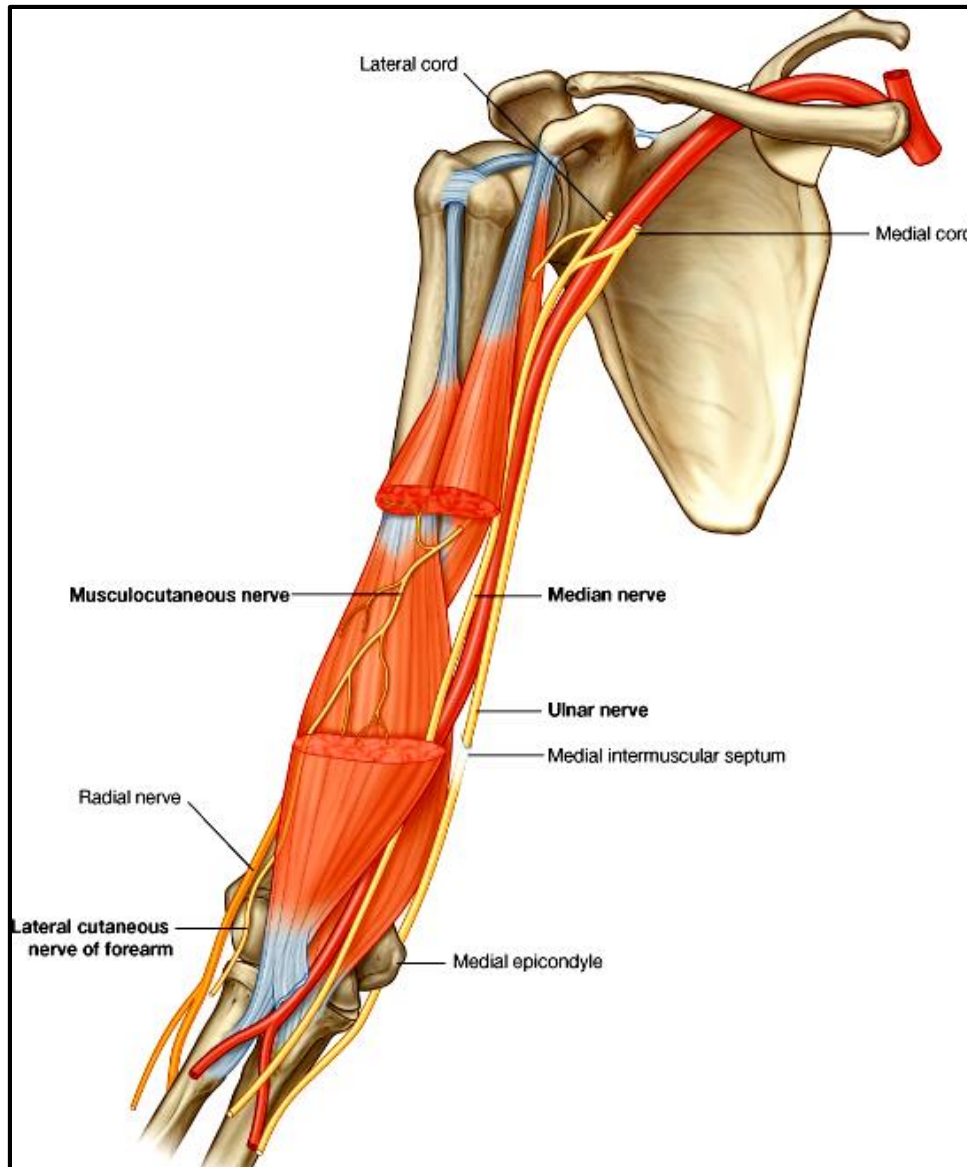
Injuries to the Superficial Branch of the Radial Nerve

Superficial radial nerve, is **Sensory nerve**

Injury like a stab wound, results in a variable small area of anesthesia over the **dorsum of the hand and lateral three and half fingers up to the base of their proximal phalanges.**



Ulnar Nerve



- **Origin:**
- Medial cord of BP.
- **Course:**
- Descends along the ***medial side of the following arteries:***
- ***Axillary,***
- ***Brachial.***
- ***Pierces the Medial Intermuscular Septum.***
- ***Passes Behind the Medial Epicondyle of the humerus.***

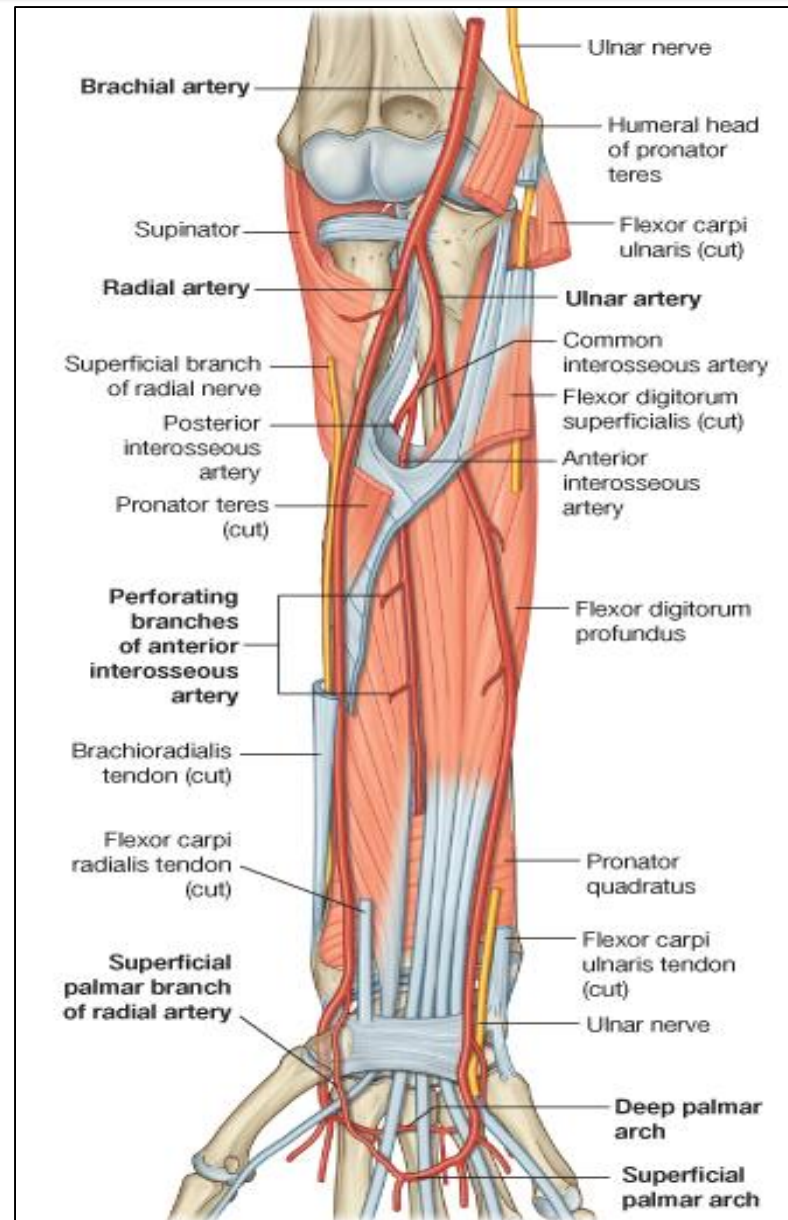
Course In the Forearm

Enters the anterior compartment through the flex carpi ulnaris.

Descends:

Behind the Flexor Carpi Ulnaris.

Medial to Ulnar Artery.



course At the Wrist

Passes:

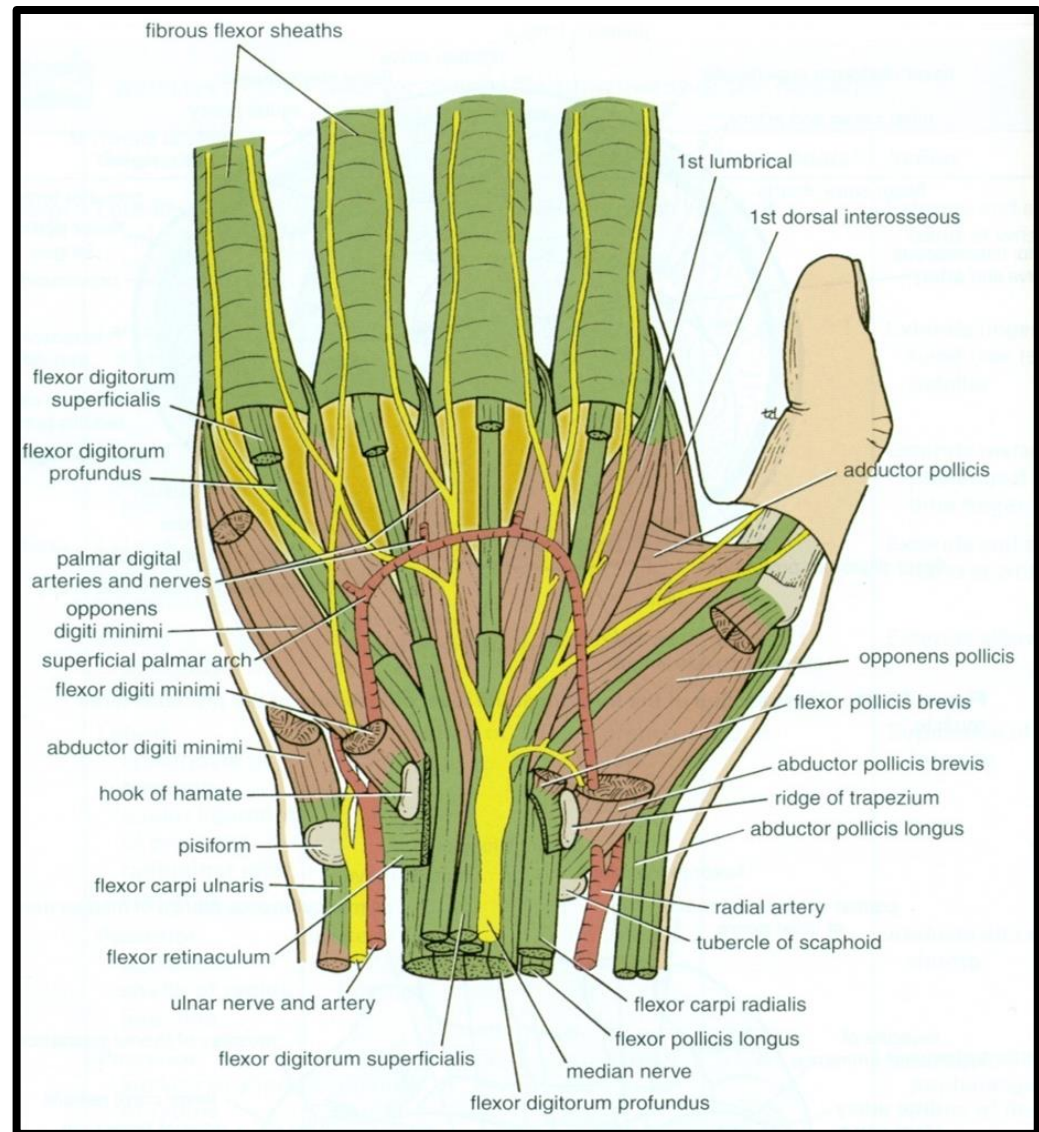
Anterior to Flexor Retinaculum.

Lateral to Pisiform bone.

Medial to Ulnar artery.

Divides into :

Superficial & Deep branches.



Branches

It has No branches in the arm

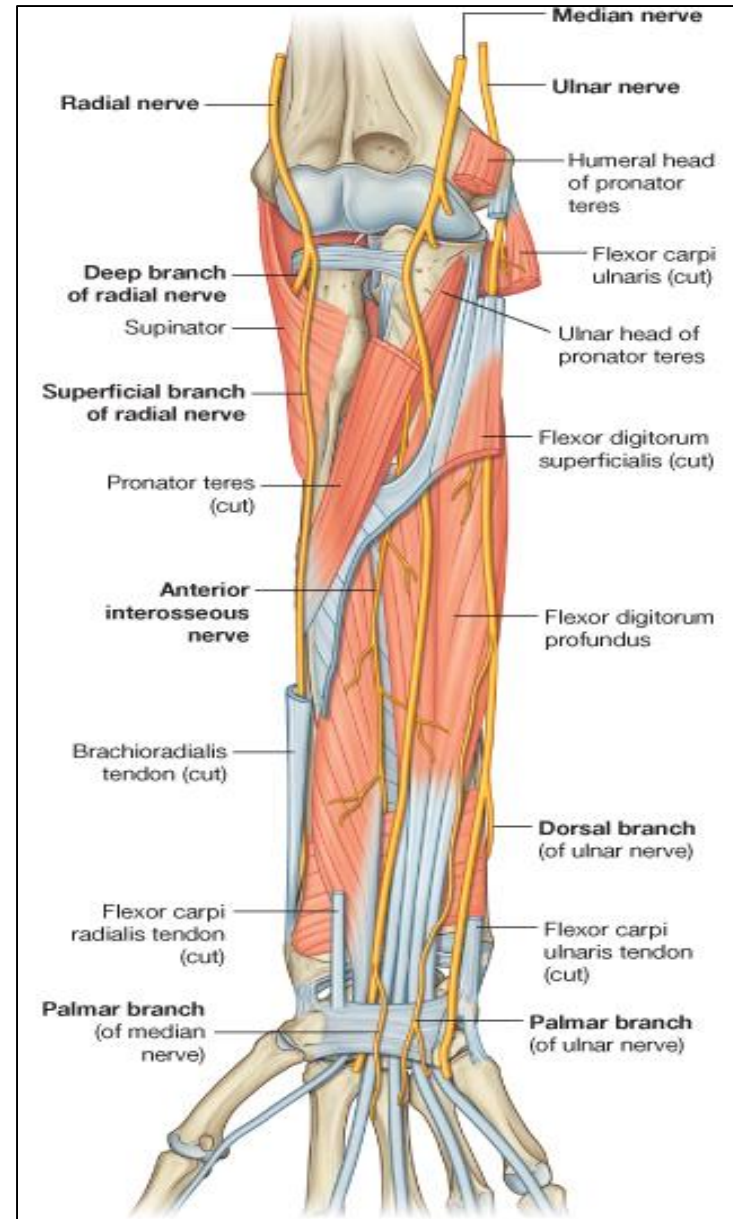
In the Forearm:

a. Muscular TO :
(1 & 1/2 muscles):

**Flexor Carpi
Ulnaris.**

**Medial 1/2 of Flexor
Digitorum
Profundus.**

b. Articular TO:
Elbow joint.



Branches

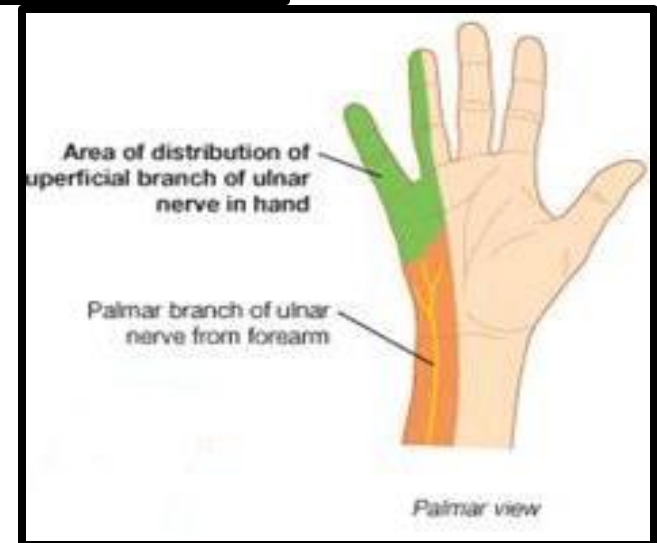
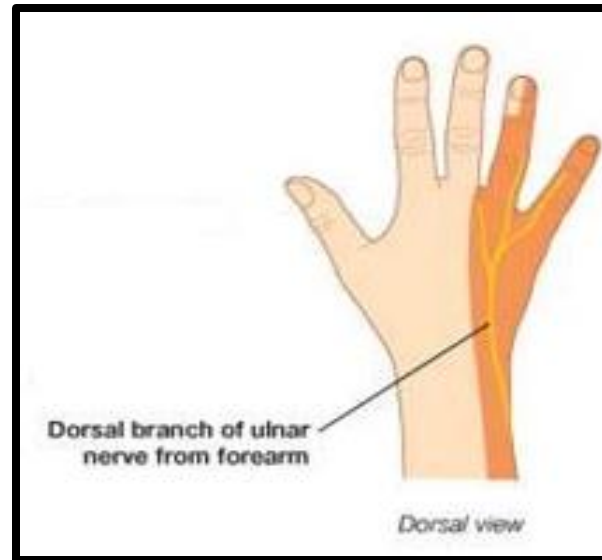
c. Cutaneous:

1. Dorsal (posterior) cutaneous:

Supplies the skin over the back of Medial side of the hand & Medial 1+1/2 fingers

2. Palmar cutaneous:

Supplies the skin over the Medial part of the palm.



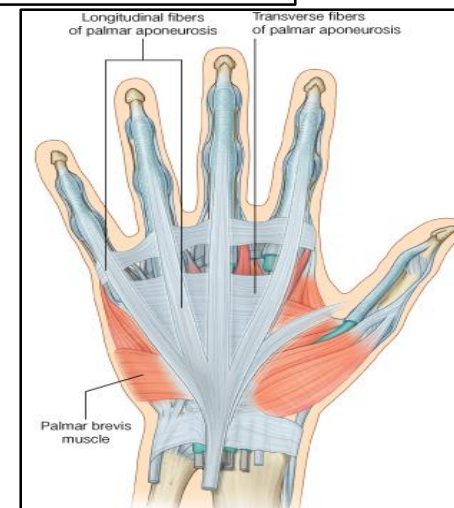
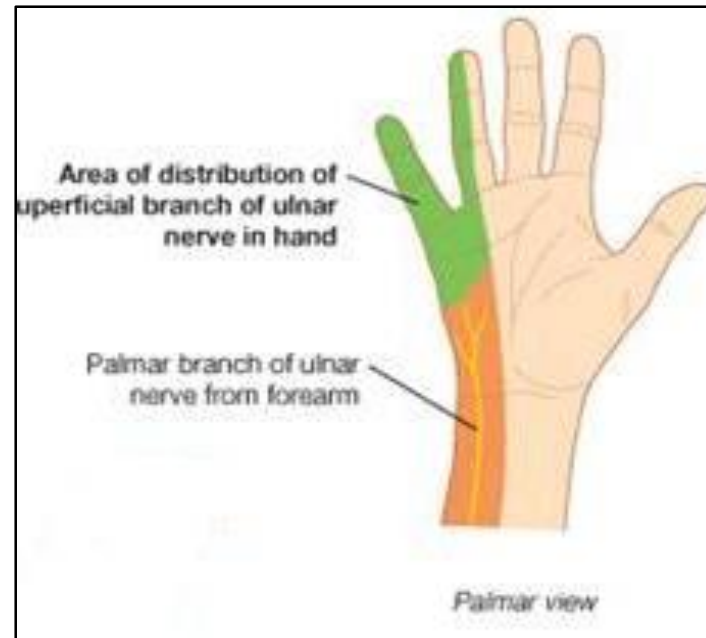
Branches of Superficial Terminal Branch

1. Muscular:

Palmaris Brevis.

2. Cutaneous:

***Skin over the
Palmar aspect of
the medial 1+ ½
fingers (including
nail beds).***

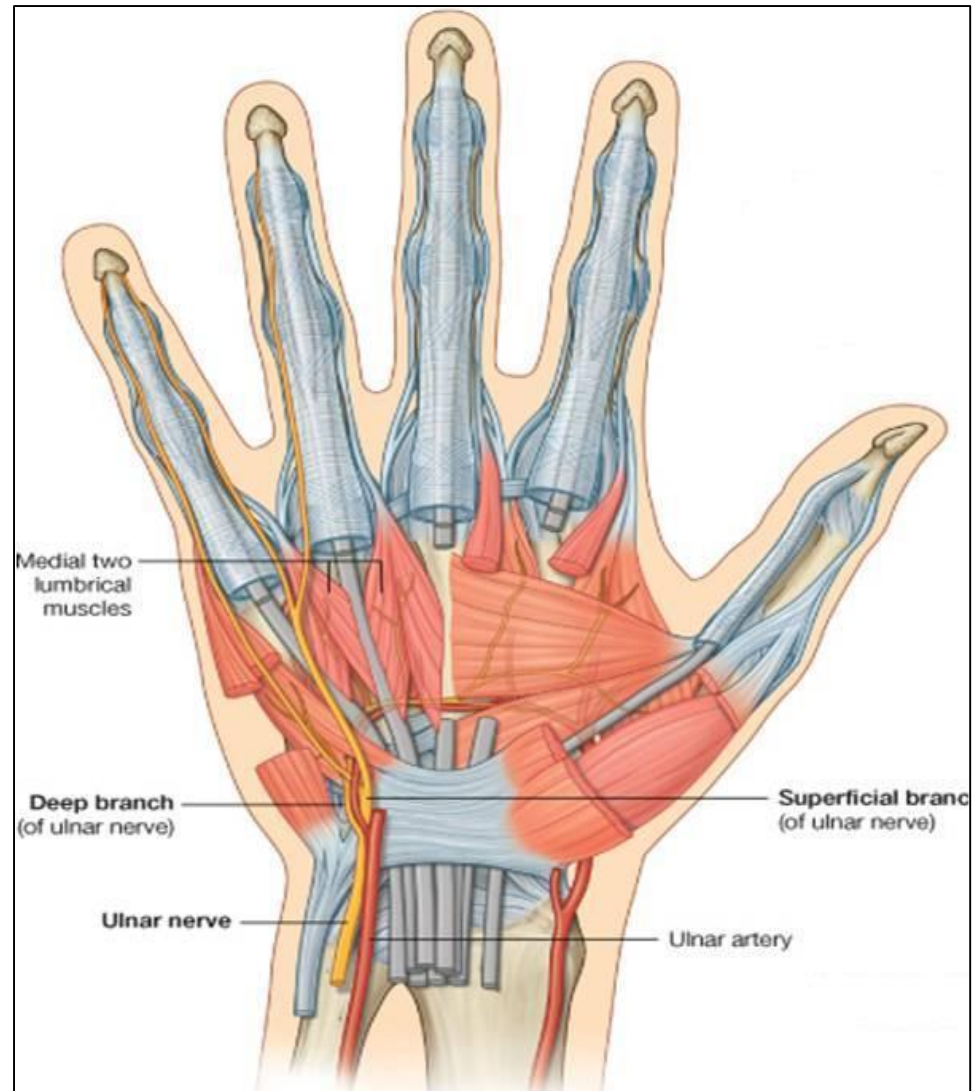


Branches of Deep Terminal Branch

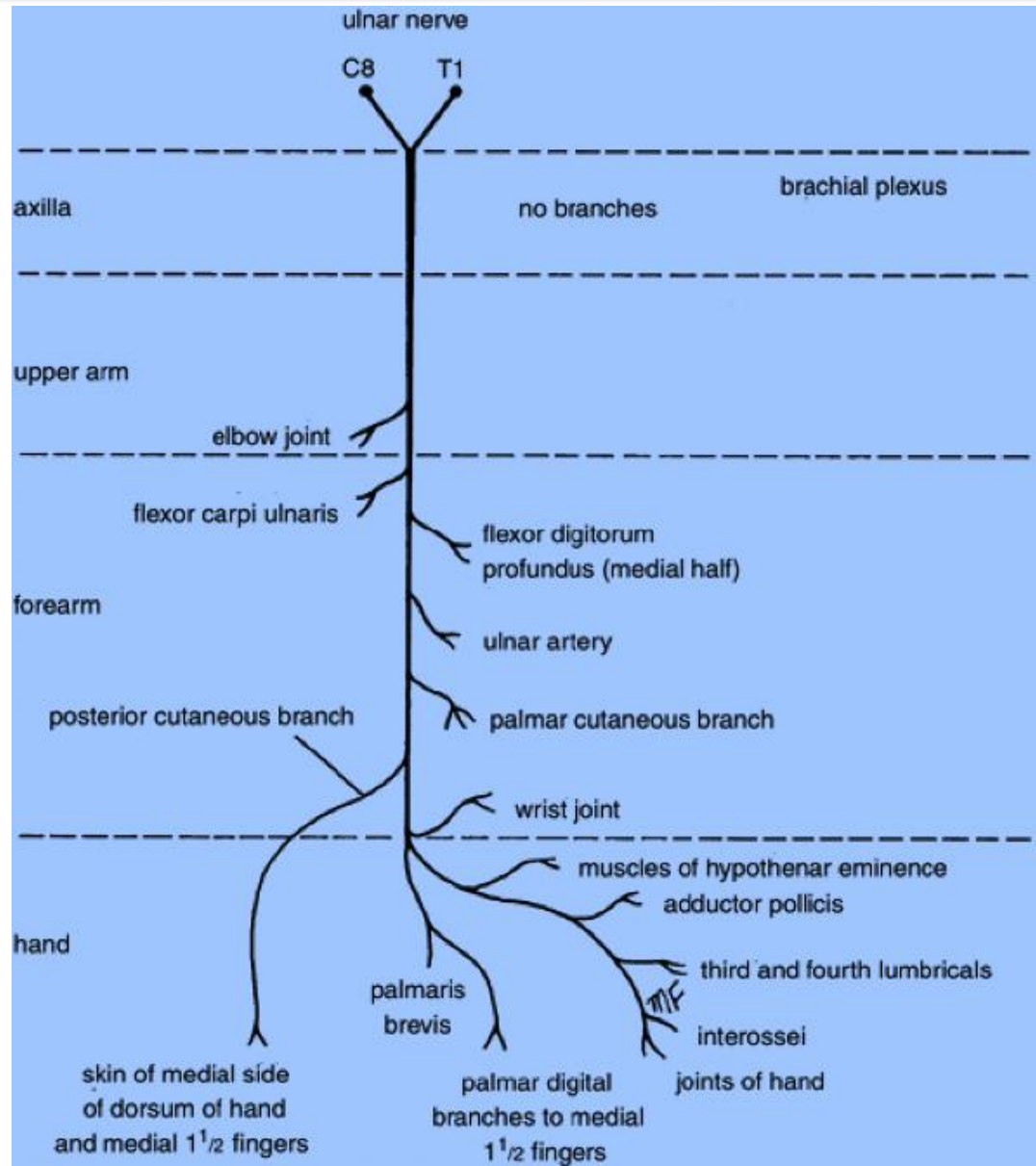
(A) Muscular branches :

- 1. Hypothenar Eminence.**
- 2. All Interossei (Palmar & Dorsal).**
- 3. 3rd & 4th Lumbricals.**
- 4. Adductor pollicis.**

(B) Articular: **Carpal joints.**



Summary of branches of Ulnar Nerve



Ulnar Nerve Injury

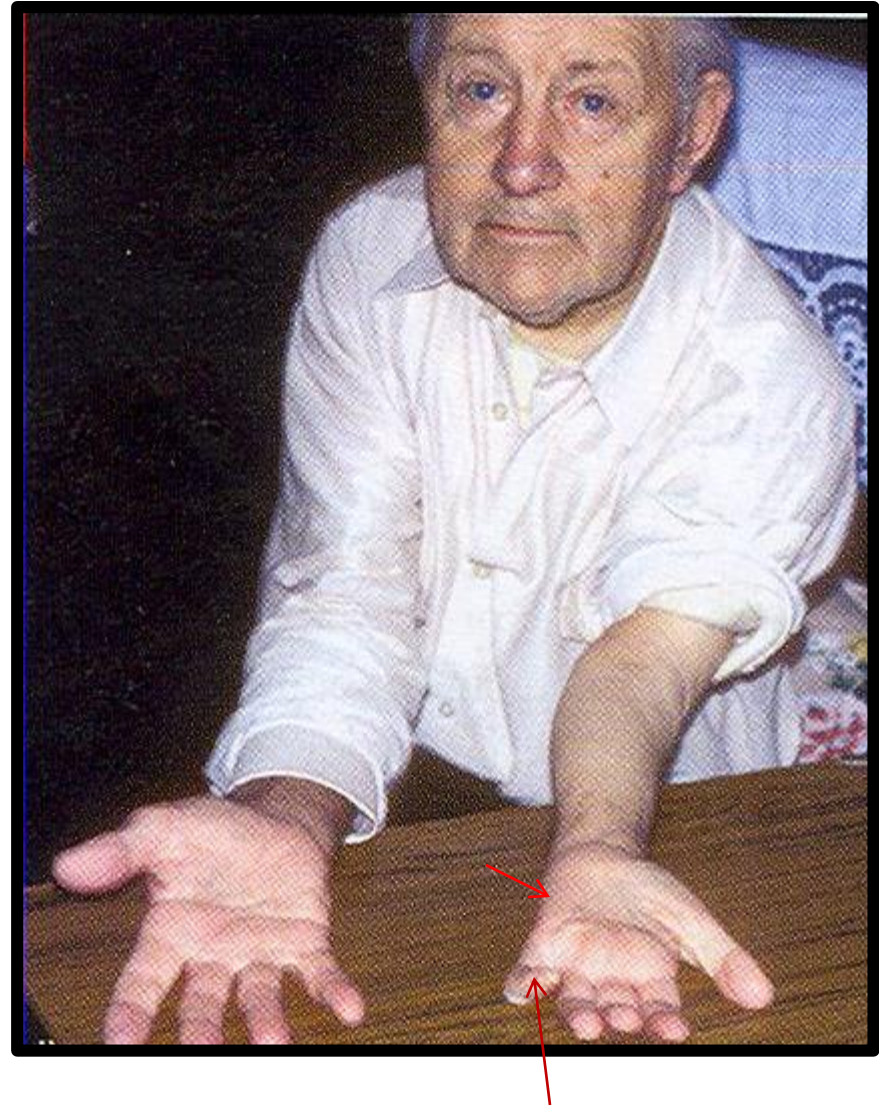
At the
Elbow:

*Atrophy of Ulnar side
of forearm.*

*Flexion of the wrist
with Abduction.*

Claw hand.

*Wasting of
Hypothenar Eminence.*

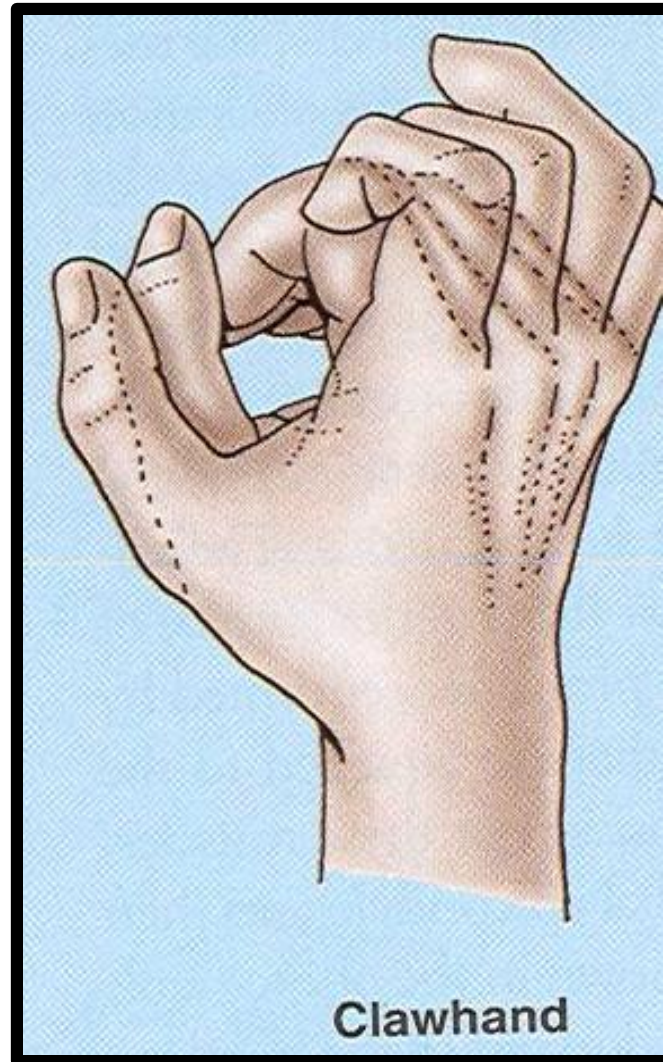


Ulnar Nerve Injury

At the wrist:

Claw Hand.

***Wasting of
Hypothenar
Eminence.***



THANK YOU