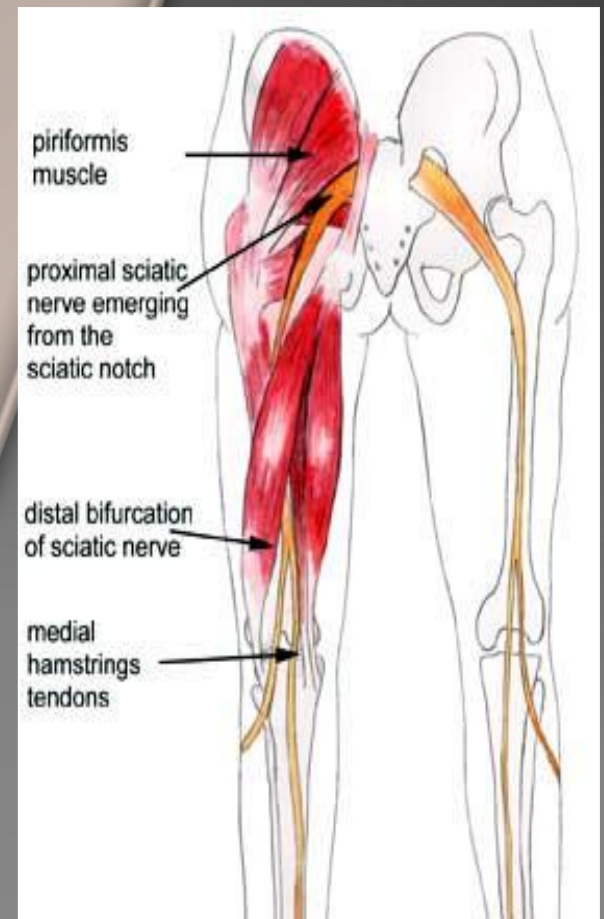


*SCIATIC NERVE

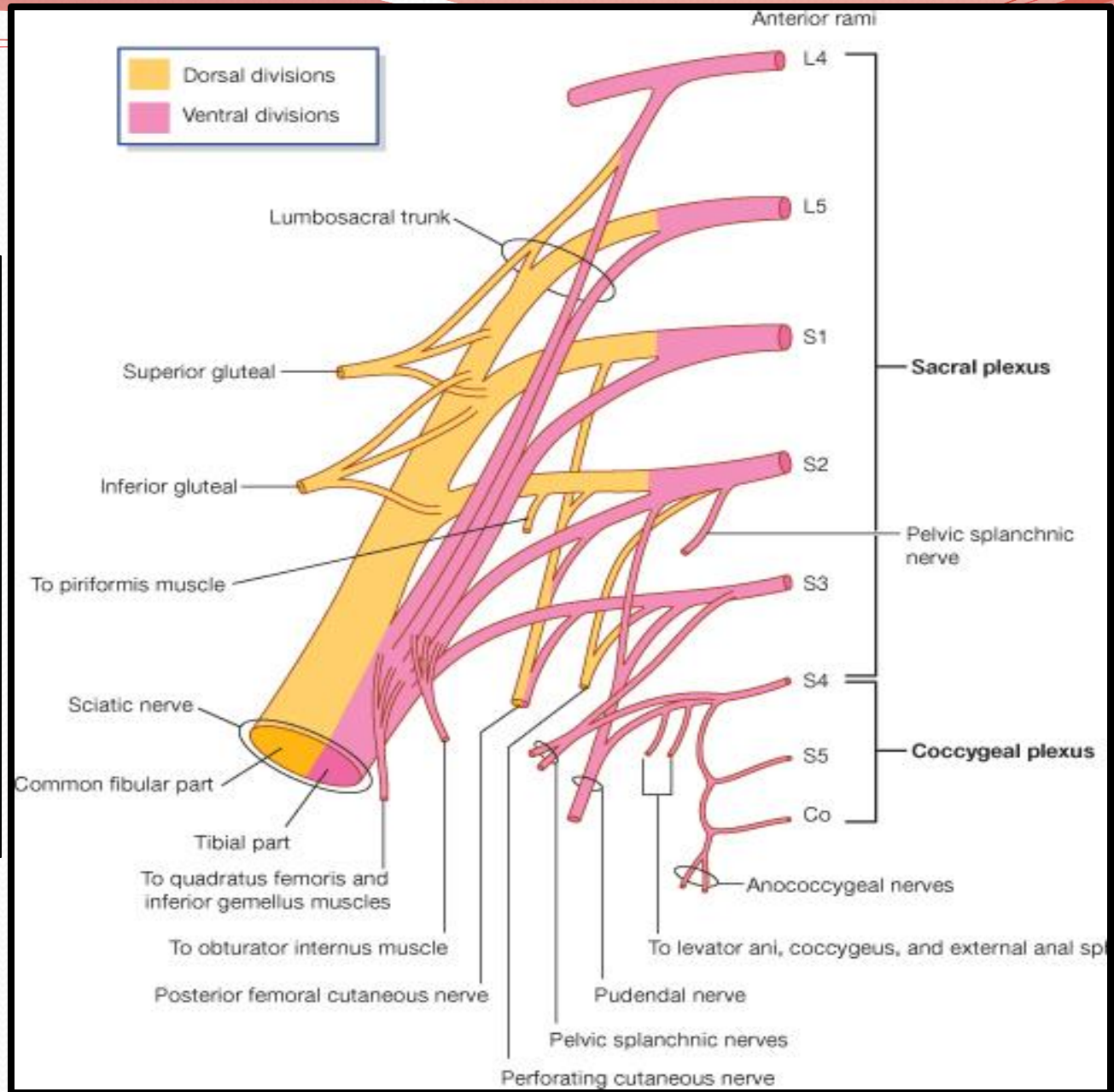


OBJECTIVES

- By the end of the lecture, students should be able to:
- Describe the anatomy (origin, course & distribution) of the sciatic nerve.
- List the branches of the sciatic nerve.
- Describe briefly the main motor and sensory manifestations in case of injury of the sciatic nerve or its main branches.

Origin

- From Sacral the Plexus,
- (L4,5, S1, 2,3).
- It is the largest branch of the plexus & the largest nerve of the body.



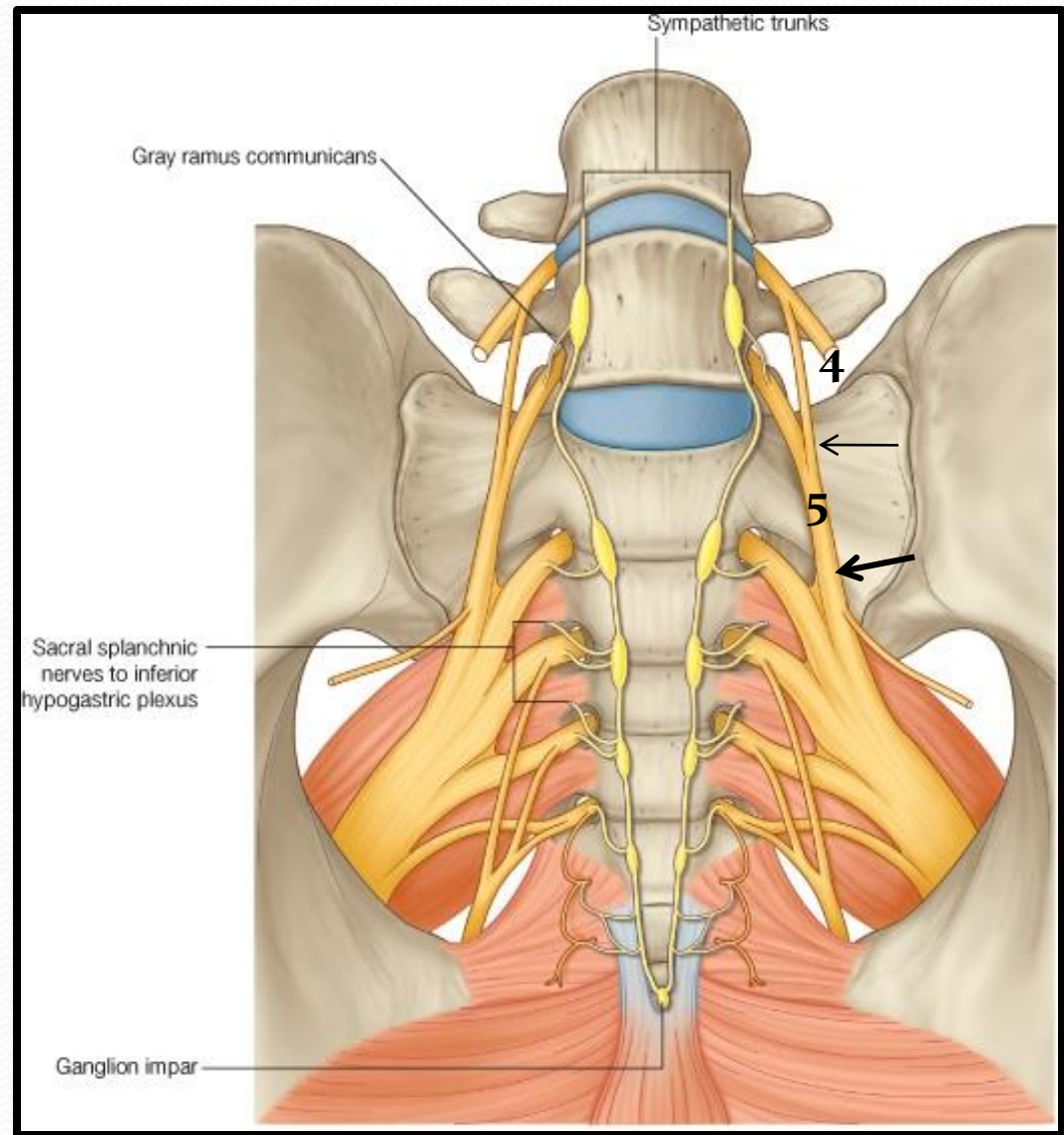
Sacral Plexus

❑ Formation:

- ❑ Ventral (anterior) rami of a part of L4 & whole L5 (lumbosacral trunk) + S1,2,3 and most of S4.

❑ Site:

- ❑ On the posterior wall of the pelvis,
- ❑ In front of Piriformis muscle.



Course & Distribution

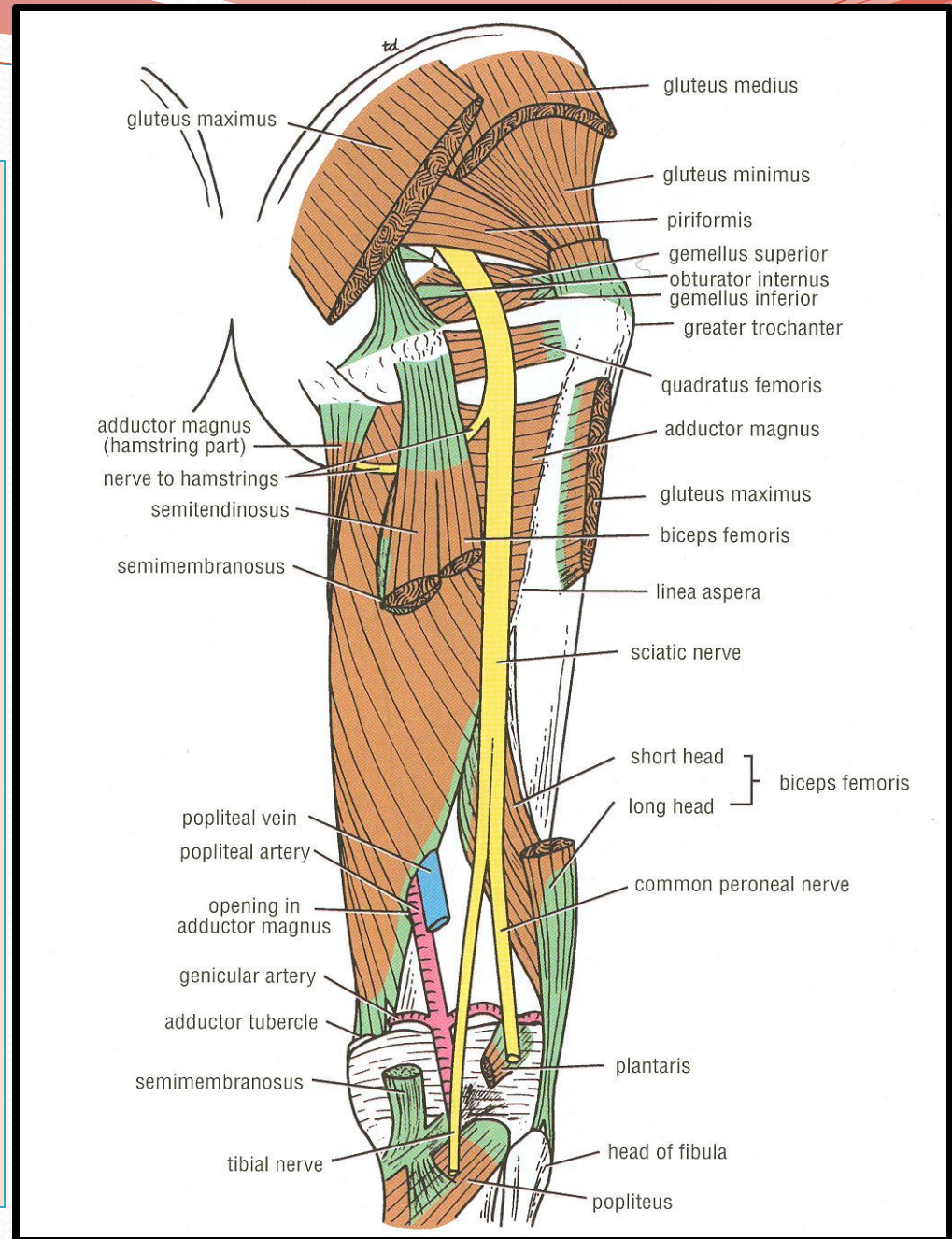
➤ It leaves the pelvis through greater sciatic foramen, below the piriformis & passes in the gluteal region (between ischial tuberosity & greater trochanter) then to posterior compartment of thigh.

➤ **Termination:**

In the middle of the back of the thigh **It** divides into 2 branches:

➤ **Tibial &**

➤ **Common Peroneal (Fibular).**

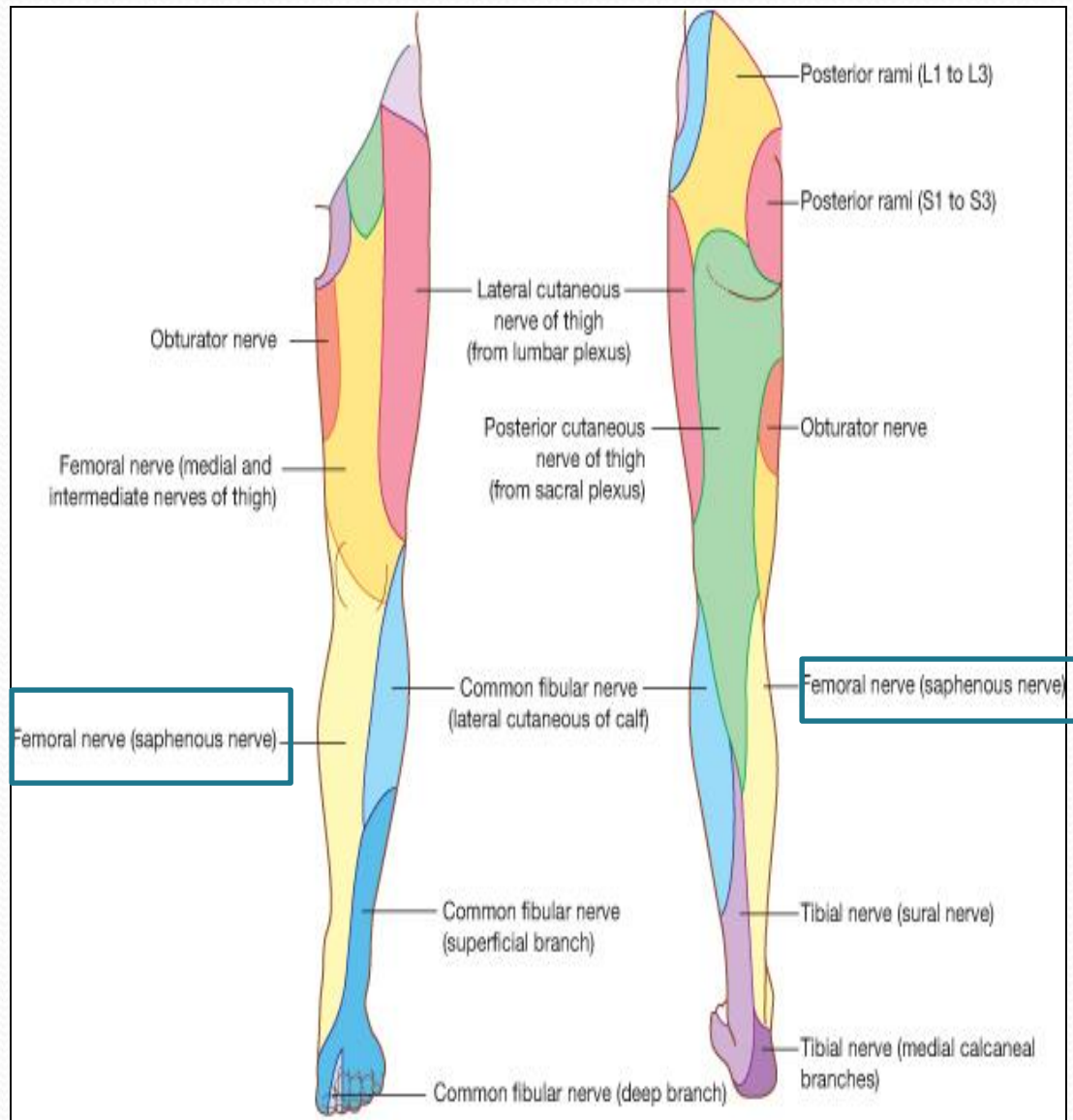


Branches of Sciatic Nerve

1. Cutaneous:

- To all leg & foot
EXCEPT:

Areas supplied by the **saphenous nerve** (branch of femoral nerve).



□ 2. Muscular:

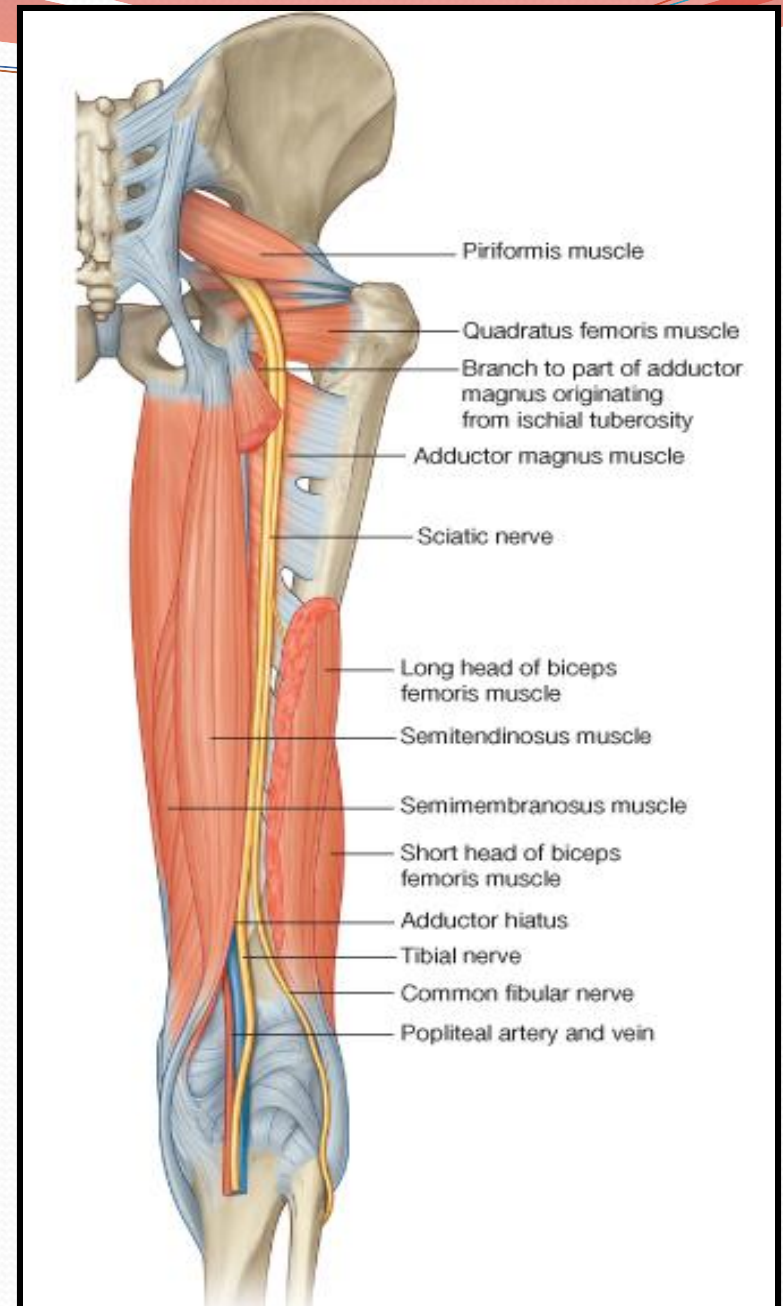
• To Hamstrings:

(flexors of knee & extensors of the hip).

(**through tibial part**) to:

1. *Hamstring part of Adductor Magnus.*
2. *Long head of Biceps Femoris.*
3. *Semitendinosus.*
4. *Semimembranosus.*

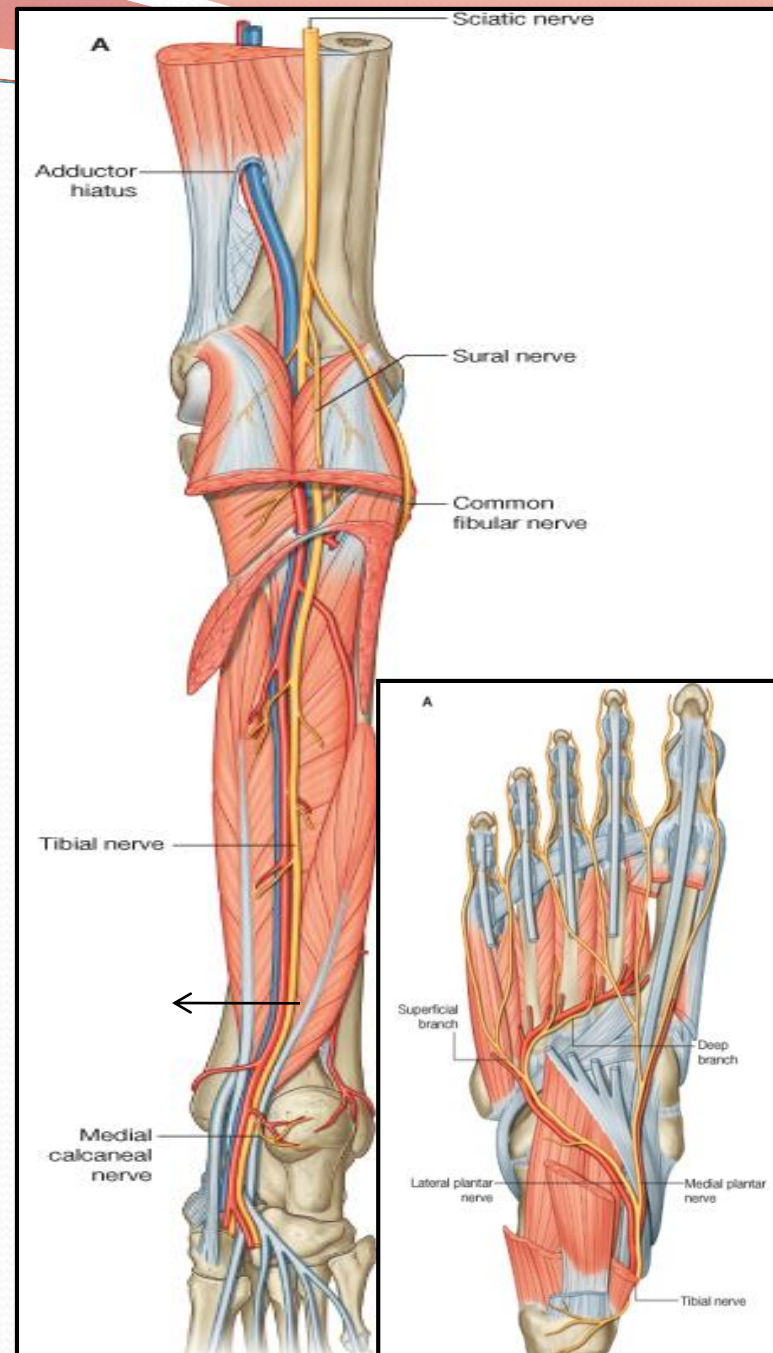
NB. The short head of biceps receives its branch from the lateral popliteal (common peroneal) nerve.



Tibial Nerve

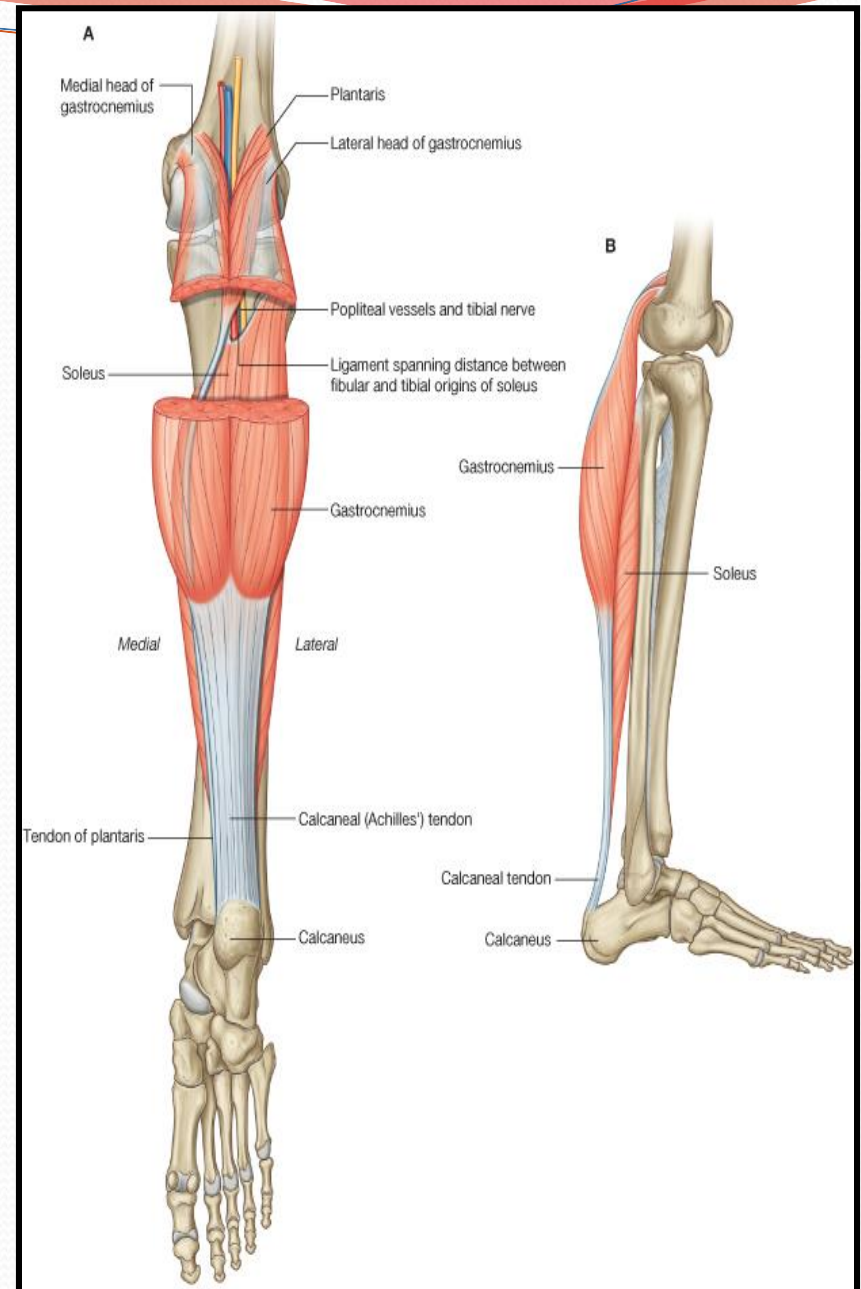
□ Course:

- Descends through popliteal fossa to posterior compartment of leg, **accompanied with posterior tibial vessels**.
- Passes deep to flexor retinaculum (through the tarsal tunnel, **behind medial malleolus**) to reach the sole of foot where it divides into 2 terminal branches (**Medial & Lateral planter nerves**).



Muscular Branches

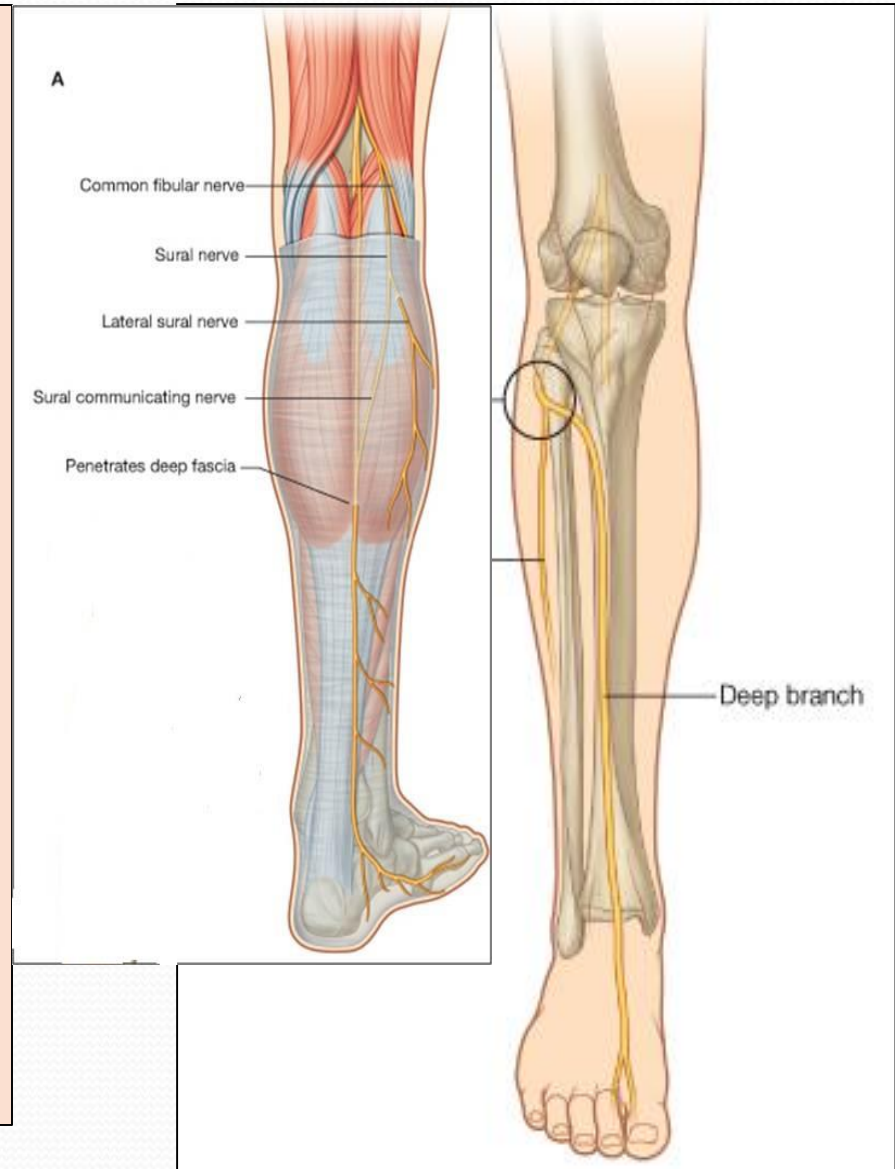
- Muscles of posterior compartment of leg:**
Planter flexors of ankle,
Flexors of toes
ONE Invertor of foot
(tibialis posterior).
- Intrinsic muscles of sole**



Common Peroneal (Fibular) Nerve

□ Course:

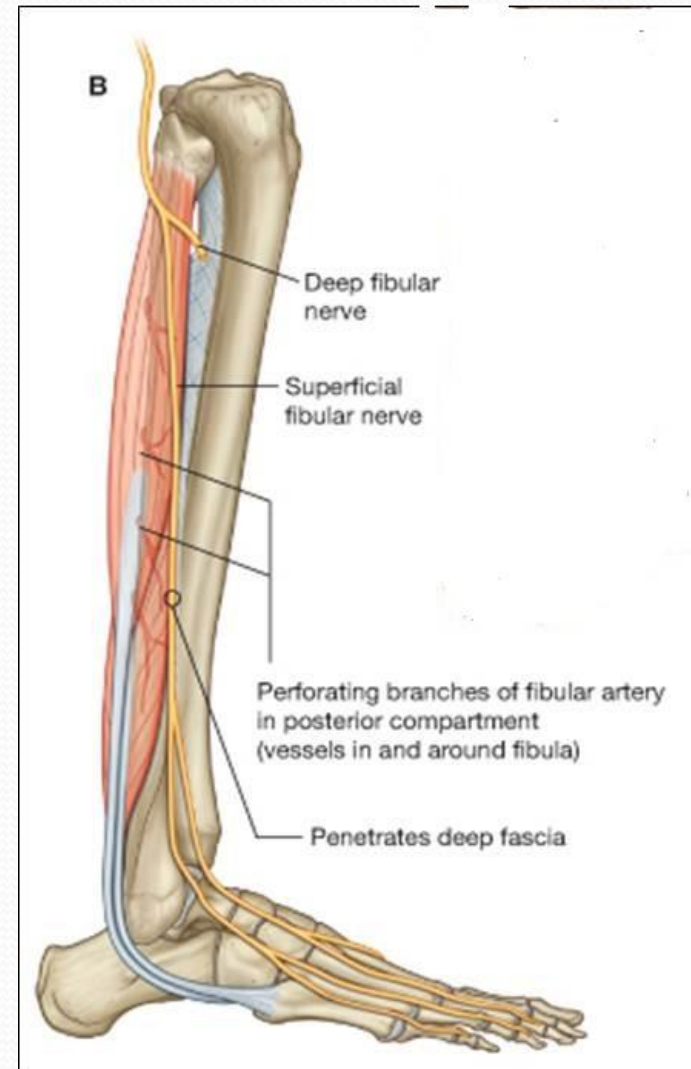
- Leaves popliteal fossa & turns around the **lateral aspect of neck of fibula**, (Dangerous Position).
- Then divides into:
 - *Superficial peroneal or (Musculocutaneous)* :
to supply the **Lateral compartment of the leg**.
 - *Deep peroneal or (Anterior Tibial)*:
to supply the **Anterior compartment of the leg**.



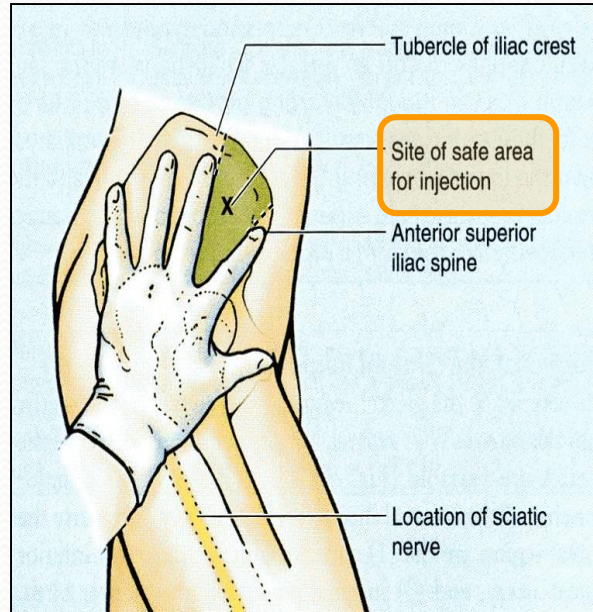
Muscular Branches

Muscles of anterior & lateral compartments of leg:

1. Dorsi flexors of ankle,
2. Extensors of toes,
3. Evertors of foot.



CAUSES OF SCIATIC NERVE INJURY



II-Posterior dislocation of the hip joint

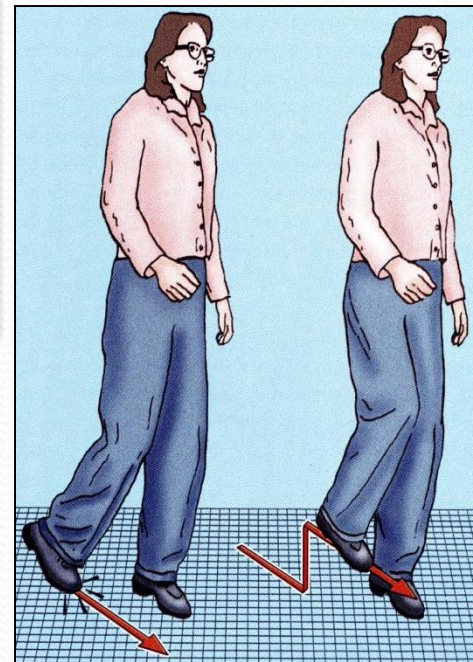
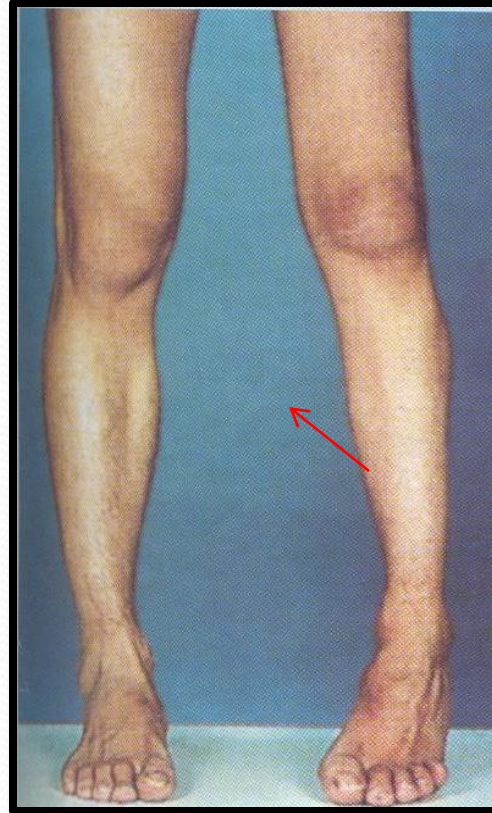


- The sciatic nerve is *most frequently injured* by...?
 - I- **Badly placed intramuscular injections in the gluteal region.**
 - To avoid this, injections should be done into the gluteus maximus or medius (into the **upper outer quadrant of the buttock**).
 - *Most nerve lesions are incomplete, and in 90% of injuries, the common peroneal (part of the nerve) is the most affected.* Why?
 - The common peroneal nerve fibers lie **superficial** in the sciatic nerve.

EFFECTS OF SCIATIC NERVE INJURY

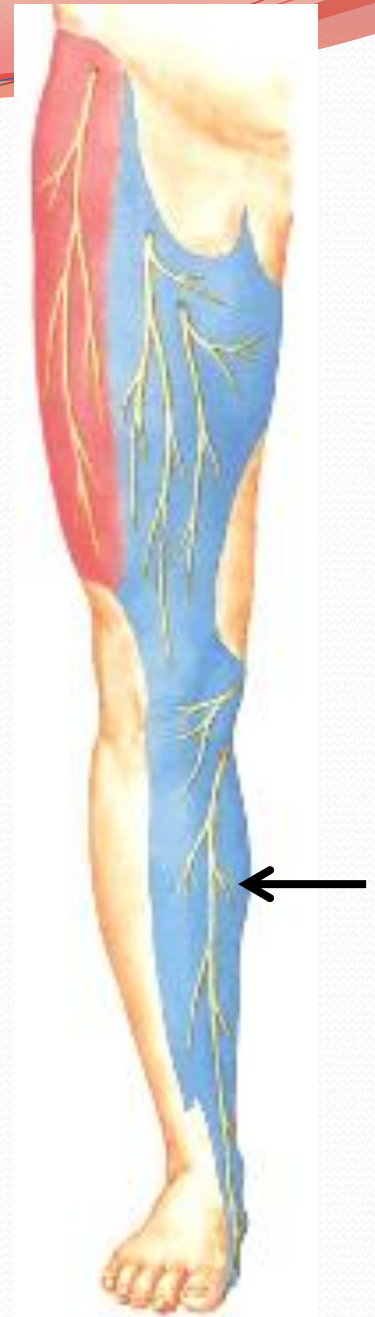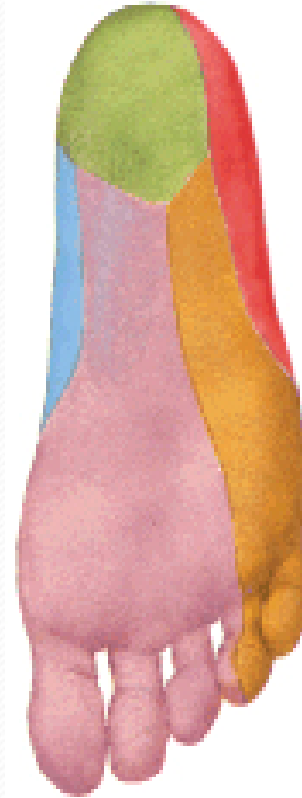❑ MOTOR EFFECT:

- Marked wasting of the muscles below the knee.
- **Weak flexion of the knee** (sartorius & gracilis are intact).
- **Weak extension of hip** (gluteus maximus is intact).
- All the muscles below the knee are paralyzed, and the weight of the foot causes it to assume the **plantar-flexed position**, or **Foot Drop**.
- (**Stamping gait**).



SENSORY EFFECT

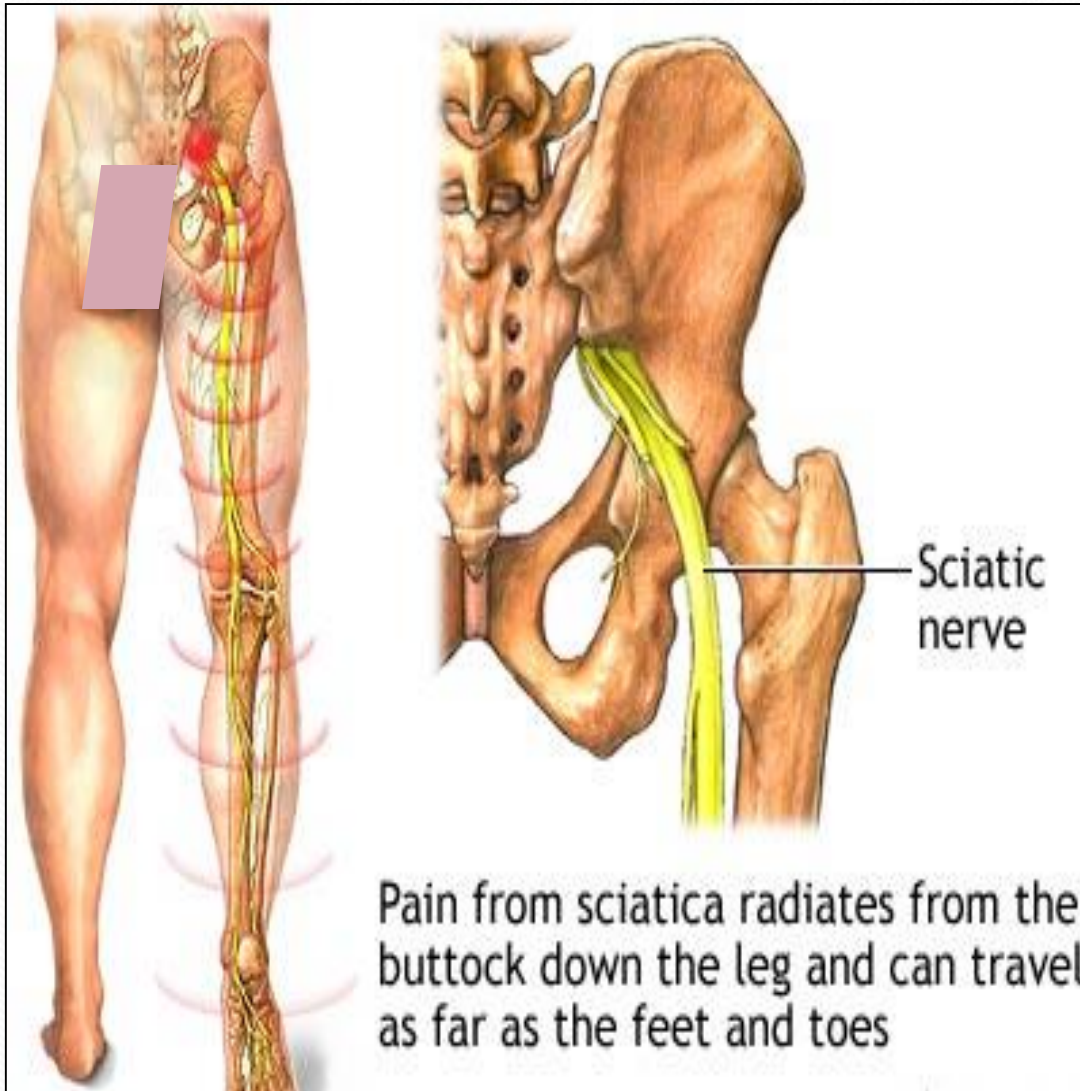
- Sensation is lost *below the knee*, **except for a narrow area down the medial side of the lower part of the leg (blue)** and along the medial border of the foot as far as the ball of the big toe, which is supplied by the **saphenous nerve** (femoral nerve).



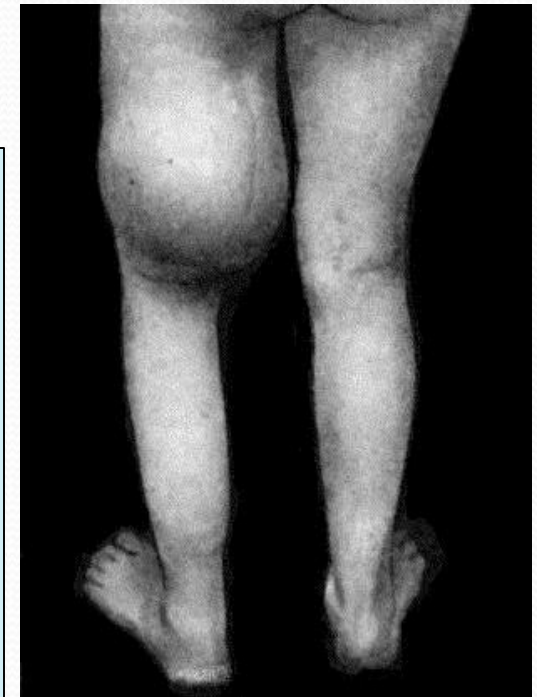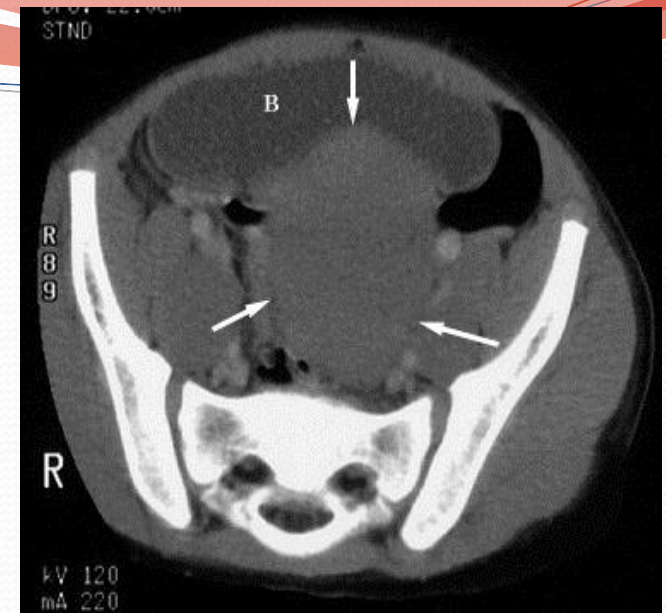
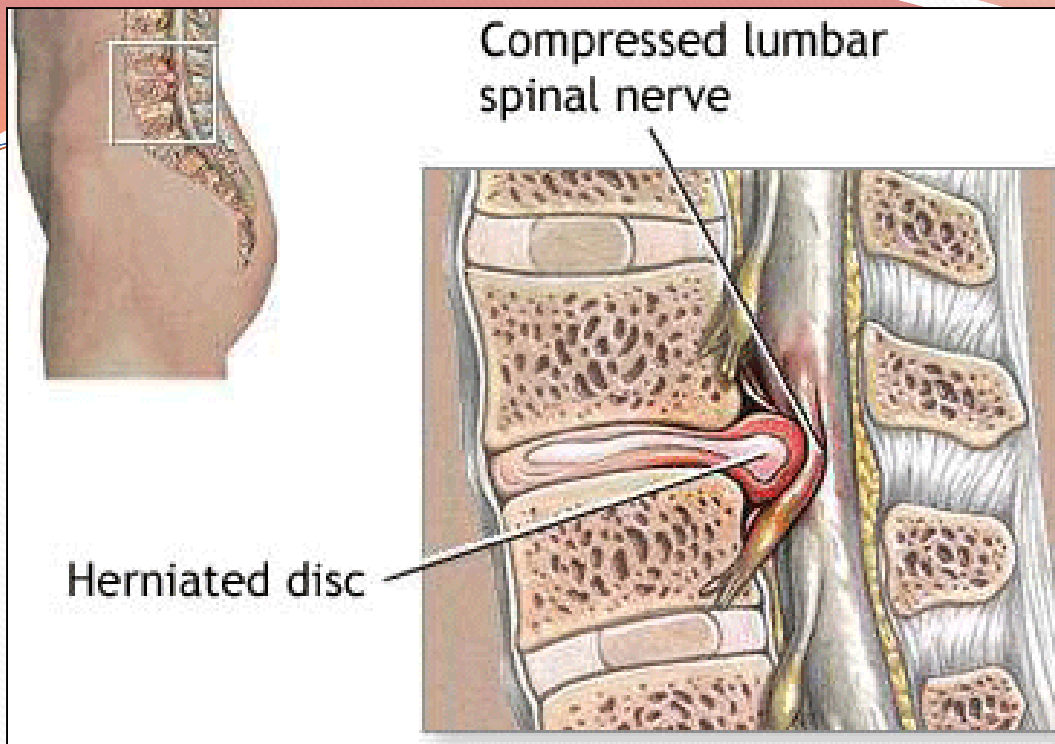
EFFECT OF SCIATIC NERVE INJURY

MOTOR EFFECT	Paralysis	Movements affected
	<u>Hamstrings</u>	Flexion of knee & Extension of hip
	<u>All muscles of Leg & Foot</u>	All movements of the <u>leg & Foot</u>
SENSORY EFFECT	Loss of sensation of the areas supplied by sciatic nerve (below knee).	EXCEPT area supplied by the (Saphenous nerve).

SCIATICA



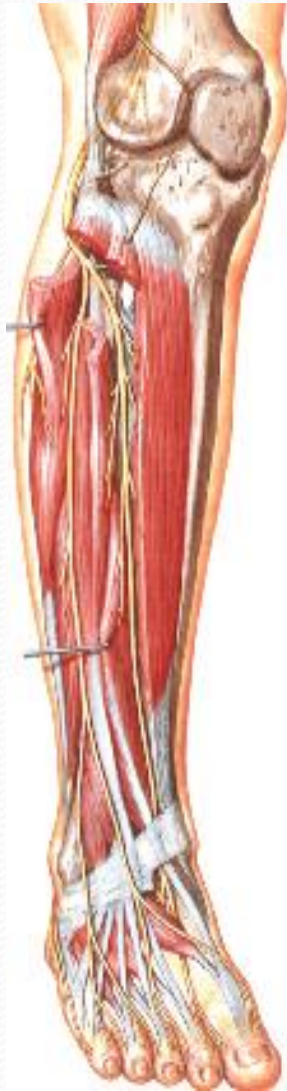- Sciatica describes the condition in which patients have *pain along the sensory distribution of the sciatic nerve.*
- **Thus the pain is experienced in the posterior aspect of the thigh, the posterior and lateral sides of the leg, and the lateral part of the foot.**



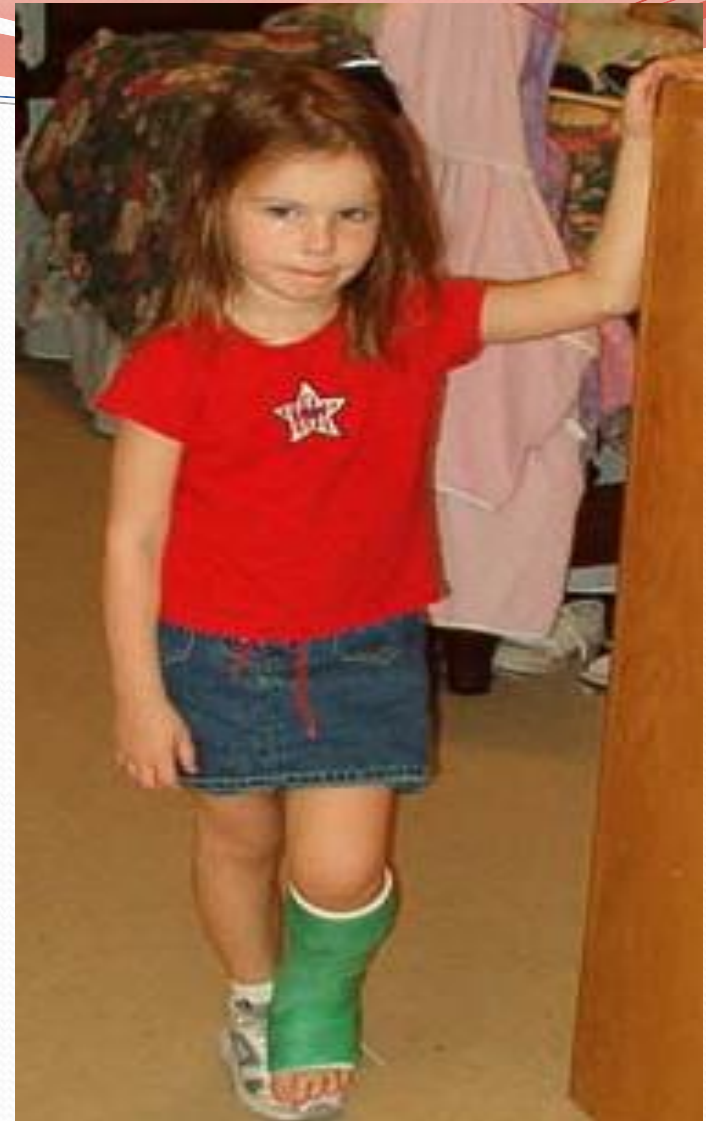Causes of Sciatica :

- Prolapse of an intervertebral disc, with pressure on one or more roots of the lower lumbar and sacral spinal nerves,
- Pressure on the sacral plexus or sciatic nerve by an intrapelvic tumor,
- Inflammation of the sciatic nerve or its terminal branches.

Common Peroneal Nerve Injury

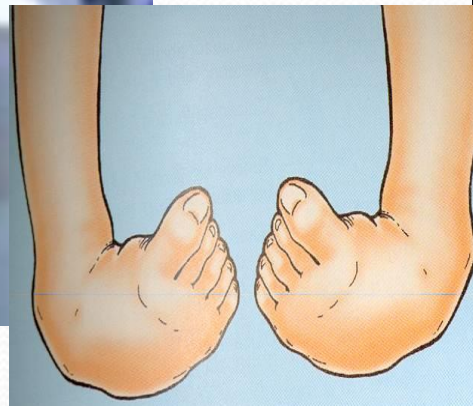
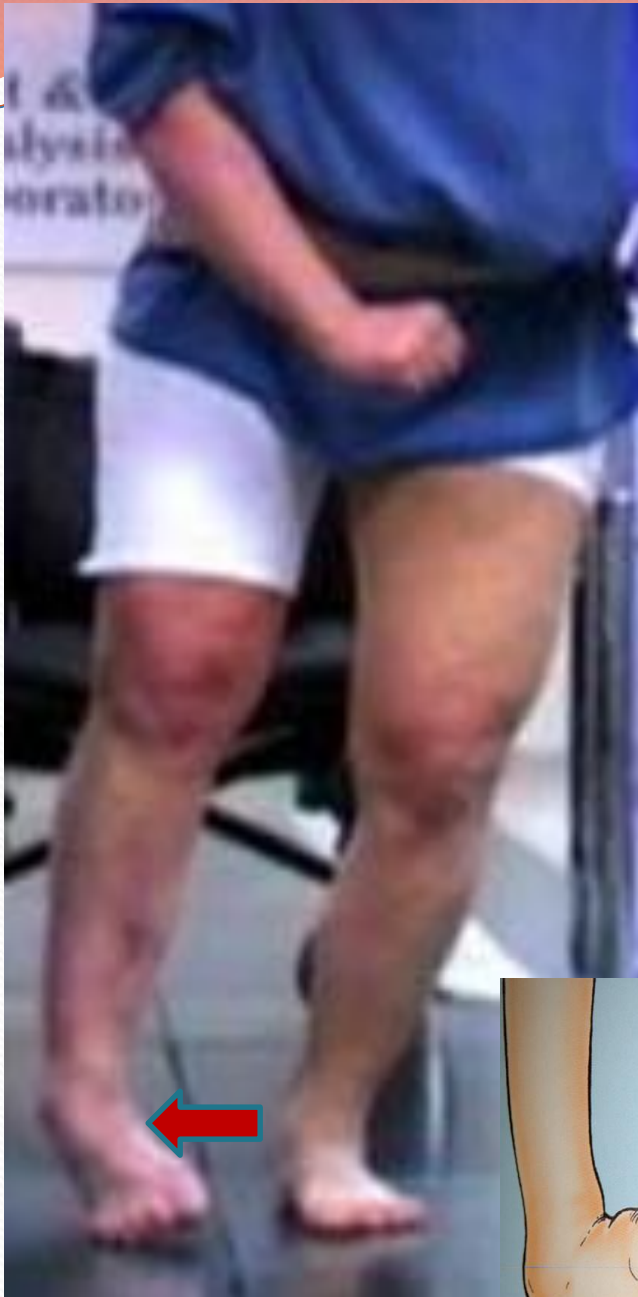

The **common peroneal nerve** is in an *exposed position* as it leaves the popliteal fossa it winds around neck of the fibula to enter peroneus longus muscle, (**Dangerous Position**).



The common peroneal nerve is commonly injured In **Fractures** of the neck of the fibula and By **pressure** from casts or splints.

Manifestations of Common Peroneal Nerve Injury



Motor:

- *The muscles of the anterior and lateral compartments of the leg are paralyzed,*
- As a result, the opposing muscles, the plantar flexors of the ankle joint and the invertors of the subtalar joints, *cause the foot to be **Plantar Flexed (Foot Drop) and Inverted***, an attitude referred to as **Talipes Equinovarus**.

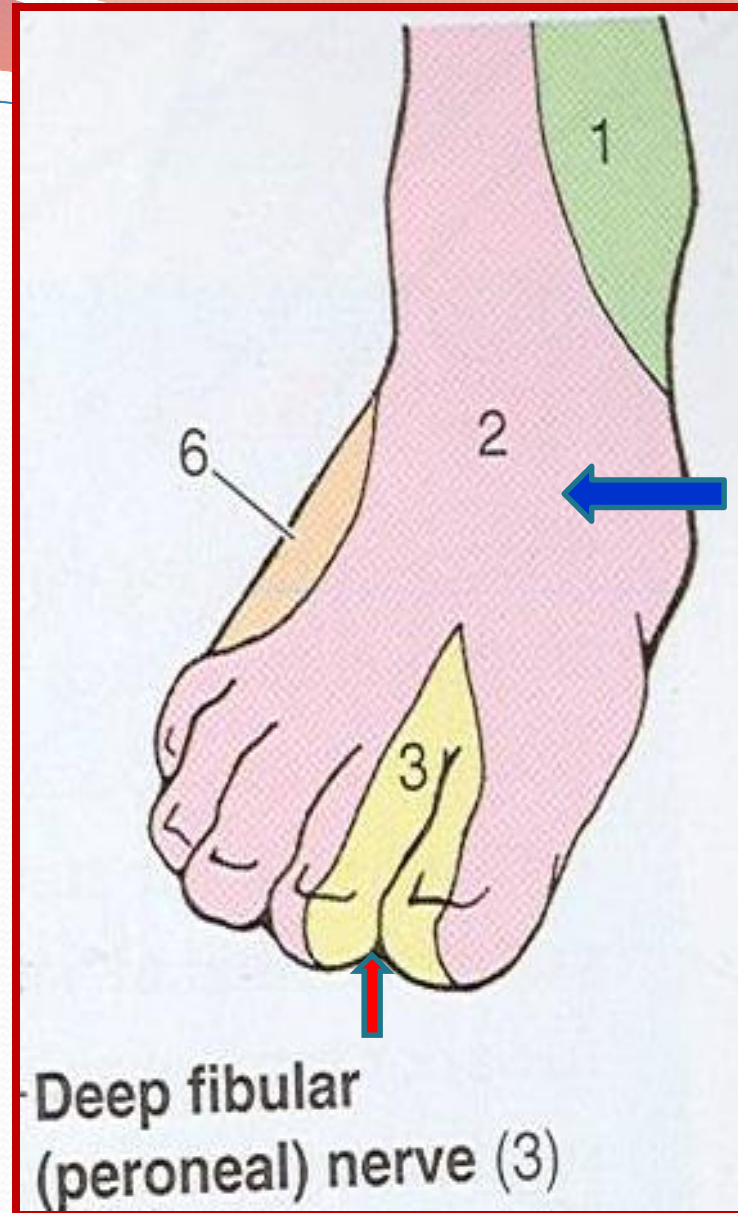
Sensory

Sensation is lost between the first and second toes.

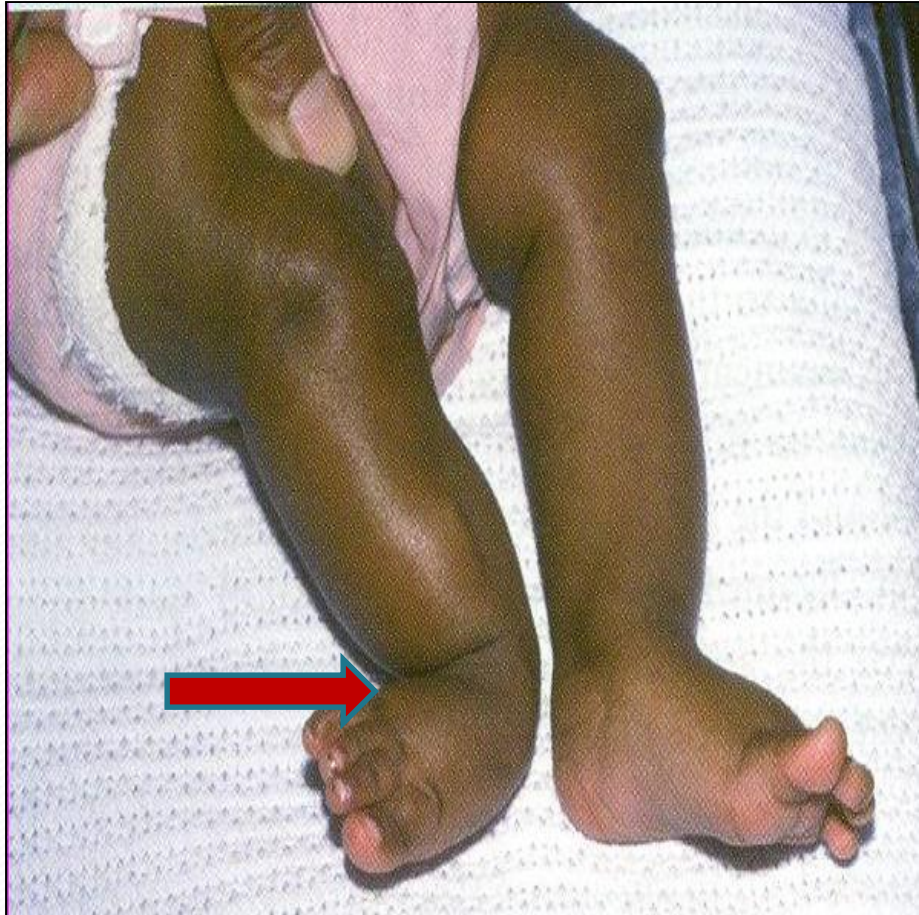Dorsum of the foot and toes.

Medial side of the big toe.

Lateral side of the leg.



Tibial Nerve Injury



- Because of its deep and protected position, the tibial nerve is *rarely injured*.
- **Complete** division results in the following clinical features:
- **Motor:**
- *All the muscles in the back of the leg and the sole of the foot are paralyzed.*
- The opposing muscles *Dorsiflex* the foot at the ankle joint *and Evert the foot* at the subtalar joint, an attitude referred to as **Taleps Calcaneovalgus.**

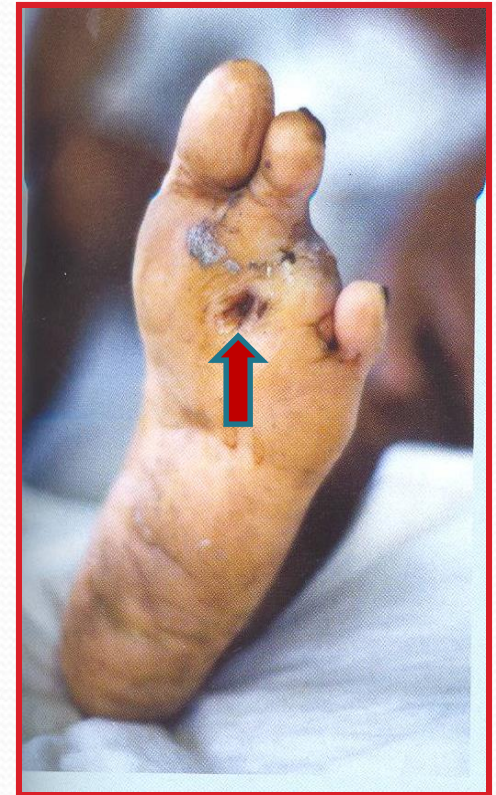
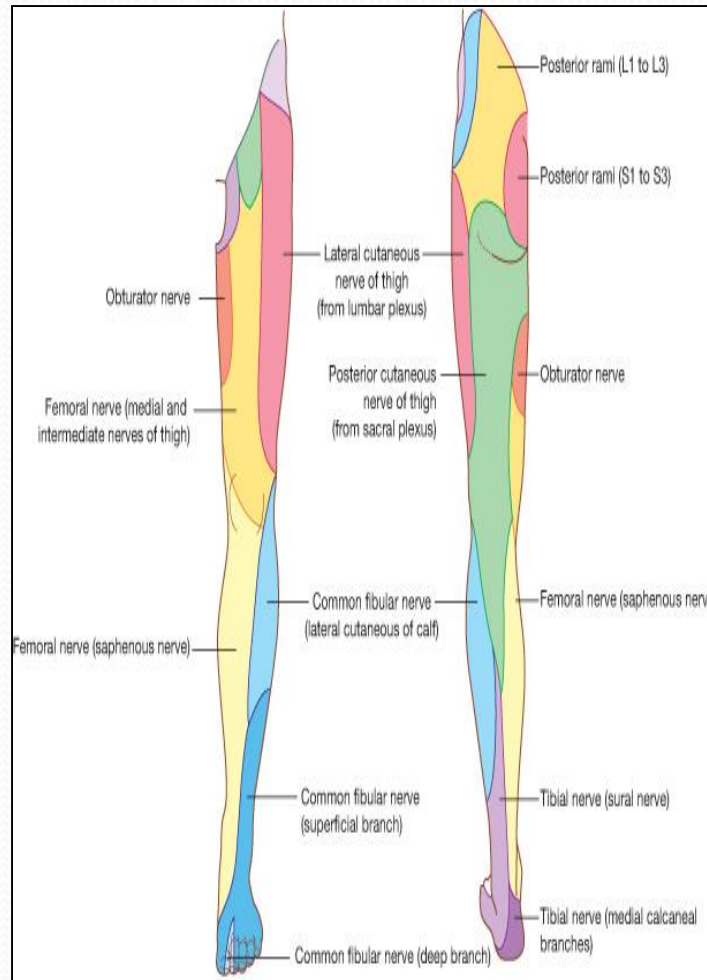
Sensory :

Sensation is lost on the Lateral side of the leg and foot &

Trophic ulcers

in the sole.

(also seen in case of **Sciatic nerve injury**)





THANK YOU