

PELVIS & SACRUM

Dr. Jamila El-Medany

Dr. Essam Eldin Salama

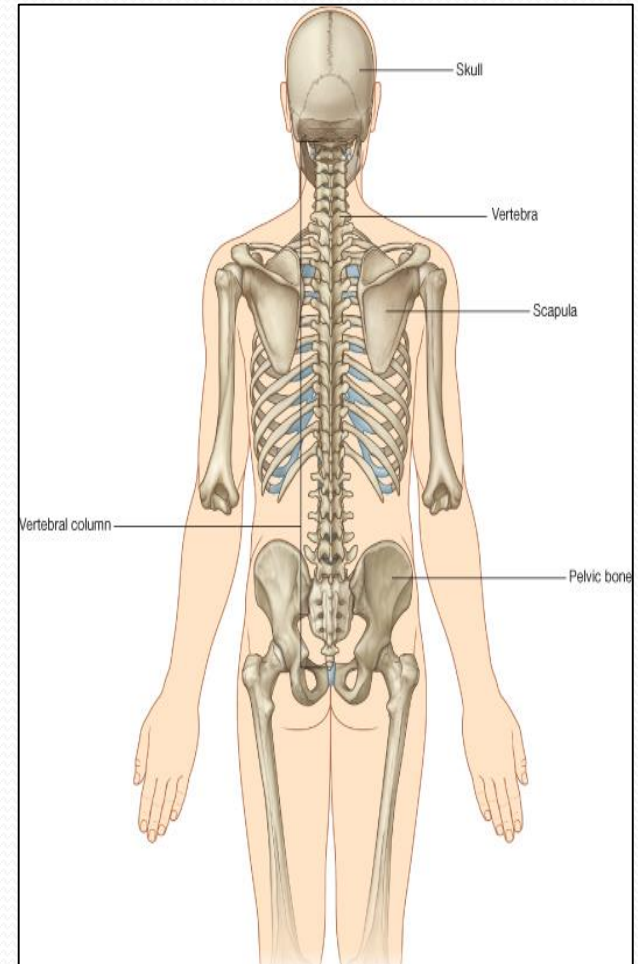
Learning Objectives

❖ *At the end of the lecture, the students should be able to :*

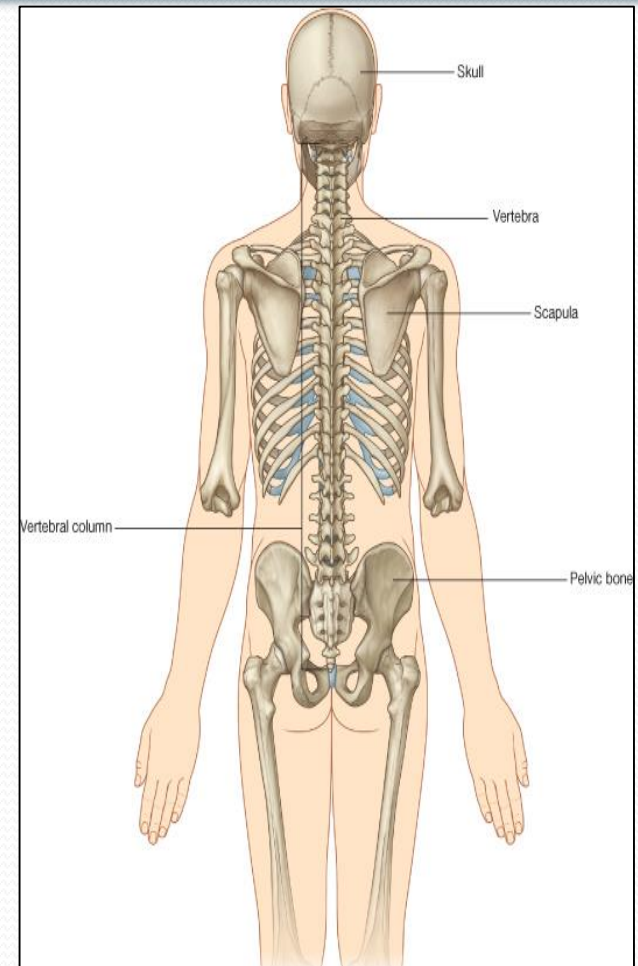
- Describe the bony structures of the pelvis.
- Describe in detail the hip bone, the sacrum, and the coccyx.
- Describe the boundaries of the pelvic inlet and outlet.
- Identify the articulations of the bony pelvis.
- List the major differences between the male and female pelvis.
- List the different types of female pelvis.

Bony Pelvis

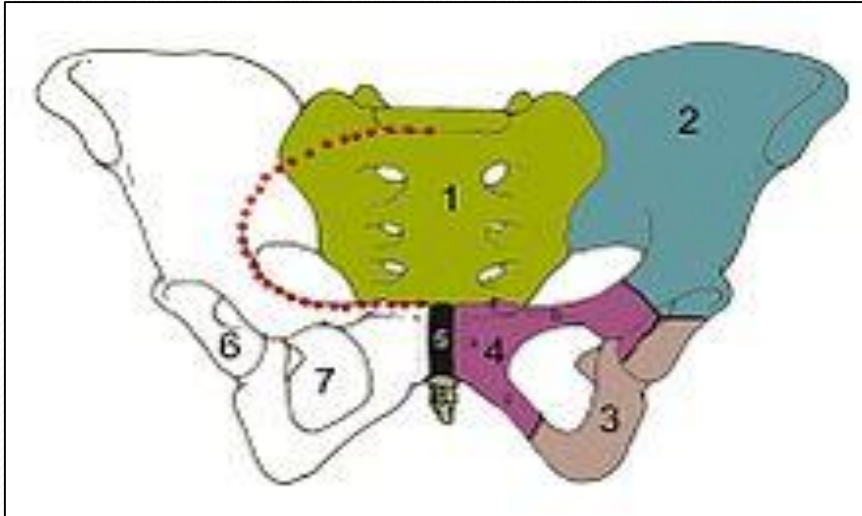
- The skeleton of the pelvis is a basin-shaped ring of bones with holes in its walls that connect the vertebral column to both femora.
- Its **Primary Functions** are;
- **Bears** the weight of the upper body when sitting and standing;
- **Transfers** that weight from the axial skeleton to the lower appendicular skeleton when standing and walking;
- **Provides** attachments and withstands the forces of the powerful muscles of locomotion and posture.



- Its **Secondary Functions**; are:
- **Contains and Protects** the pelvic and abdominopelvic viscera (inferior parts of the urinary tracts, internal reproductive organs);
- **Provides** attachment for external reproductive organs and associated muscles and membranes.



Pelvic Girdle

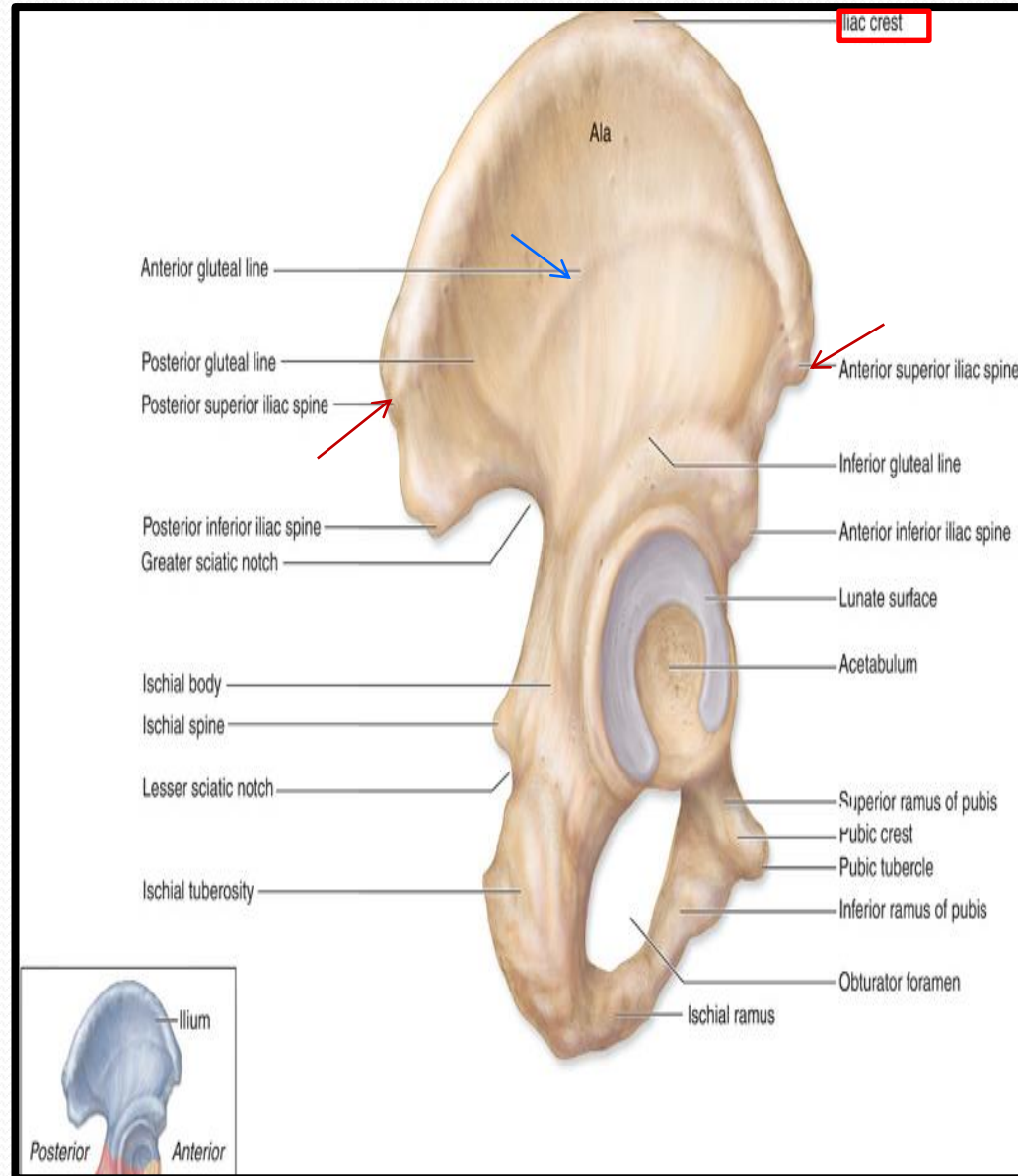


1. Sacrum
 2. Ilium
 3. Ischium
 4. Pubic bone
 5. Pubic symphysis
 6. Acetabulum
 7. Obturator foramen
 8. Coccyx
- Red line: Terminal line/pelvic brim

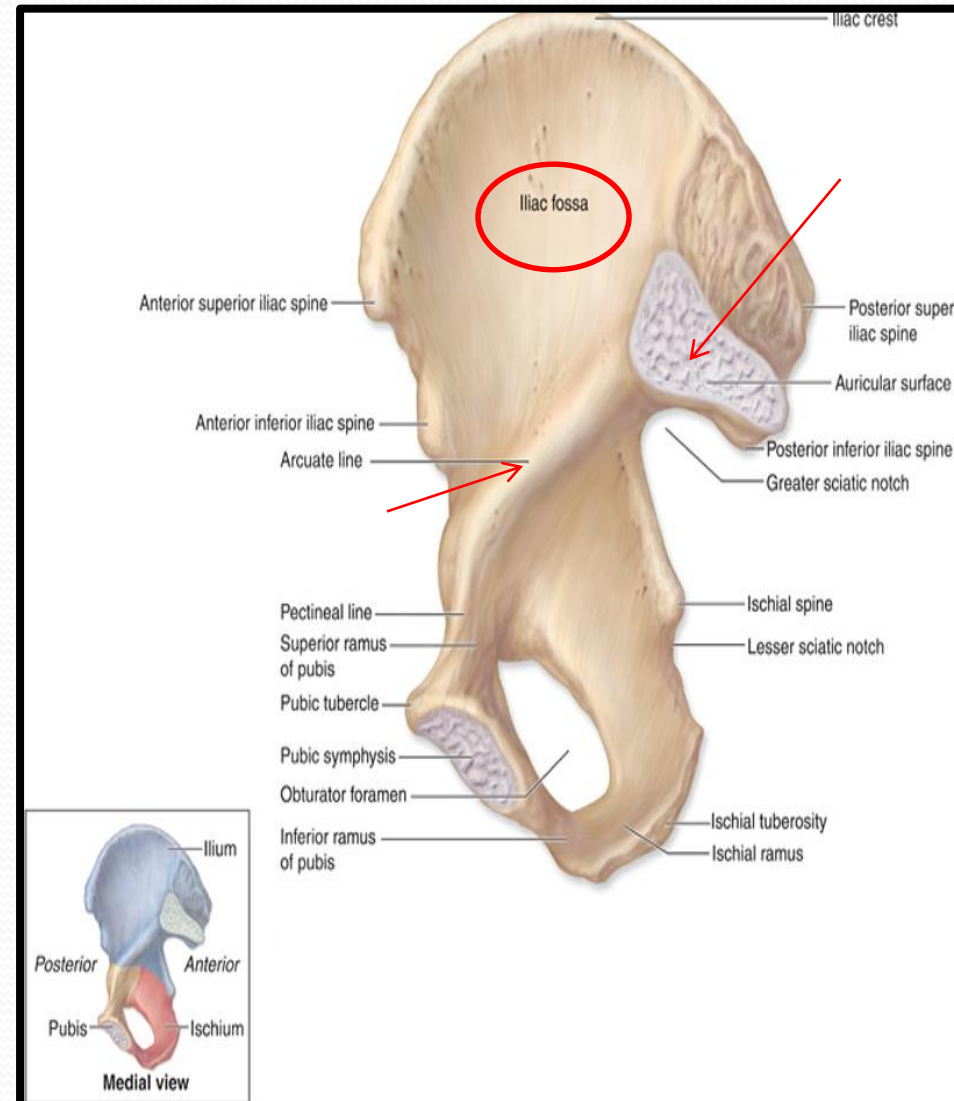
- ❑ Compared to the shoulder girdle, the pelvic girdle is stronger and heavier .
- ❑ It is composed of Two Hip (Coxal) Bones
- ❑ Each one is a large irregular bone.
- ❑ Formed of three (elements) bones:
 - Ilium
 - Ischium
 - Pubis.
- ❑ They are joined at a deep socket (**Acetabulum**)
 - During childhood, these sections are separate bones, joined by Y shaped cartilage.
 - During puberty, they fuse together to form a single bone.

Ilium

- It is the **Upper Flattened Part** of the hip bone.
- It Possesses:
- **Iliac Crest:** An important anatomical landmark below the waist.
- It runs between the Anterior and Posterior **Superior Iliac Spines**.
- Below are the corresponding Anterior and Posterior **Inferior Iliac Spines**.
- The ilium has two surfaces:
- The **Outer Surface:** rough and has three **Gluteal Lines**.

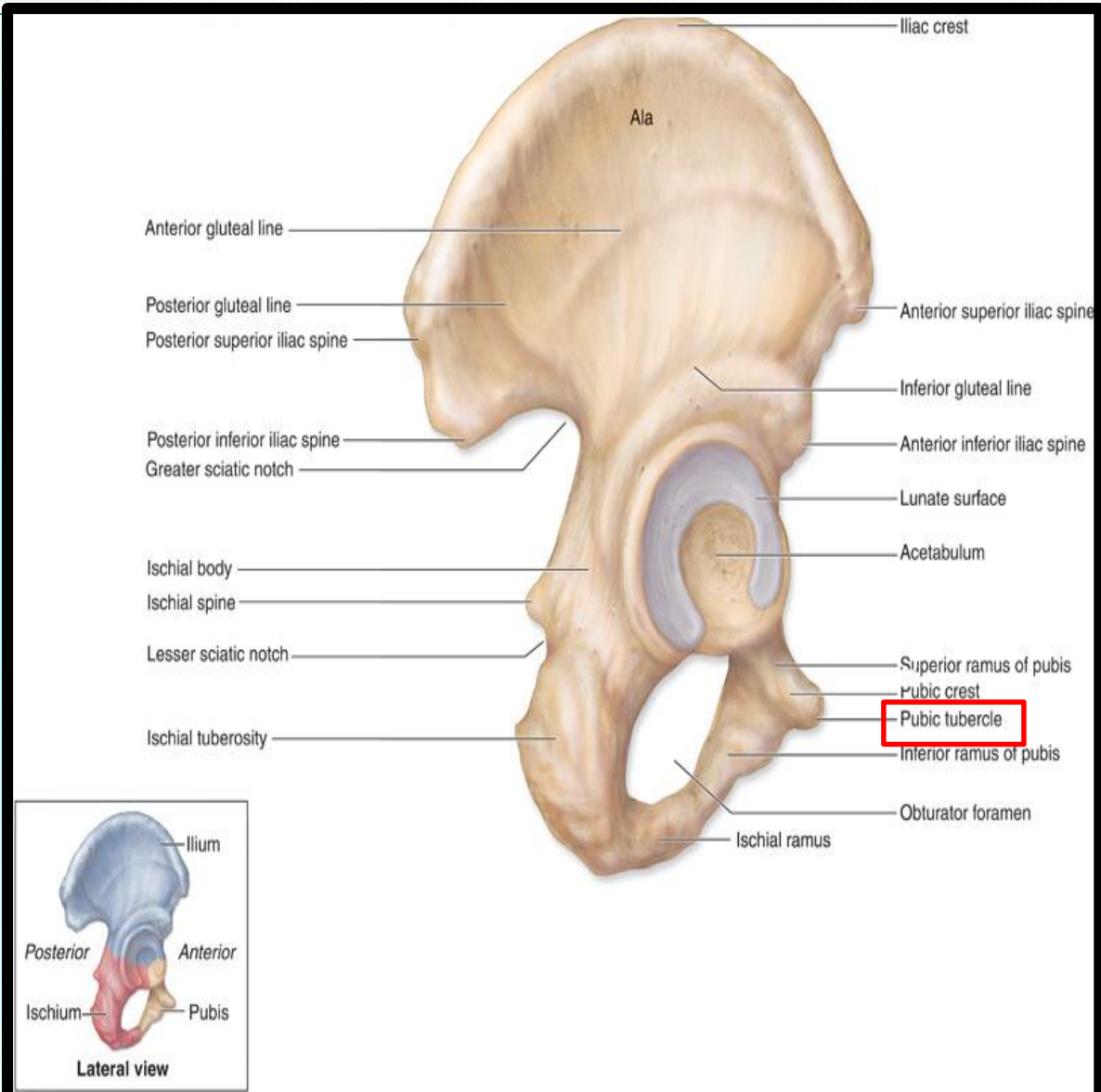


- **The Inner surface has:**
- **Iliac Fossa** (forms false pelvis)
- **Auricular surface** (for articulation with the sacrum).
- **Iliopectinal (Arcuate) Line:**
- Runs downwards & forwards.
- It separates between the False & the True pelvis .



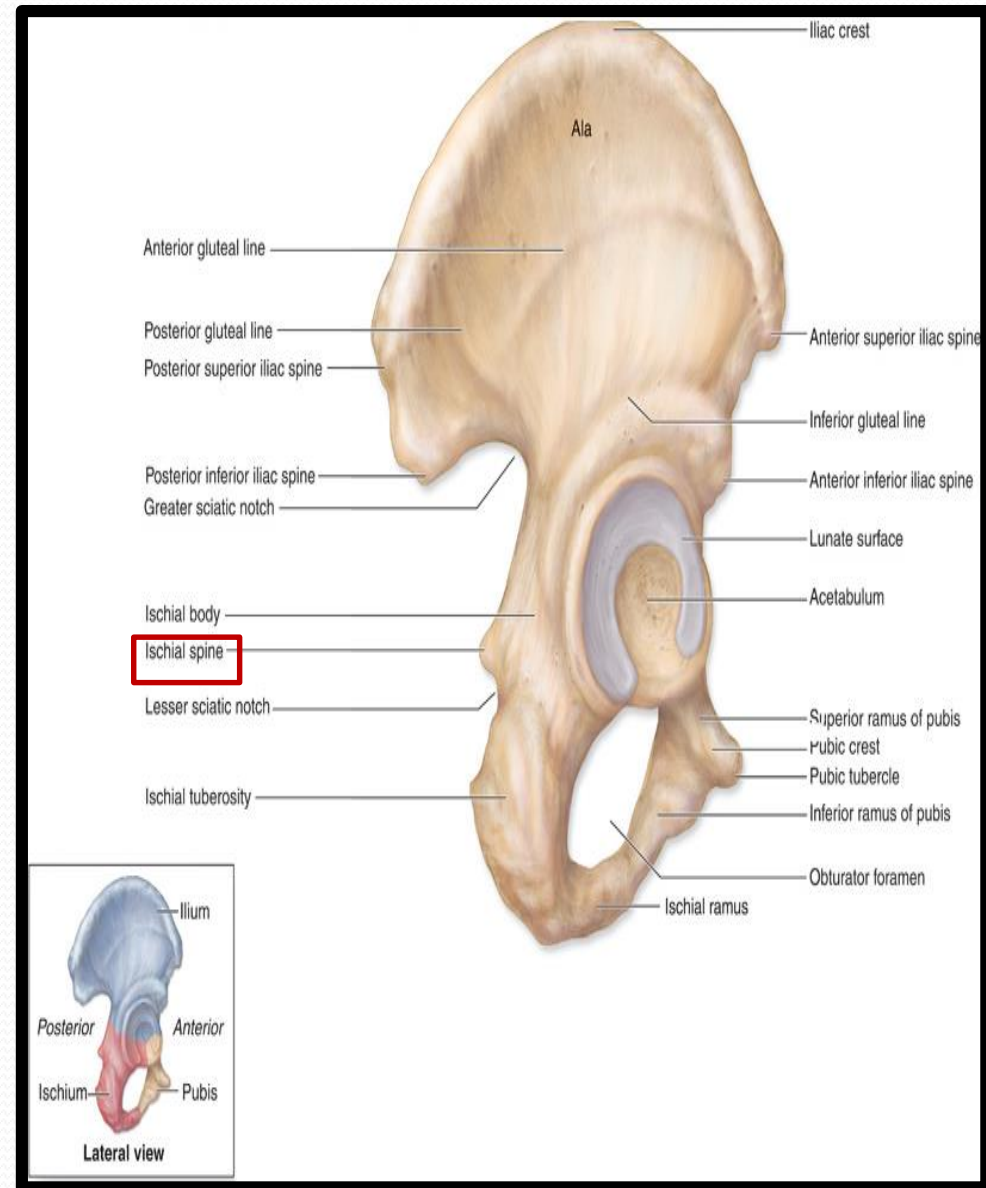
Pubis

- Forms the Anterior & Inferior part.
- It is composed of;
- **Body**; bears the **Pubic Crest** and **Pubic Tubercle**.
- **Two pubic Rami**;
- Superior & Inferior.
- They bound the **Obturator Foramen**, which is closed partially by the obturator membrane.



Ischium

- Forms the Inferior and Posterior part of the hip bone
- It has;
- **Ischial Tuberosity:**
- A roughened area that receives body weight in sitting.
- **Ischial Spine:**
- Superior to the tuberosity, it is important landmark in pregnant women.
- **Greater sciatic notch.**
- **Lesser sciatic notch.**



Articulations of Hip Bone

❖ Symphysis Pubis:

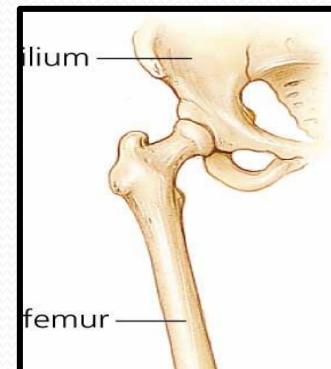
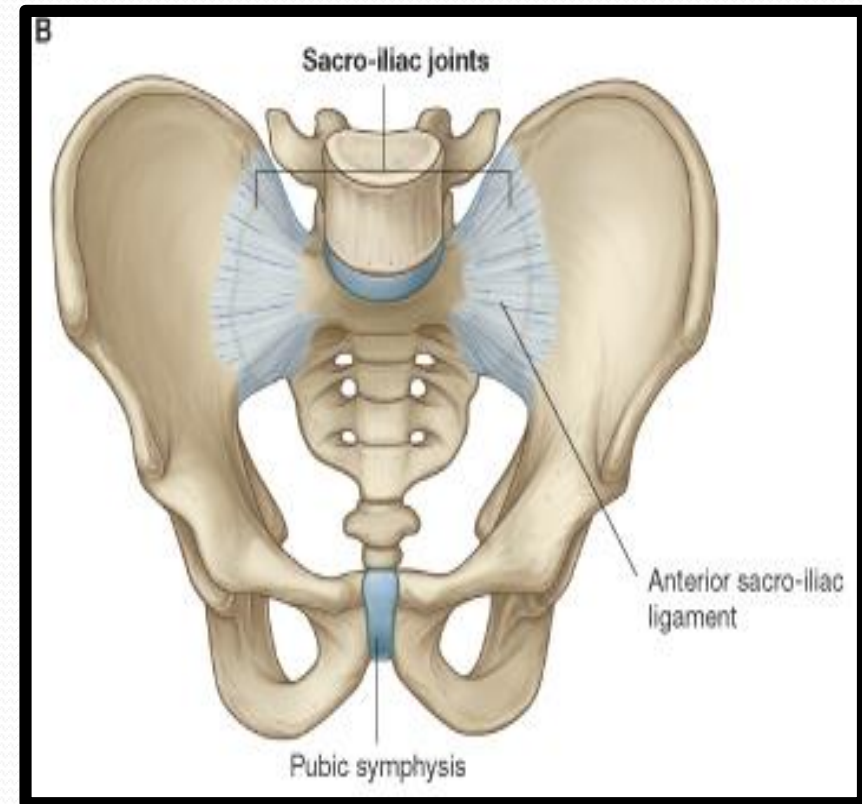
❑ A secondary cartilagenous joint between the two pubic bones

❖ Sacroiliac Joints:

❑ Strong synovial joints, between the auricular surfaces of both iliac bones and the sacrum.

❖ Hip Joints:

❑ The acetabulum articulates with the head of the femur.



Sacrum

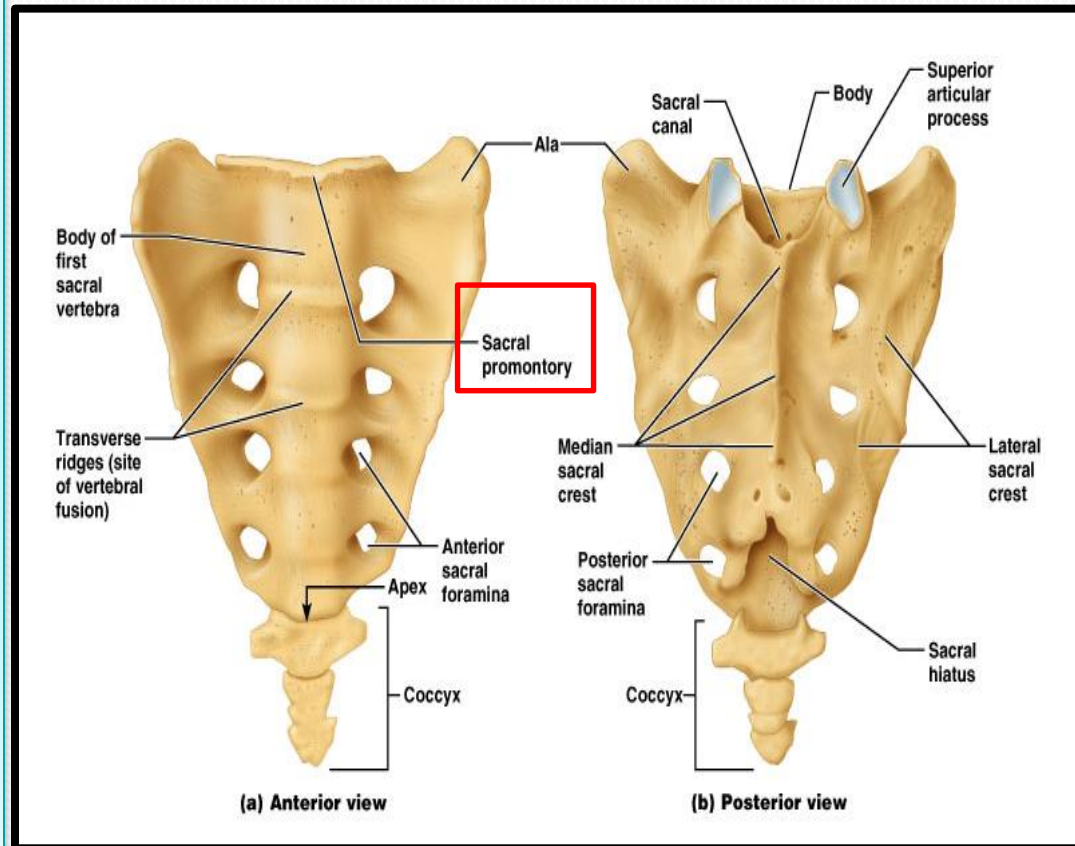
➤ A **Single Wedge** shaped bone (consists of Five rudimentary vertebrae fused together).

➤ **Sacral Promontory:**

- The anterior and upper margin.
- It is tilted forward forming the **lumbosacral angle**.

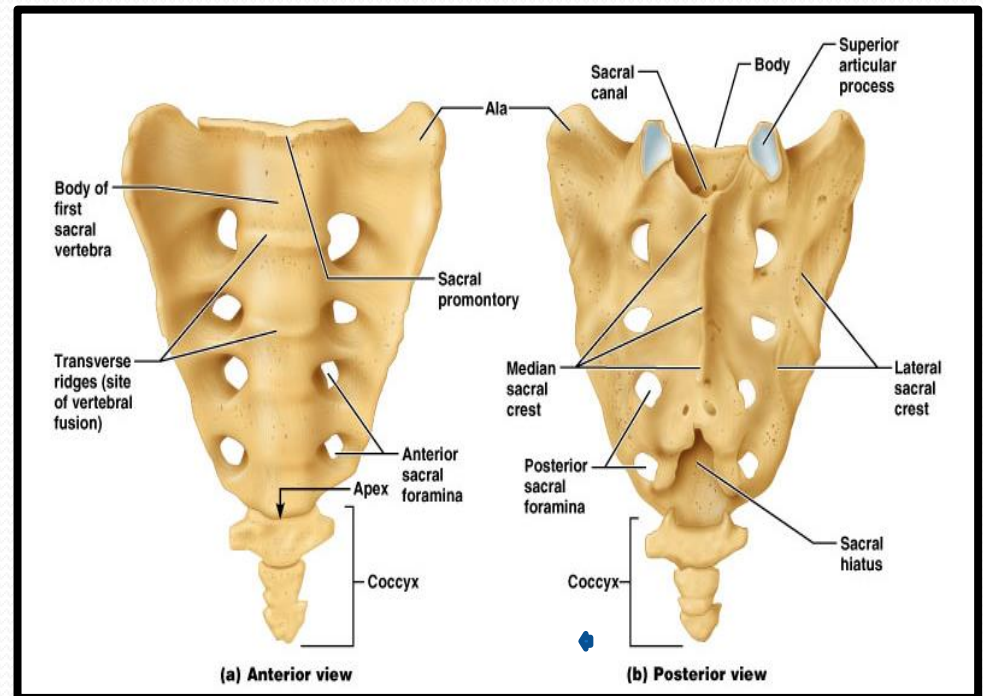
- The anterior and posterior surfaces possess on each side **Four Sacral Foramina**.

➤ The fused vertebral foramina form the **Sacral Canal**, its lower limit is the **Sacral Hiatus**



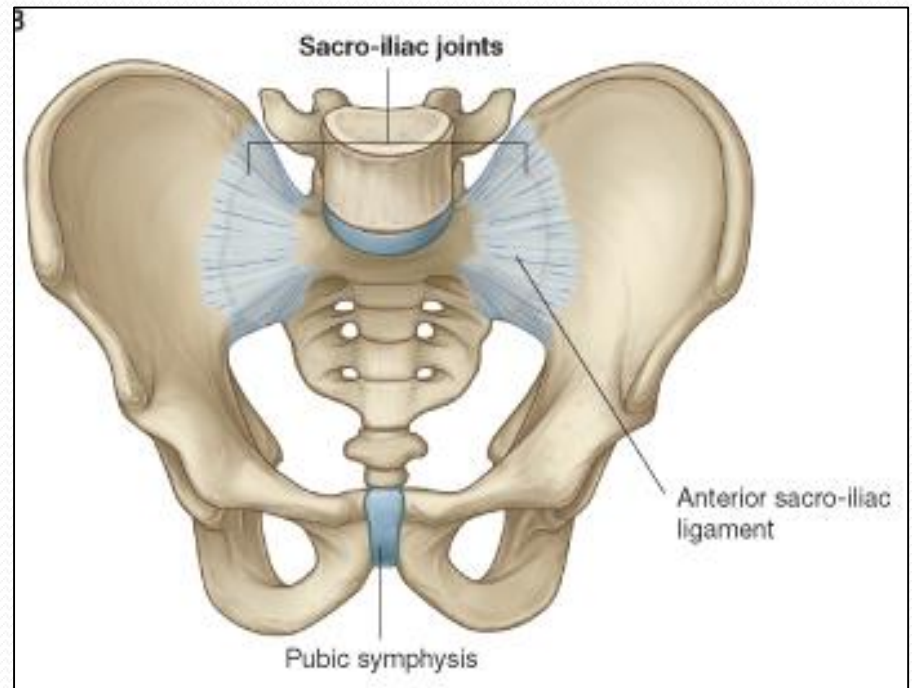
Coccyx

➤ Consists of four vertebrae fused together forming a single **Triangular piece**

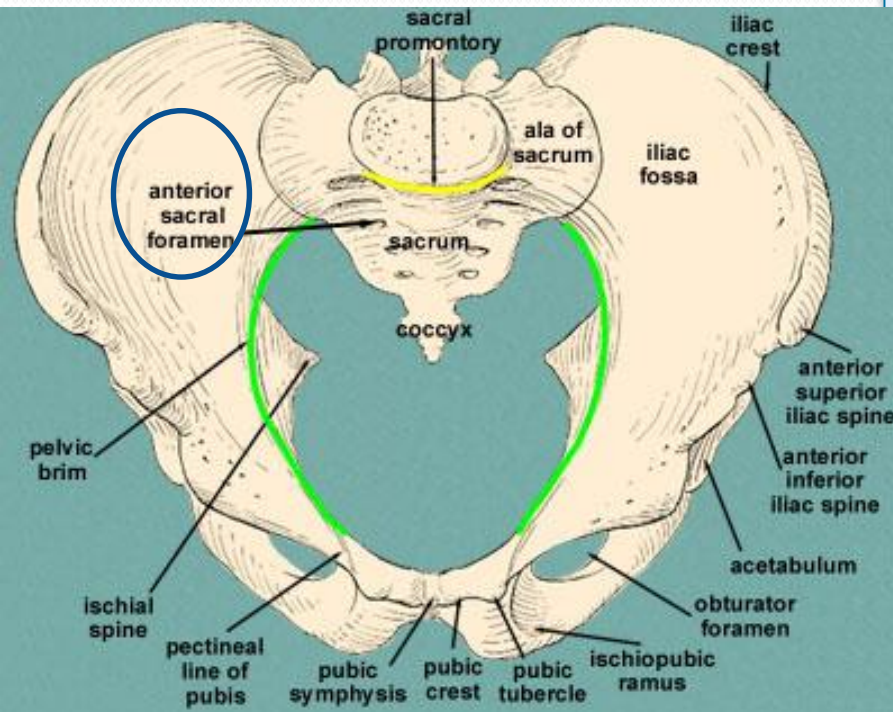


Articulations of Sacrum

- **Lumbosacral joint:**
- The upper border articulates with the 5th Lumber vertebra
- **Sacrococcygeal joint:**
- The inferior part articulates with the Coccyx
- **Sacroiliac joints:**
- Lateral articulation with the both Hip bones.



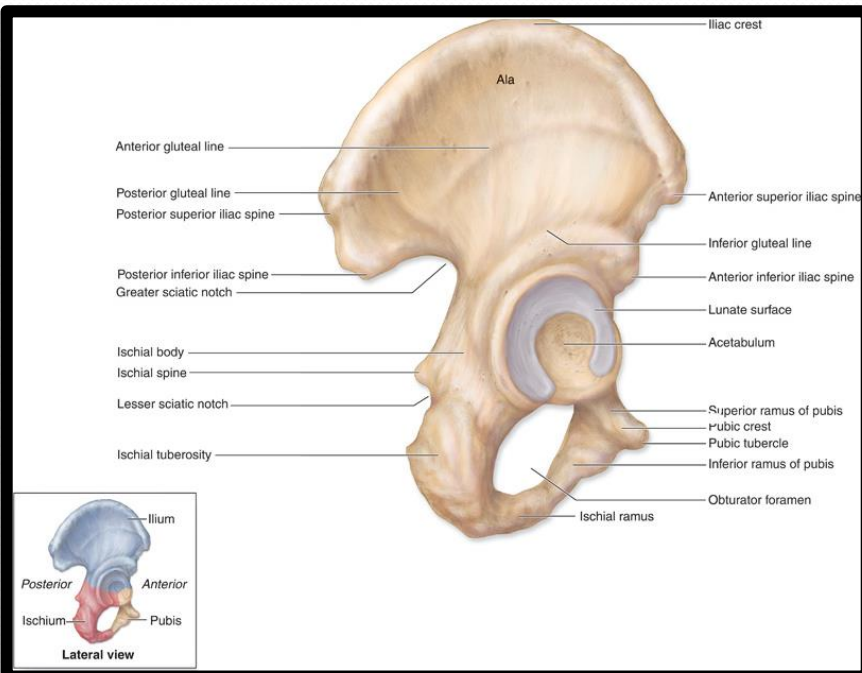
Foramina in Bony Pelvis



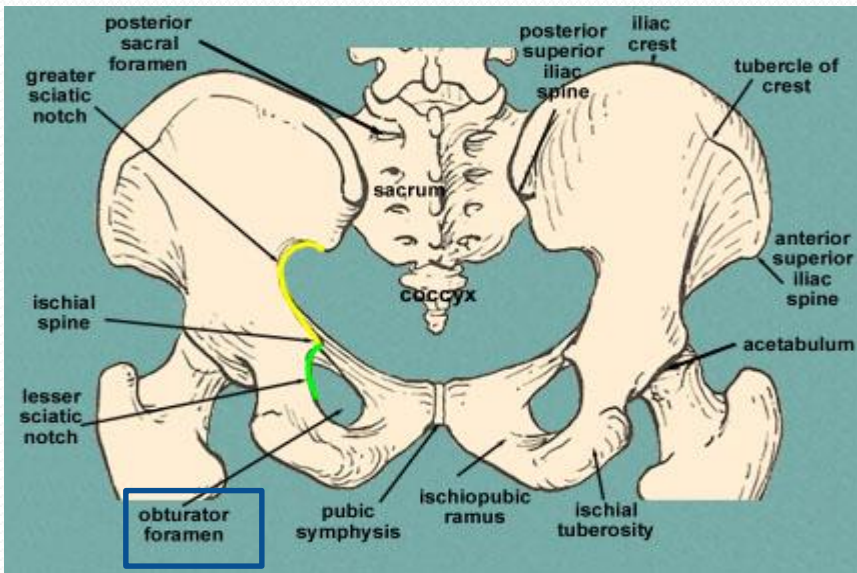
- The holes of the basin are called foramina.
- The important foramina in the bony pelvis include:
- **Anterior sacral foramina:** These are present on the anterior surface of the sacrum (which forms the posterior surface of the bony pelvis). Through these foramina pass the anterior rami of the sacral spinal nerves.

Foramina in Bony Pelvis

- **Greater and lesser sciatic foramina**: These are the major foramina of the pelvis.
- In the bony pelvis, they are present as greater and lesser sciatic notches but by the attachment of **sacrospinous** and **sacrotuberous** ligaments, these notches are converted to respective foramina.
- Through these foramina various structures enter and leave the pelvis.



Foramina in bony pelvis

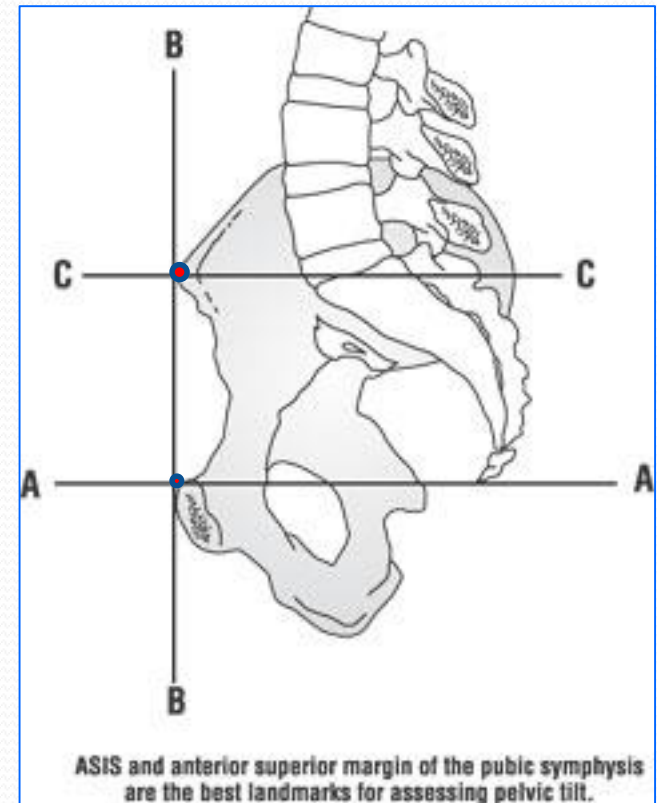


- **Obturator foramen:**
- Each lateral wall of the pelvis has a large hole, called the **obturator foramen**.
- In living subjects, this hole is closed by the obturator membrane except for a small opening, which represents the obturator canal .
- Obturator nerve passes through this small opening.

Orientation of the Pelvis

□ **It is the Correct Position** of the bony pelvis relative to the trunk (in the anatomical position):

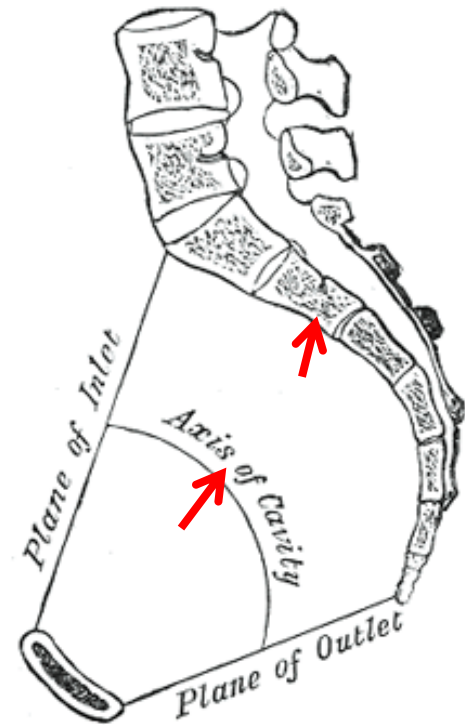
1. The anterior-superior iliac spine and the pubic tubercles are in the same **Vertical plane**.
2. The coccyx is in the same **Horizontal plane** as the upper margin of the pubic symphysis.



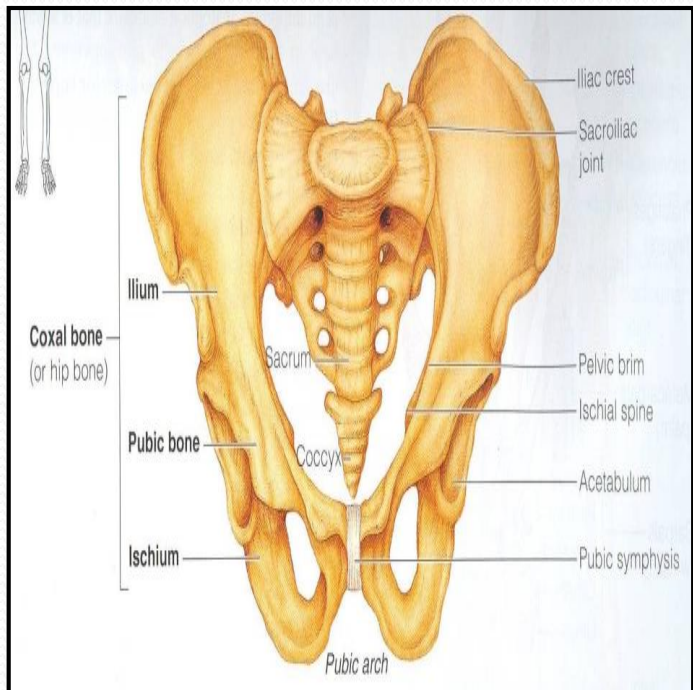
Orientation of the Pelvis

3. The axis of the pelvic cavity running through the central point of the inlet and the outlet almost parallels the curvature of the sacrum.

In this position: The anterior surface of the **Sacrum** is directed forward and downward while the pelvic surface of **symphysis pubis** faces upward and backward.

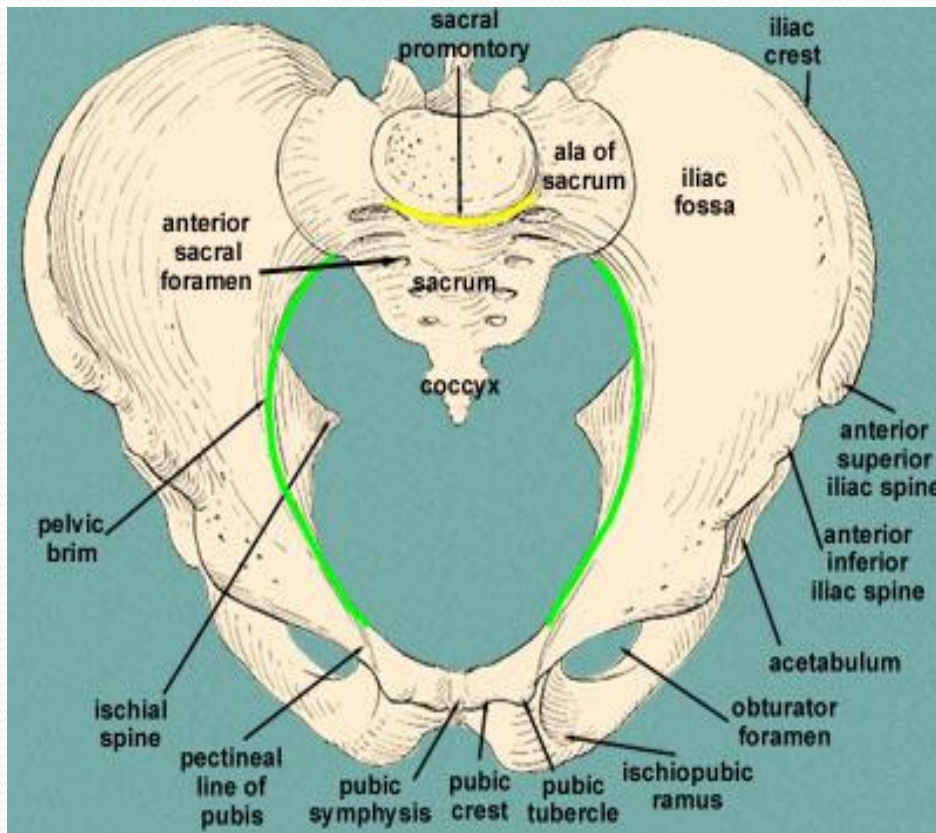


Fractures of the Bony Pelvis



- **The weakest parts of the bony pelvis are:**
- Pubic rami.
- Acetabula.
- Region of sacroiliac joint.
- Alae of the ilium.
- **Pelvic Fractures** can result from direct trauma to the pelvic bones as occurs in car accidents or by forces transmitted to these bones from the lower limbs during falls on the feet.
- Pelvic fractures may cause injury to the pelvic soft tissues, blood vessels, nerves and organs.

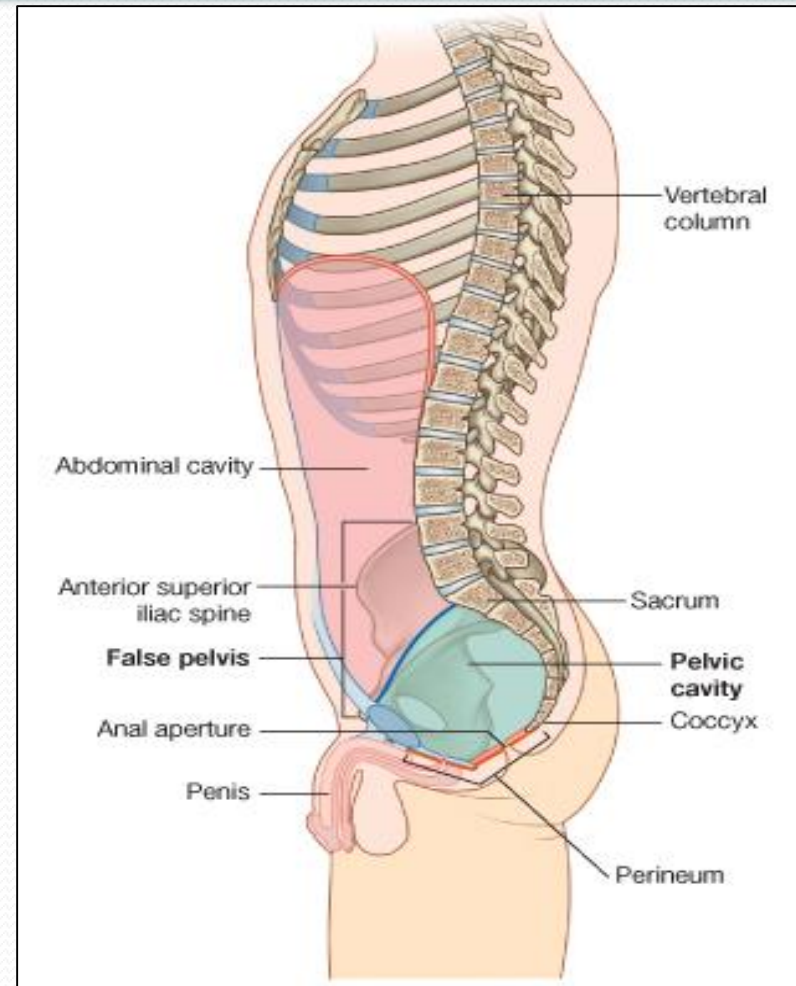
Subdivision of the Bony Pelvis



- The bony pelvis is divided into two parts by the **Pelvic Brim**.
- The brim is formed **Posteriorly: Sacral Promontory**,
- **Laterally: Iliopectineal line.**
- **Anteriorly : Symphysis pubis.**
- Above the pelvic brim lies the **False Pelvis**, which is not of much clinical importance.
- Below the brim is the **True Pelvis**

False pelvis

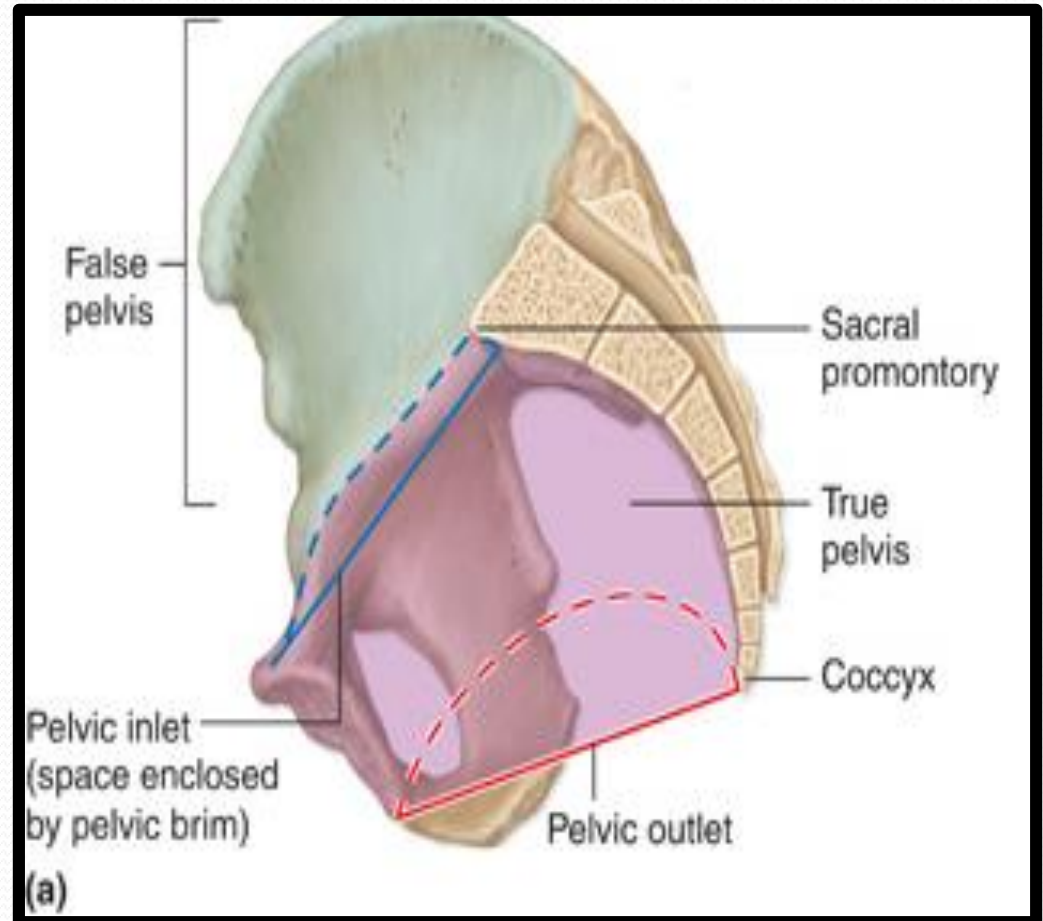
- Lies superior to the pelvic brim.
- Enclosed by the **Fossae of the iliac bones**
- Forms the inferior region of the abdominal cavity.
- Houses the **Inferior abdominal organs**



True Pelvis

- Lies **inferior** to the pelvic brim.
- Encloses the **pelvic cavity**.
- Contains the **pelvic organs**.
- It has :
 - **Inlet**
 - **Outlet**.

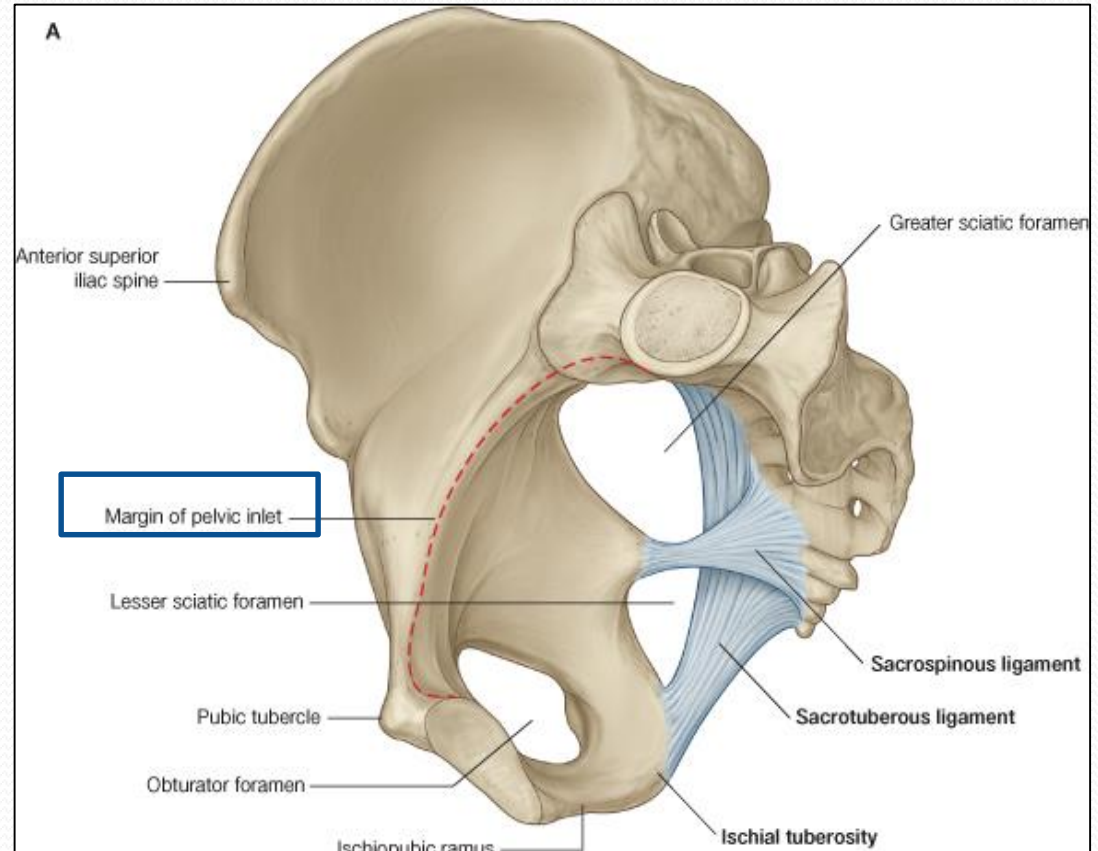
□ Pelvic walls



Pelvic Inlet (Pelvic Brim)

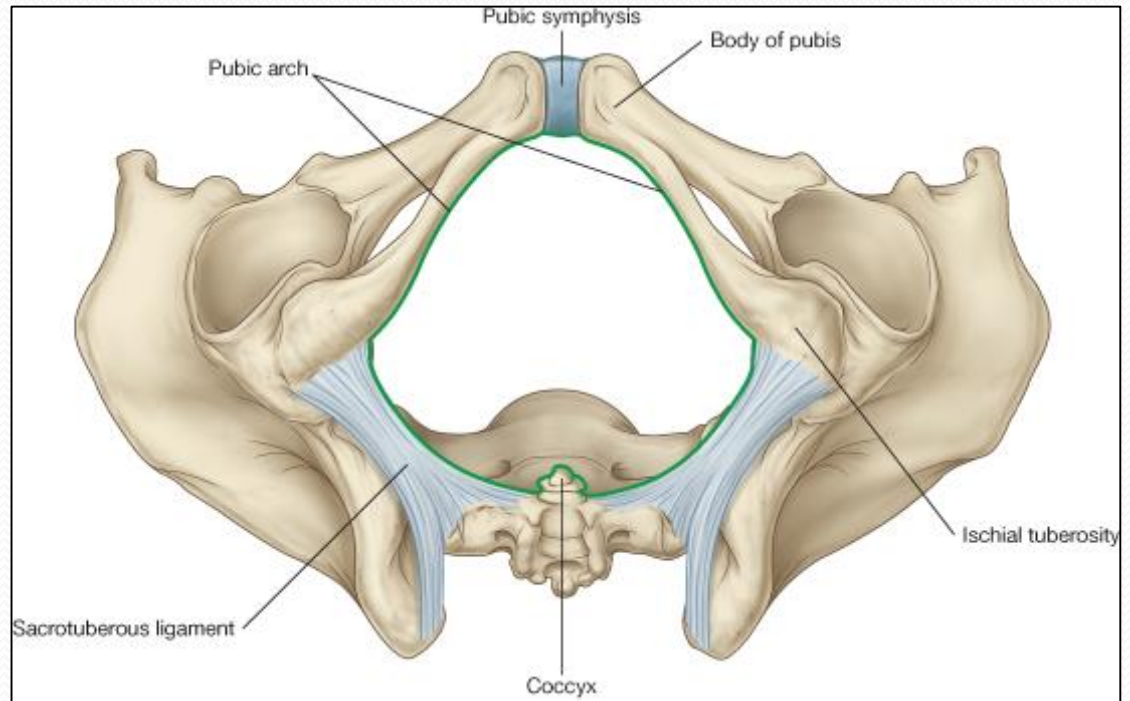
□ Bounded by:

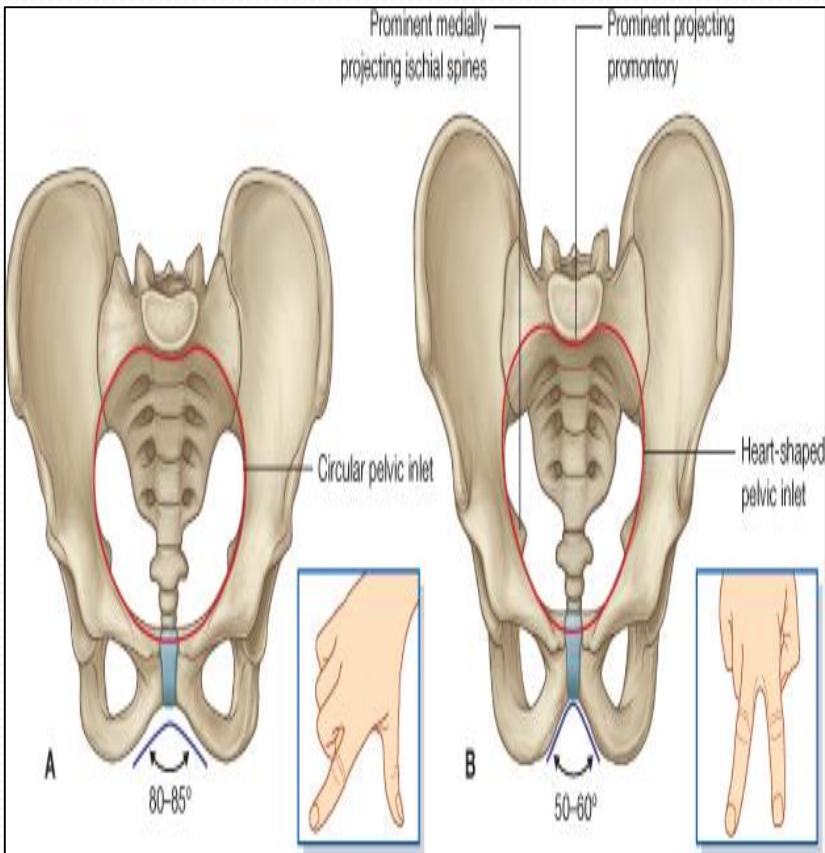
- Sacral promontory
- Iliopectineal lines.
- Symphysis pubis.



Pelvic Outlet

- Bounded by:
- Coccyx
- Ischial tuberosities.
- Pubic arches.





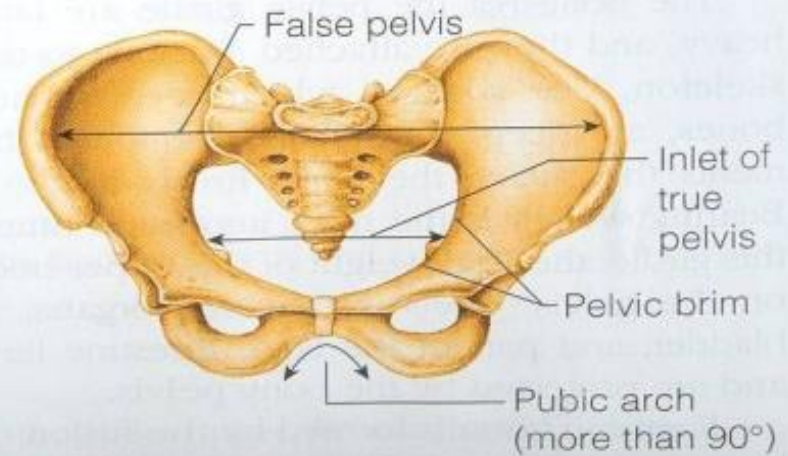
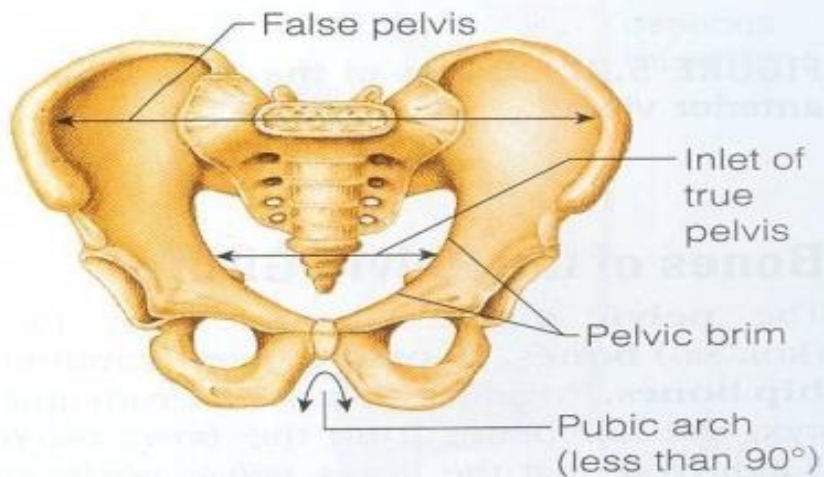
Bony pelvis	Male	Female
General structure	Thick & Heavy	Thin, Smaller & lighter
False (major) pelvis	Deep	Shallow
True (lesser) pelvis	Narrow & Deep	Wide & Shallow
Pelvic inlet	Heart shaped	Oval or Rounded
Pelvic outlet	Small	larger because of the everted ischial tuberosities
Pubic arch & Subpubic angle	Narrow	Wide
Obturator foramen	Round	Oval
Acetabulum	Large	Small

Sacrum

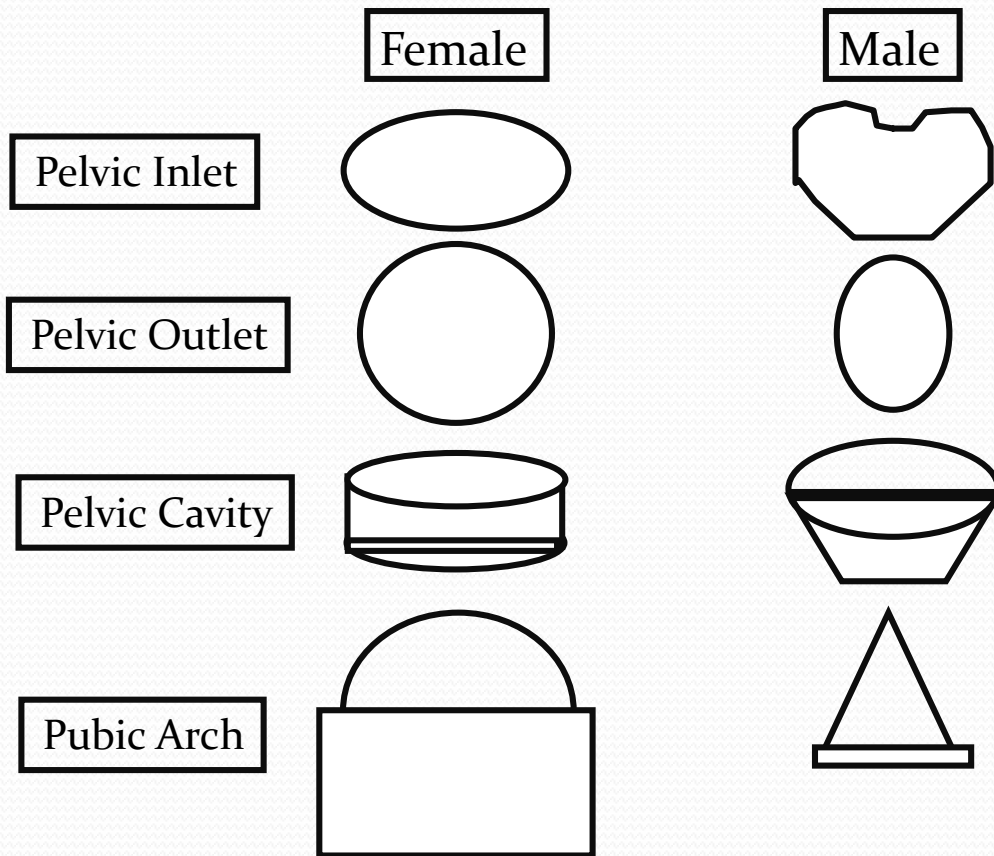
M

F

Length	Longer	Shorter
Breadth	Narrower	Wider
Curvature	More curved	Less Curved



Forensic Medicine & Bony Pelvis

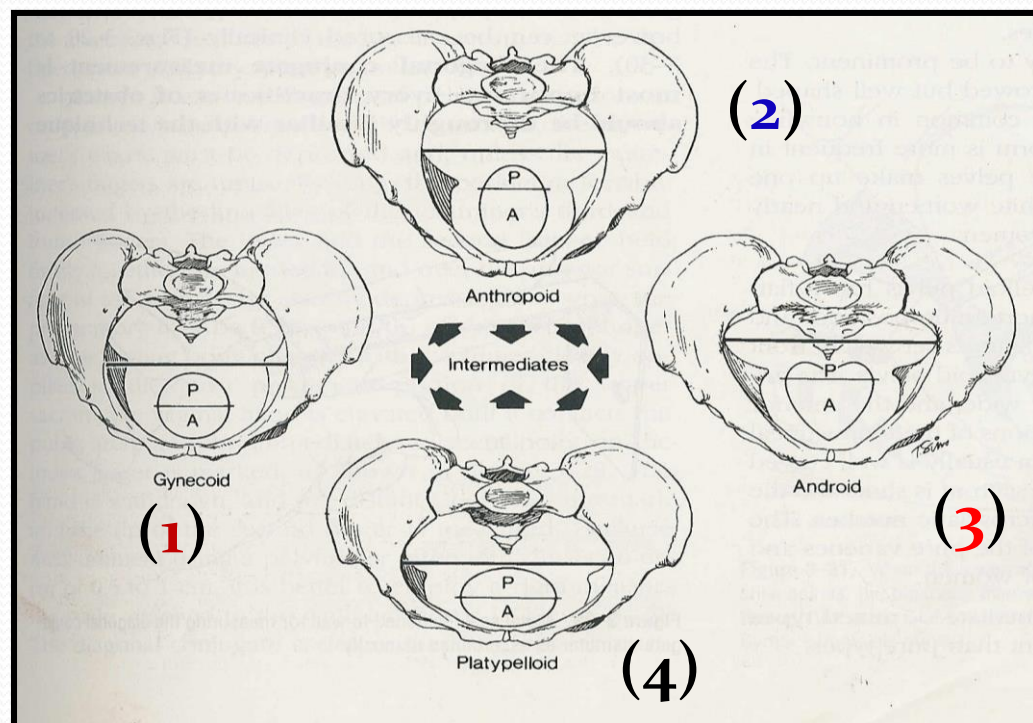


For identification of human skeletal remains, the bony pelvis is of prime focus of attention because sexual differences are clearly visible.

Even parts of the pelvis are useful in making a diagnosis of sex.

Types of Obstetrical Female Pelvis

- (1) **Gynaecoid**:
 - The typical female type
- (2) **Anthropoid**:
 - Long, narrow and oval shaped.
- (3) **Android** :
 - Funnel shaped with contracted outlet.
 - (it causes hazards to normal vaginal delivery)
- (4) **Platypelloid**:
 - wide , flattened at the brim, with forward promontory.





Thank you