

Lecture Title: Mycetoma and other Subcutaneous Mycoses

(Musculoskeletal Block, Microbiology)



Lecture Objectives..



1. Acquire the basic knowledge about mycetoma and the clinical features of the disease
2. Acquire the basic knowledge about other common subcutaneous mycosis and their clinical features.
3. Know the main fungi that affect subcutaneous tissues, muscles and bones.
4. Identify the clinical settings of such infections
5. Know the laboratory diagnosis, and treatment of these infections.

SUBCUTANEOUS MYCOSES



- Fungal infections involving the dermis, subcutaneous tissues, muscle and may extend to bone.
- They are initiated by trauma to the skin.
- Are difficult to treat and surgical intervention is frequently employed.
- Diseases in healthy host, however, more severe disease in immunocompromised host.

SUBCUTANEOUS MYCOSES



- Mycetoma
- Subcutaneous zygomycosis
- Sporotrichosis
- Chromoblastomycosis
- Pheohyphomycosis
- Rhinosporidiosis
- Lobomycosis



MYCETOMA

- Mycetoma is a chronic, granulomatous disease of the skin and subcutaneous tissue, which sometimes involves muscle, and bones.
- It is characterized by Swelling , abscess formation, and multiple draining sinuses that exude characteristic grains of clumped organisms .
- It typically affects the lower extremities, but also other areas of the body e.g. hand, back and neck.
- The disease was first described in the Madura district of India in 1842, (Madura foot).

MYCETOMA



➤ Classified as :

- **Eumycetoma:** those caused by fungi
- **Actinomycetoma:** those caused by aerobic filamentous bacteria (Actinomycetes)

➤ Mycetoma is endemic in tropical, subtropical, and temperate regions. Sudan, Senegal, Somalia, India, Pakistan, Mexico, Venezuela

➤ Is more common in men than in women (ratio is 3:1).

➤ Commonly in people who work in rural areas, framers

MYCETOMA



Mycetoma is acquired via trauma of the skin

Trauma

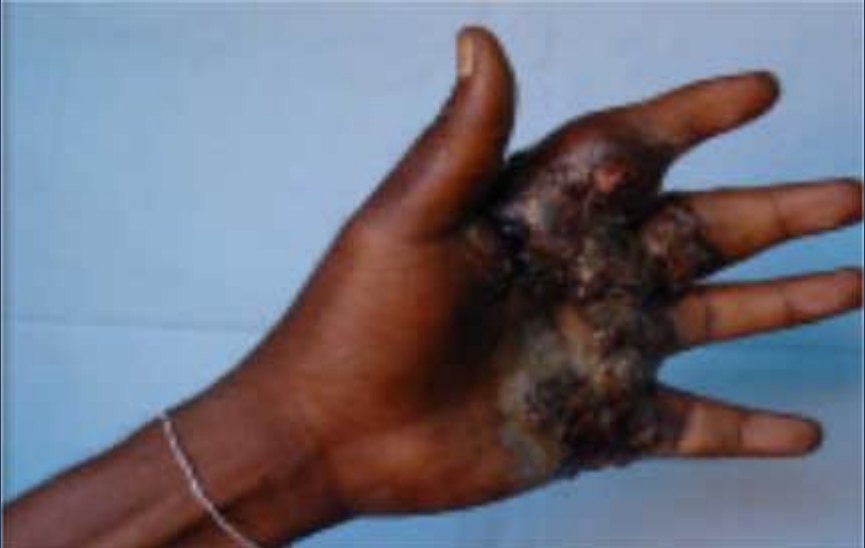
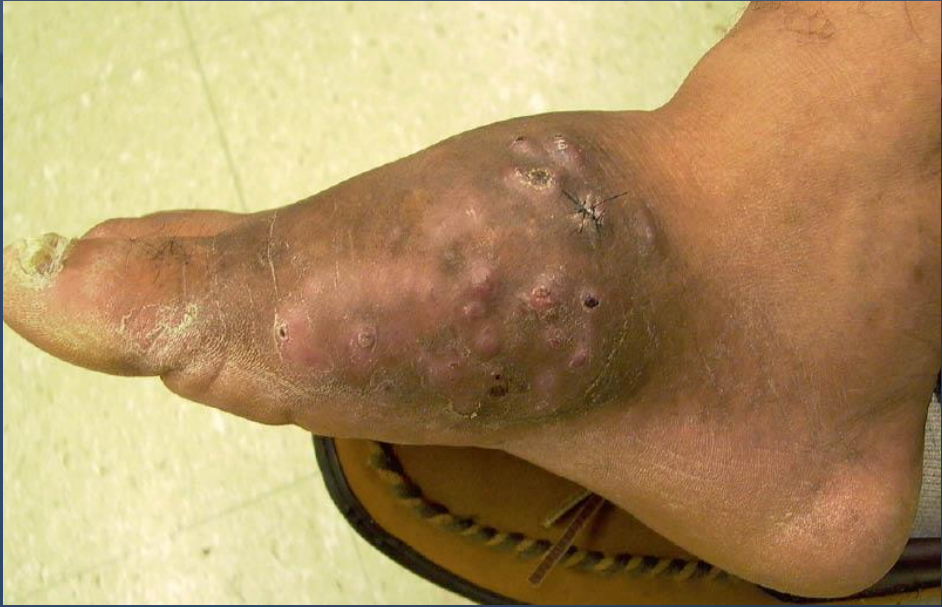
painless subcutaneous firm nodule is observed



massive swelling with skin rupture, and sinus tract formation

old sinuses close and new ones open, draining exudates with grains (granules)
Grains may sometimes be seen with the naked eye.



MYCETOMA

Etiology

Eumycetoma

Caused by a several mould fungi

The most common are

Madurella mycetomatis, *Madurella grisea*, and *Pseudallescheria boydii*

The color of grains is black or white

Actinomycetoma

Caused by aerobic filamentous bacteria , gram positive

Actinomadura madurae

Streptomyces somaliensis

Nocardia brasiliensis

Color of grains yellow, white, yellowish-brown, pinkish – red.

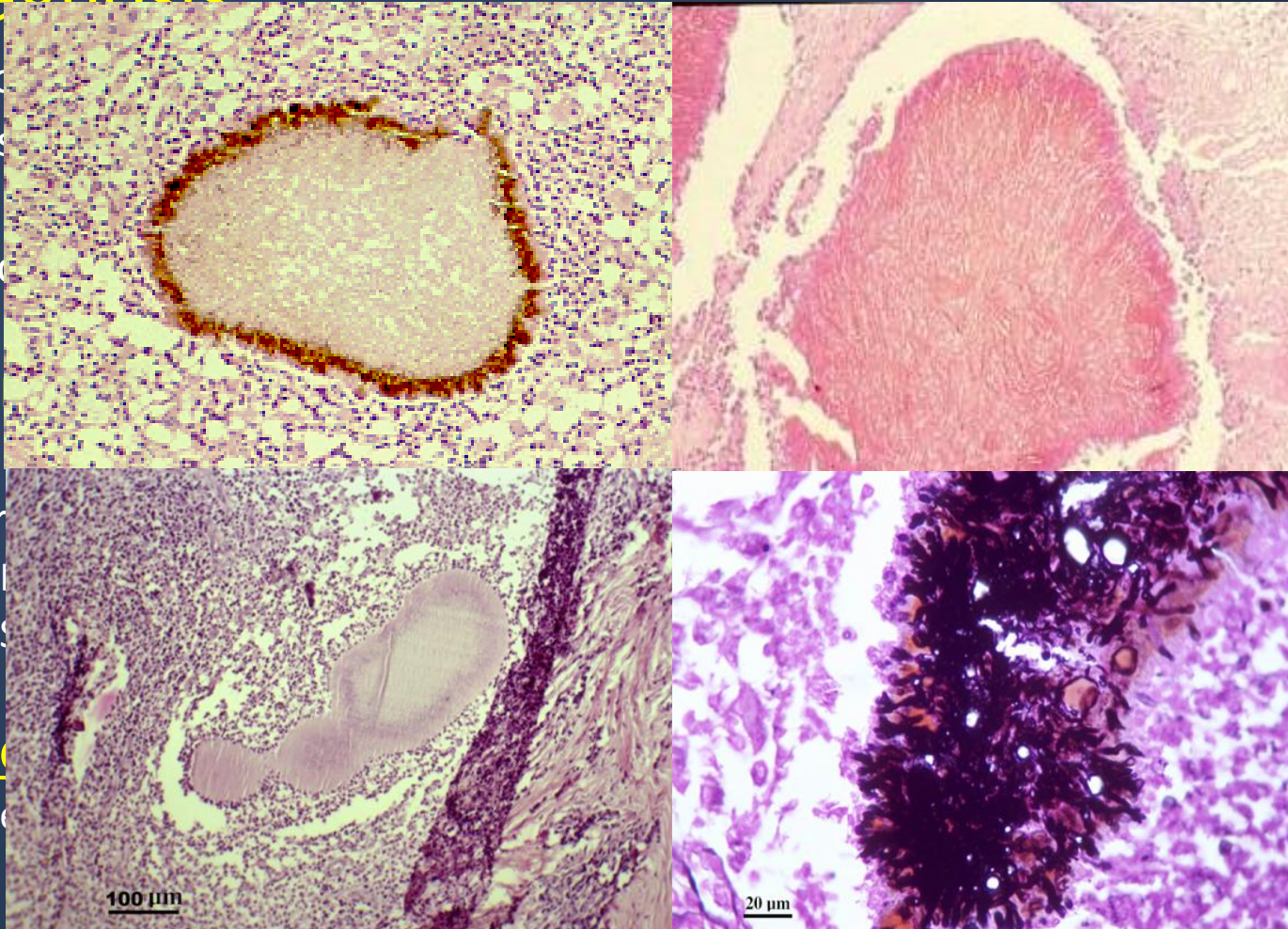
MYCETOMA

Diagnosis:

Clinic
Biops
Pus
Blood

1.

Micro



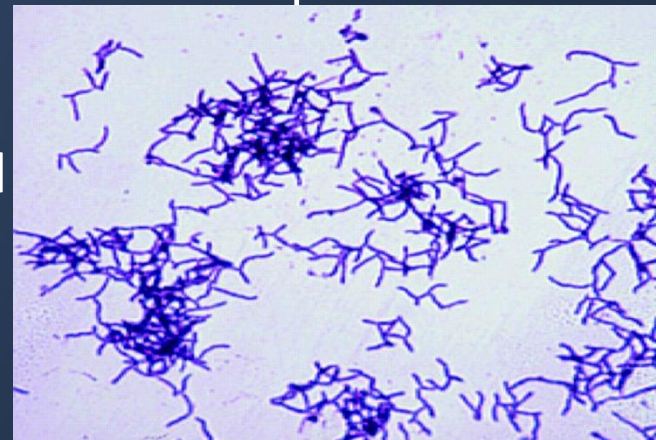
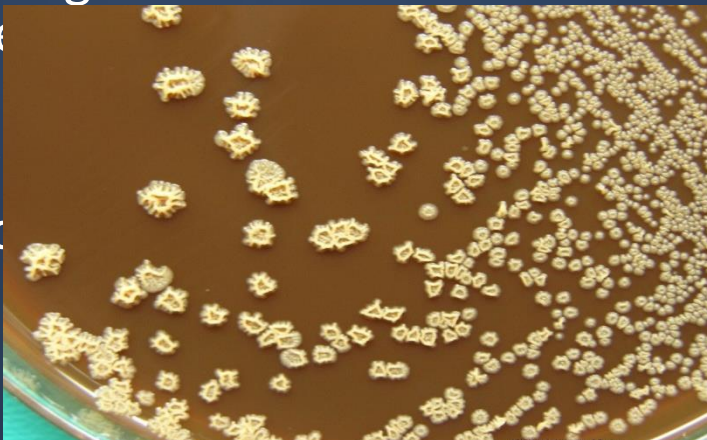
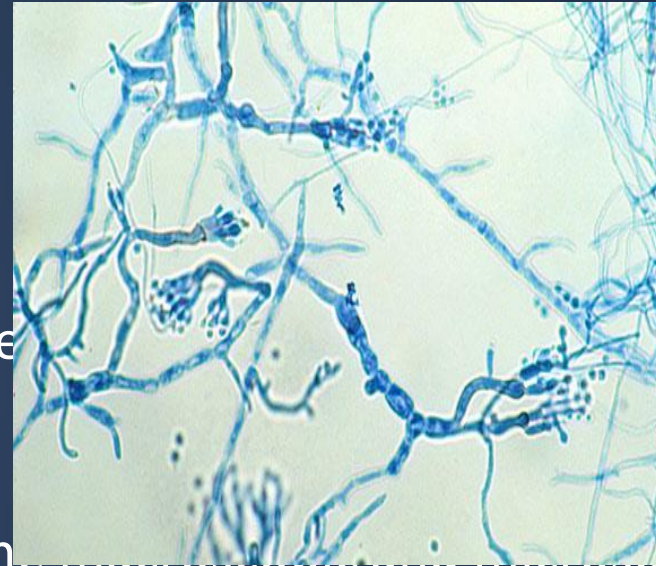
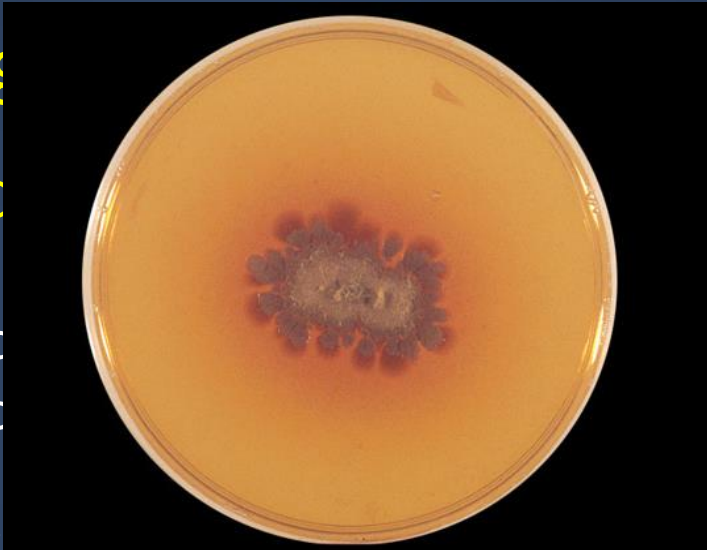➤ Black grains indicate, *Madurella* species infection.

MYCETOMA

Diag

2. C

- Med
- Bloo



Fungi are identified based on the macroscopic and microscopic

Fungi are identified based on the macroscopic and microscopic

MYCETOMA



Treatment

Eumycetoma : Itraconazole

Actinomycetoma: Trimethoprim-sulfamethoxazole

Dapsone

Streptomycin

Combination of 2 drugs is used

- Therapy is suggested for several months or years (1-2 years or more)
- Actinomycetoma generally respond better to treatment than eumycetoma
- Radiologic tests (bone radiographs) if bone involvement is suspected

Surgical Care: In eumycetoma, surgical treatment (debridement or amputation) in patient not responding to medical treatment alone and if bone is involved.

SUBCUTANEOUS ZYGOMYCOSIS

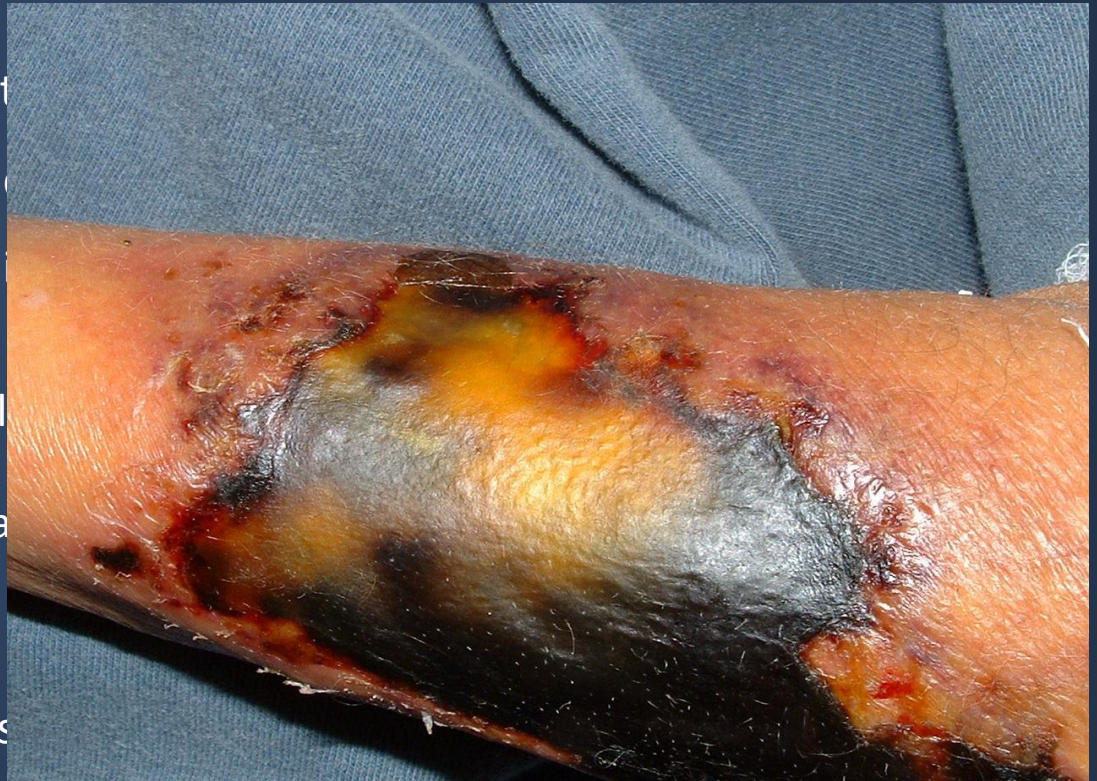

- Chronic localized firm Subcutaneous
- facial area or other like hand
- Firm swelling of site with bone and tissue.
- Acquired via traumatic implantation
needle-stick, tattooing, contact

Etiology:

Mould fungi of the Zygomycetes

Conidiobolus coronatus, *Basidiobolus ranarum*, and few mucorales.



SUBCUTANEOUS ZYGOMYCOSIS



Laboratory Diagnosis:

Specimen: Biopsy tissue

Direct microscopy:

stained sections or smears: broad non-septate hyphae

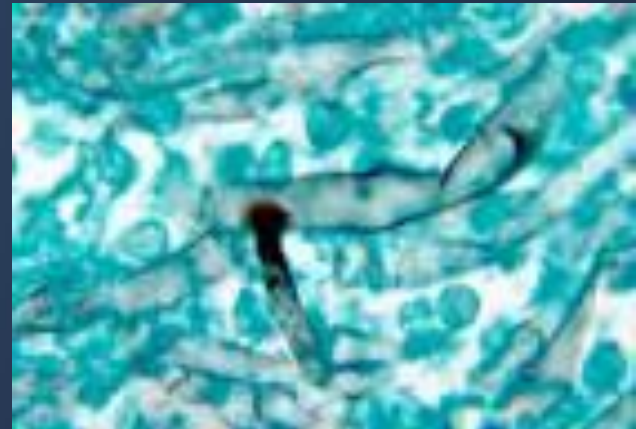
Culture: Culture on SDA

Treatment:

Oral Potassium iodide (KI)

Amphotericin B

Posaconazole



PHAEOHYPHOMYCOSIS



Is a group of fungal infections caused by dematiaceous (darkly pigmented) fungi widely distributed in the environment

Subcutaneous or brain Abscess

Presents as nodules or erythematous plaques with no systemic involvement

Affected site: Thigh, legs, feet, arms

Etiology

Dematiaceous mold fungi.

common: *Cladosporium*, *Exophiala*, *Wangiella*, *Cladophialophora*, *Bipolaris*

Diagnosis

Specimens: Pus, biopsy tissue

Direct Microscopy: KOH & smears will show brown septate fungal hyphae

Culture: On SDA

Treatment

The treatment of choice is Surgical excision of the lesion

Antifungal (Itraconazole, Posaconazole)

SPOROTRICHOSIS

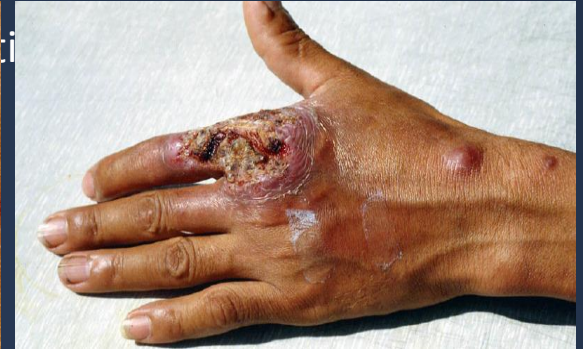
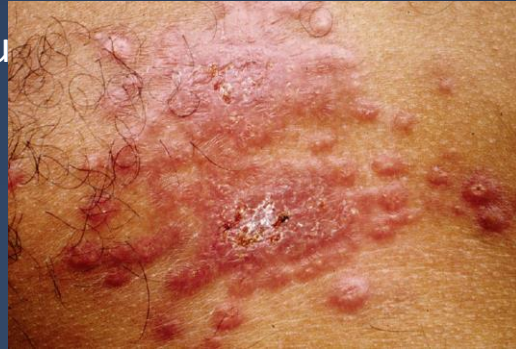
Subcutaneous , deep cutaneous

Inoculation into the skin

Can present as

- plaque (subcutaneous nodules)
- Lymphangitic
- Dissiminated



Etiology: *Sporothrix schenckii*.
Dimorphic fungus

➤ **Laboratory Diagnosis:**

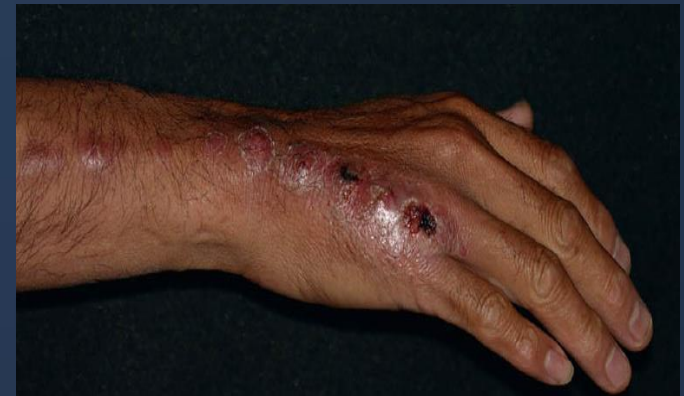Specimen: Biopsy tissue, pus

Direct Microscopy: smear will show Finger-like yeast cells or Cigar shaped

Culture: On SDA at room temperature and at 37°C

Treatment

Itraconazole, KI



Other subcutaneous fungal infections



| | Sporotrichosis | Phaeohyphomycosis | Chromoblastomycosis | Rhinosporidiosis | Lobomycosis |
|--------------------------|--|---|--|--|---|
| Clinical features | Subcutaneous or systemic infection Nodular subcutaneous lesions, verrucous plaques or Lymphatic | Subcutaneous or brain Abscess Nodules and erythematous plaques | Subcutaneous Verrucous plaques, cauliflower aspect, hyperkeratotic, Ulcerative | Granulomatous, mucocutaneous polyps | Subcutaneous Nodular lesions, keloids |
| Etiology | Dimorphic fungus <i>Sporothrix schenckii</i> | Dematiaceous (darkly pigmented) mould fungi | Dematiaceous mould fungi | Obligatory parasitic fungus <i>Rhinosporidium seeberi</i> | Obligatory parasitic fungus <i>Lacazia loboi</i> |
| Clinical sample | Biopsy tissue | Biopsy tissue | Biopsy tissue | Biopsy tissue | Biopsy tissue |
| Direct Microscopy | Elongated yeast cells | Brown septate hyphae | Muriform cells (sclerotic bodies) | Spherules with endospores | Chains of yeast cells |
| Treatment | Potassium iodide Itraconazole | Surgery (Antifungal therapy) | Surgery (Antifungal therapy) | Surgery | Surgery |

Bone and joint infections

They are uncommon

Not as isolated clinical problem

Result from:

- Hematogenous dissemination

- Presence of foreign body

- Direct inoculation of organism (trauma, surgery , etc)

- Spared through direct extension of infection to the bone

- e.g. Rhinocerebral zygomycosis, Aspergillosis, mycetoma

Osteomyelitis

Joint infections

Etiology:

Candida species

Aspergillus species and mould fungi

Blastomyces dermatiditis

Coccidioides immitis

Histoplasma capsulatum

Paracoccidioides brasiliensis

Thank You 😊

(Musculoskeletal Block, Microbiology)

