

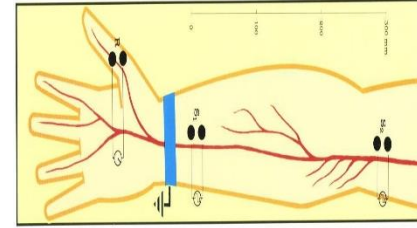
Applied Nerve & Muscle Physiology :

Nerve Conduction Study (NCS))and
Electromyography (EMG)

Objectives

- Define what is nerve conduction study (NCS) and electromyography (emg) .
- Explain the procedure of NCS using Abductor Pollicicis Brevis muscle .
- Define the normal conduction velocity in upper limb and lower limb nerves .
- Define the motor unit potentials (MUPs) and how they are changed in muscle and nervediseases .

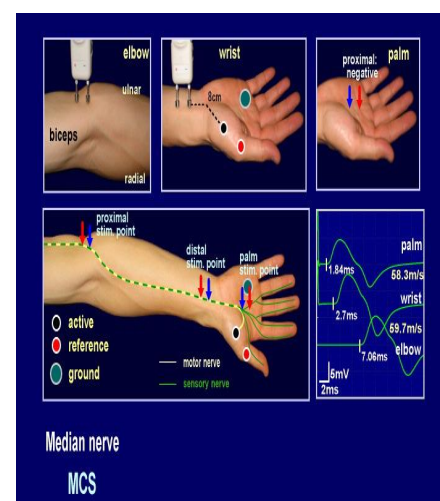
Nerve Conduction Study (NCS)



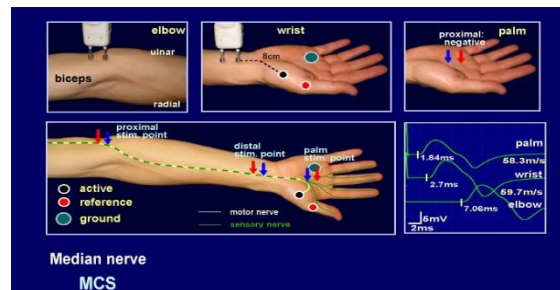
- A nerve conduction study (NCS) is an electrophysiology test commonly used to evaluate the function of peripheral nerves of the human body.
- It could be motor nerve conduction study (motor NCS) , sensory nerve conduction study or mixed nerve conduction study .
- In this lecture, because of time constraint, only motor nerve conduction study will be discussed
- In the motor test the recorded response is the muscle CMAP (compound muscle action potential)

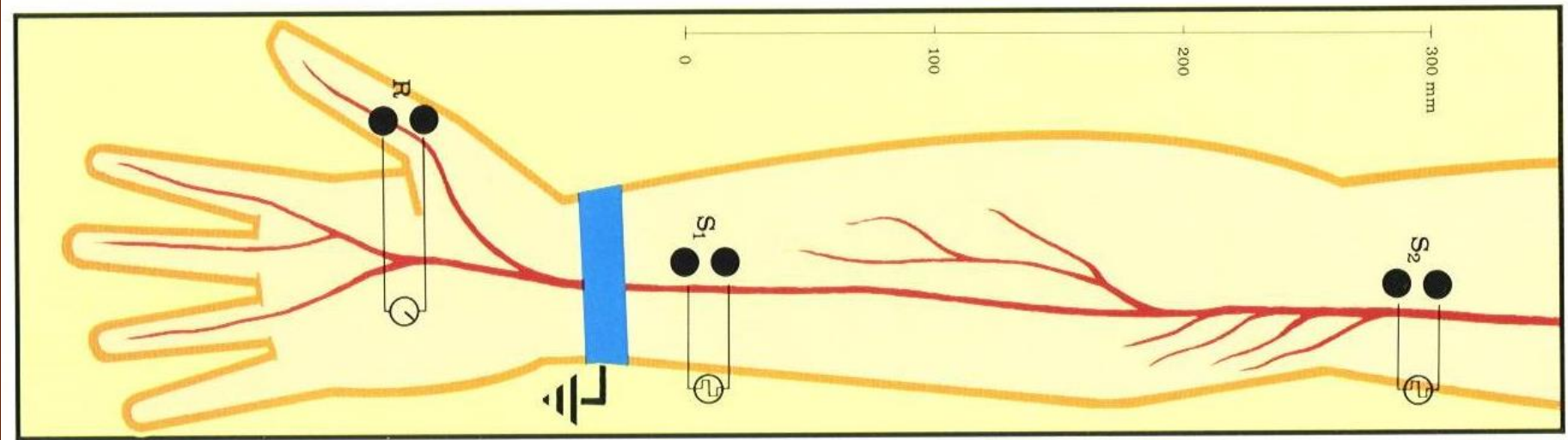
Procedure

- An electrical stimulus is applied over a nerve (e.g., median nerve) and a recording electrode is place over the muscle supplied by that motor nerve .
- The stimulus is applied at two sites : a distal site (wrist) and a proximal one (antecubital fossa , elbow).
- The muscle usually chosen in this routine test is the Abductor Pollicis Brevis
- The active recording electrode (G1) is place over the thenar eminence which overlies the muscle .
- And the reference recording electrode (G2) about 3 cm away .
- The oscilloscope (CRO) sweep speed is

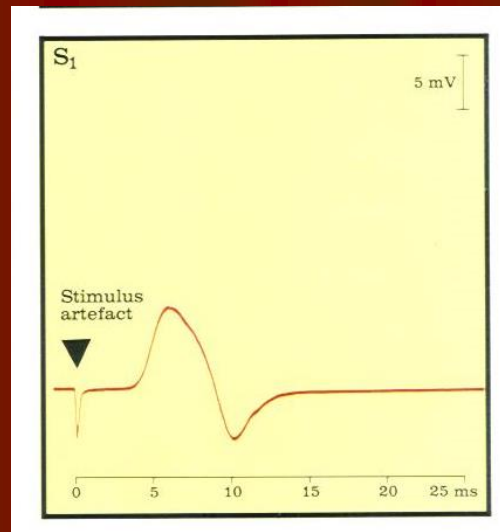


- The stimulus duration used is 0.2 ms and stimulus frequency to 1 / sec.
- Apply the stimulus and record the response from stimulation at the wrist .
- Store the CMAP (compound muscle action potential) in the first channel of the oscilloscope .
- Change the stimulating site from wrist to antecubital fossa (elbow) .
- Stimulate the nerve & record the CMAP for median nerve stimulation at the elbow .

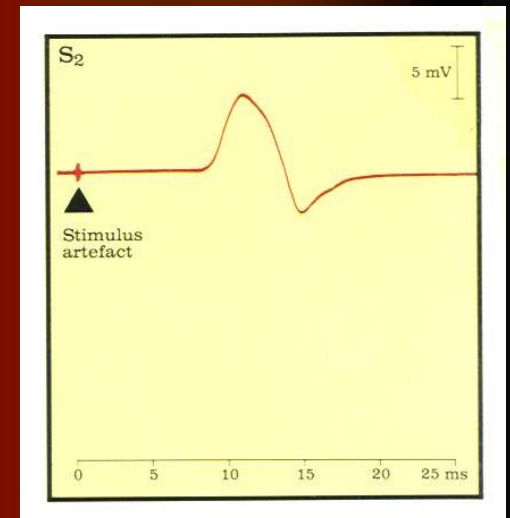




Distance
 $d = 284 \text{ mm}$



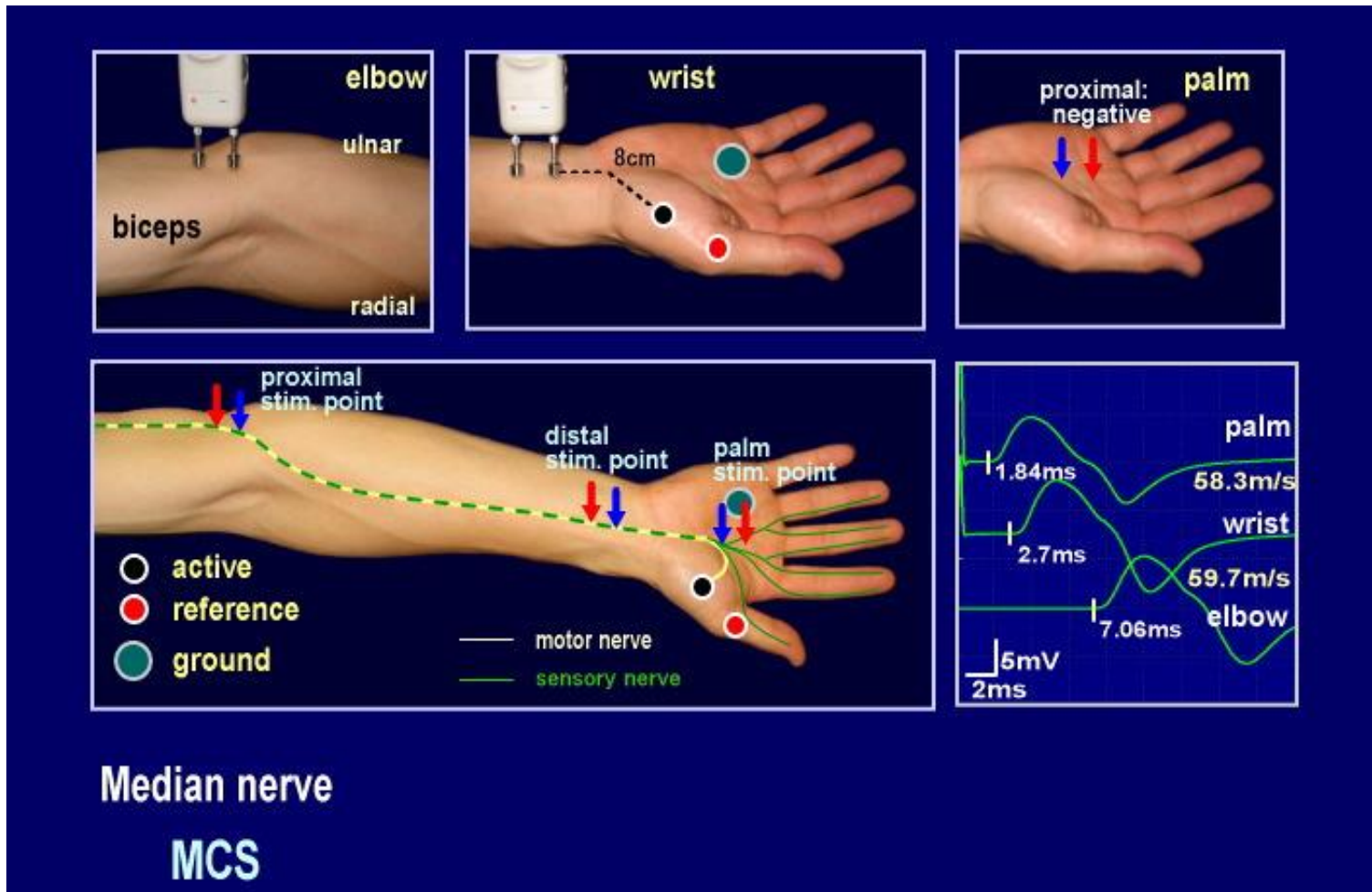
L1 Latency At
 wrist
 $= 3.5 \text{ ms}$



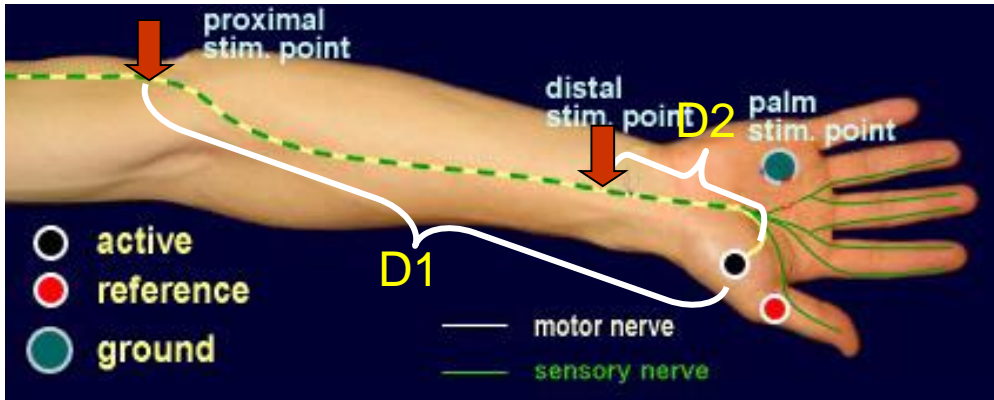
L2 Latency At
 elbow
 $= 8.5 \text{ ms}$

- Measure the distance from elbow to wrist with a measuring tape.
- Measure the latency in first CMAP & in the next CAMP.
- Enter the distance between the elbow and wrist
- .

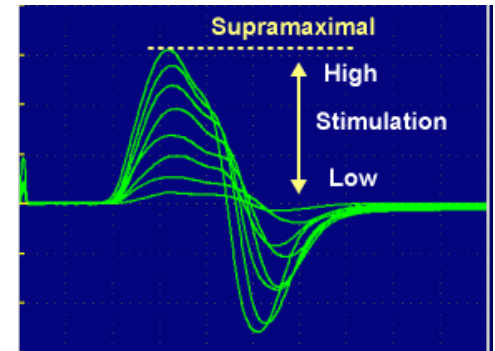
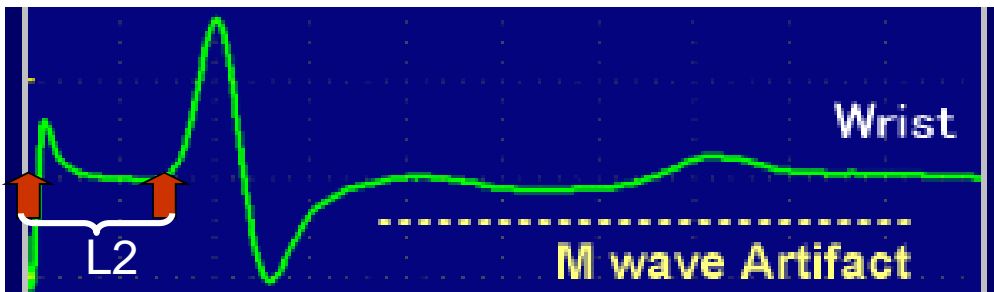
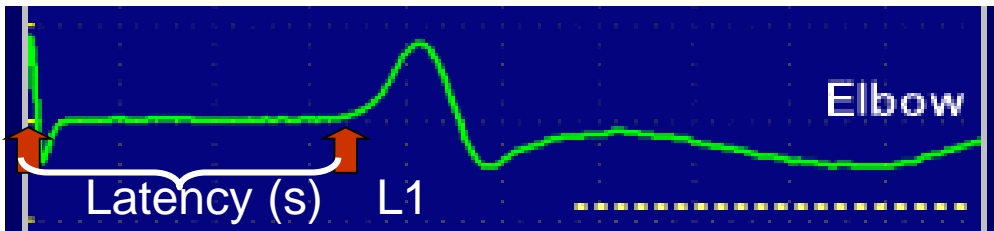
Motor conduction study: Median nerve

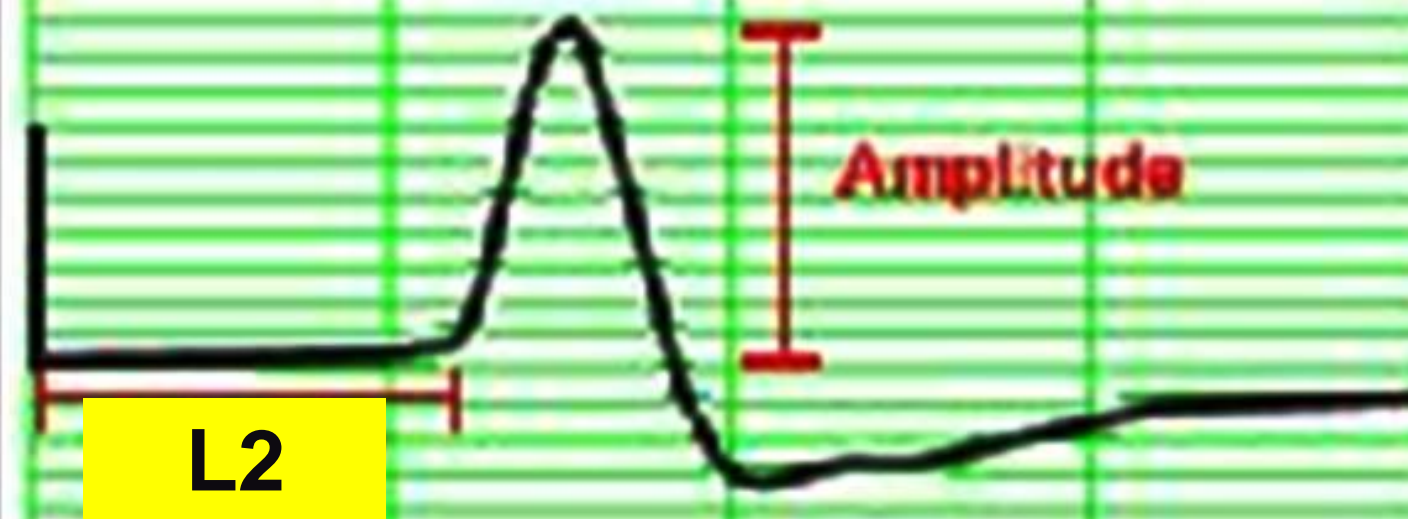
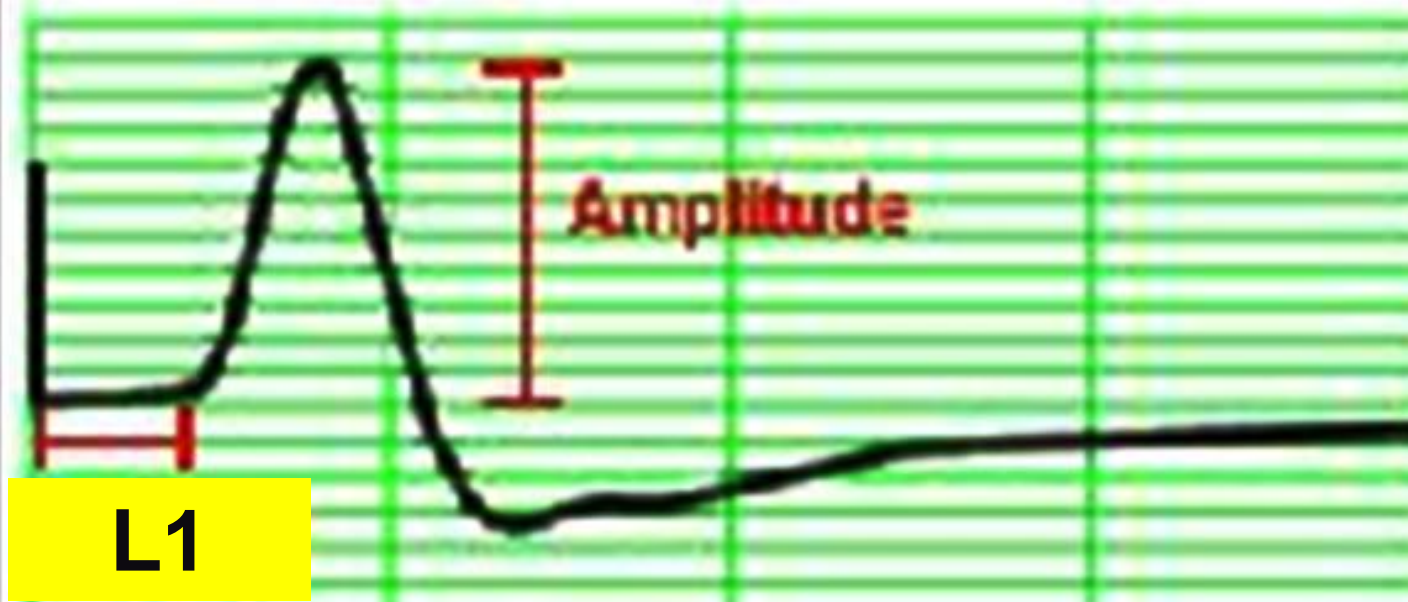


Nerve conduction velocity



$$NCV = \frac{D1-D2}{L1-L2}$$





MNCV

- MNCV will appear.
- It can also be calculated by formula

- $$\text{MNCV (m/sec)} = \frac{\text{Distance (mm)}}{\text{L2-L1 (ms)}}$$

- L1 = latency at wrist
- L2 = latency at elbow

Normal values for conduction velocity

✓ In arm

– 50 – 70 m / sec.

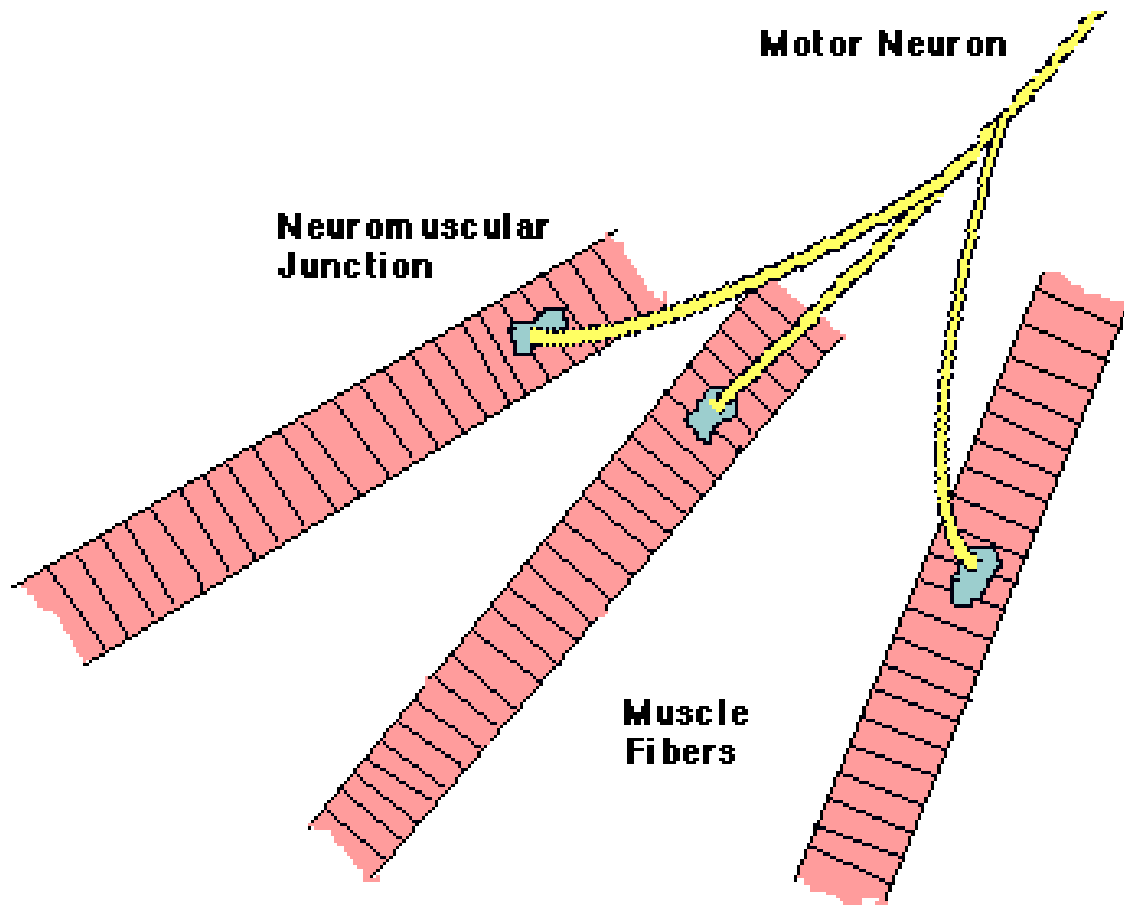
✓ In leg

– 40 – 60 m / sec.

Electromyography (EMG)

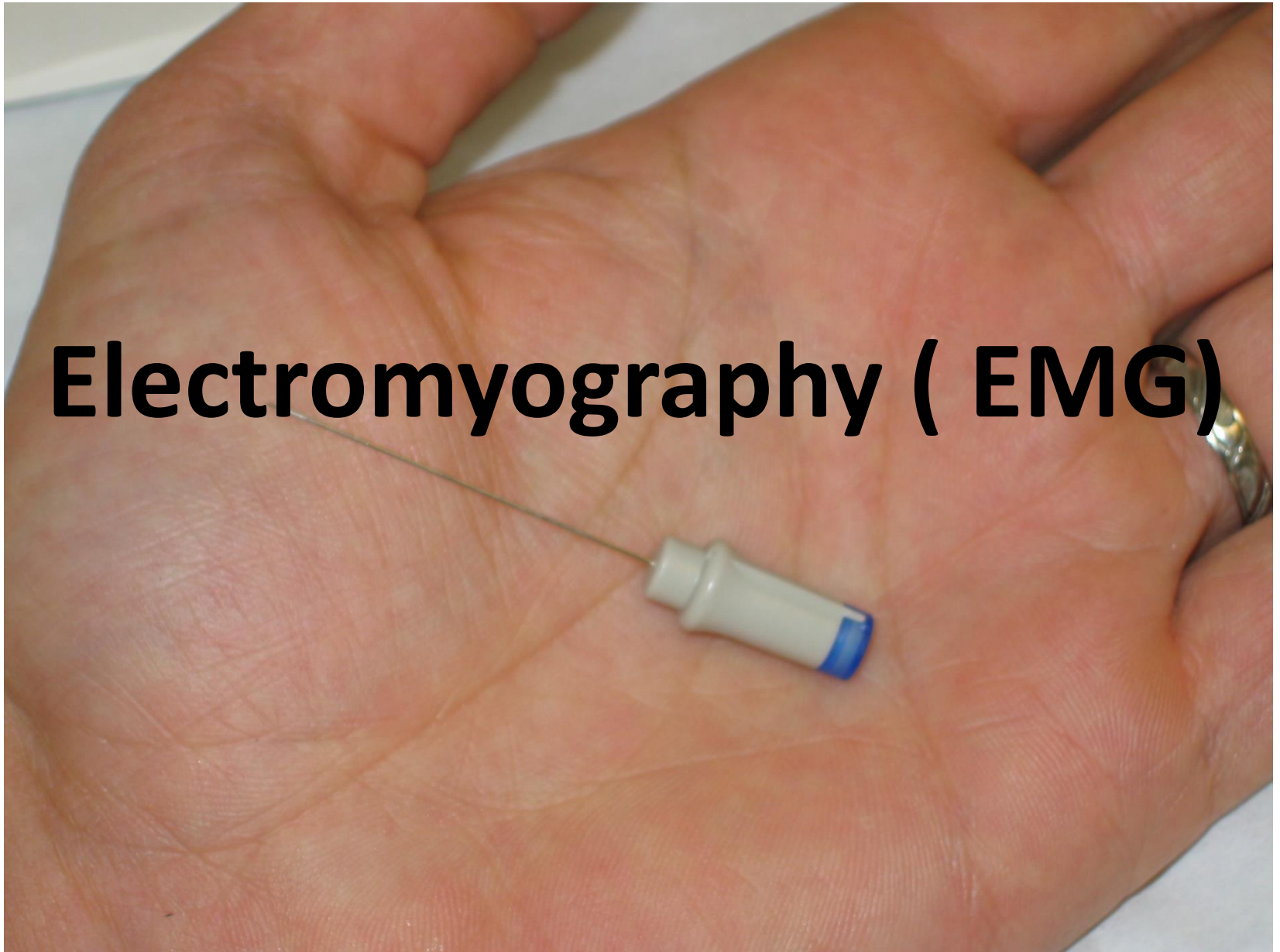
- Electromyography (EMG) is a technique for evaluating and recording physiologic properties of muscles at rest and while contracting.
- It's a recording of electrical activity of the muscle by inserting needle electrode in the belly of the muscles (needle emg) or by applying the surface electrodes (surface emg)
- The potentials recorded in needle emg are derived from motor units of the muscle, hence known as motor unit potentials (MUPs).
- Q: Define what is a " motor unit "?

- A motor unit is defined as one motor neuron and all of the muscle fibers it innervates.



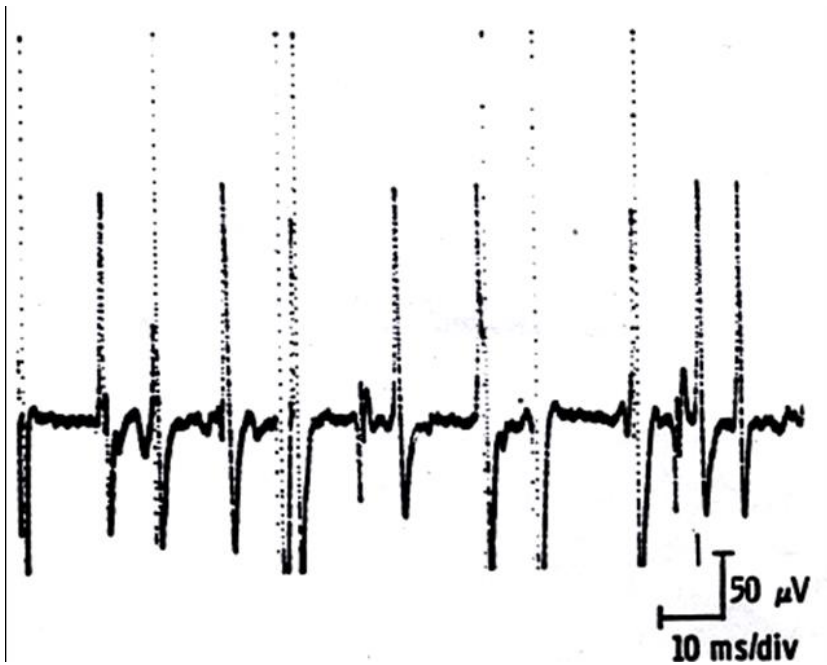

-
-

Electromyography (EMG)




MUPs (2)

During Mild Effort



During Moderate Effort \rightarrow note recruitment of additional motoneurons



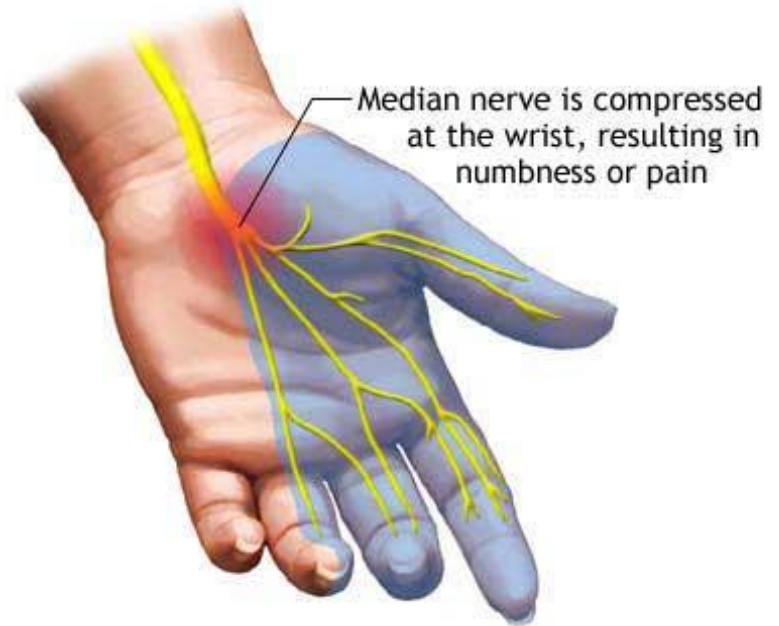
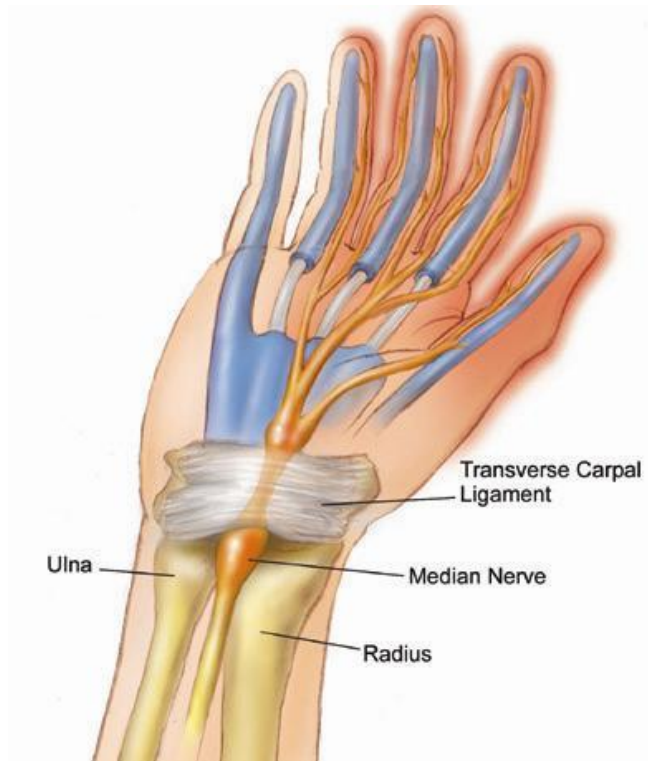During Full Voluntary Effort .
There is full recruitment (you can not see the baseline)

Examples of Abnormalities of MUPs

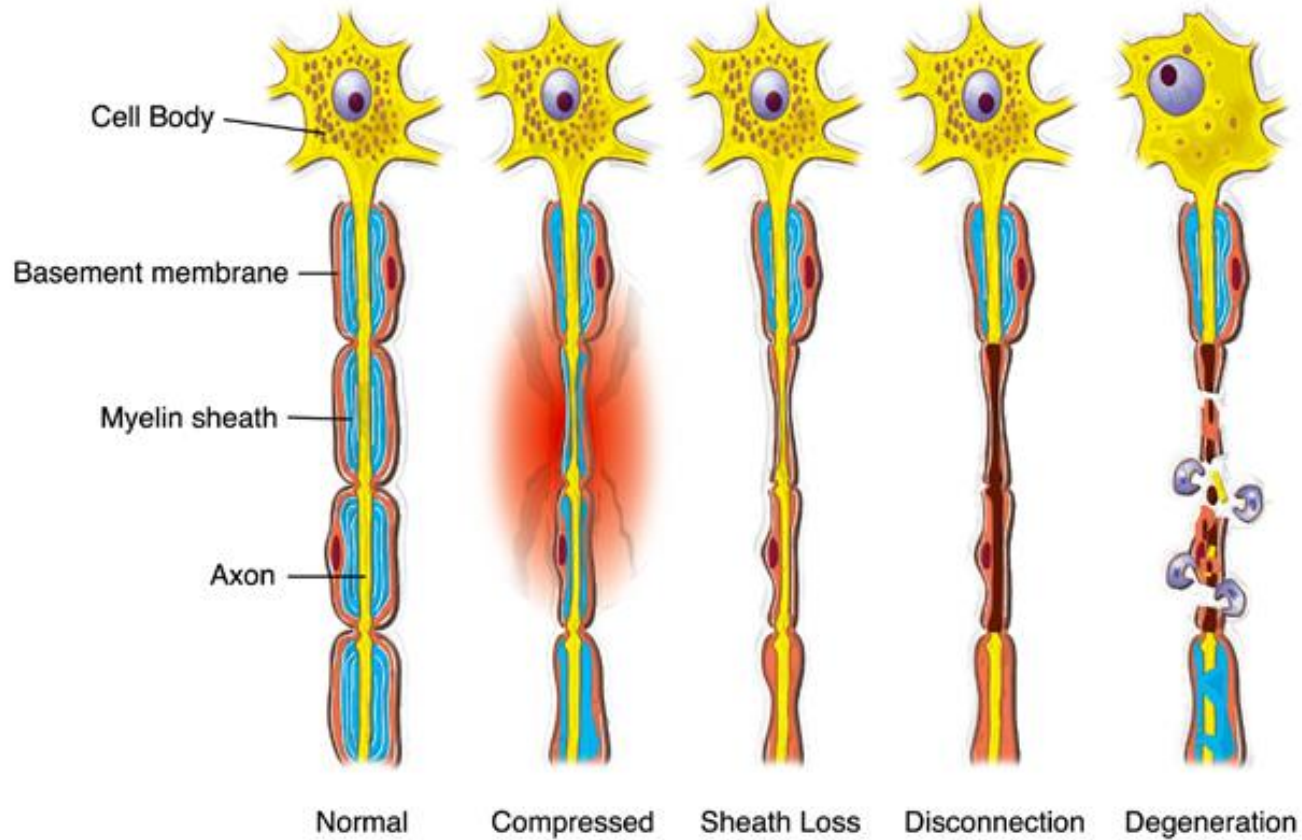
- In nerve diseases : Giant MUPs due to reinnervation $> 5 \text{ mV}$
- In muscle disease : Small MUPs $< 300 \mu\text{V}$

Clinical Application

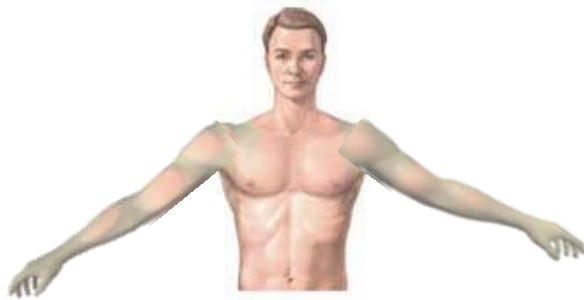Carpal tunnel syndrome



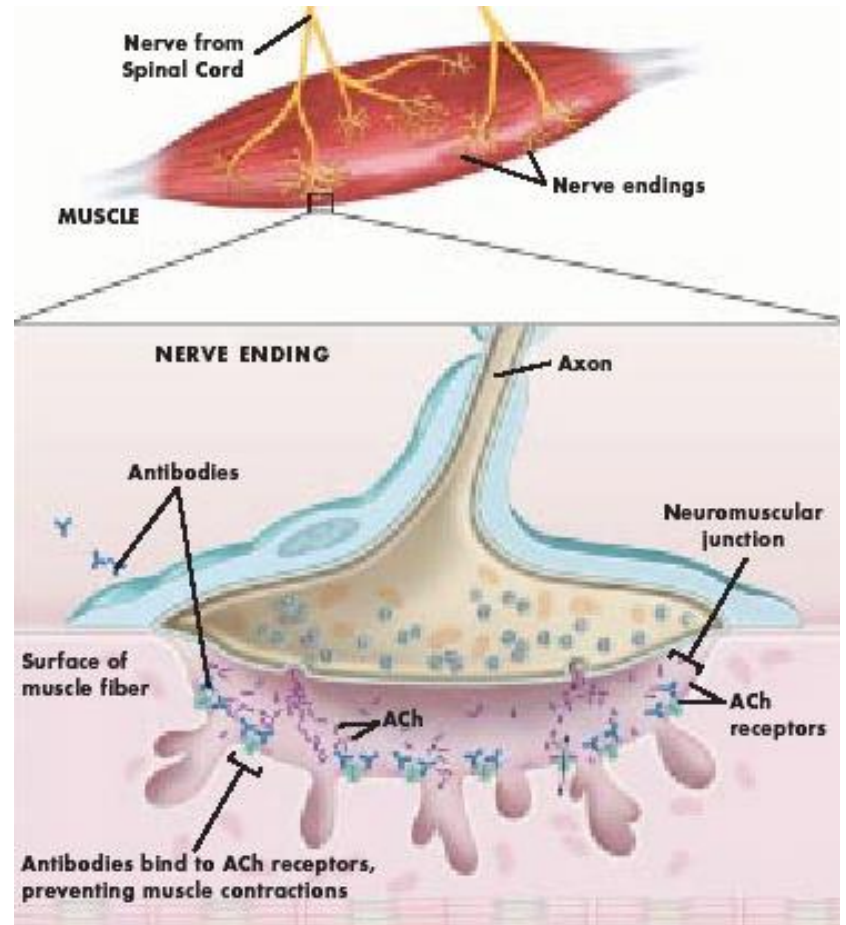
Nerve injury



Myasthenia gravis



Arms raised to fatigue the muscles



Thanks