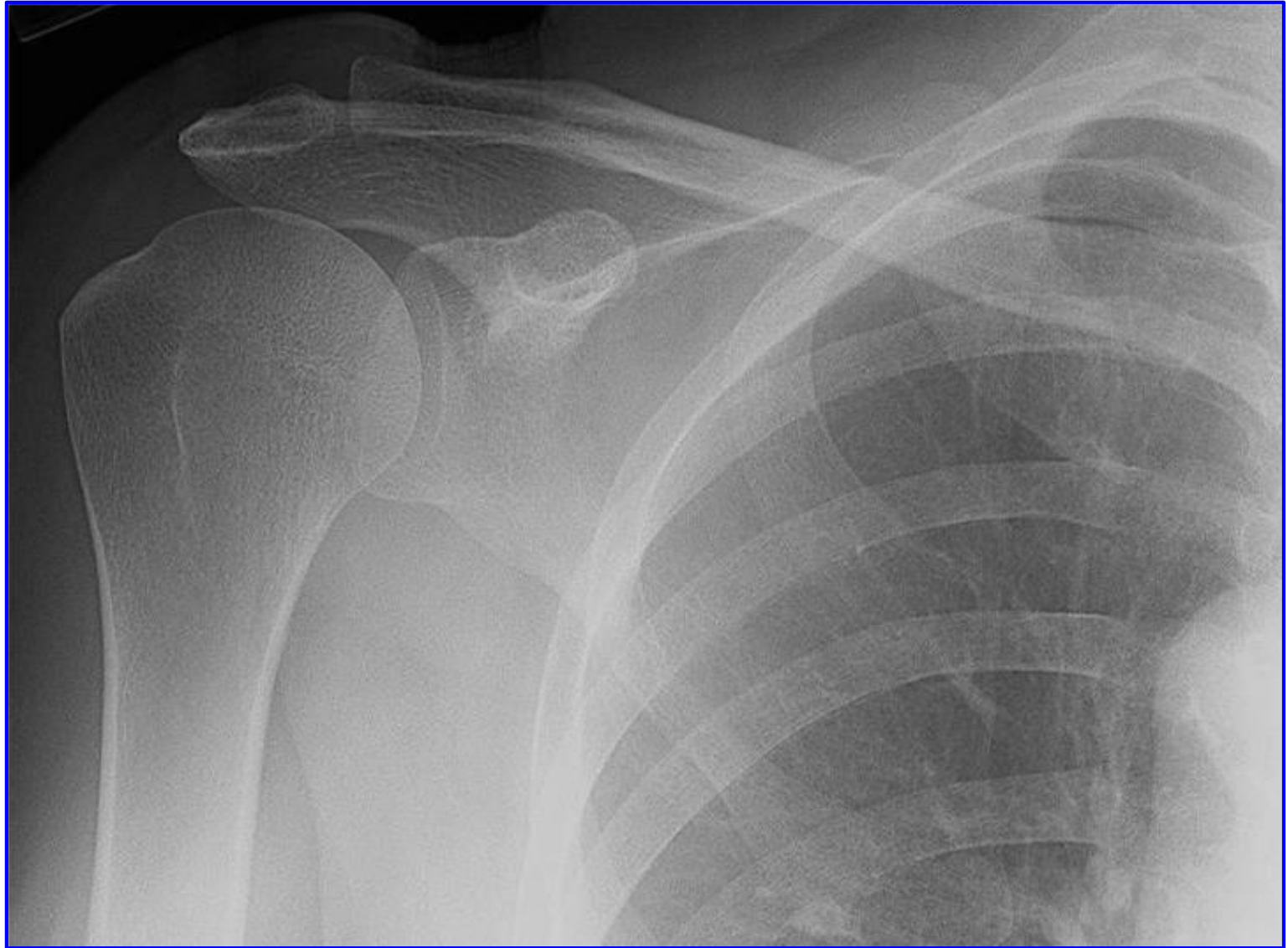


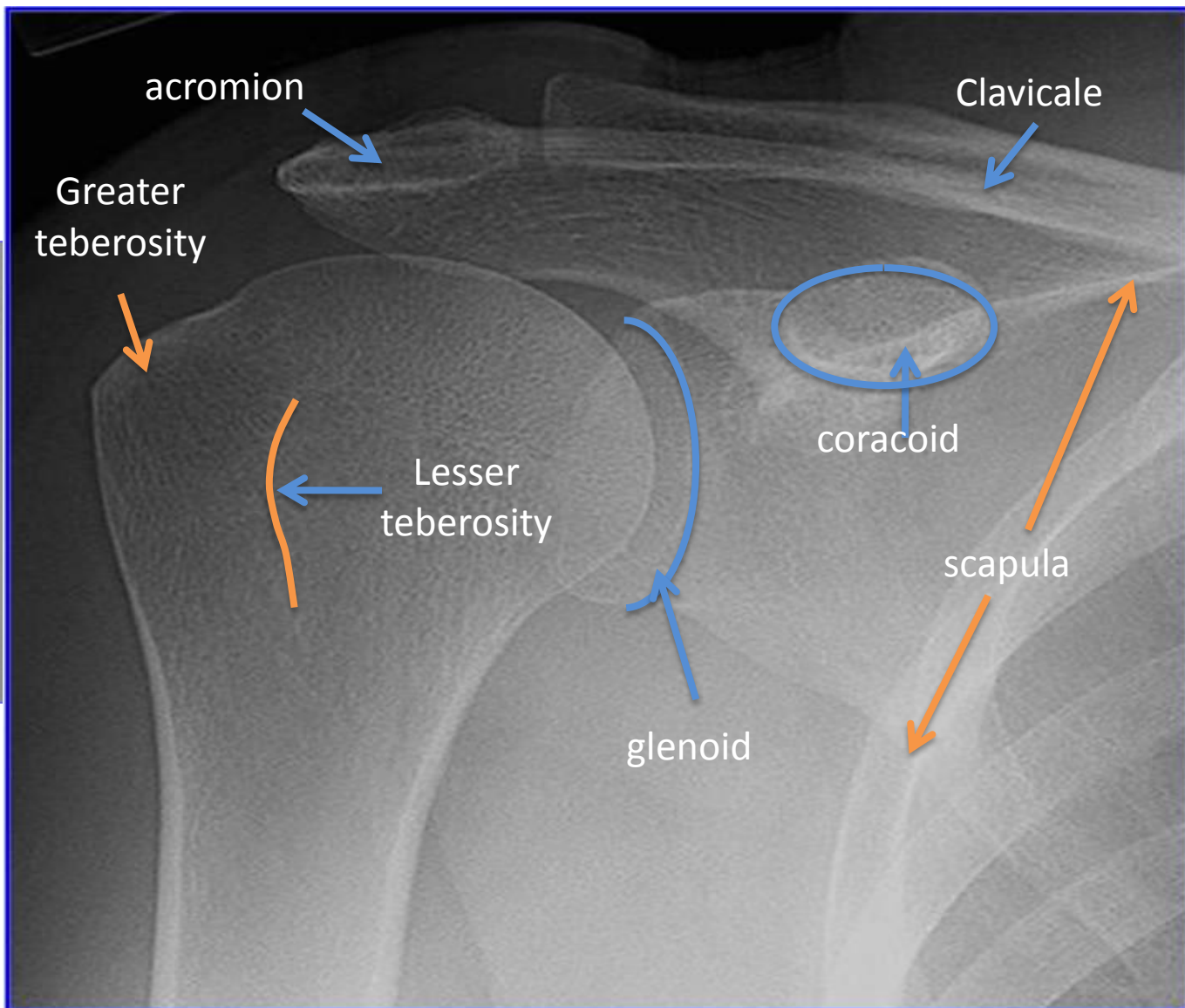
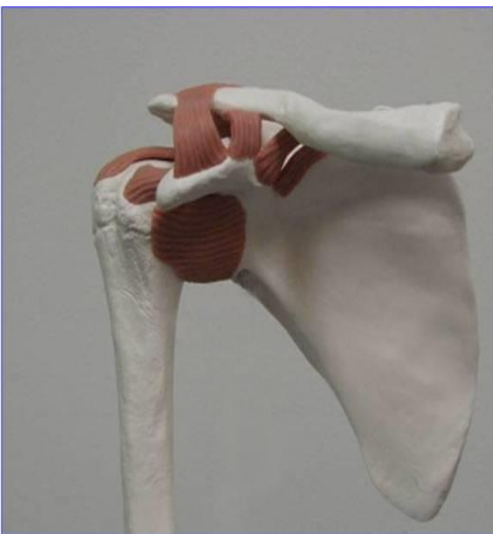# RADIOLOGY ANATOMY OF UPPER LIMB

Dr. Abdulrahman Alhawas

SHOULDER

X-RAY





acromion

Clavicale

Greater  
teberosity

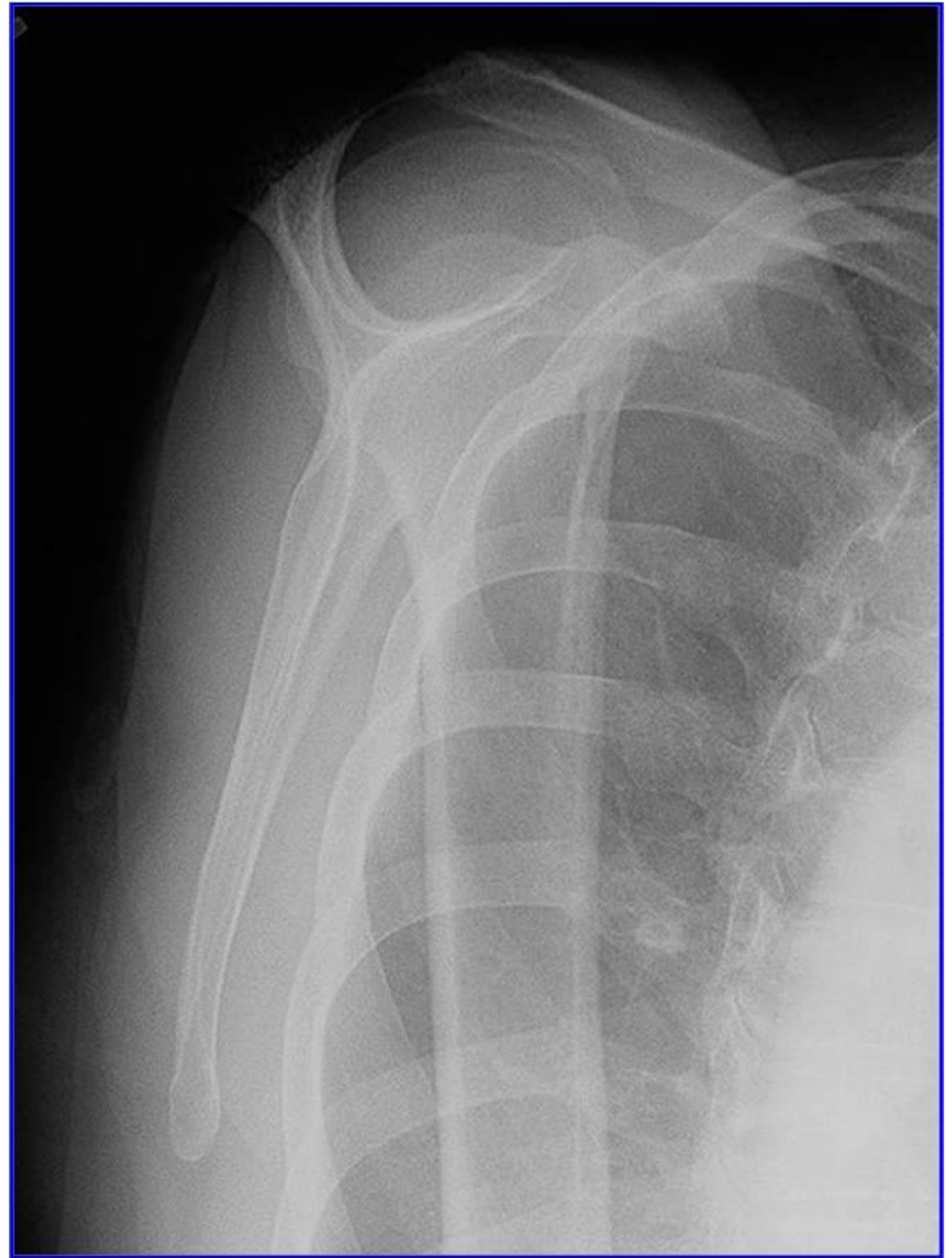

coracoid

Lesser  
teberosity

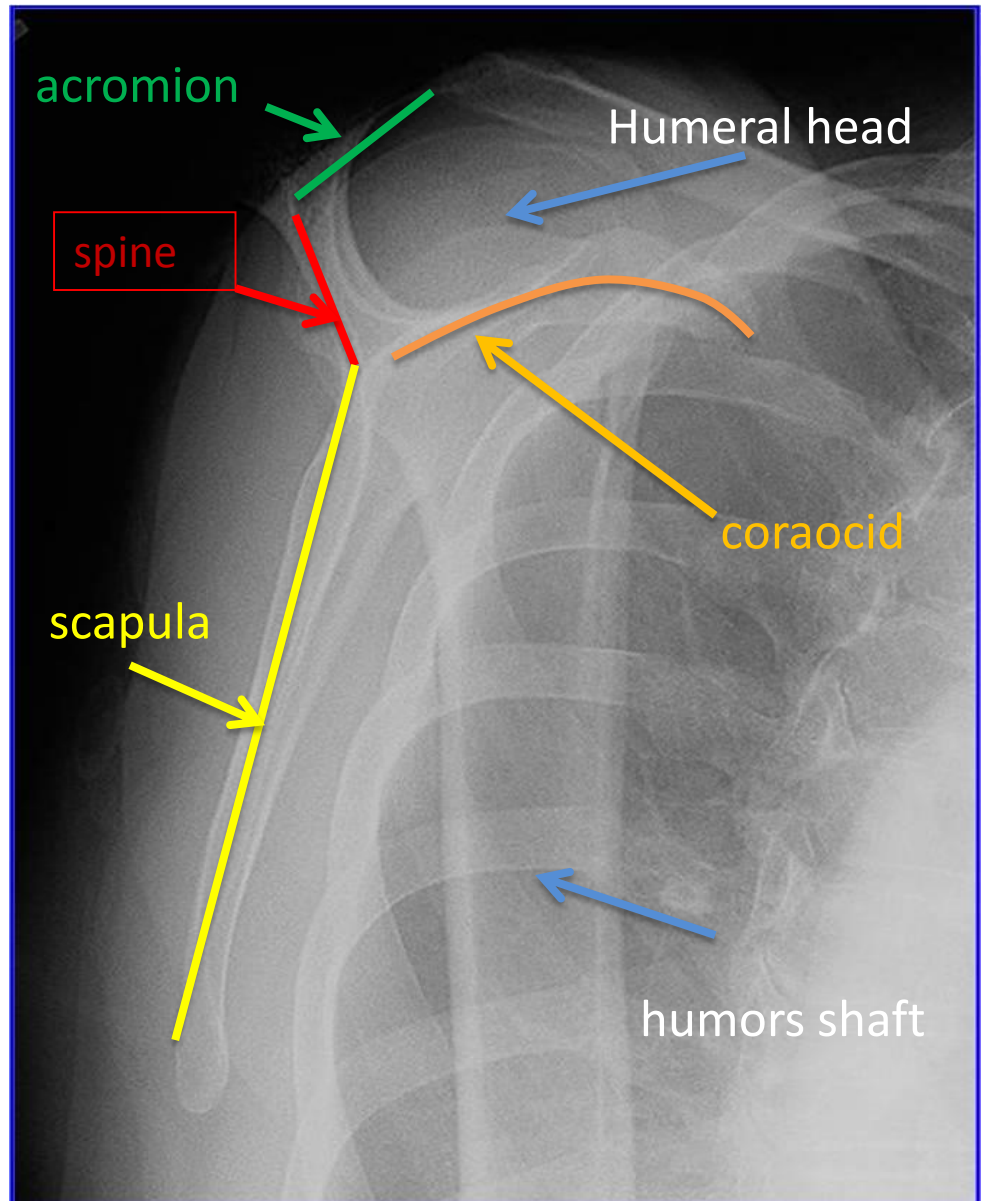
scapula

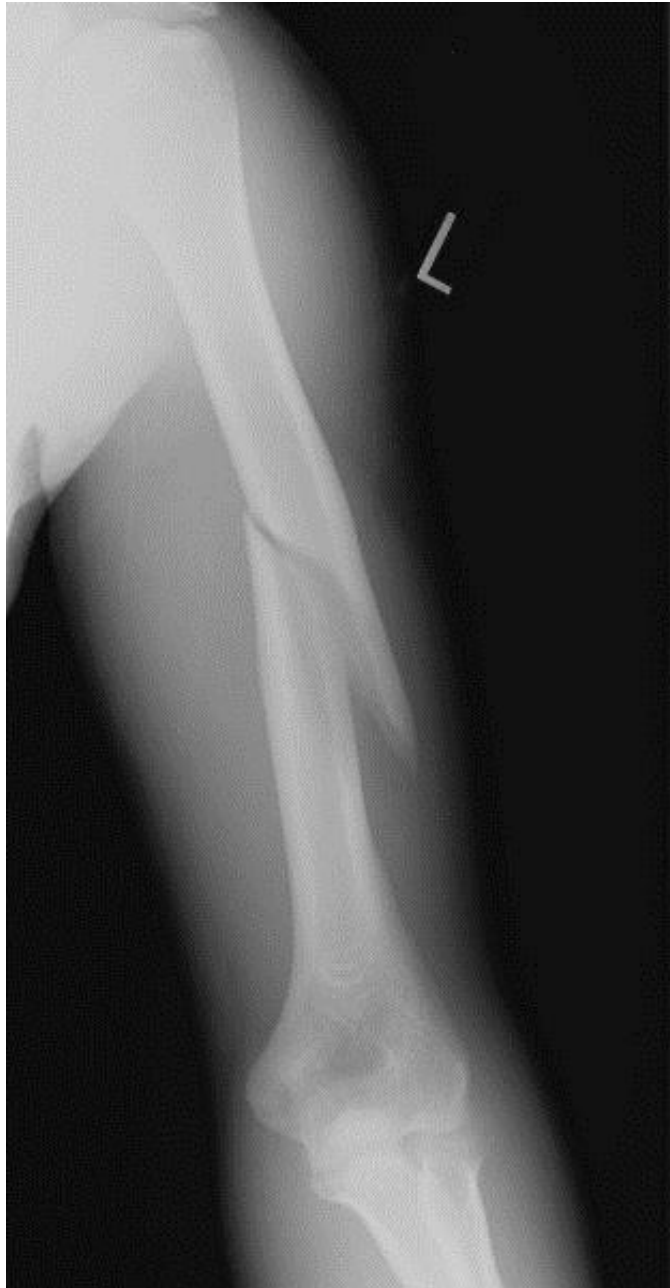glenoid

# Y view



# Y view

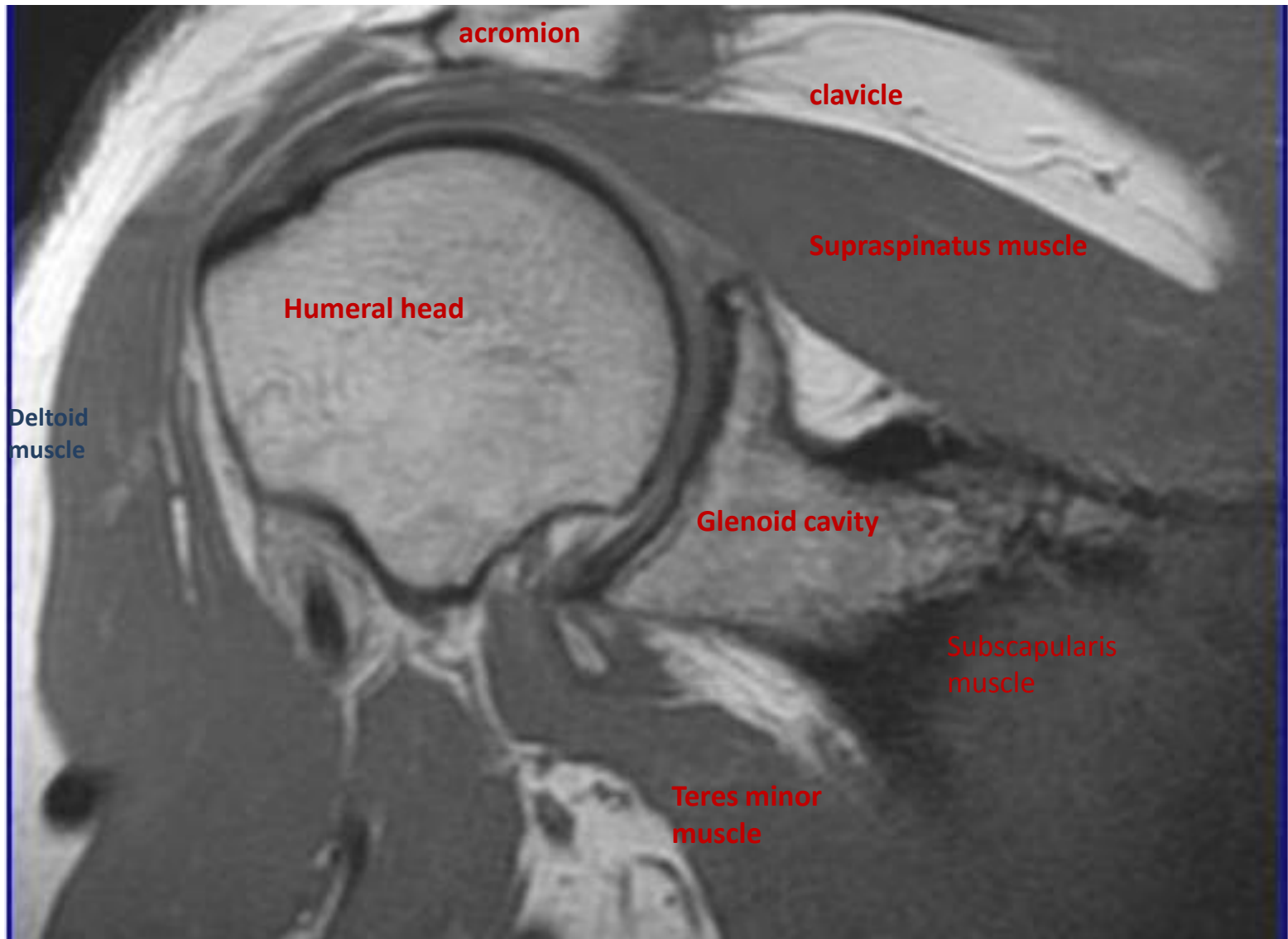




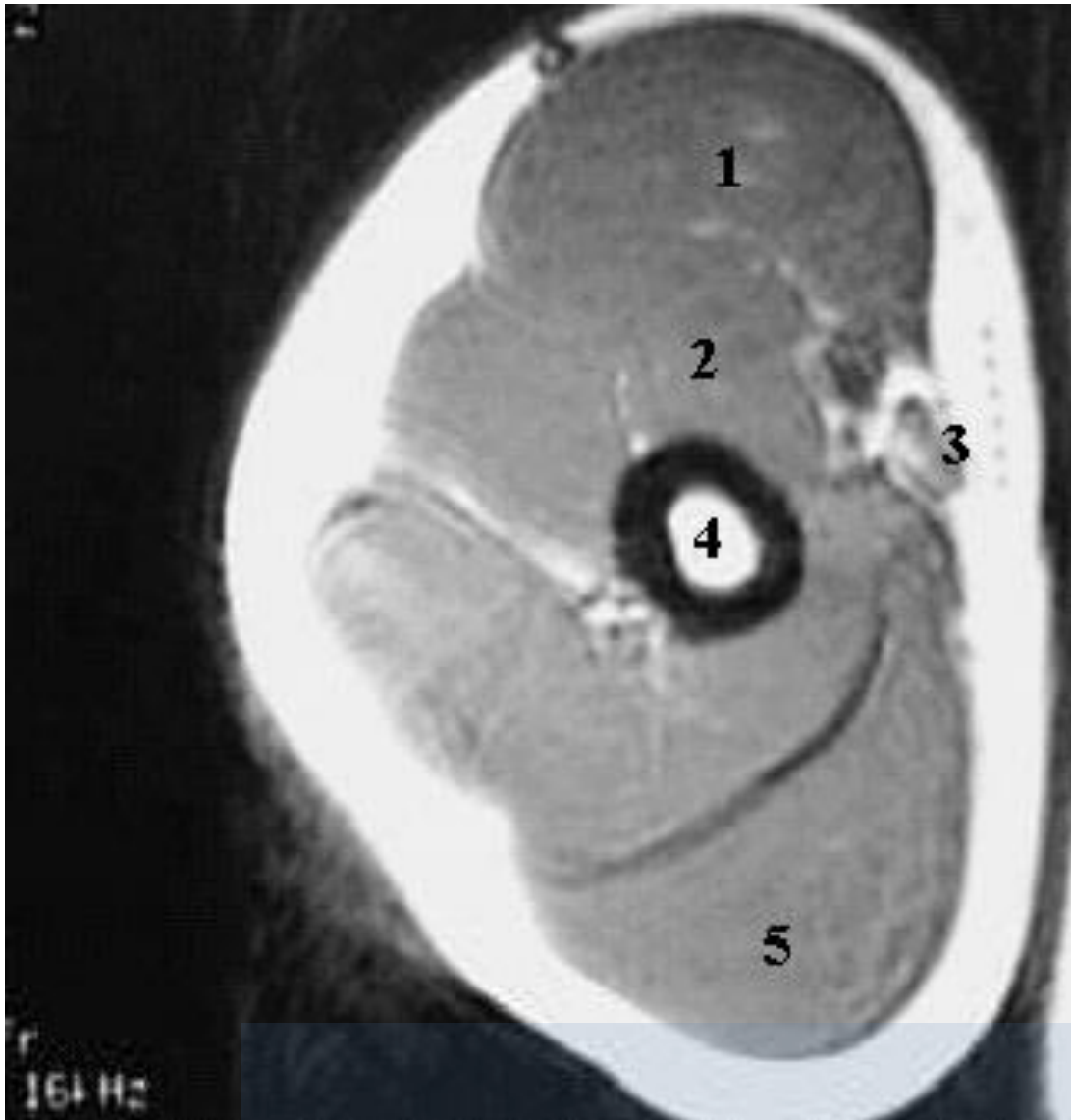
Humerus  
fracture



**MRI**



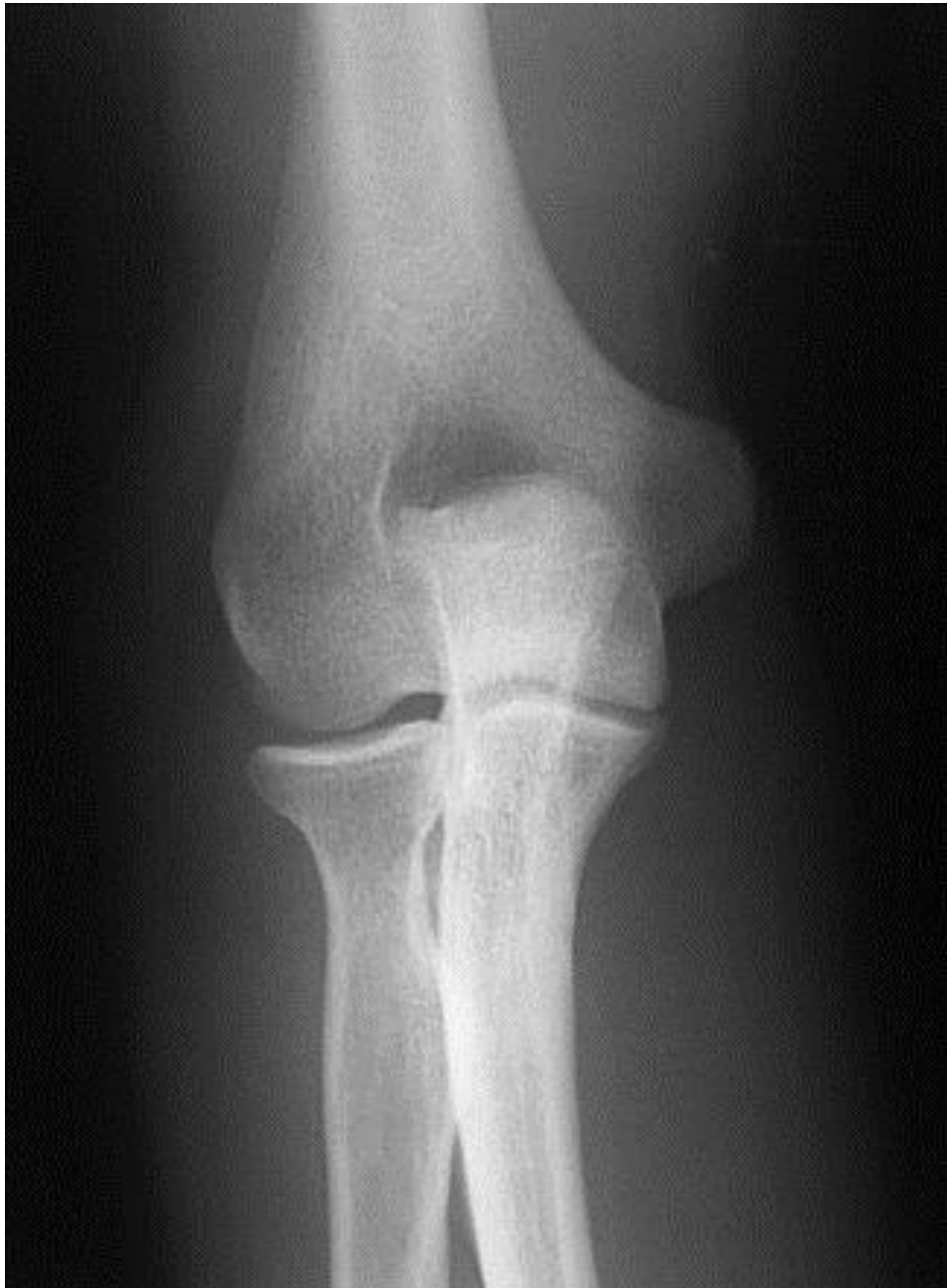**ARM MRI**

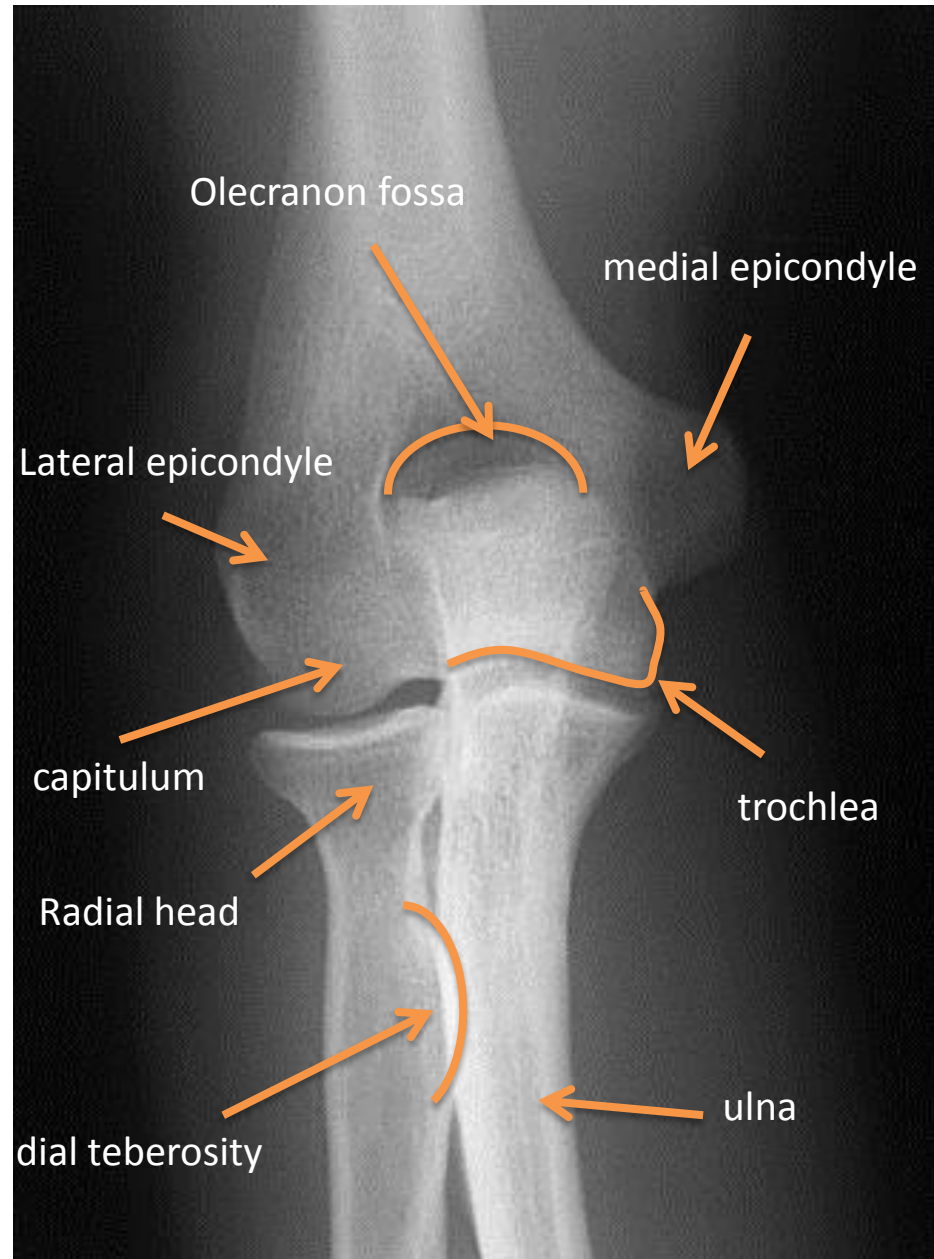
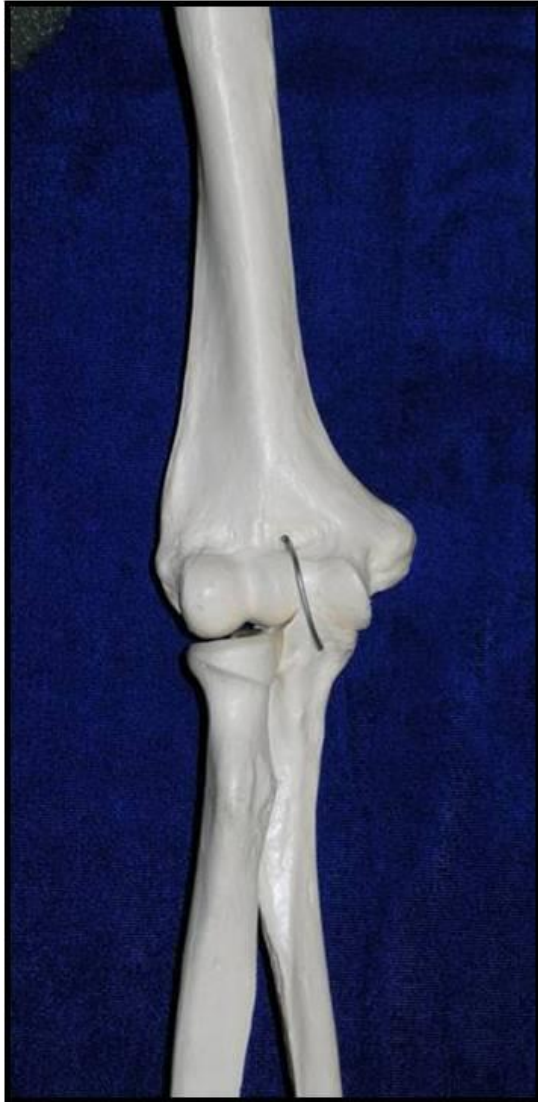

- 1-Biceps Muscle.
- 2-Brachialis Muscle.
- 3-Brachial Artery.
- 4-Humerus.
- 5-Triceps Muscle

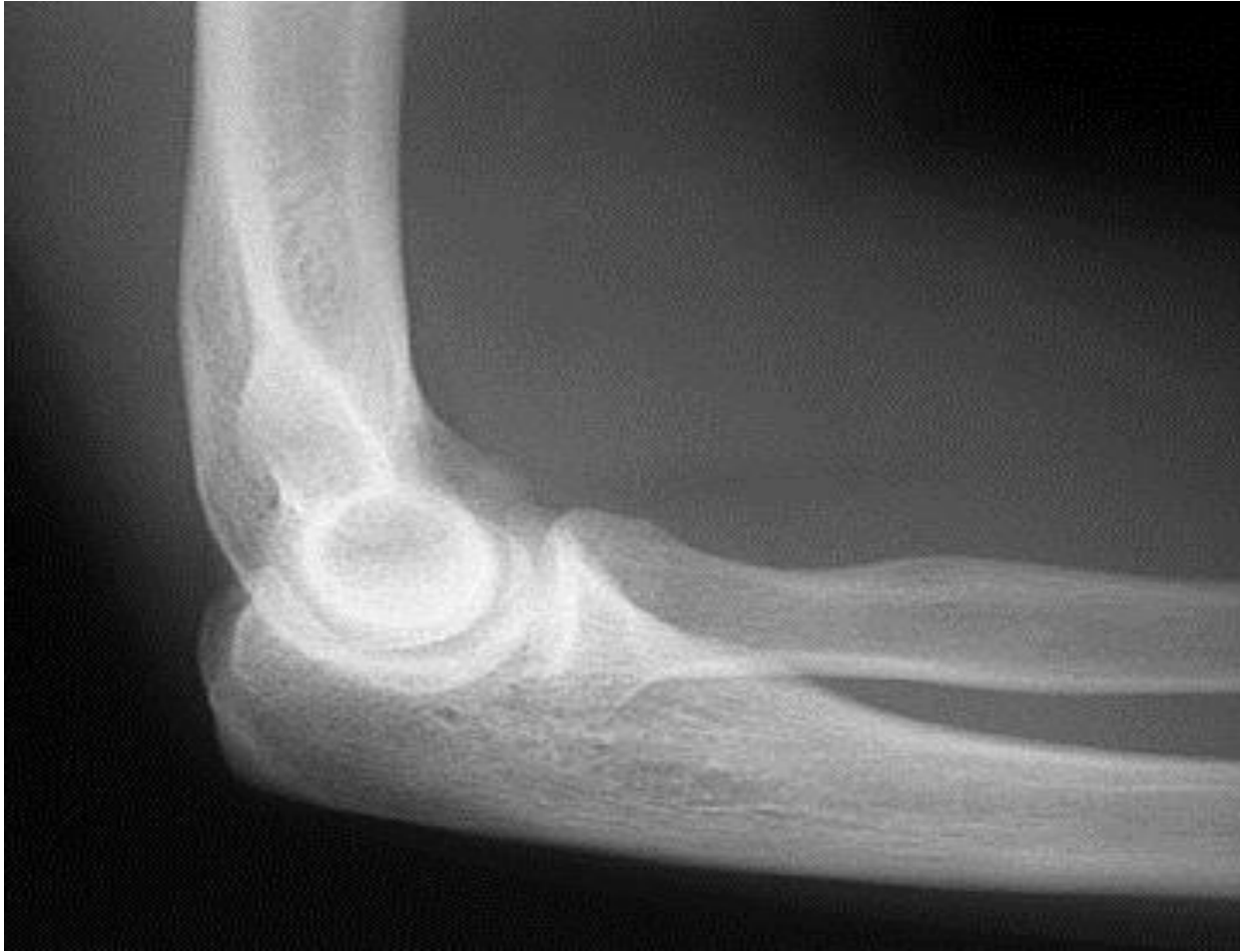**ELBOW**

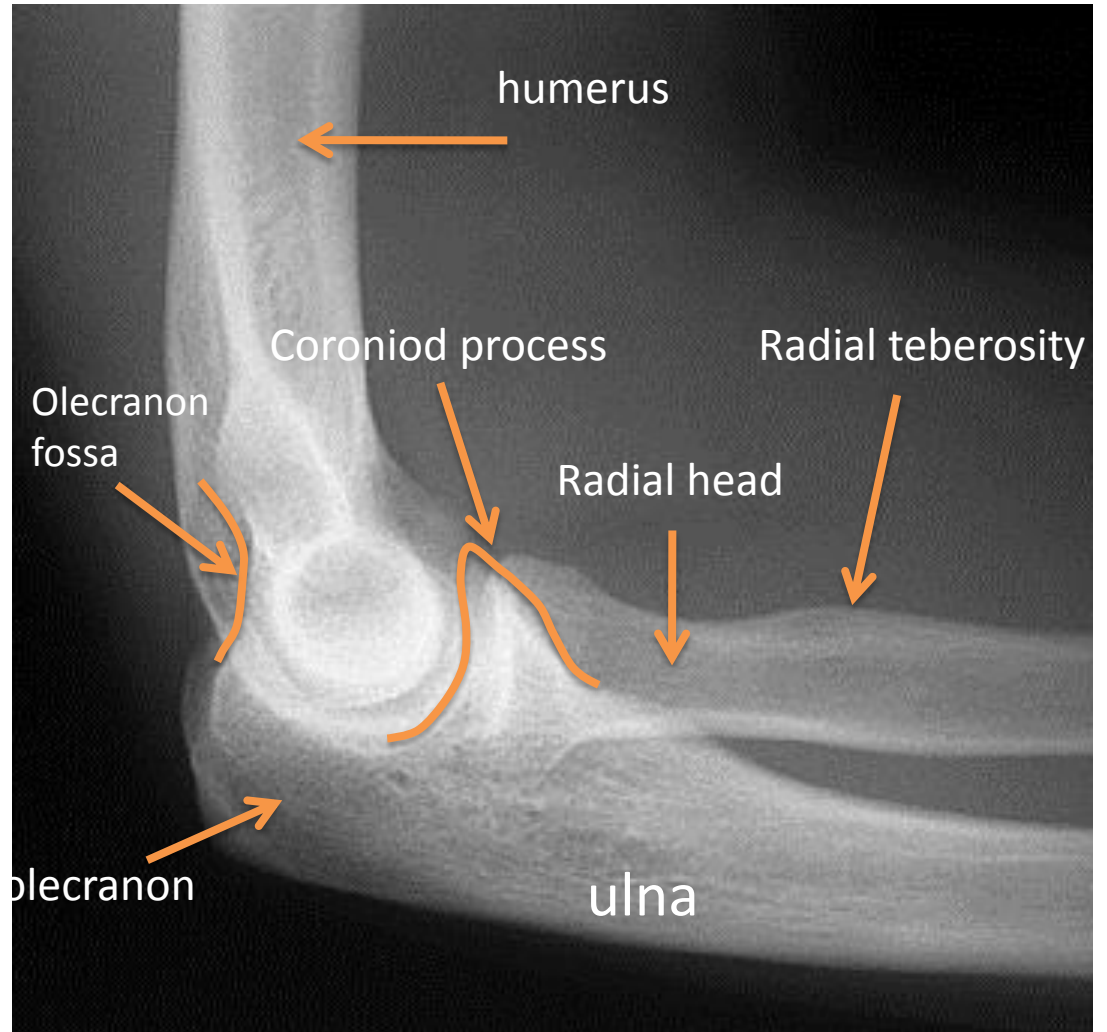
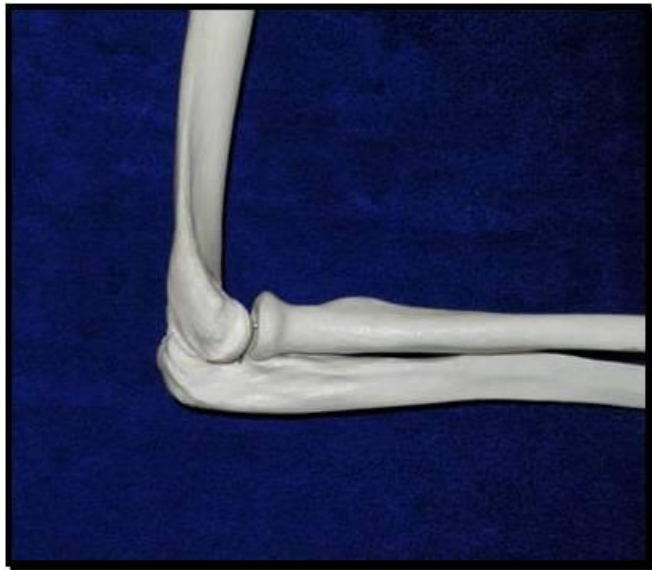**X RAY**



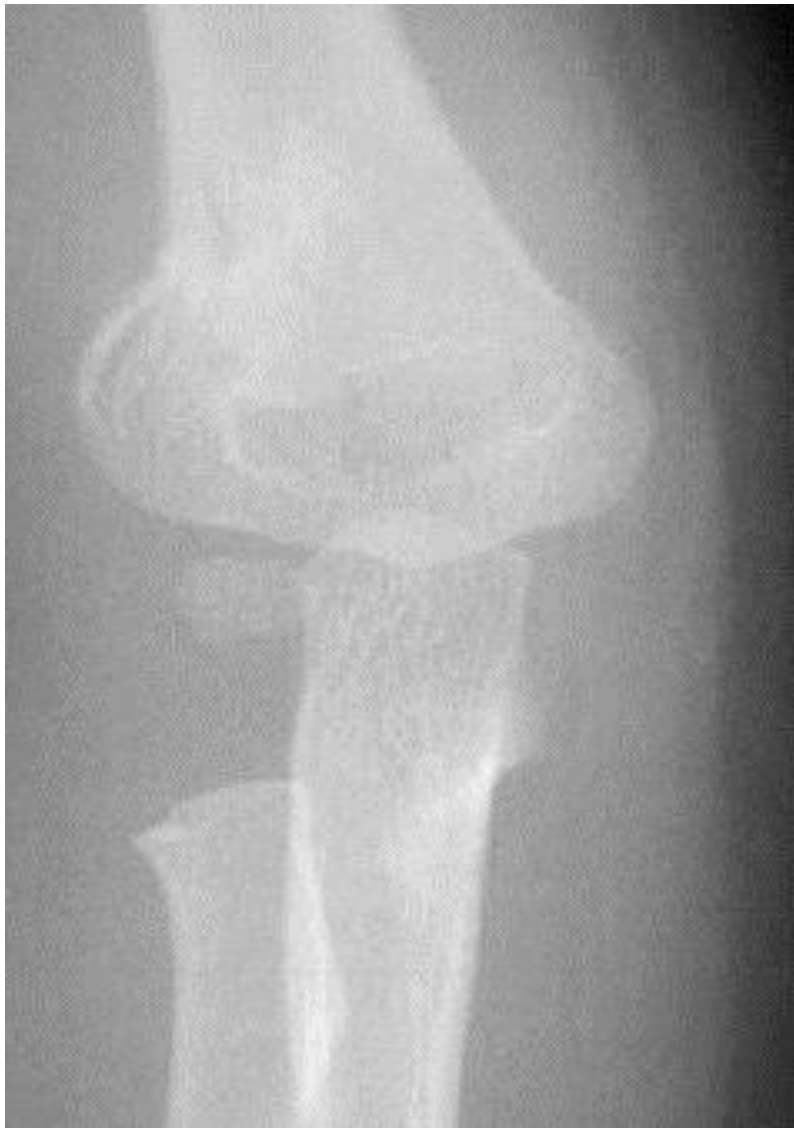




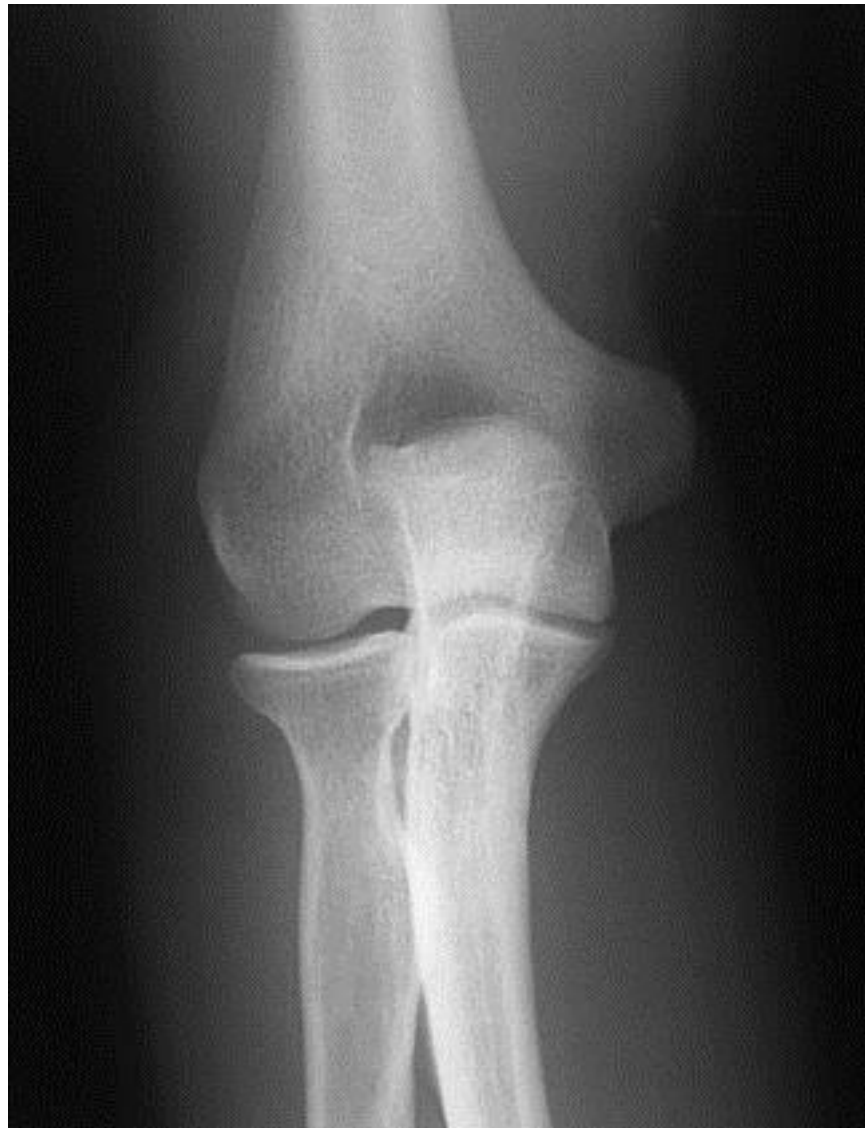


**CHILD**

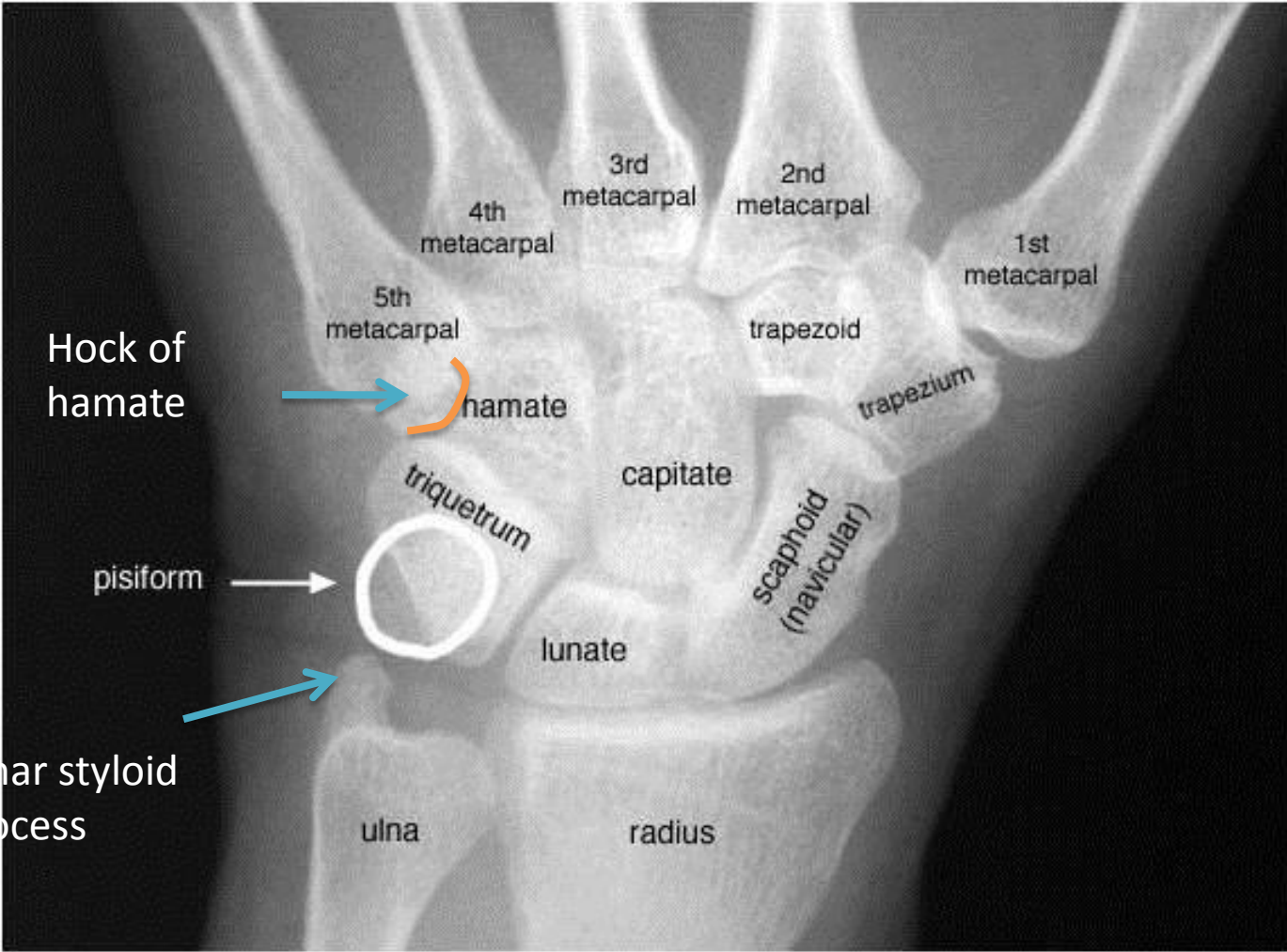


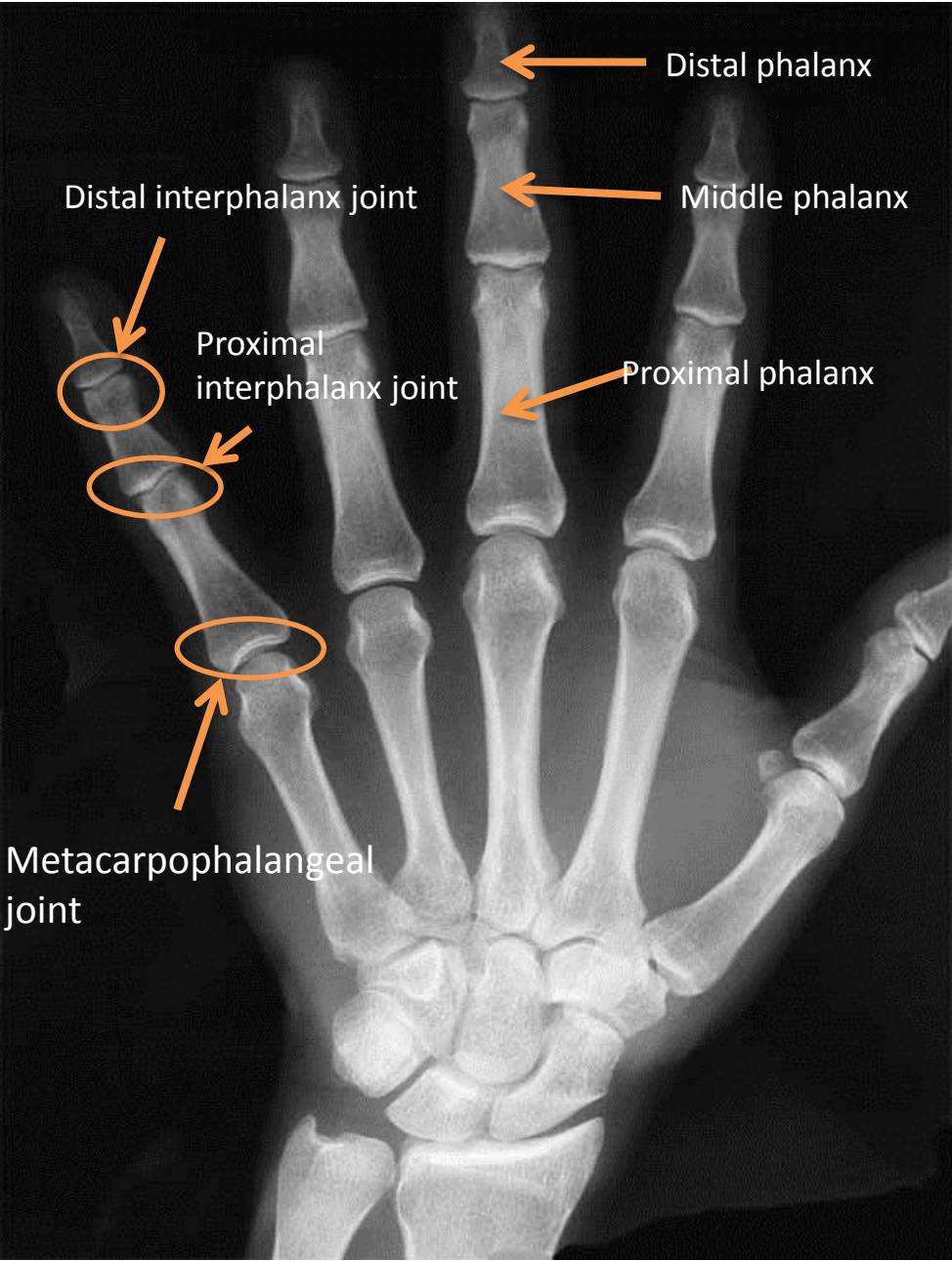
**ADULT**



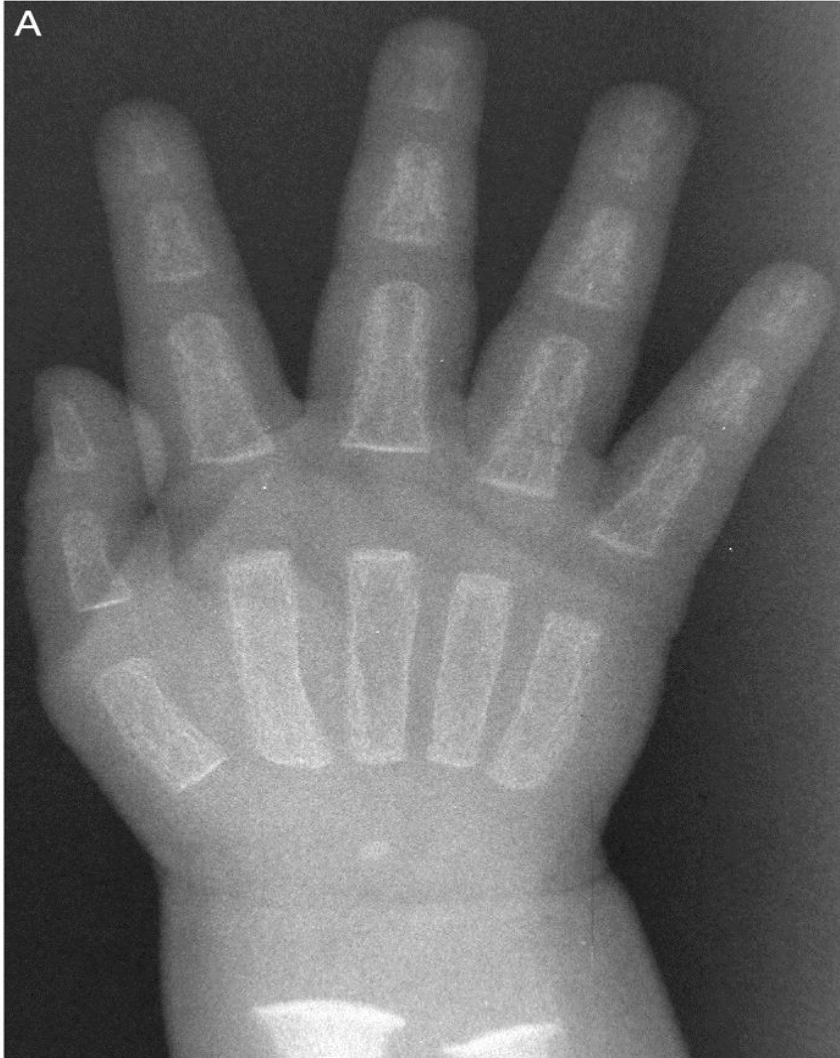**HAND**

**X RAY**

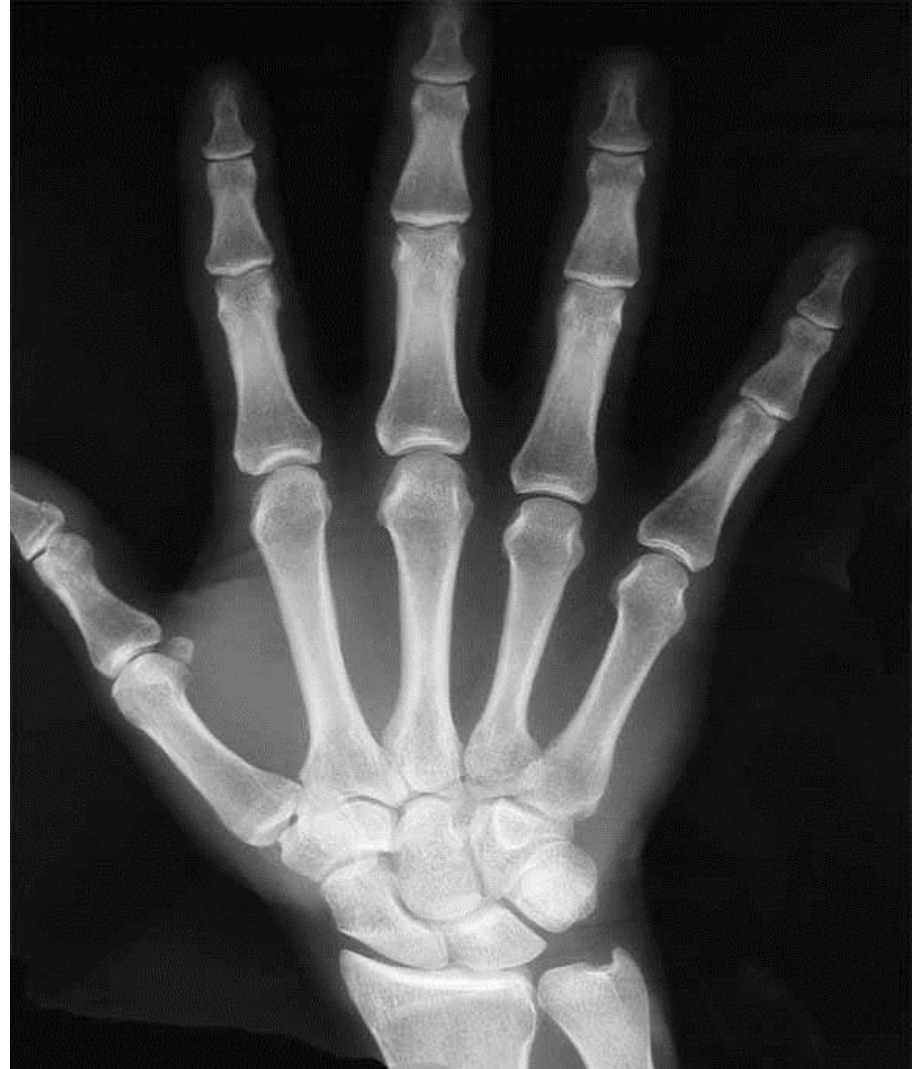



**CHILD**



**ADULT**



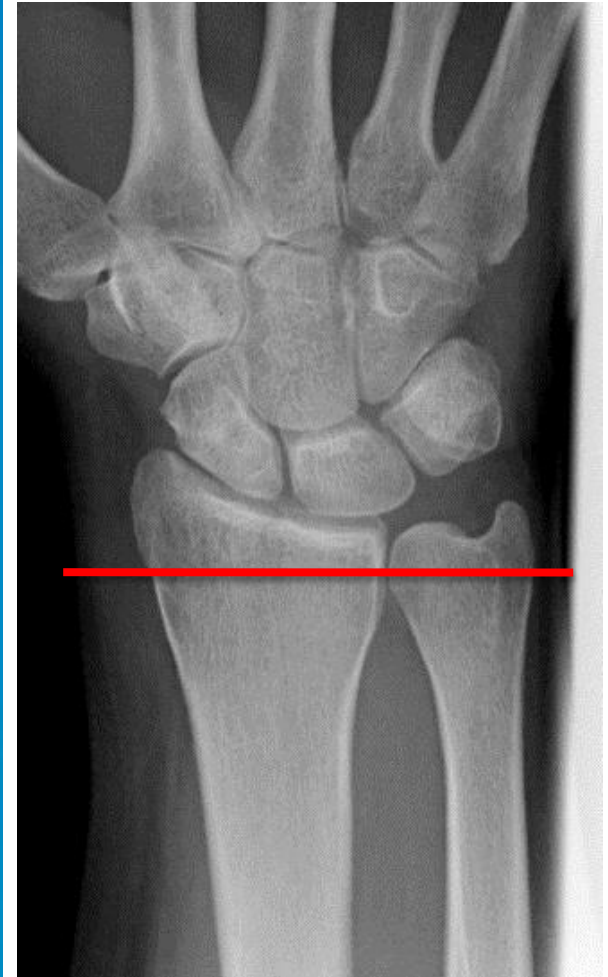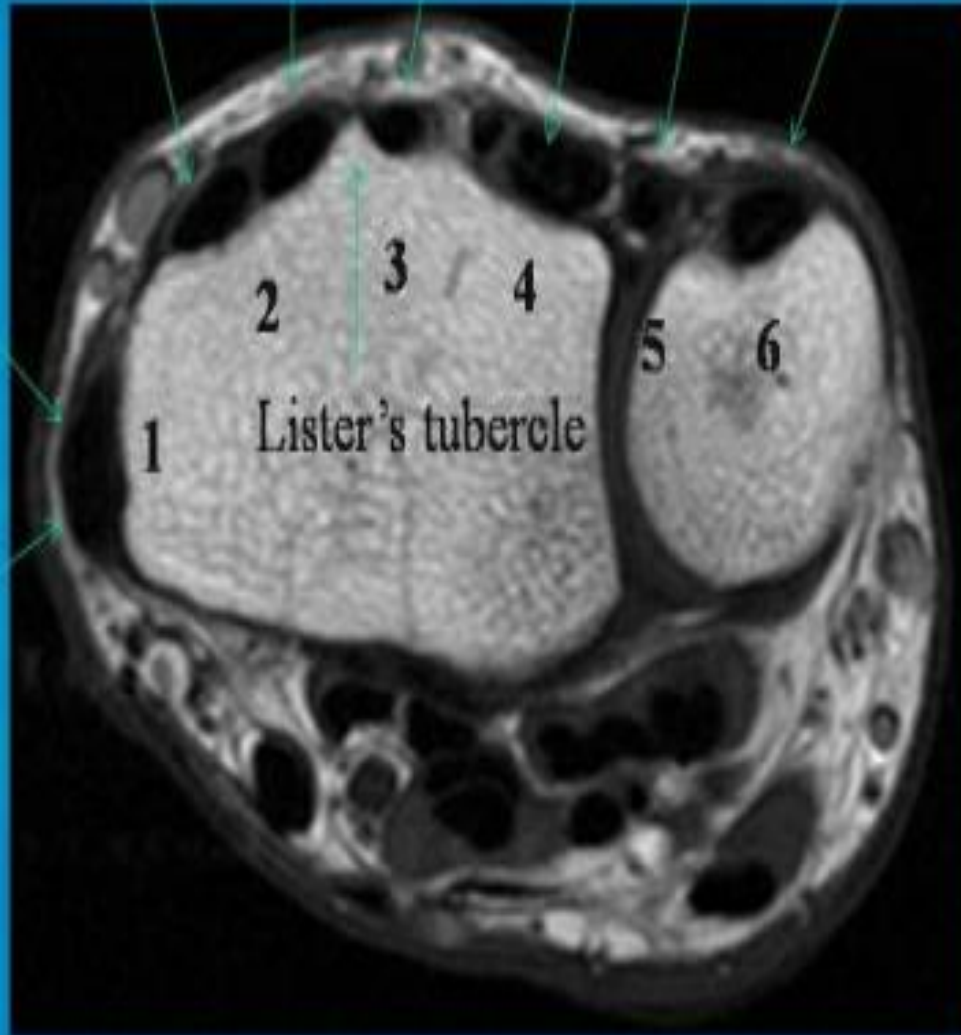


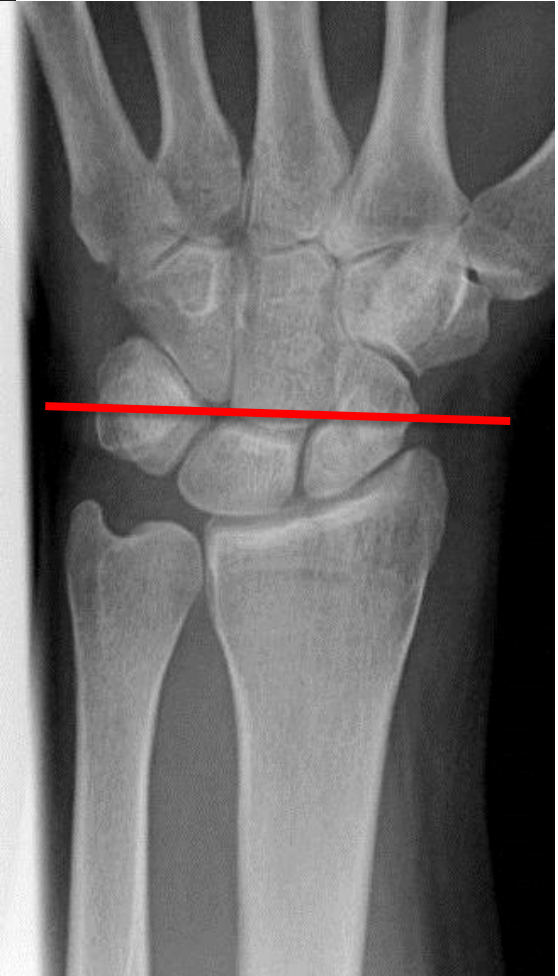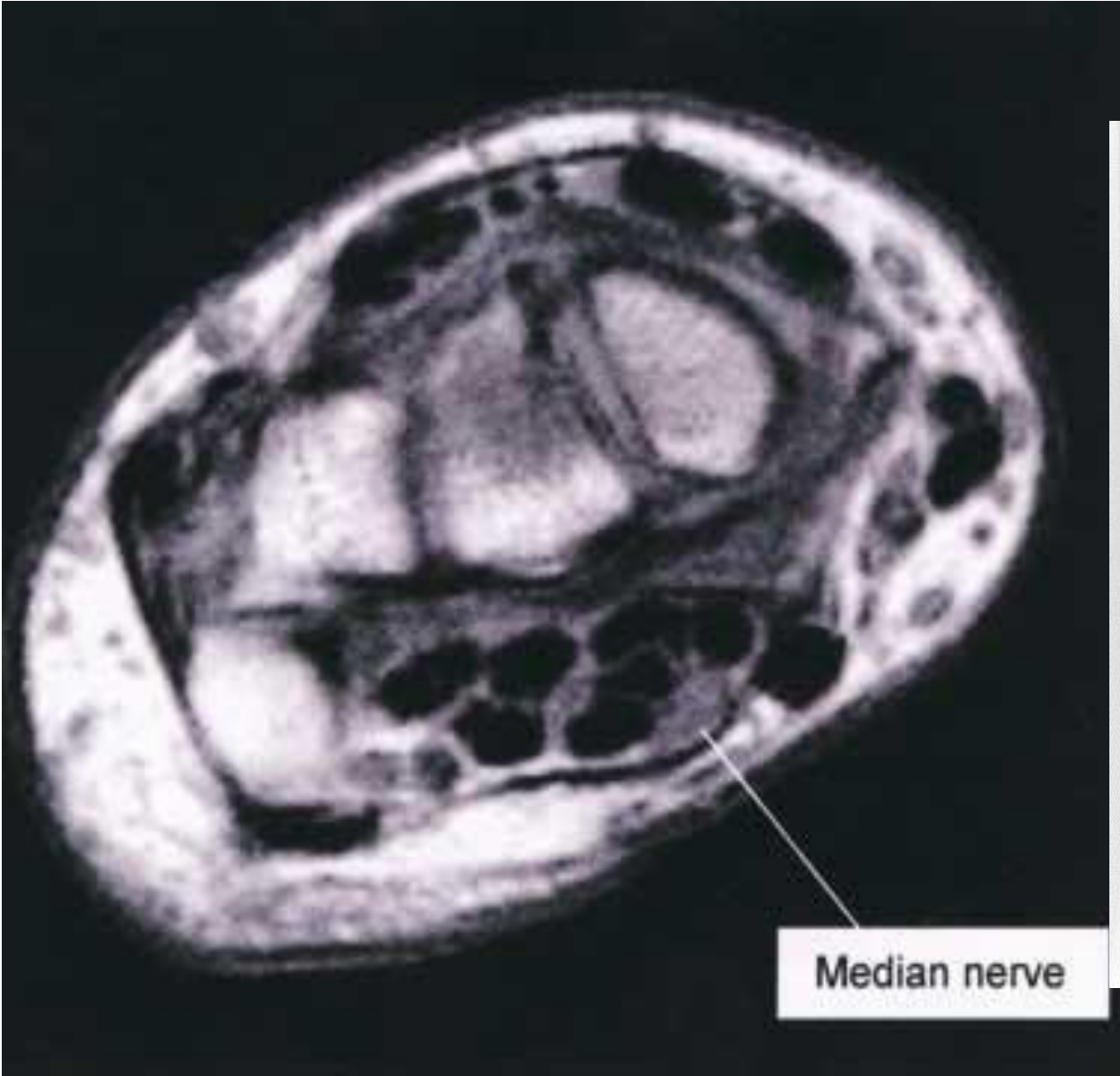
MRI

ECRL ECRB EPL ED EDM EU

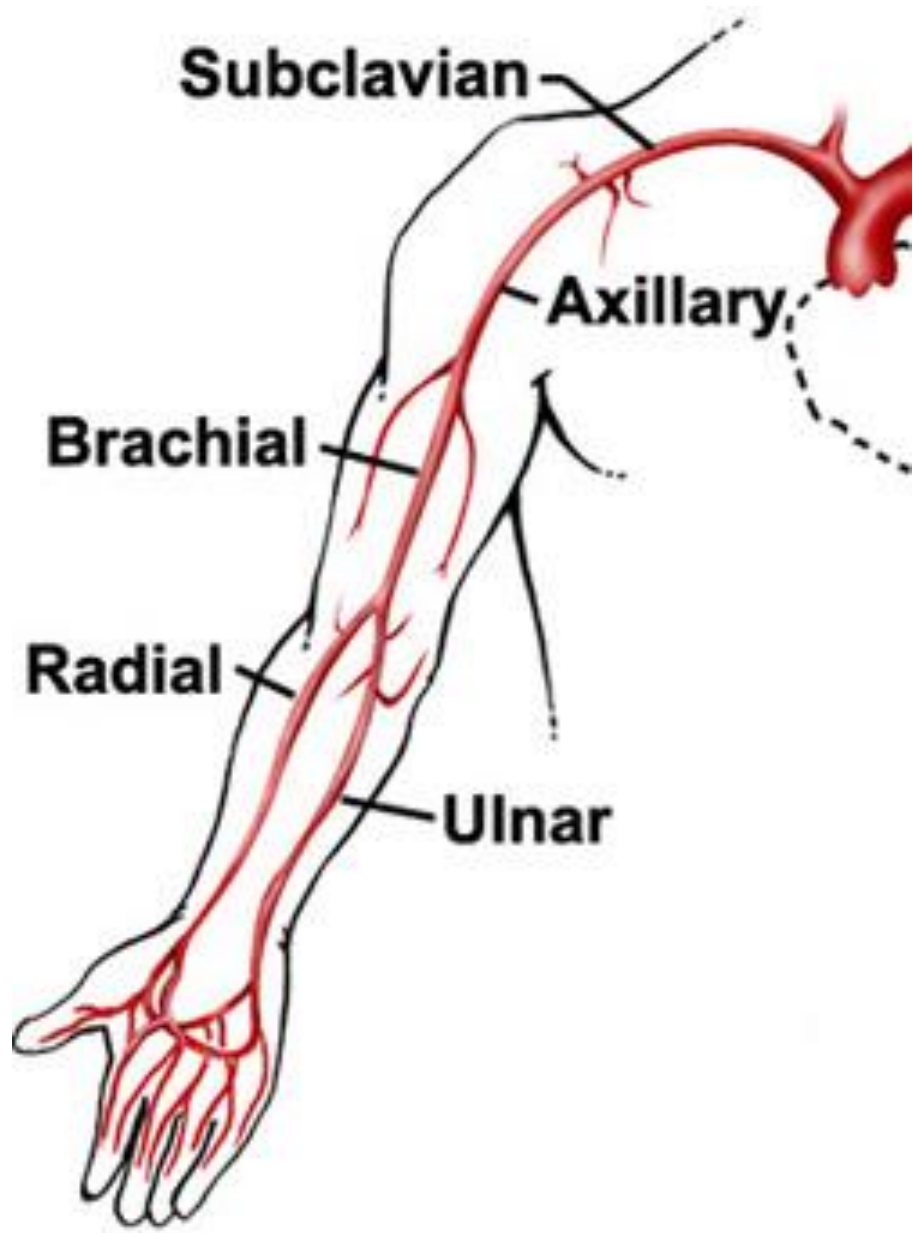
EPB

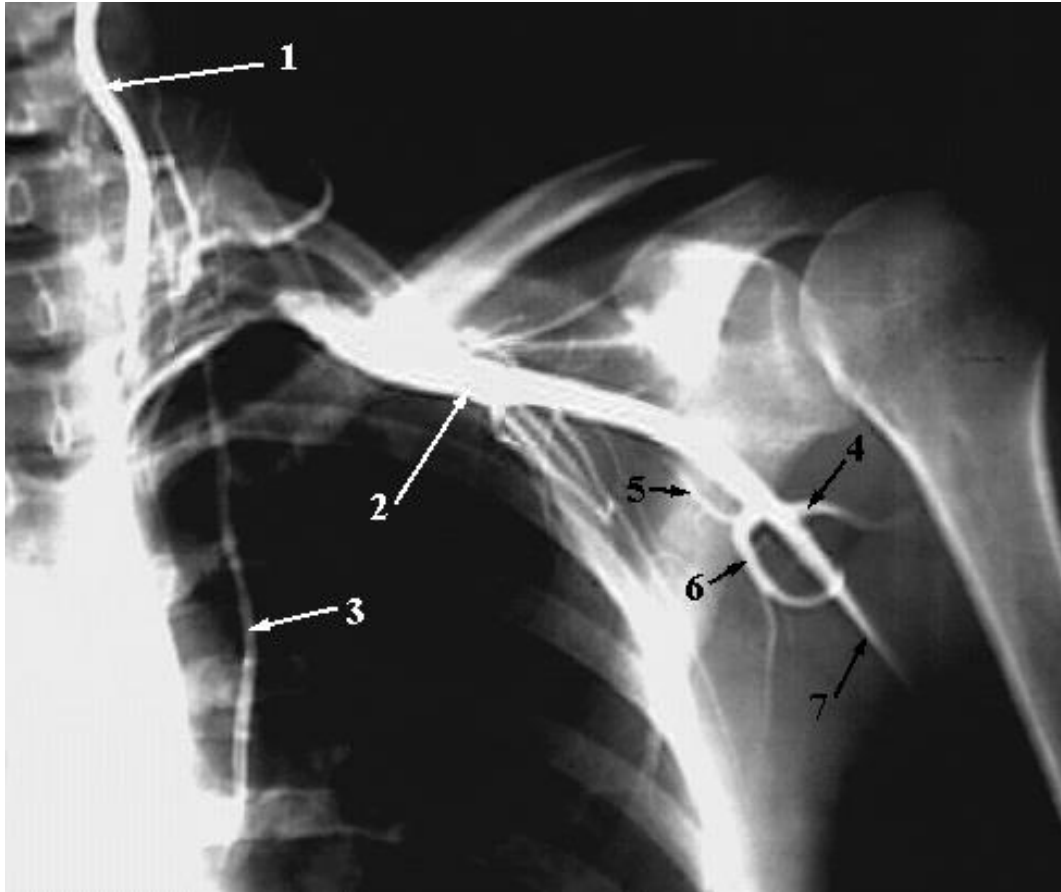APL



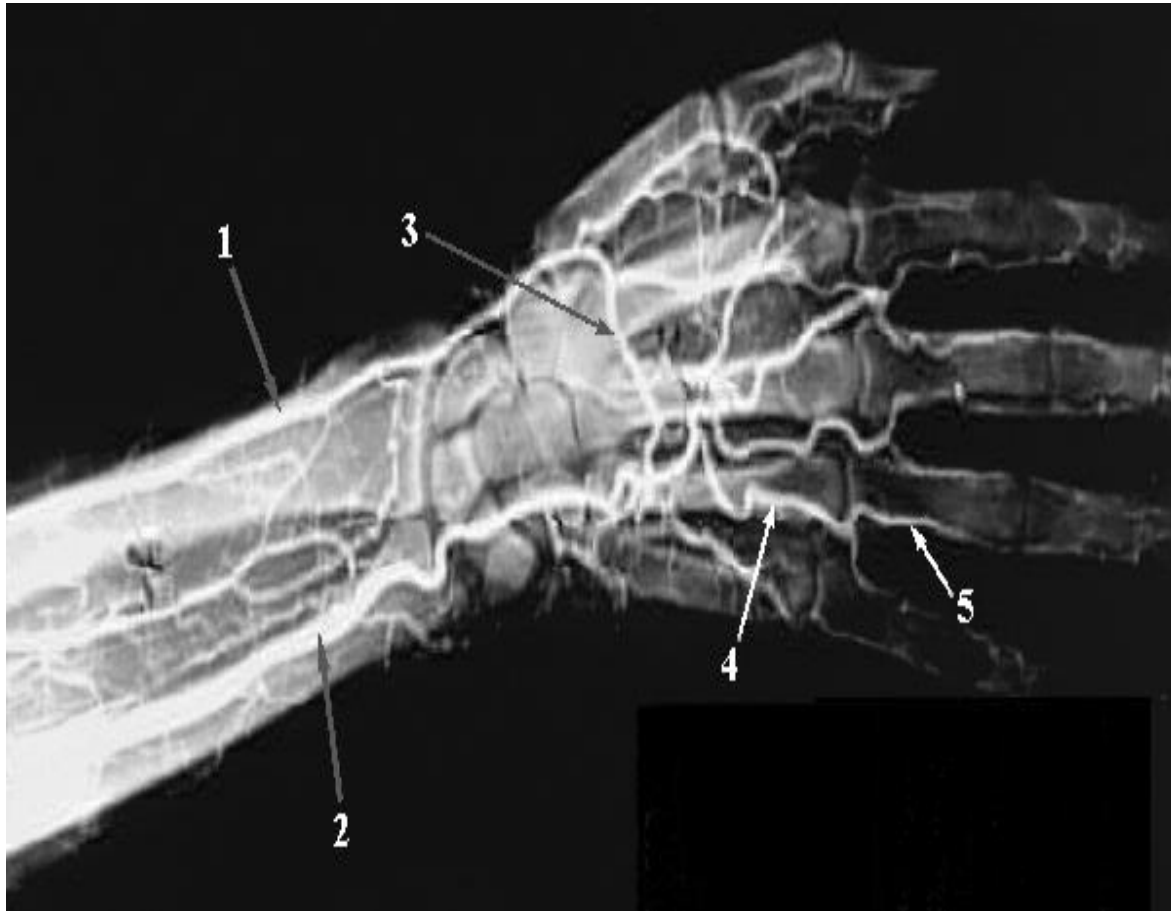

# UPPER LIMB VESSELS



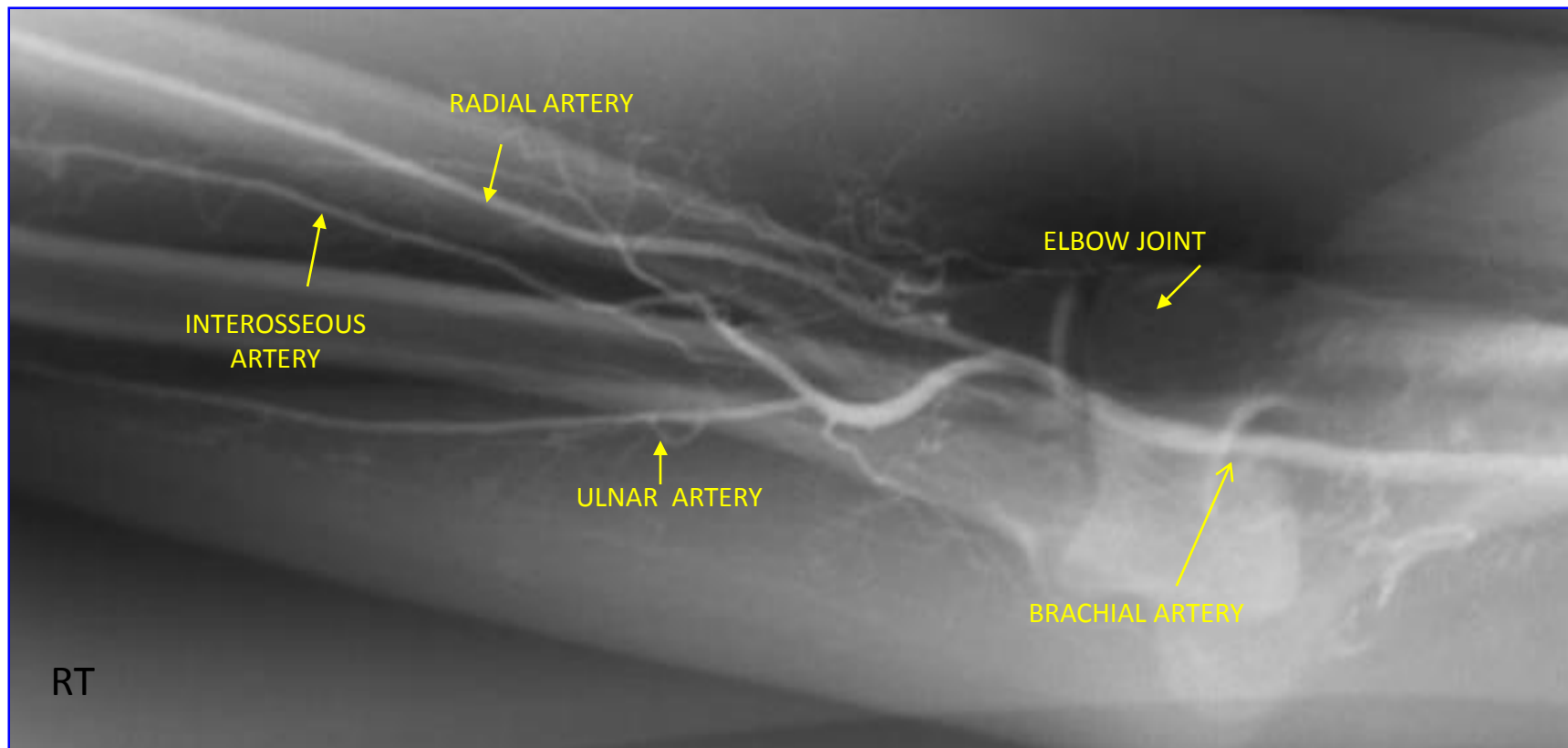


- 1-Vertebral Artery.
- 2-Axillary Artery.
- 3-Internal Thoracic Artery.
- 4-Posterior Humeral Circumflex Artery.
- 5-Circumflex Scapular Artery.
- 6-Subscapular Artery
- 7-brachial artery



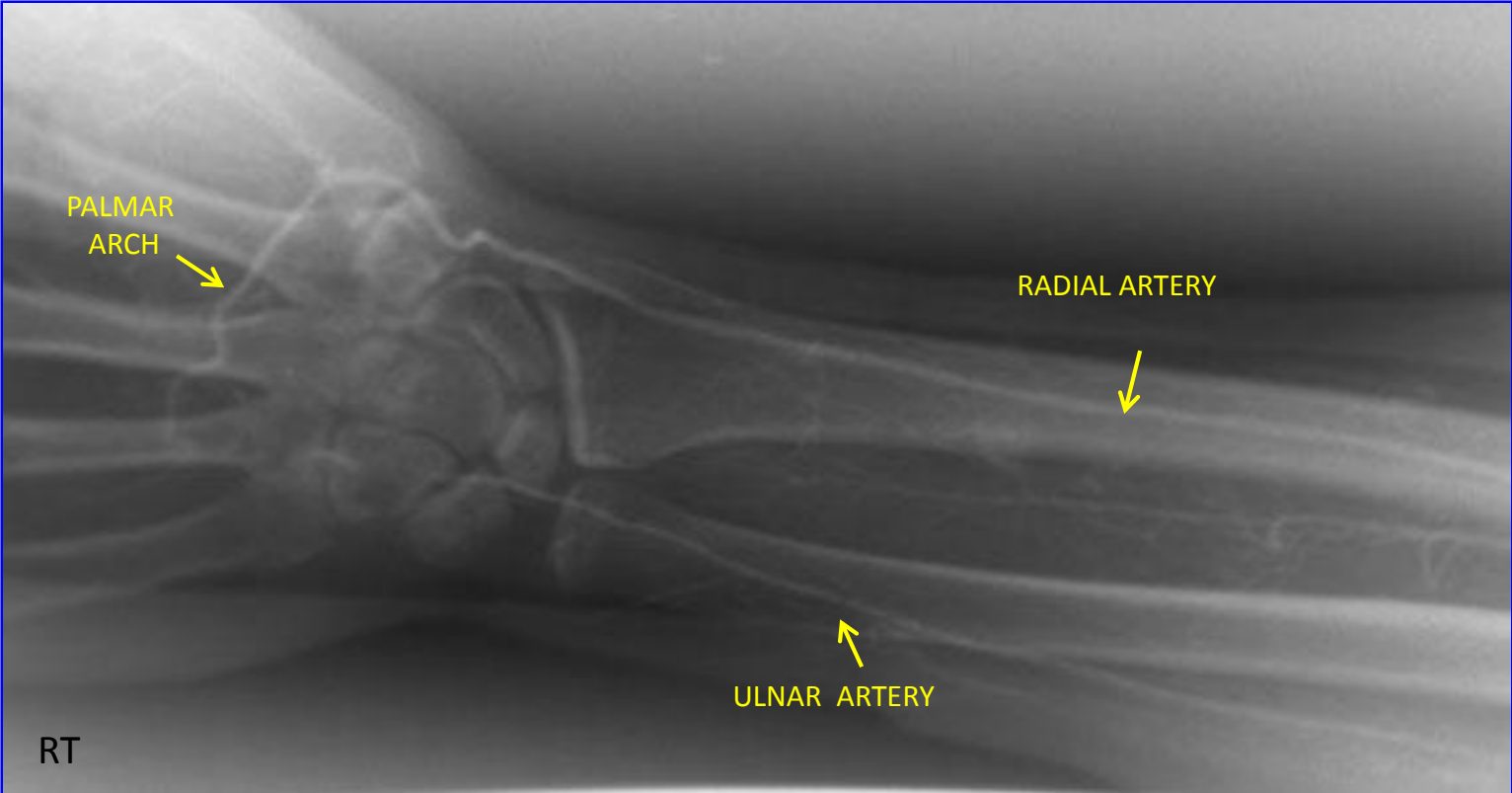
- 1-Radial Artery.
- 2-Ulnar Artery.
- 3-Deep Palmar Arch.
- 4-Common Palmar Digital Artery.
- 5-Proper Palmar Digital Artery

## RT. UPPER EXTREMITY ANGIOGRAM





RT. UPPER EXTREMITY ANGIOGRAM



**THE END**