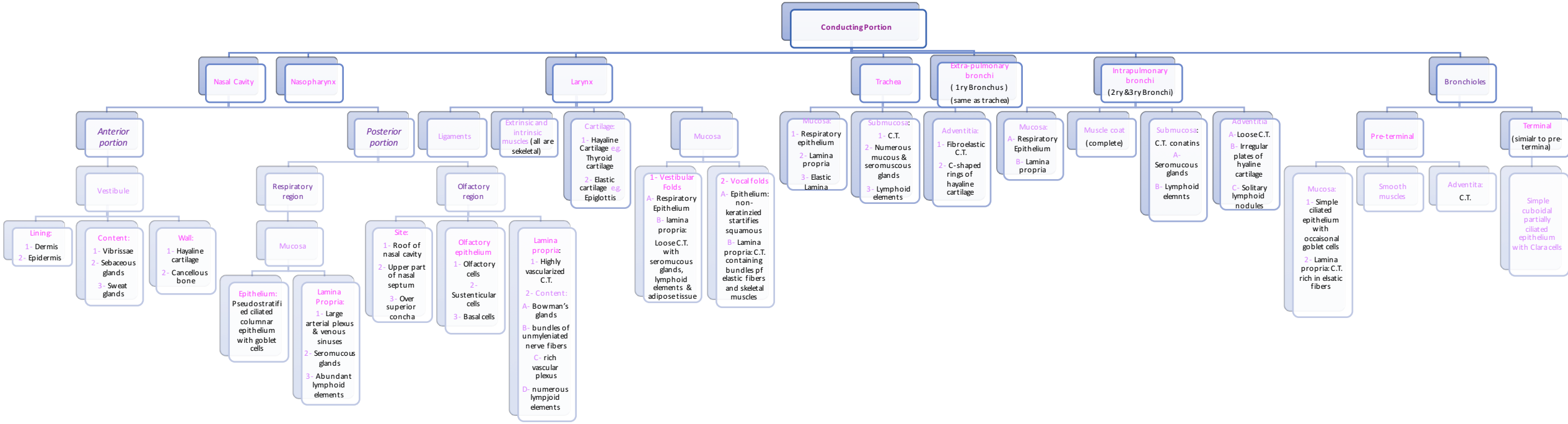
Conducting Portion
Nasal Cavity
Nasopharynx
Larynx
Trachea
Extra-pulmonary bronchi
(1ry Bronchus)
(same as trachea)
Intrapulmonary bronchi
(2ry &3ry Bronchi)
Bronchioles
Anterior portion
Posterior portion
Vestibule
Lining:
1- Dermis
2- Epidermis
Content:
1- Vibrissae
2- Sebaceous glands
3- Sweat glands
Wall:
1- Hayaline cartilage
2- Cancellous bone
Respiratory region
Mucosa
Epithelium:
Pseudostratified ciliated columnar epithelium with goblet cells
Lamina Propria:
1- Large arterial plexus & venous sinuses
2- Seromucous glands
3- Abundant lymphoid elements
Olfactory region
Site:
1- Roof of nasal cavity
2- Upper part of nasal septum
3- Over superior concha
Olfactory epithelium
1- Olfactory cells
2- Sustenticular cells
3- Basal cells
Lamina propria:
1- Highly vascularized C.T.
2- Content:
A- Bowman's glands
B- bundles of unmyleniated nerve fibers
C- rich vascular plexus
D- numerous lympjoid elements
Ligaments
Extrinsic and intrinsic muscles (all are sekeletal)
Cartilage:
1- Hayaline Cartilage e.g. Thyroid cartilage
2- Elastic cartilage e.g. Epiglottis
Mucosa
1- Vestibular Folds
A- Respiratory Epithelium
B- lamina propria:
Loose C.T. with seromucous glands, lymphoid elements & adiposetissue
2- Vocal folds
A- Epithelium: non-keratinzied startifies squamous
B- Lamina propria: C.T. containing bundles pf elastic fibers and skeletal muscles
Mucosa:
1- Respiratory epithelium
2- Lamina propria
3- Elastic Lamina
Submucosa:
1- C.T.
2- Numerous mucous & seromuscous glands
3- Lymphoid elements
Adventitia:
1- Fibroelastic C.T.
2- C-shaped rings of hayaline cartilage
Mucosa:
A- Respiratory Epithelium
B- Lamina propria
Muscle coat
(complete)
Submucosa:
C.T. conatins
A- Seromucous glands
B- Lymphoid elemnts
Adventitia
A- Loose C.T.
B- Irregular plates of hyaline cartilage
C- Solitary lymphoid nodules
Pre-terminal
Mucosa:
1- Simple ciliated epithelium with occaisonal goblet cells
2- Lamina propria: C.T. rich in elsatic fibers
Smooth muscles
Adventita:
C.T.
Terminal
(simialr to pre-termina)
Simple cuboidal partially ciliated epithelium with Clara cells

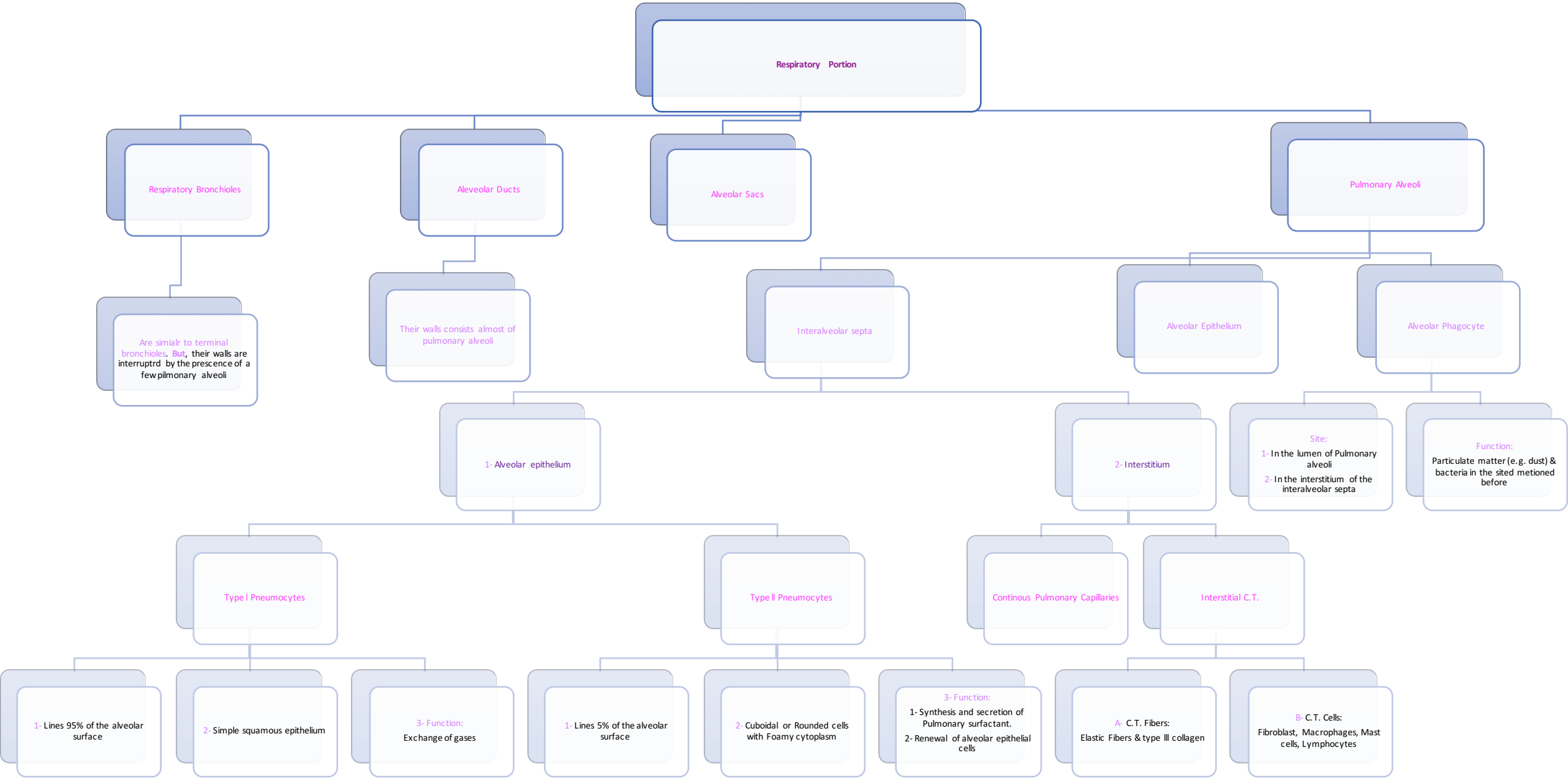
Respiratory Portion
Respiratory Bronchioles
Are simialr to terminal bronchioles. But, their walls are interruptrd by the prescence of a few pilmonary alveoli
Aleveolar Ducts
Their walls consists almost of pulmonary alveoli
Alveolar Sacs
Pulmonary Alveoli
Interalveolar septa
1- Alveolar epithelium
Type I Pneumocytes
1- Lines 95% of the alveolar surface
2- Simple squamous epithelium
3- Function:
Exchange of gases
Type II Pneumocytes
1- Lines 5% of the alveolar surface
2- Cuboidal or Rounded cells with Foamy cytoplasm
3- Function:
1- Synthesis and secretion of Pulmonary surfactant.
2- Renewal of alveolar epithelial cells
2- Interstitium
Continous Pulmonary Capillaries
Interstitial C.T.
A- C.T. Fibers:
Elastic Fibers & type III collagen
B- C.T. Cells:
Fibroblast, Macrophages, Mast cells, Lymphocytes
Alveolar Epithelium
Alveolar Phagocyte
Site:
1- In the lumen of Pulmonary alveoli
2- In the interstitium of the interalveolar septa
Function:
Particulate matter (e.g. dust) & bacteria in the sited metioned before