



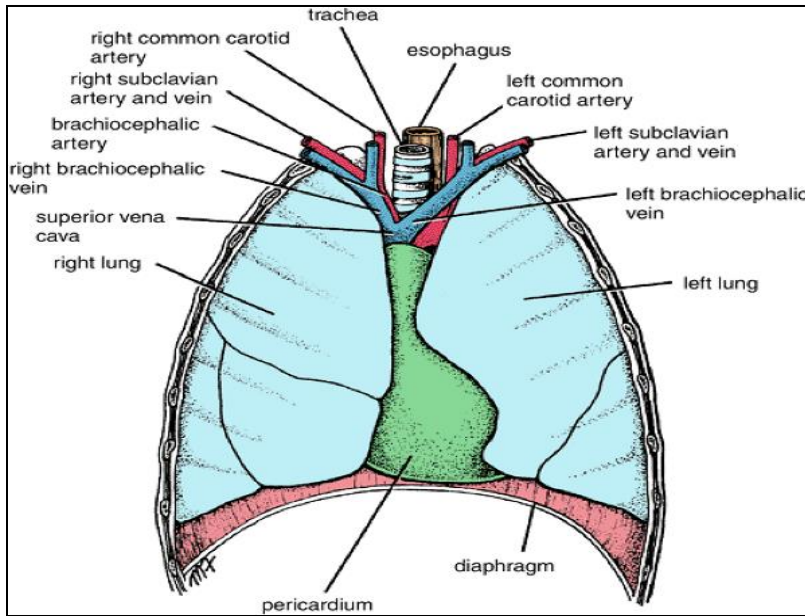
Anatomy of the Heart

DR. SANAA AL-SHAARAWI
DR. SAEED VOHRA

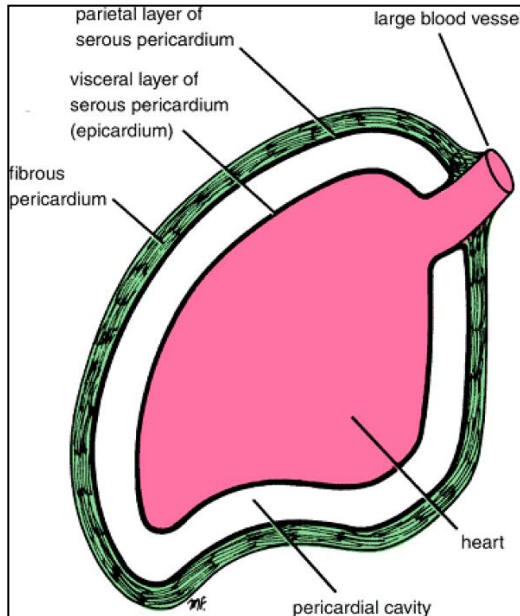
OBJECTIVES

- ***At the end of the lecture, the student should be able to :***
- ***Describe the shape of heart regarding :*** apex, base, sternocostal and diaphragmatic surfaces.
- ***Describe the interior of heart chambers :*** right atrium, right ventricle, left atrium and left ventricle.
- ***List the orifices of the heart :***
- *Right atrioventricular (Tricuspid) orifice.*
- *Pulmonary orifice.*
- *Left atrioventricular (Mitral) orifice.*
- *Aortic orifice.*
- ***Describe the innervation of the heart***
- *Briefly describe the conduction system of the Heart*

The Heart



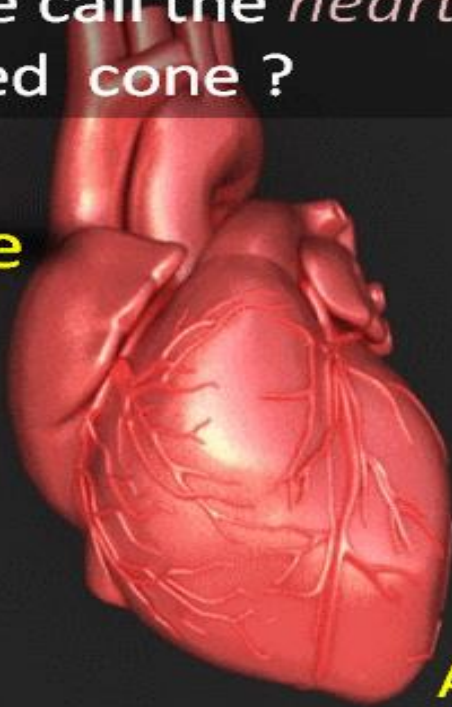
- It lies in the **middle mediastinum**.
- It is surrounded by a fibroserous sac called **pericardium** which is differentiated into an **outer fibrous layer (Fibrous pericardium)** & **inner serous sac (Serous pericardium)**.
- The Heart is somewhat pyramidal in shape, having:
 - **Apex**
 - **Sterno-costal (anterior surface)**
 - **Base** (posterior surface).
 - **Diaphragmatic** (inferior surface)
- It consists of 4 chambers, 2 atria (right & left) & 2 ventricles (right & left).



Apex of the heart

Can we call the *heart* as a inverted cone ?

Base



Apex

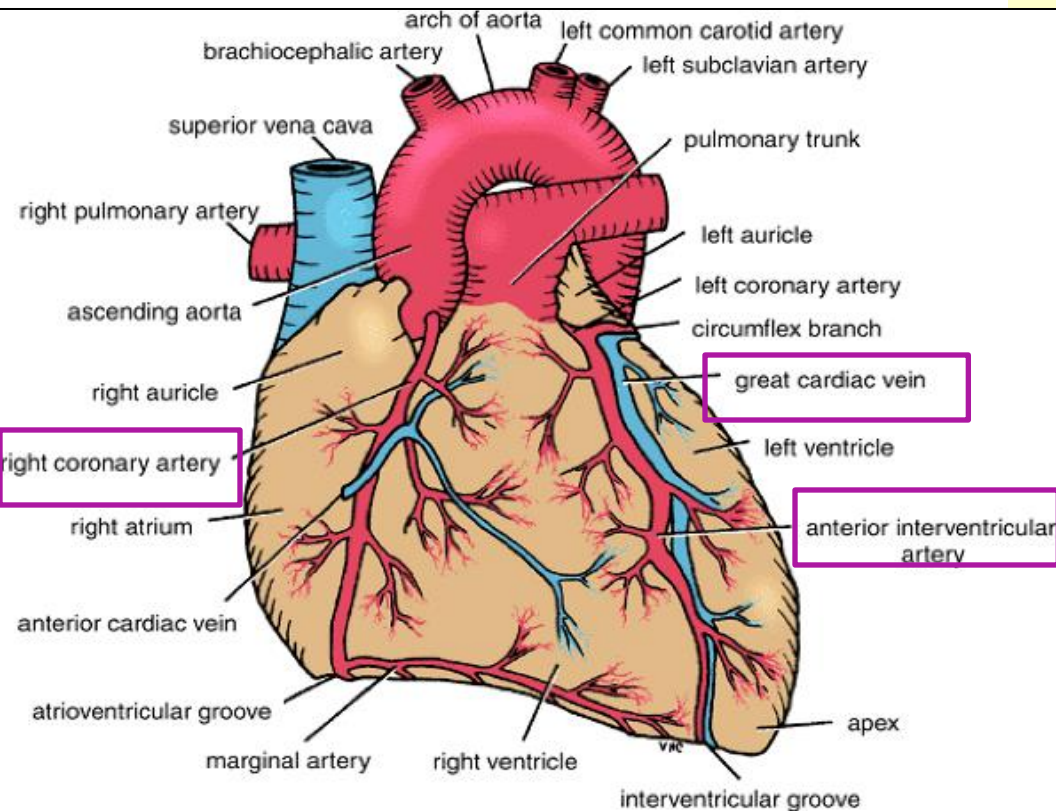
www.drsvenkatesan.co.in

- Directed downwards, forwards and to the left.
- It is formed by the **left ventricle**.
- Lies at the level of **left 5th intercostal space** 3.5 inch from midline.

Note that the base of the heart is called the base because the heart is pyramid shaped; the base lies opposite the apex. The heart does not rest on its base; it rests on its diaphragmatic (inferior) surface

Sterno-costal (anterior) surface

This surface is formed mainly by the **right atrium** and the **right ventricle**



- Divided by **coronary (atrio-ventricular) groove** into :
 - **Atrial part**, formed mainly by right atrium.
 - **Ventricular part** , the right 2/3 is formed by right ventricle, while the left 1/3 is formed by left ventricle. So, it is also formed of some of the left ventricle.

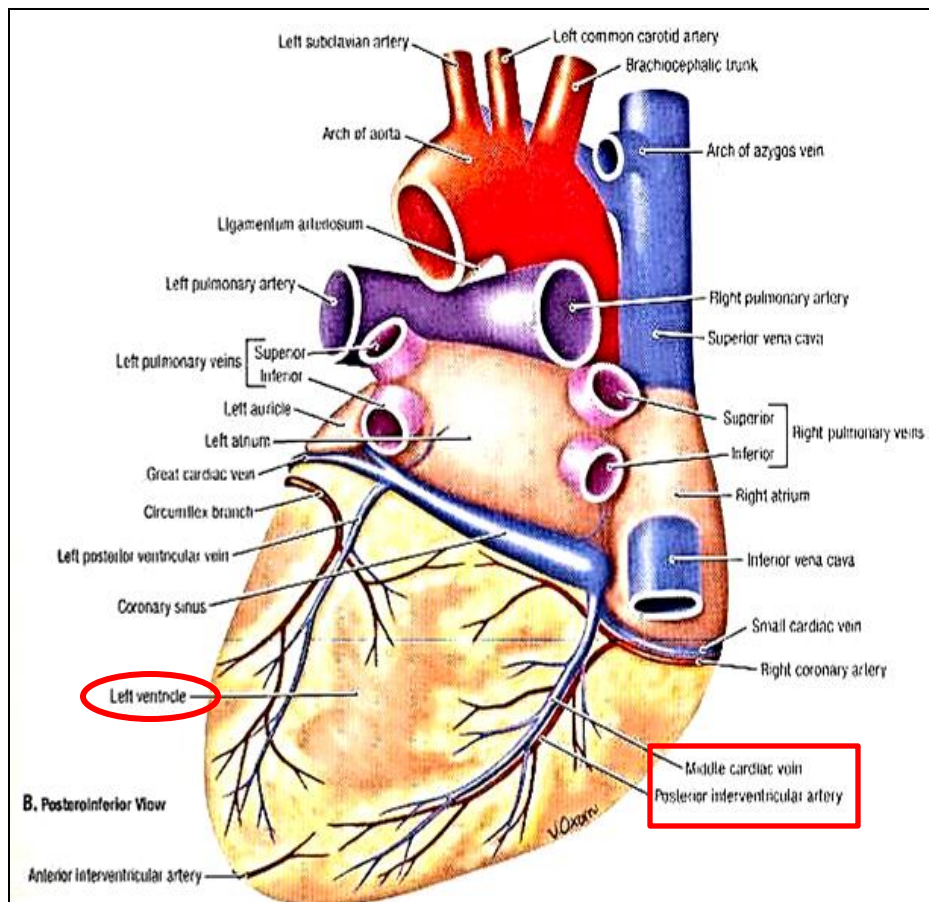
The 2 ventricles are separated by **anterior interventricular groove**, which lodges :

Anterior interventricular artery (branch of left coronary).

Great cardiac vein.

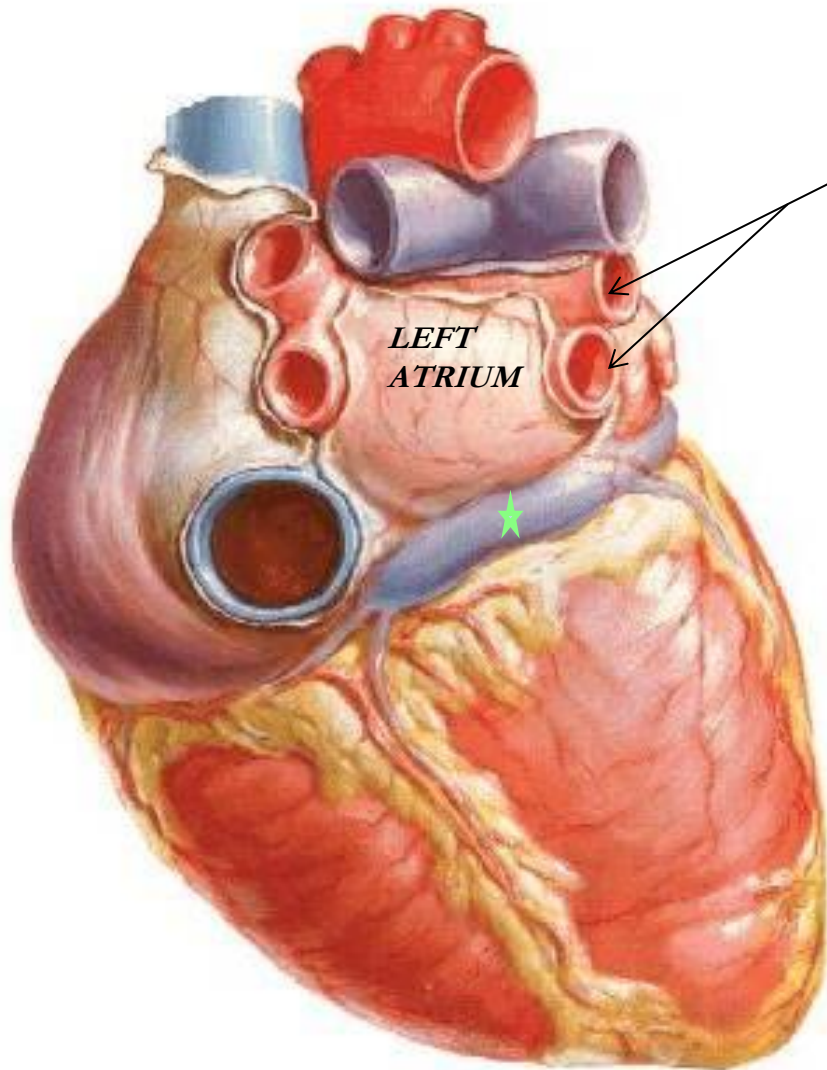
The coronary groove lodges the **right coronary artery.**

Diaphragmatic (Inferior) surface



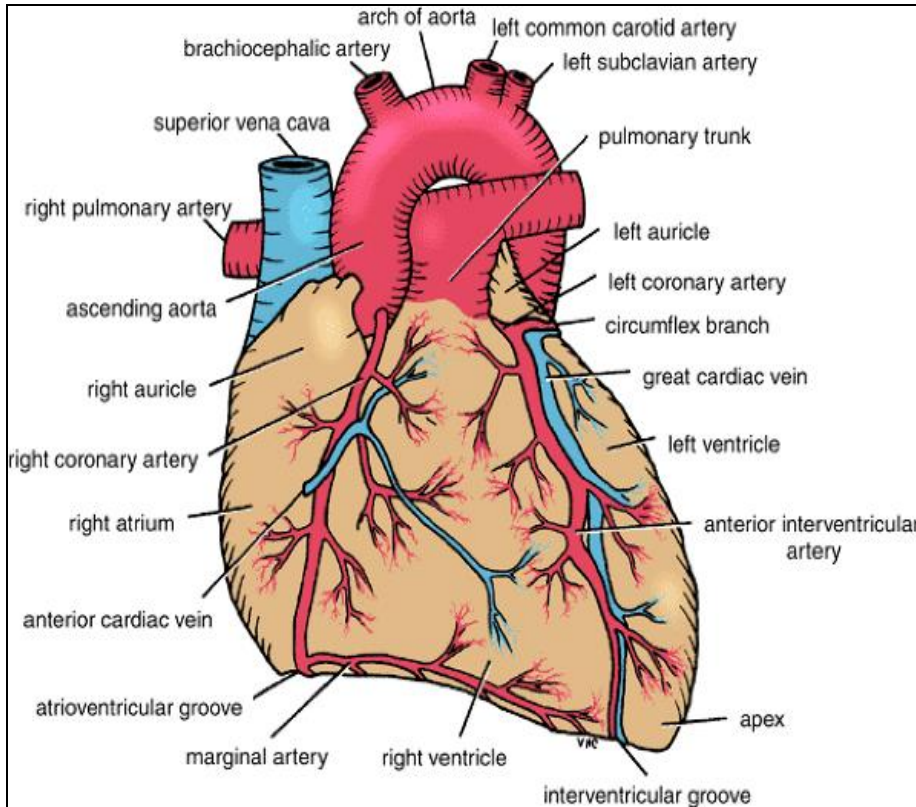
- **Formed** by the 2-ventricles, mainly left ventricle (left 2/3).
- Slightly concave as it rests on diaphragm.
- **Directed** inferiorly & backward.
- **Separated** from base of heart by posterior part of coronary sulcus
- The 2-ventricles are separated by **posterior interventricular groove** which lodges:
 - **Posterior interventricular artery**
 - **Middle cardiac vein**

Base of the Heart (posterior surface)



- It is formed by the 2 atria, mainly left atrium, into which open the 4 pulmonary veins.
- It is directed backwards.
- Lies opposite middle thoracic vertebrae(5-7)
- Is separated from the vertebral column by descending aorta, esophagus and **oblique sinus of pericardium**
- Bounded inferiorly by **post part of coronary sulcus** , which lodges the **coronary sinus**★

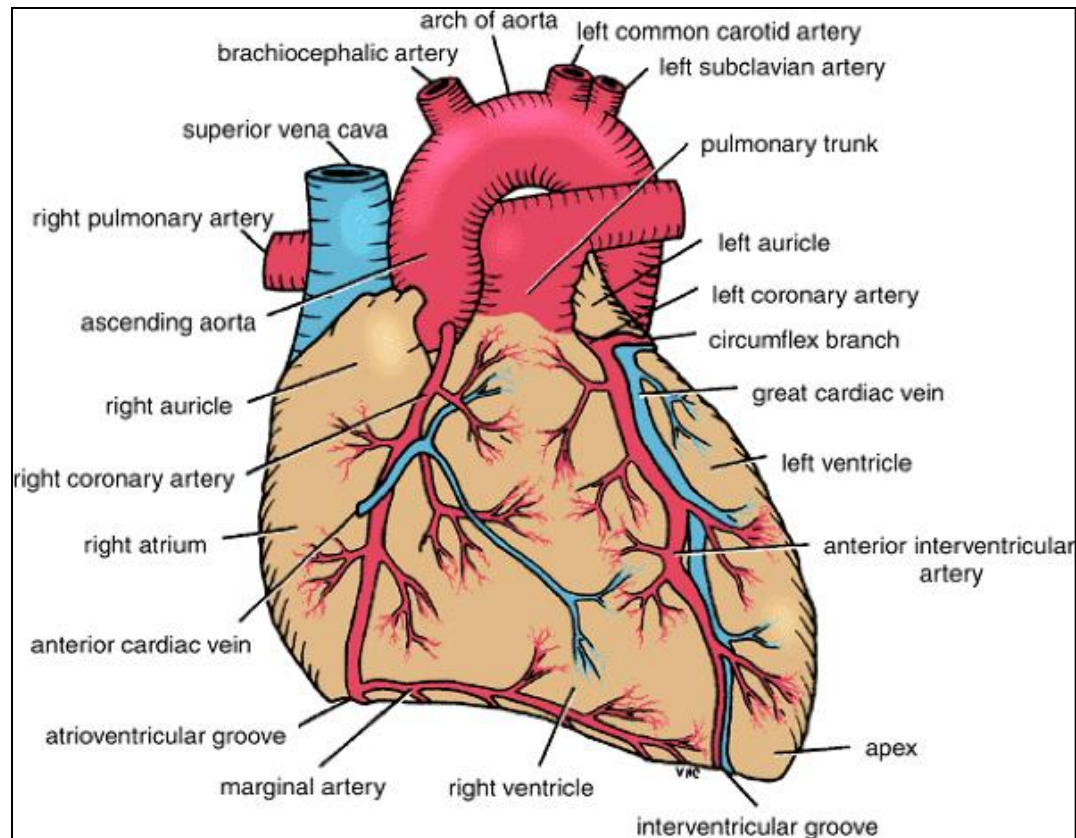
Borders of the Heart



- **Upper border:**
 - Is formed by the 2 atria.
 - It is concealed by ascending aorta & pulmonary trunk.
- **Right border:**
 - Is formed by right atrium
- **Lower border:**
 - Is formed mainly by right ventricle + apical part of left ventricle.
- **Left border:**
 - Is formed mainly by left ventricle + auricle of left atrium.

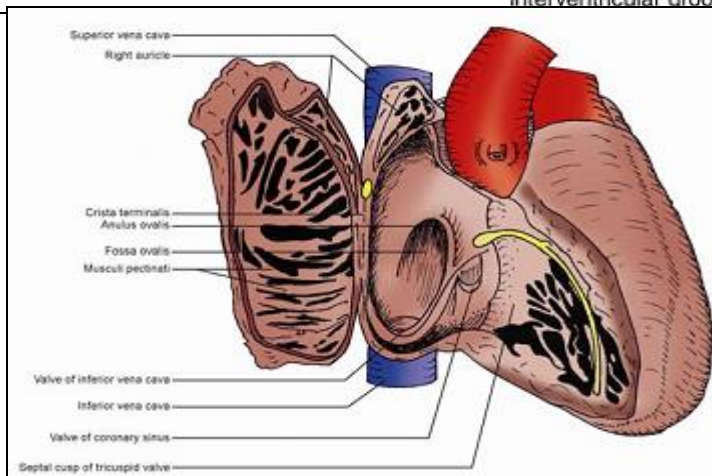
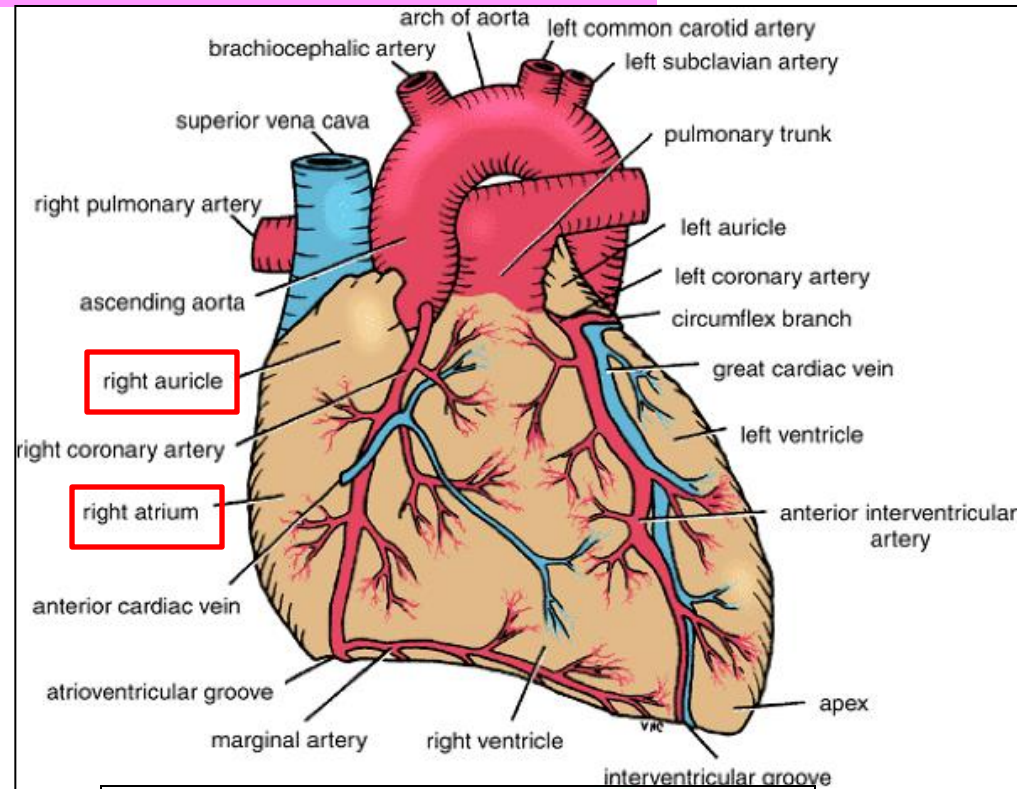
Chambers of the Heart

The heart is divided by vertical septa into four chambers: the right and left atria and the right and left ventricles. **The right atrium** lies **anterior** to the left atrium, and the **right ventricle** lies **anterior** to the left ventricle.

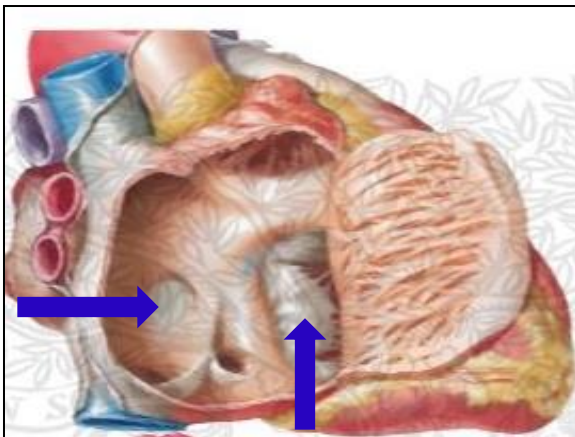
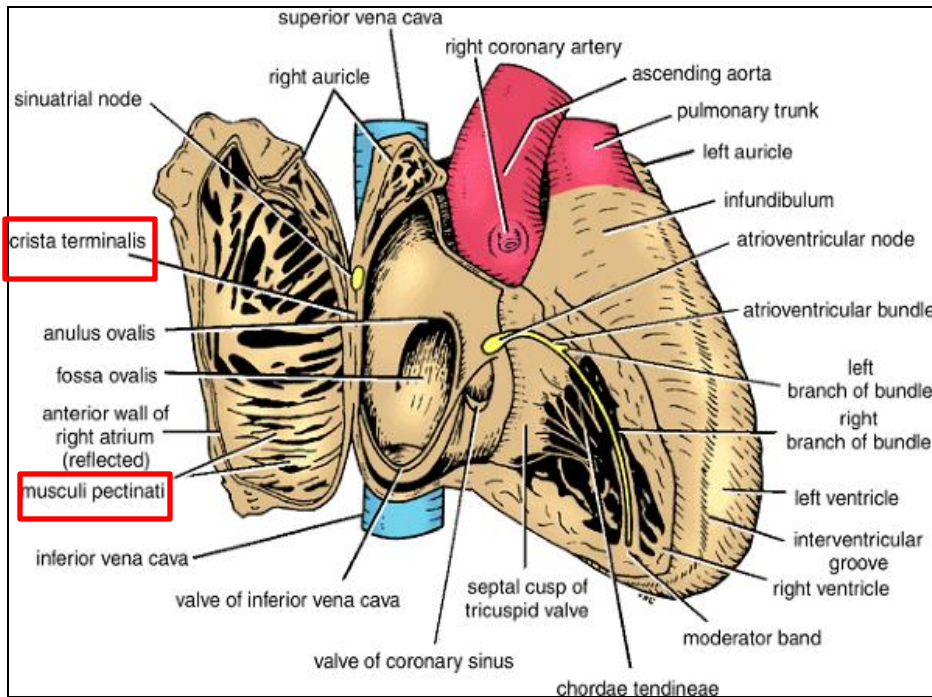


Right Atrium

- The right atrium consists of a **main cavity** and a small out pouching, the **auricle**.
- **On the outside** of the heart at the junction **between the right atrium and the right auricle** is a vertical groove, the **sulcus terminalis**, which **on the inside** forms a ridge, the **crista terminalis**.



Cavity of Right Atrium



➤ **Crista terminalis** divides right atrium into:

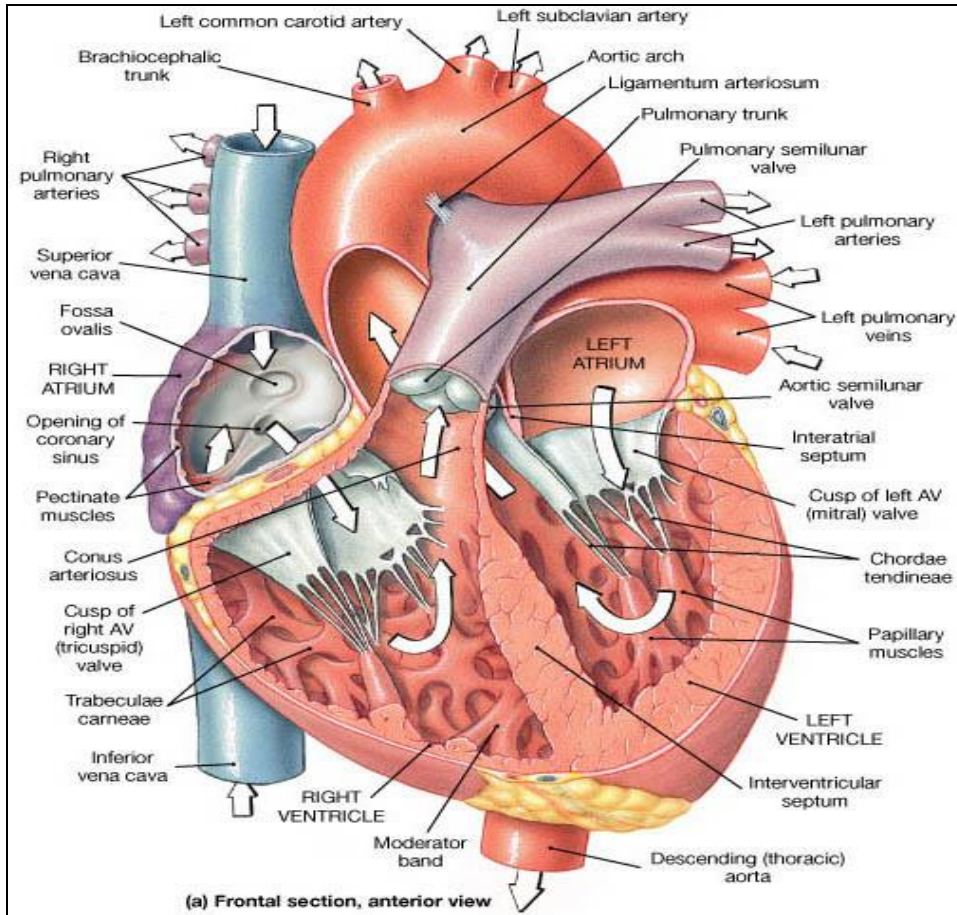
1- **Anterior part:** rough and trabeculated by bundles of muscle fibres (**muscoli pectinati**).

2- **Posterior part (sinus venarum)** is smooth.

➤ **The interatrial septum** carries an oval depression called **Fossa ovalis**. The margin of this depression is called **Anulus ovalis**.

➤ **The blood leaves right atrium to right ventricle via tricuspid valve.**

Cavity of Right Atrium



Openings in right atrium:

➤ **SVC** --- has no valve

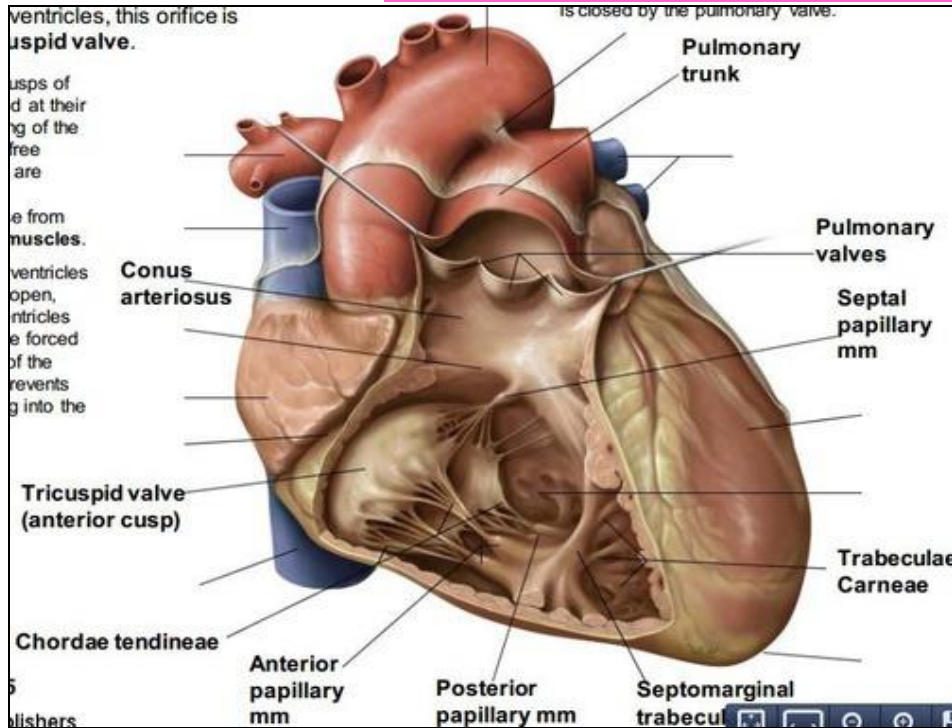
➤ **IVC** --- guarded by a valve

➤ **Coronary sinus** : has a well-defined valve

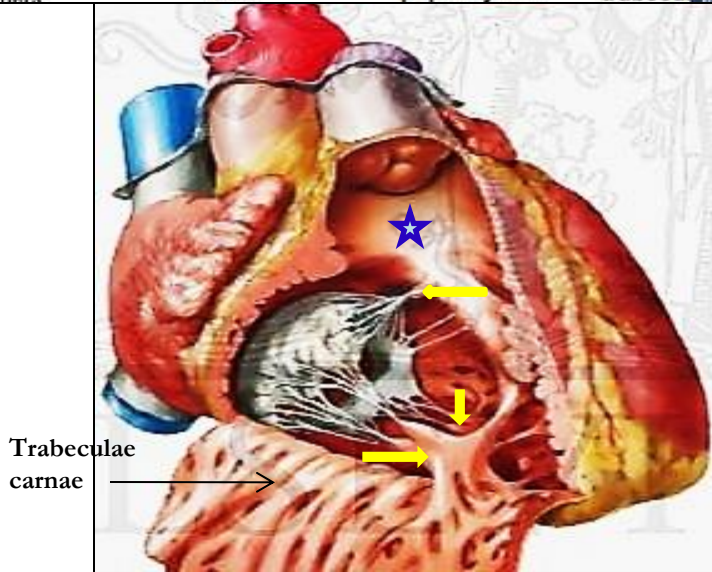
➤ **Right atrioventricular orifice** lies anterior to IVC opening , it is surrounded by a fibrous ring which gives attachment to the **tricuspid valve**

➤ **Small orifices** of small veins

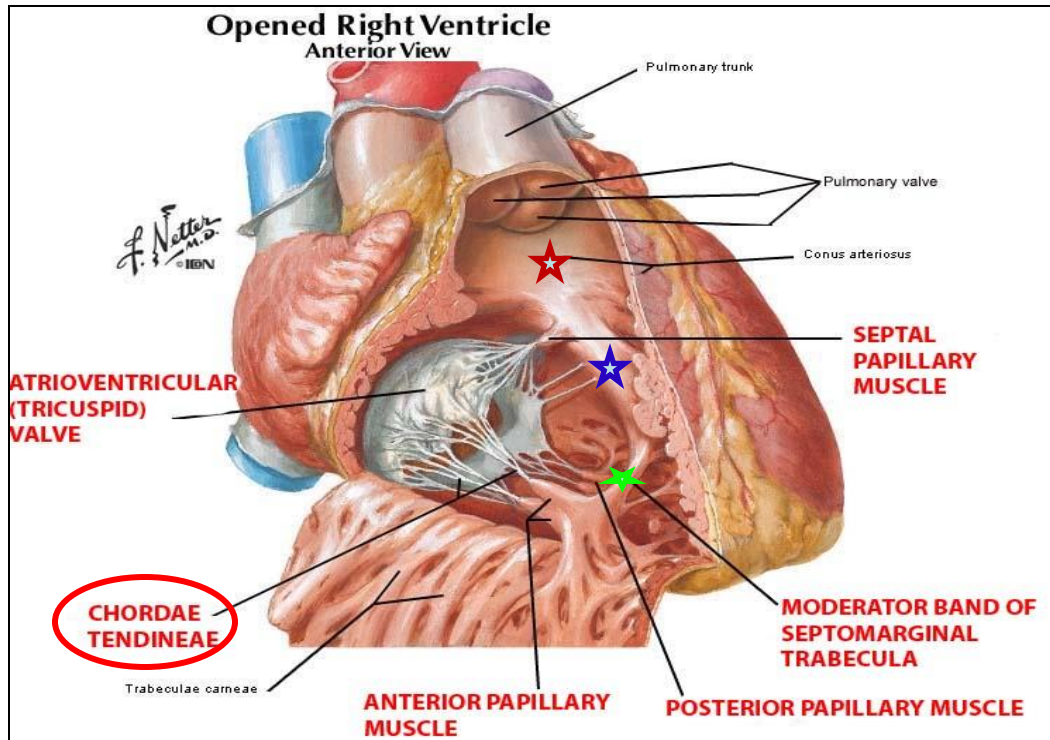
Cavity of right ventricle



- Its wall is **thinner** than that of left ventricle
- Its wall contains projections called ***trabeculae carnae***.
- The right ventricle communicates **with right atrium** through **right atrioventricular orifice** & **with pulmonary trunk** through **pulmonary orifice**.
- As **the cavity** approaches the pulmonary orifice it **becomes funnel shaped**, at which point it is referred to as the **infundibulum**.★
- Large projections arise from the walls called ***papillary muscles*** :
 - ***Anterior papillary muscle***
 - ***Posterior papillary muscle***
 - ***Septal papillary muscle***



Cavity of right ventricle



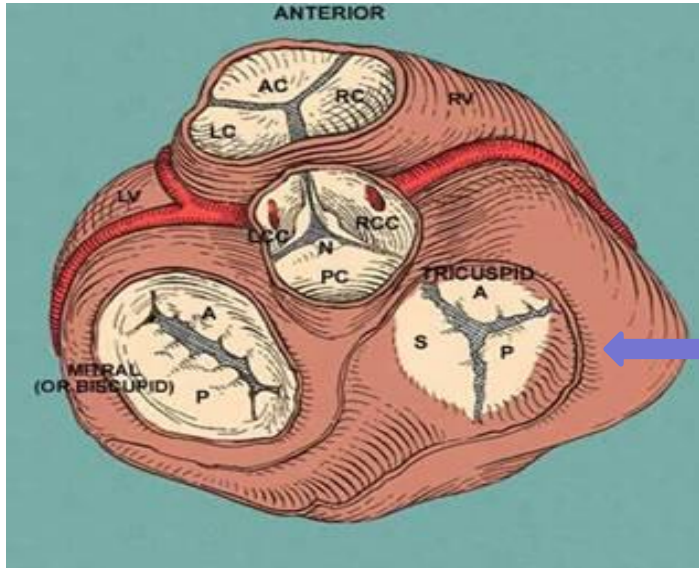
➤ Each papillary muscle is attached to the cusps of tricuspid valve by tendinous threads called **chordae tendinae**.

➤ Blood leaves the right ventricle to pulmonary trunk through pulmonary orifice.

➤ The wall of **infundibulum** ★ (conus arteriosus) is smooth and contains no trabeculae.

➤ Interventricular septum ★ is connected to **anterior papillary muscle** by a muscular band called **moderator band** ★

Right atrio-ventricular (tricuspid) orifice

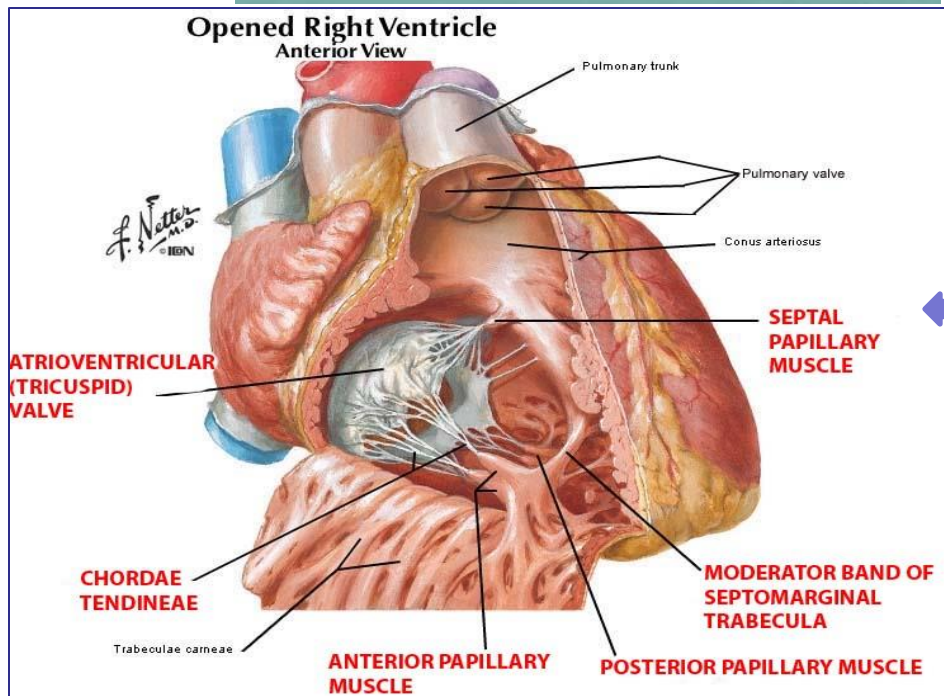


➤ About one inch wide, admitting tips of 3 fingers.

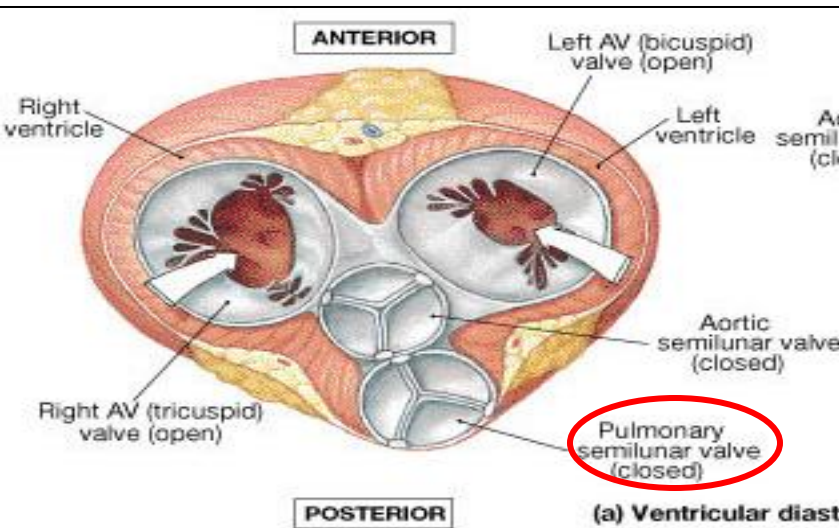
➤ It is guarded by a fibrous ring which gives attachment to the cusps of tricuspid valve.

➤ It has 3-cusps (anterior-posterior-septal or medial).

➤ **The atrial surface** of the cusps are smooth, while their **ventricular surfaces** give attachment to the **chordae tendinae**.



Pulmonary orifice

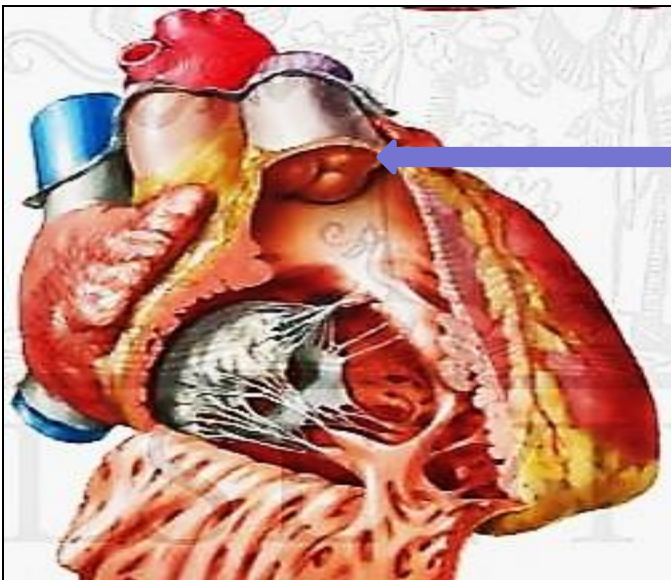

➤ Surrounded by a fibrous ring which gives attachment to the **cusps of the pulmonary valve.**

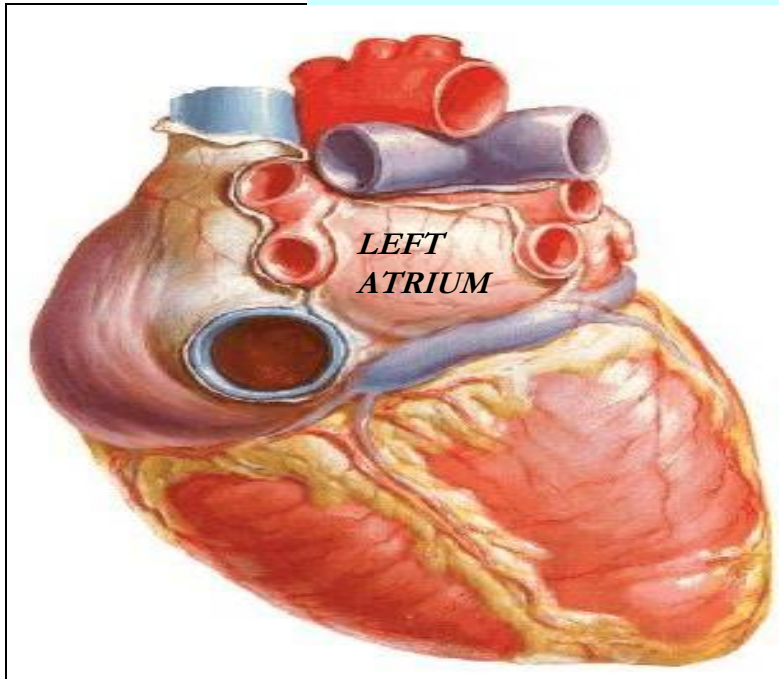
➤ The valve is formed of **3 semilunar cusps** :

2 anterior and one posterior which are concave superiorly and convex inferiorly.

➤ **No chordae tendineae or papillary muscles** are attached to these cusps



Left atrium of the heart



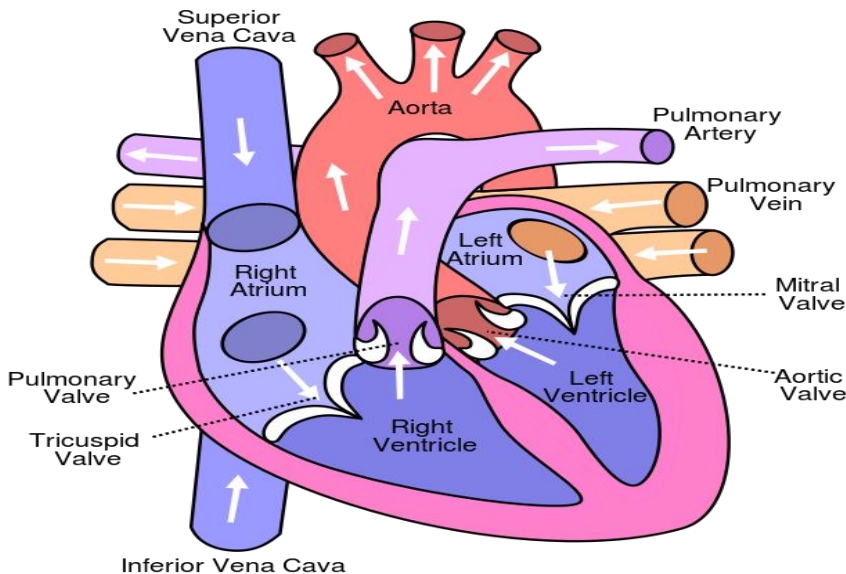
➤ The **left atrium** communicates with the **left ventricle** through the **left atrioventricular orifice**.

➤ It forms the greater part of **base of heart**.

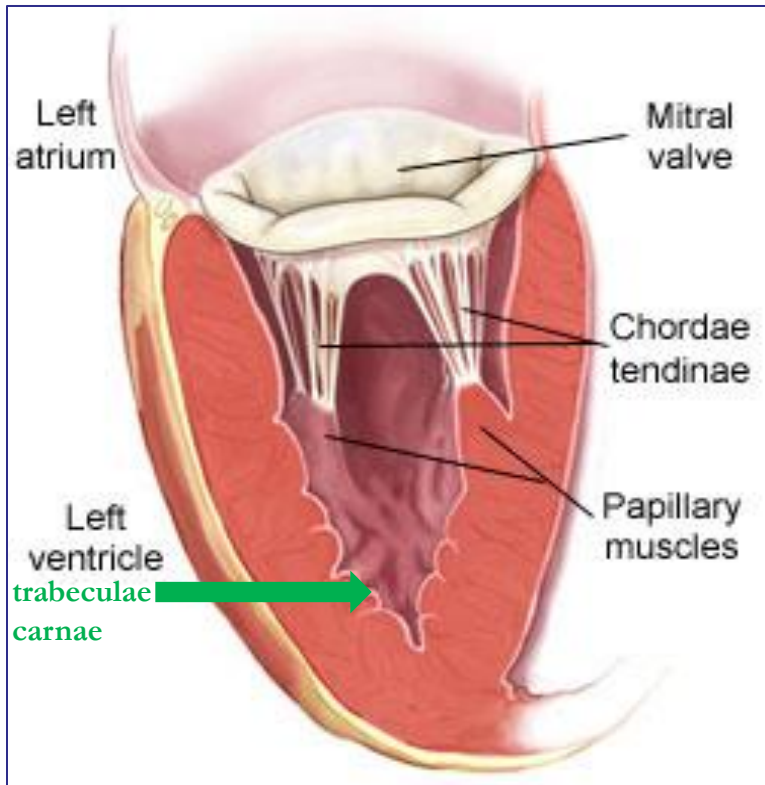
➤ Its wall is smooth **except** for small muscoli pectinati in the **left auricle**.

➤ **Receives 4 pulmonary veins** which have no valves.

➤ Sends blood to left ventricle through the **left atrioventricular orifice** which is guarded by **mitral valve (Bicuspid valve)**.



Left ventricle of the heart



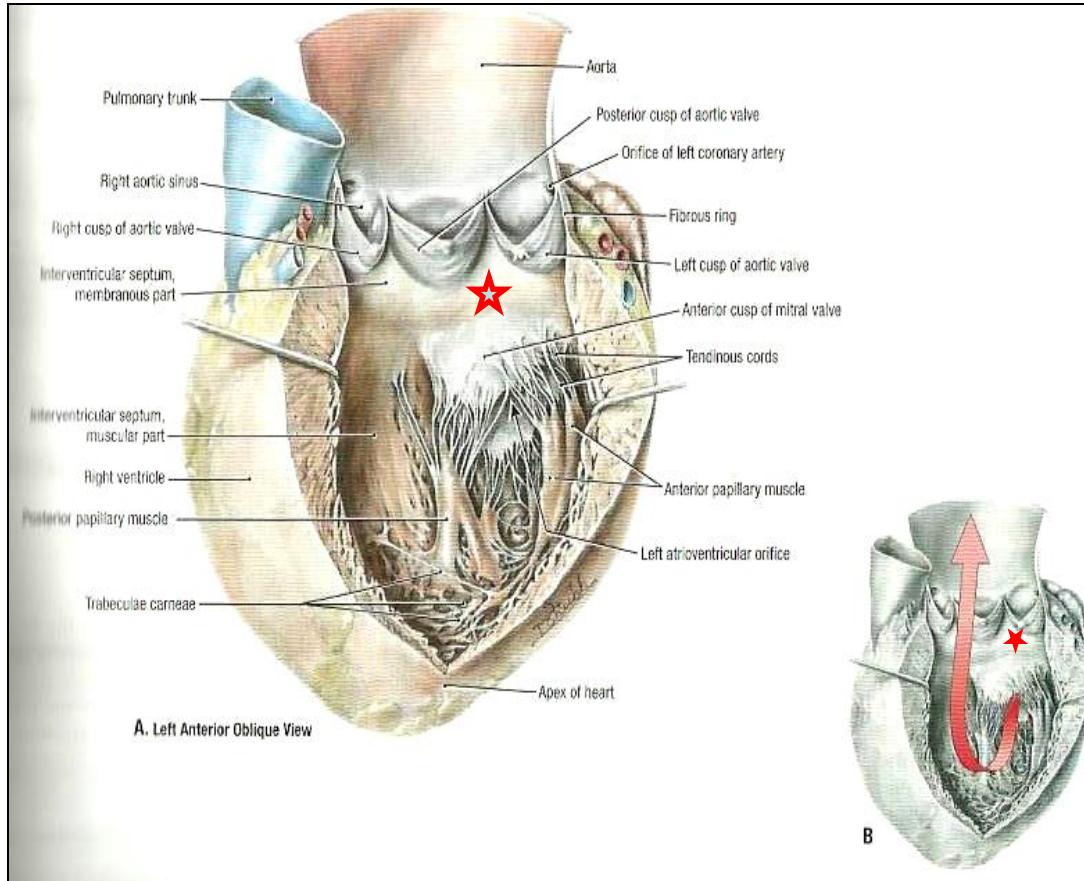
➤ Its wall is **thicker** than that of right ventricle.

➤ It receives blood from left atrium through left atrio-ventricular orifice which is guarded by **mitral valve (bicuspid)**

➤ Its wall contains **trabeculae carneae**.

➤ Its wall contains **2 large papillary muscles** (anterior & posterior). They are attached by **chordae tendinae** to cusps of mitral valve.

Left ventricle of the heart

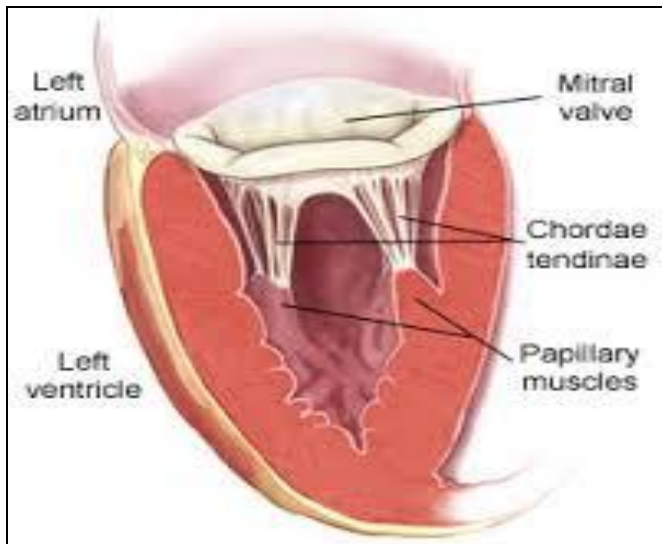
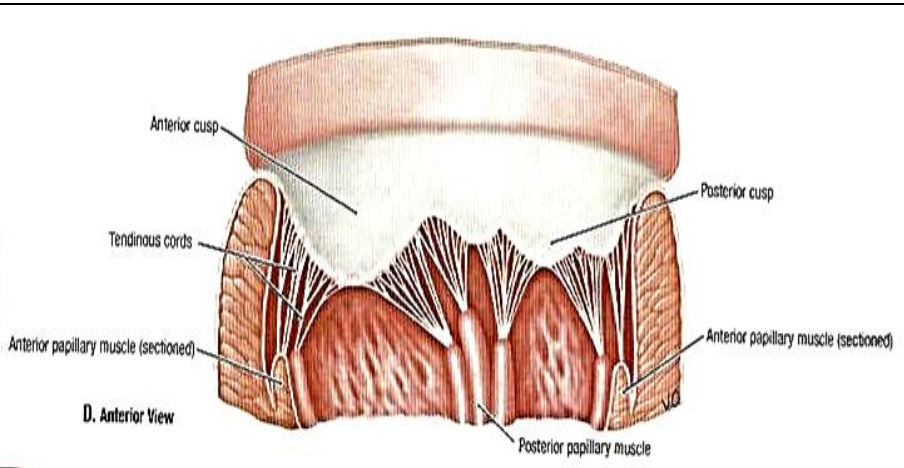


➤ The **blood** leaves the **left ventricle** to the **ascending aorta** through the **aortic orifice**.

➤ The **part of left ventricle** leading to **ascending aorta** is called **aortic vestibule** ★

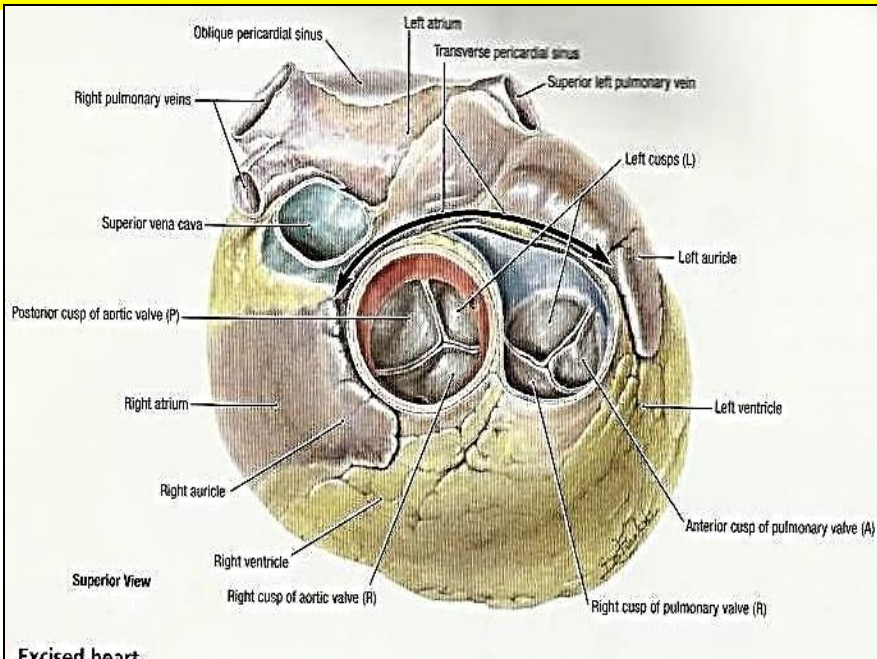
➤ The wall of this part is **fibrous** and smooth.

Left atrio-ventricular (mitral) orifice

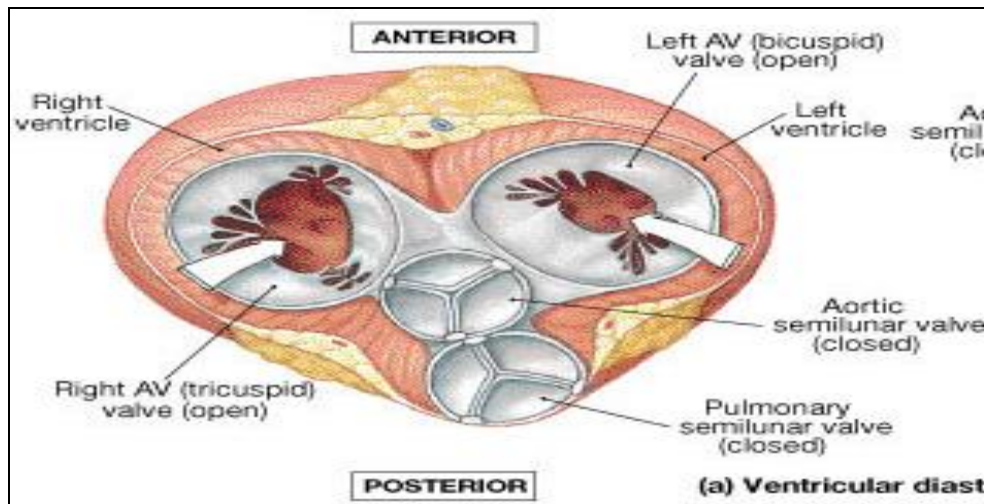


- Smaller than the right, admitting only tips of 2 fingers.
- Guarded by a **mitral valve**.
- Surrounded by a fibrous ring which gives attachment to the cusps of mitral valve.
- Mitral valve is composed of 2 cusps:
 - **Anterior cusp** : lies anteriorly and to right.
 - **Posterior cusp** : lies posteriorly and to left.
 - The atrial surfaces of the cusps are smooth, while ventricular surfaces give attachment to **chordae tendinae**.

Aortic orifice

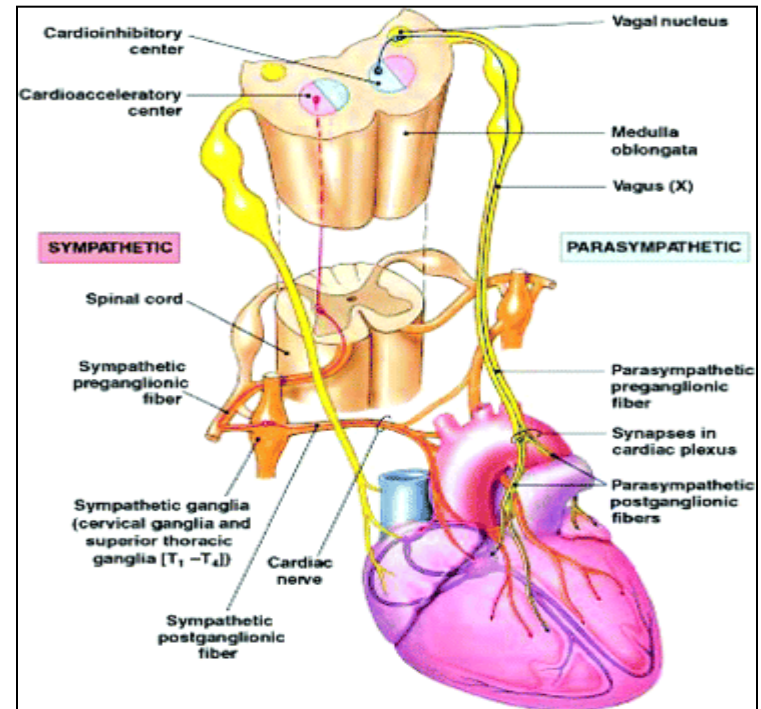
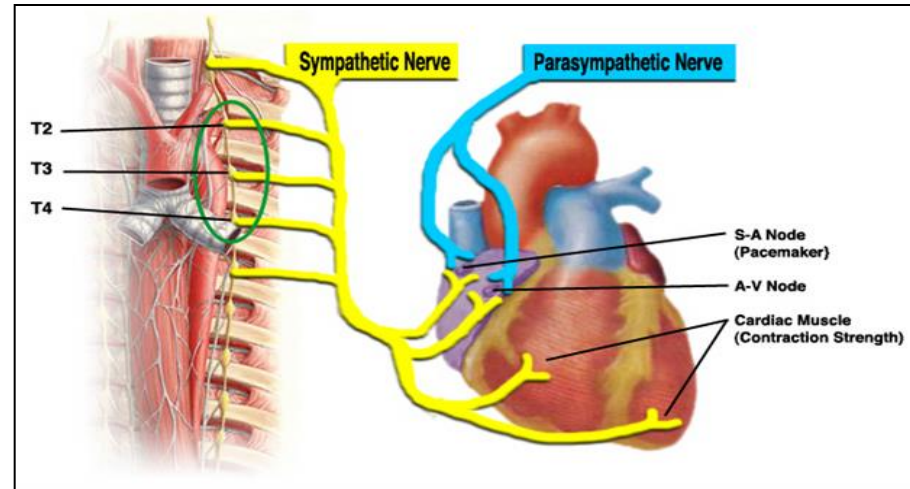


- Surrounded by a **fibrous ring** which gives attachment to the **cusps** of **aortic valve**.
- **Aortic valve** is formed of **3 semilunar cusps** which are similar to those of pulmonary valve, but the position of the cusps differs being **one anterior** and **2 posterior**.

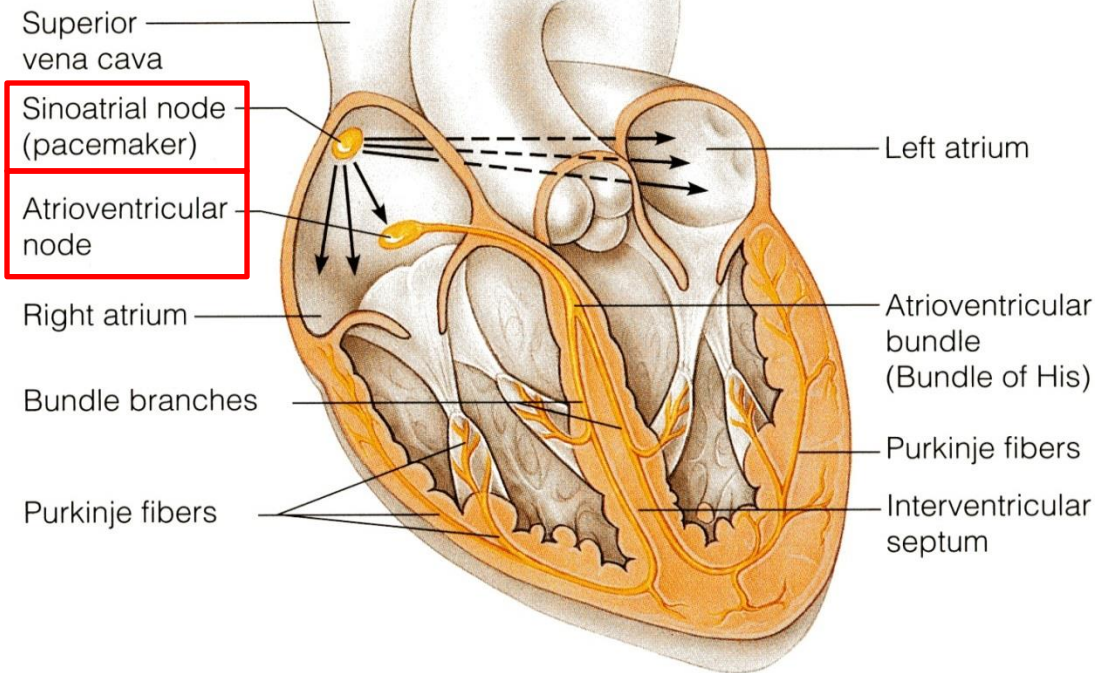


Nerve supply of the heart

- **By sympathetic & parasympathetic fibers** via the **cardiac plexus** situated below arch of aorta.
- **The sympathetic fibres** arise from the **cervical & upper thoracic ganglia** of **sympathetic trunks**.
- **The parasympathetic fibres** arise from the **vagus nerves**.
- **Postganglionic fibres** reach heart along – SAN, AVN & nerve plexus around coronary arteries.
- **Symp. Fibers**--- accelerate heart rate **but**
- **Parasymp. Fibers** --- slow heart rate (constriction of coronary arteries)

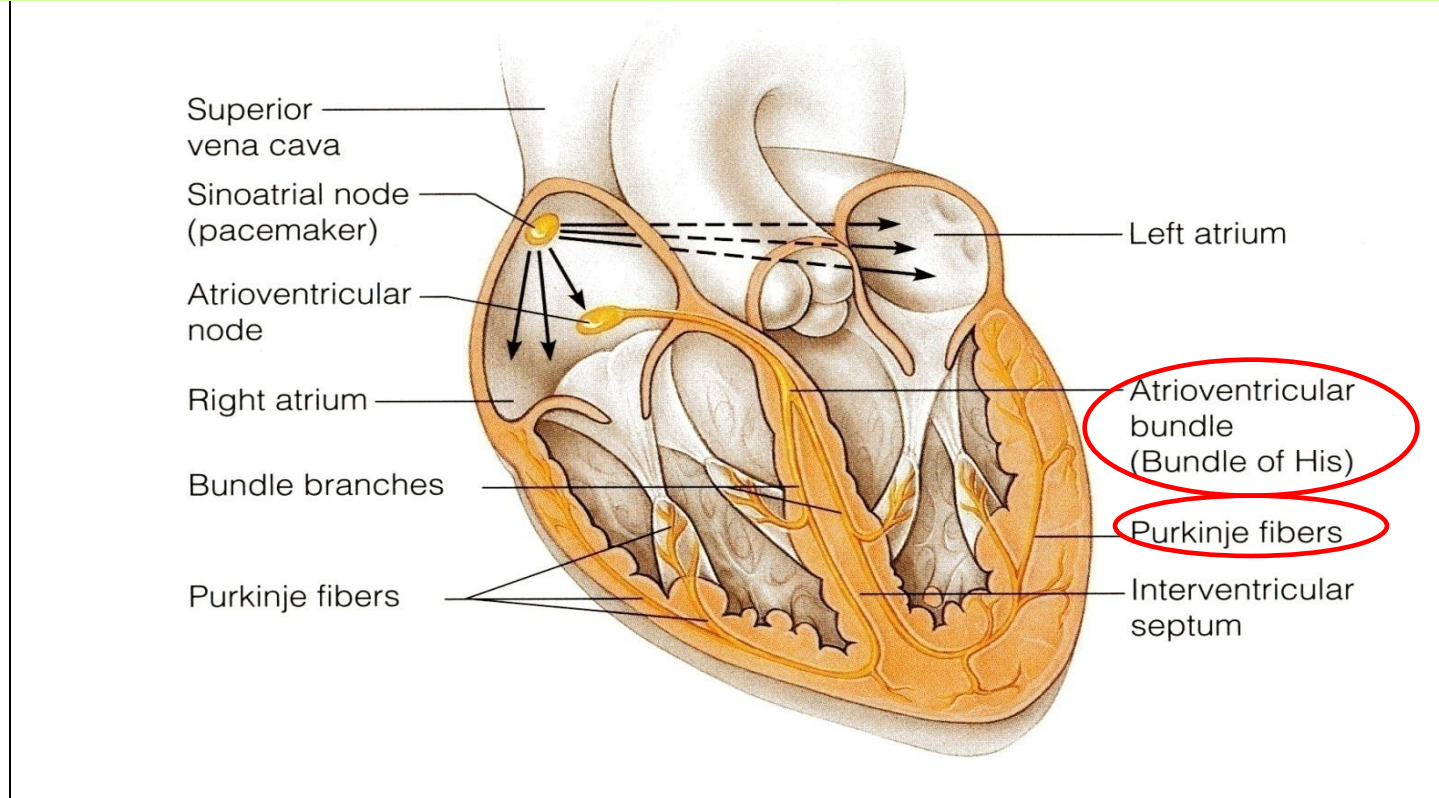


Conduction system of the heart



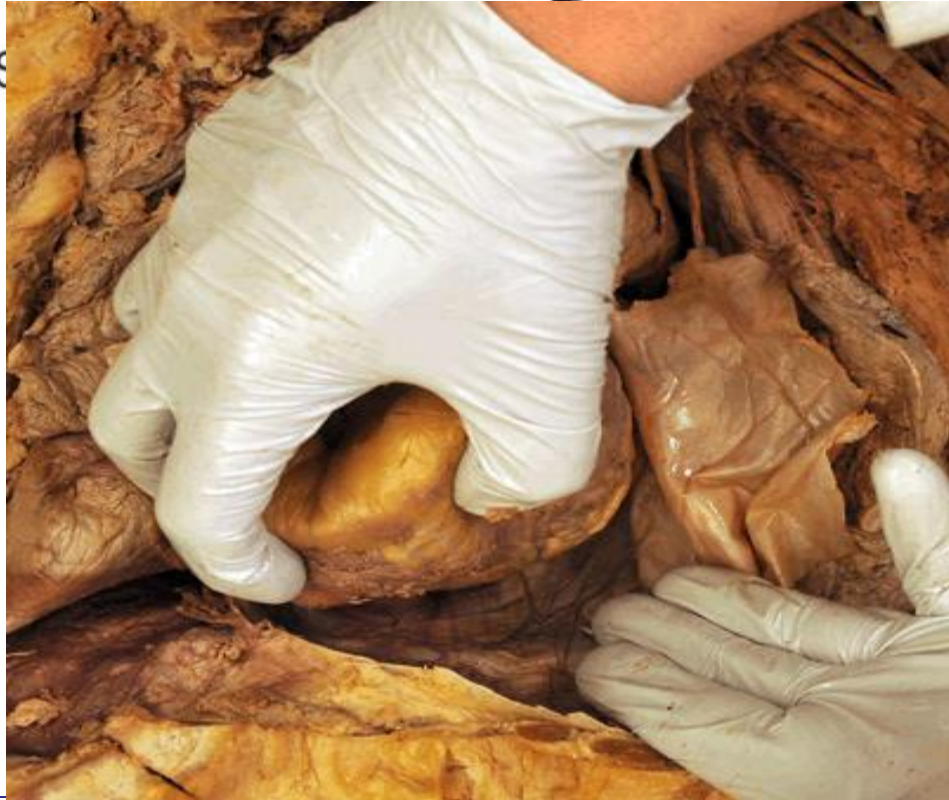- The **beating of the heart** is regulated by the **intrinsic conduction (nodal) system**
- **Its function** is to ensure that the chambers of the heart contract in the proper rhythm and sequence:
- The **main center** is the **sinoatrial (SA) node**, located in the right atrium
- The **atrioventricular (AV) node** is located at the junction of the atria and the ventricles

Conduction system of the heart



- The **atrioventricular (AV) bundle (bundle of His)** is located in the interventricular septum
- The **Purkinje fibers** are located inside the walls of the ventricles
- the SA node is called the **pacemaker** of the heart, because it generates the impulse.

Pericardial Sinuses



➤ **Transverse Sinus:** It is a recess of serous pericardium **between** ascending aorta & pulmonary T. **anteriorly**, and upper parts of 2 atria & S.V.C. **Posteriorly**.

➤ **Oblique Sinus :** It lies *posterior to the heart*. It is a recess of serous pericardium **behind** the base of heart (left atrium), **separate base from** descending aorta & esophagus.

THANK YOU