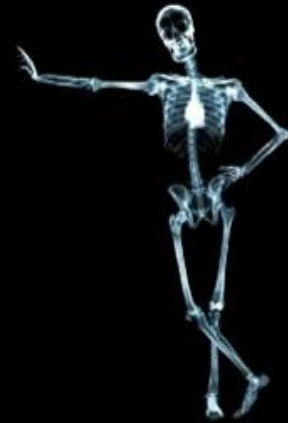
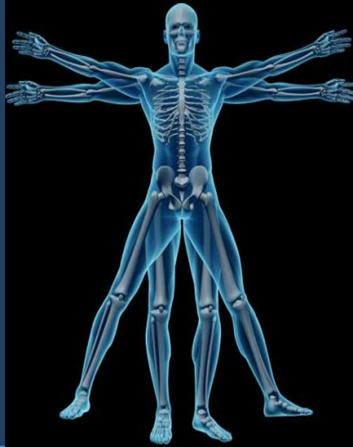
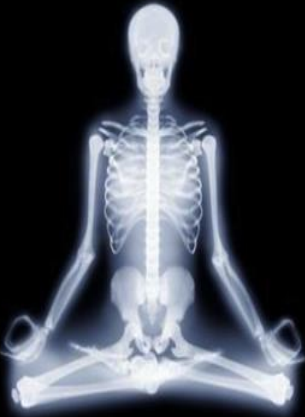

RADIOLOGY

TEAM 435



Radiology Of The Renal System

MCQs

1) Which of the following modalities assist the kidneys function?

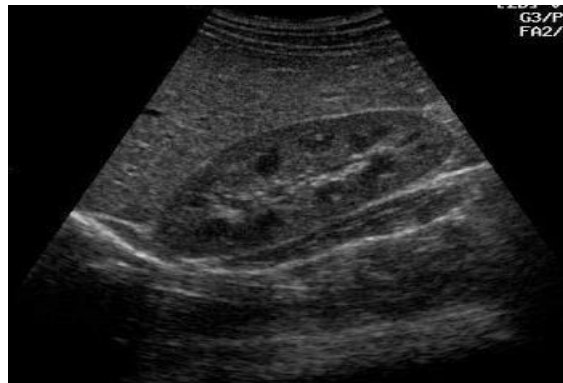
- A. US
- B. CT
- C. MRI
- D. Nuclear scan

2) A 22 year old man had a car accident, the doctor suspects that he has multiple fractures, what of the modalities should he use in this case?

- A. x-ray
- B. CT
- C. MRI
- D. Nuclear scan

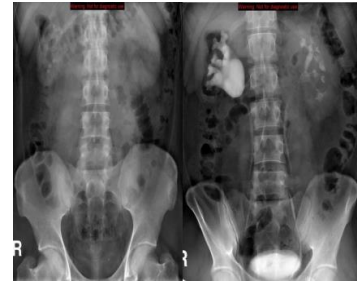
3) A young Adult presented with right loin pain and hematuria. Ultrasound Exam was performed. Which of the following is the likely finding?

- A. Hydronephrosis.
- B. Normal.
- C. Renal mass.
- D. Upper pole renal stone.



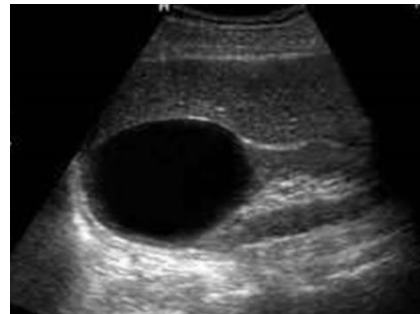
4) **Adult patient presents with hematuria. An intravenous urogram examination was performed. Which of the following is the likely cause of his presentation?**

- A. Non-functioning kidneys.
- B. Renal stones.
- C. Renal mass.
- D. Uretric stricture.



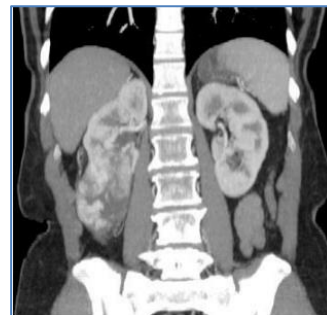5) **Young Adult presented with right loin pain and hematuria. Ultrasound Exam was performed. Which of the following is the likely finding?**

- A. Normal.
- B. Hydronephrosis.
- C. Renal cyst.
- D. Lower pole renal stone.



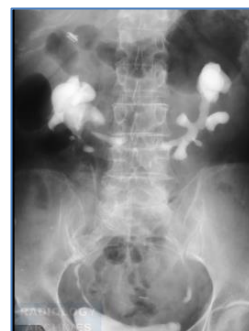6) **49 Adult patient smokes for 30 years presented to PHC with hematuria and weight loss, from the patient's CT scan what is the diagnosis?**

- A. Renal cyst.
- B. Pyelonephritis.
- C. Polycystic kidney
- D. Renal cell carcinoma.



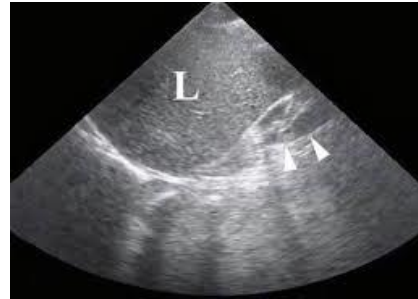7) **From the following IVP scan what is the congenital disorder the patient has?**

- A. Horseshoe kidneys.
- B. Polycystic Kidney.
- C. Ectopic Kidney.
- D. Duplicating Collecting System.



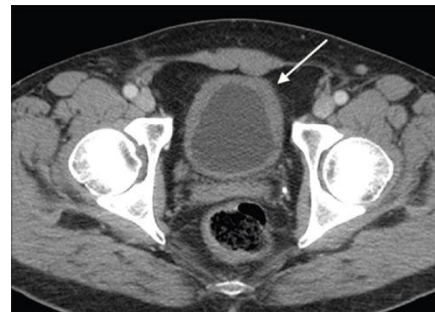8) A diabetic patient presents with a headache, decreased urination, weight loss, dry and itchy skin, from the following US what's your diagnosis?

- A. Normal kidney.
- B. Renal cyst.
- C. Atrophic kidney.
- D. Renal stone.



9) A 55 year old women, complains of pain with urination and pain in the lower abdomen, from the following CT scan what could be the diagnosis?

- A. Cystitis.
- B. Pyelonephritis.
- C. Ruptured bladder.
- D. Normal bladder.



Answers:

- | | | |
|------|------|------|
| 1) D | 4) B | 7) A |
| 2) B | 5) C | 8) C |
| 3) B | 6) D | 9) A |

For any questions, suggestions or useful information don't hesitate to contact us: