

Renal block

Abdulrhman Aleisa

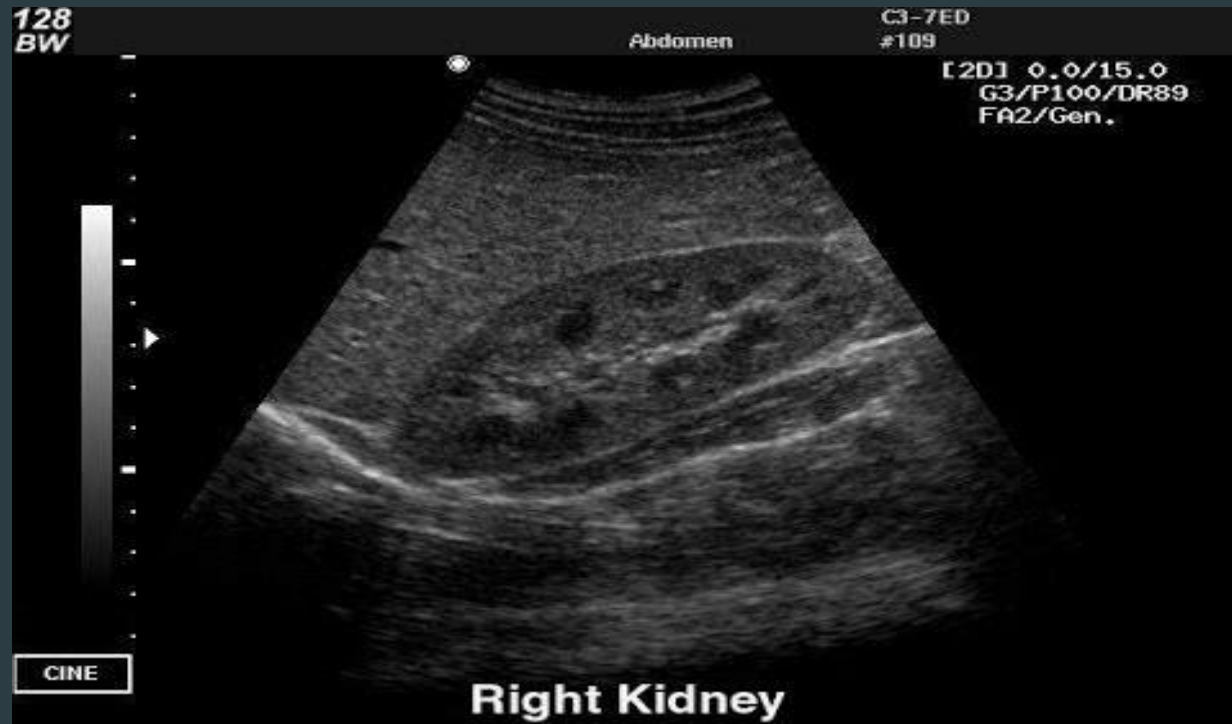Radiology department

objective

- ▶ Modality used for assessment of the urinary system
 - ▶ X-ray
 - ▶ us
 - ▶ Ct
 - ▶ MRI
 - ▶ Nuclear
- ▶ Normal anatomy
- ▶ Common pathologies
 - ▶ Kidney
 - ▶ Ureter
 - ▶ Bladder
 - ▶ Urethra

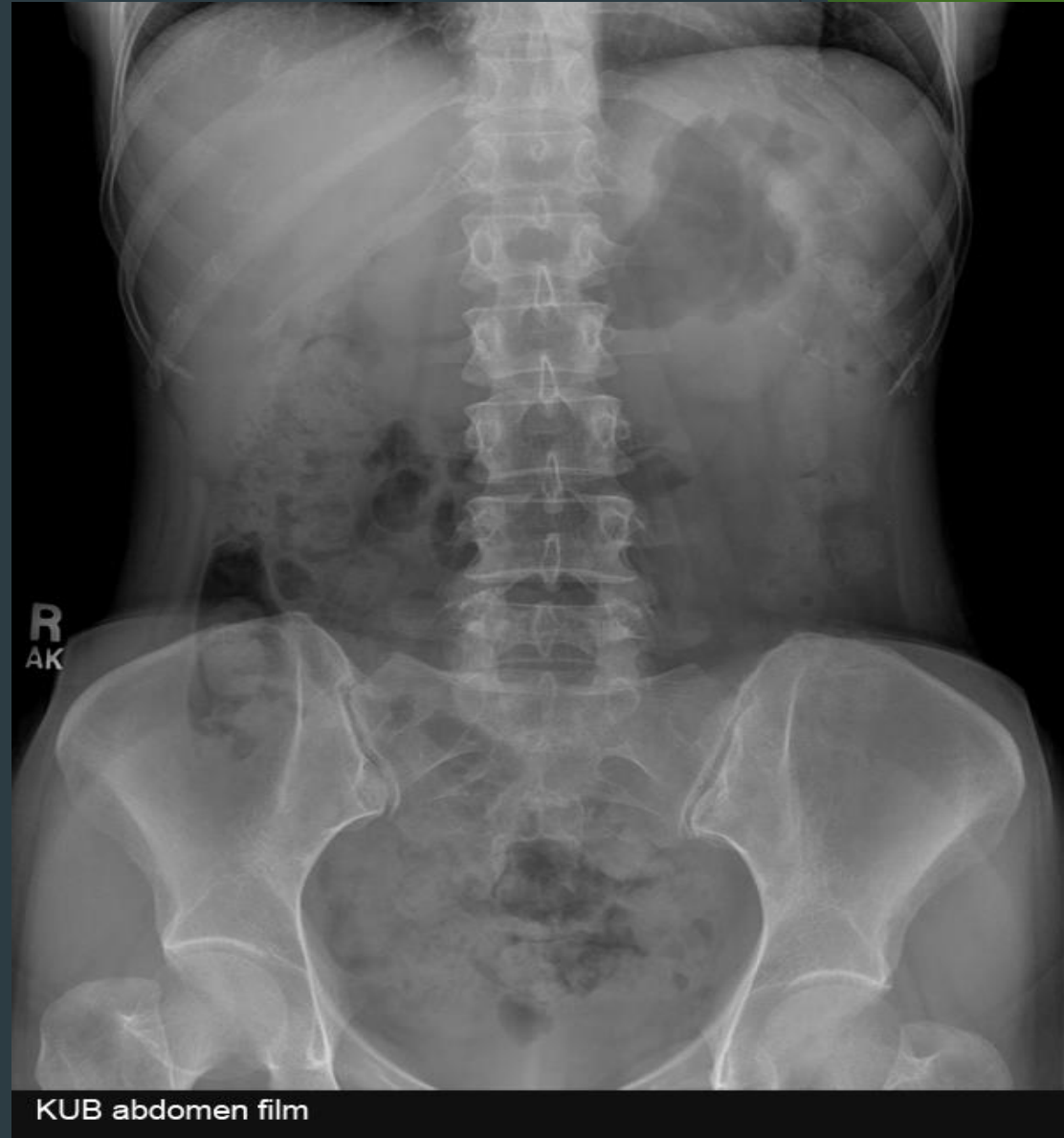Modalities used

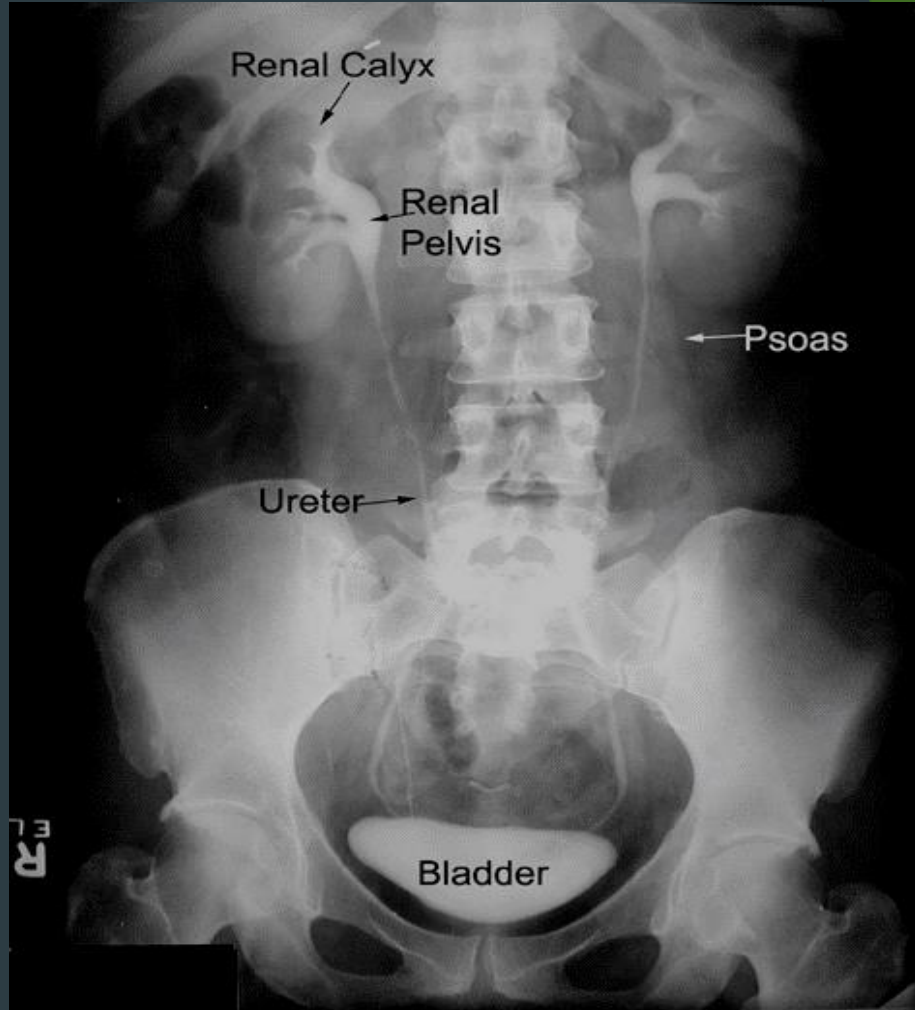
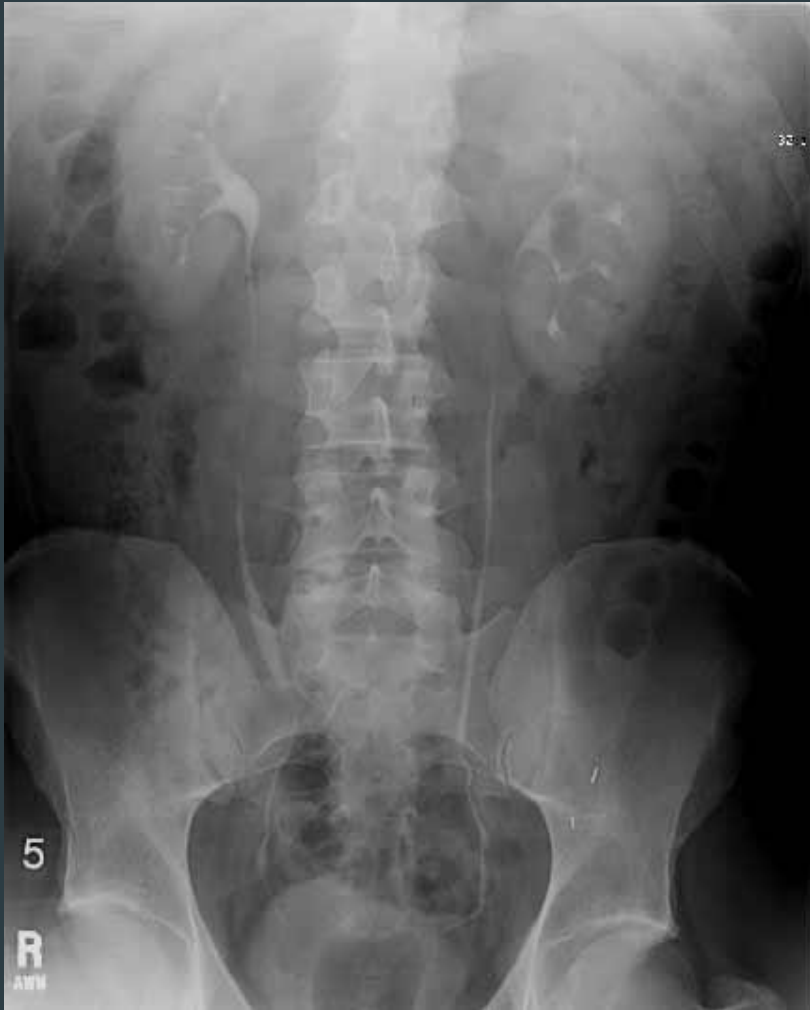- ▶ US
 - ▶ Pros (no ionizing radiation , inexpensive , portable)
 - ▶ Cons (operator dependent, time consuming ,)



Modalities used

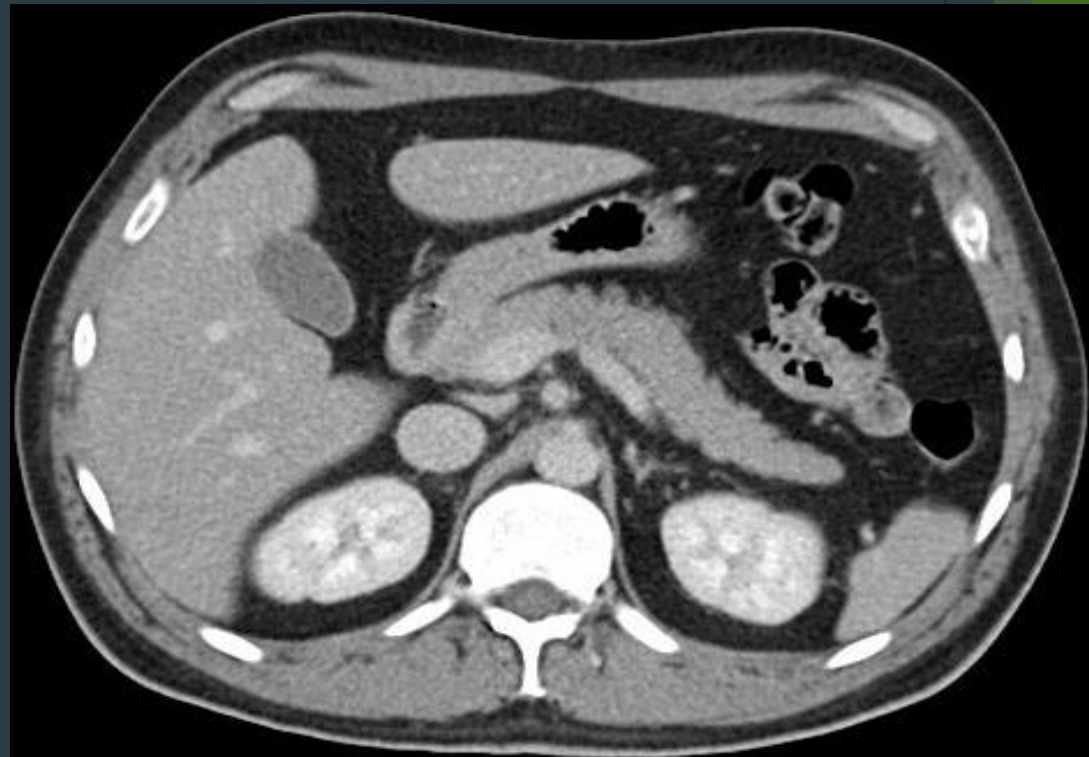- ▶ X rays
 - ▶ Pros (inexpensive , quick)
 - ▶ Cons (ionizing radiation , not definitive)

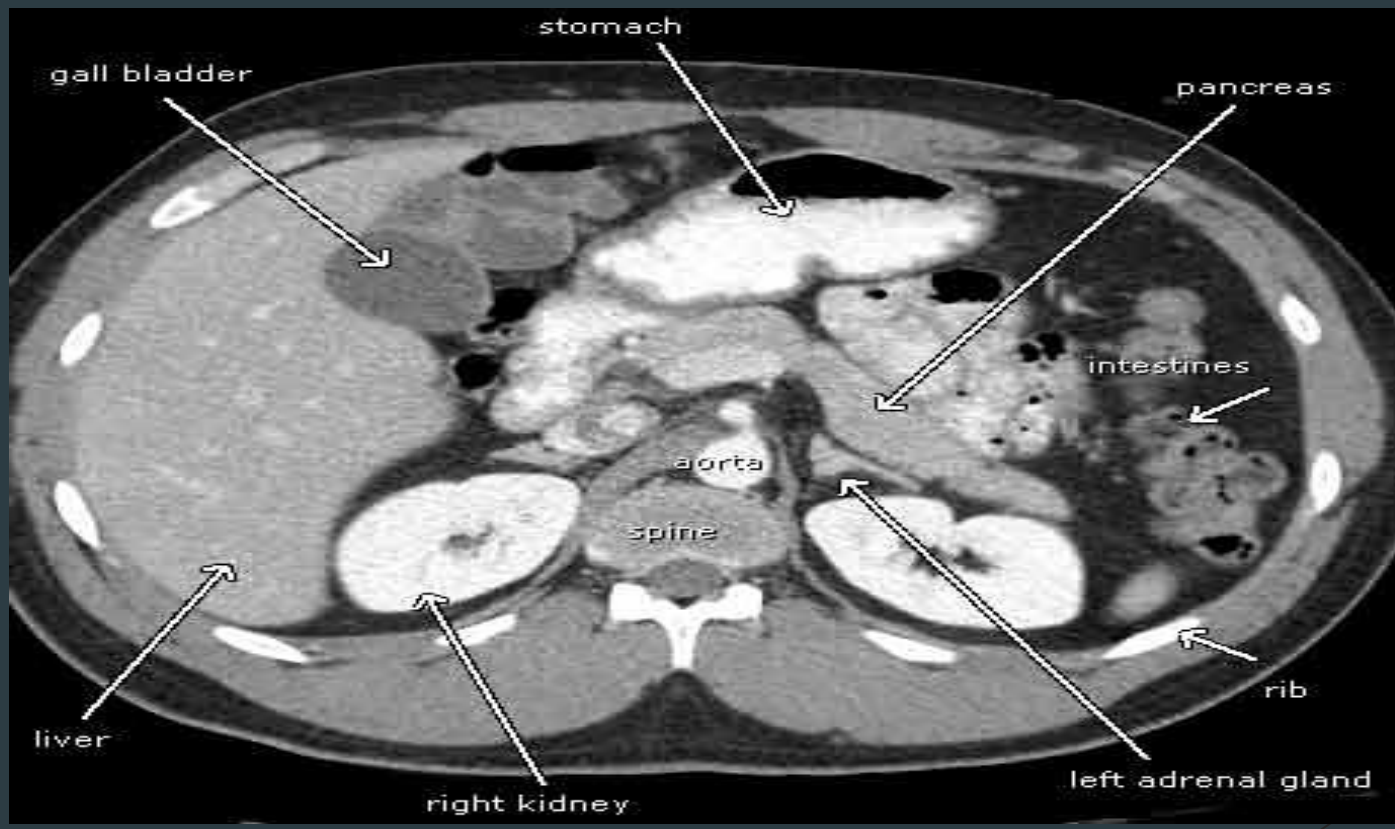




Modalities used

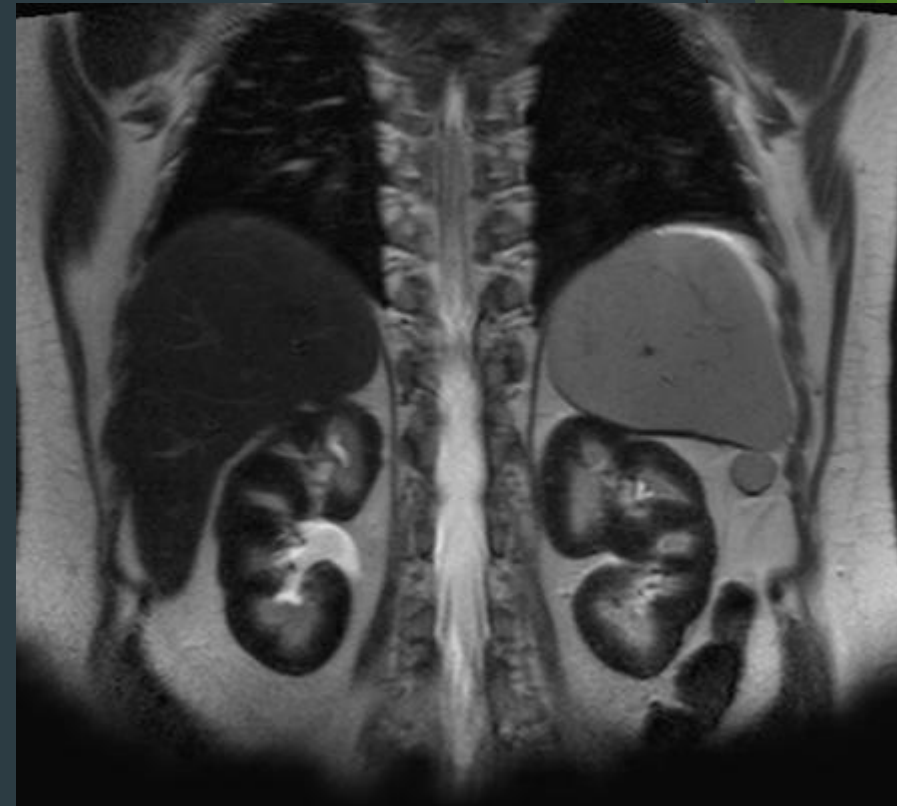
- ▶ CT
 - ▶ Pros (quick , a lot of information)
 - ▶ Cons (ionizing radiation , expensive)

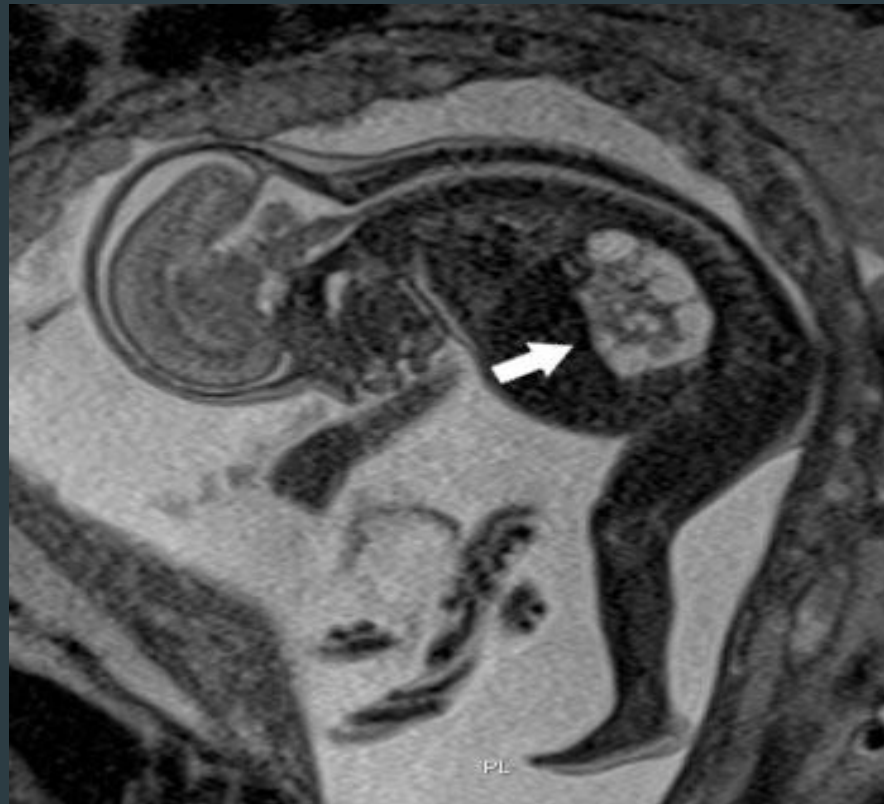



Modalities used

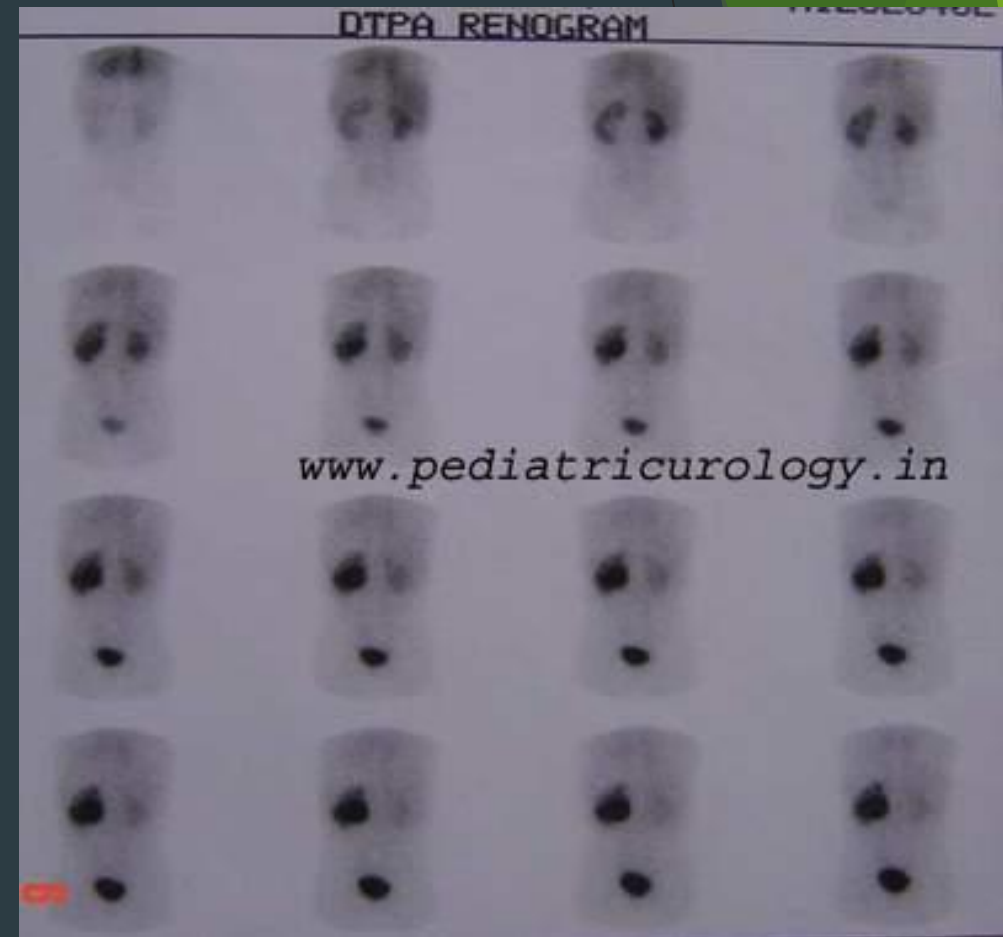- ▶ MRI
 - ▶ Pros (no ionizing radiation , a lot of information)
 - ▶ Cons (expensive , time consuming)



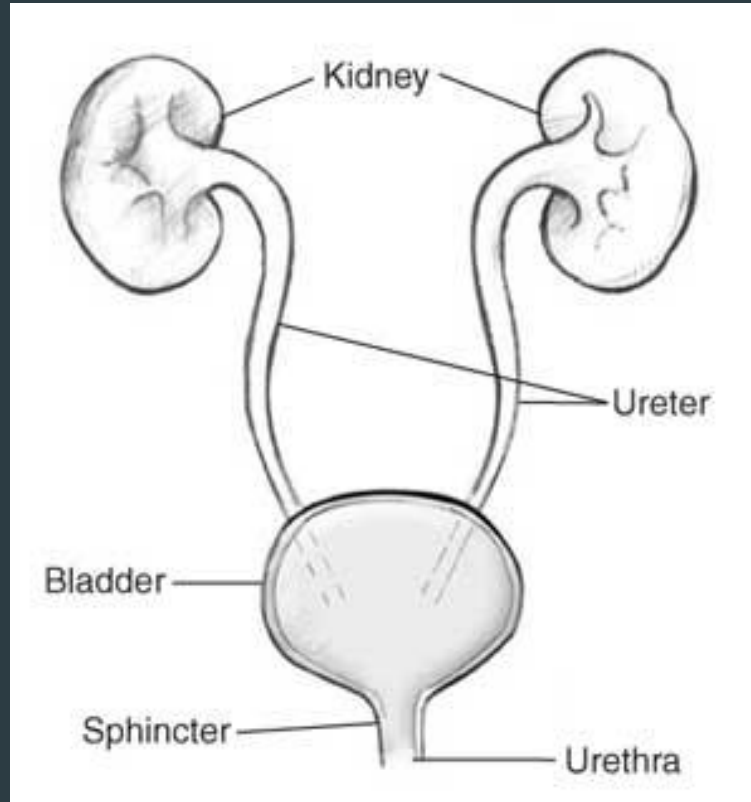


Modalities used

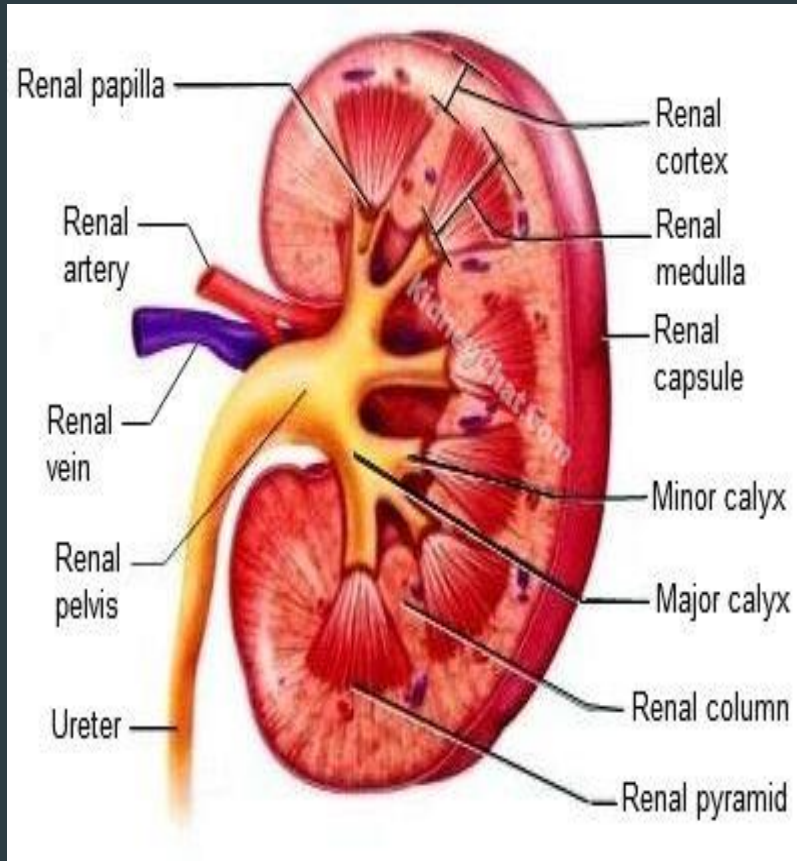
- ▶ Nuclear scans
 - ▶ Pros (assess the function)
 - ▶ Cons (time consuming , radioactive materials)



Anatomy of the urinary system



kidneys



Gross Anatomy of Kidney

Copyright © The McGraw-Hill Companies, Inc. Permission required for reproduction or display.

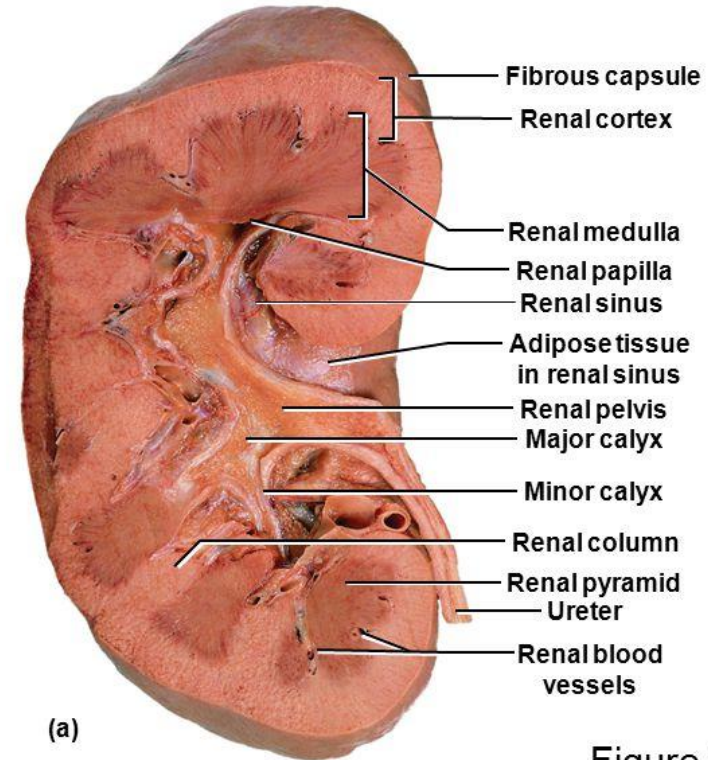
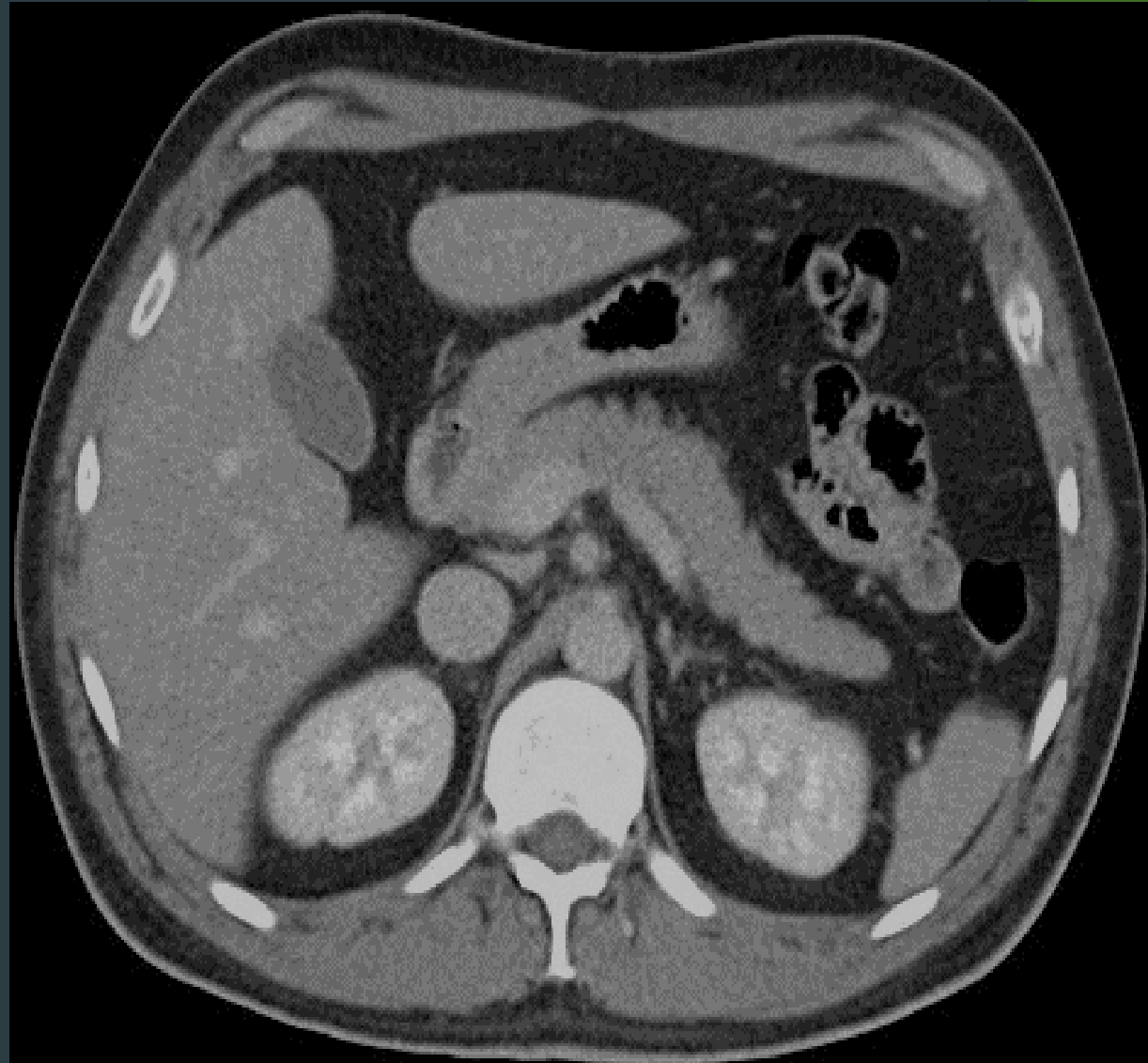
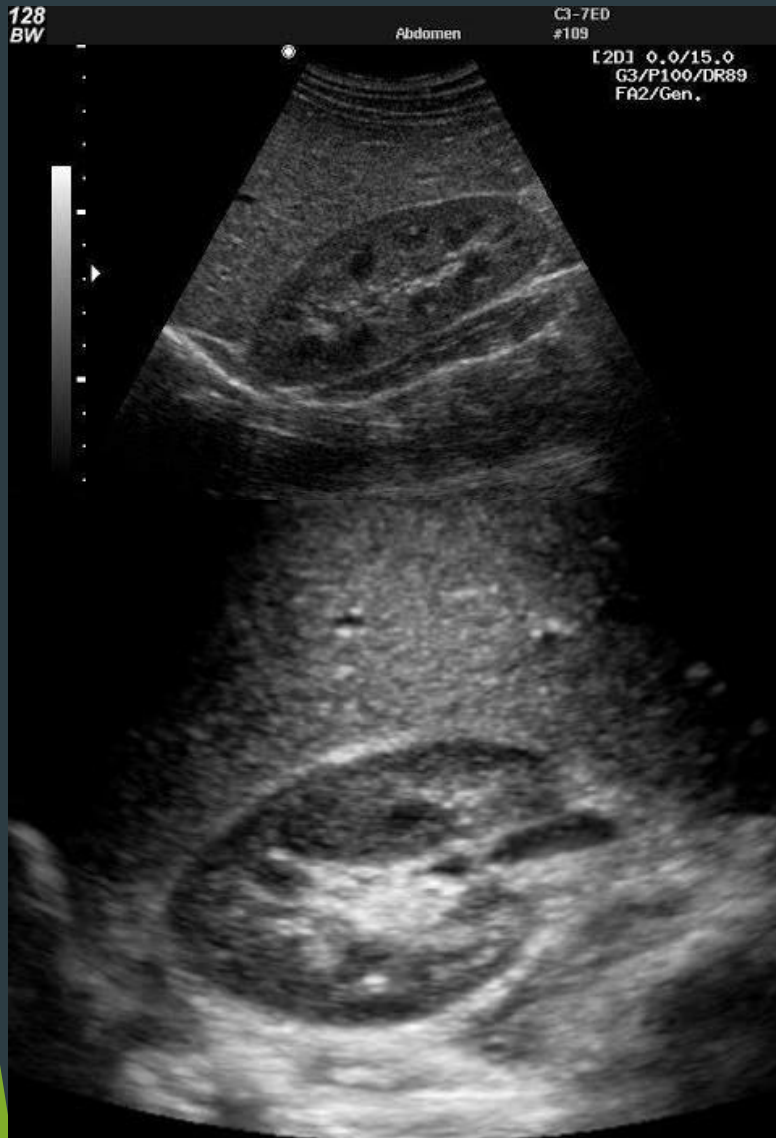
Figure 23.4a

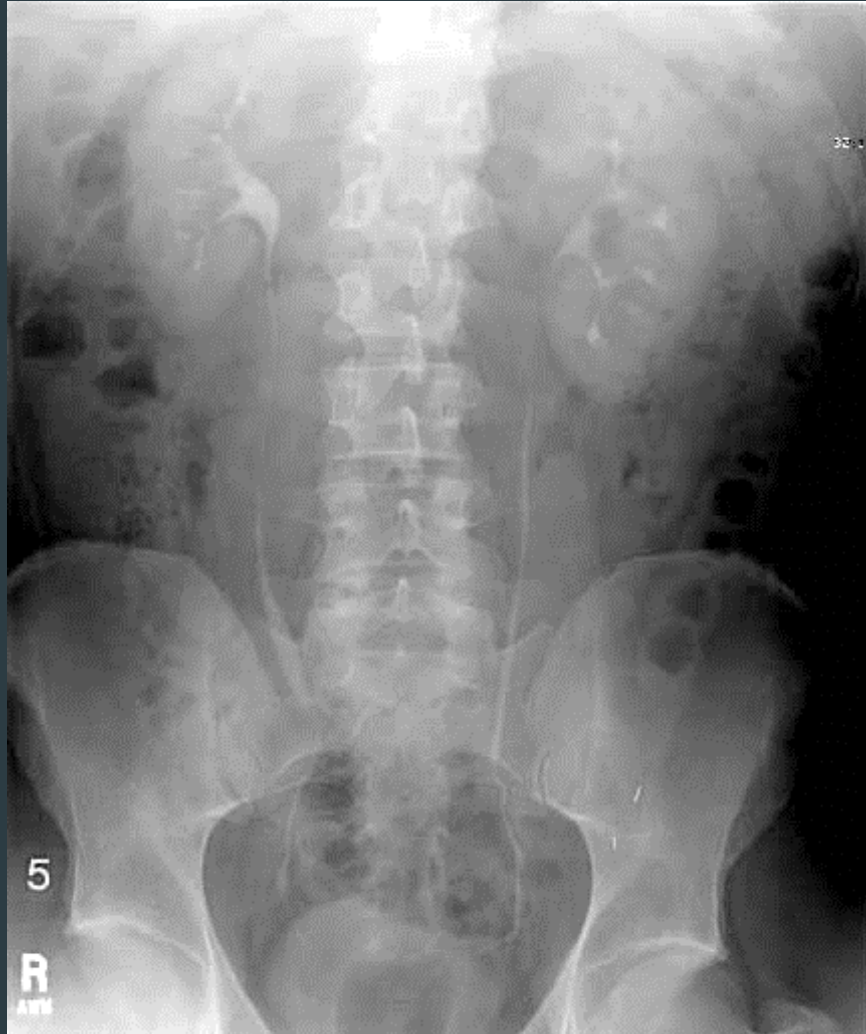23-10

Ralph Hutchings/Visuals Unlimited

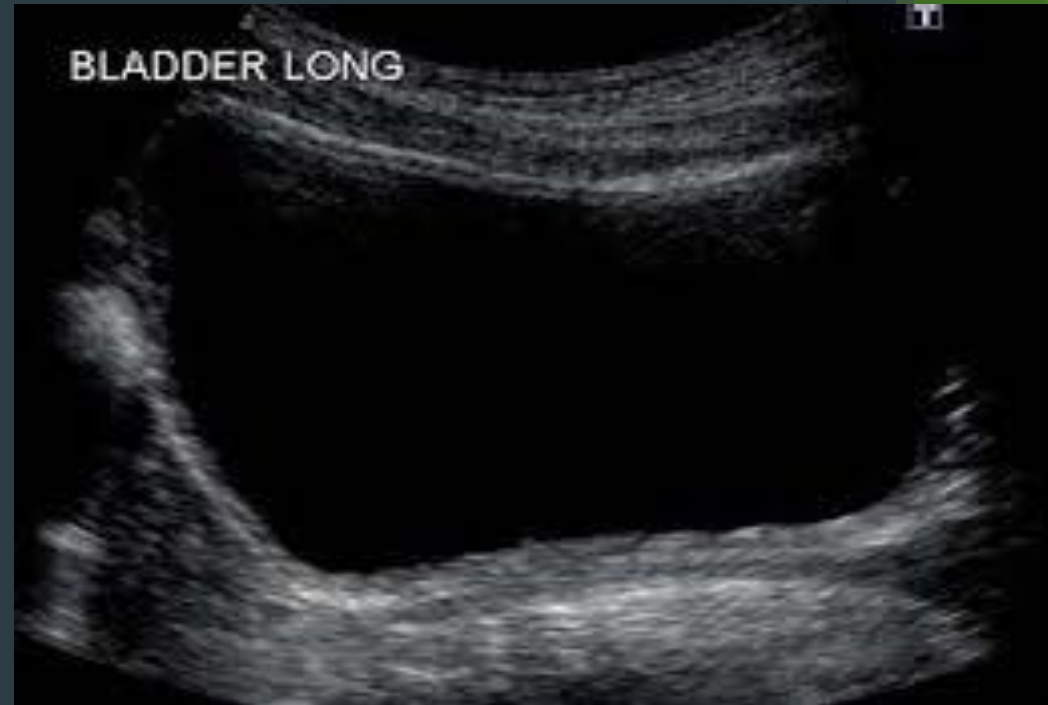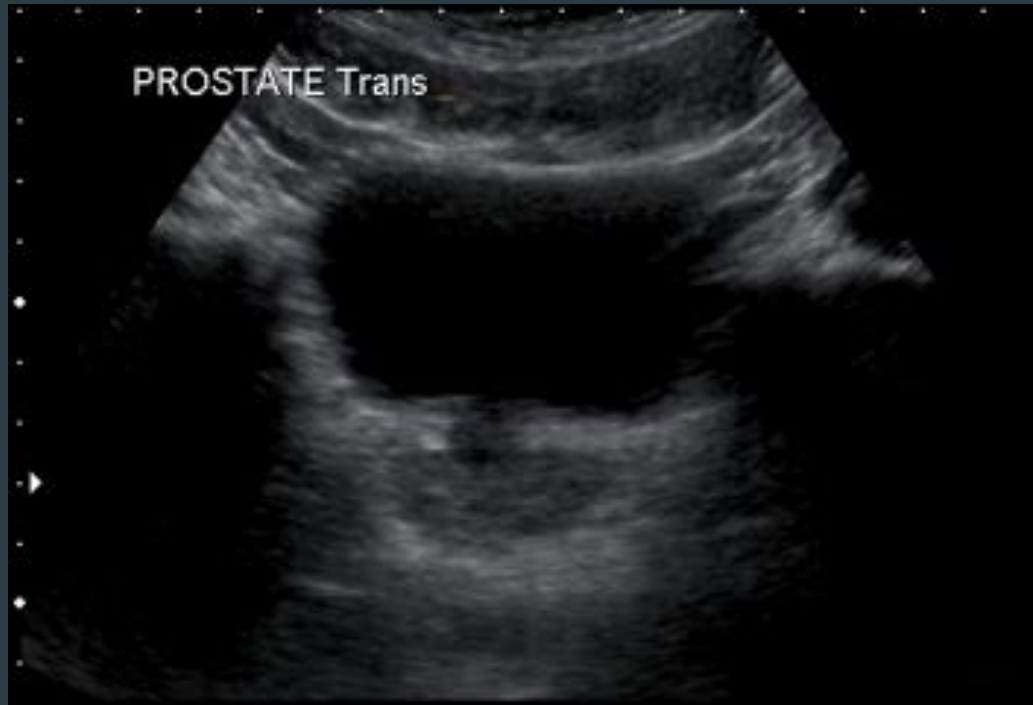
kidneys



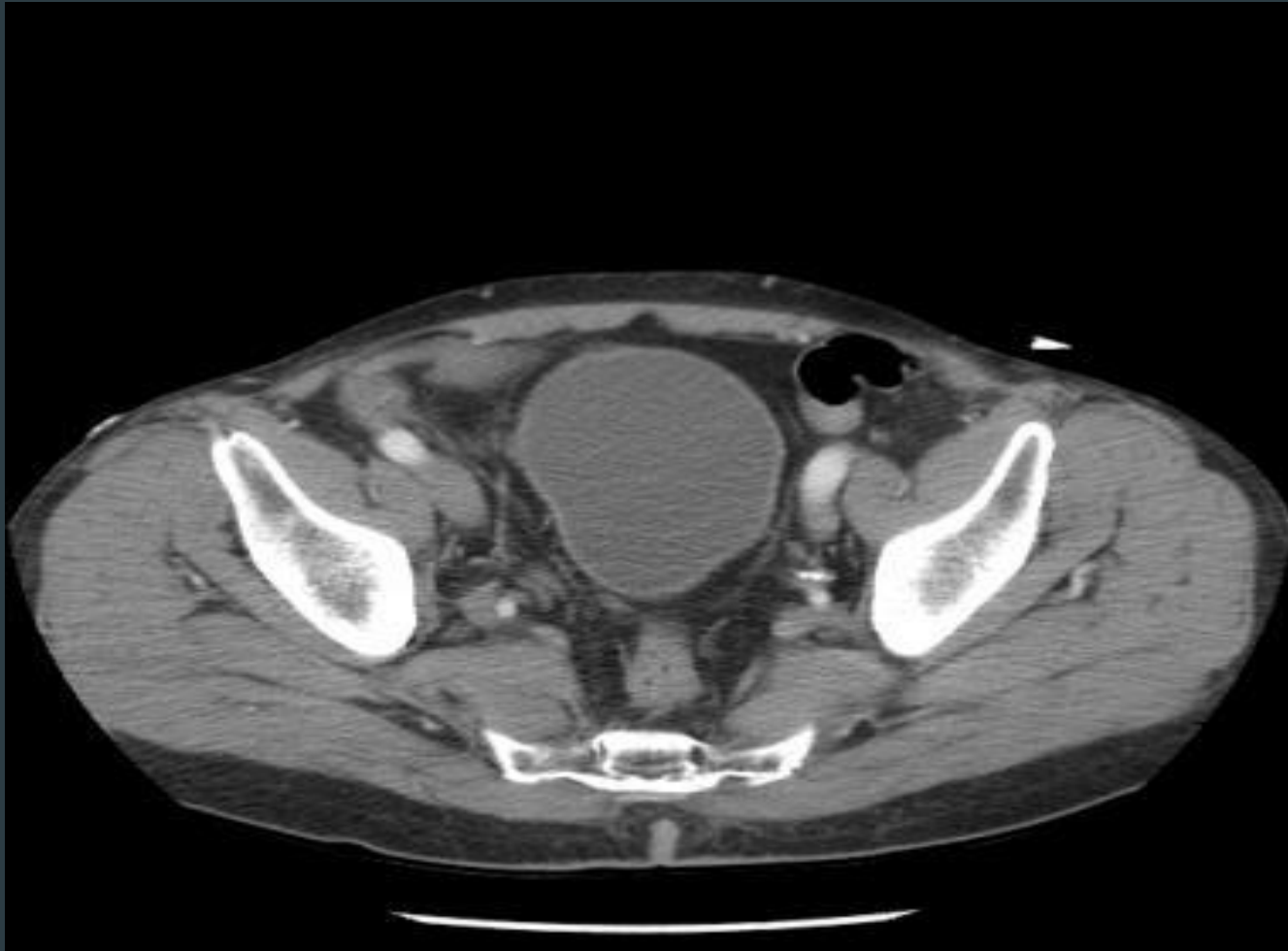ureters



Urinary bladder

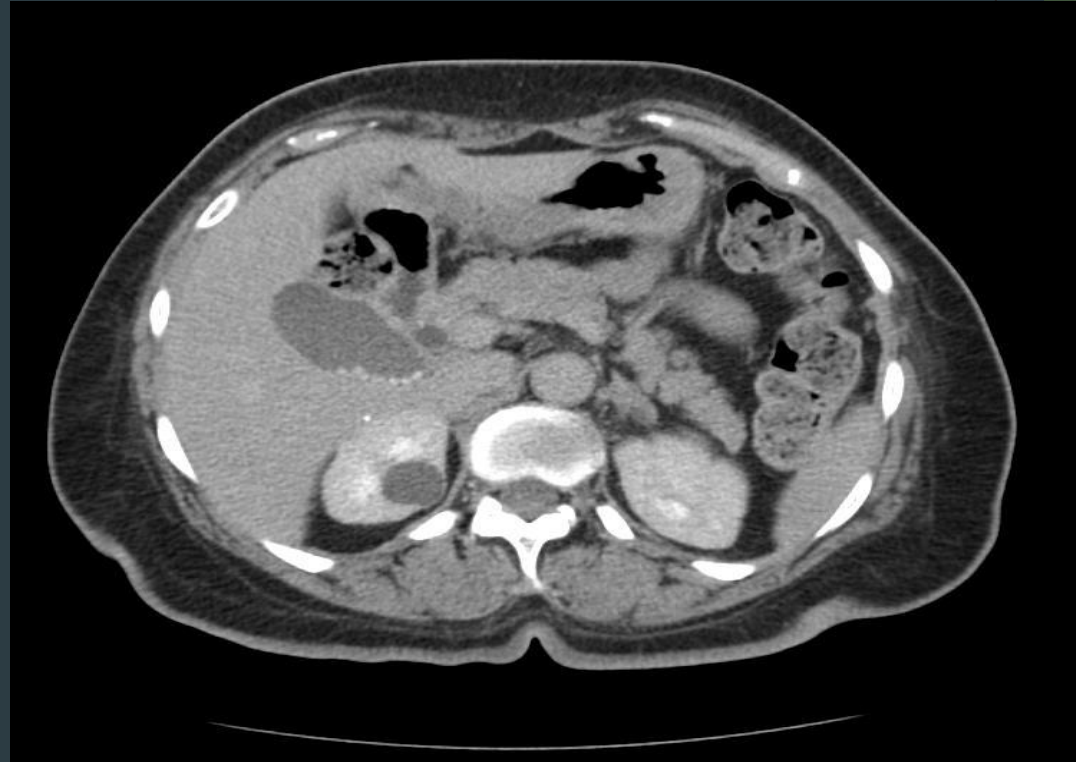
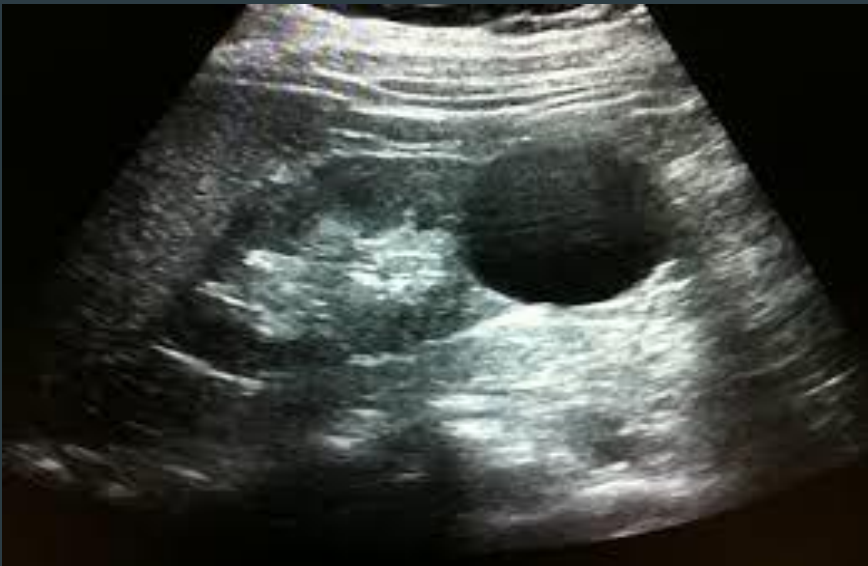
Urinary bladder



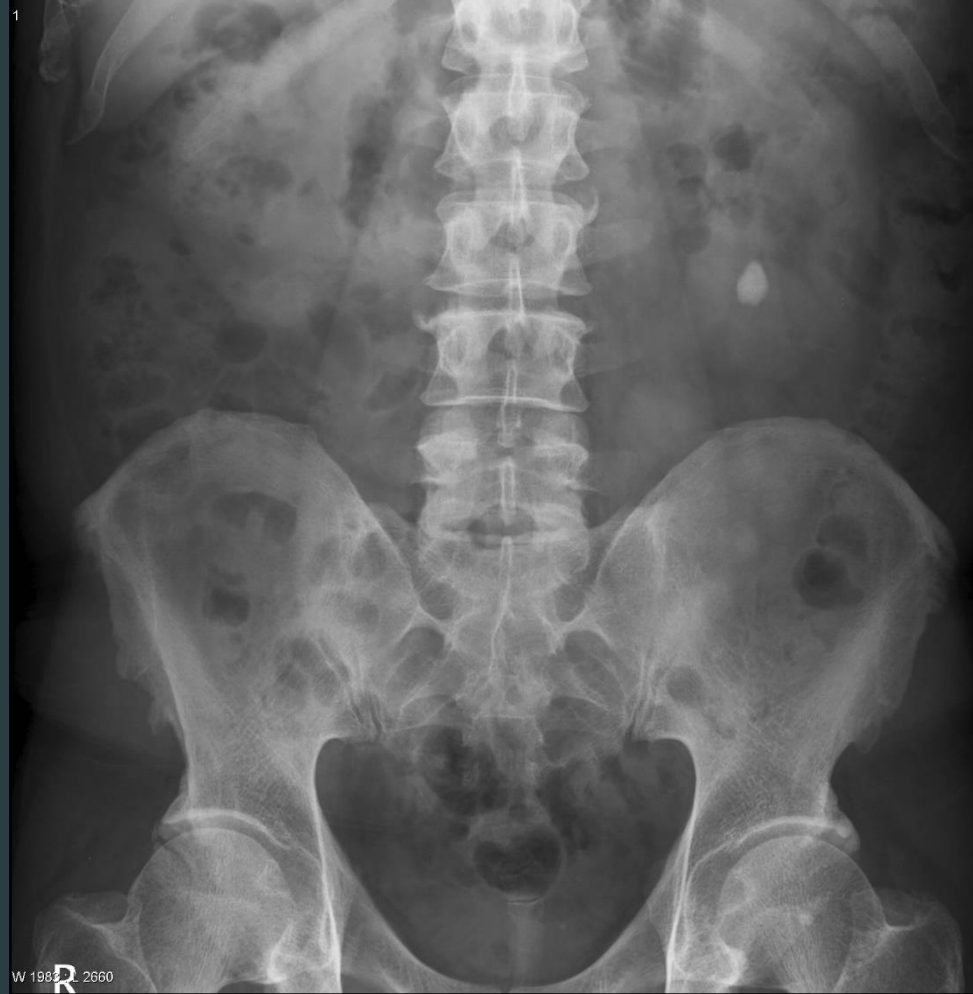Common Kidney pathologies

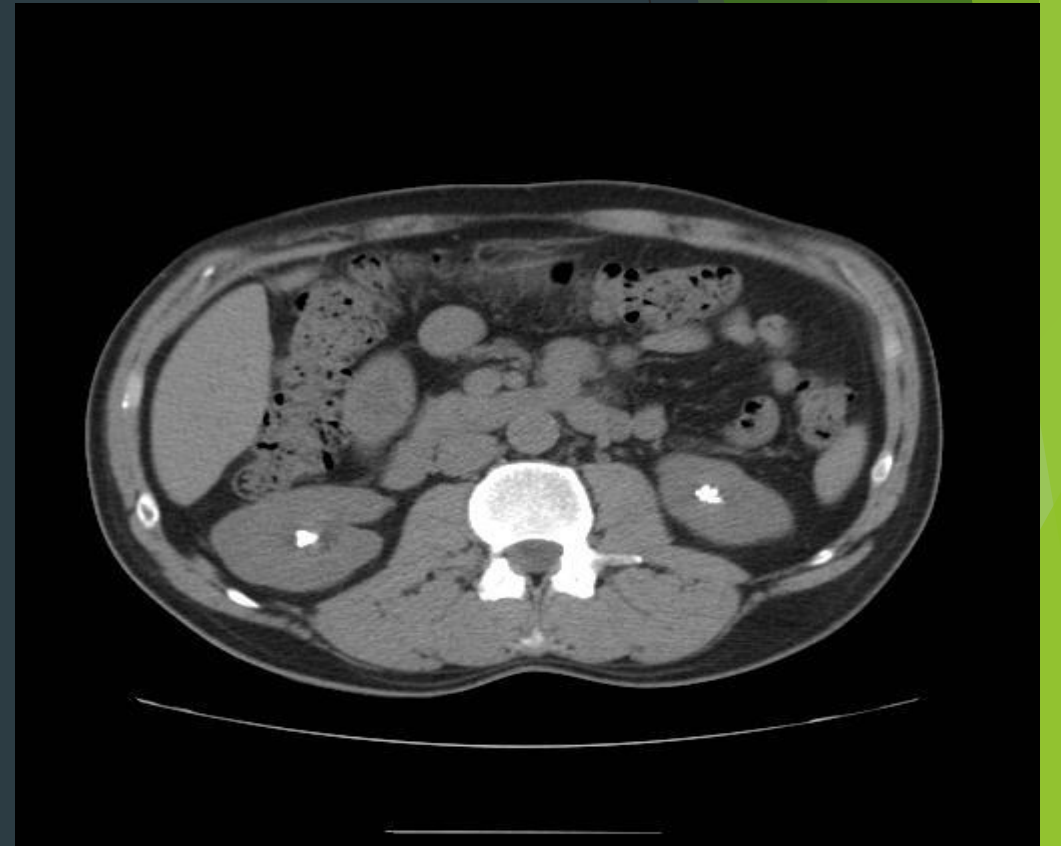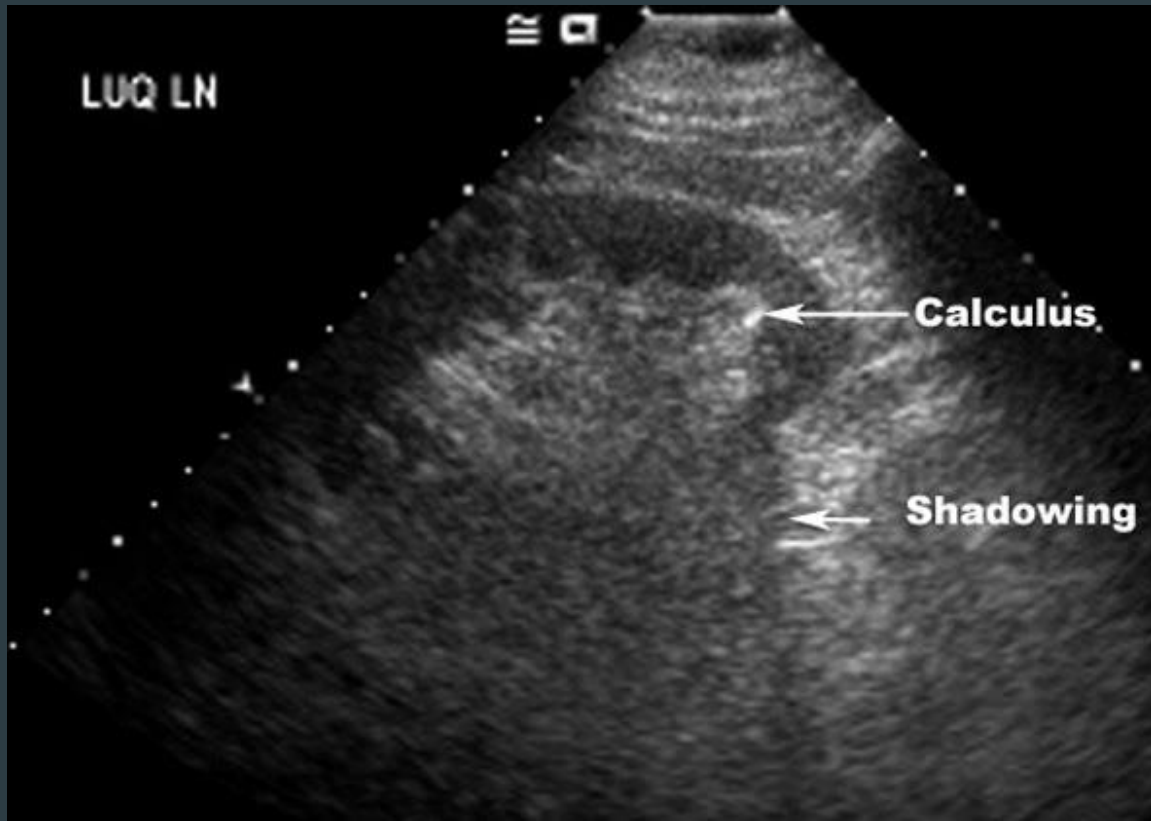
- ▶ Cysts (benign , common , bosniak classification)



Common Kidney pathologies

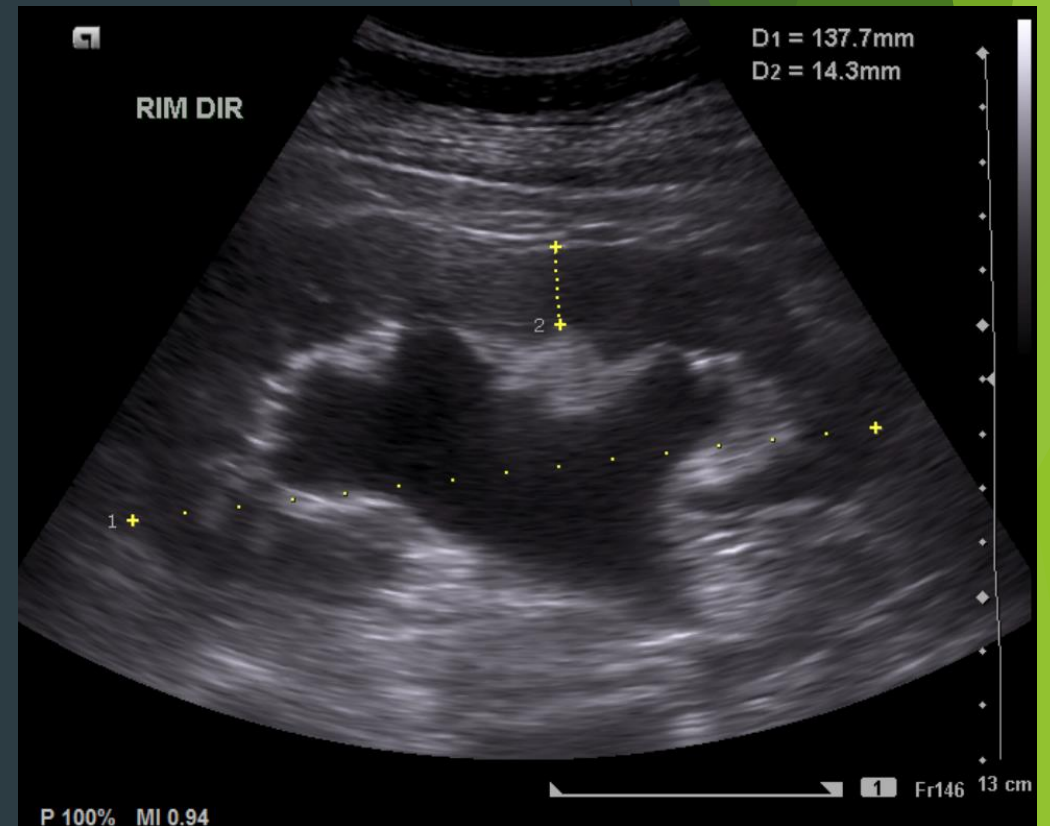
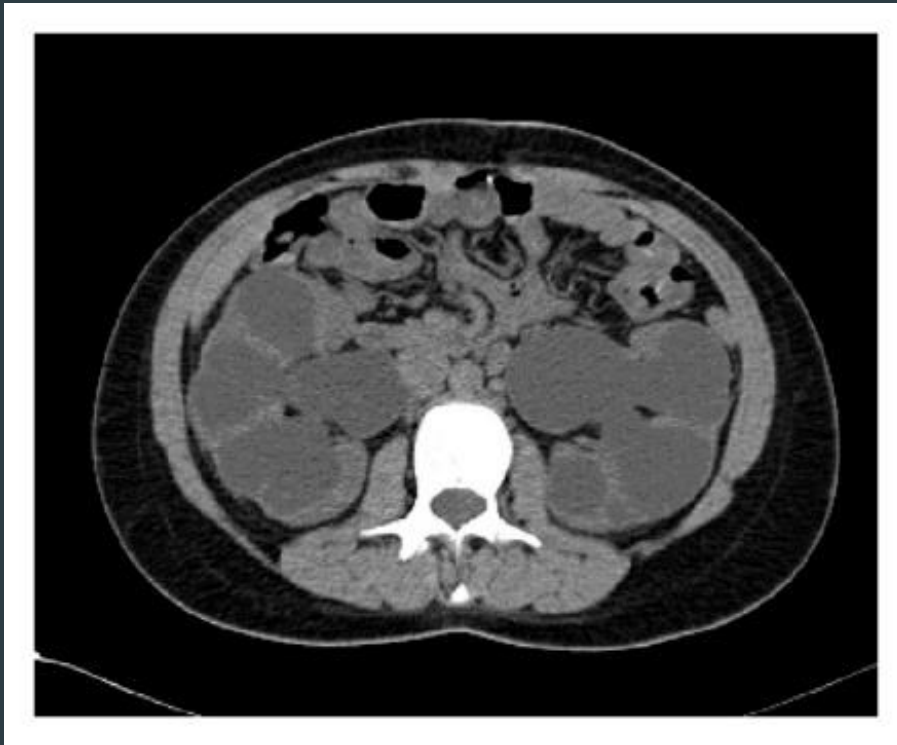
- ▶ Stones :
 - ▶ Radio-opaque (calcium , struvite)
 - ▶ Radio-lucent (uric acid , cysteine)





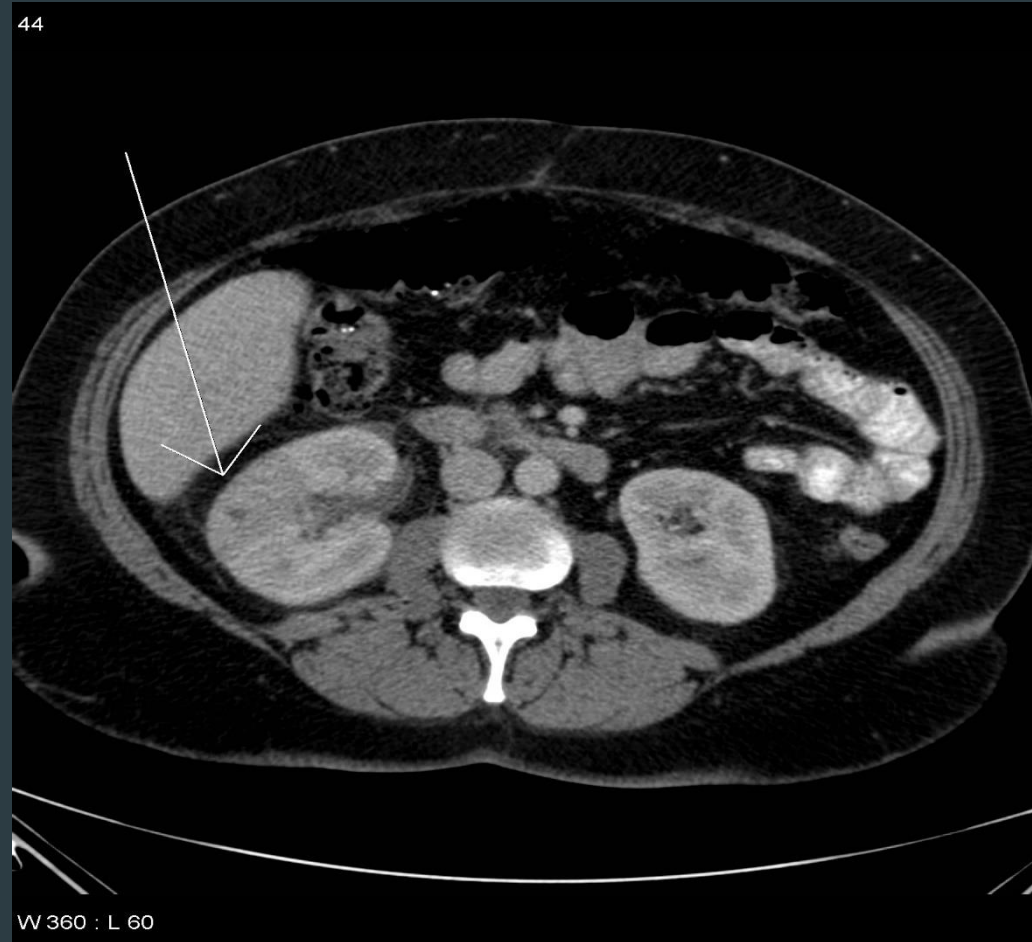Common Kidney pathologies

► hydronephrosis

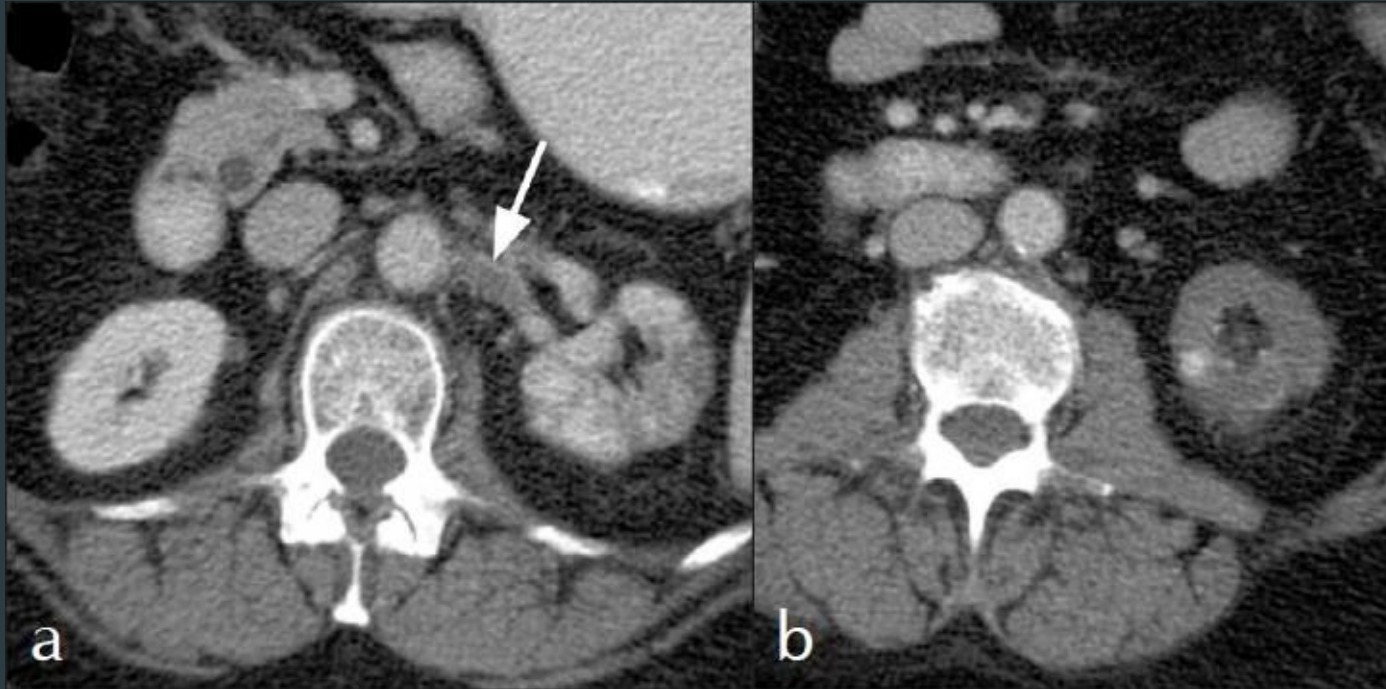


Common Kidney pathologies

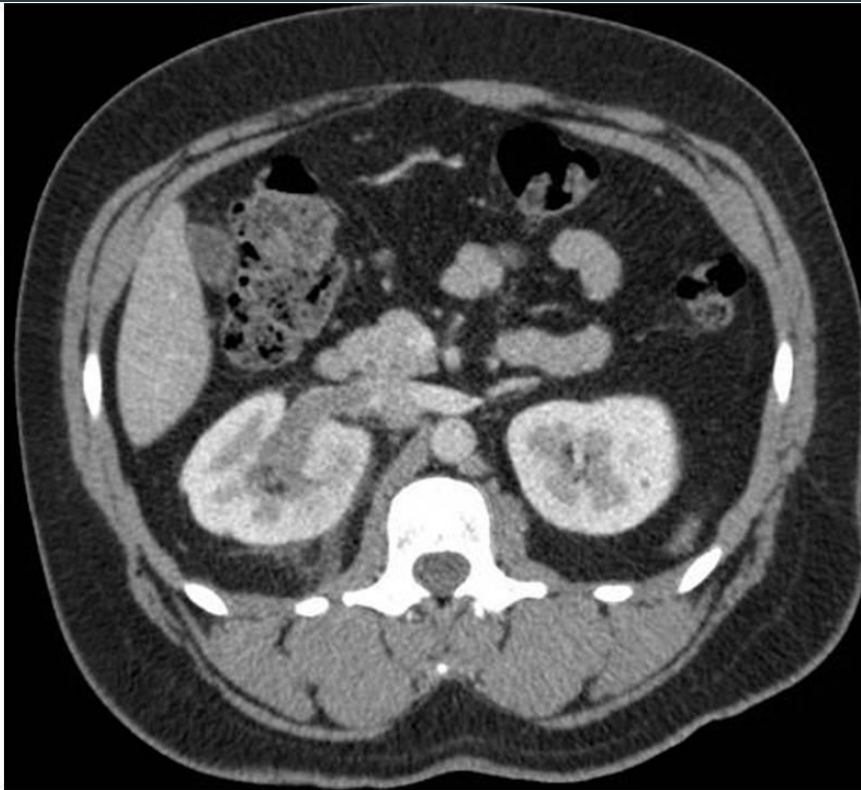
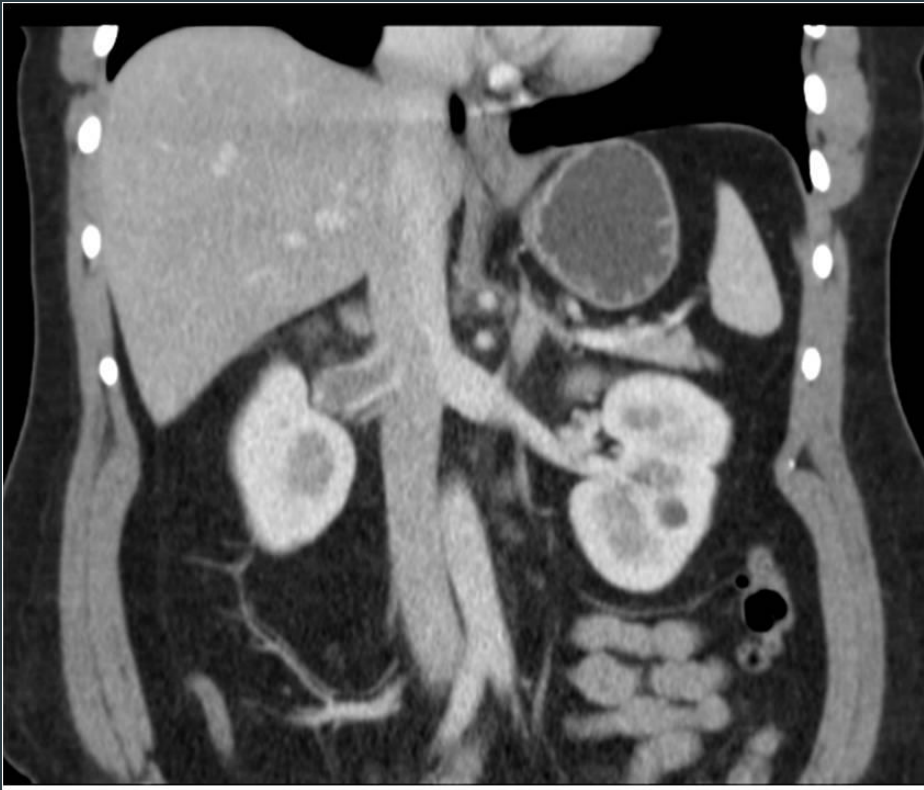- ▶ Pyelonephritis



Common Kidney pathologies

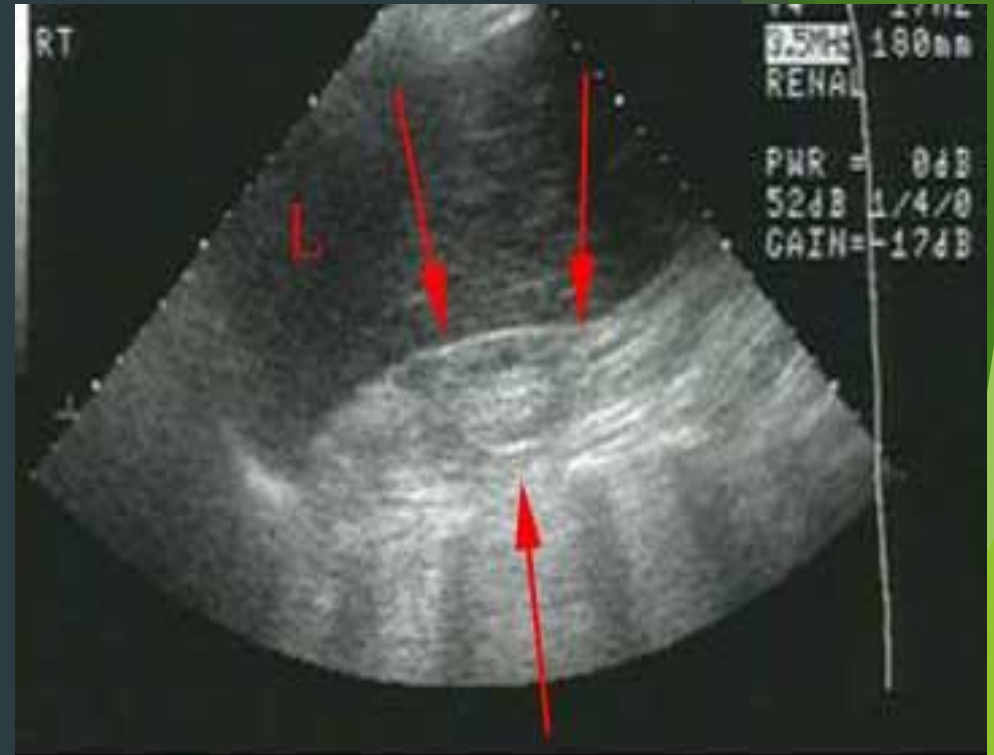
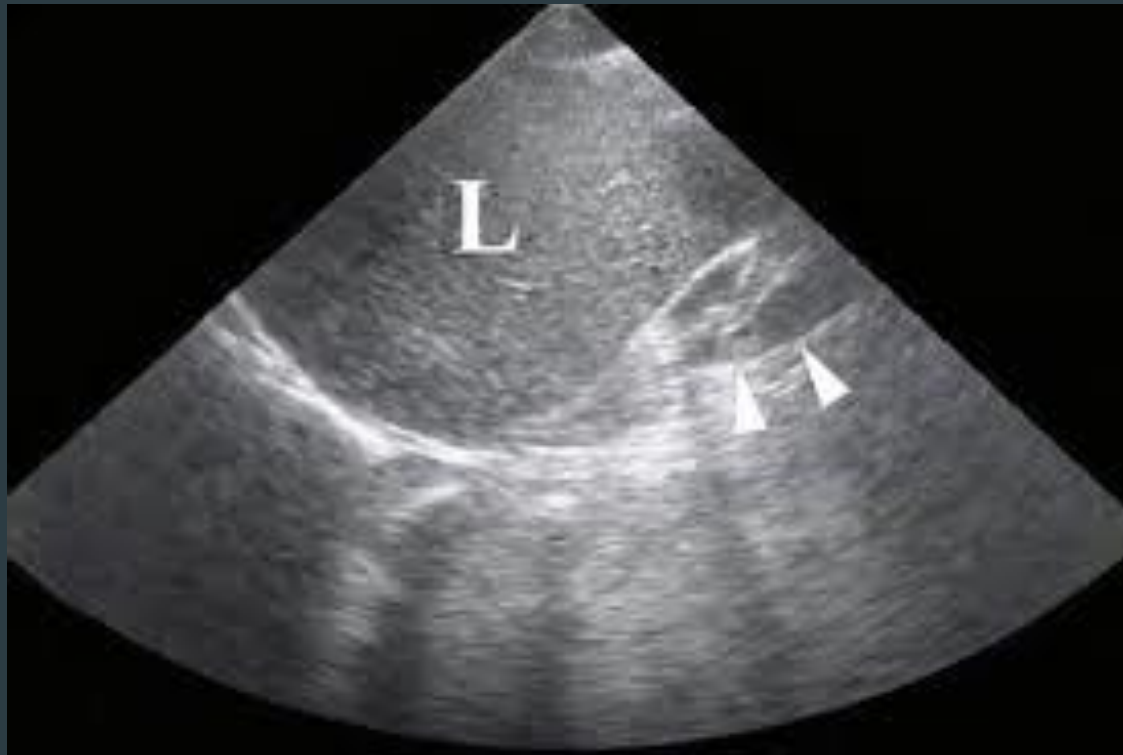

Common Kidney pathologies

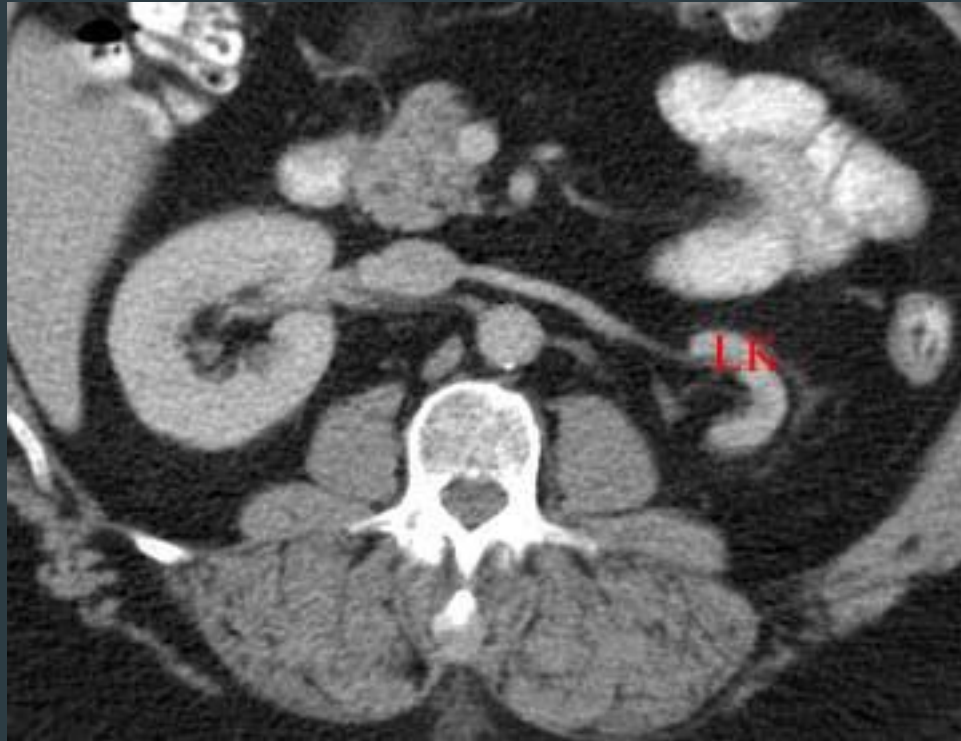


Common Kidney pathologies

► ESRD

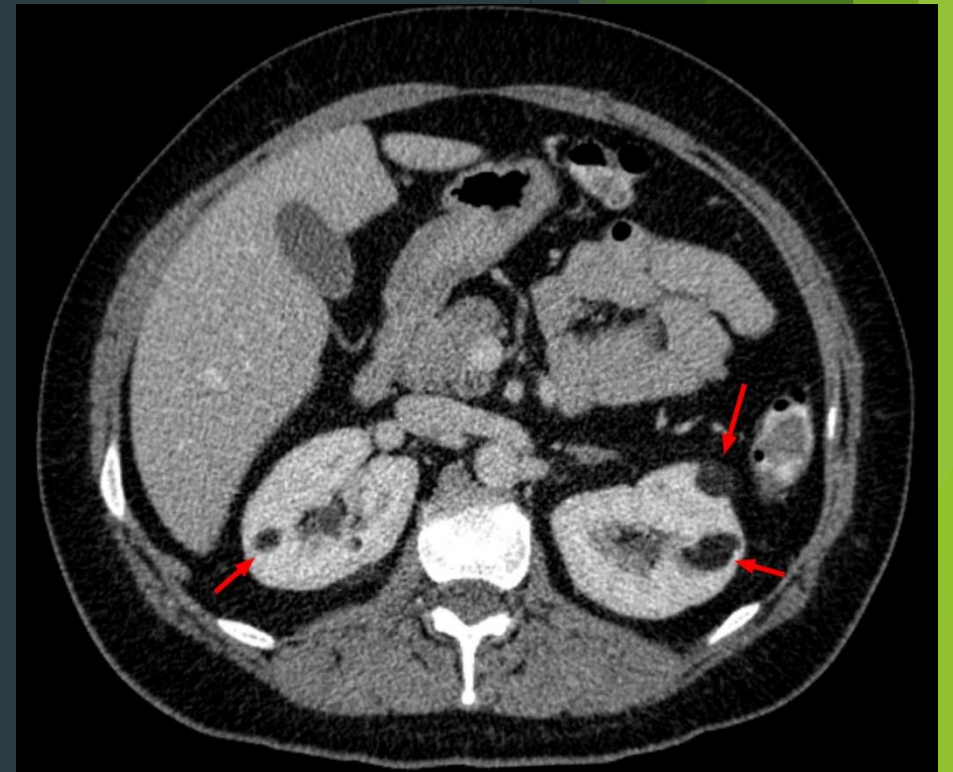
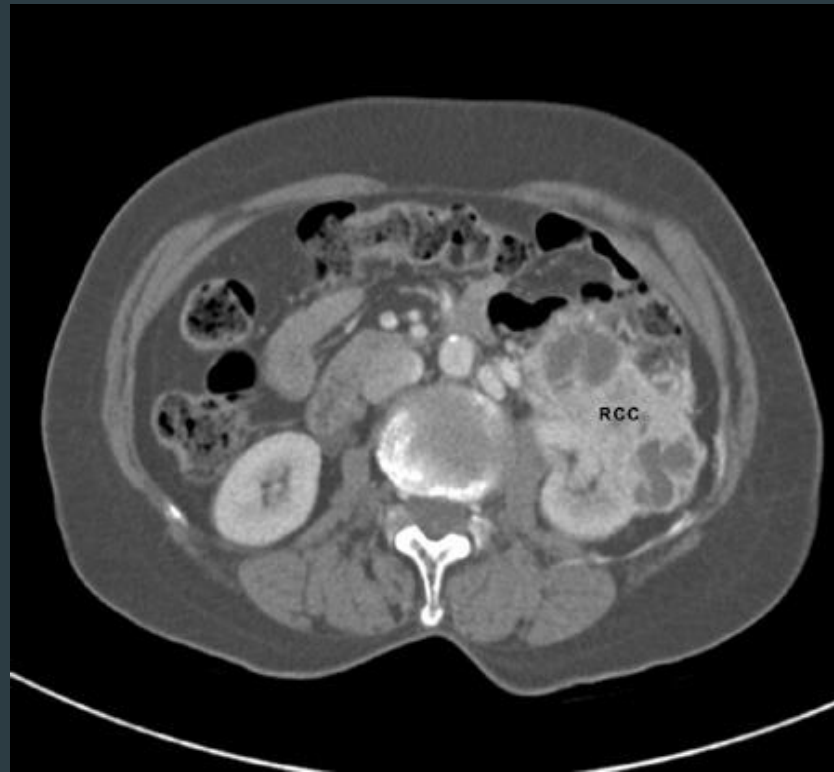


Common Kidney pathologies



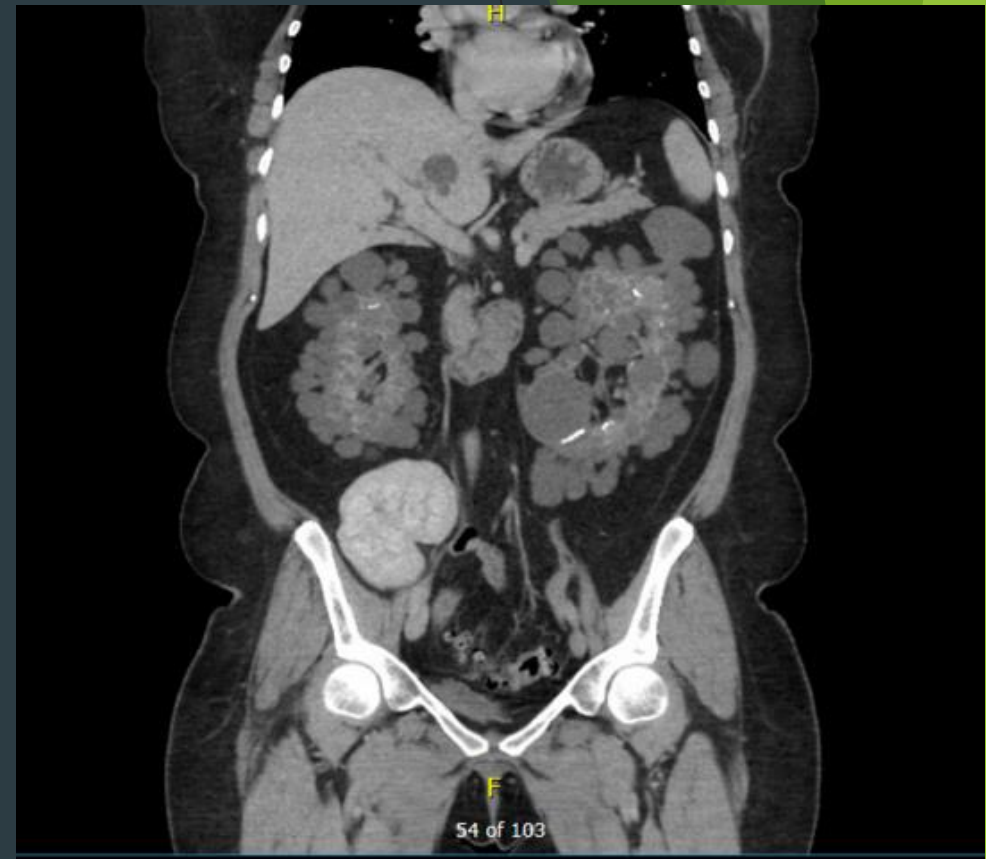
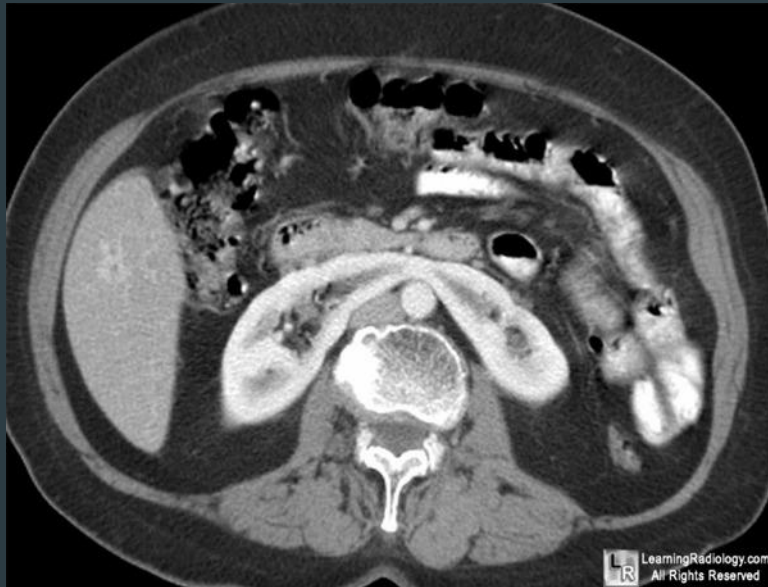Common Kidney pathologies

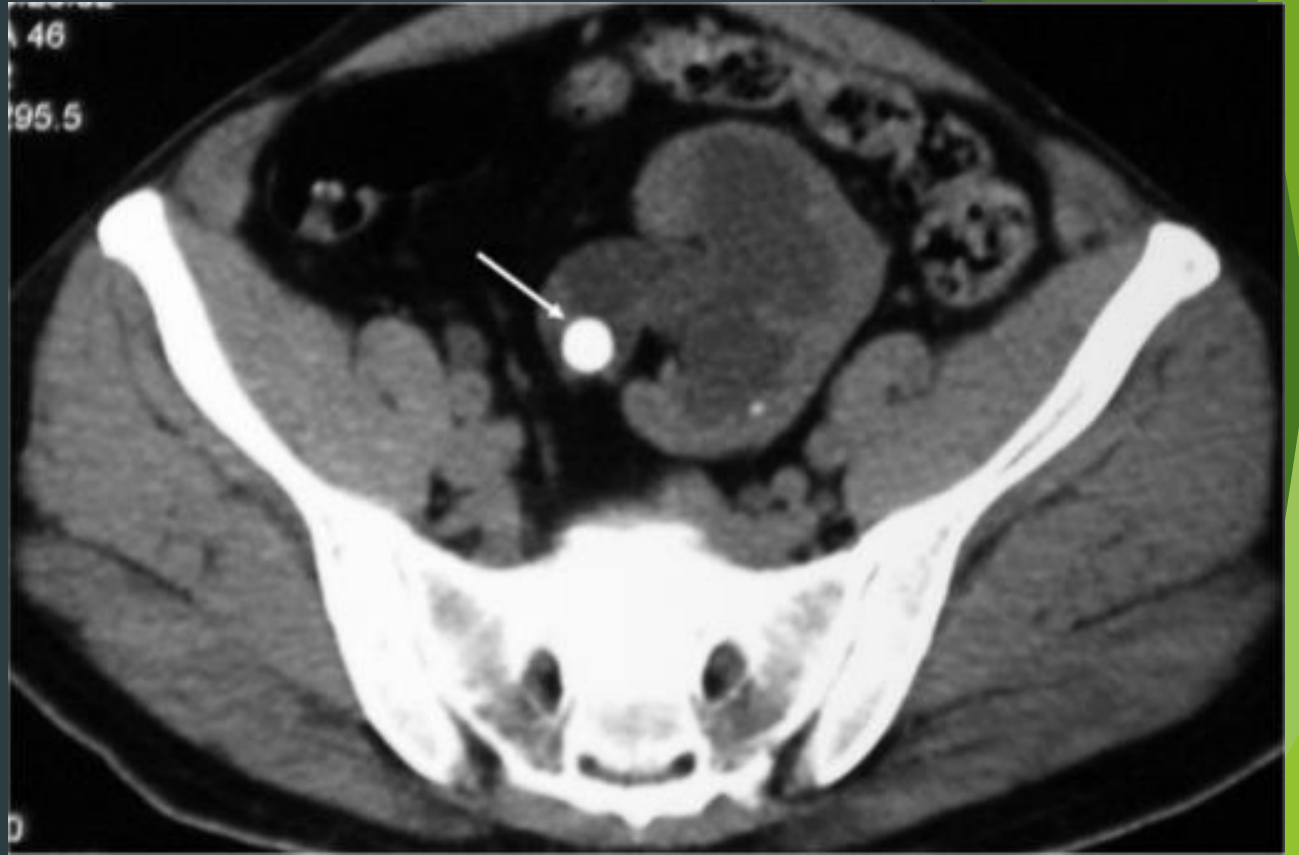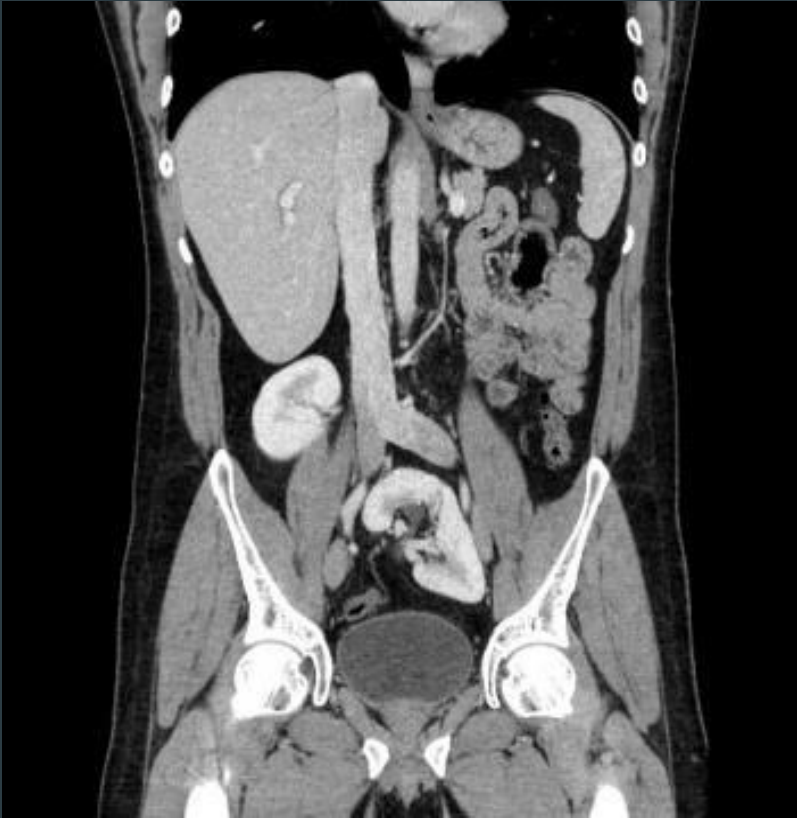- ▶ tumors



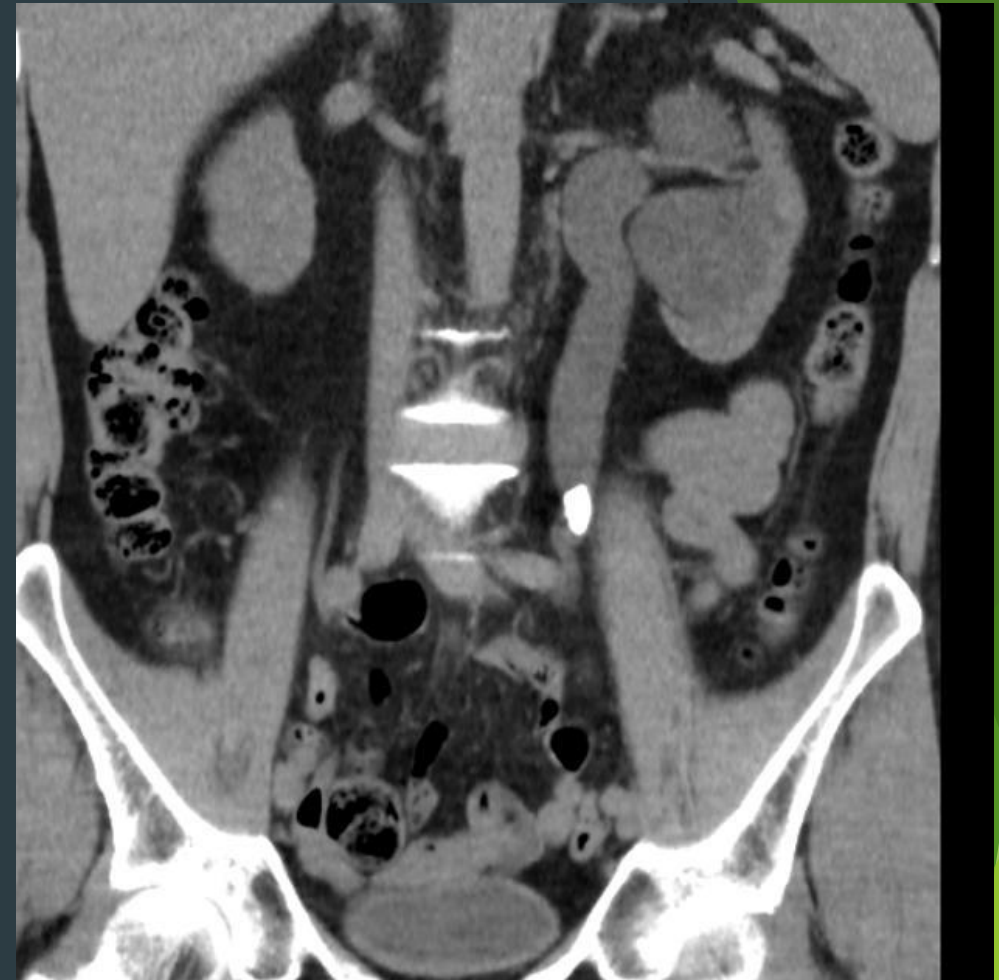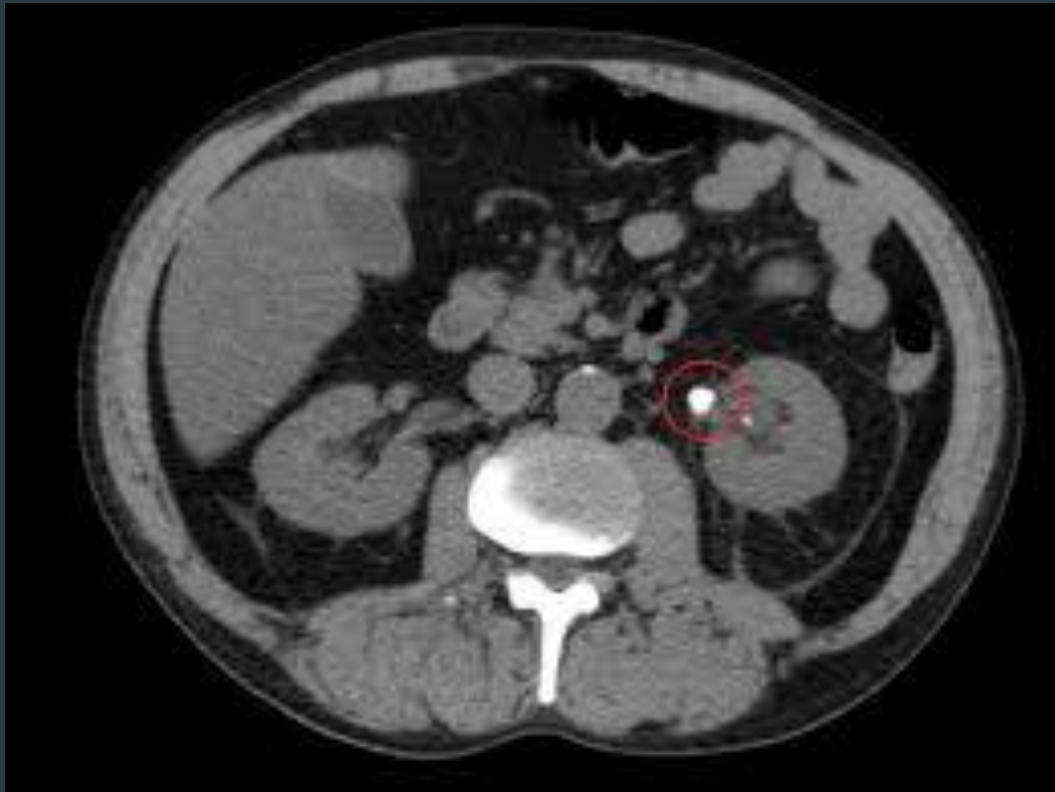
Common Kidney pathologies

- ▶ Congenital



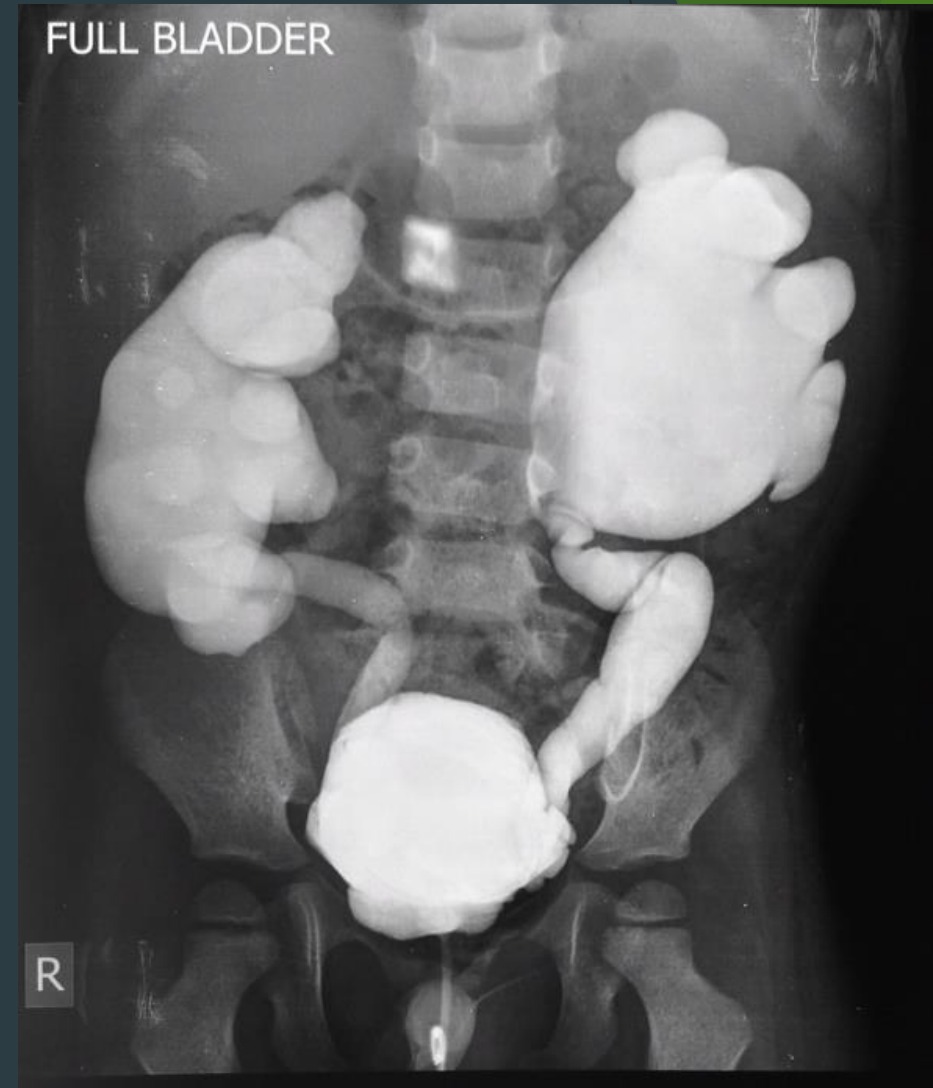

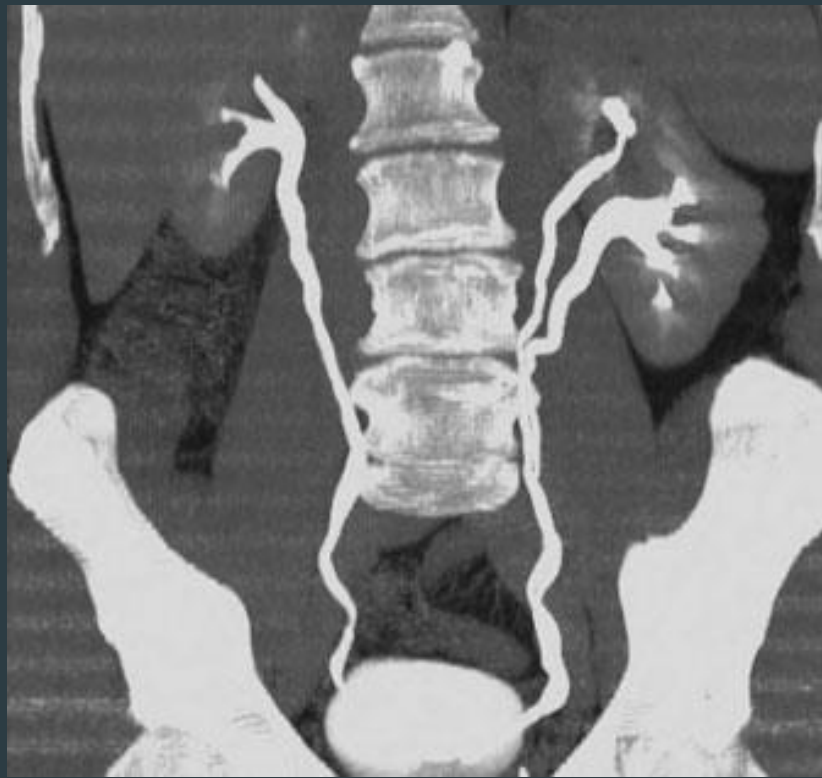
Common pathologies



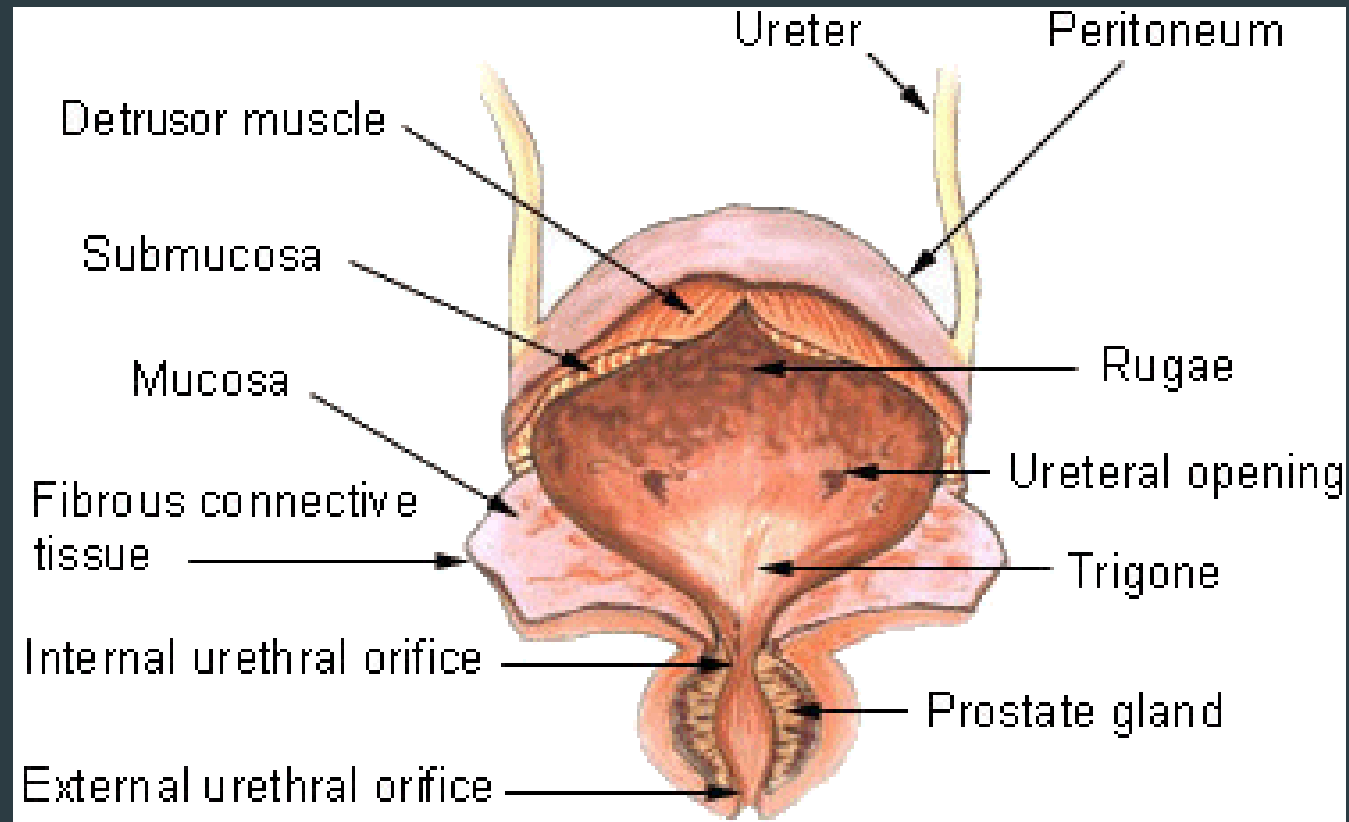
Common pathologies

- ▶ vesicoureteral reflux disease



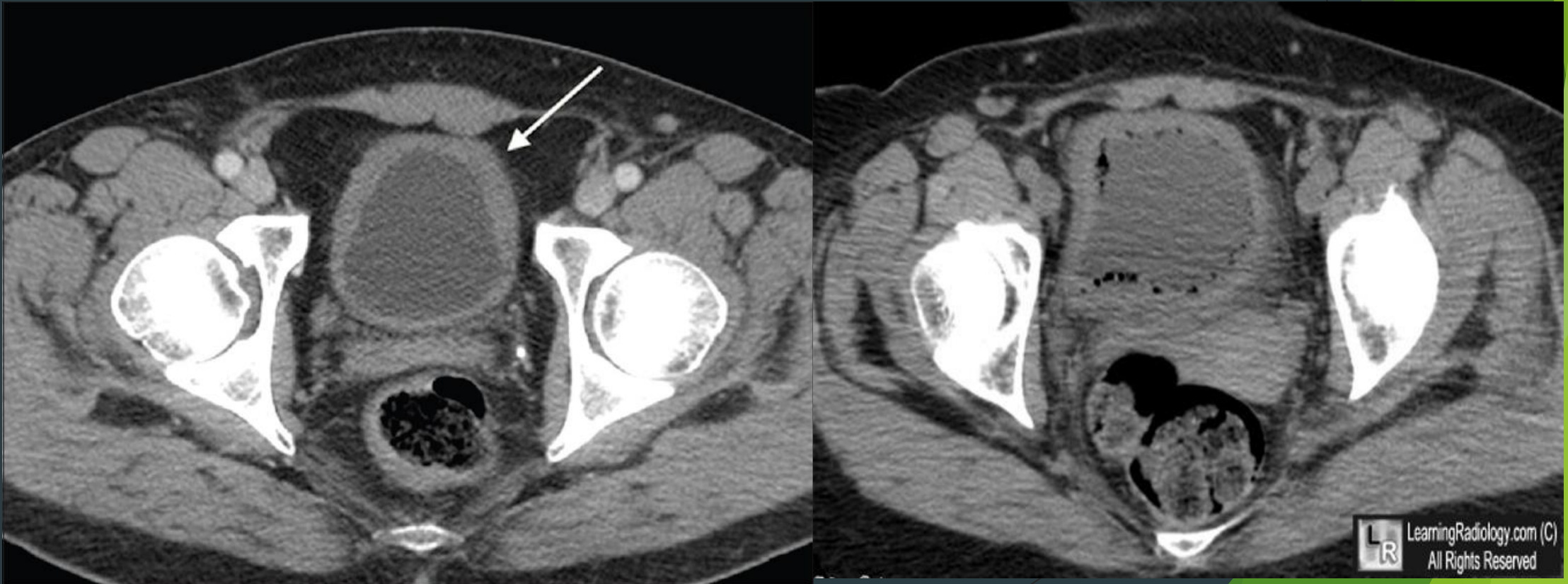


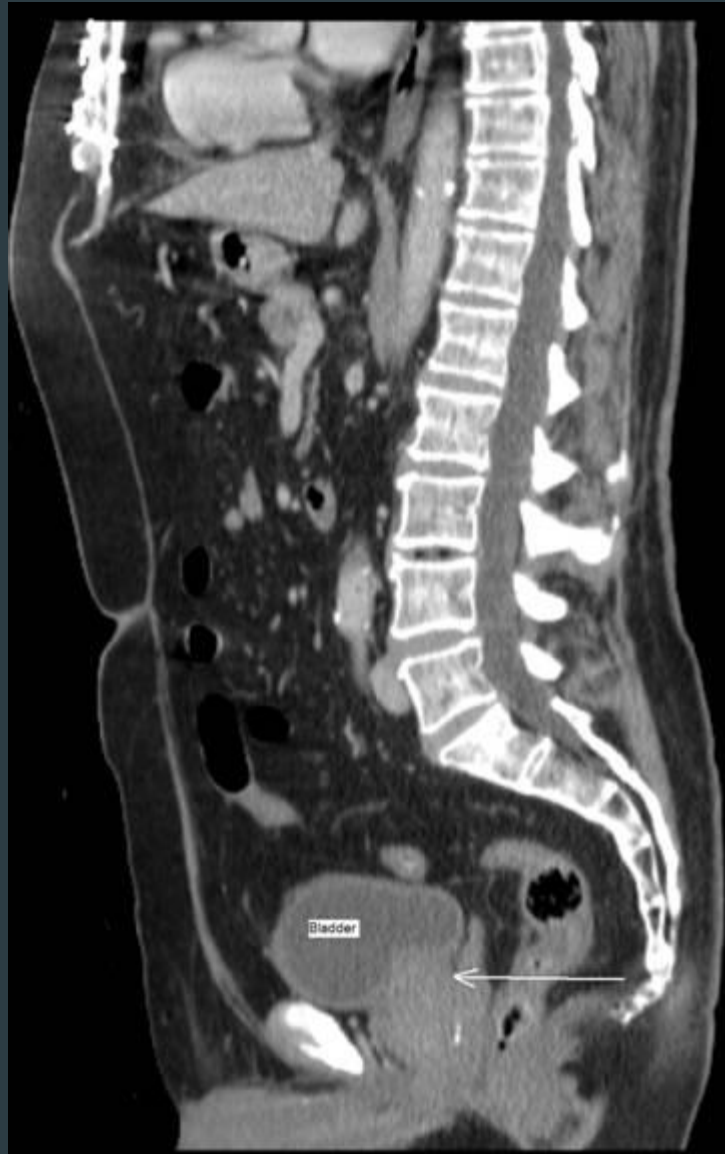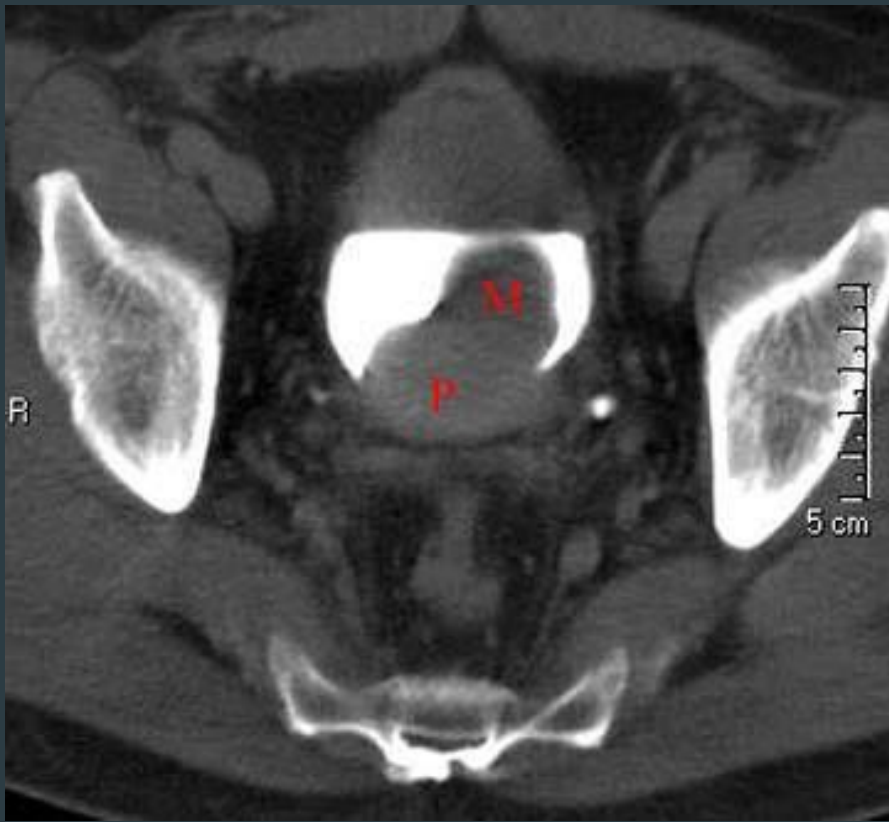
Urinary bladder

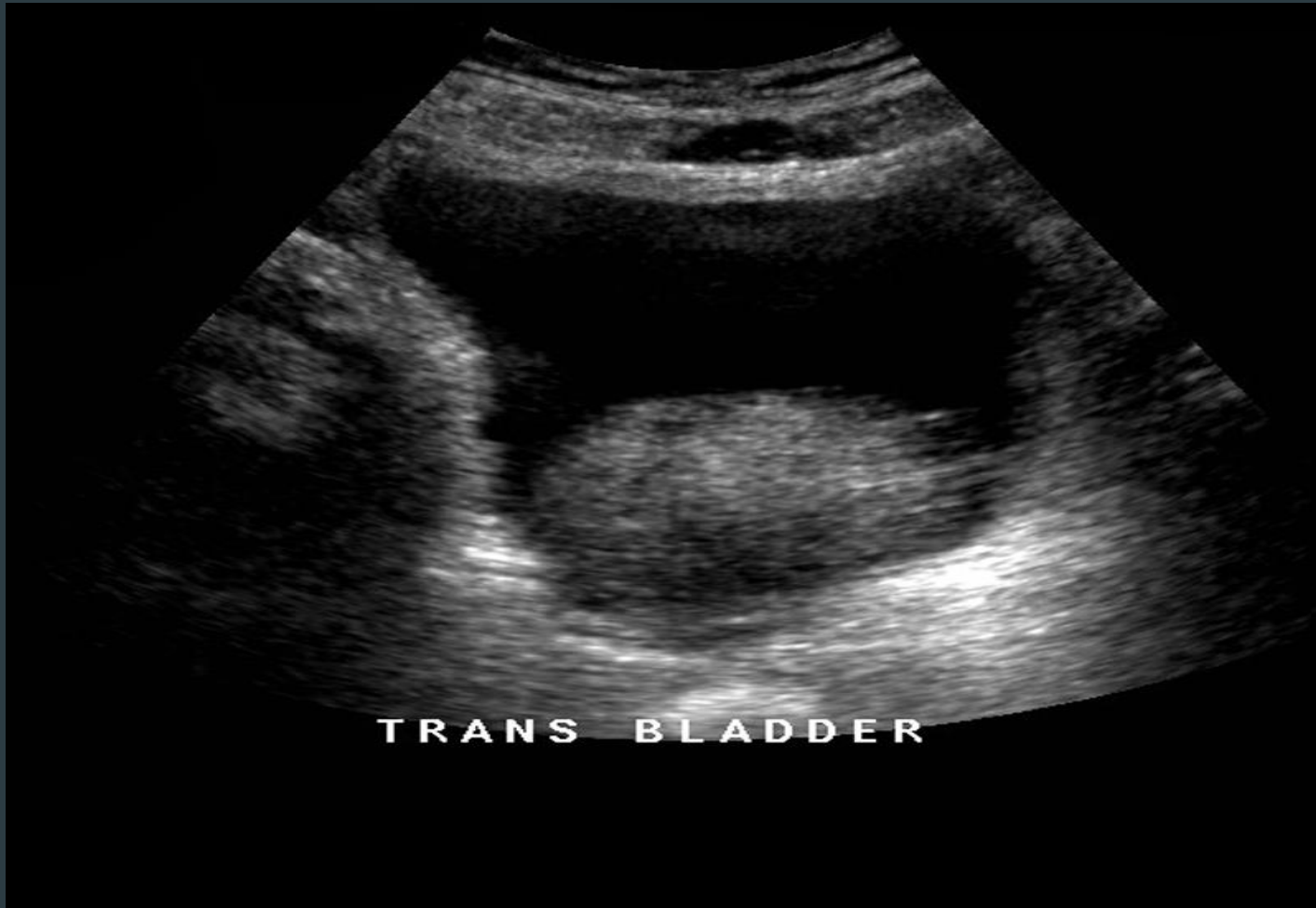

Common urinary bladder pathologies

► Cystitis



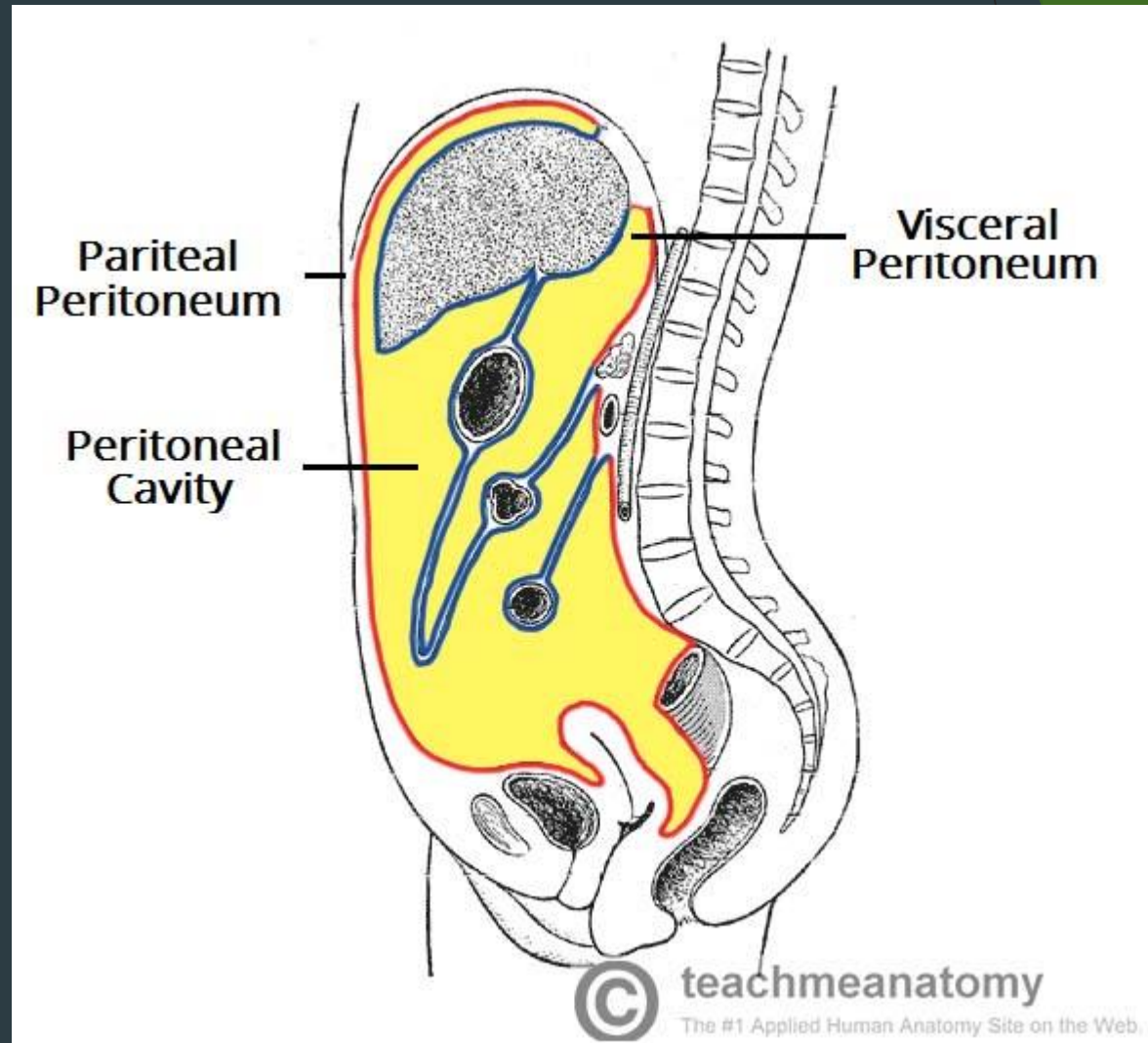




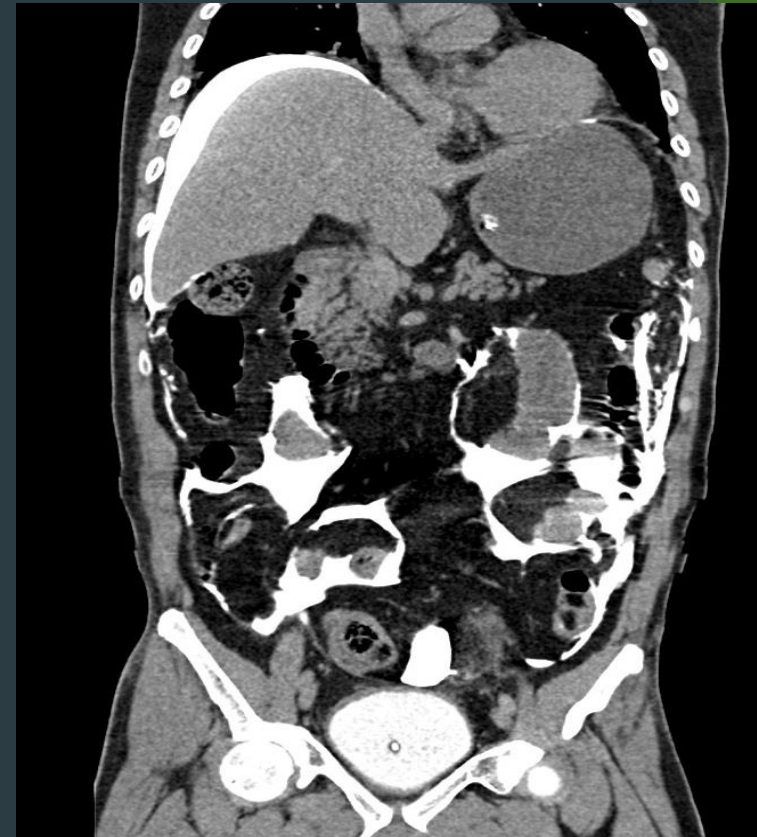
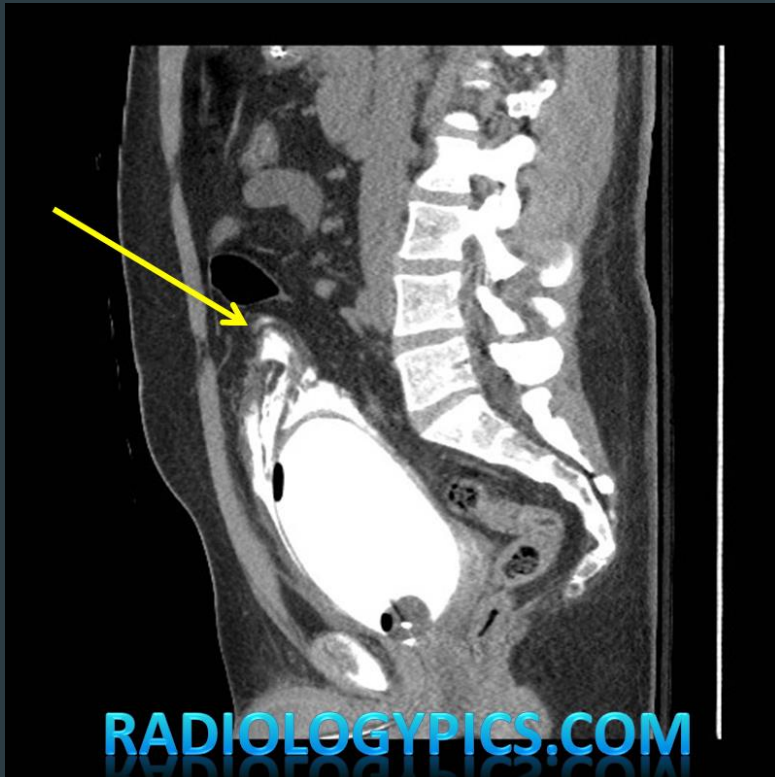
TRANS BLADDER

Common urinary bladder pathologies

- ▶ Bladder rupture



Common urinary bladder pathologies



Urethra

