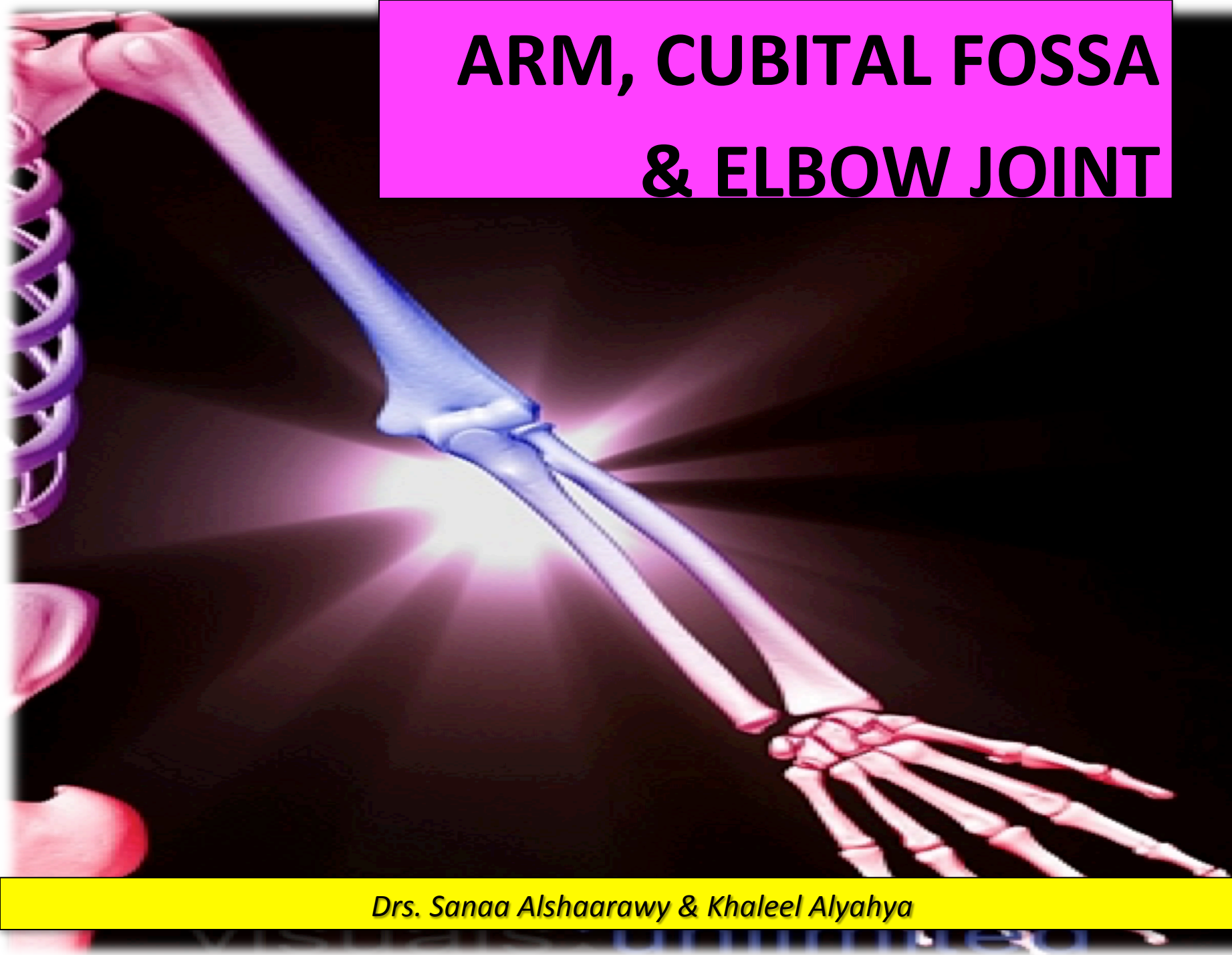

ARM, CUBITAL FOSSA & ELBOW JOINT



Drs. Sanaa Alshaarawy & Khaleel Alyahya

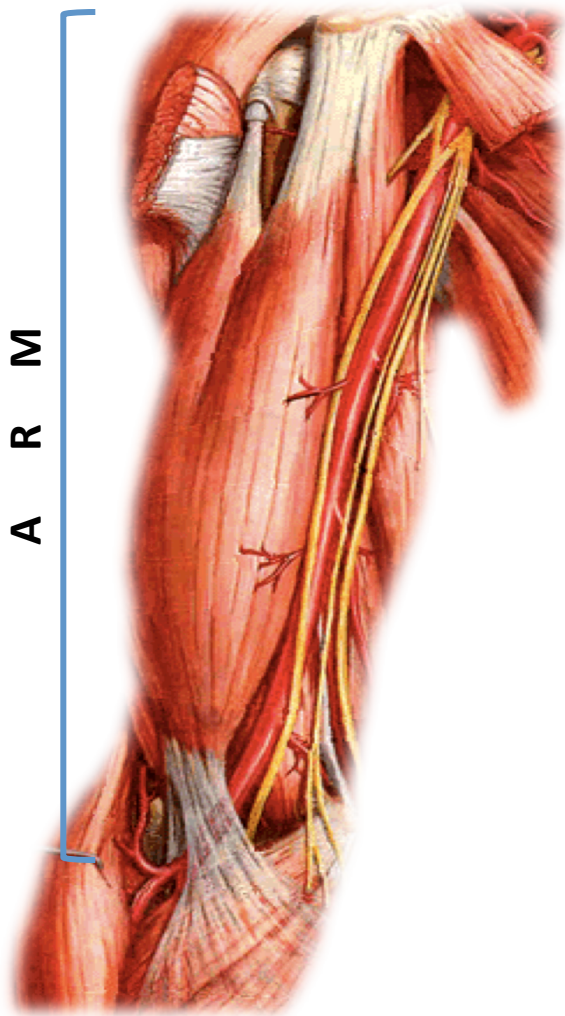
OBJECTIVES

❖ At the end of the lecture, students should:

- Describe the attachments, actions and innervations of:
 - ✓ Biceps brachii
 - ✓ Coracobrachialis
 - ✓ Brachialis
 - ✓ Triceps brachii
- Define the **boundaries of the cubital fossa** and enumerate **its contents**.
- Demonstrate the following features of the elbow joint:
 - ✓ Articulating bones
 - ✓ Capsule
 - ✓ Lateral & medial collateral ligaments
 - ✓ Synovial membrane
- Demonstrate the movements: **flexion** and **extension** of the elbow.
- List the main muscles producing the above movements.

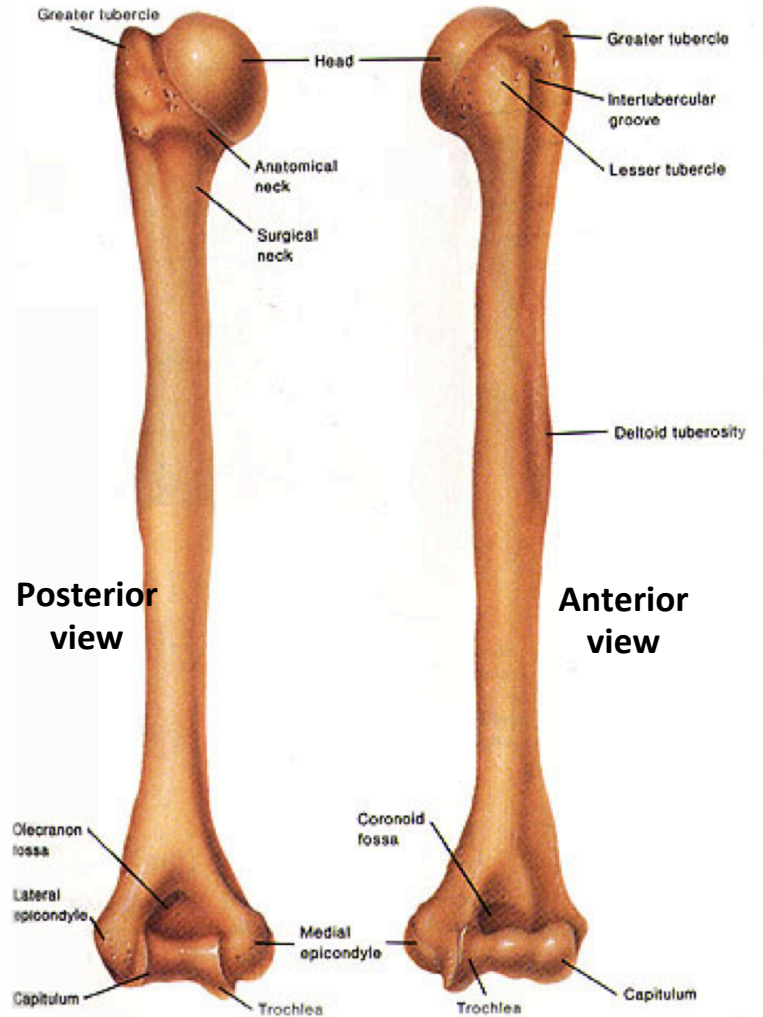
The ARM

Shoulder



Elbow

Arm



Posterior view

Anterior view

Posterior view

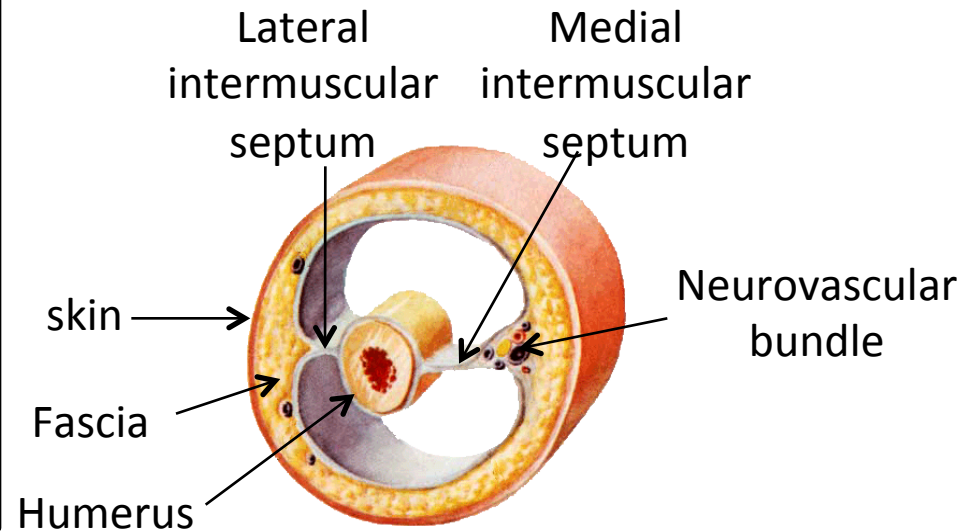
Anterior view

Humerus

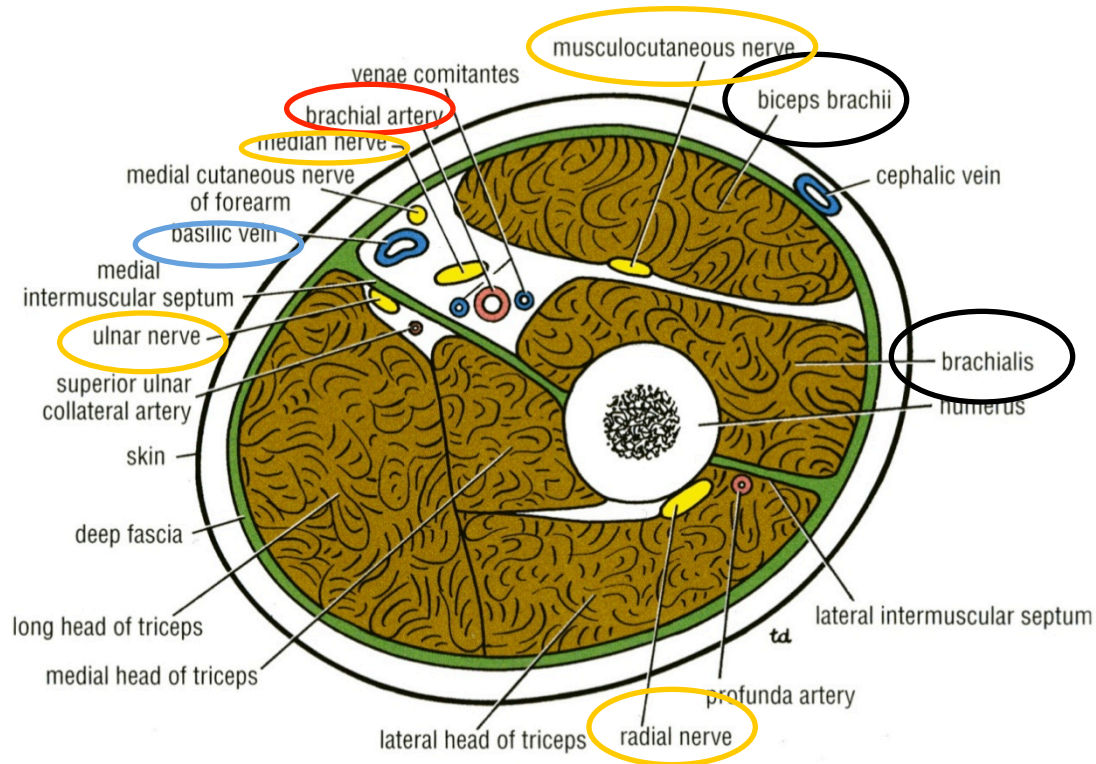
The ARM

❖ The lateral and medial **intermuscular septa** **divide** the distal part of the **arm** into two compartments:

- Anterior
- Posterior

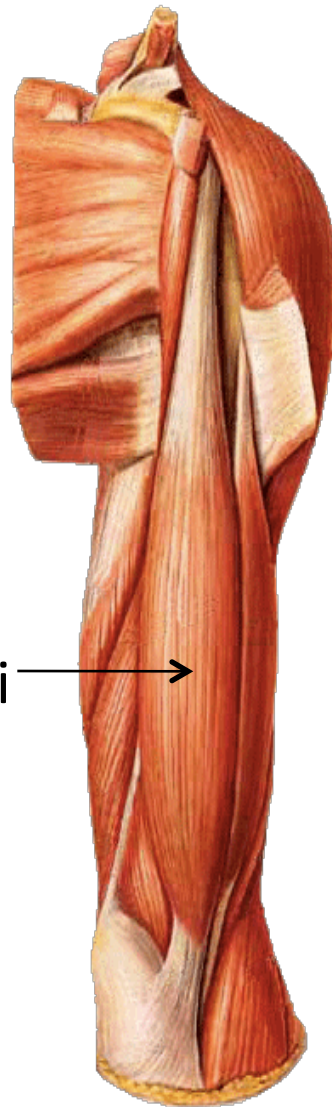


Anterior Fascial Compartment Contents

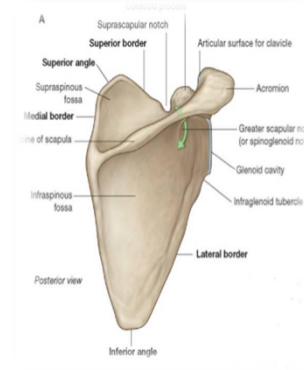


- **Muscles:** Biceps brachii, Coracobrachialis & Brachialis.
- **Blood Vessels:** Brachial artery & Basilic vein.
- **Nerves :** Musculocutaneous, Median, Radial & Ulnar.

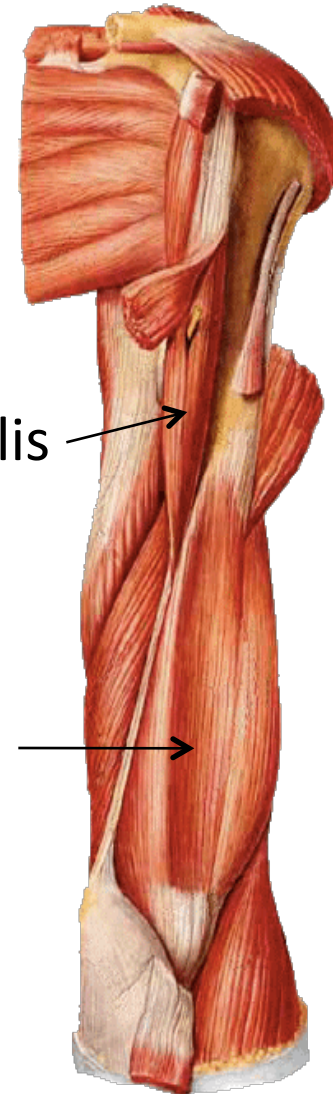
Muscles of the Anterior Compartment



Biceps brachii →



Coracobrachialis →



Brachialis →

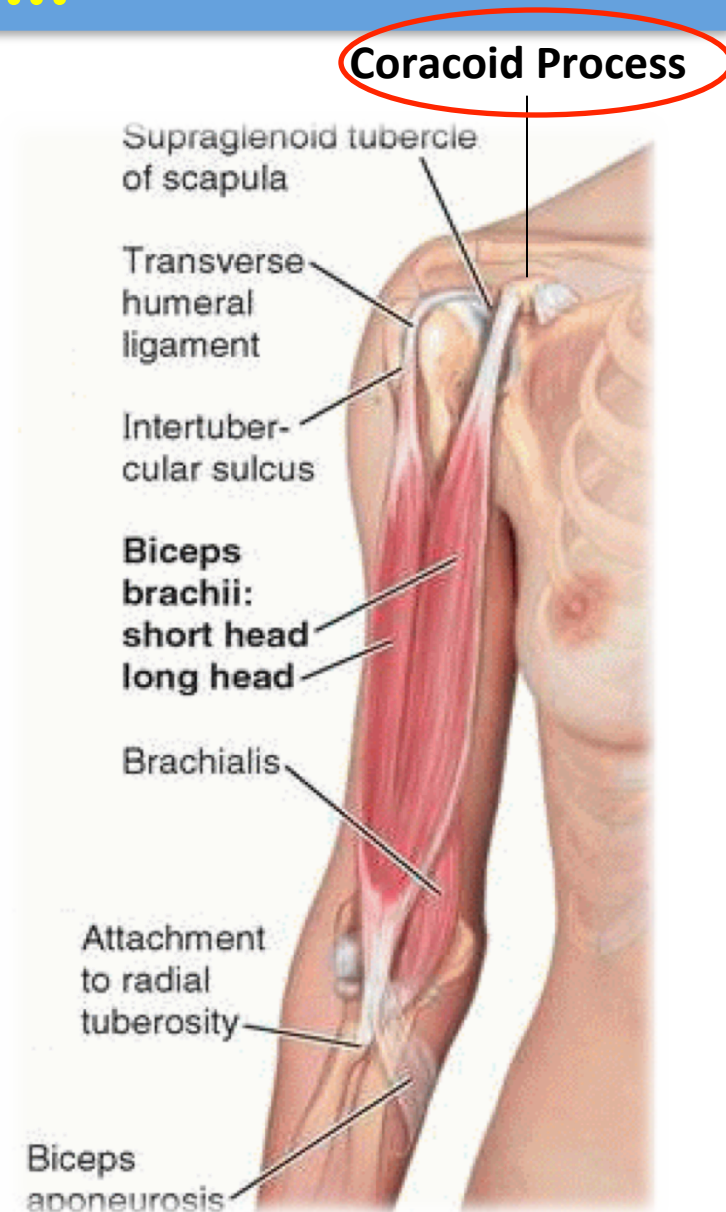
Biceps Brachii

❖ **Origin:** Two heads:

➤ **Long Head (lateral head)** from supraglenoid tubercle of scapula (intracapsular)

➤ **Short Head** from the tip of **coracoid process of scapula**.

❖ The two heads join in the middle of the arm



Biceps Brachii

❖ Insertion:

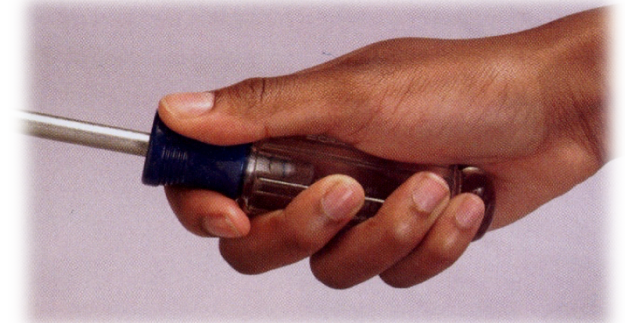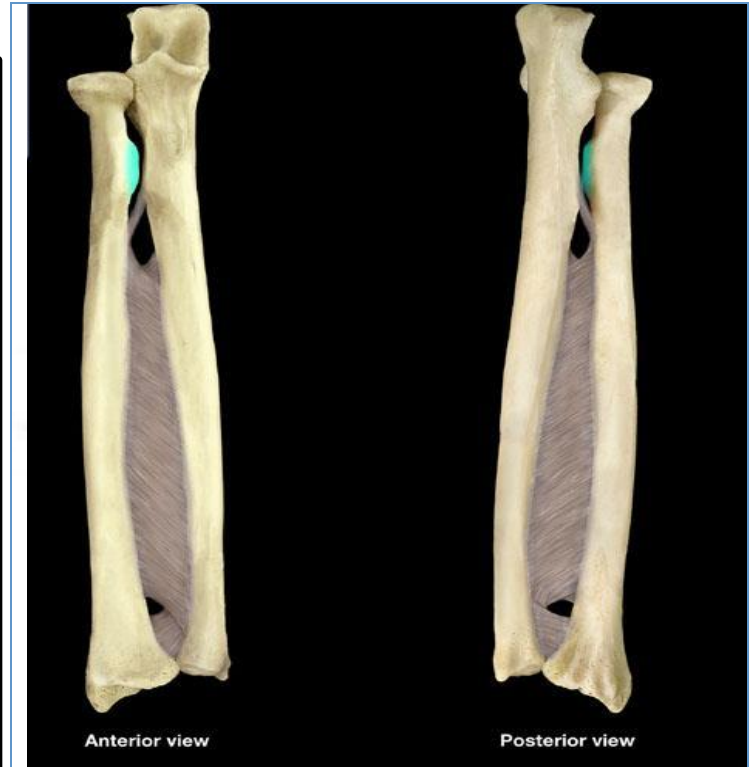- into the posterior part of the **radial tuberosity**.
- into the **deep fascia of the medial aspect of forearm through bicipital aponeurosis**.

❖ Nerve supply:

- **Musculocutaneous**

❖ Action:

- **Strong supinator** of the forearm
 - ✓ used in screwing.
- **Powerful flexor** of elbow
- **Weak flexor** of shoulder



Coracobrachialis

❖ Origin:

- Tip of the **coracoid process of scapula** (with short head of biceps brachii).

❖ Insertion:

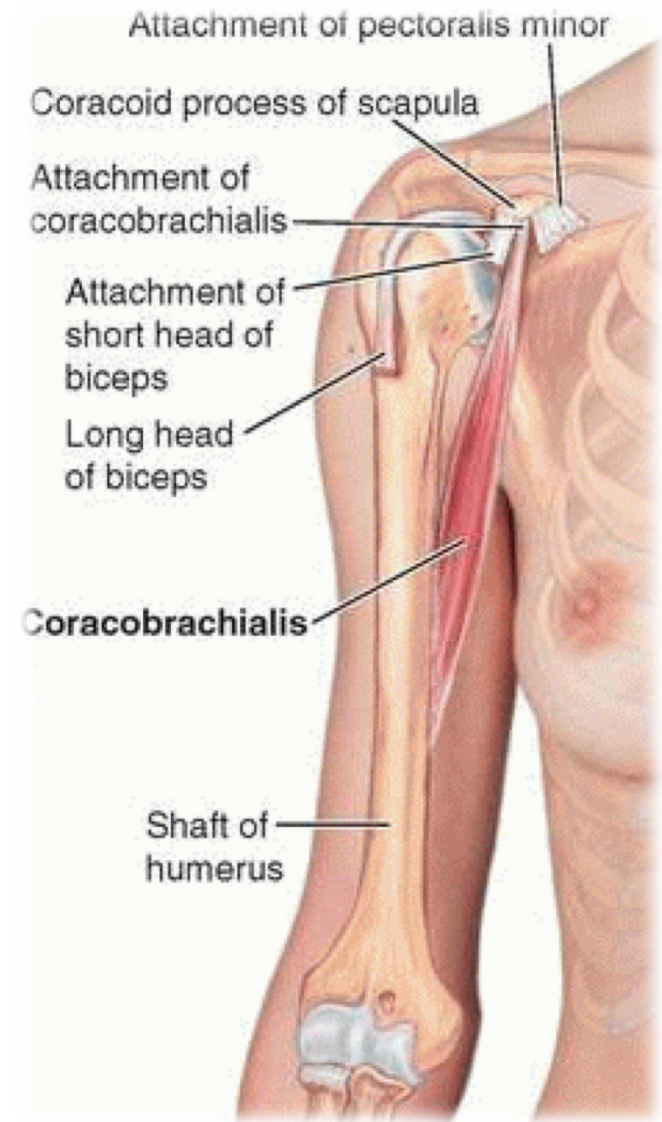
- **Middle** of the medial side of the **shaft of the humerus**

❖ Nerve supply:

- **Musculocutaneous**

❖ Action:

- **Flexor** & a weak adductor of the **arm**.



Brachialis

❖ Origin:

- Front of the **lower half** of **humerus**

❖ Insertion:

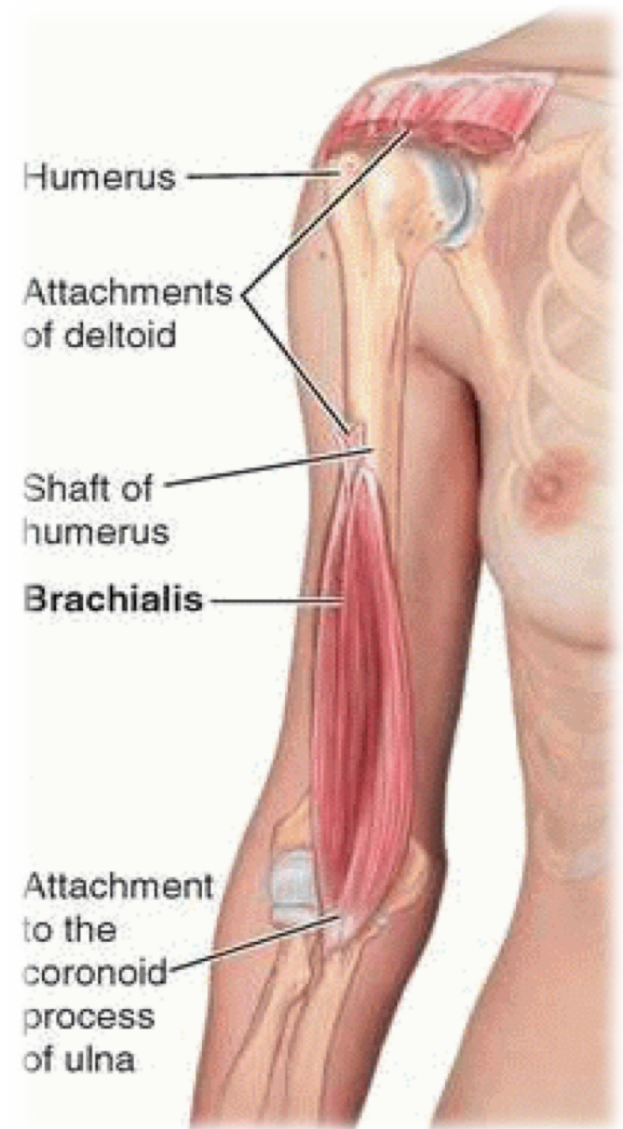
- Anterior surface of **coronoid process of ulna**

❖ Nerve supply:

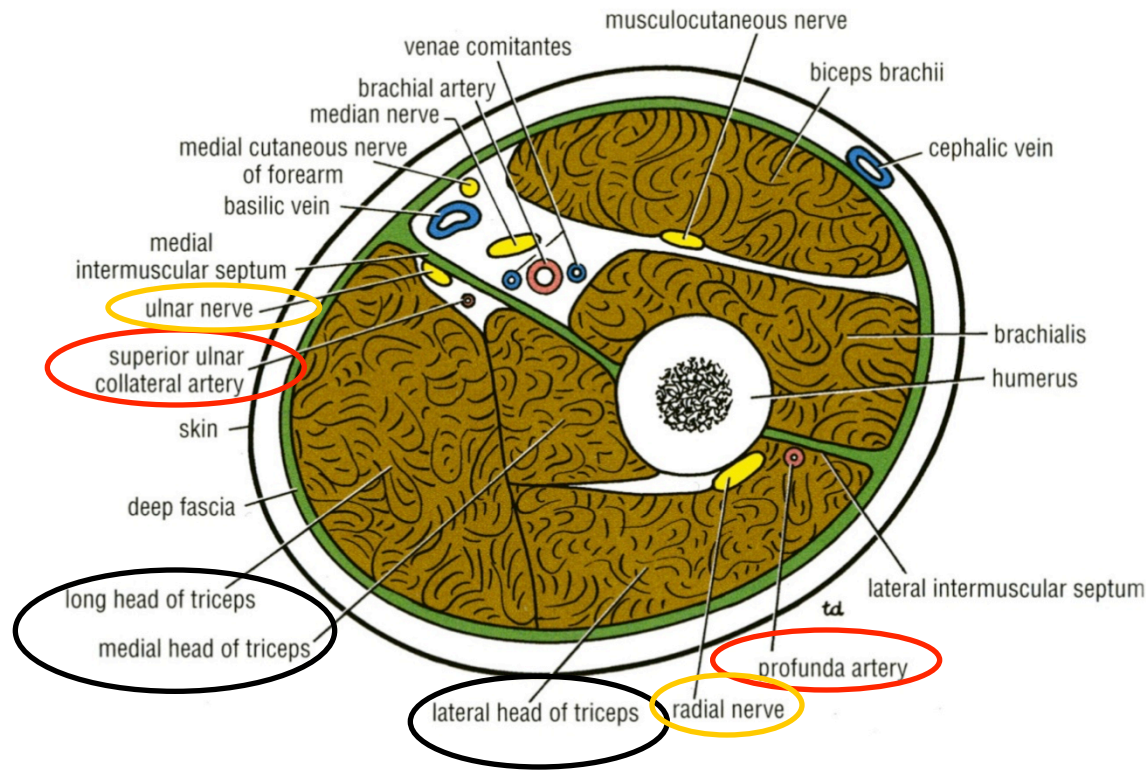
- **Musculocutaneous & Radial**

❖ Action:

- **Strong flexor** of the **forearm**



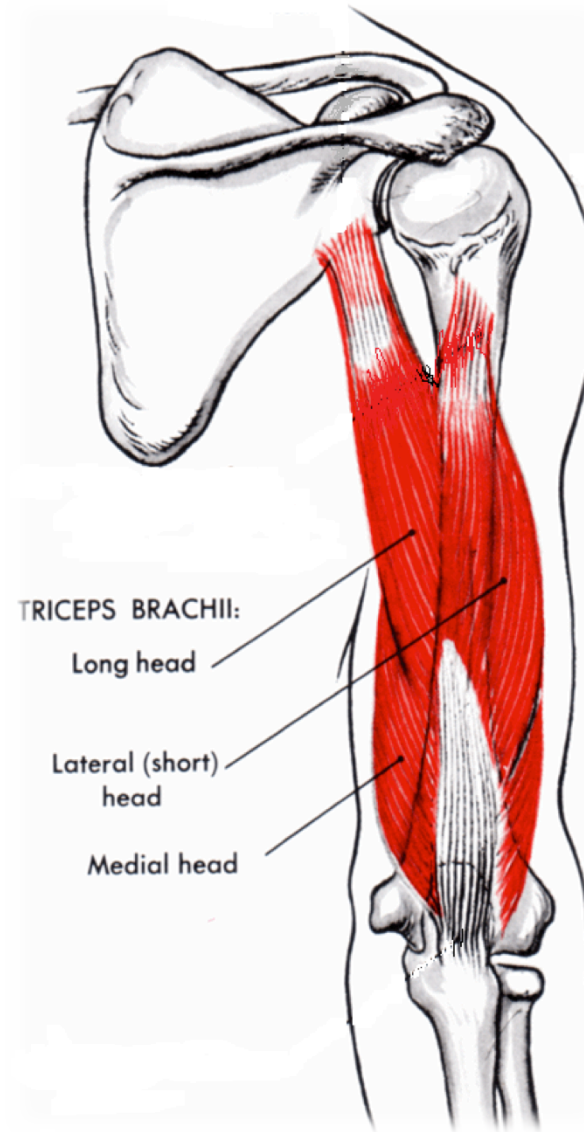
Posterior Fascial Compartment Contents



- **Muscles:** Triceps
- **Vessels:** Profunda brachii & Ulnar collateral arteries
- **Nerves:** Radial & Ulnar

Muscles of the Posterior Compartment

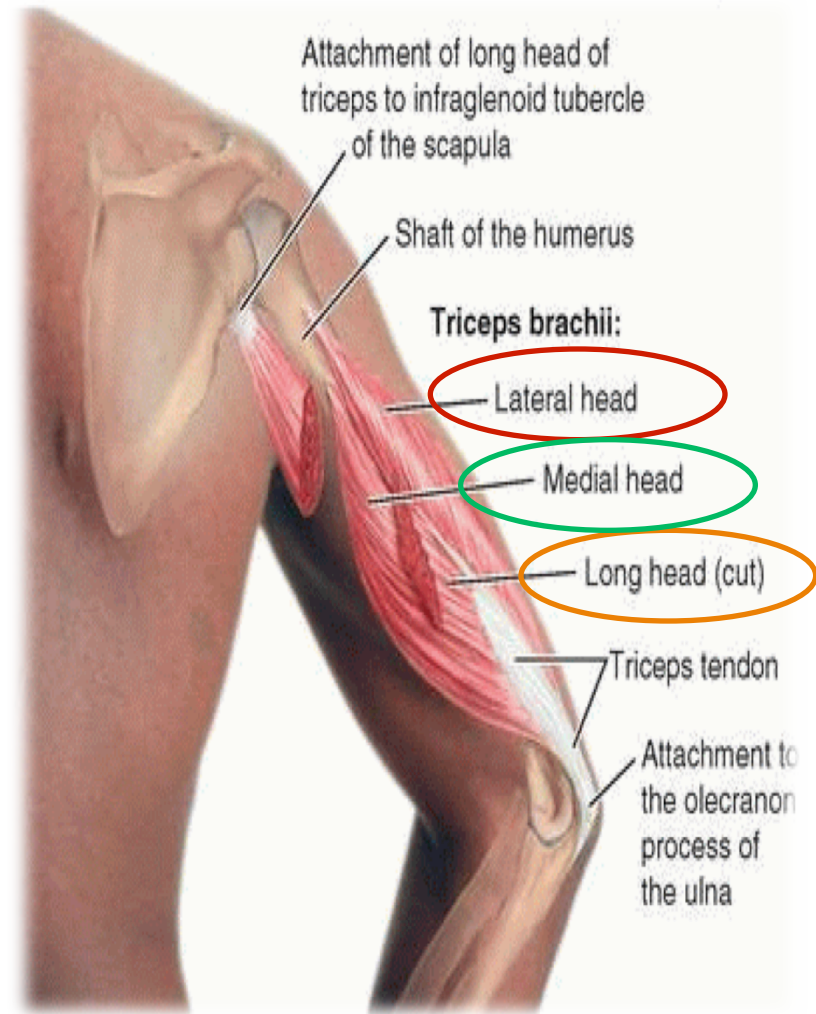
Triceps brachii



Triceps

Origin: Three heads:

- **Long Head** from **infraglenoid tubercle** of the scapula
- **Lateral Head** from the upper half of the **posterior surface** of the shaft of **humerus above** the **spiral groove**
- **Medial Head** from the lower half of the **posterior surface** of the shaft of **humerus below** the **spiral groove**



Triceps

❖ Insertion:

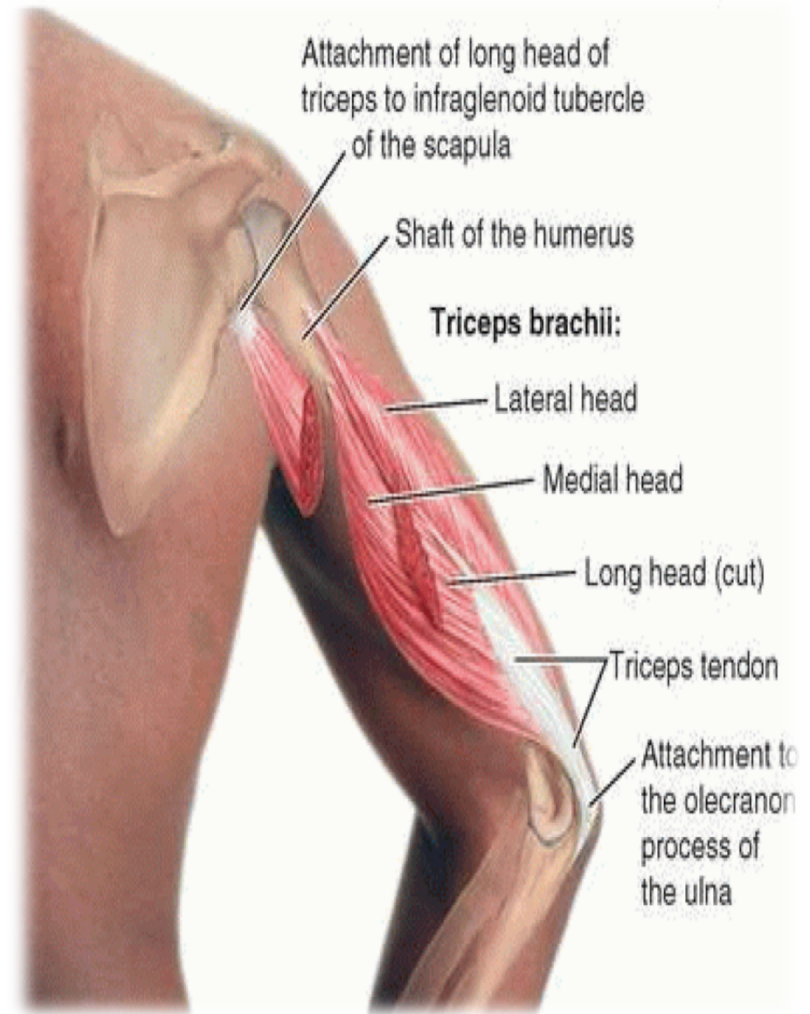
➤ **Common tendon** inserted into the upper surface of the **olecranon process of ulna**

❖ Nerve supply:

➤ **Radial nerve**

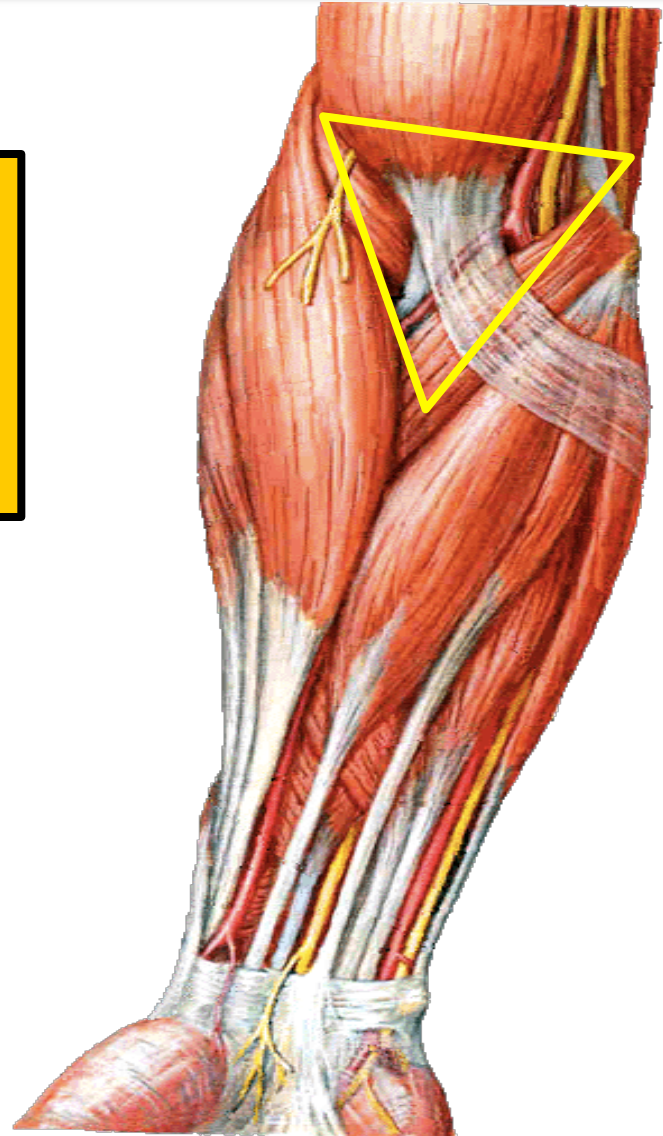
❖ Action:

➤ **Strong extensor** of the **elbow joint**



Cubital Fossa

is a **triangular depression** that **lies in front of the elbow**



Boundaries of Cubital Fossa

❖ Base:

- Line drawn through the **two epicondyles of humerus**

❖ Laterally:

- Brachioradialis

❖ Medially:

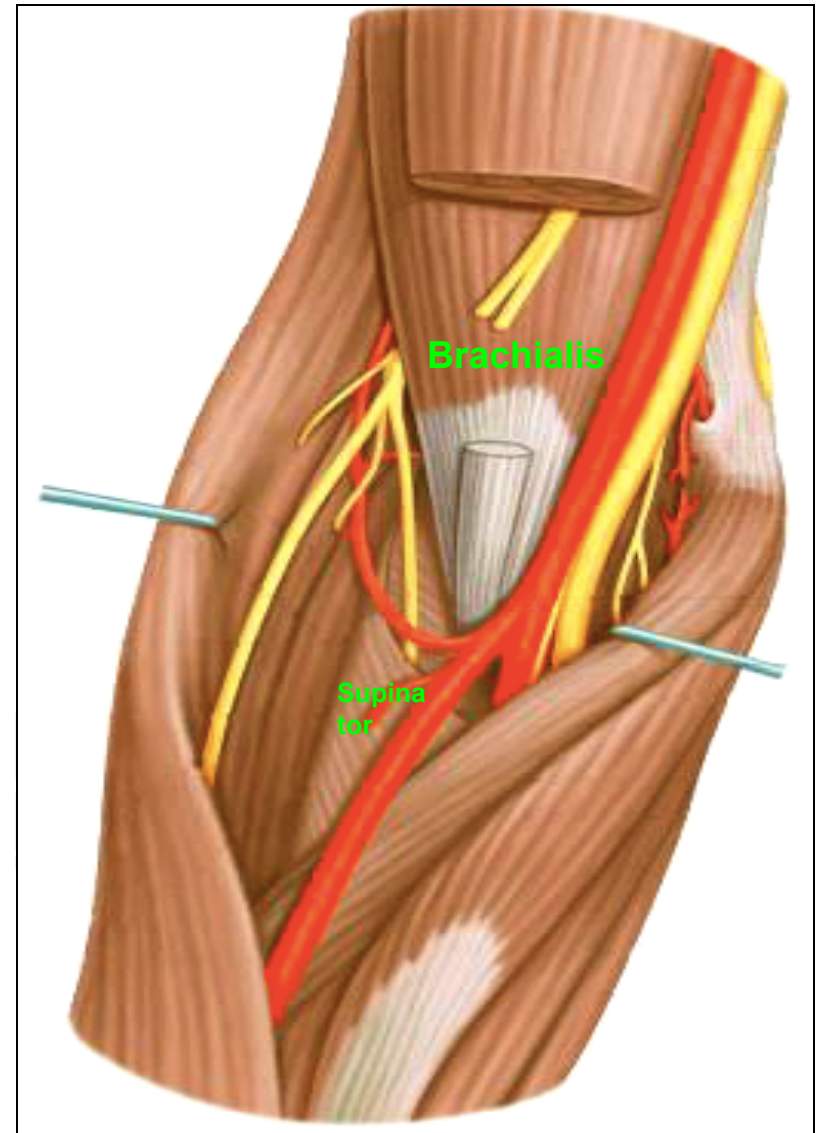
- Pronator teres

❖ Roof:

- Skin, superficial & deep fascia and bicipital aponeurosis

❖ Floor:

- **Brachialis** medially and **supinator** laterally.



Contents of Cubital Fossa

(From medial to lateral side)

3. Biceps brachii tendon

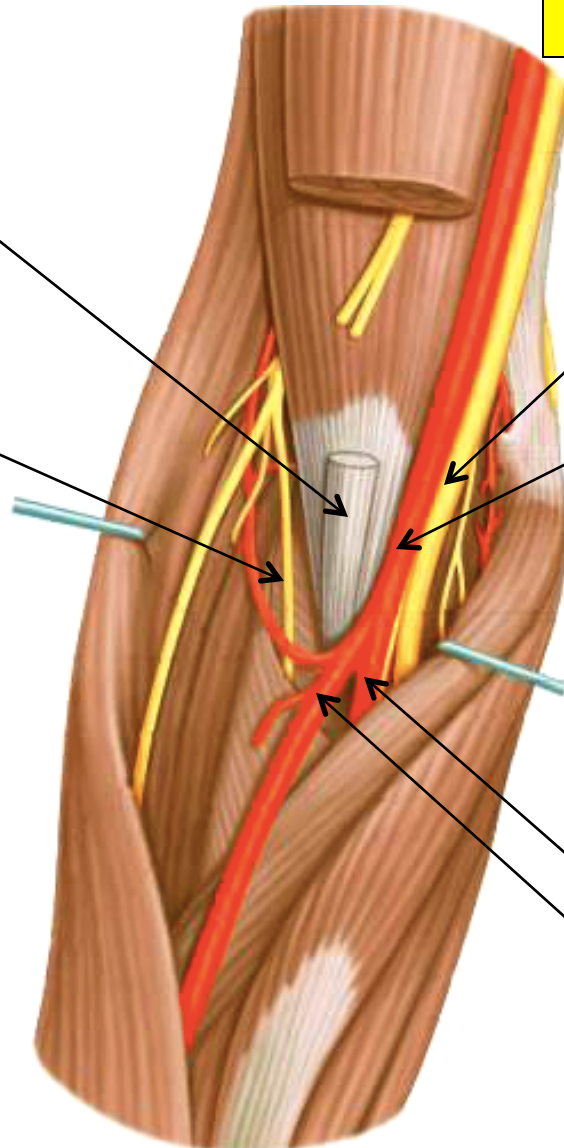
4. Deep branch of radial nerve

1. Median nerve

2. Brachial artery divides into radial & ulnar arteries.

Ulnar artery

Radial artery



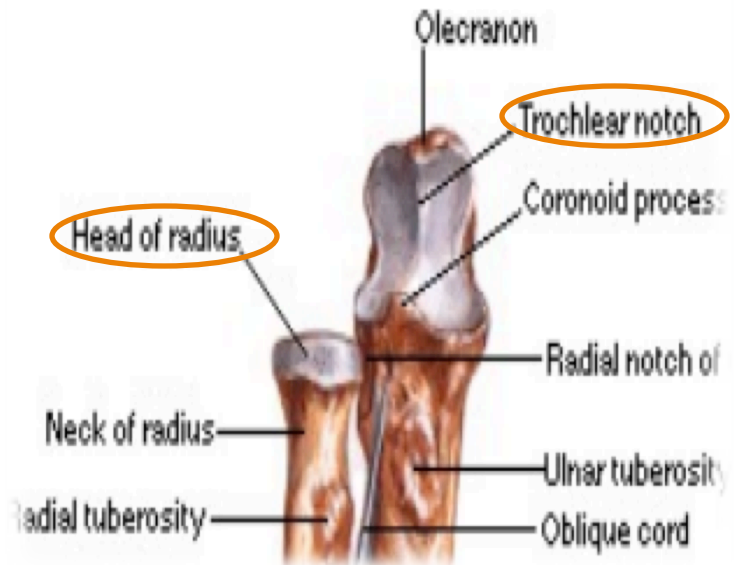
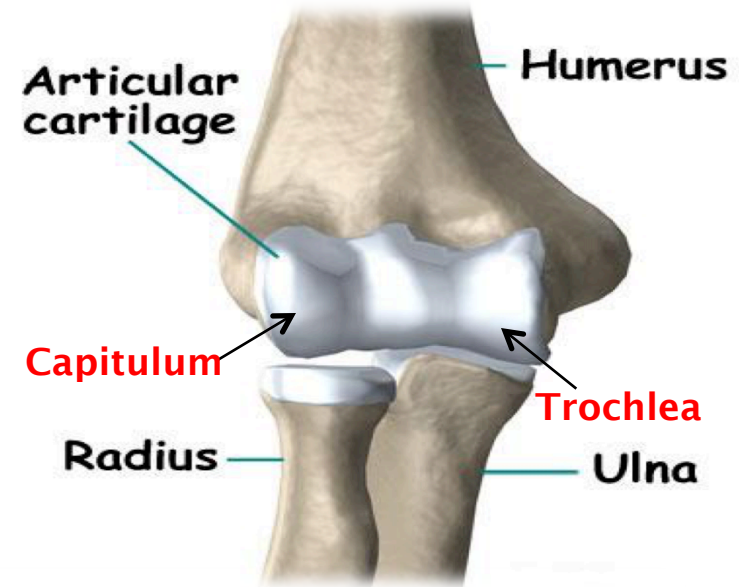
ELBOW Joint

Uniaxial, Synovial Hinge joint

Articulation

- Trochlea and capitulum of the humerus above
- Trochlear notch of ulna and the head of radius below

❖ The articular surfaces are covered with articular (hyaline) cartilage.



Capsule

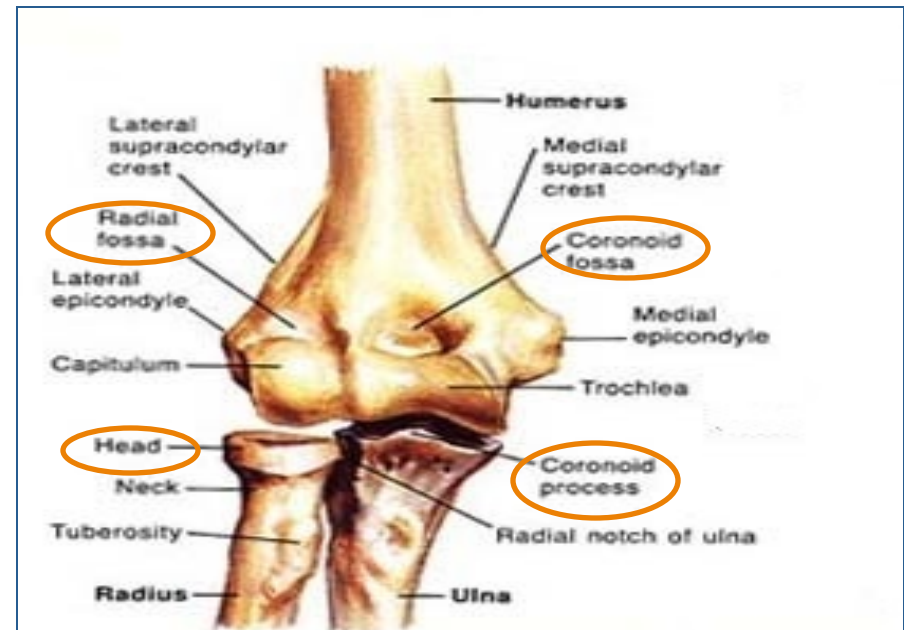
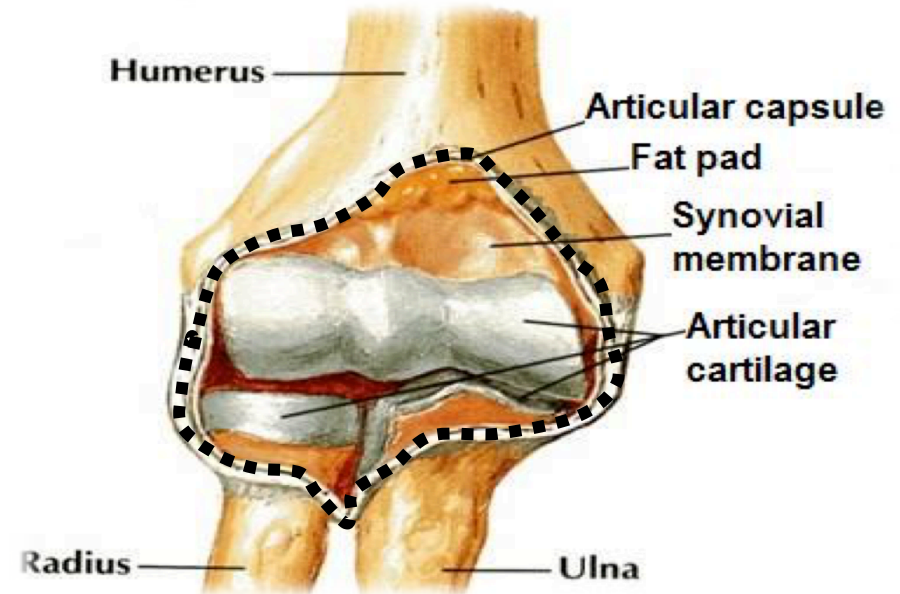
Anteriorly: attached

➤ Above

✓ To the **humerus** along the **upper margins** of the **coronoid** and **radial fossa** and to the **front** of the **medial** and **lateral epicondyles**.

➤ Below

✓ To the **margin** of the **coronoid process** of the **ulna** and to the **anular ligament**, which surrounds the **head** of the **radius**.



Capsule

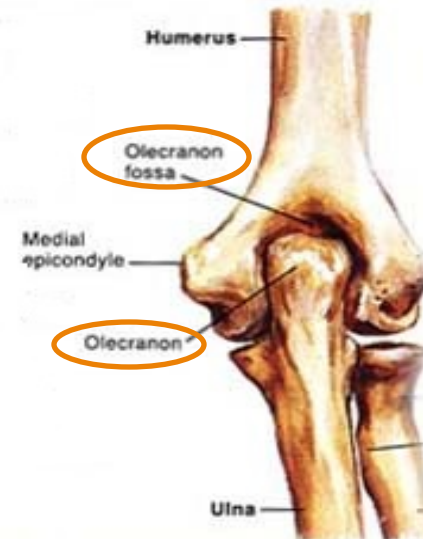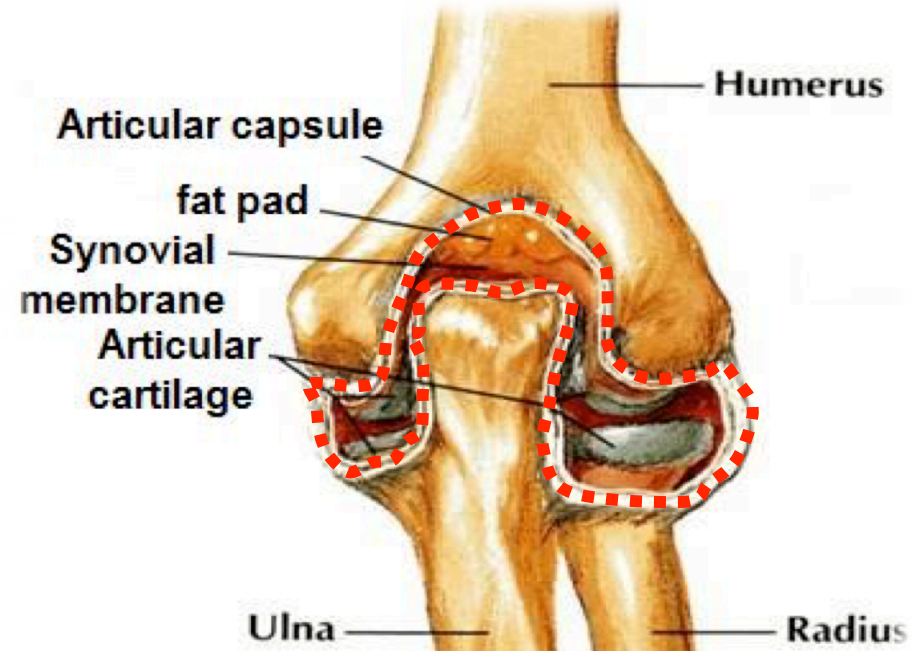
Posteriorly: attached

➤ **Above**

✓ To the **margins** of the **olecranon fossa** of the **humerus**.

➤ **Below**

✓ To the **upper margin** and **sides** of the **olecranon process** of the **ulna** and to the **anular ligament**.



Ligaments

Lateral (radial collateral) ligament

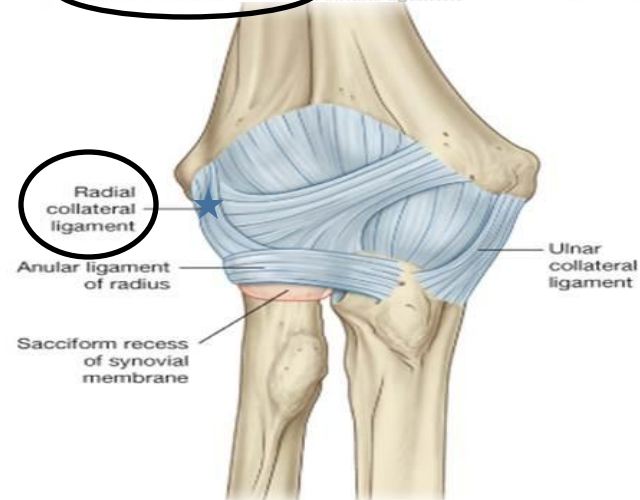
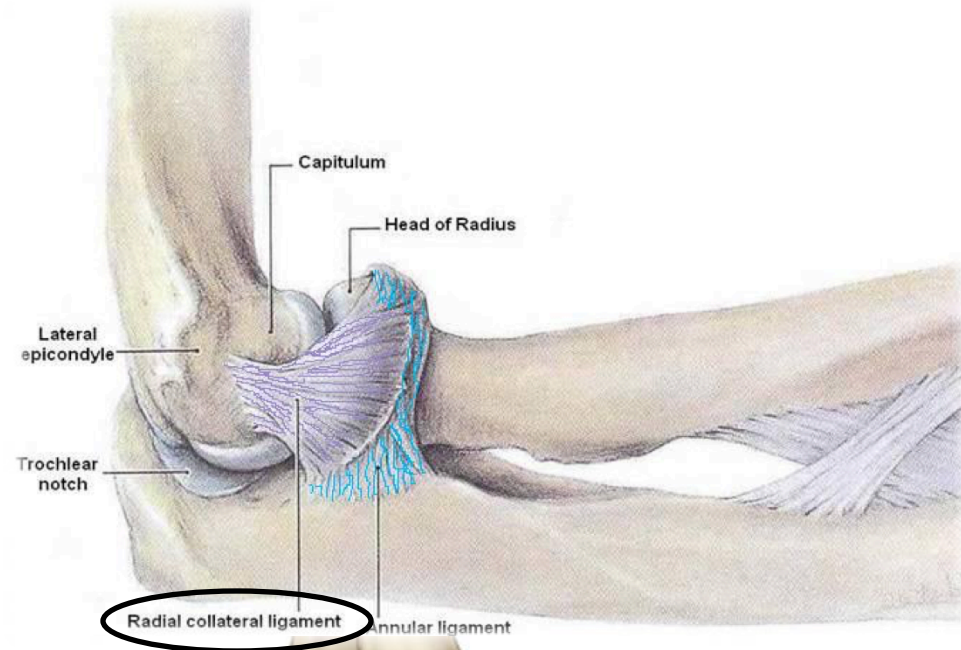
❖ Triangular in shape:

❖ Apex

➤ Attached to the **lateral epicondyle of humerus**

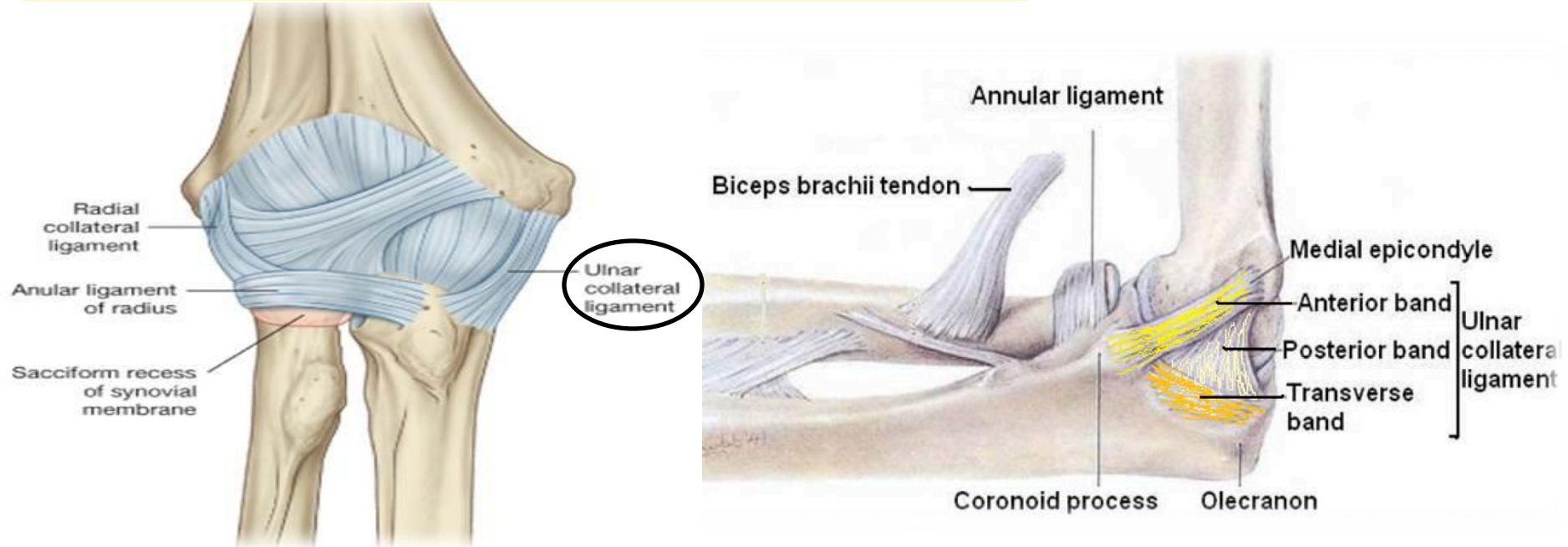
❖ Base

➤ Attached to the upper margin of **annular ligament**.



Ligaments

Medial (ulnar collateral) ligament



❖ **Anterior strong cord-like band:**

- Between **medial epicondyle** and the **coronoid process** of ulna

❖ **Posterior weaker fan-like band:**

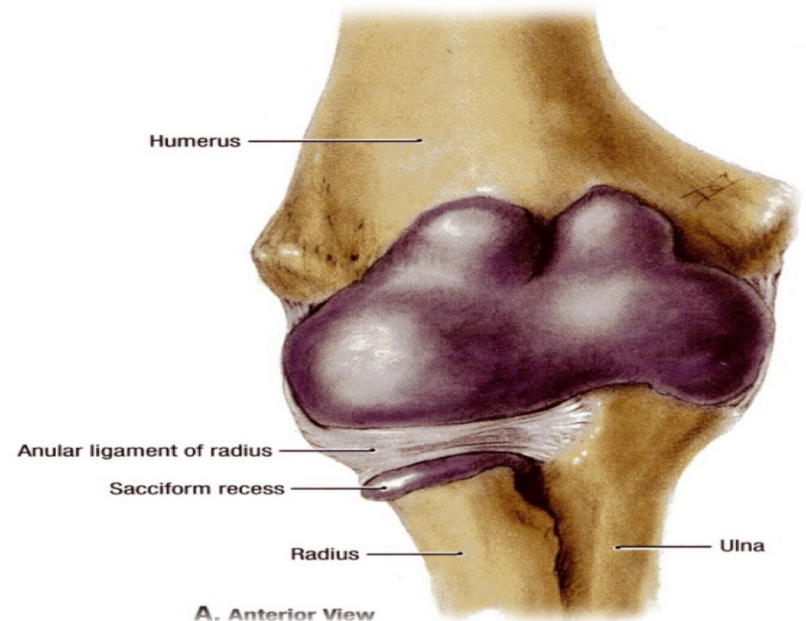
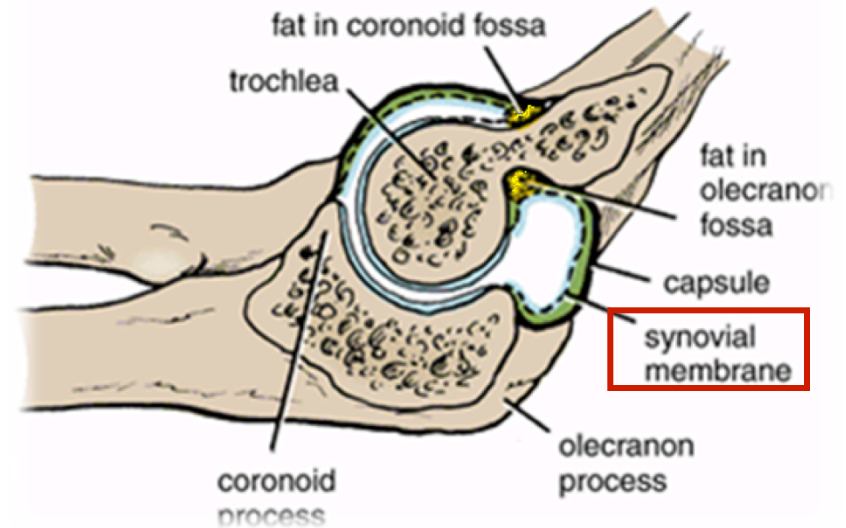
- Between **medial epicondyle** and the **olecranon process** of ulna

❖ **Transverse band:**

- Passes **between** the **anterior** and **posterior bands**

Synovial Membrane

- ❖ This lines the inner surface of the capsule and covers fatty pads in the floors of the coronoid, radial, and olecranon fossa.
- ❖ Is continuous below with synovial membrane of the superior radioulnar joint



Relations

❖ Anterior:

- Brachialis, tendon of biceps, **median nerve**, **brachial artery**

❖ Posterior:

- Triceps muscle, small bursa intervening

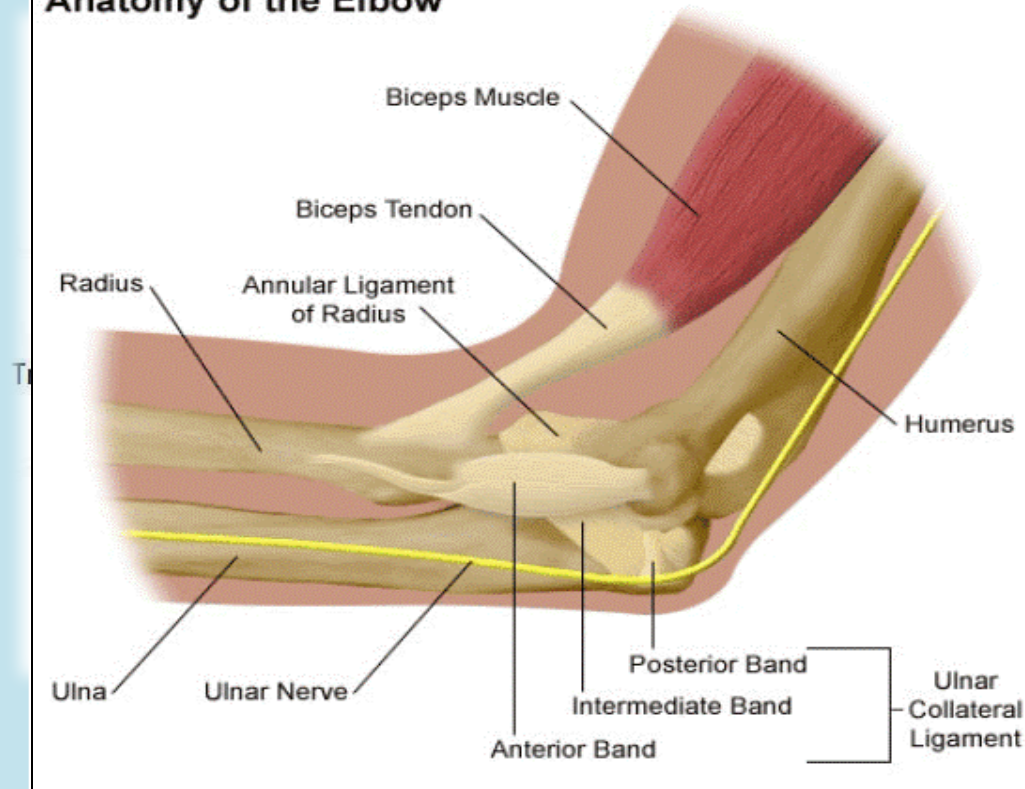
❖ Lateral:

- Common extensor tendon (lateral epicondyle of the humerus) & supinator

❖ Medial:

- Ulnar nerve
 - Considered the largest unprotected nerve by muscle or bone.

Anatomy of the Elbow



Bursae around the elbow joint:

- Subcutaneous olecranon bursa
- Subtendinous olecranon bursa

Movements

❖ Flexion

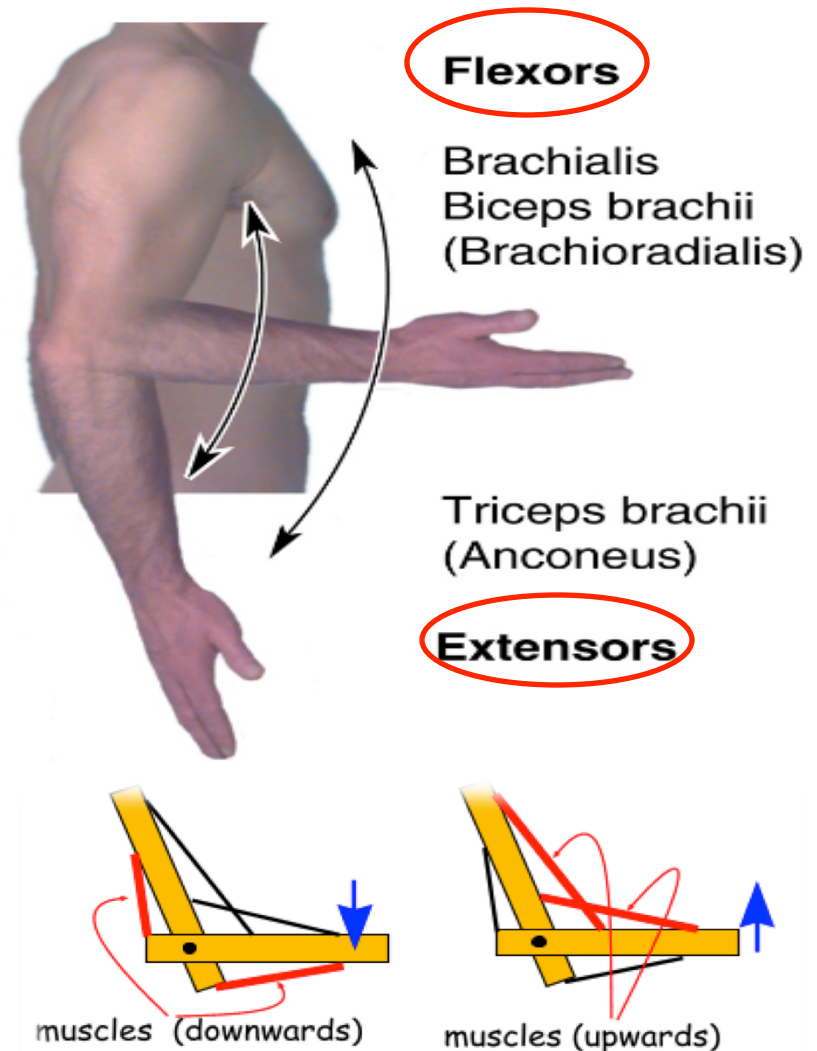
- Is limited by the anterior surfaces of the forearm and arm coming into contact.

❖ Extension

- Is limited by the tension of the anterior ligament (medially) and the brachialis muscle.

❖ The joint is supplied by branches from the:

- Median
- Ulnar
- Musculocutaneous
- Radial nerves



Carrying Angle

❖ Angle

➤ **Between the long axis of the extended forearm and the long axis of the arm**

❖ Opens

➤ Laterally

❖ About

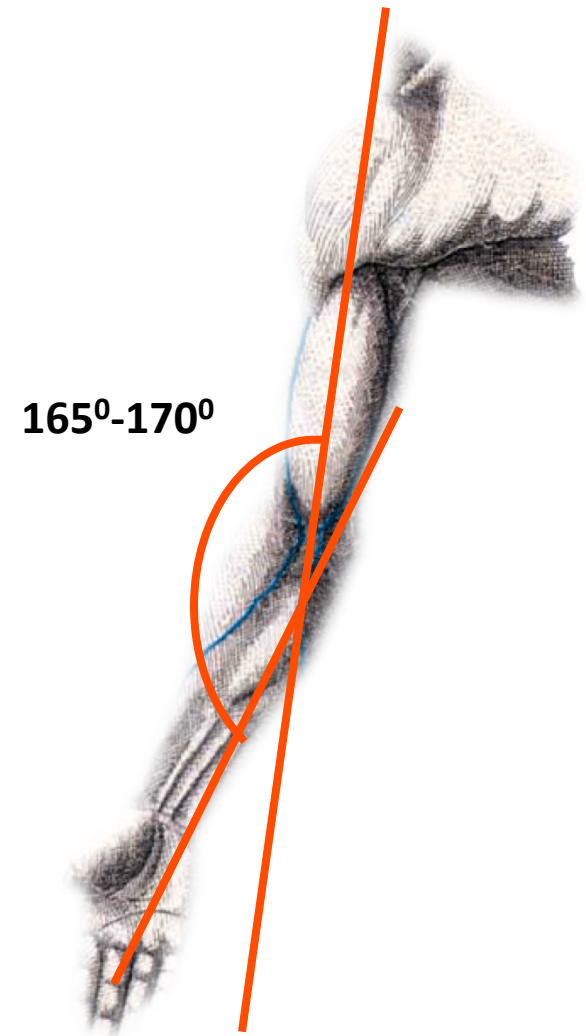
➤ 170 degrees in **male** and 167 degrees in **females**

❖ Disappears

➤ When the **elbow joint is flexed**

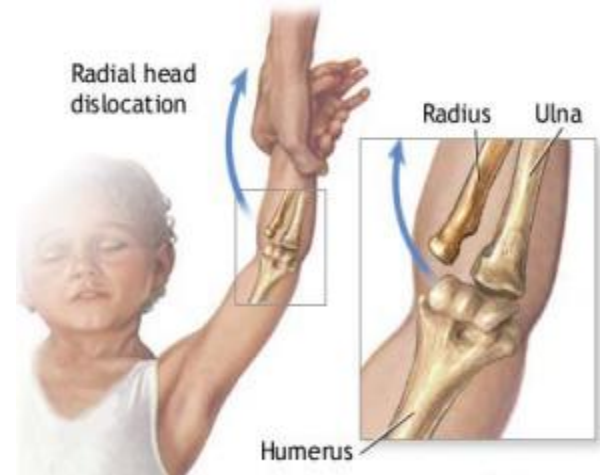
❖ Permits

➤ The forearms to **clear the hips** in **swinging movements** during **walking**, and is important when **carrying objects**

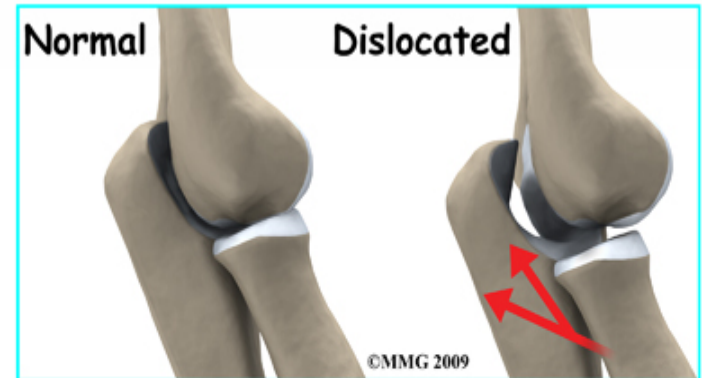


Articulations and applied anatomy

- ❖ The elbow joint is **stable** because of the:
 - Wrench-shaped articular surface of the olecranon and the pulley-shaped trochlea of humerus
 - Strong medial and lateral ligaments.
- ❖ Elbow **dislocations** are **common & most are posterior**.
 - **Posterior dislocation** usually follows falling on the outstretched hand.
 - Posterior dislocations of the joint are **common in children** because the parts of the **bones** that stabilize the joint are **incompletely developed**.



Elbow Dislocation

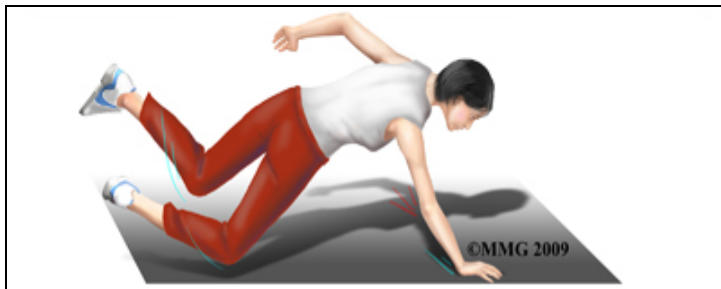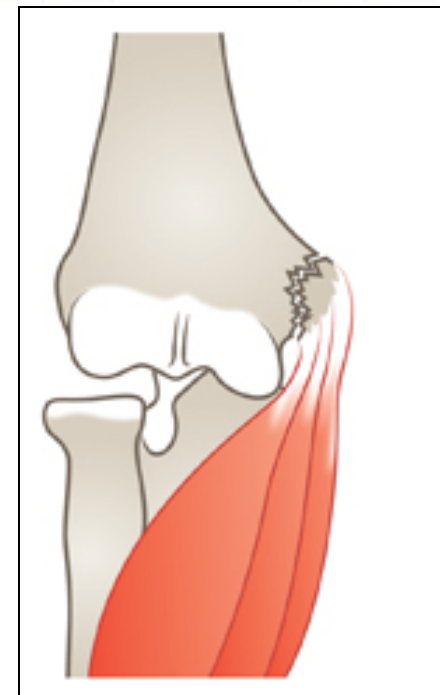
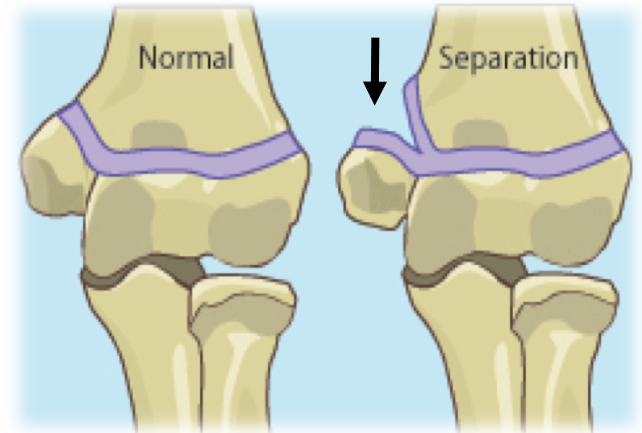


ELBOW Joint

❖ **Avulsion of the epiphysis** of the **medial epicondyle** is also **common in childhood** because the **medial ligament** is **much stronger** than the **bond** of union between the **epiphysis** and the **diaphysis**.

❖ They are usually a **result from** an **avulsion (pull off) injury** caused by a **valgus stress** at the **elbow** and **contraction** of the **flexor** muscles as in :

- ✓ fall on an outstretched hand with the elbow in full extension
- ✓ posterior elbow dislocation
- ✓ direct blow



THANK YOU