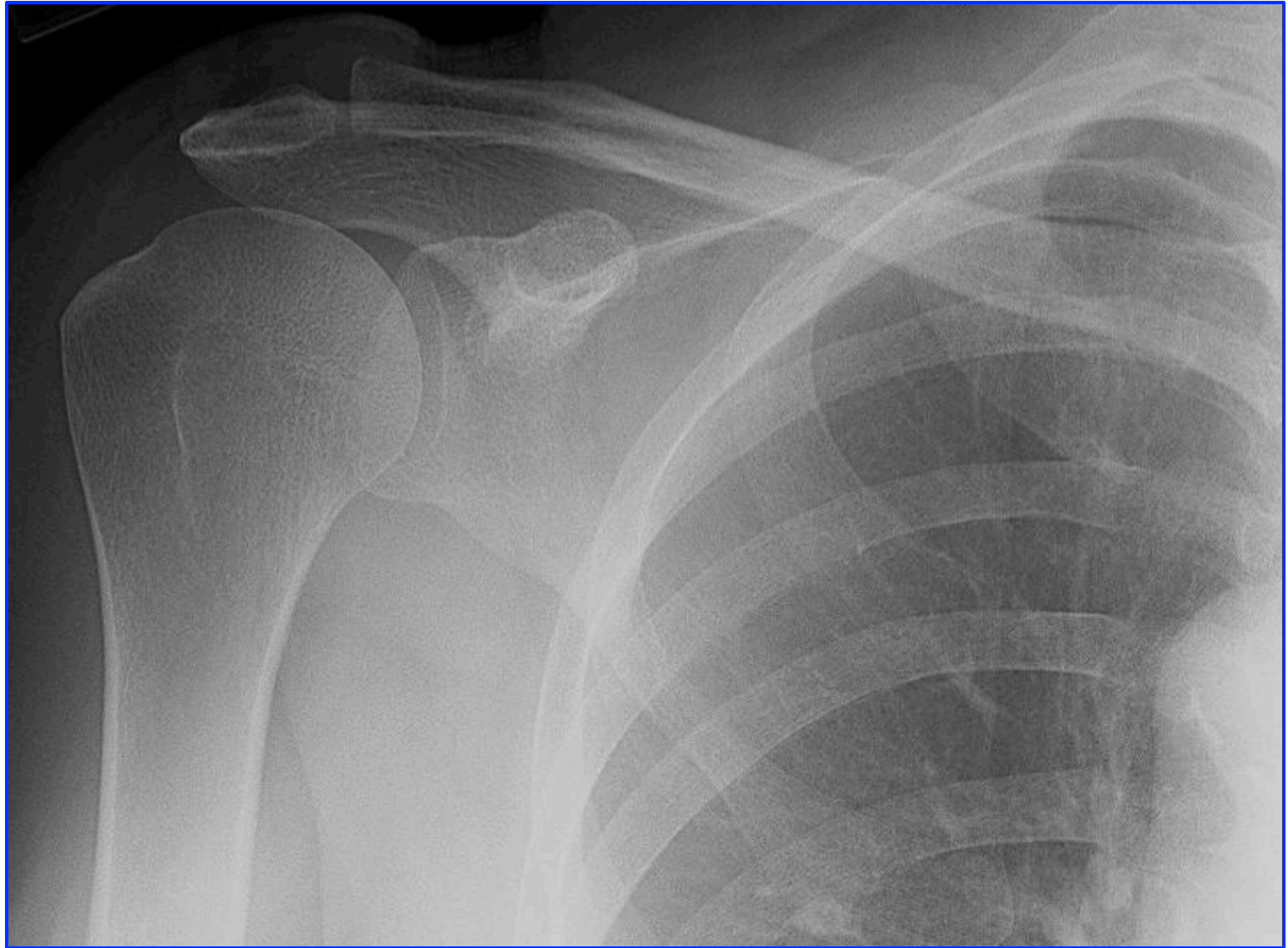


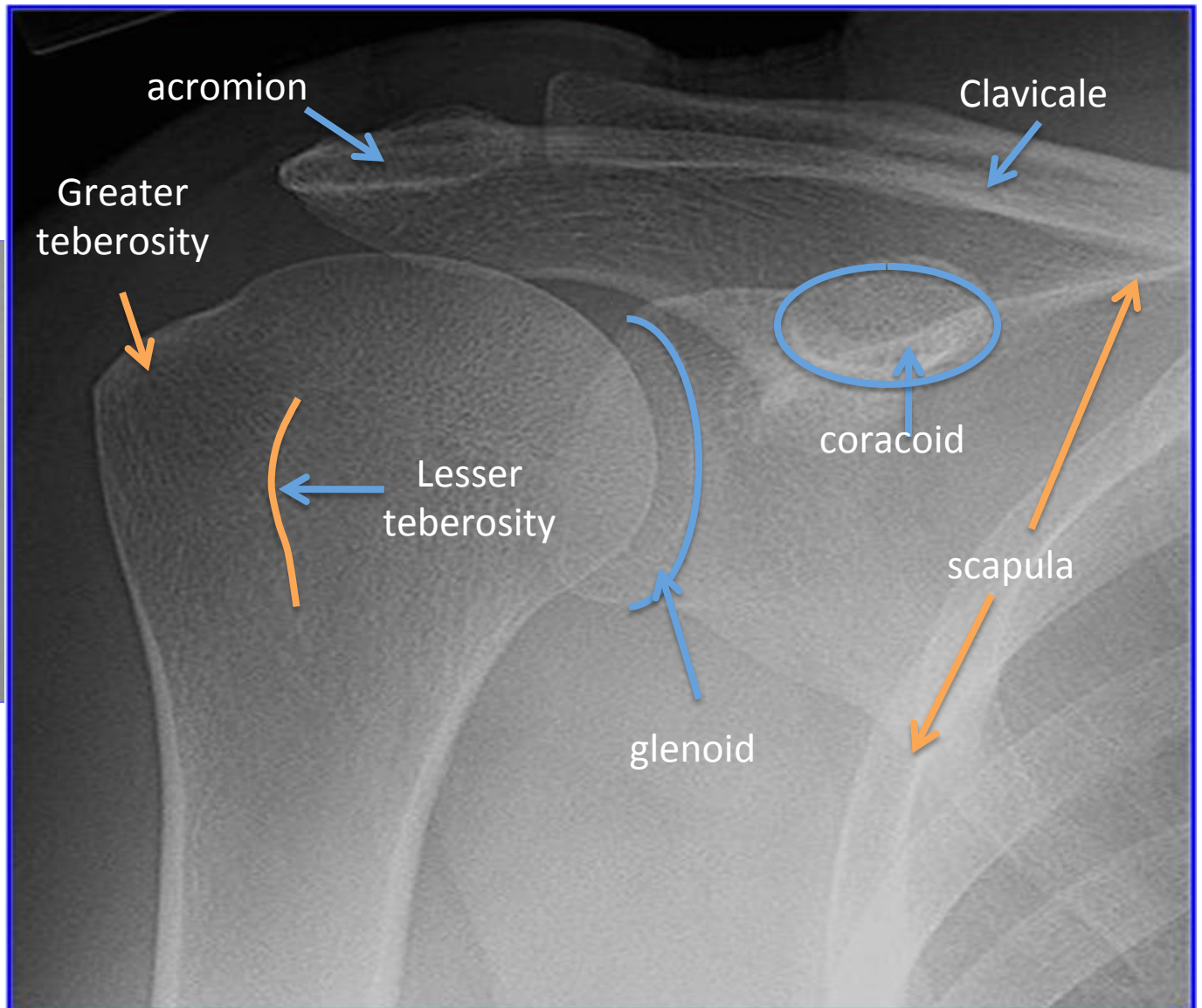
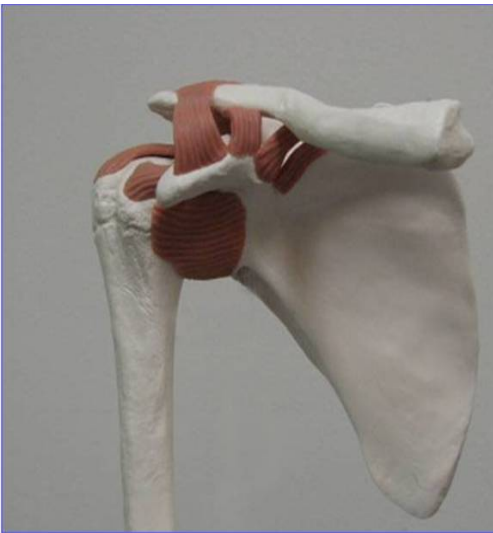RADIOLOGY ANATOMY OF UPPER LIMB

Dr. Abdulrahman Alhawas

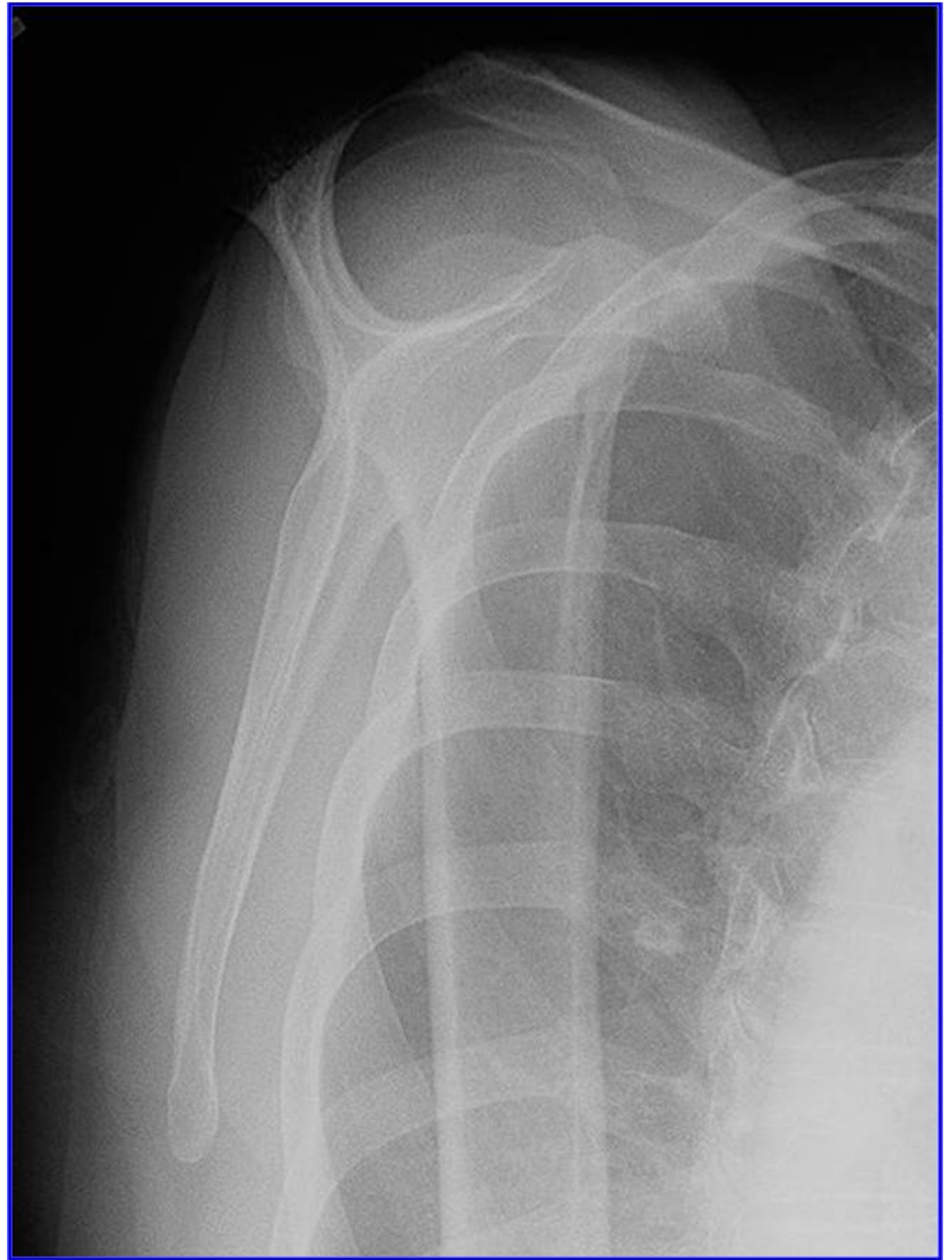
SHOULDER

X-RAY

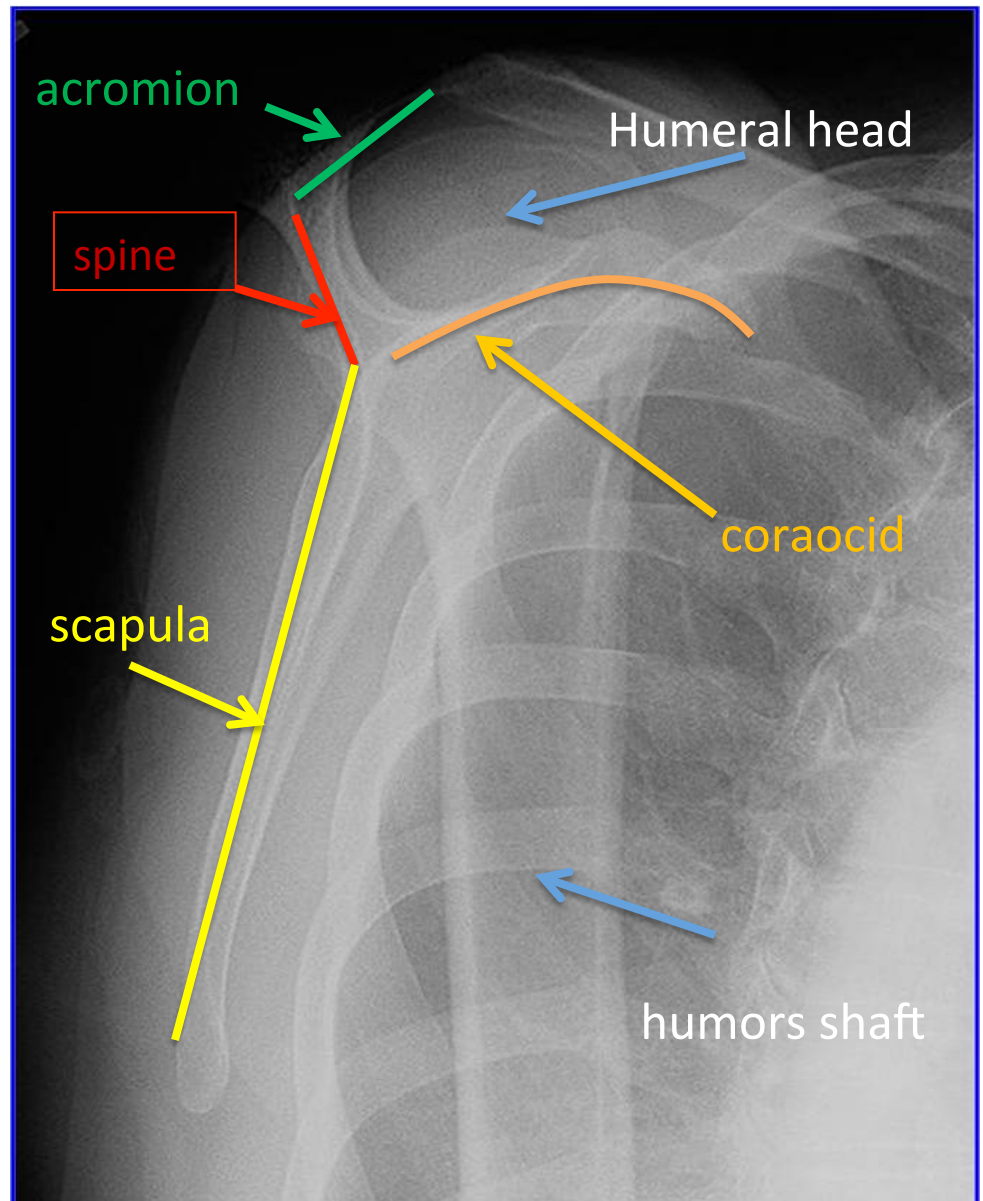


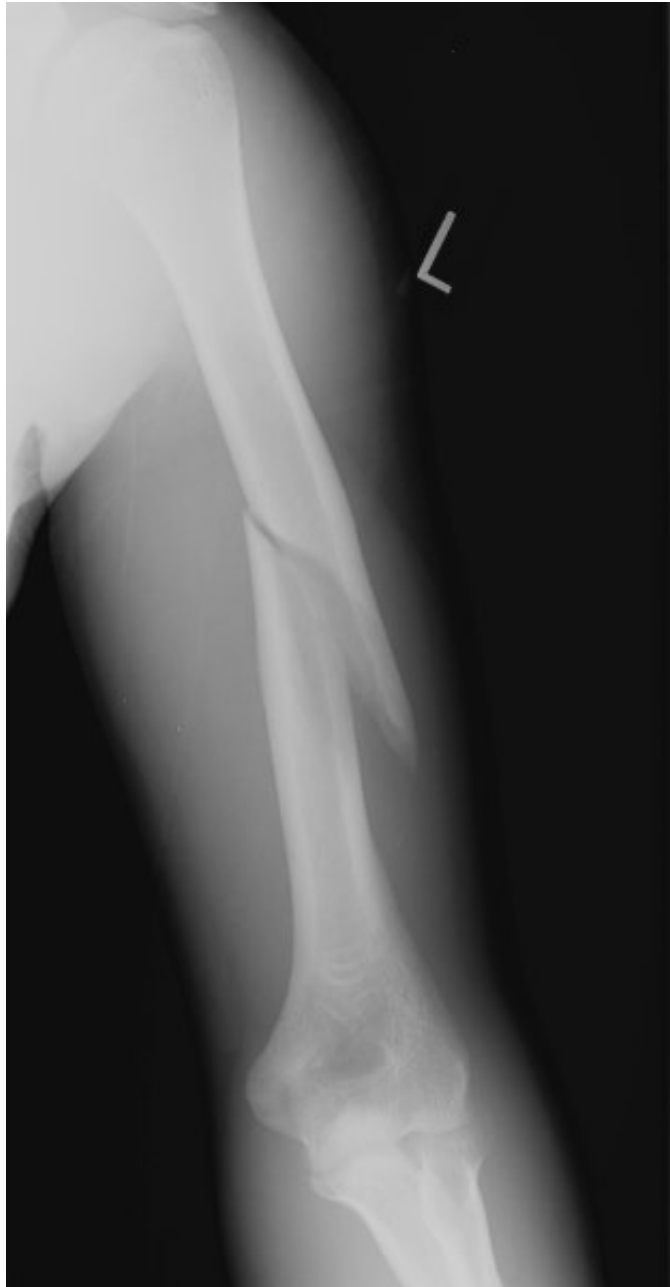

Y view



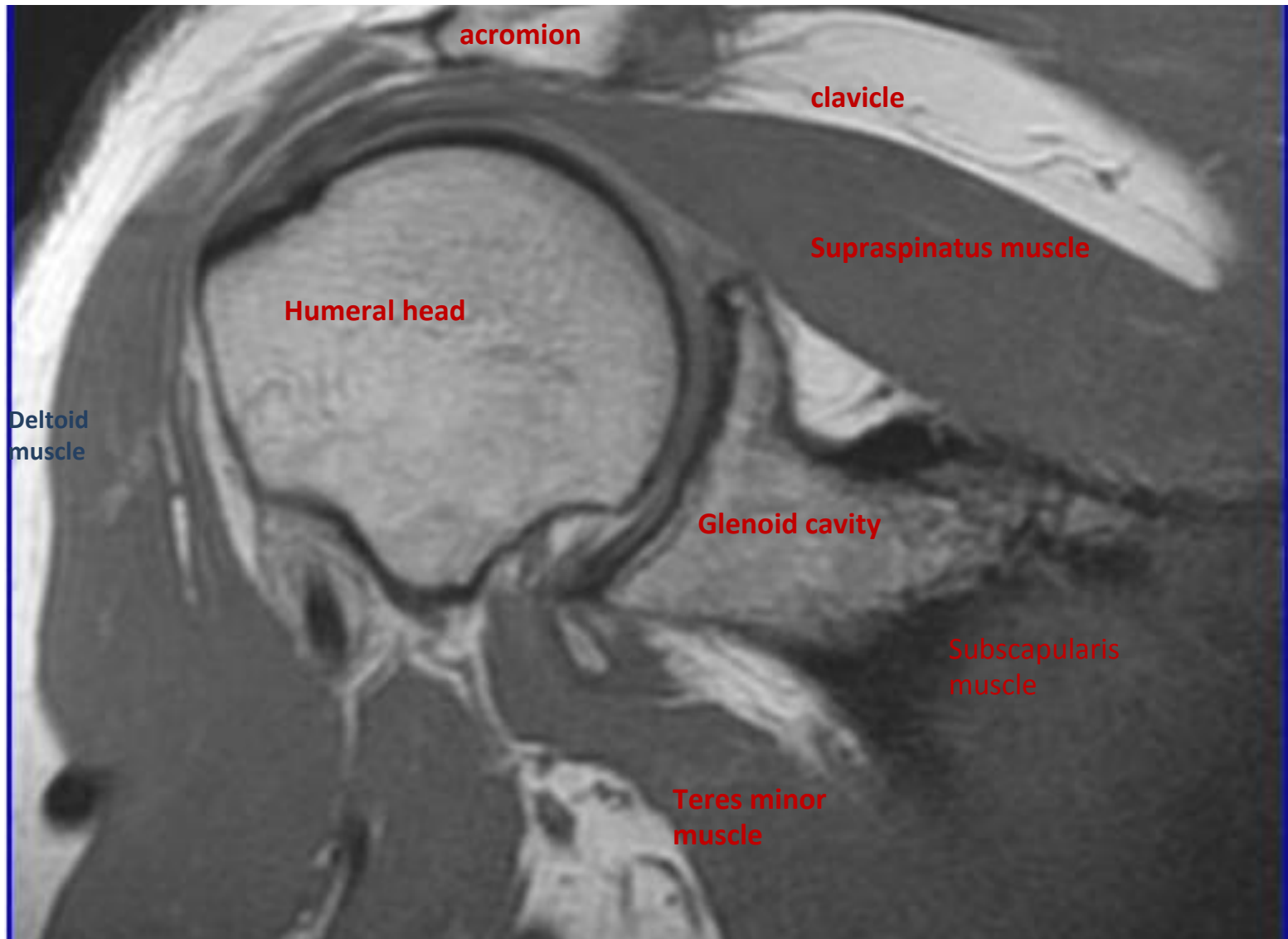
Y view



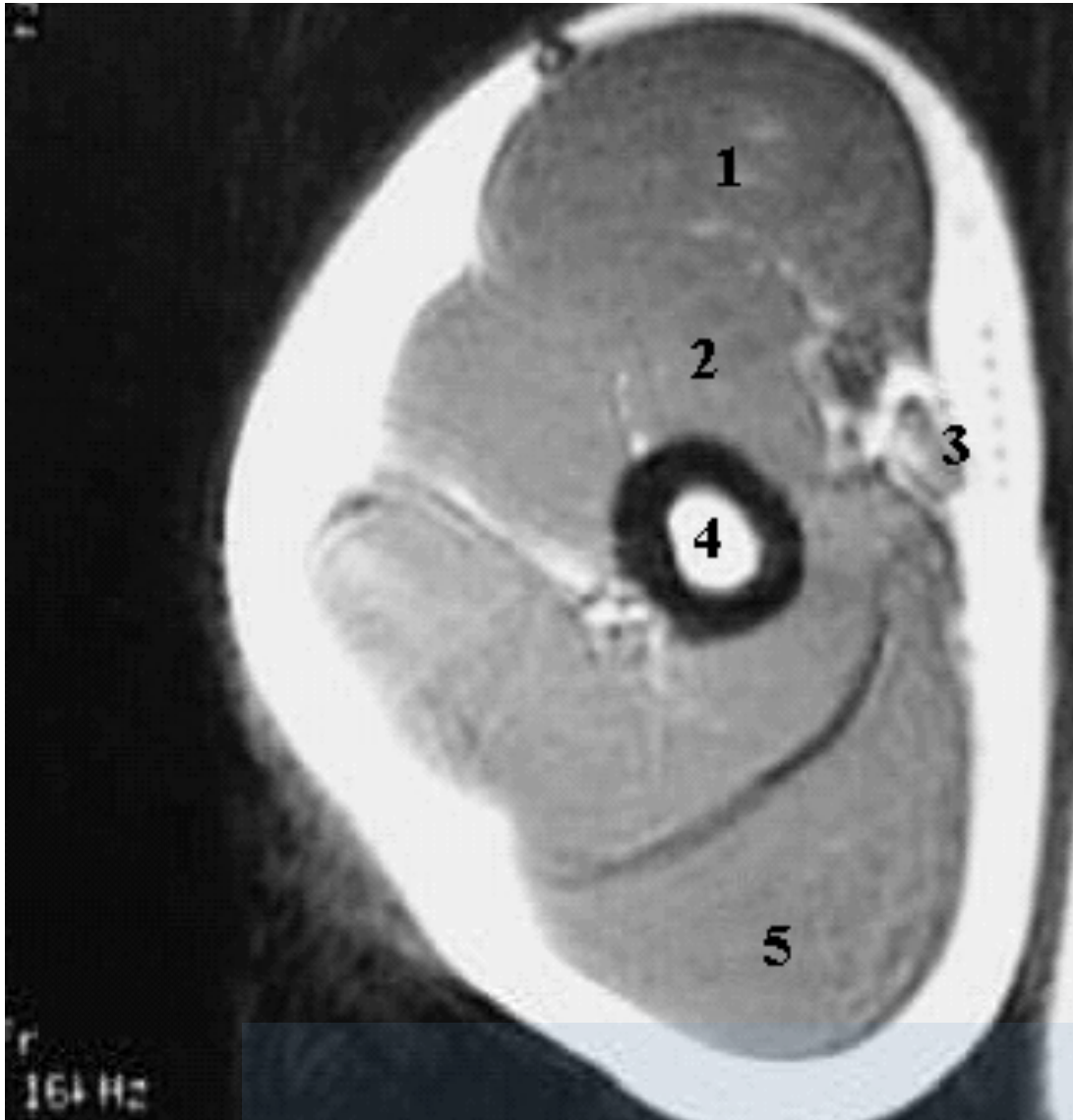


Humerus
fracture

MRI



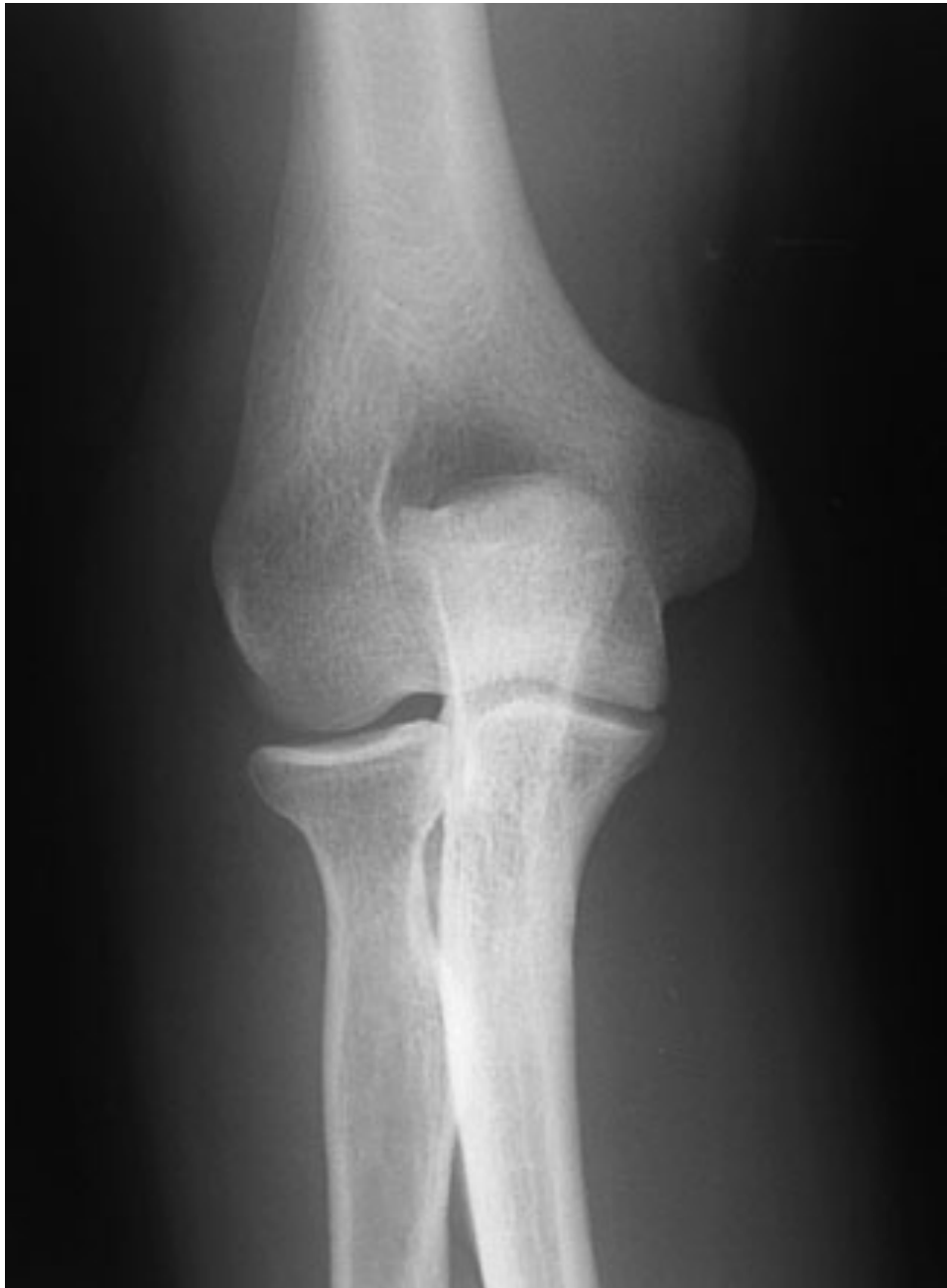ARM MRI

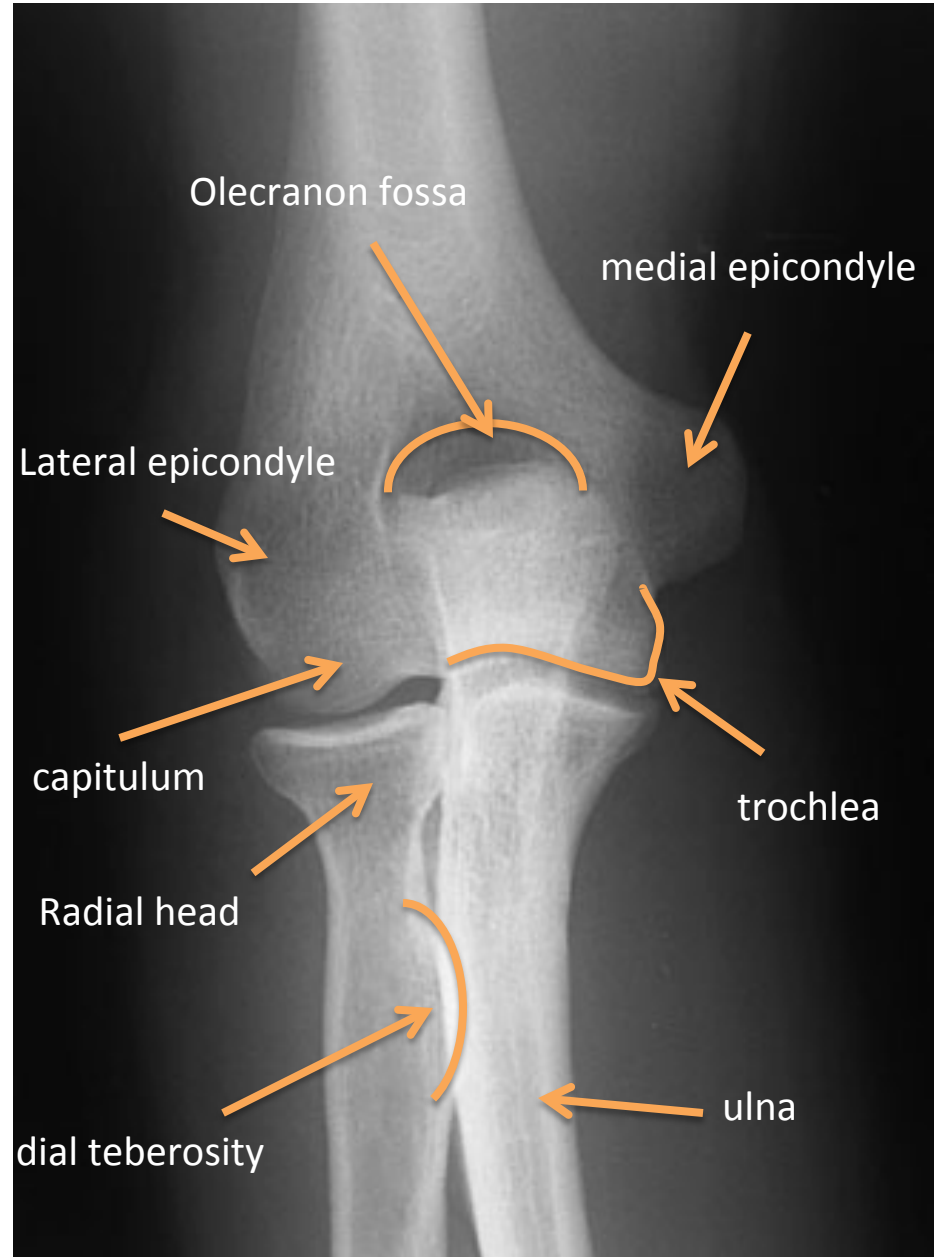
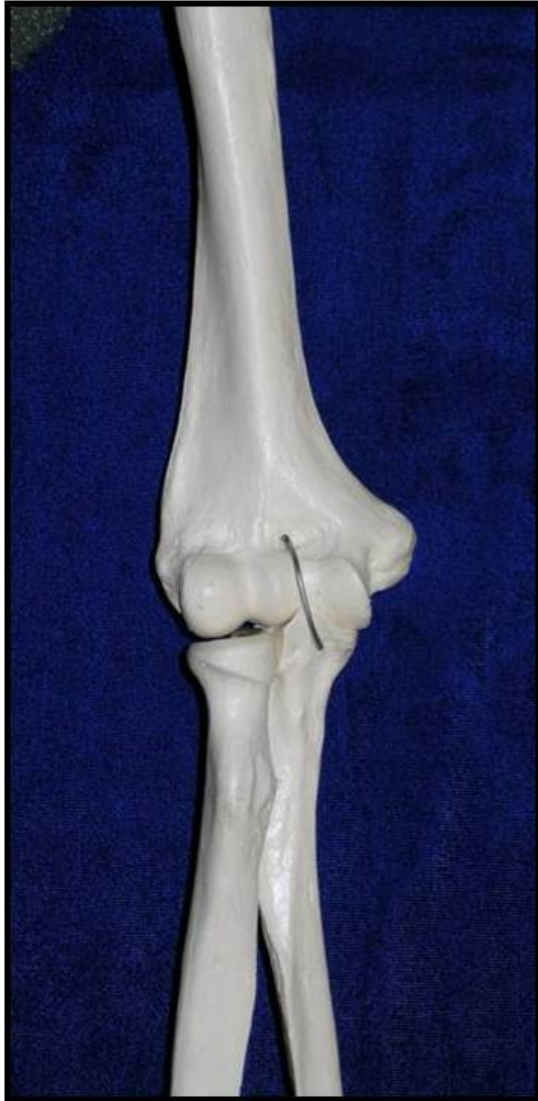

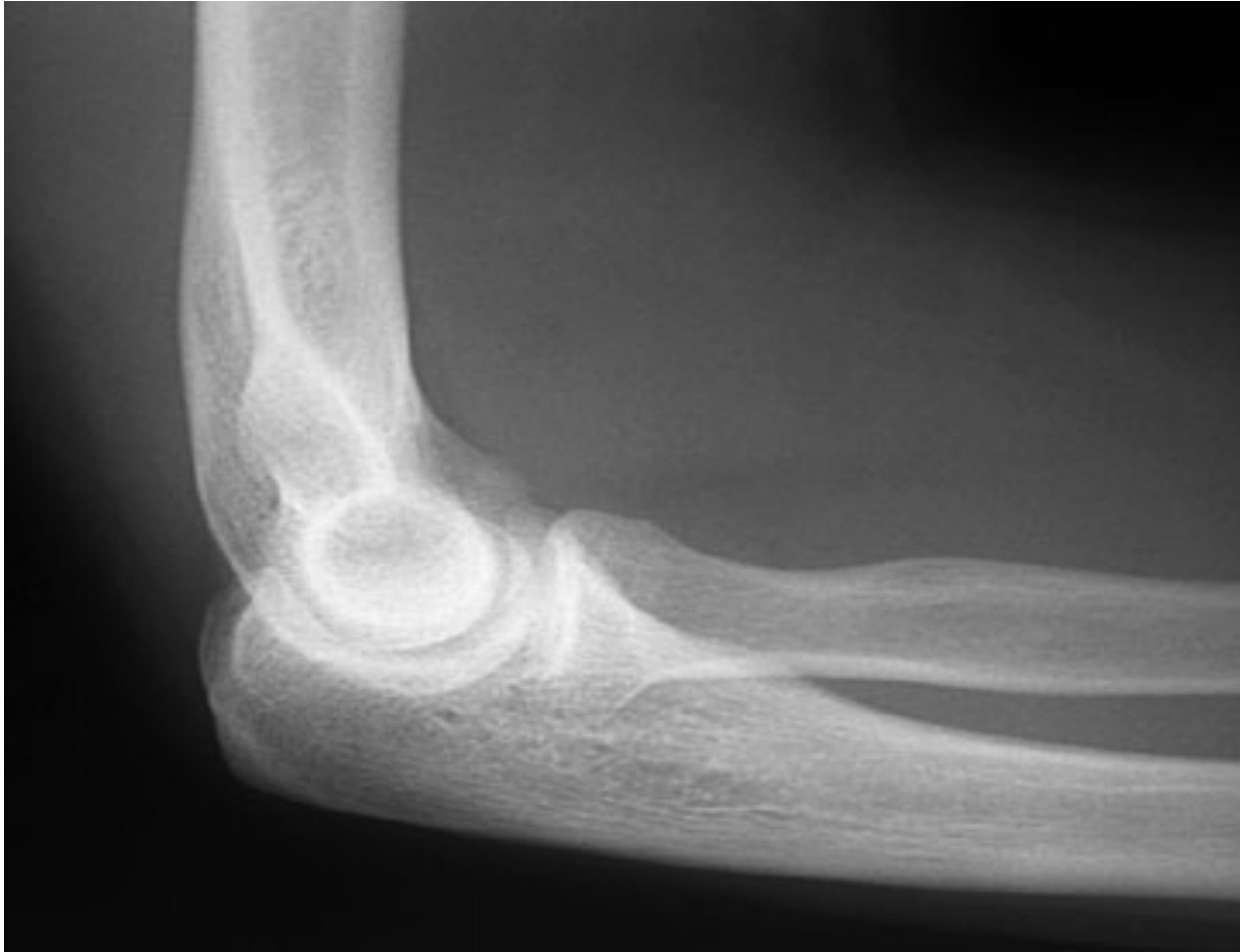- 1-Biceps Muscle.
- 2-Brachialis Muscle.
- 3-Brachial Artery.
- 4-Humerus.
- 5-Triceps Muscle

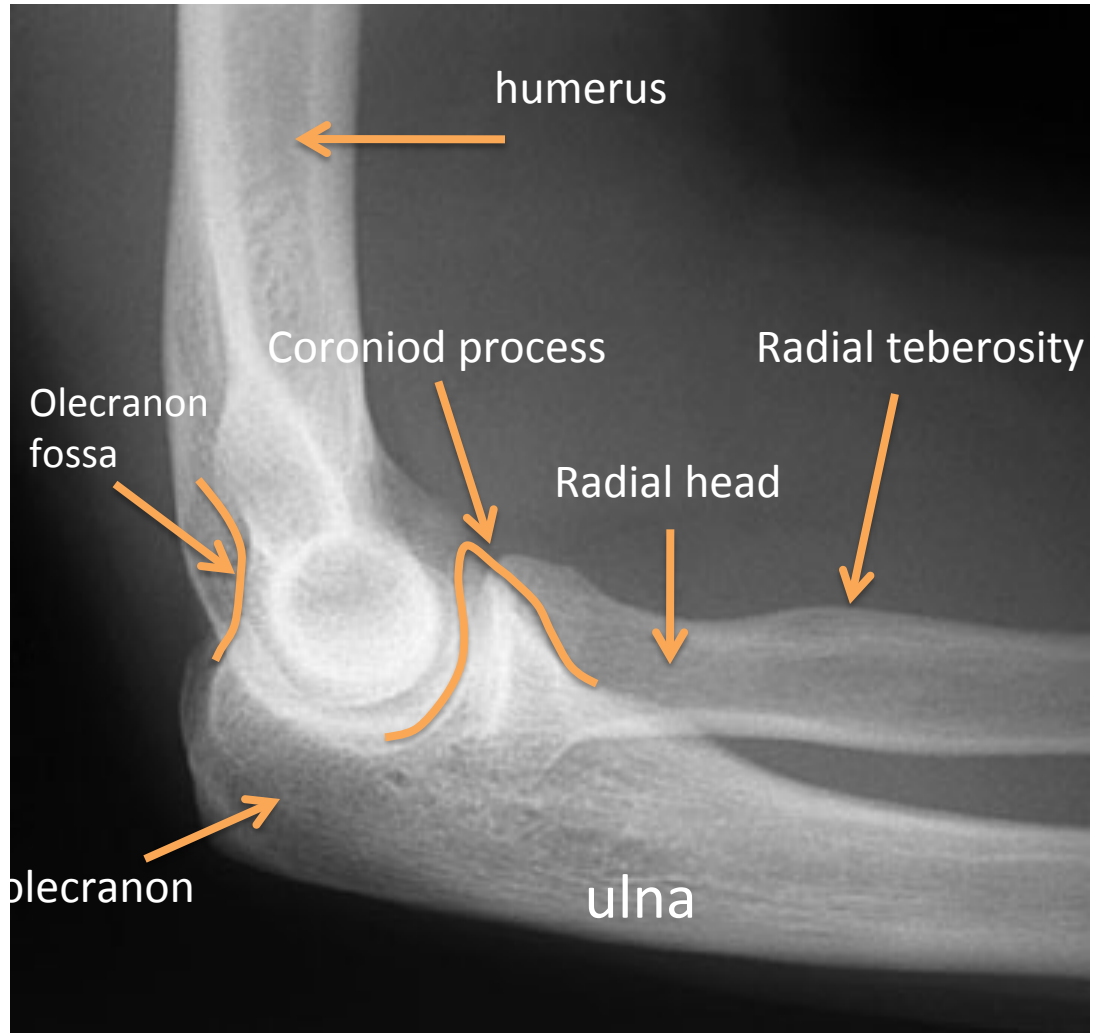
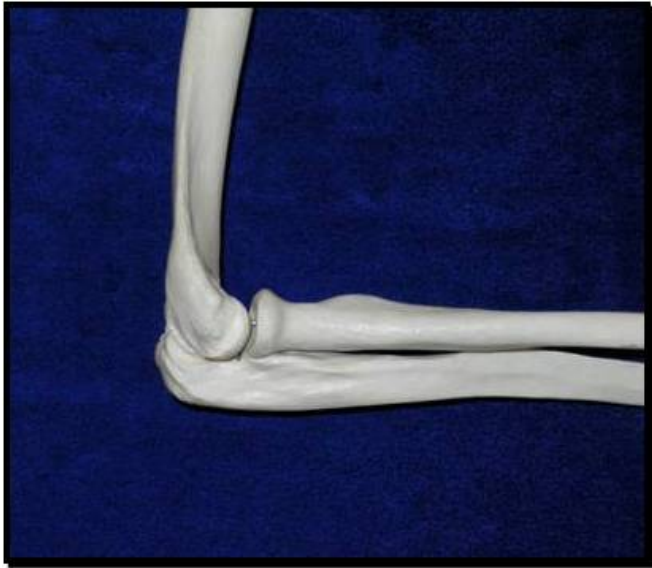ELBOW

X RAY

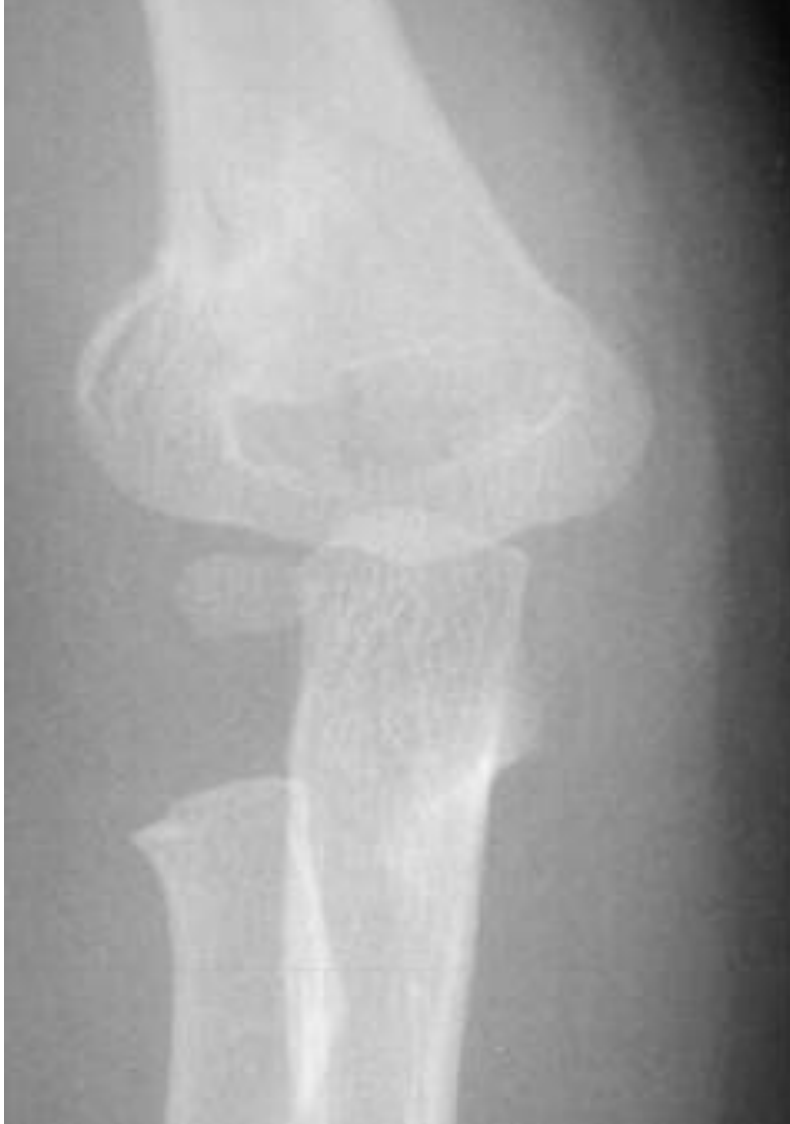




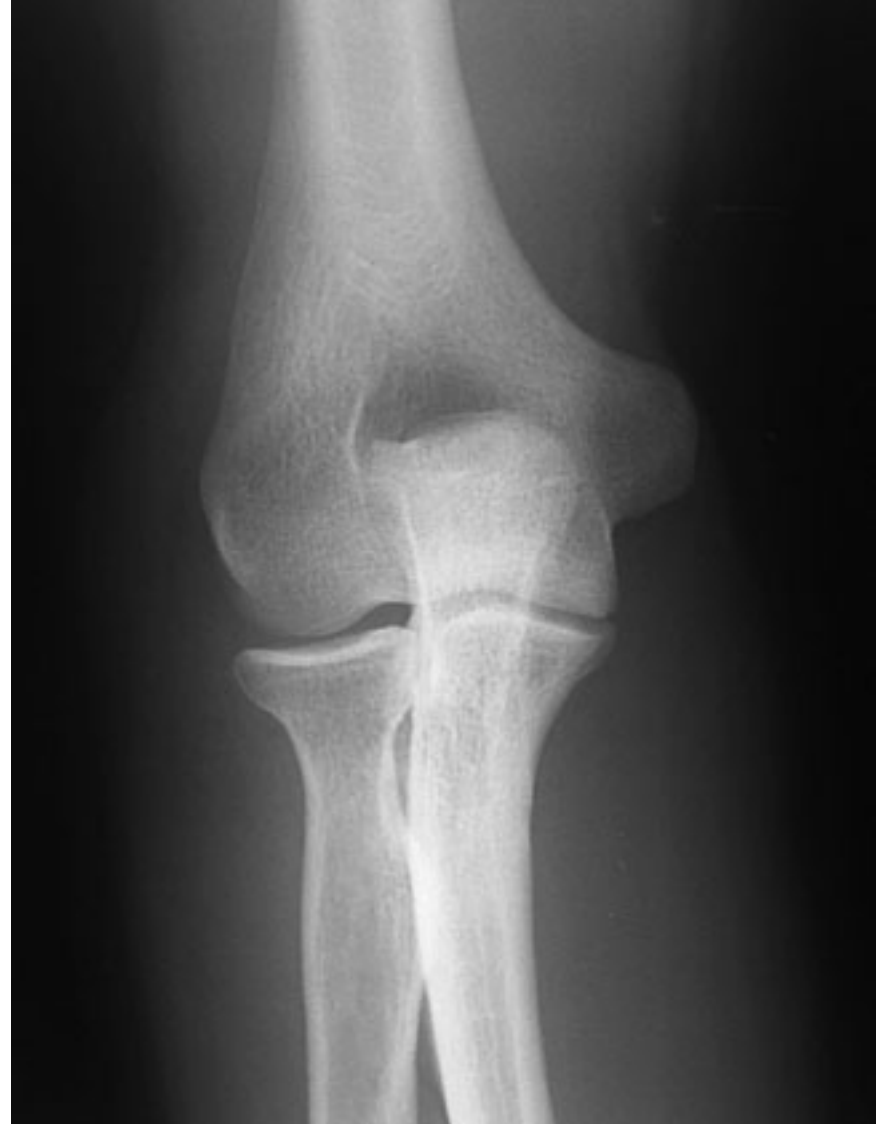


CHILD

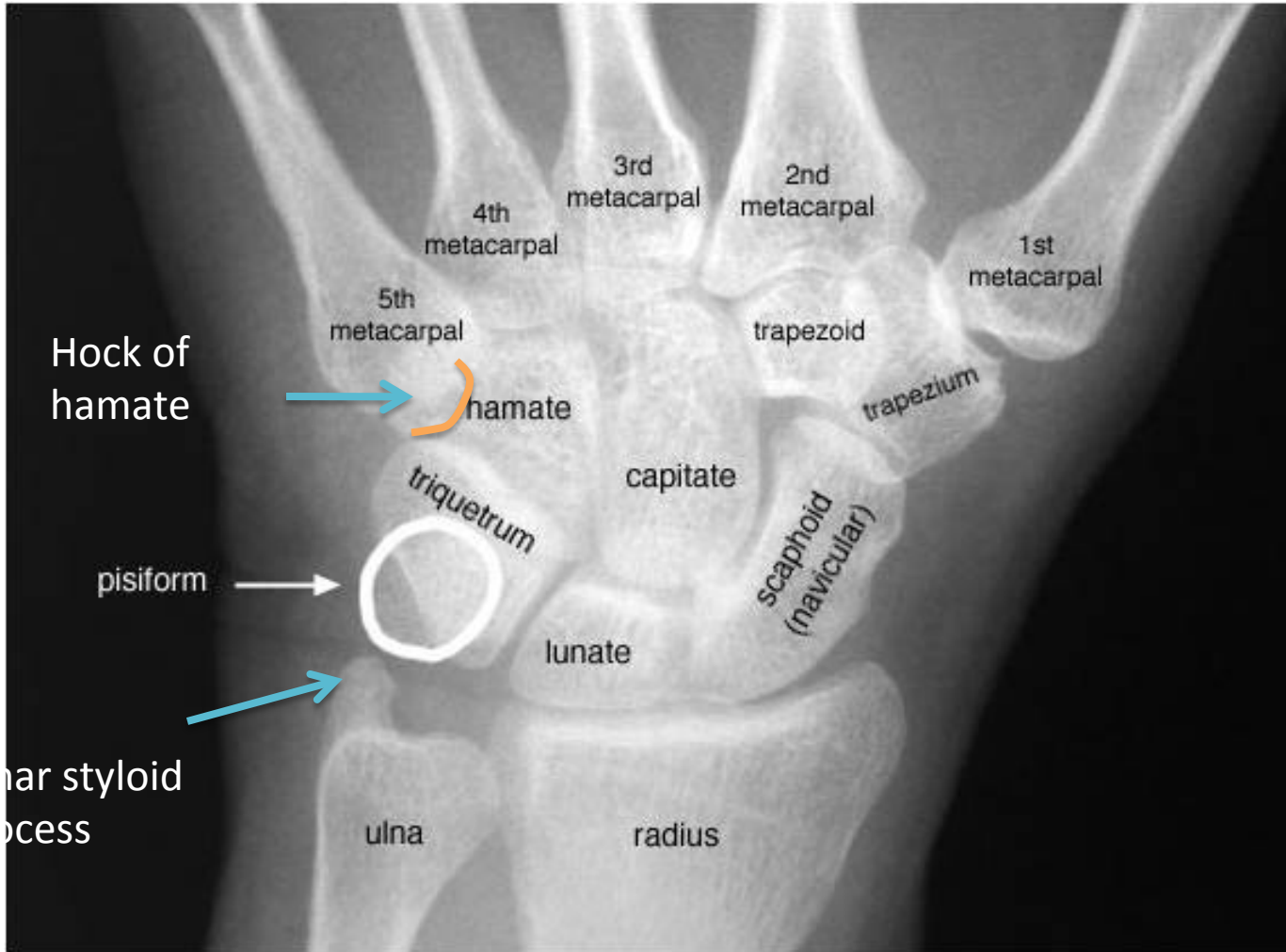

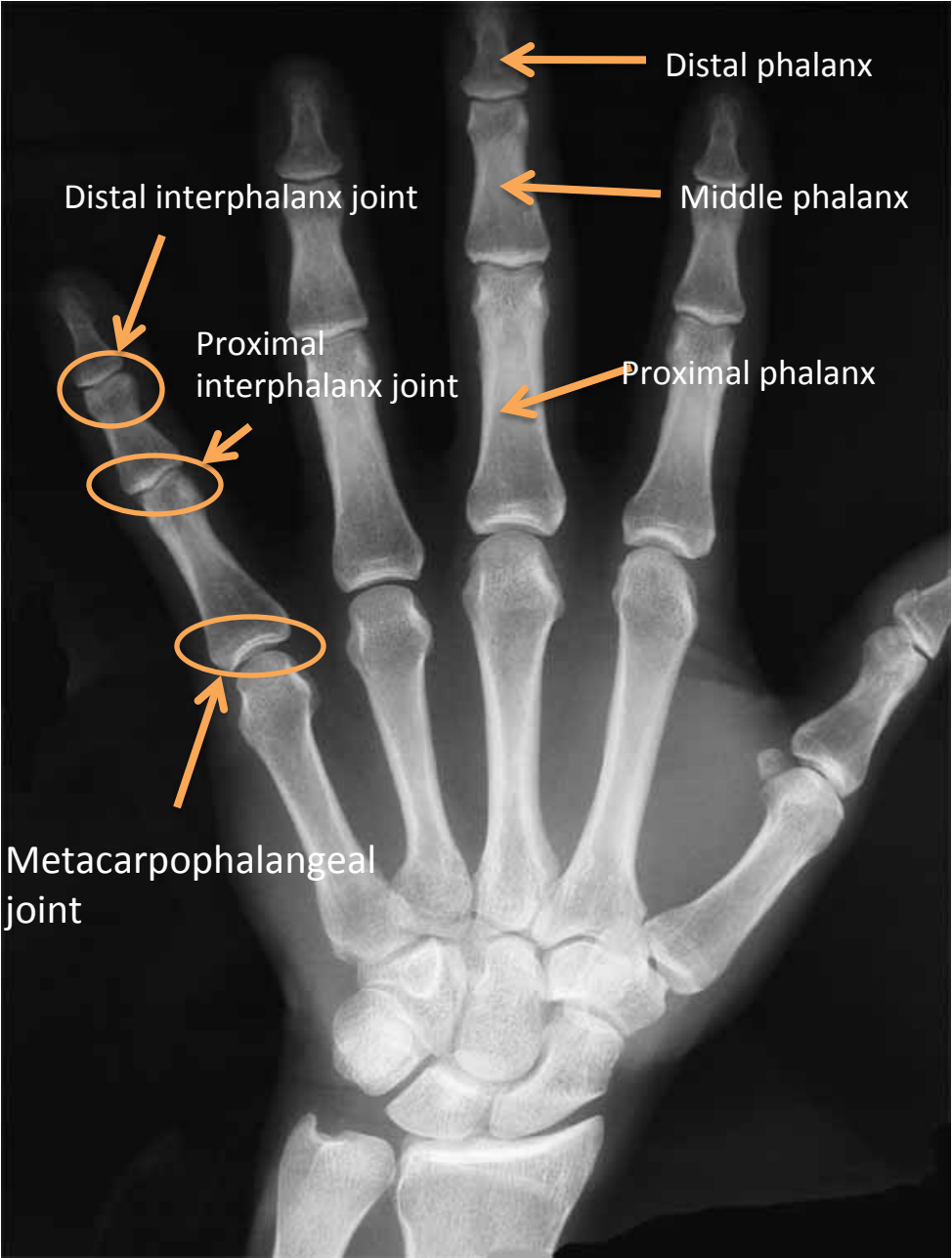ADULT



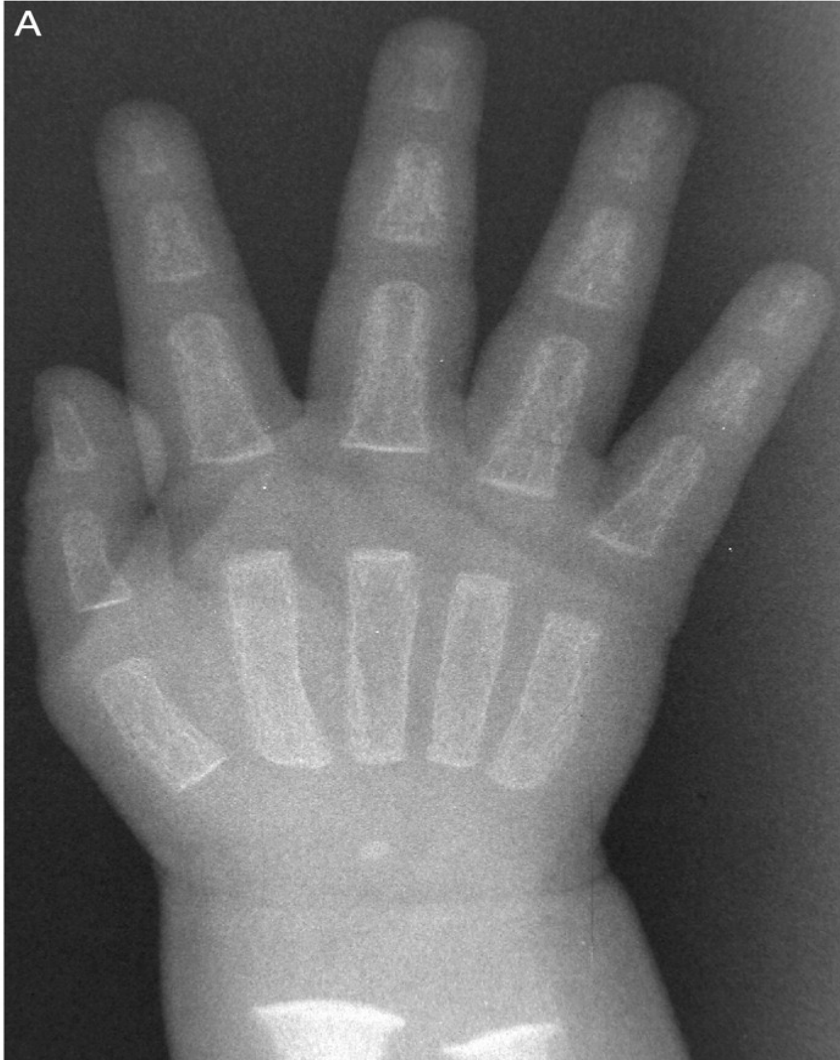HAND

X RAY

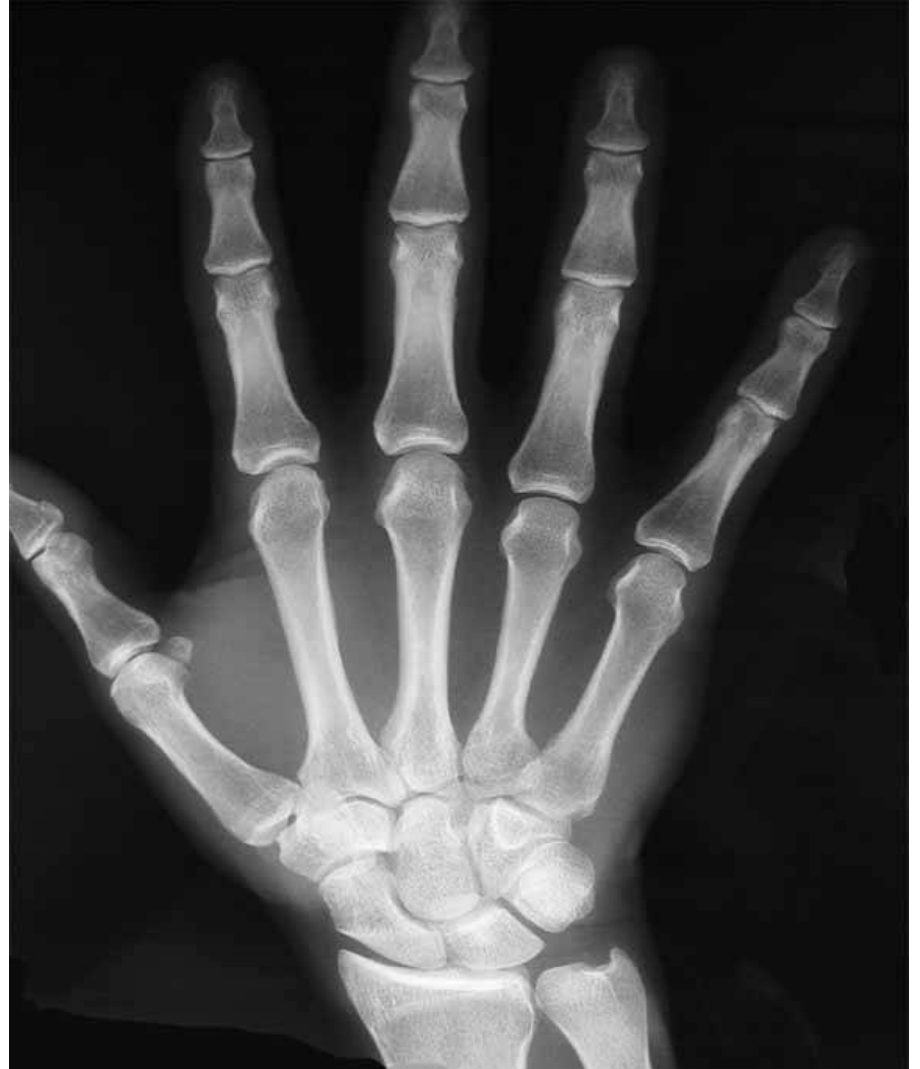



CHILD



ADULT

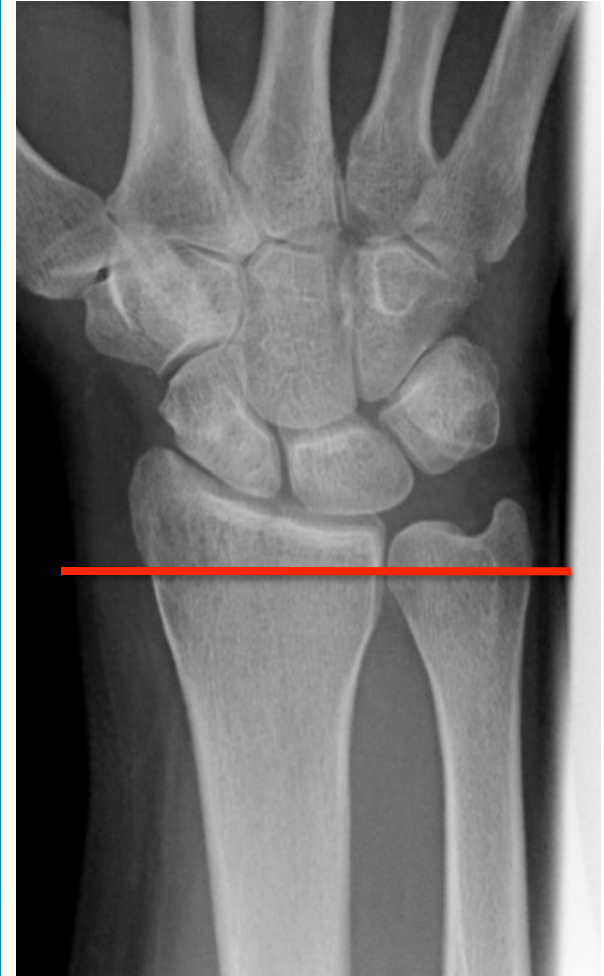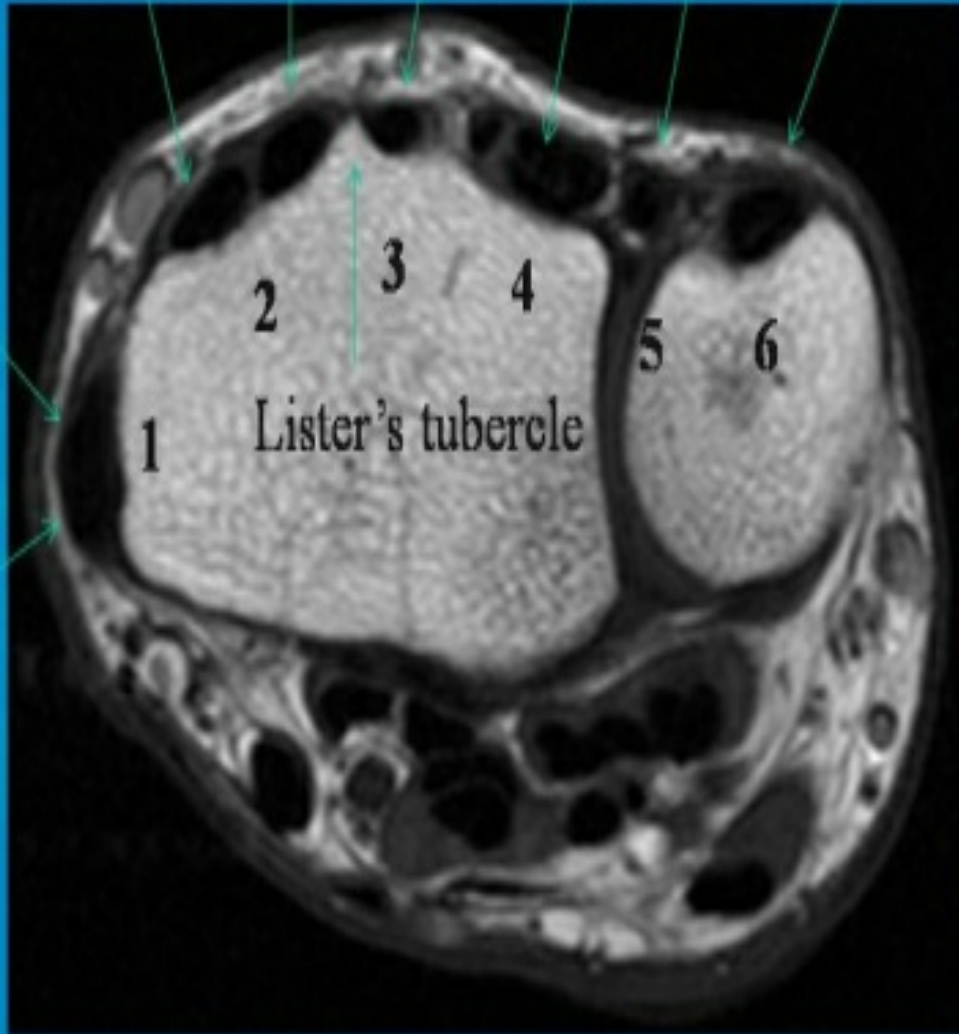


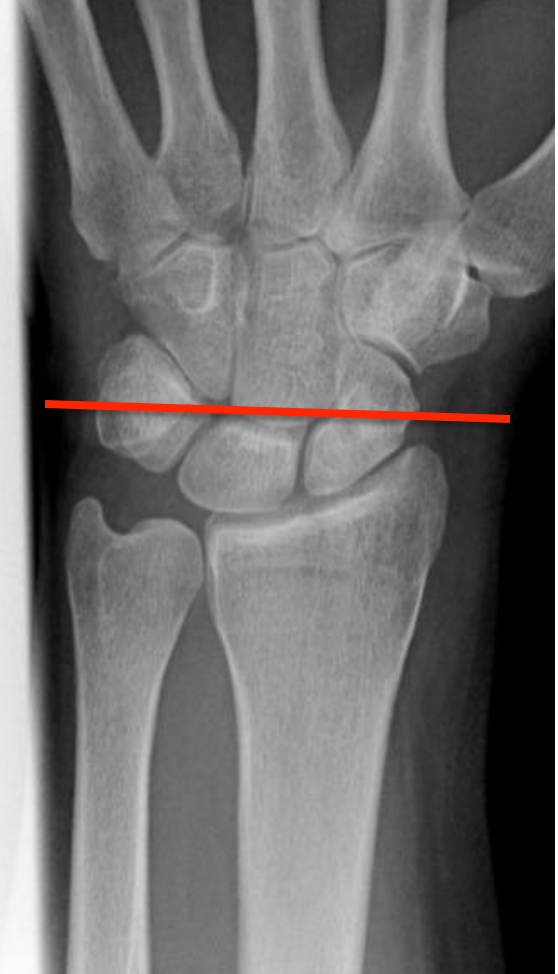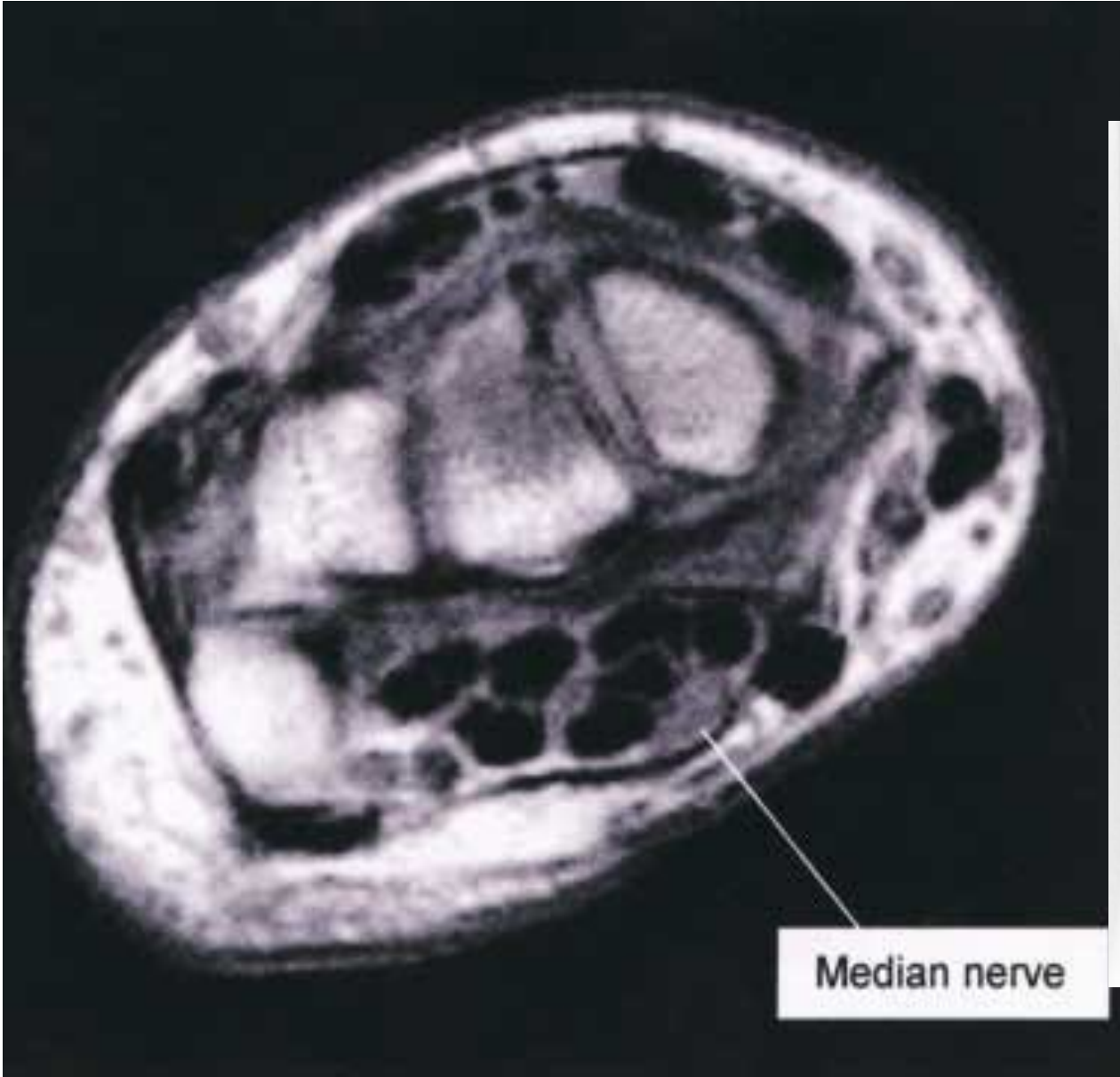
MRI

ECRL ECRB EPL ED EDM EU

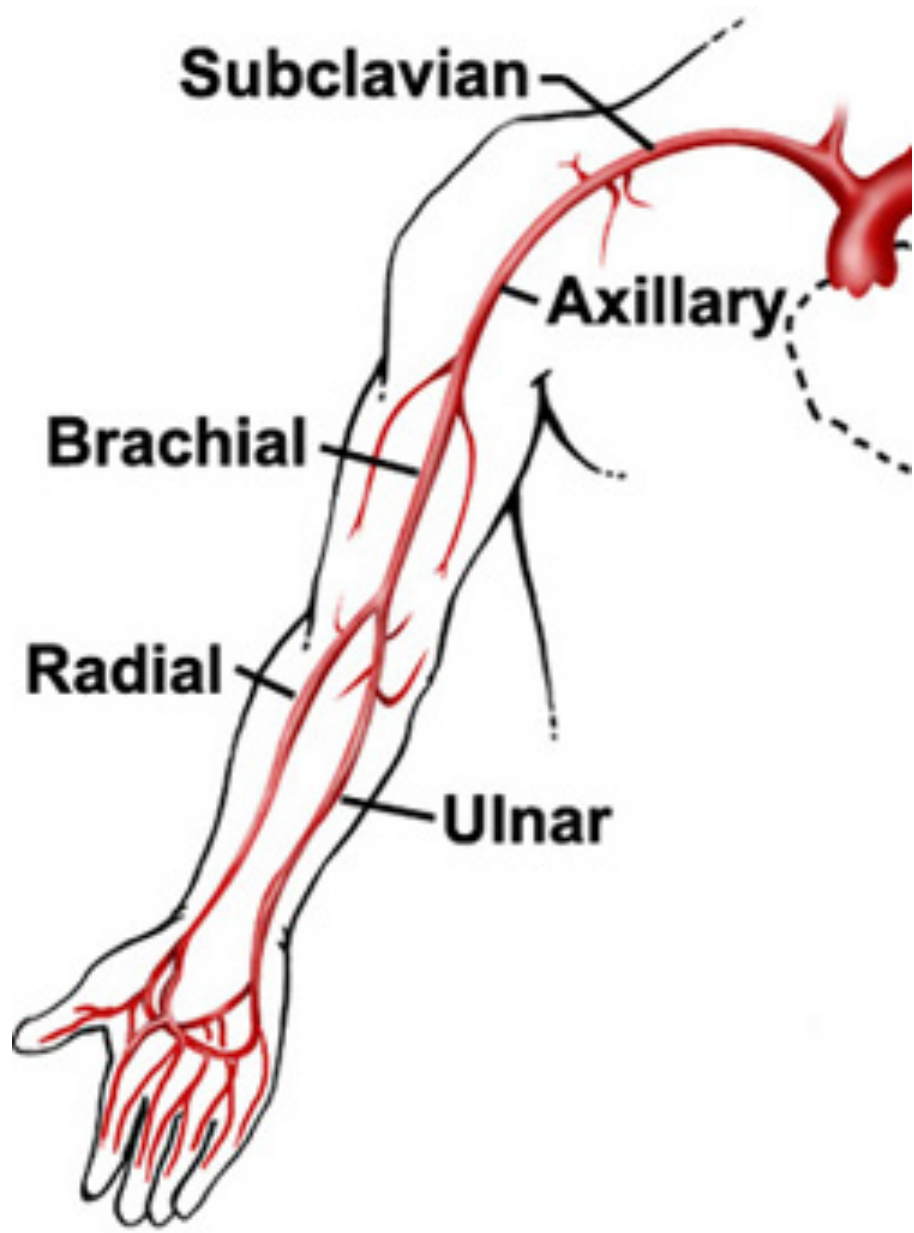
EPB

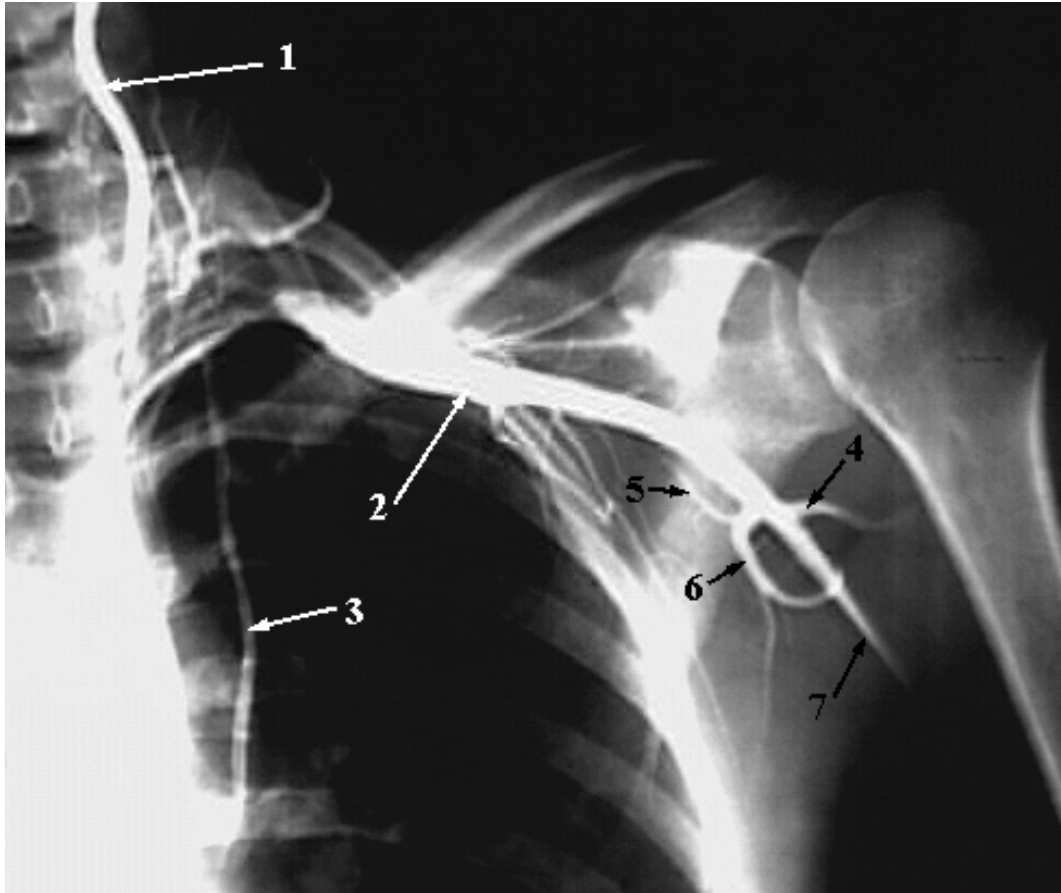APL



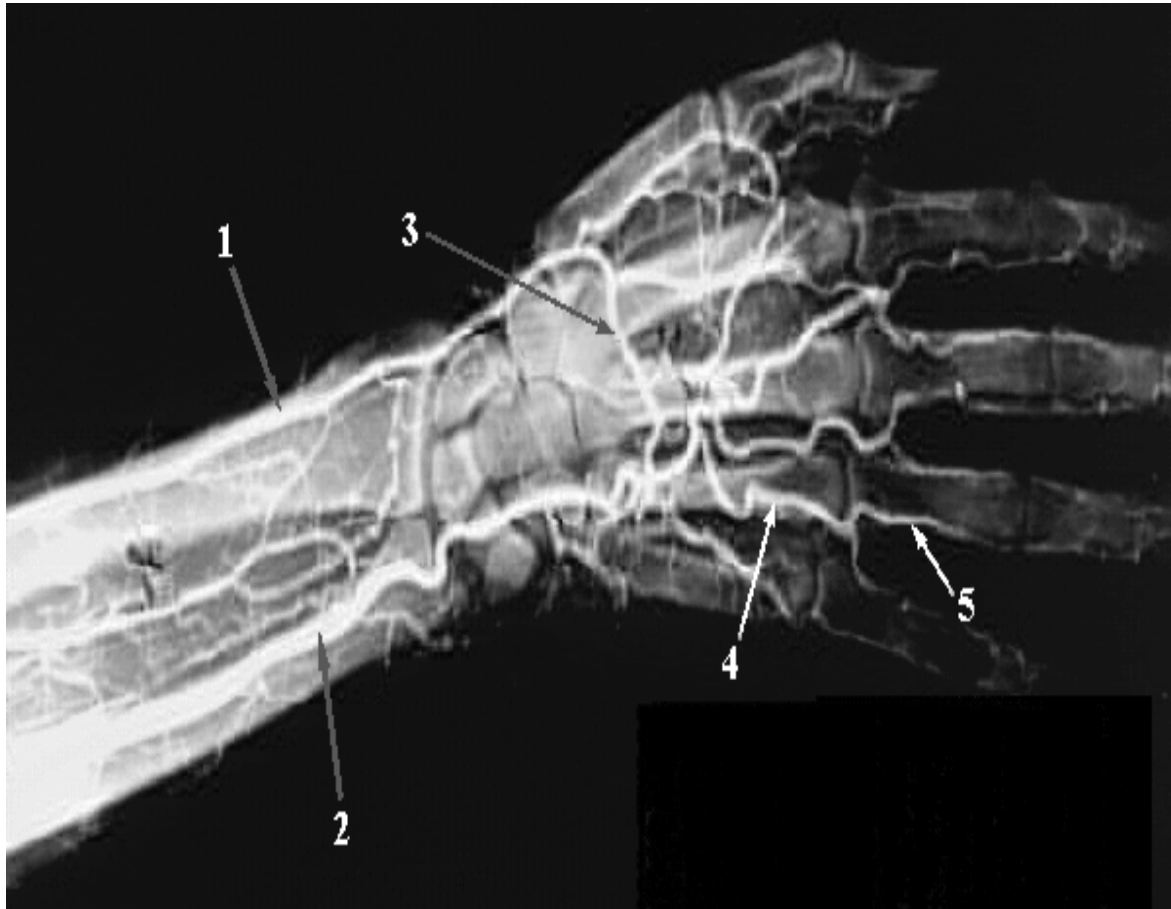

UPPER LIMB VESSELS



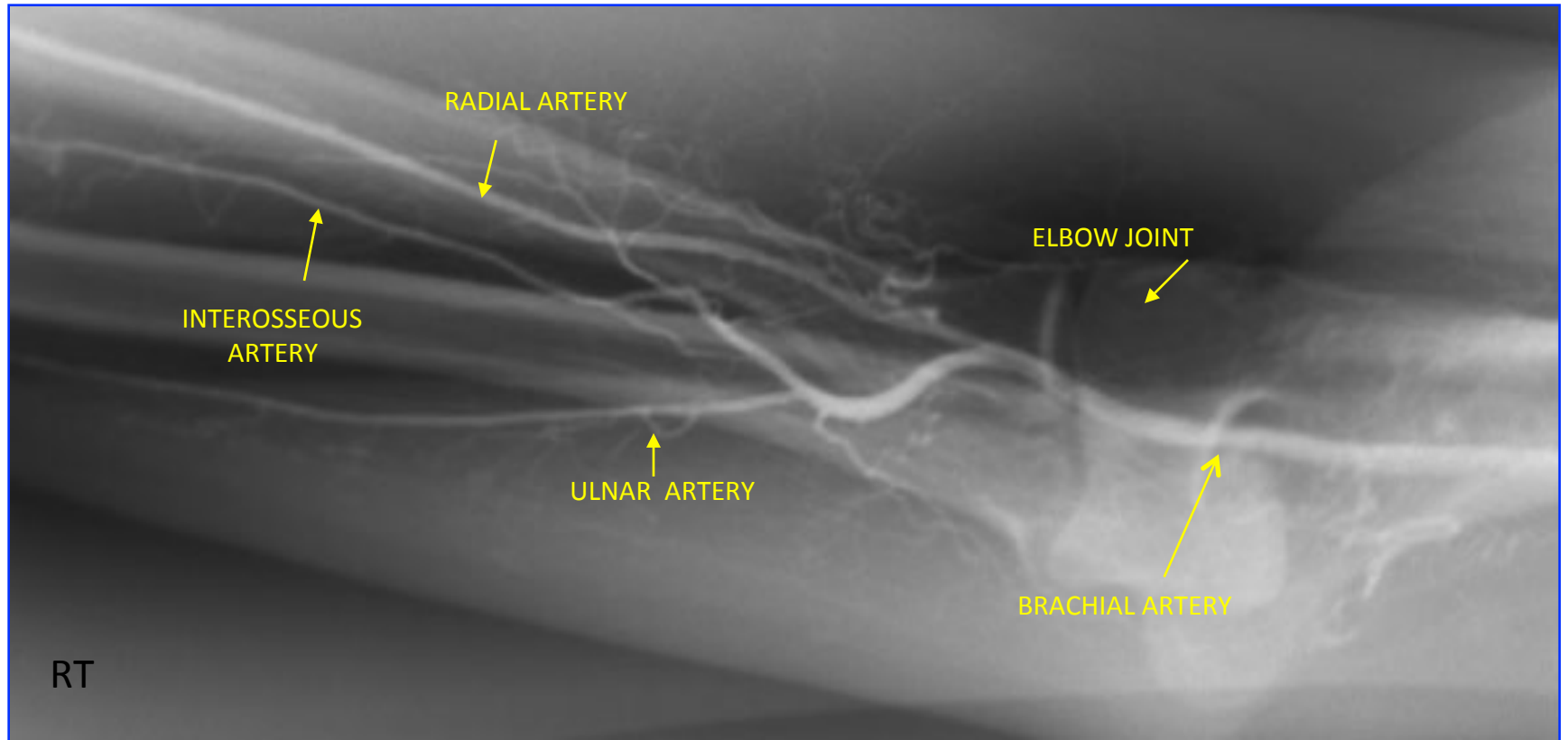


- 1-Vertebral Artery.
- 2-Axillary Artery.
- 3-Internal Thoracic Artery.
- 4-Posterior Humeral Circumflex Artery.
- 5-Circumflex Scapular Artery.
- 6-Subscapular Artery
- 7-brachial artery

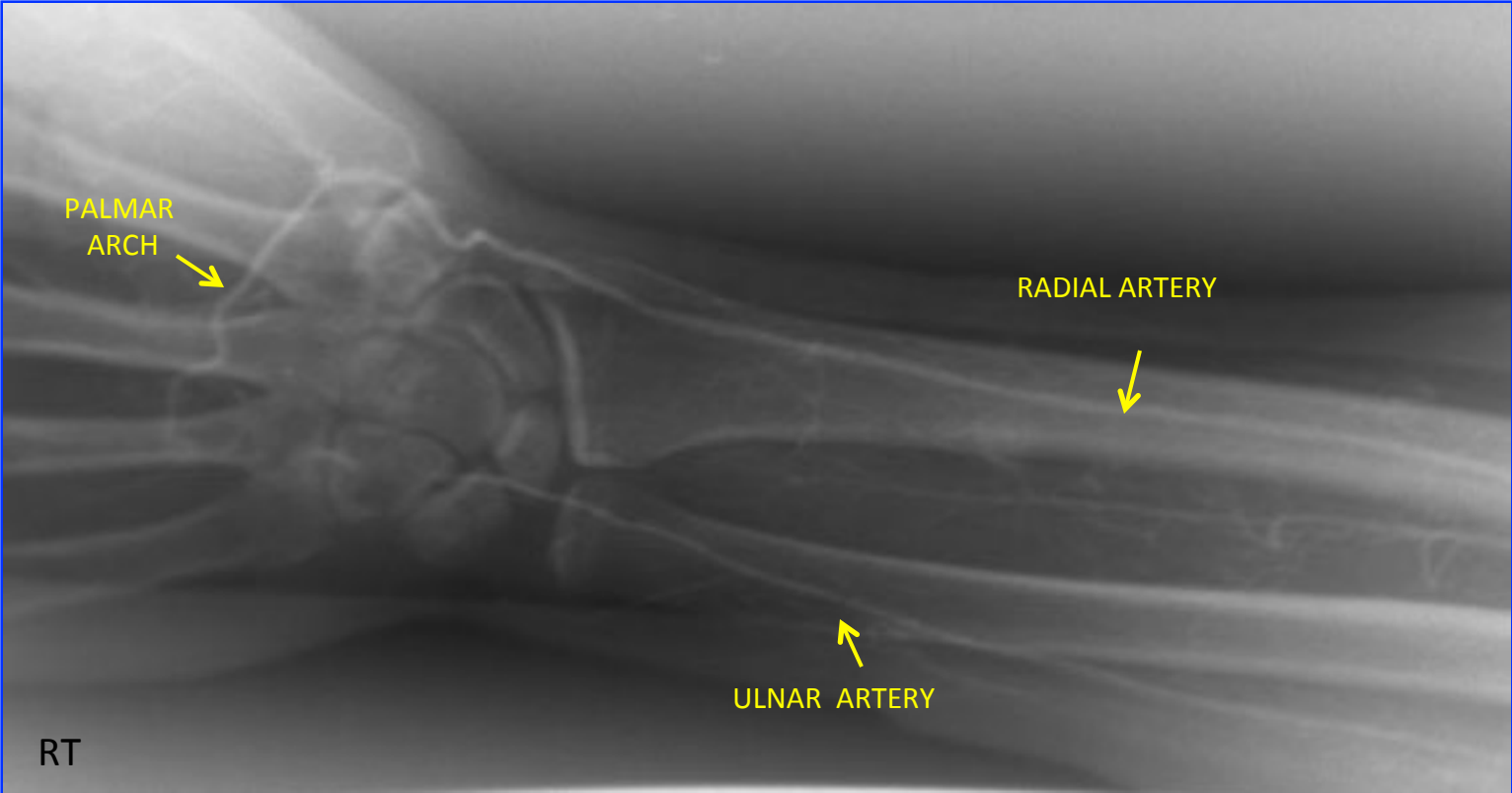


- 1-Radial Artery.
- 2-Ulnar Artery.
- 3-Deep Palmar Arch.
- 4-Common Palmar Digital Artery.
- 5-Proper Palmar Digital Artery

RT. UPPER EXTREMITY ANGIOGRAM



RT. UPPER EXTREMITY ANGIOGRAM



THE END