

**INTRODUCTION TO SURFACE
ANATOMY
OF
UPPER & LOWER LIMBS**

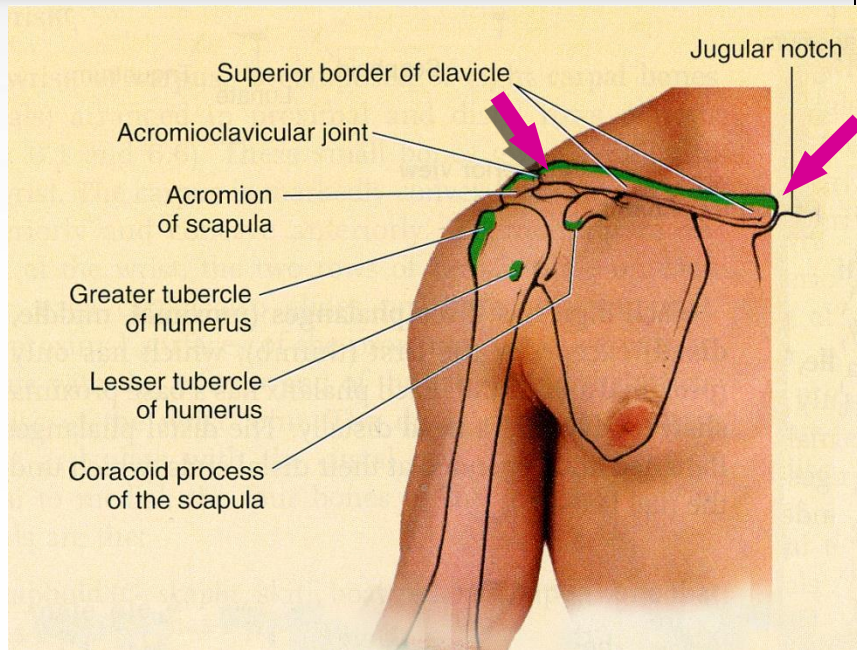
OBJECTIVES

By the end of the lecture, you should be able to:

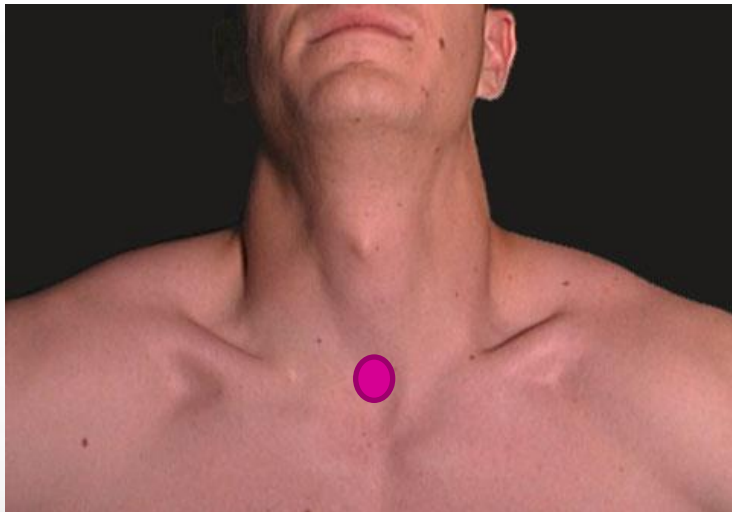- Palpate and feel the important bony prominences in upper and lower limbs.
- Palpate and feel the different muscles and muscular groups and tendons.
- Perform some movements to see the action of individual muscle or muscular groups in the upper and lower limbs.
- Feel the pulsations of most of the arteries of the upper and lower limbs.
- Locate the site of most of the superficial veins in the upper and lower limbs

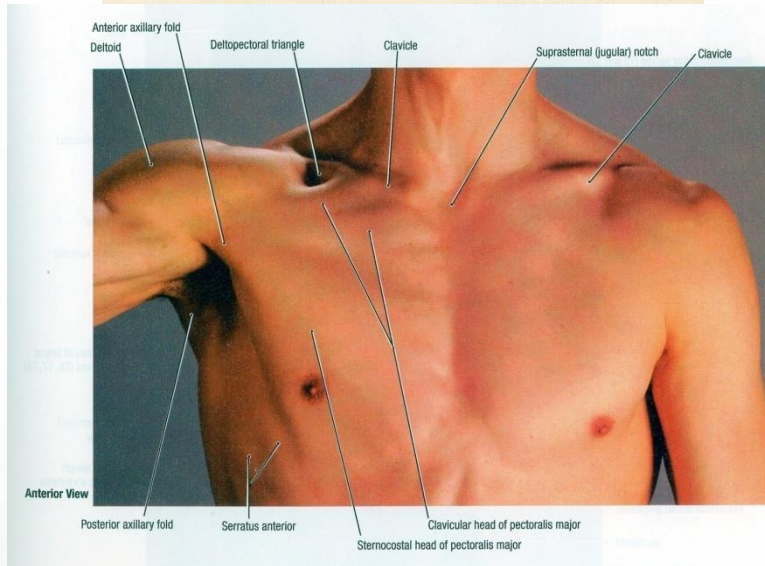
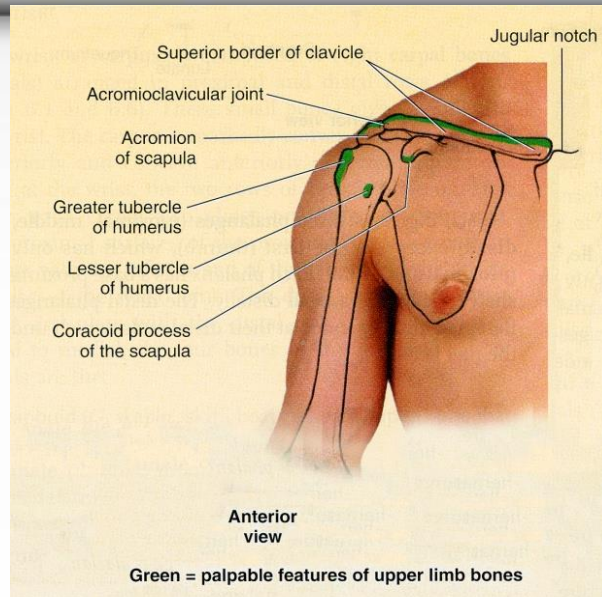
What is Surface Anatomy?

- It is a branch of gross anatomy that examines shapes and markings on the surface of the body as they are related to deeper structures.
- It is essential in locating and identifying anatomic structures prior to studying the internal gross anatomy.
- It helps to locate the affected organ / structure / region in disease process.



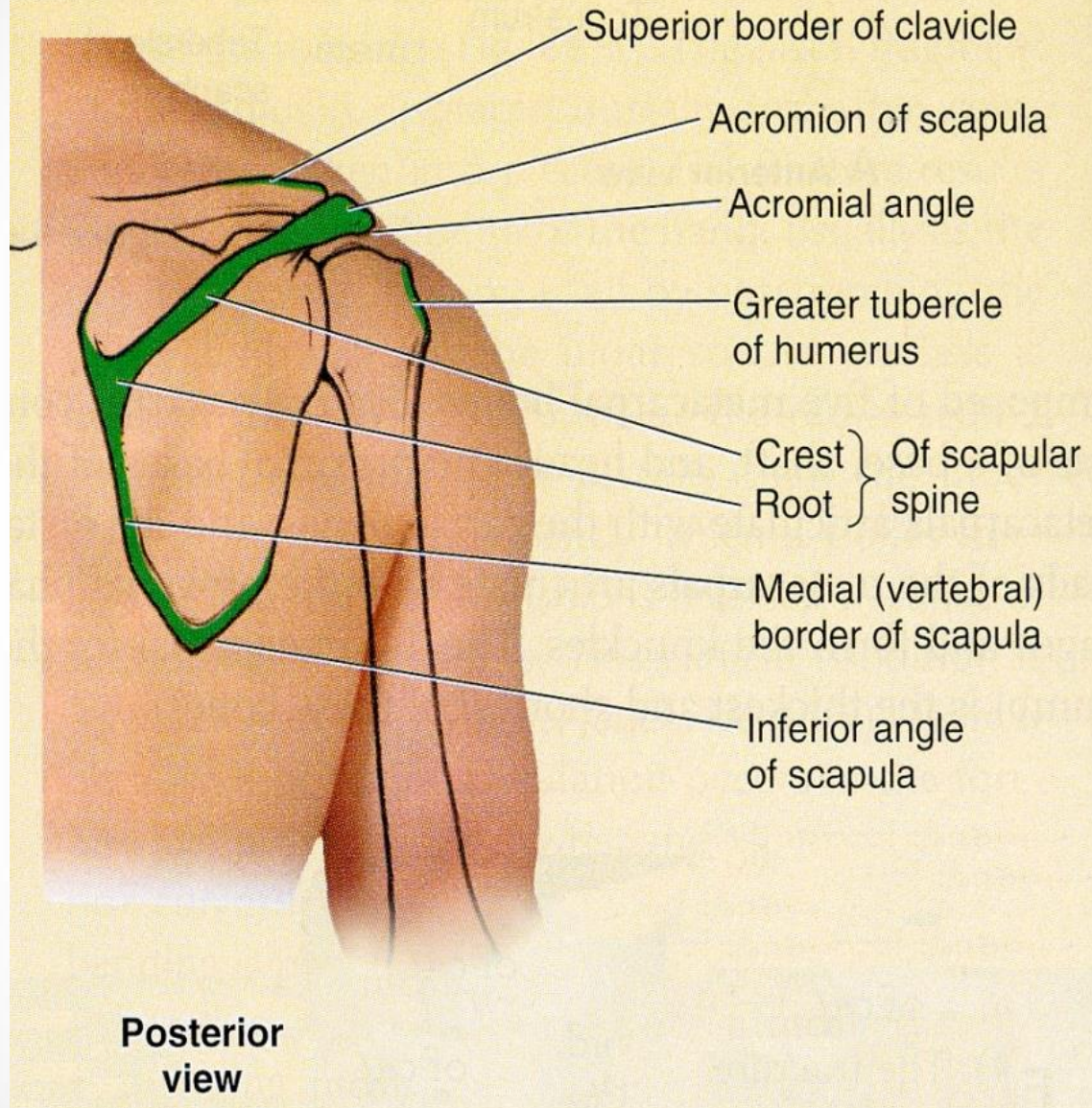
- The **clavicle** is subcutaneous and can be palpated throughout its length.
- Its **sternal end** projects little above the manubrium.
- Between the 2 sternal ends of the 2 clavicle lies the **jugular notch** (suprasternal notch).
- The **acromial** end of the clavicle can be palpated medial to the lateral border of the **acromion**, of the scapula. particularly when the shoulder is alternately raised and depressed.
- The large vessels and nerves to the upper limb pass posterior to the convexity of the **clavicle**.





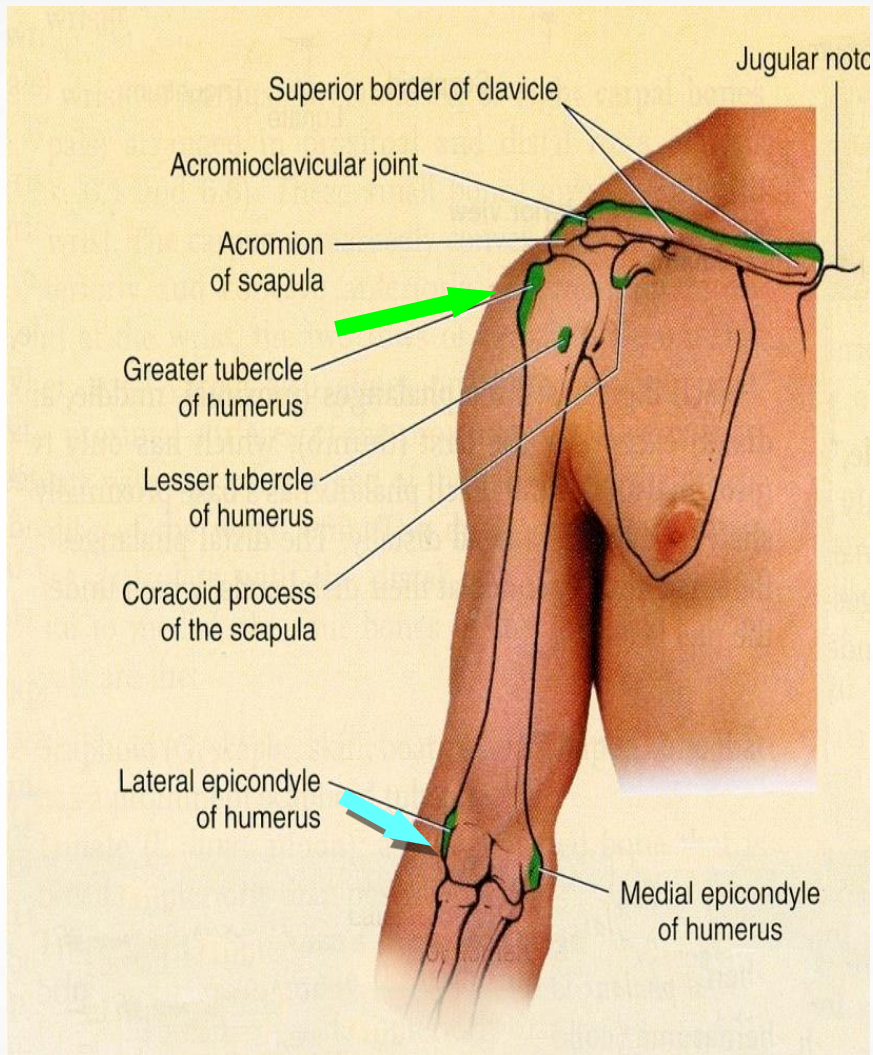
- The **coracoid process** of scapula can be felt deeply below the lateral one third of the clavicle in the **Deltopectoral GROOVE** or **clavipectoral triangle**.
- The **clavipectoral** or the **(Deltopectoral) triangle** is the slightly depressed area just inferior to the lateral third of clavicle.
- The clavipectoral triangle is bounded by:
 - Clavicle **superiorly**,
 - Deltoid **laterally**, and
 - Pectoralis major **medially**.

otch



The lateral and posterior borders of the acromion meet to form the **acromial angle**.

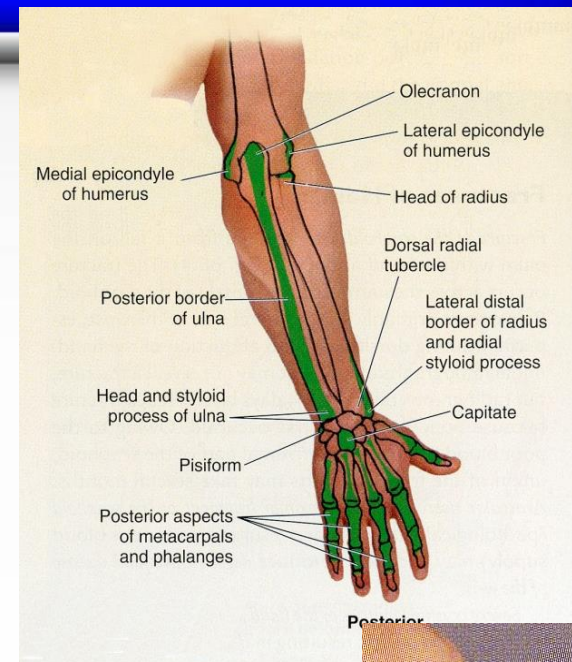
Inferior to the acromion, the **deltoid muscle** forms the rounded contour of the shoulder.



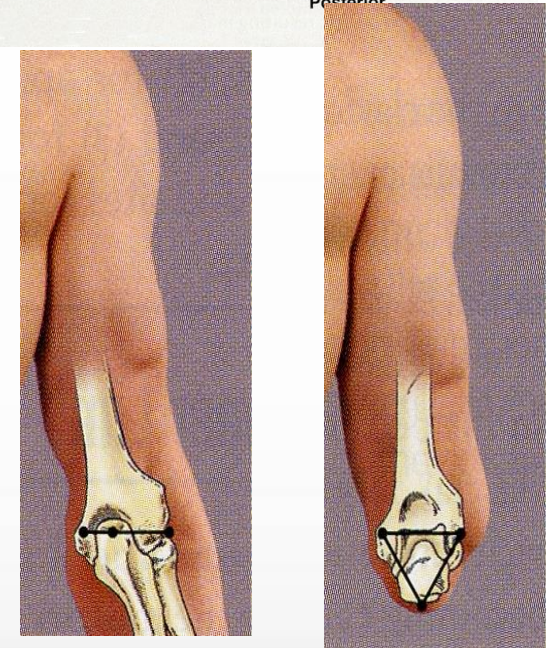
- The **greater tubercle of humerus** can be felt by deep palpation through the deltoid muscle, inferior to the acromion when the arm is by the side.
- In this position, the greater tubercle is the most lateral bony point of the shoulder.

- The **shaft of the humerus** may be felt in different areas deep to muscles surrounding it.
- The **medial and lateral epicondyles of the humerus** are palpated on the medial & lateral sides of the elbow.

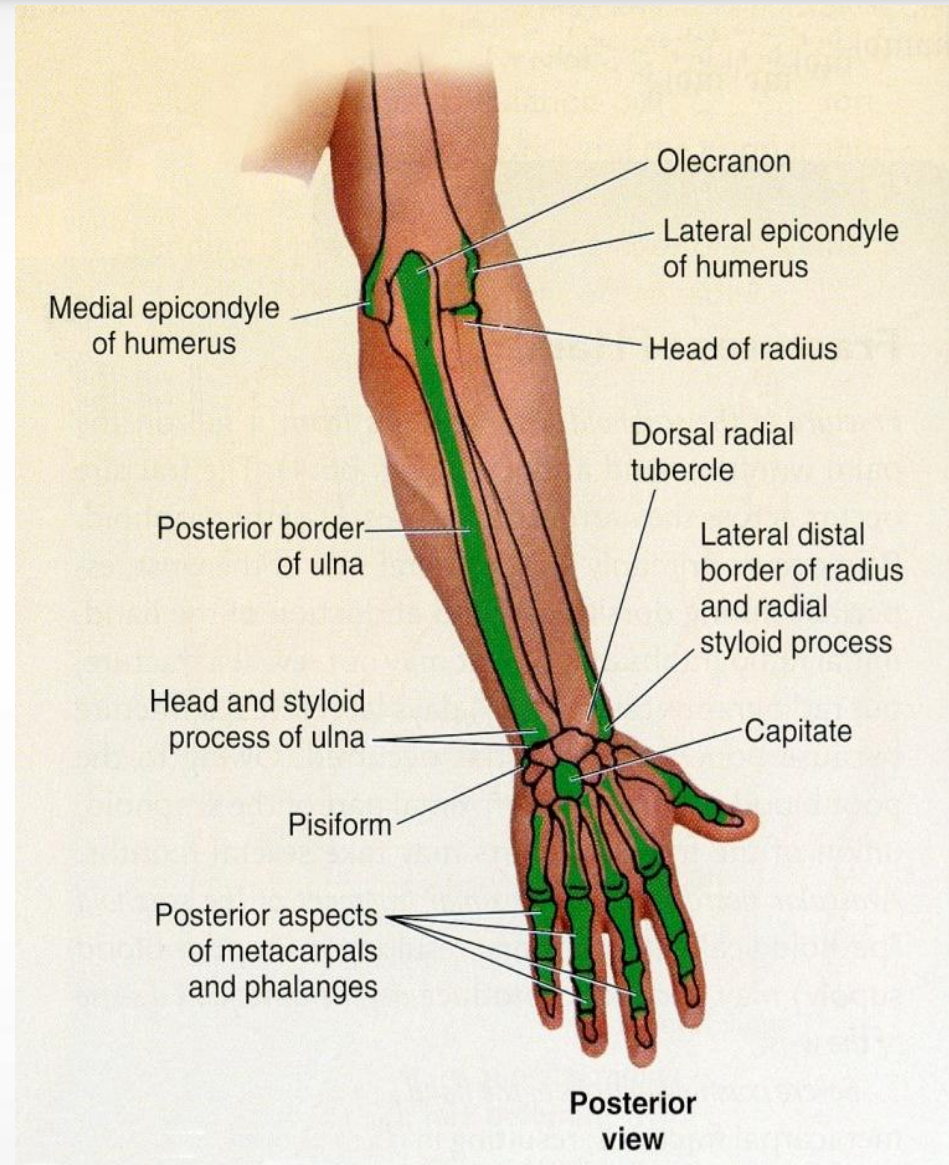
- The **head of ulna** forms a rounded subcutaneous prominence that can be easily seen and palpated on the medial side of dorsal aspect of the wrist.
- The pointed subcutaneous **ulnar styloid process** may be felt slightly distal to the head when the hand is supinated.
- The **olecranon** and **posterior border of the ulna lie subcutaneously and** can be palpated easily.

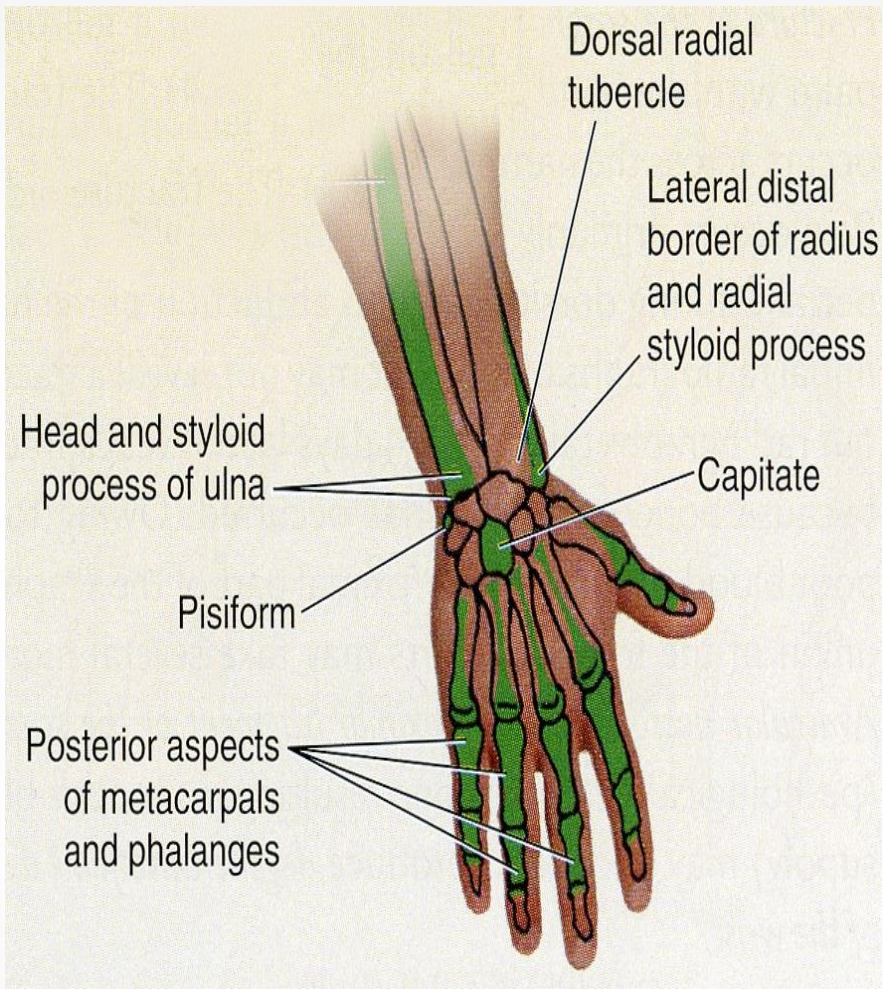


- **When the elbow joint is extended**, the tip of the olecranon process, the medial and the lateral epicondyles lie in a **straight line**.
- **When the elbow is flexed**, the olecranon forms the apex of an equilateral **triangle**, where the epicondyles form the angles.
- Fractures of any of these structures will disturb this arrangement.



- The **head of radius** can be palpated and felt to rotate in the depression on the posterolateral aspect of the extended elbow, just distal to the lateral epicondyle of the humerus with supination and pronation.
- The **radial styloid process** can be palpated on the lateral side of the wrist in the anatomical snuff box.
- It is approximately 1 cm distal to that of the ulna.

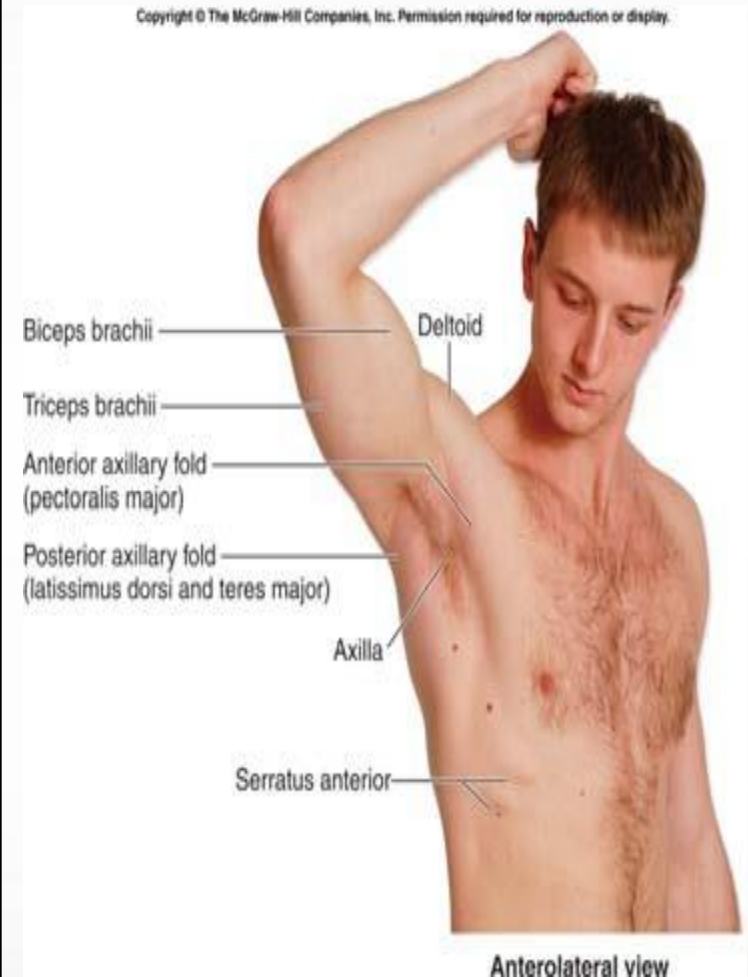

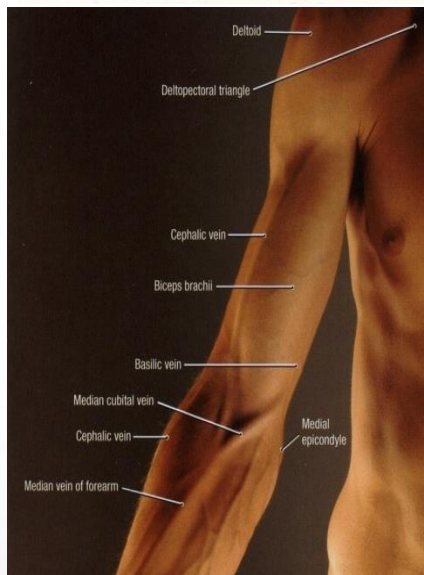
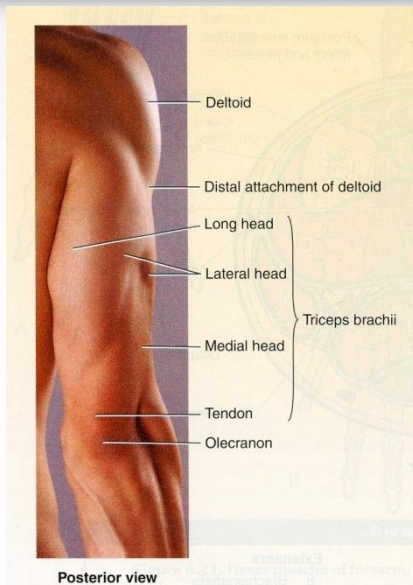


- The **metacarpals**, although they overlapped by the long extensor tendons of the fingers, they can be palpated on the dorsum of the hand.
- The **heads of the metacarpals** form the knuckles of the hand.
- Notice that the 3rd metacarpal head is the most prominent.

- The dorsal aspects of the **phalanges** can be easily palpated.
- The knuckles of the fingers are formed by the **heads of the proximal and middle phalanges.**

- **Axillary Folds**
- **The anterior axillary folds** is formed by the lower margin of the pectoralis major, and can be palpated by the finger.
- This can be made by asking the patient to press the hand against the ipsilateral hip.
- The posterior axillary fold is formed by the tendon of latissimus dorsi and teres major muscles.
- **Axilla**
- When the arm by the side, the inferior part of the head of the humerus can be easily palpated through the floor of the axilla.
- **Pulsations** of the **axillary artery** can be felt high up in the axilla, and around the artery the cords of the brachial plexus.
- The medial wall of the axilla is formed by the upper ribs covered by the serratus anterior.
- The lateral wall is formed by the coracobrachialis and biceps brachii and the bicipital groove.





- The borders of the **deltoid** are visible when the arm is abducted against resistance.
- The **distal attachment of the deltoid** can be palpated on the lateral surface of the humerus.

- Biceps brachii & triceps brachii form bulge on the anterior and posterior surfaces of the arm.
- The **biceps tendon** can be palpated in the cubital fossa, immediately lateral to the midline.
- The triceps tendon can be palpated where it is attached to the olecranon process.

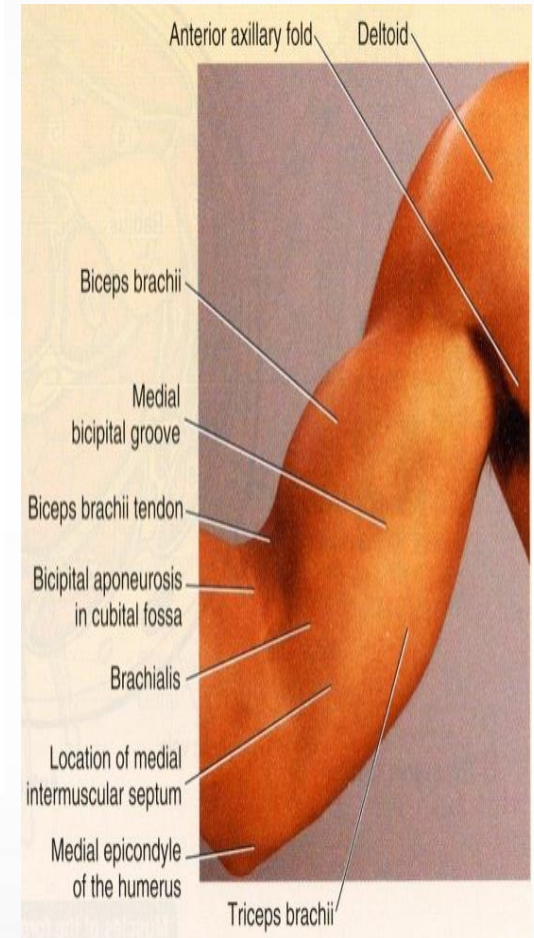
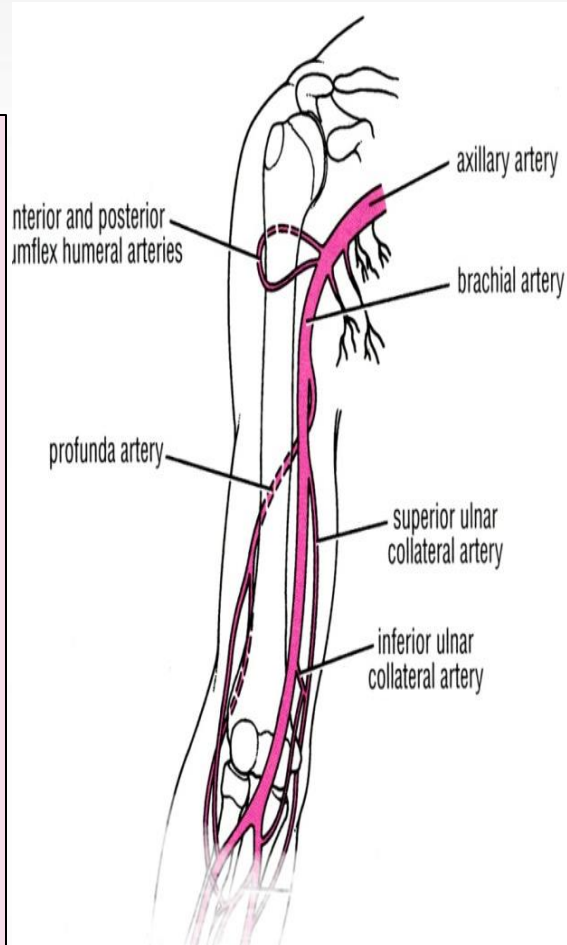
- **There are 2 grooves: Medial and lateral grooves** separate the bulges formed by the biceps and triceps.
- The **cephalic vein** ascends superiorly in the lateral groove and
- The **basilic vein** ascends in the medial groove.

The **brachial artery** can be felt pulsating deep to the medial border of the biceps.

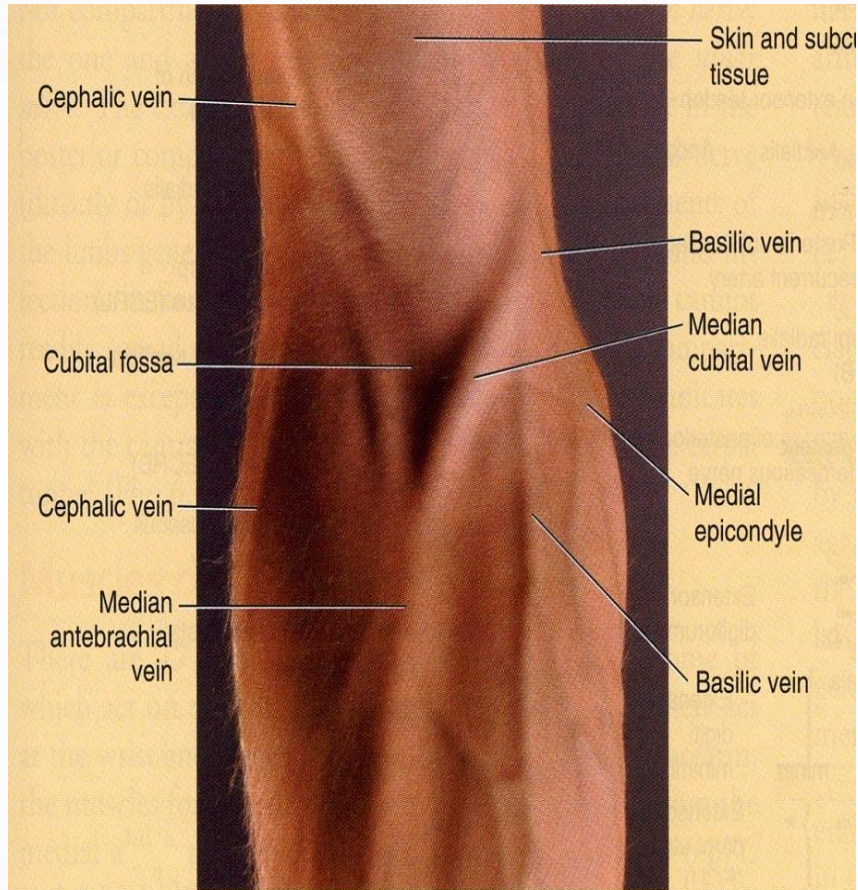
To stop bleeding by pressure on the artery in the upper half of the arm it is pushed laterally against the humerus.

In the lower half it is pushed posteriorly.

In the cubital fossa, it lies beneath the bicipital aponeurosis.



CUBITAL FOSSA



In the cubital fossa, try to locate:

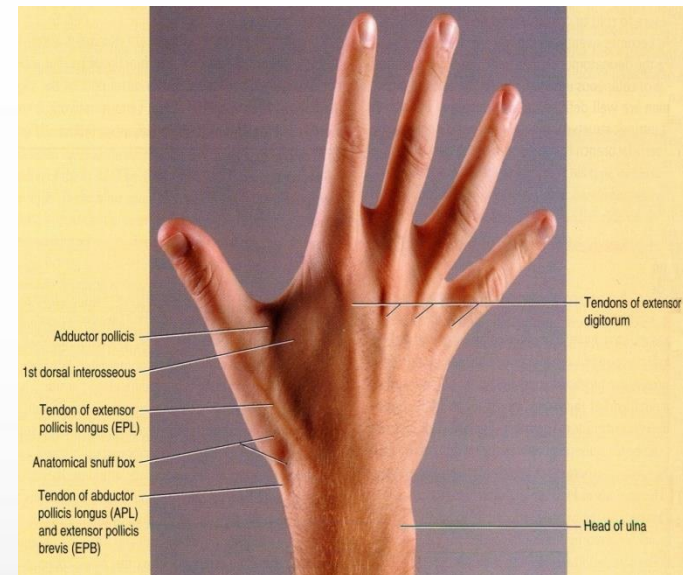
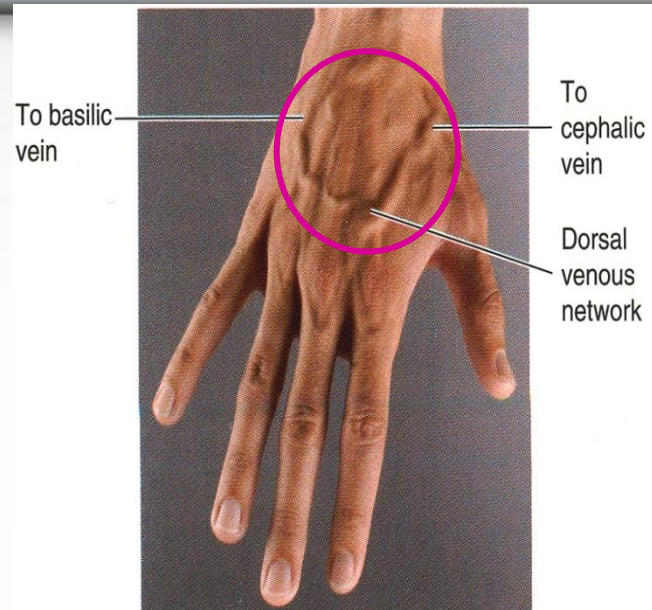
- **Cephalic vein**
- **Basilic vein** and
- **Median cubital vein** are clearly visible.
- The median cubital vein connects the cephalic and the basilic veins .
- **It crosses over the bicipital aponeurosis.**
- It is the vein of choice for IV line, **WHY?**

DORSUM OF THE HAND

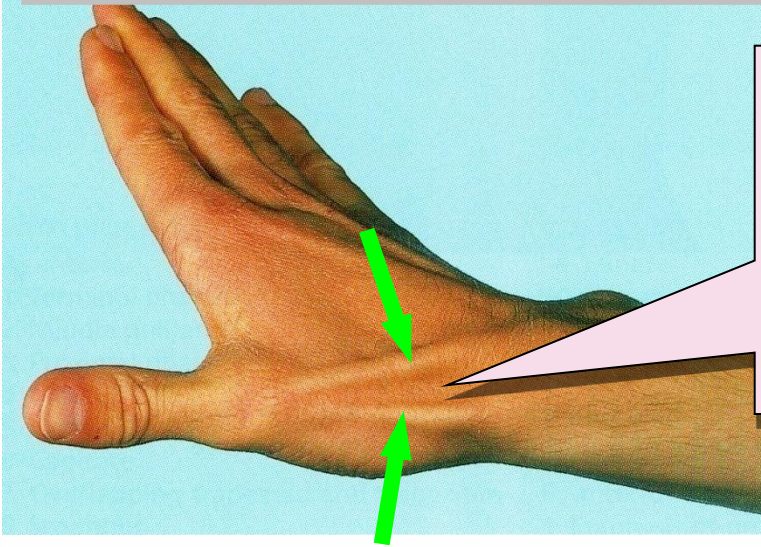
The dorsal venous network:

The network of superficial veins can be seen on the dorsum of the hand. The network drains upward into the cephalic vein laterally, and the basilic vein medially.

The tendons of extensor digitorum, extensor indicis, and extensor digiti minimi can be seen and felt as you extend your fingers.



ANATOMICAL SNUFF BOX

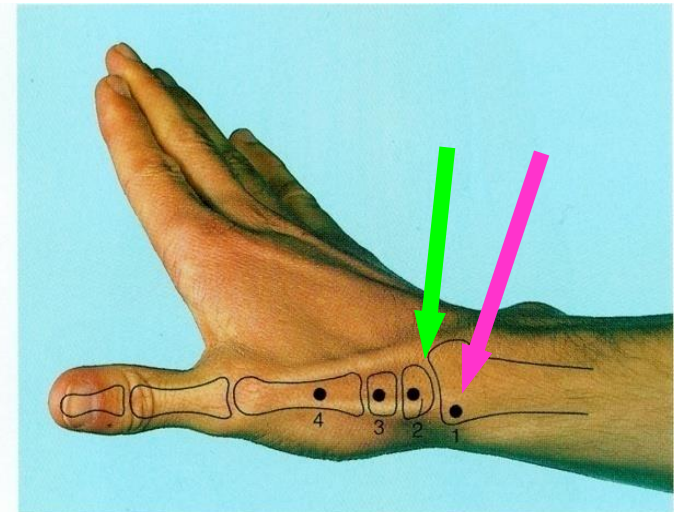


It is a depression on the lateral aspect of the wrist joint which is accentuated when you extends your thumb.

- In its proximal part the **radial styloid process** is palpable.
- The **scaphoid bone** is also palpable in the distal part of the anatomical snuff box.

Boundaries

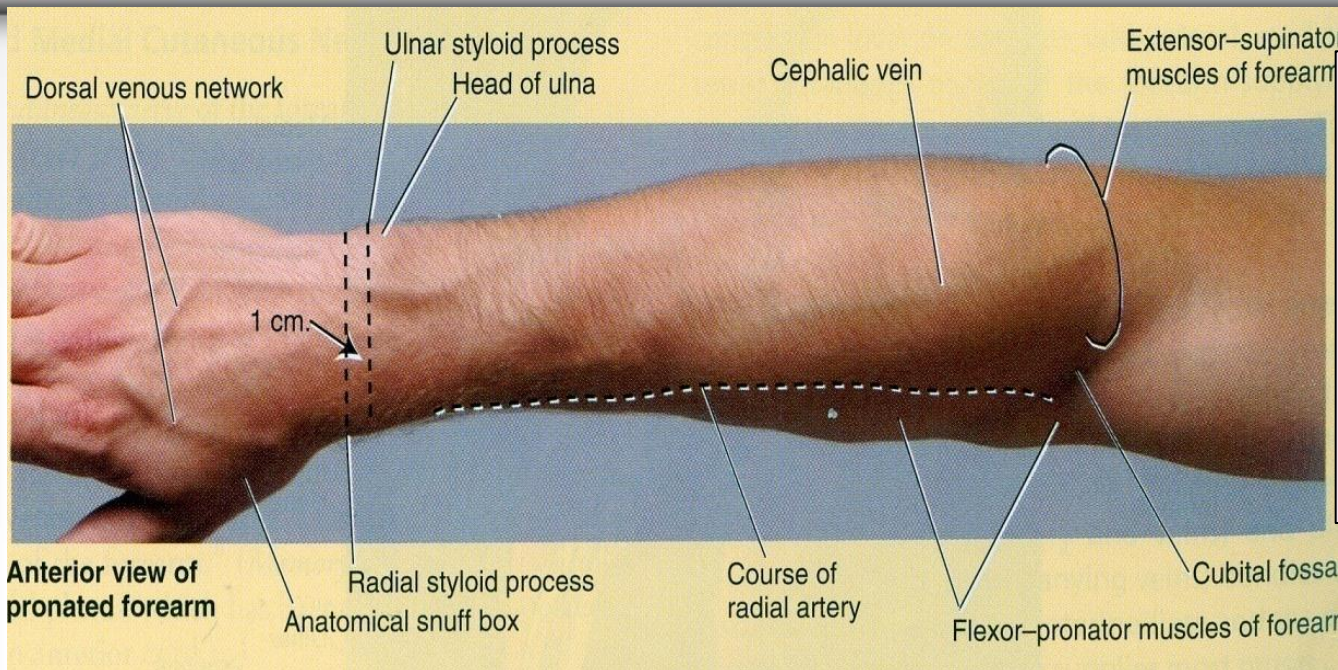
- The snuff box is bounded :
- **Laterally** by 2 tendons:
 - Abductor pollicis longus
 - Extensor pollicis brevis
- **Medially** by extensor pollicis longus



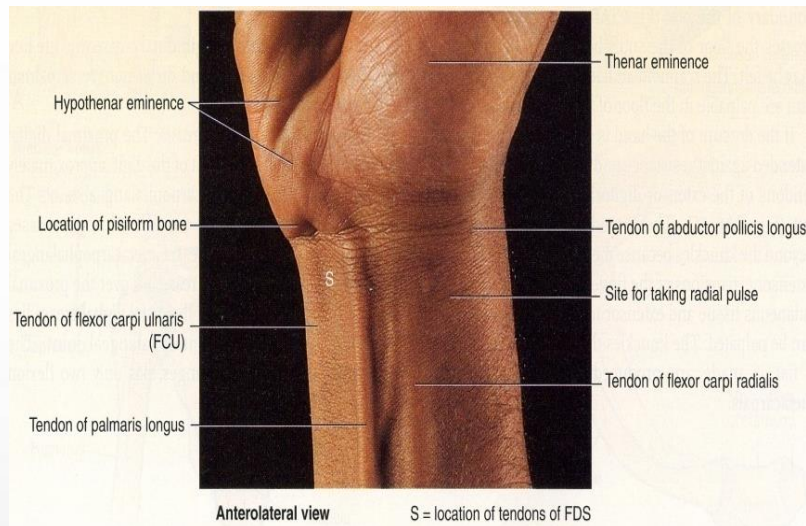
Anatomical snuff box: bones

1 Radial styloid
2 Scaphoid

3 Trapezium
4 First metacarpal

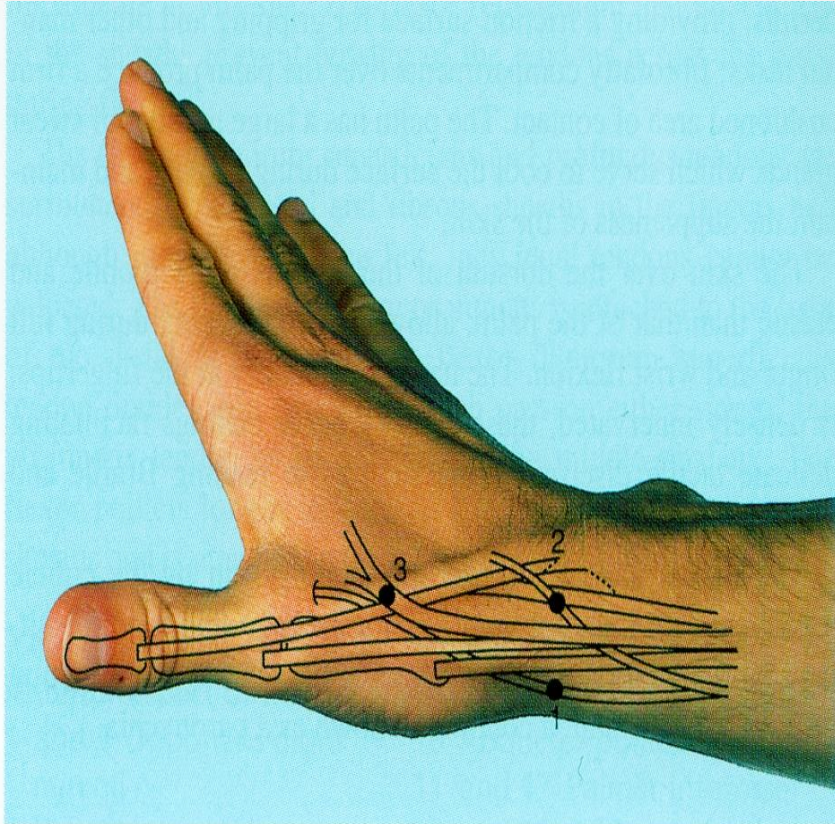


The Radial artery can be drawn by a line extends from the midpoint of the cubital fossa to the base of the styloid process of radius.



Radial Artery pulsation:

Universally, its pulsations can easily be felt anterior to the distal third of radius. Here it lies just beneath the skin and fascia lateral to the tendon of **flexor carpi radialis muscle**



Anatomical snuff box: radial artery and nerve, and cephalic vein

1 Radial artery
2 Radial nerve

3 Cephalic vein

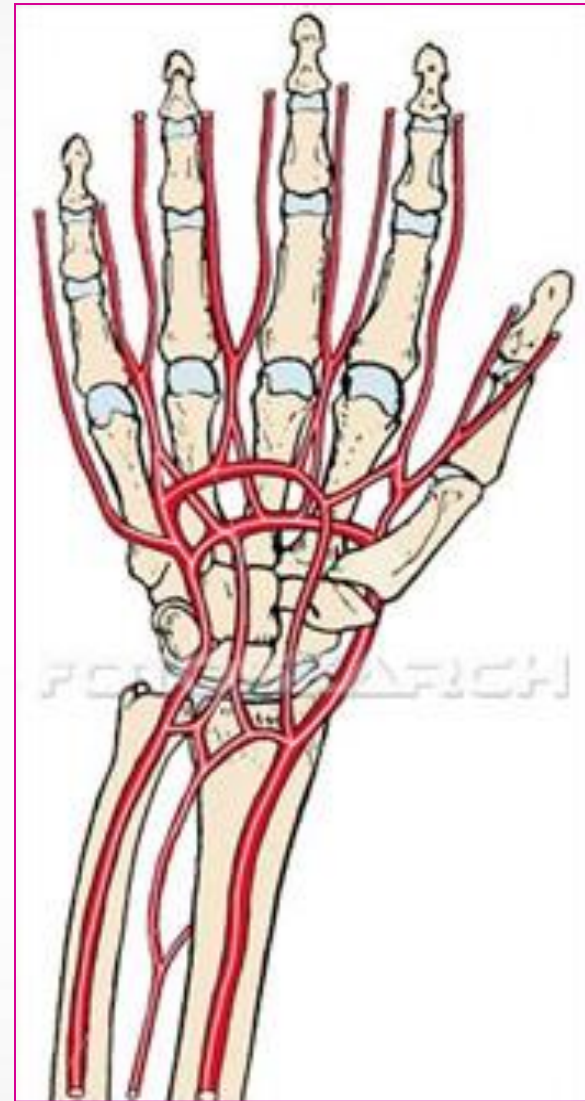
- Also, the **radial artery** pulsation can be felt against the floor of the snuff box.
- More superficially, the anatomical snuff box is crossed by
- The **cephalic vein**.
- The **radial nerve**.

Superficial Palmar Arterial Arch.

The superficial palmar arterial arch is located in the central part of the palm and lies on a line drawn across the palm at the level of the **distal border** of the fully ex-tended thumb.

Deep Palmar Arterial Arch.

The deep palmar arterial arch is also located in the central part of the palm (**proximal** to the superficial one), lies on a line drawn across the palm at the level of the **proximal border** of the fully extended thumb.



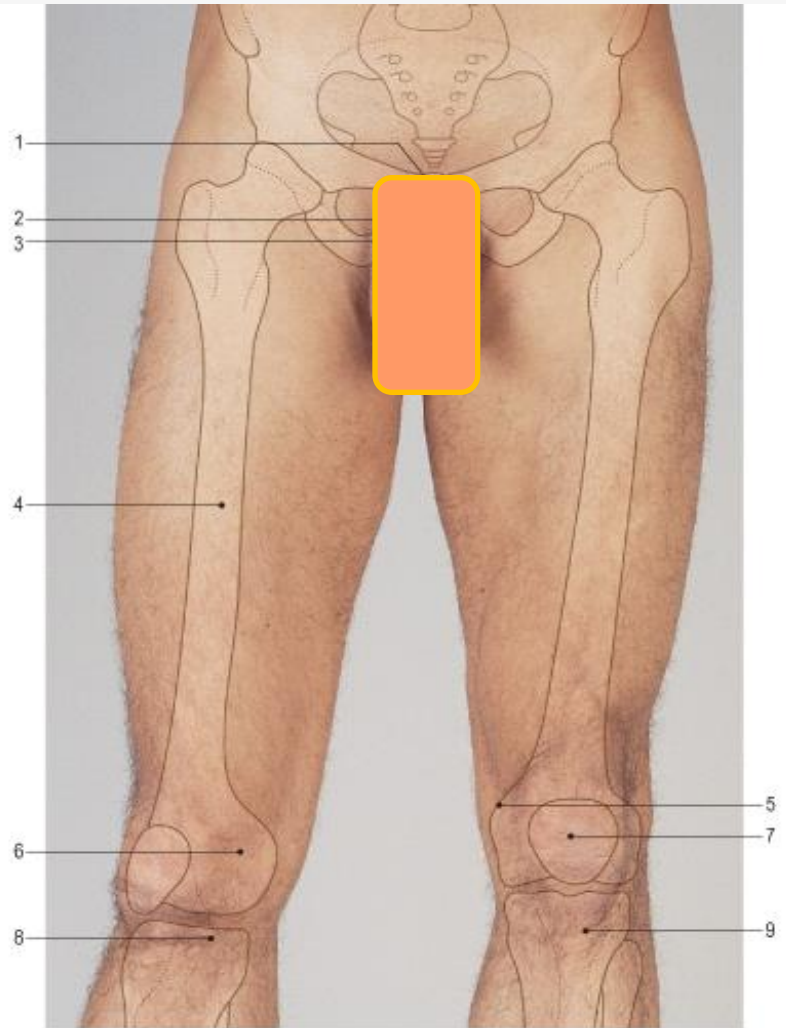
All of the following structures are palpable in the inguinal region:

Symphysis pubis

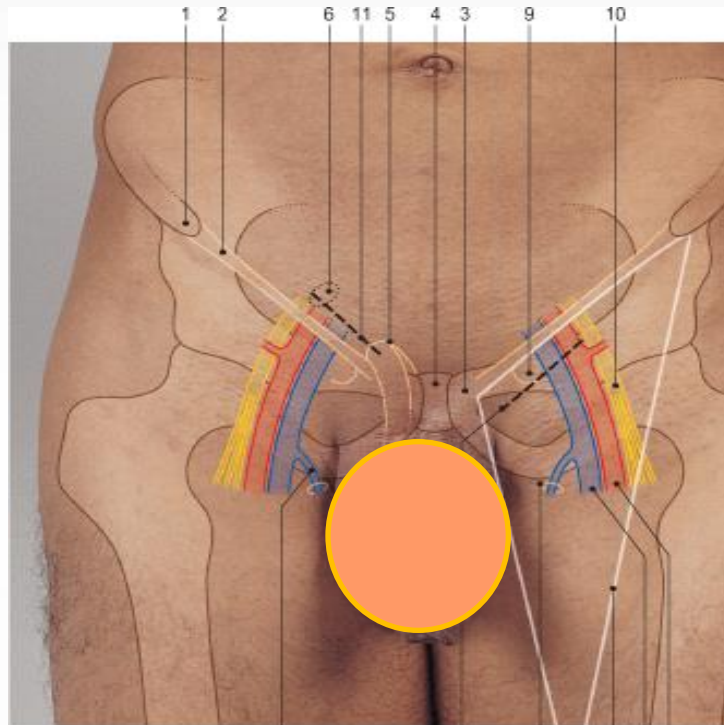
Body of pubis

Pubic tubercle

ASIS



1. Symphysis pubis. 2. Body of pubis. 3. Inferior pubic ramus. 4. Femur. 5. Adductor tubercle. 6. Medial femoral condyle. 7. Patella. 8. Medial tibial plateau. 9. Tibial tuberosity



1. Anterior superior iliac spine. 2. Inguinal ligament. 3. Pubic tubercle.
4. Symphysis pubis. 5. Superficial inguinal ring. 6. Deep inguinal ring.
7. Femoral artery. 8. Femoral vein. 9. Femoral canal. 10. Femoral nerve.
11. Inguinal hernia incision. 12. Femoral hernia incision. 13. Saphenous opening.
14. Long saphenous vein. 15. Femoral triangle.

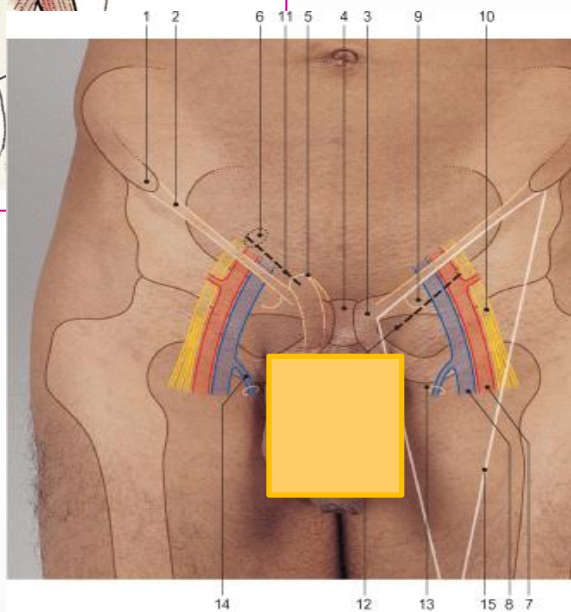
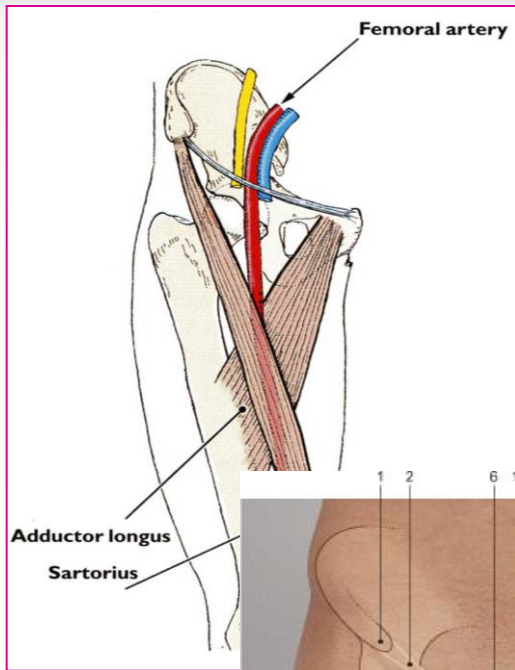
The inguinal ligament extends between:

The pubic tubercle and
The ASIS.

In the **mid-inguinal point** you can feel the pulsations of the **femoral artery**.

The femoral vein lies on the medial side of the artery.

While the femoral nerve lies lateral to the artery.



1. Anterior superior iliac spine. 2. Inguinal ligament. 3. Pubic tubercle.
4. Symphysis pubis. 5. Superficial inguinal ring. 6. Deep inguinal ring.
7. Femoral artery. 8. Femoral vein. 9. Femoral canal. 10. Femoral nerve.
11. Inguinal hernia incision. 12. Femoral hernia incision. 13. Saphenous opening.
14. Long saphenous vein. 15. Femoral triangle.

Midinguinal point:

It is a point on the inguinal ligament midway between the symphysis pubis and the ASIS.

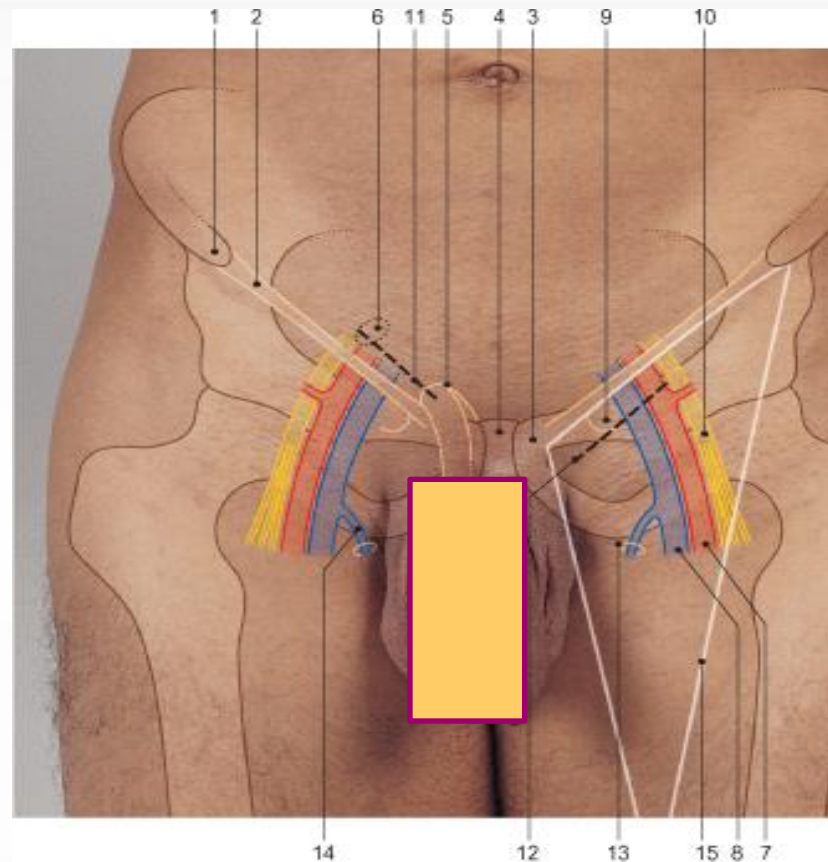
The **femoral artery** is an important site for vascular access as a large number of arteriographic procedures are undertaken through its percutaneous puncture, (coronary angiography).

Femoral Triangle

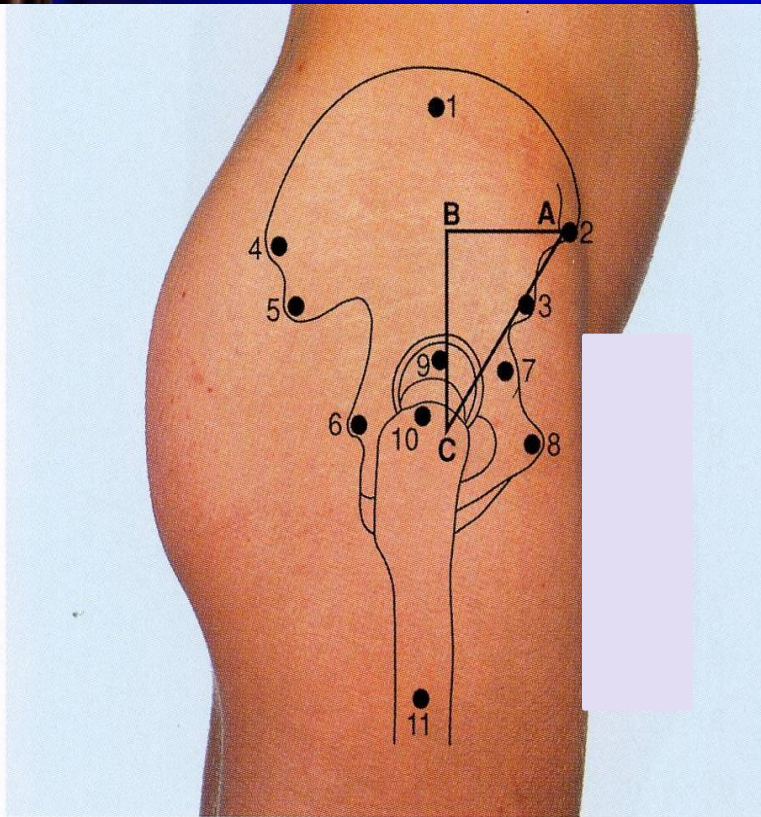
The **femoral triangle** can be seen as a depression below the fold of the groin in the upper part of the thigh.

In a thin, muscular subject, the boundaries of the triangle can be identified when the thigh is flexed, abducted, and laterally rotated.

The base of the triangle is formed by the inguinal ligament, the lateral border by the sartorius and the medial border by the adductor longus.



1. Anterior superior iliac spine.
2. Inguinal ligament.
3. Pubic tubercle.
4. Symphysis pubis.
5. Superficial inguinal ring.
6. Deep inguinal ring.
7. Femoral artery.
8. Femoral vein.
9. Femoral canal.
10. Femoral nerve.
11. Inguinal hernia incision.
12. Femoral hernia incision.
13. Saphenous opening.
14. Long saphenous vein.
15. Femoral triangle.



The **iliac crest** is subcutaneous and can be palpated throughout its length, from the ASIS to the PSIS.

The **greater trochanter** of the femur is also subcutaneous and can be palpated on the lateral aspect of the hip joint behind and distal to the ASIS.

8.17

Lateral aspect of the hip joint: bones

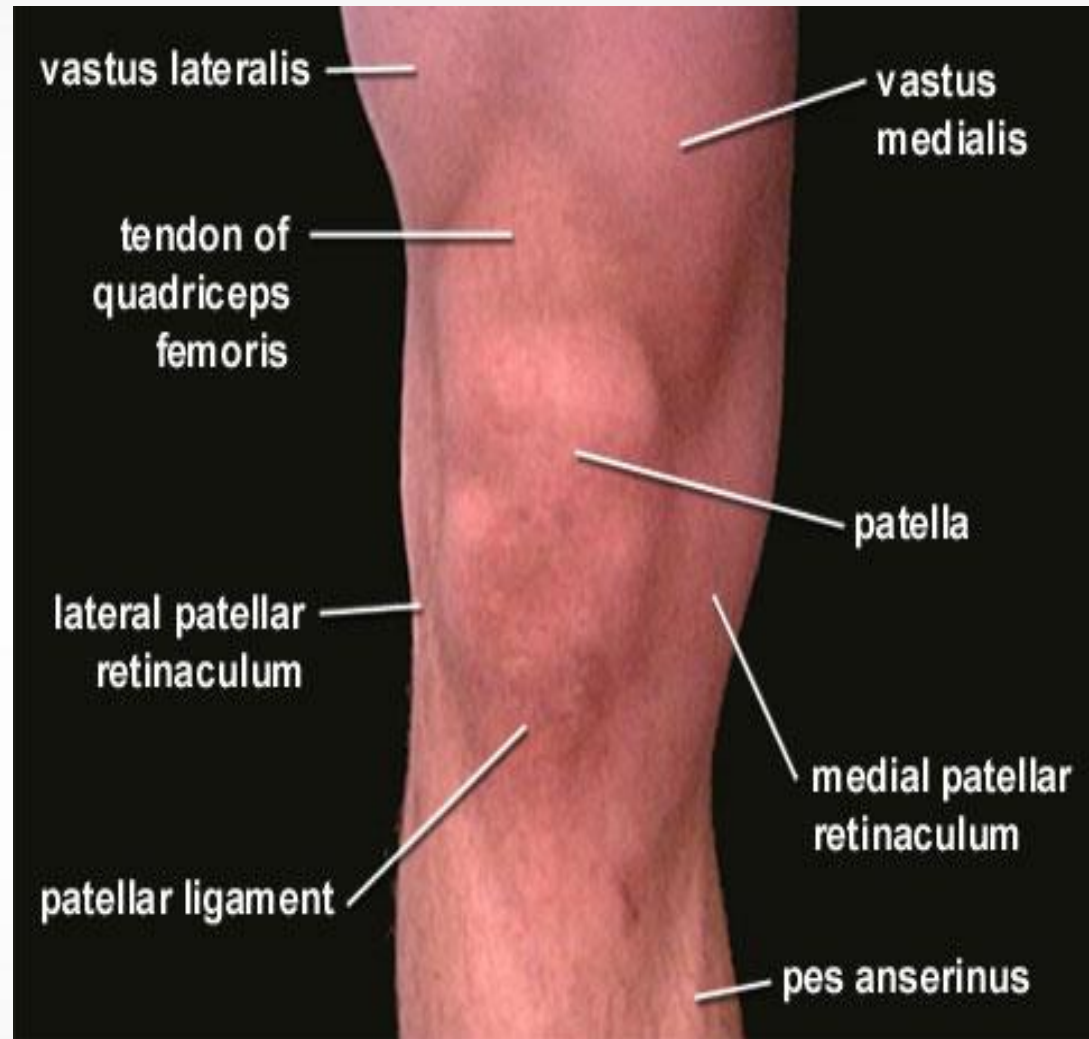- | | |
|----------------------------------|-----------------------|
| 1 Ilium | 6 Ischial spine |
| 2 Anterior superior iliac spine | 7 Iliopubic eminence |
| 3 Anterior inferior iliac spine | 8 Body of pubis |
| 4 Posterior superior iliac spine | 9 Head of femur |
| 5 Posterior inferior iliac spine | 10 Greater trochanter |
| | 11 Shaft of femur |
| ABC, Bryant's triangle | |

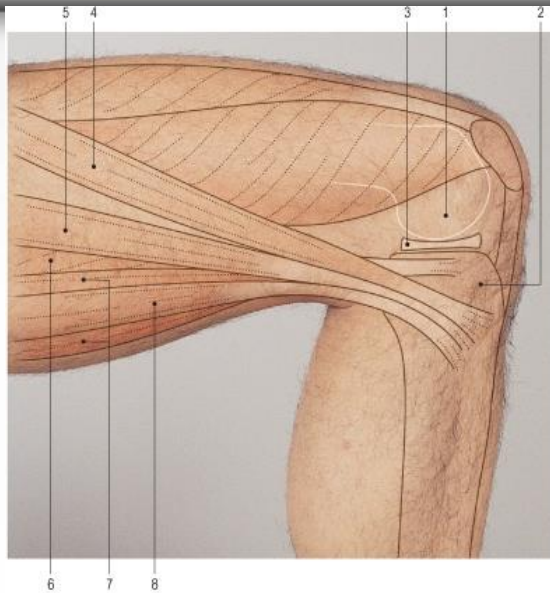
KNEE REGION

In front of the knee joint the **patella** and the **ligamentum patellae** can be easily palpated.

The ligamentum patellae can be traced downward as it is attached to the tibial **tuberosity**.

The **condyles of the femur and tibia** can be recognized on the sides of the knee and the joint line can be identified between them.





1. Medial femoral condyle. 2. Medial tibial condyle. 3. Medial meniscus. 4. Sartorius.
5. Gracilis. 6. Adductor magnus. 7. Semimembranosus. 8. Semitendinosus.

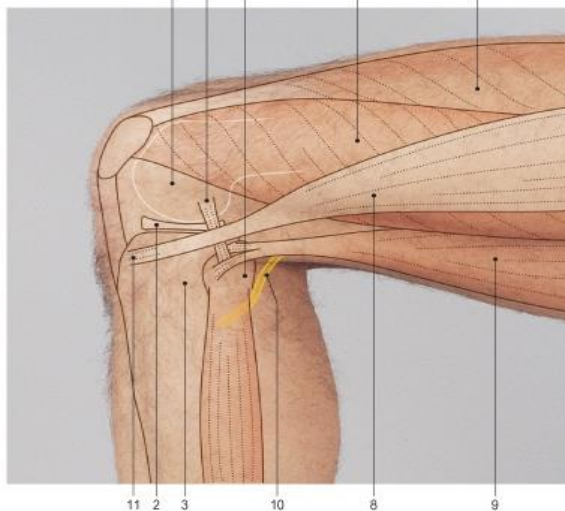
On the medial aspect of the knee Joint try to palpate:

Medial femoral condyle

Medial tibial condyle

The 3 tendons of

1. sartorius.
2. Gracilis
3. Semitendinosus.



1. Lateral femoral condyle. 2. Lateral meniscus. 3. Lateral tibial condyle. 4. Head of fibula.
5. Lateral collateral ligament. 6. Rectus femoris. 7. Vastus lateralis. 8. Iliotibial band.
9. Biceps femoris. 10. Common peroneal nerve. 11. Gerdy's tubercle.

On the lateral aspect of the knee Joint try to palpate:

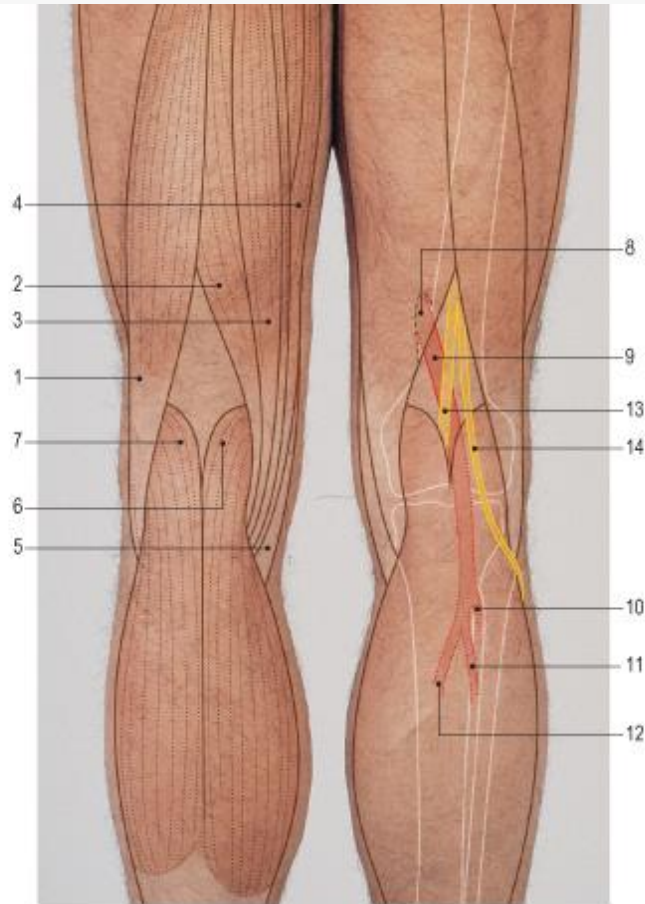
Lateral femoral condyle

Lateral tibial condyle

Head of the fibula

Neck of the fibula

Tendon of biceps femoris.

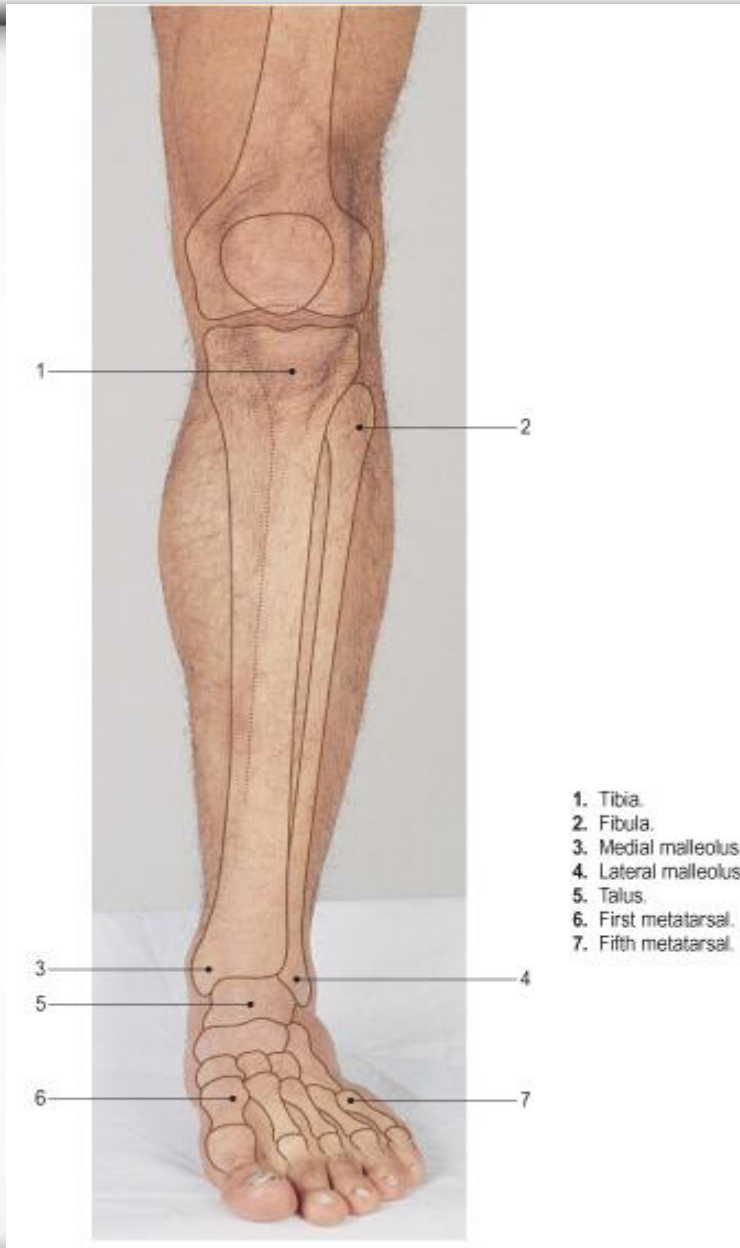


1. Biceps femoris. 2. Semimembranosus. 3. Semitendinosus. 4. Gracilis. 5. Sartorius.
 6. Gastrocnemius, medial head. 7. Gastrocnemius, lateral head. 8. Adductor hiatus.
 9. Popliteal artery. 10. Anterior tibial artery. 11. Peroneal artery. 12. Posterior tibial artery.
 13. Tibial nerve. 14. Common peroneal nerve.

**In the back of the knee and leg
try to palpate:**

The boundaries of the popliteal fossa.

The pulsation of the popliteal artery which is deeply situated in the fossa.



On the anterior aspect of the leg and knee Joint and try to palpate:

The patella.

The tibial tuberosity.

The anterior border of the tibia, (shine).

The medial tibial condyle.

The medial surface of the tibia.

The medial malleolus.

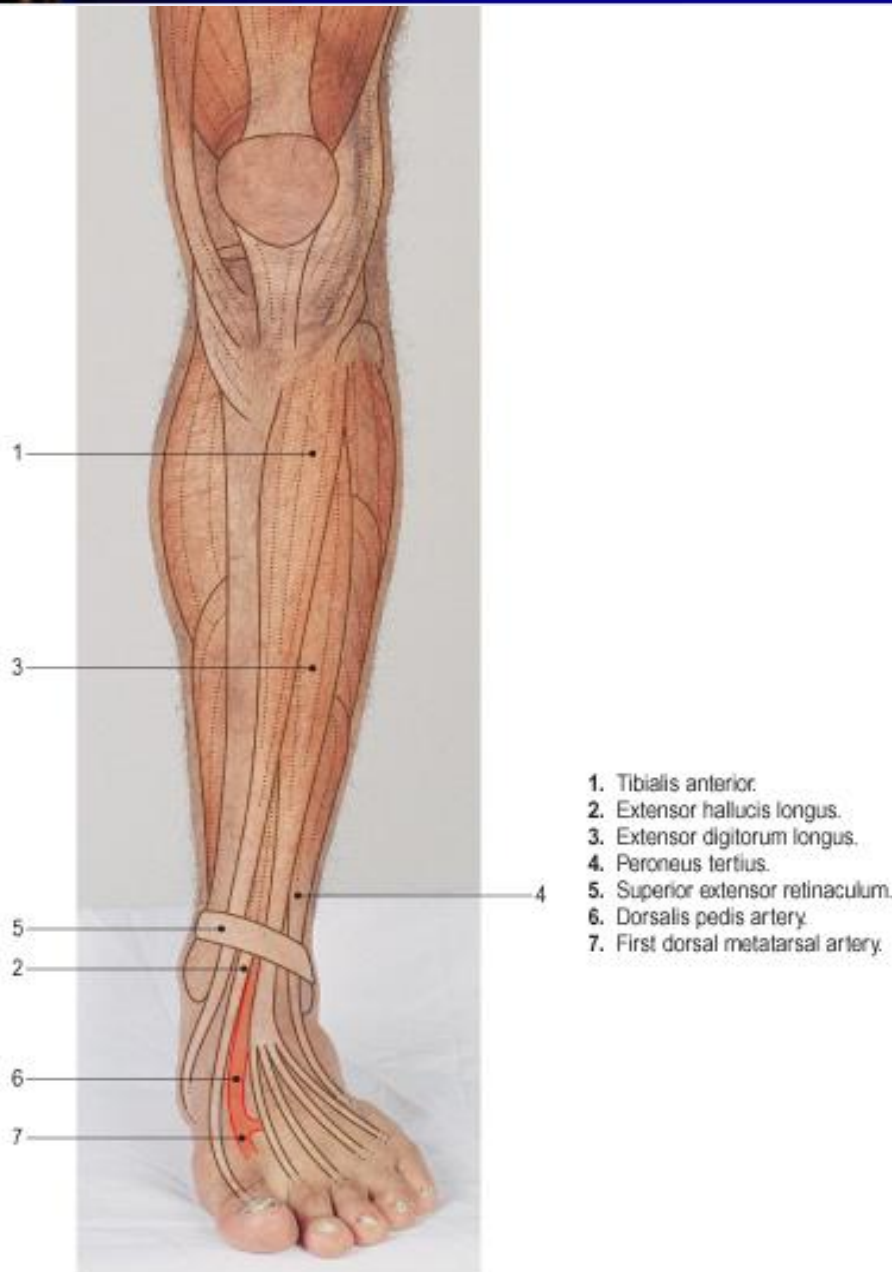
The lateral malleolus.

On the dorsum of the foot try to palpate:

The tuberosity of the 5th metatarsal

The tubercle of navicular.

The metatarsals.



On the dorsum of the foot try to palpate:

The long extensor tendons:

Tibialis anterior

Extensor hallucis longus.

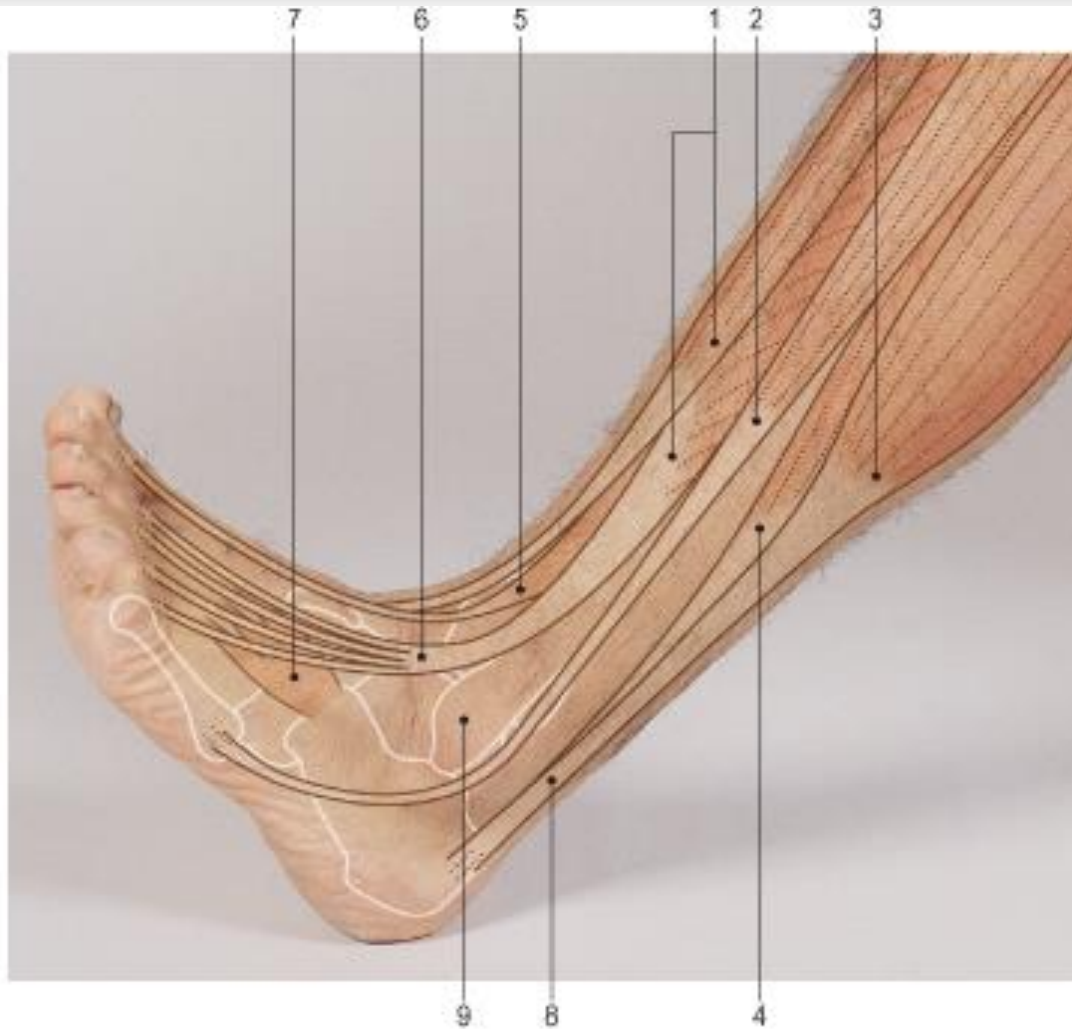Extensor digitorum longus.

Peroneus tertius.

Also, try to feel the pulsation of the

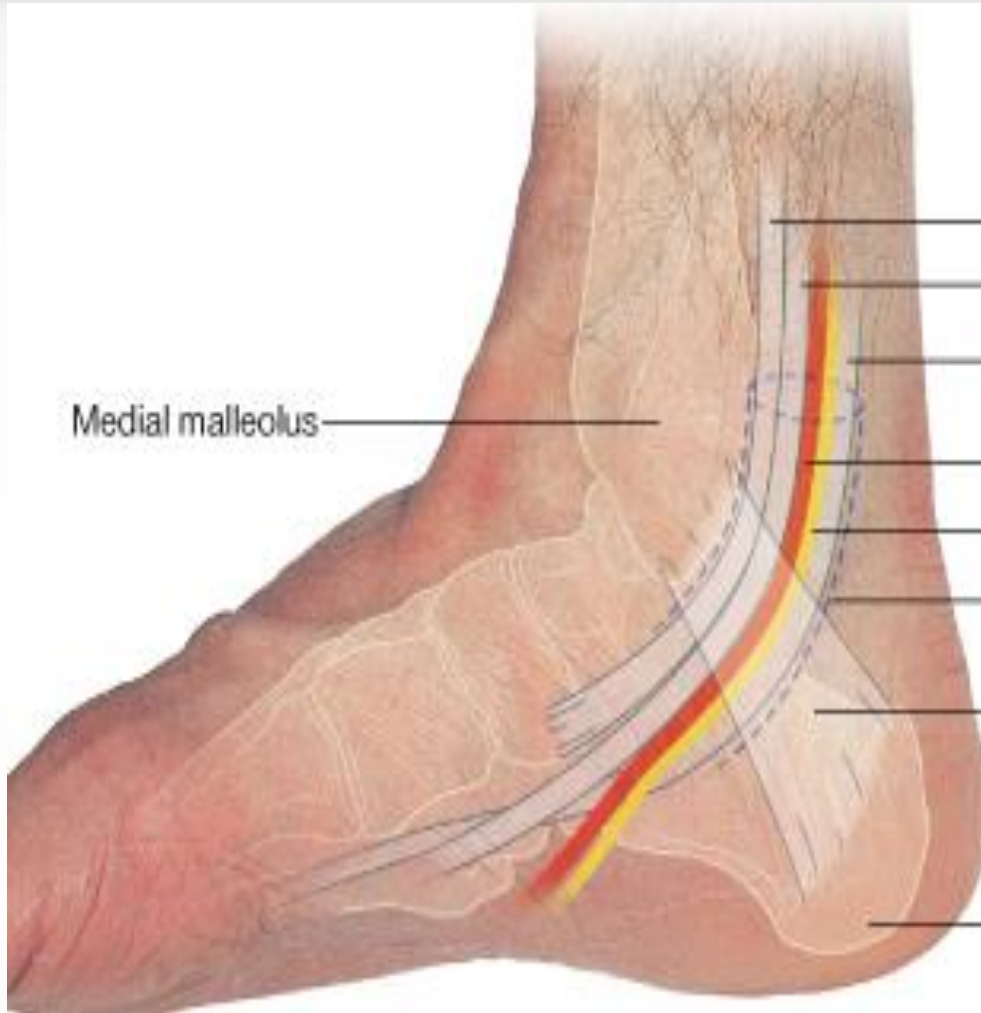dorsalis pedis artery.

Between the tendons of extensor hallucis longus & extensor digitorum longus.



1. Tibialis anterior. 2. Peroneus longus. 3. Gastrocnemius 4. Soleus.
 5. Tendon of extensor hallucis longus. 6. Tendons of extensor digitorum longus.
 7. Extensor digitorum brevis. 8. Calcaneus tendon (Achilles tendon) 9. Lateral malleolus.

On the lateral aspect of the leg try to palpate:
 The tendons of peroneus longus and brevis.
 The tendon Achilles.
 The lateral malleolus.



On the Medial aspect of the ankle try to palpate and feel:
The medial malleolus.
The tendons of tibialis posterior
The tendon of flexor digitorum longus.
The posterior tibial artery
The calcaneus.