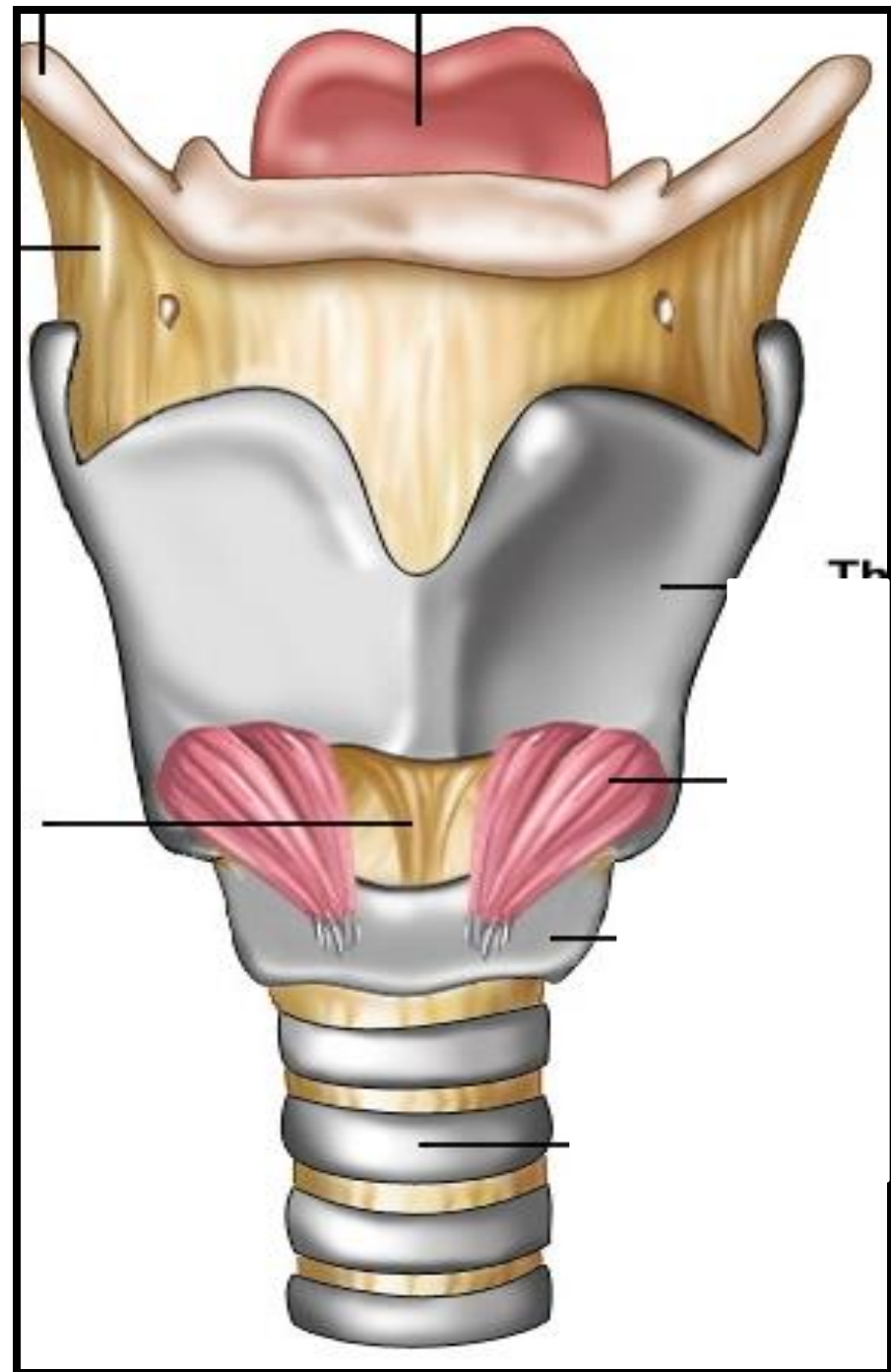


# LARYNX TRACHEA & BRONCHI

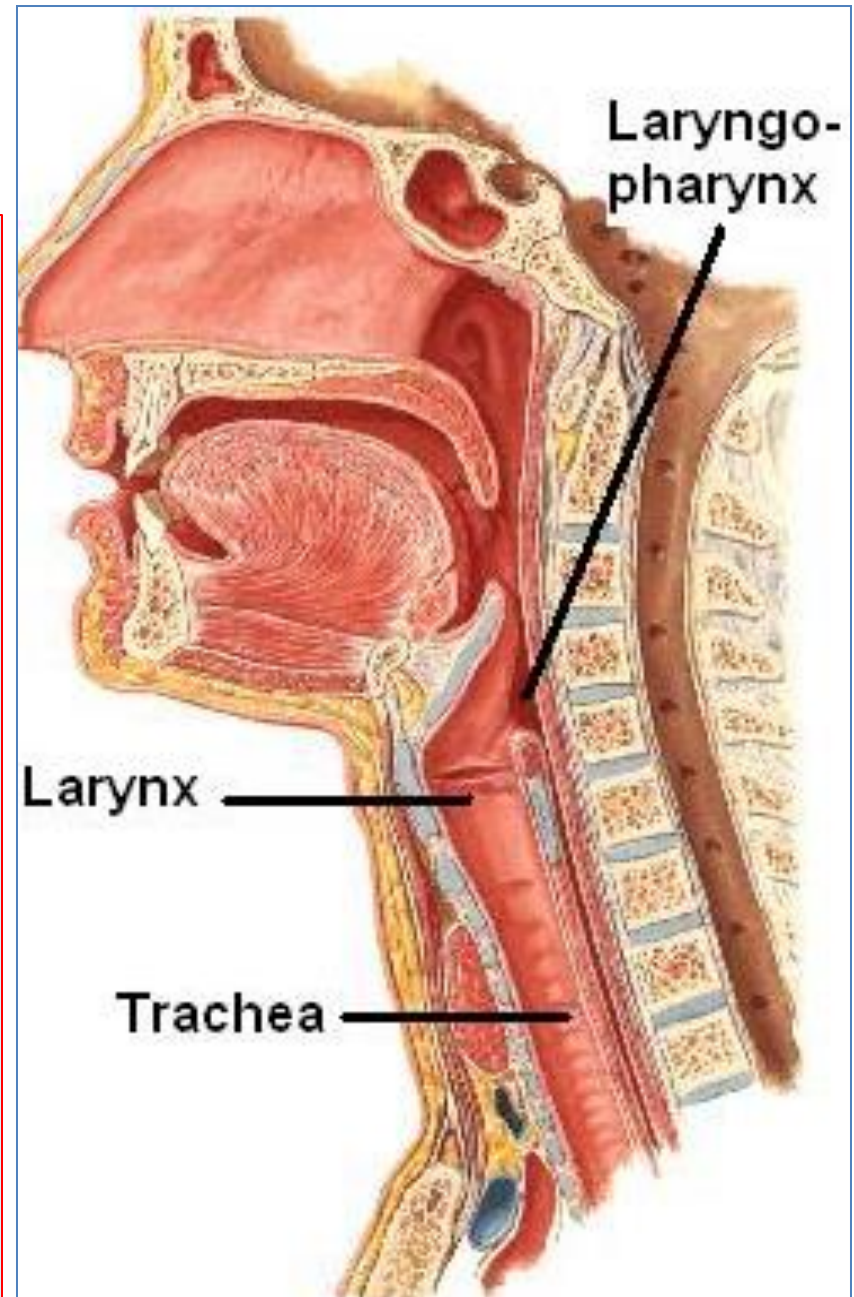


# Objectives

- **By the end of the lecture, you should be able to:**
- Describe the Extent, structure and functions of the larynx.
- Describe the Extent, structure and functions of the trachea.
- Describe the bronchi and branching of the bronchial tree.
- Describe the functions of bronchi and their divisions.

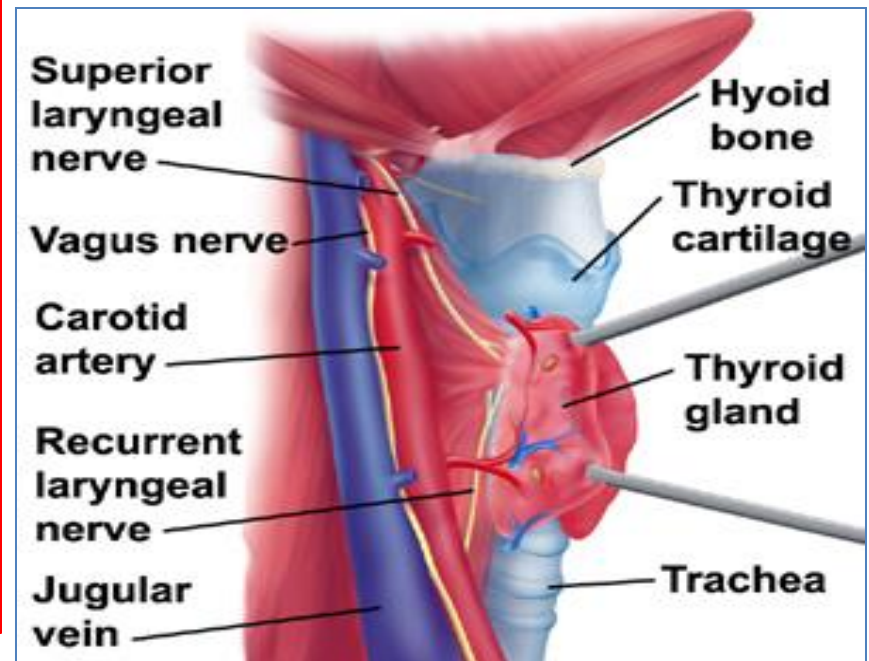
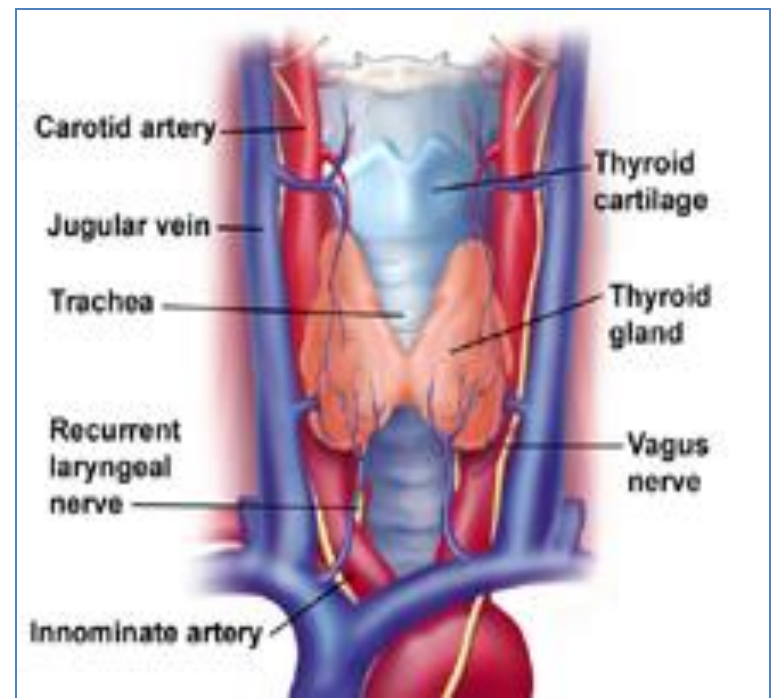
# LARYNX

- The larynx is the part **of the respiratory tract** **which** contains the vocal cords.
- In adult it is **2-inch-long** tube.
- It opens above into the **laryngeal part of the pharynx**.
- Below, it is continuous with the **trachea**.
- The larynx has functions in:
  - **Respiration** (breathing).
  - **Phonation** (voice production).
  - **Deglutition** (swallowing).



# Relations

- The larynx is related to major **critical** structures in the neck.
- **Arteries:**
- **Carotid arteries:** (common, external and internal).
- **Thyroid arteries:** (superior & inferior thyroid arteries).
- **Veins:**
- Jugular veins, (external & internal).
- **Nerves:**
- Laryngeal nerves: (Superior laryngeal & recurrent laryngeal).
- Vagus nerves.



# Structure

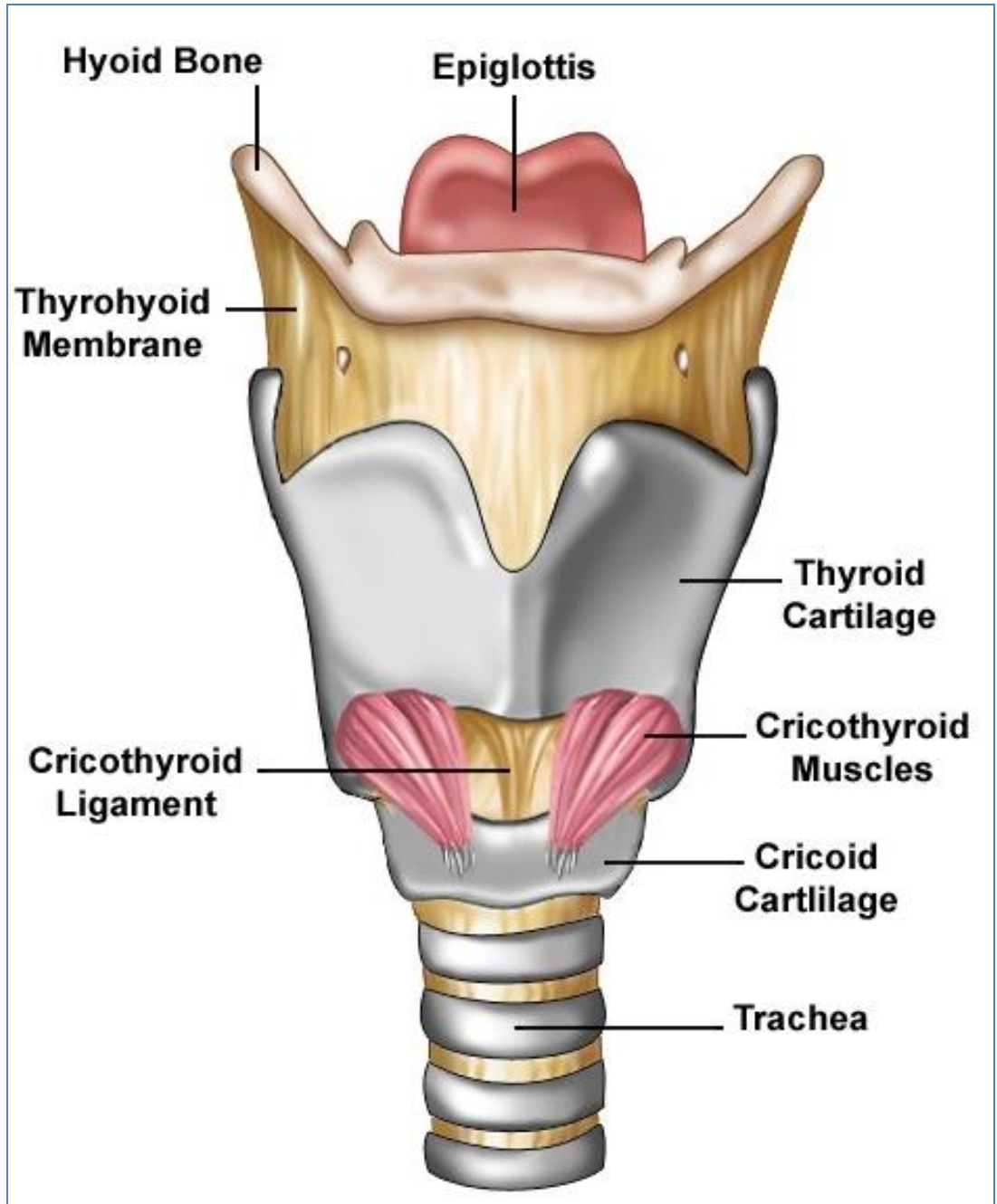
- The larynx consists of four basic components:

1- Cartilaginous skeleton.

2- Membranes and ligaments.

3- Muscles (Intrinsic & extrinsic muscles).

4- Mucosal lining.



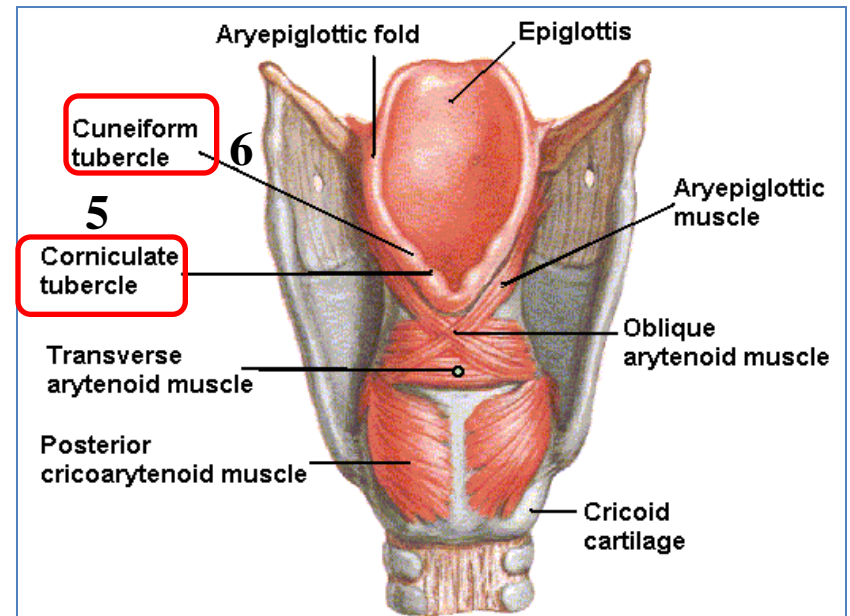
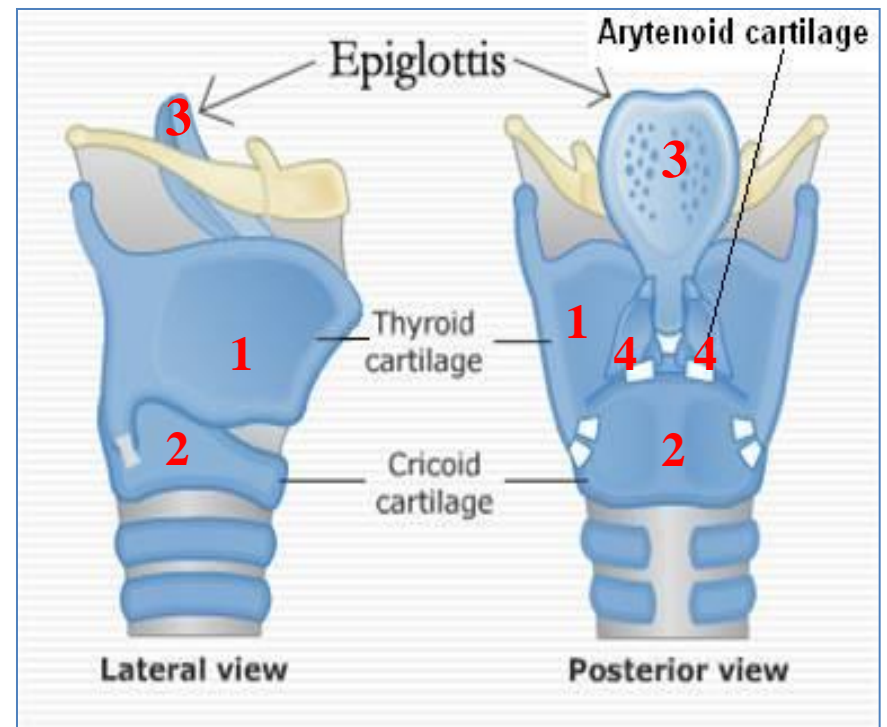
# The Cartilages

- The cartilaginous skeleton is composed of:

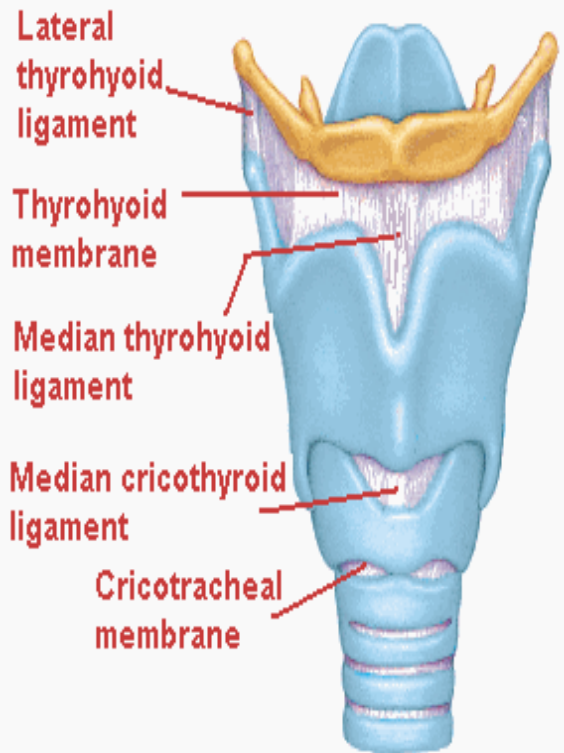
1. Thyroid
  2. Cricoid
  3. Epiglottis
- 3 Single

- 
4. Arytenoid
  5. Corniculate
  6. Cuneiform
- 3 Paired

- All the cartilages, are **hyaline** except the **epiglottis** which is **Elastic** cartilage.
- The cartilages are:
  - Connected by **joints**, & **ligaments**.
  - Lined by **membranes**.
  - Moved by **muscles**.

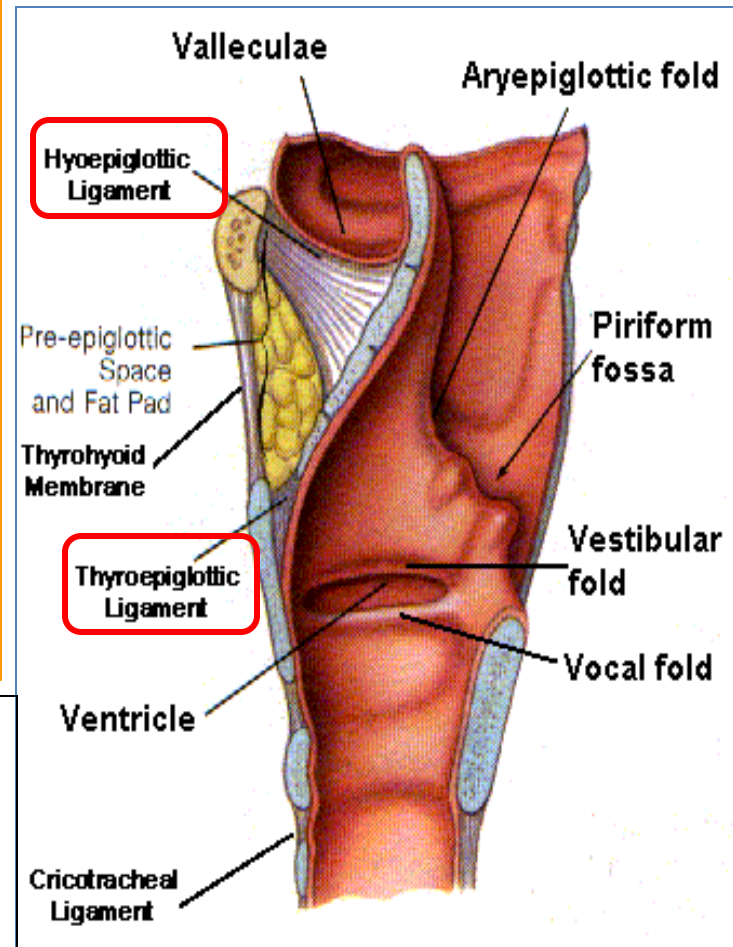


# MEMBRANES & LIGAMENTS

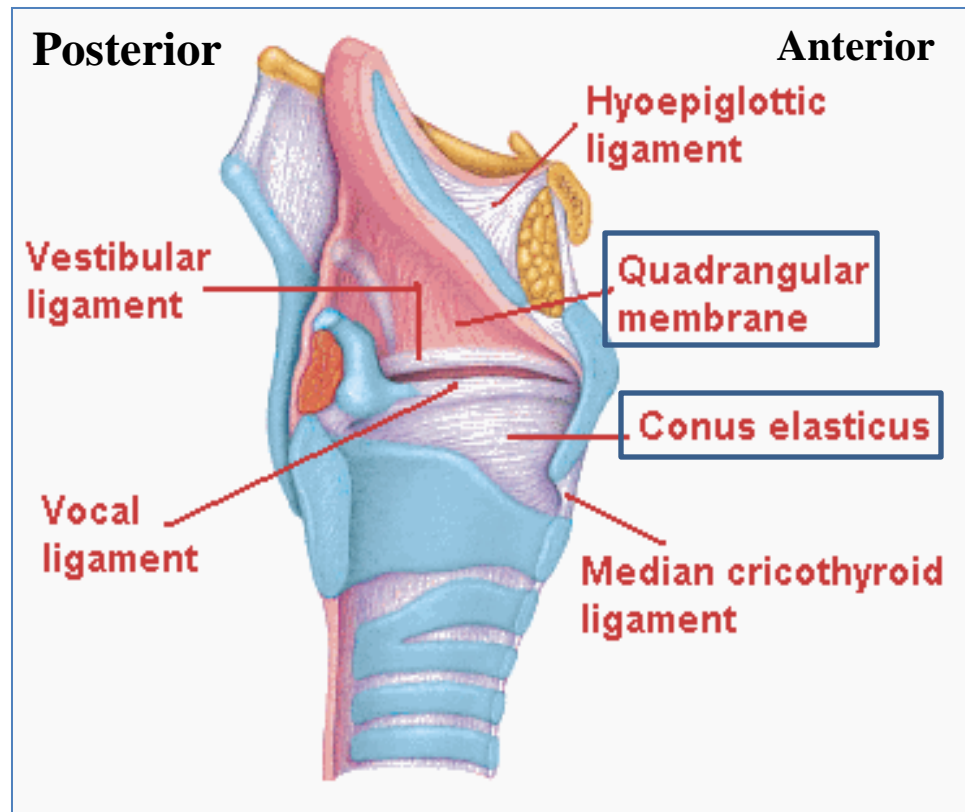


- Thyrohyoid membrane.
- Cricothyroid membrane.
- Cricotracheal membrane.
- Hyoepiglottic ligament.
- Thyroepiglottic ligament

The **thyrohyoid membrane** is thickened in the median plane to form **median thyrohyoid ligament** and on both sides to form **lateral thyrohyoid ligaments**.



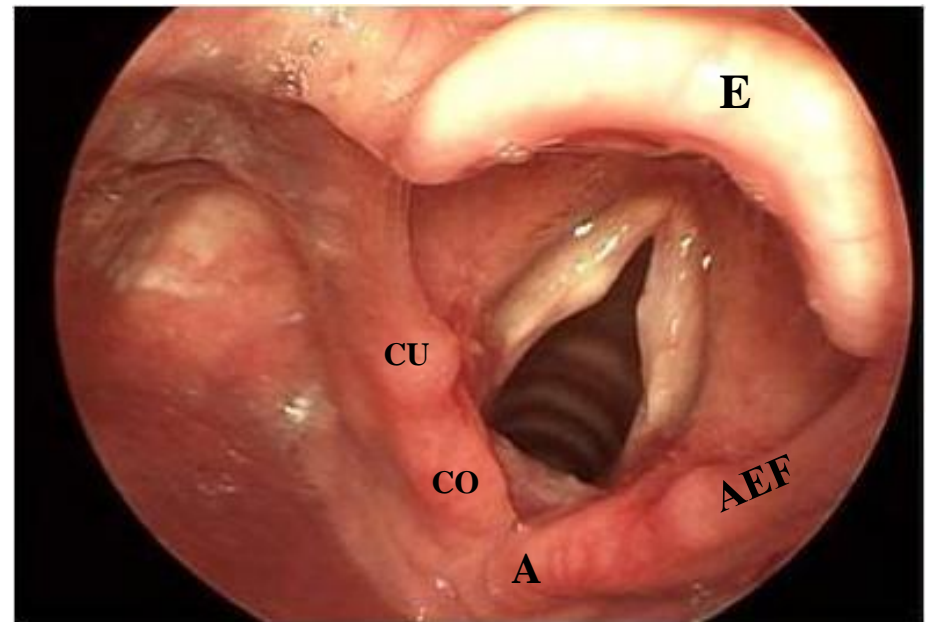
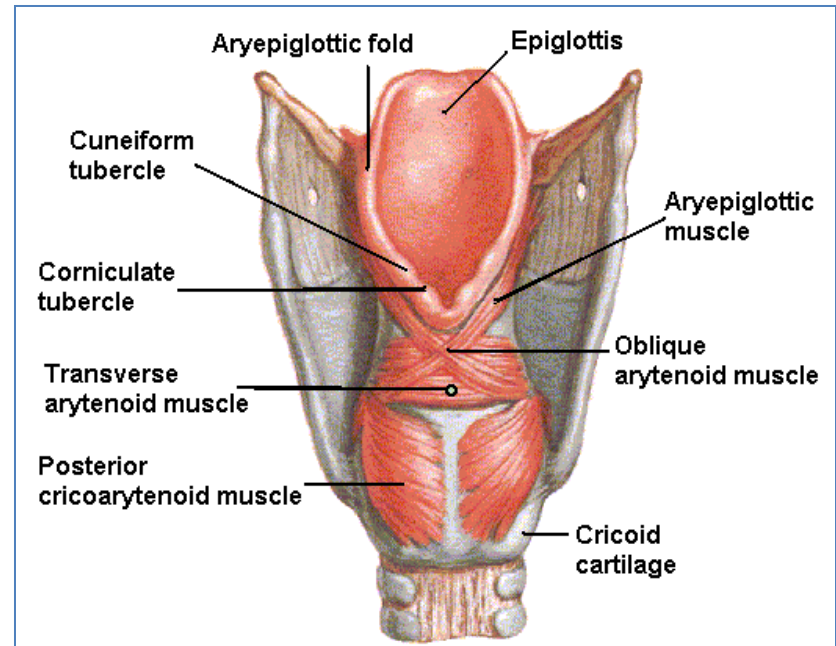
- **Quadrangular membrane:**
  - Or aryepiglottic membrane,
  - It extends between the arytenoid and epiglottis.
  - Its lower free margin forms the **vestibular ligament** which forms the false vocal cord or **vestibular fold**.
- **Cricothyroid membrane (conus elasticus):**
  - Its upper free margin forms **Vocal ligament**.
  - Its lower margin is attached to the upper border of cricoid cartilage.





# Laryngeal Inlet

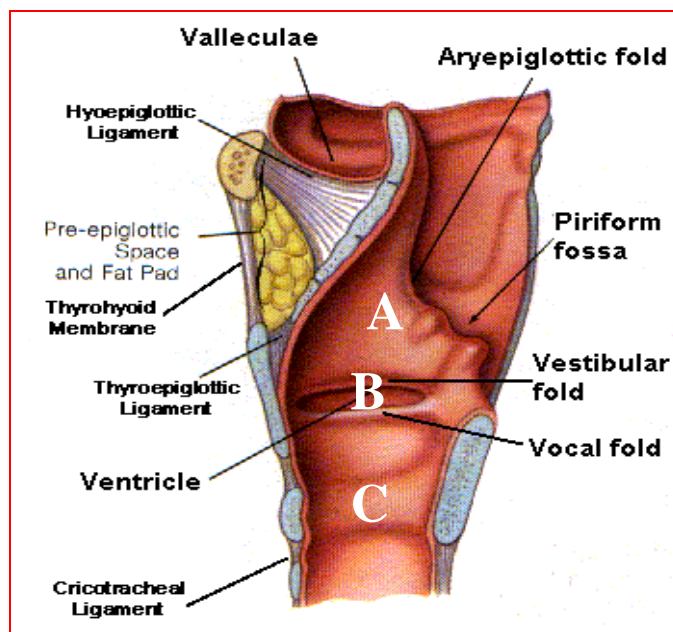
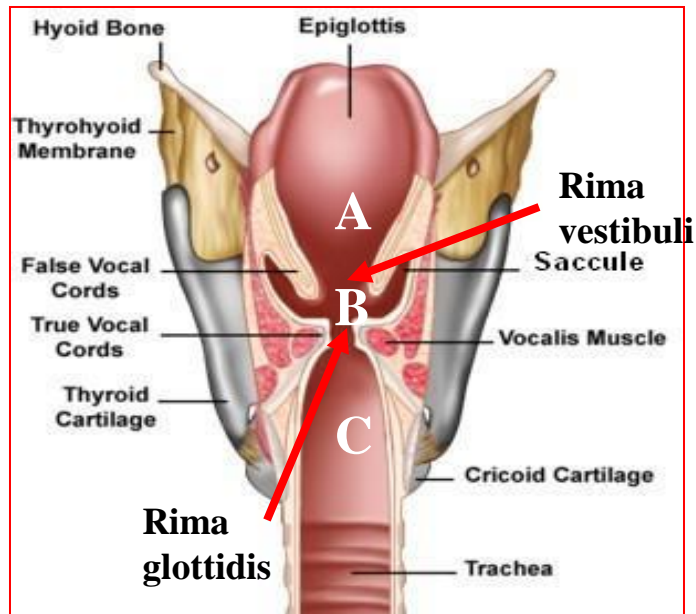
- It is the upper opening of the larynx.
- It is directed upward and backward.
- It opens into the laryngeal part of the pharynx, (laryngopharynx).
- **It is bounded by:**
  - **Anteriorly:** upper margin of epiglottis (E).
  - **Posteriorly & below:** arytenoid cartilages (A).
  - **Laterally** by the Aryepiglottic folds (AEF).



# Laryngeal Cavity

- Extends from **laryngeal inlet** to **lower border of the cricoid cartilage**.
- Narrow in the region of the vestibular folds (**rima vestibuli**).
- Narrowest in the region of the vocal folds (**rima glottidis**).
- Divided into **three parts**:
  - A. Supraglottic part or vestibule**: it is the part above the vestibular folds.
  - B. Ventricle**: it is the part between the vestibular folds & the vocal folds.
  - C. Infraglottic part**, the part below the vocal folds.

NB. The ventricle has an upward invagination called **saccul** which is rich in goblet cells.



## Mucous Membrane

- The cavity is lined with **ciliated columnar epithelium** except the surface of the vocal cords.
- The surface of **vocal folds**, is covered with **stratified squamous epithelium**, because of exposure to continuous trauma during phonation.
- It contains many **mucous glands**, more numerous in the region of the saccule (for lubrication of vocal folds).

## Muscles

Laryngeal muscles are divided into two main groups:

- **Extrinsic muscles:** subdivided into two groups:
  - **Elevators** of the larynx.
  - **Depressors** of the larynx.
- **Intrinsic muscles:** subdivided into two groups:
  - Muscles **controlling the laryngeal inlet.**
  - Muscles **controlling the movements of the vocal cords.**

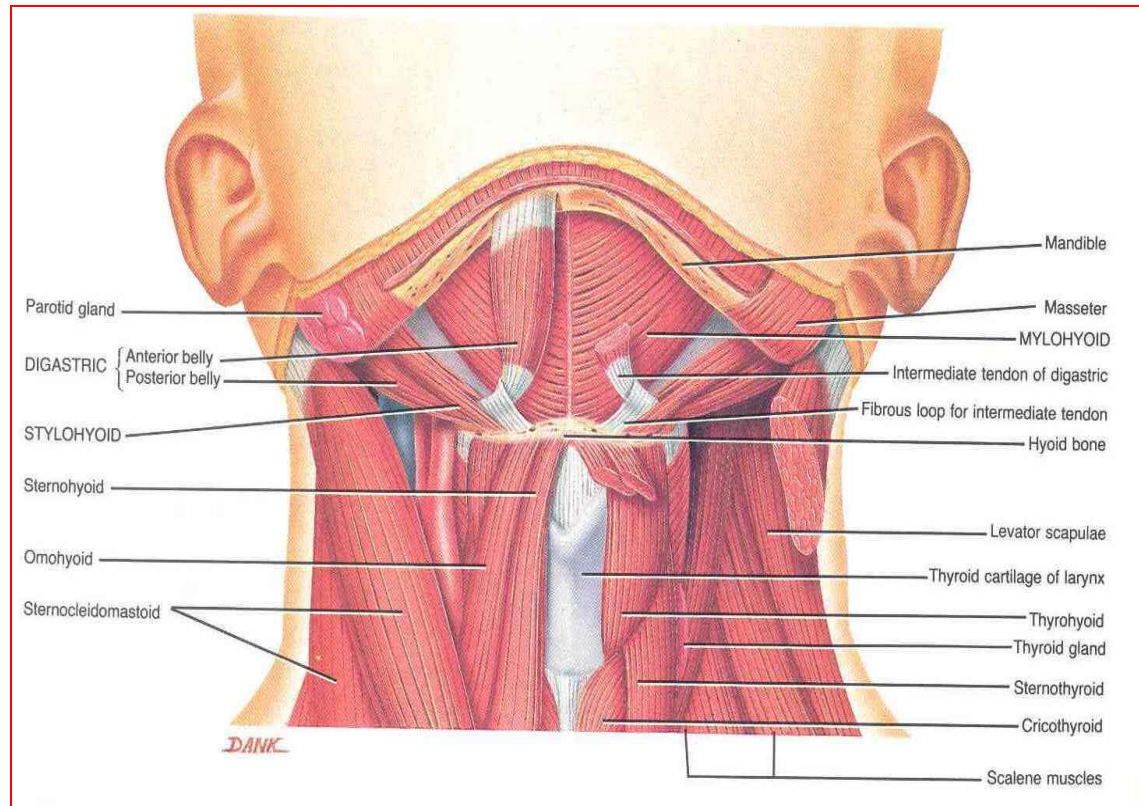
## Elevators of the Larynx

- **A- The Suprahyoid Muscles: (MSGD)**

1. Mylohyoid.
2. Stylohyoid.
3. Geniohyoid.
4. Digastric.

- **B- The Longitudinal Muscles of the Pharynx:**

- Stylopharyngeus.
- Salpingopharyngeus.
- Palatopharyngeus.



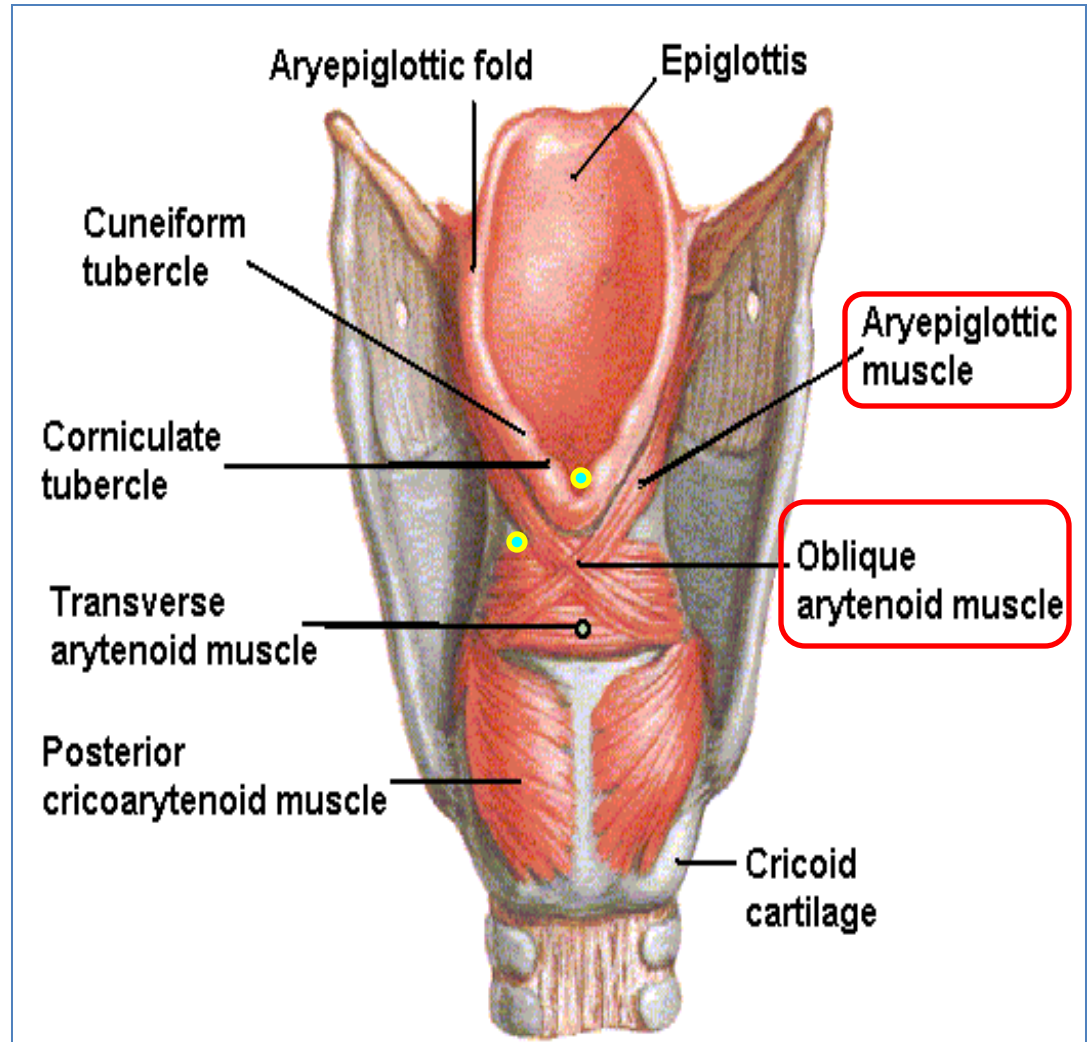
## Depressors of the Larynx

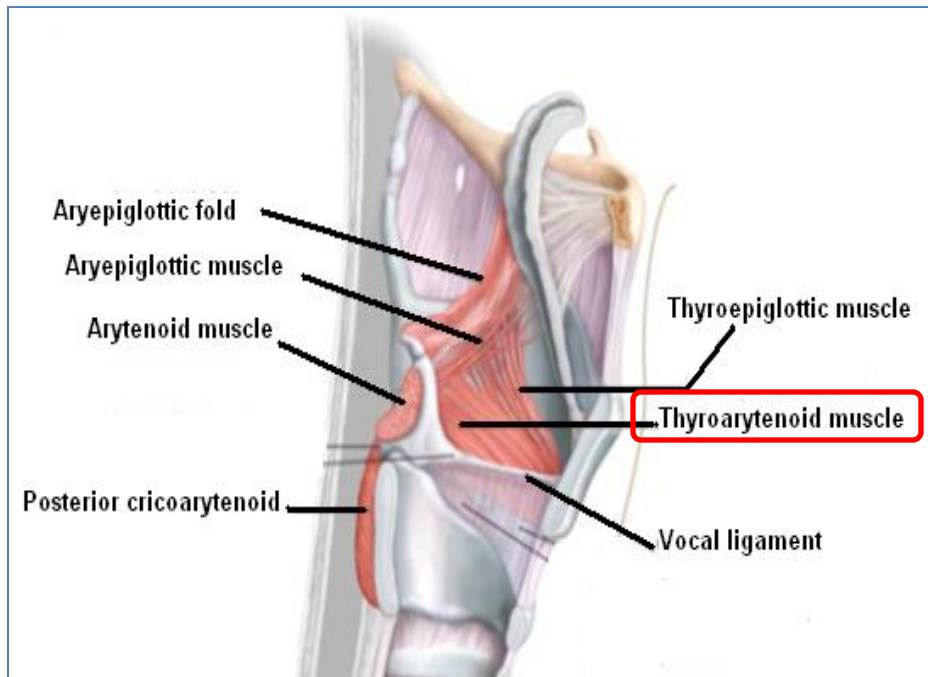
- **The Infrahyoid Muscles:**

- Sternohyoid.
- Sternothyroid.
- Omohyoid.

## Muscles Controlling the Laryngeal Inlet

- Oblique arytenoid.
- Aryepiglottic muscle.

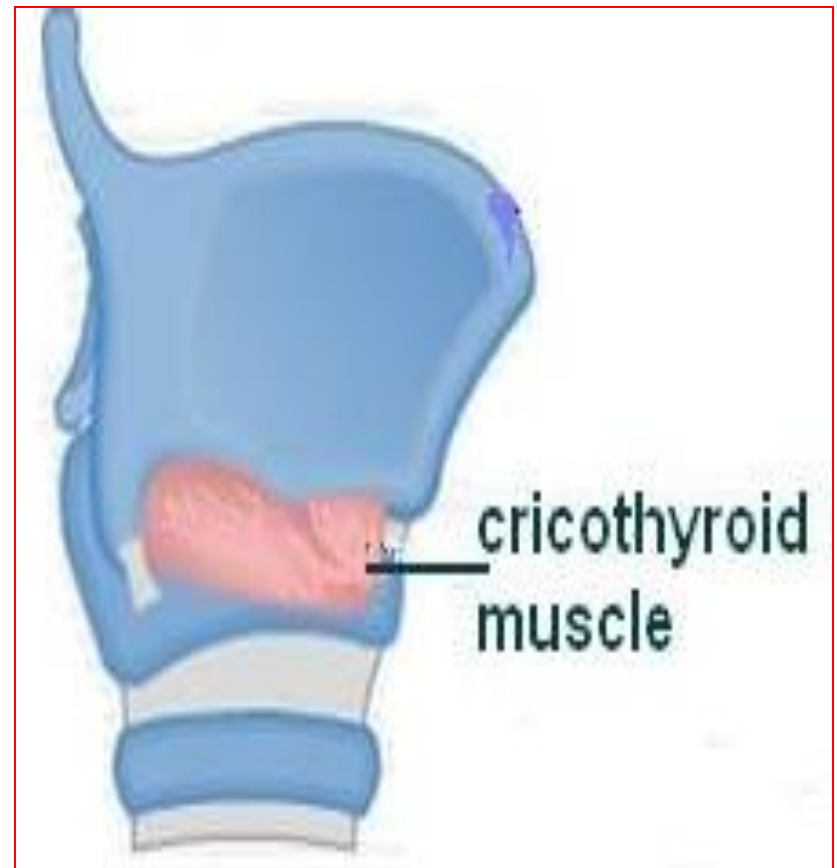




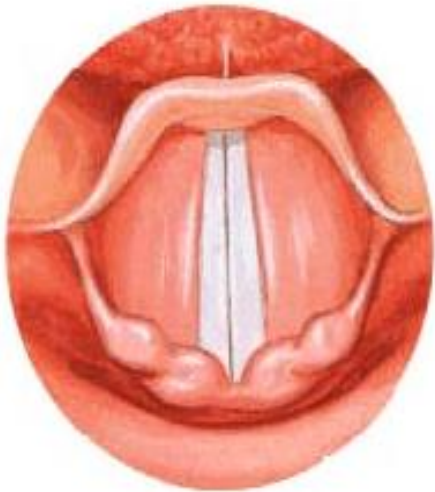- **Muscle decreasing the Length & Tension of Vocal Cords**
  - Thyroarytenoid (vocalis).

- **Muscle increasing the Length & Tension of Vocal Cords.**

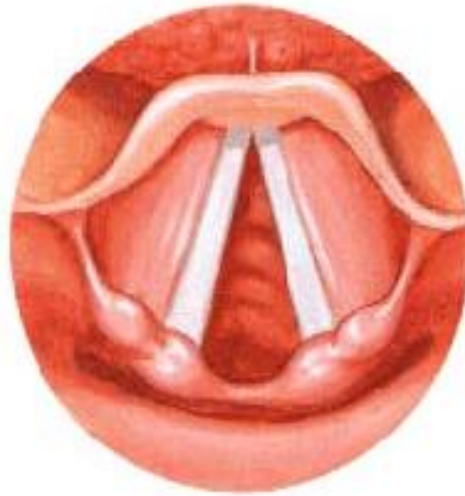
- Cricothyroid.
- NB. It is the only intrinsic muscle which found outside the larynx.



- **Movements of the Vocal Cords**



**Adduction**



**Abduction**

**Adductors:**

- Lateral cricoarytenoid.
- Transverse arytenoid.

**Abductor:**

- Posterior cricoarytenoid.

## Blood Supply

- **Arteries:**
  - **Upper half:** Superior laryngeal artery, branch of superior thyroid artery.
  - **Lower half:** Inferior laryngeal artery, branch of inferior thyroid artery.
- **Veins:**
  - Accompany the corresponding arteries.
- **Lymphatics:**
  - The lymph vessels drain into the **deep cervical lymph nodes**.

## Nerve Supply (very important):

- **Sensory**
  - **Above the vocal cords:** Internal laryngeal nerve, branch of the superior laryngeal of the vagus nerve.
  - **Below the vocal cords:** Recurrent laryngeal nerve, of the vagus nerve.
- **Motor**
  - All intrinsic muscles, **are** supplied by the **recurrent laryngeal nerve of vagus nerve except the cricothyroid**.
  - The cricothyroid is supplied by the **external laryngeal nerve** of superior laryngeal of vagus.

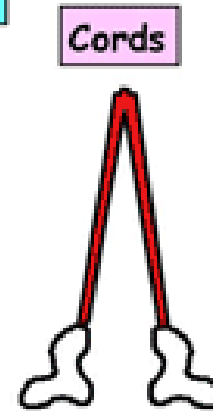
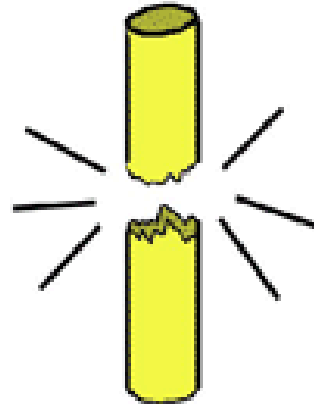


## SEMON'S LAW OR DAMAGE OF THE LARYNGEAL NERVES

### Semon's Law

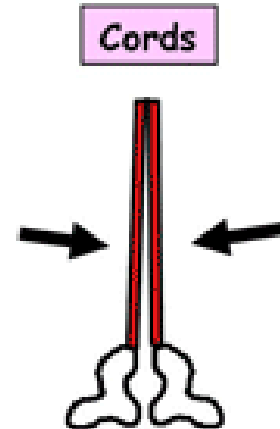
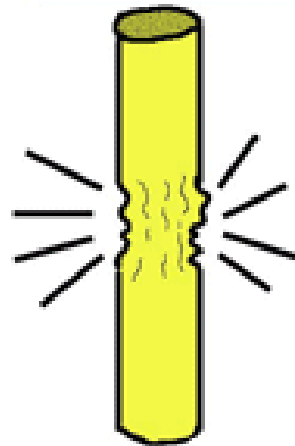
indicates the different effect between damage (surgical trauma) and transection of the recurrent laryngeal nerve due to surgery in region of the neck (e.g. thyroidectomy or parathyroidectomy).

Transection of recurrent laryngeal nerve



- Complete paralysis
- Cords half abducted/ adducted
- Cannot speak or cough

Trauma but no transection



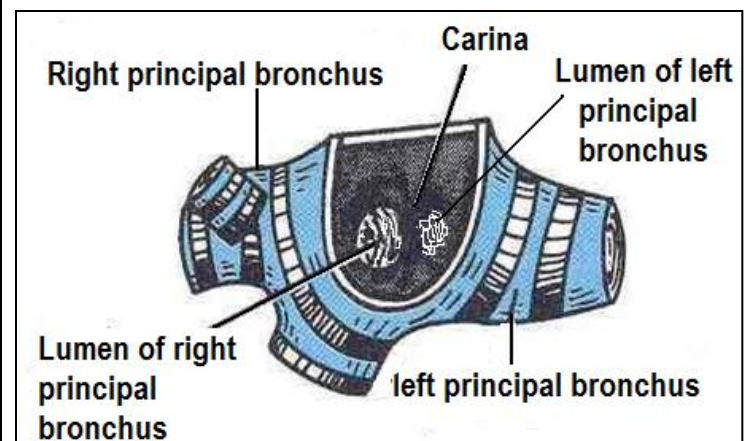
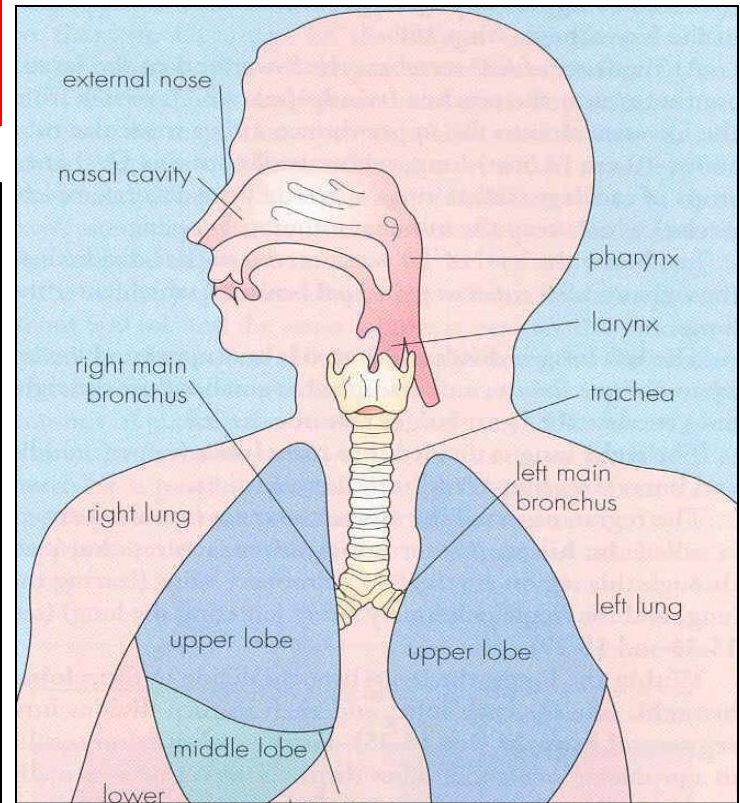
- Partial paralysis
- Adducted cords as posterior crico-arytenoid most vulnerable
- Cannot breathe

BILATERAL → DISASTER

UNILATERAL → CAN PARTIALLY COMPENSATE

# TRACHEA (windpipe)

- Mobile, fibrocartilaginous tube, **5** inches long, 1 inch in diameter
- **Begins:** In the neck below the **cricoid cartilage** of the larynx (C 6).
- **Ends:** In the thorax at the level of sternal angle (lower border of T 4), by dividing into **right and left principal (main, primary) bronchi**.
- The ridge at the bifurcation from inside is called **carina**.
- It is the most sensitive part of the respiratory tract and is associated with the cough reflex.



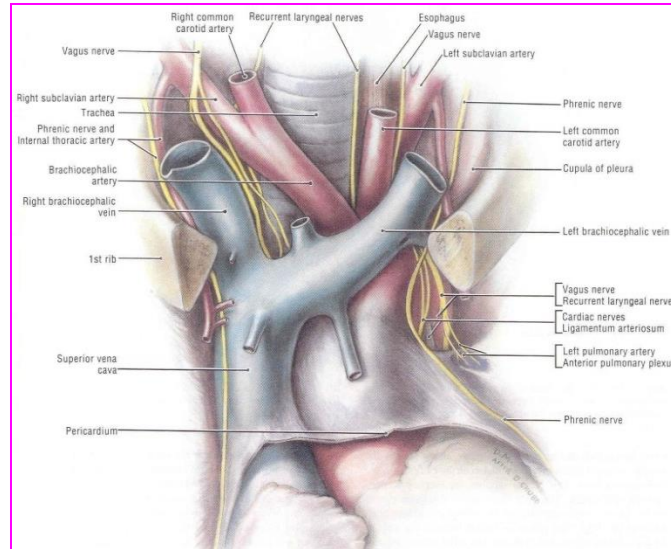
# Relations in the Superior Mediastinum

## Anterior

- Sternum.
- Thymus, (remains of thymus gland).
- **Left brachiocephalic vein.**
- **Arch of aorta.**
- Origin of:
- **Brachiocephalic artery.**
- **left common carotid artery.**

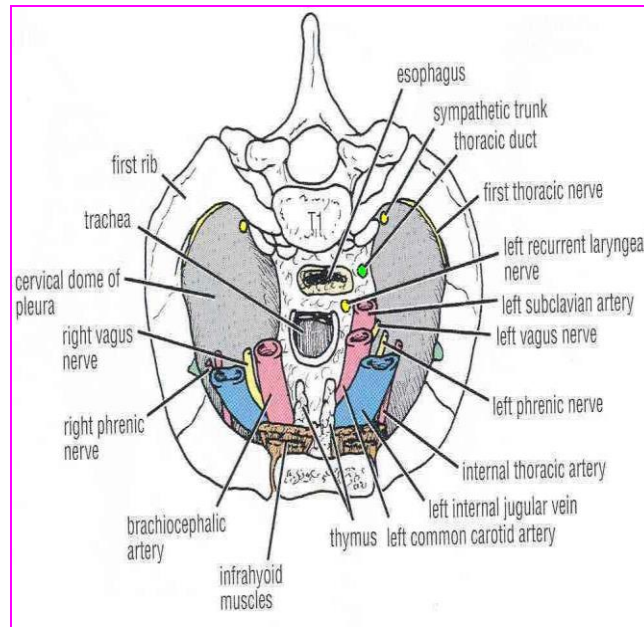
## Posterior

- Esophagus.
- **Left** recurrent laryngeal nerve.



## Left side

- **Arch of aorta.**
- **Left common carotid artery.**
- **left subclavian artery.**
- Left vagus nerve.
- Left phrenic nerve.
- Pleura.



## Right side

- Azygos vein.
- Right vagus nerve.
- Pleura.

## Nerve Supply

- Branches of the **vagus nerve** and **recurrent laryngeal nerve** give **sensory** fibers to supply the mucous membrane.
- Branches from the **sympathetic trunks** supply the **trachealis muscle** and the **blood vessels**.

## Blood Supply

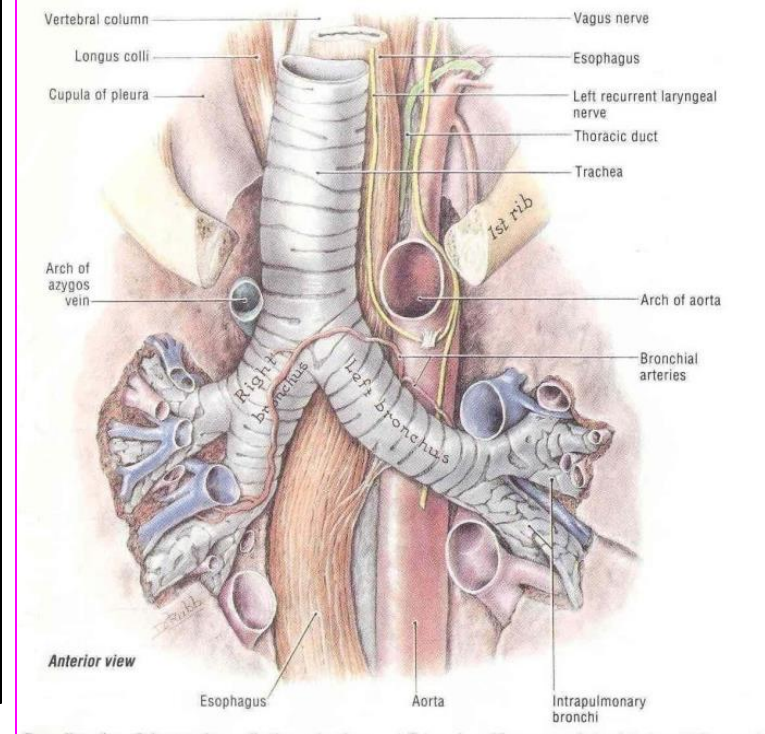
- **Arteries:** Branches from the **inferior thyroid** and **bronchial arteries**
- **Veins:** Drain to **inferior thyroid veins**.

## Lymphatic Drainage

- Into the **pretracheal** and **paratracheal** lymph nodes.

## Right Principal Bronchus:

- About **one inch** long.
- **Wider, shorter** and **more vertical** than the left.
- Gives **superior lobar bronchus** before entering the hilum of the right lung.
- On entering the hilum it divides into **middle** and **inferior lobar bronchi**.



## **Left Principal Bronchus**

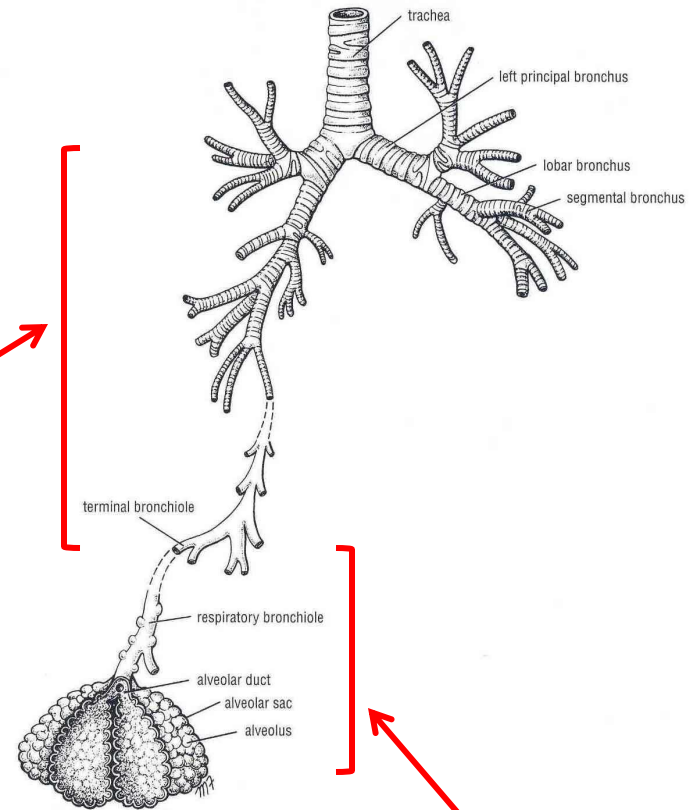
- About **two inches** long.
- **Narrower, longer** and **more horizontal** than the right.
- Passes to the left below the aortic arch and in front of esophagus.
- On entering the hilum of the left lung it divides into **superior** and **inferior lobar bronchi**.

# Bronchial Divisions

- Within the lung each bronchus divides and redivides into number of branches that can be divided into two groups:

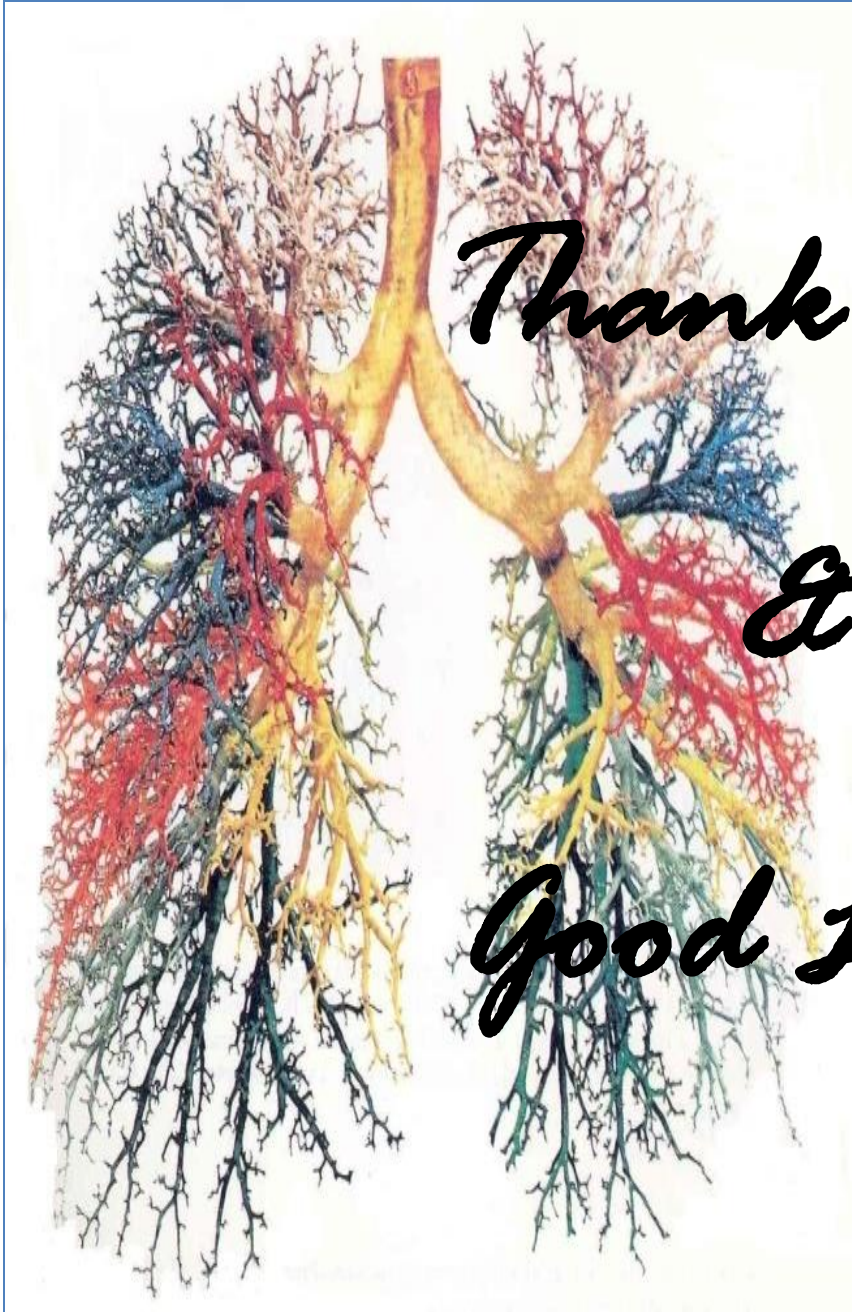## Conduction zone branches

1. Primary (main) bronchi.
2. Secondary (lobar) bronchi.
3. Tertiary (segmental) bronchi.  
(supply the bronchopulmonary segment).
4. Smaller bronchi.
5. Bronchioles.
6. Terminal bronchioles.



## Respiratory zone branches:

1. Respiratory bronchioles.
2. Alveolar ducts.
3. Alveolar sacs.
4. Alveoli.



*Thank You*

*&*

*Good Luck*

