

PATHOLOGY OF CARDIOVASCULAR SYSTEM

6 LECTURES

1. Rheumatic Heart Disease.....Dr Rikabi

2. Ischemic Heart Disease } 1
3. Atherosclerosis } 1

4. Hypertension Revision → 2

5. Thromboembolism } 3,4
6. Vasculitis } 3,4

Revision 5





HYPERTENSION

**Ahmed Alhumaidi, associate professor and consultant
Pathology Department
KSU, Riyadh
2016**

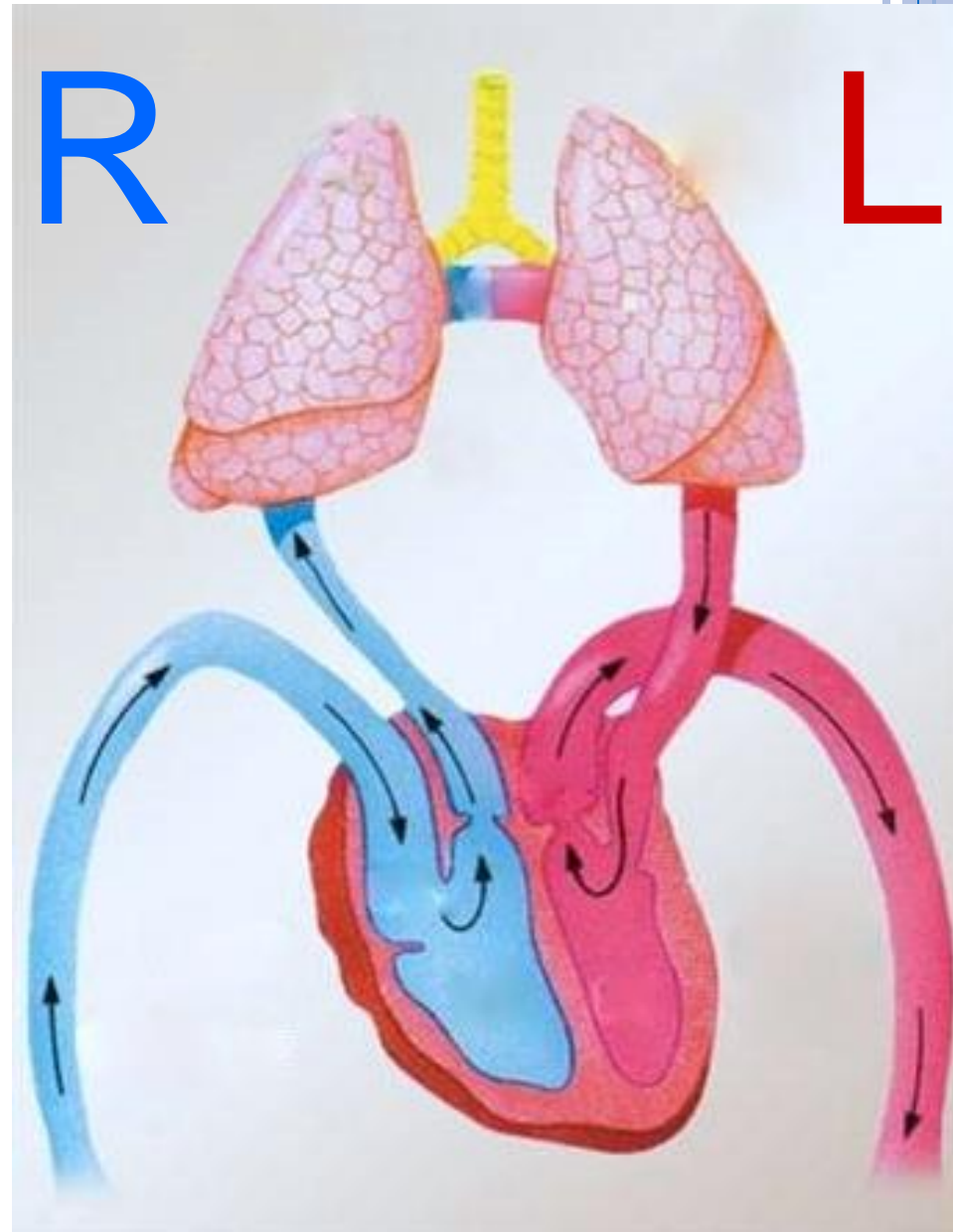OBJECTIVES

- Know the etiology, risk factors of hypertension,
- Know the types of hypertension
- Know the possible complications of untreated hypertension



LECTURE OUTLINE

- Definition
- Primary vs secondary HTN
- Benign vs malignant HTN
- Causes of secondary HTN
- Pathogenesis
- Regulation of blood pressure
- Vessels in HTN
- Heart in HTN
- Complications of HTN



HYPERTENSION - INTRODUCTION

- Common problem (25% of population)
- Asymptomatic until late- Silent Killer – painless –
- Leading risk factor – MI & Stroke
- Complications alert to diagnosis but late...



DEFINITION

- ▶ sustained diastolic pressure more than 90 mm Hg or a sustained systolic pressure in excess of 140 mm Hg (>140/90)



RISK FACTORS FOR HYPERTENSION

- **Hereditary, Genetics-** family history
- **Race.** African-Americans
- **Gender.** Men & postmenopausal women
- **Age**
- **Obesity**
- **Diet, particularly sodium intake**
- **Lifestyle-stressful**
- **Heavy alcohol consumption**
- **Diabetes**
- **Use of oral contraceptives**
- **Sedentary or inactive lifestyle**



CLASSIFICATION: BASED ON ETIOLOGY/CAUSE

- I. **Primary/Essential Hypertension (95%)** : Mechanisms largely unknown. It is idiopathic.
- II. **Secondary Hypertension (5-10%)**: it can be due to pathology in the renal, endocrine, vascular or neurogenic systems



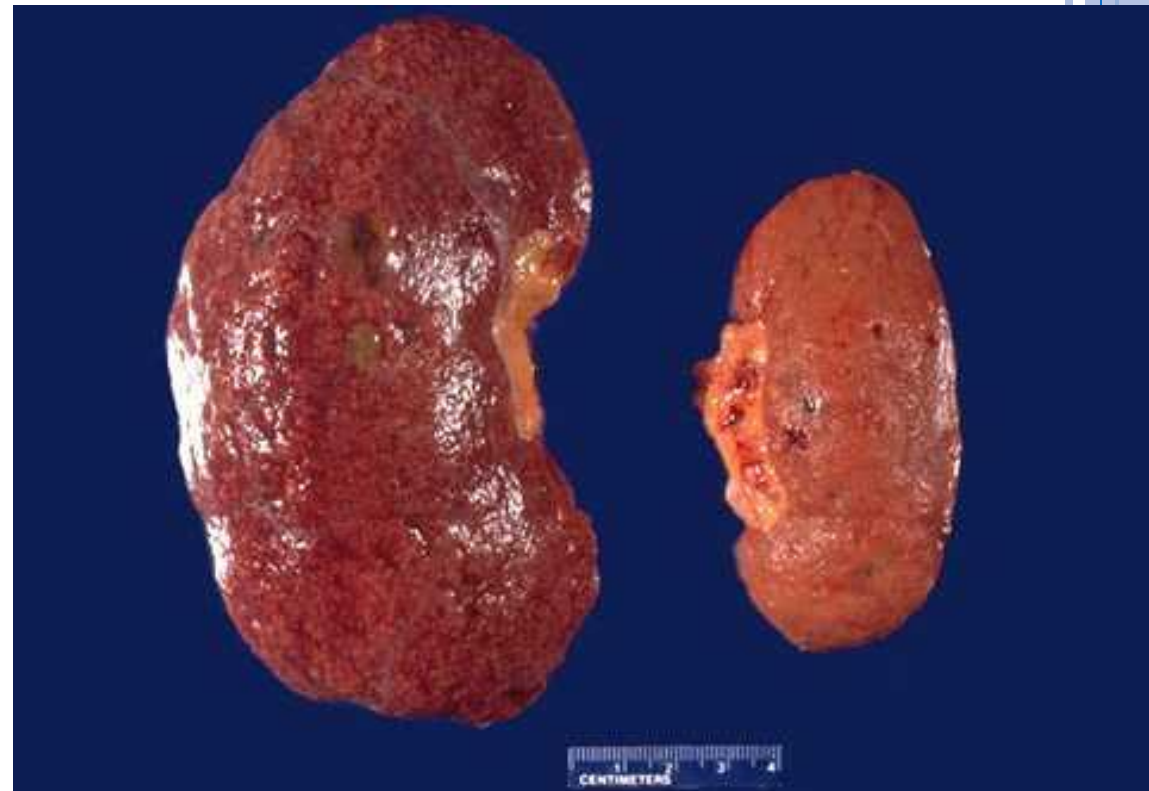CAUSES OF SECONDARY HYPERTENSION

Renal	Glomerulonephritis, Renal artery stenosis, Renal vasculitis Adult polycystic disease Chronic renal disease, Renin producing tumors
Endocrine	Adrenocortical hyperfunction (Cushing syndrome, primary aldosteronism, congenital adrenal hyperplasia) Hyperthyroidism/Thyrotoxicosis Hypothyroidism/Myxedema, Pheochromocytoma Acromegaly Exogenous hormones (glucocorticoids, estrogen e.g. oral contraceptives) Pregnancy-induced
Vascular	Coarctation of aorta Vasculitis e.g. Polyarteritis nodosa Increased intravascular volume Increased cardiac output Rigidity of the aorta
Neurogenic	Psychogenic Increased intracranial pressure Sleep apnea Acute stress, including surgery

POLYCYSTIC KIDNEY



Renal Artery stenosis - Atrophy



CLASSIFICATION BASED ON CLINICAL FEATURES.

○ Benign:

- Modest level.
- Fairly stable over years to decades.
- Compatible with long life.

○ Malignant(5%):

- There is rapidly rising BP which often leads to end organ damage
- It can complicate any type of HTN (i.e. essential or secondary)
- It is seen in 5% of HTNive patients.
- The diastolic pressure is usually over 120mmHg
- It is associated with:
 - Widespread arterial necrosis and thrombosis
 - Rapid development of renal failure
 - Retinal hemorrhage and exudate
 - Hypertensive encephalopathy
 - Left ventricular failure
 - Leads to death in 1 or 2 years if untreated.

Kidney
Retina
brain
Heart



POSTULATED MECHANISMS/PATHOGENESIS OF ESSENTIAL HYPERTENSION

1. Defect in sodium excretion

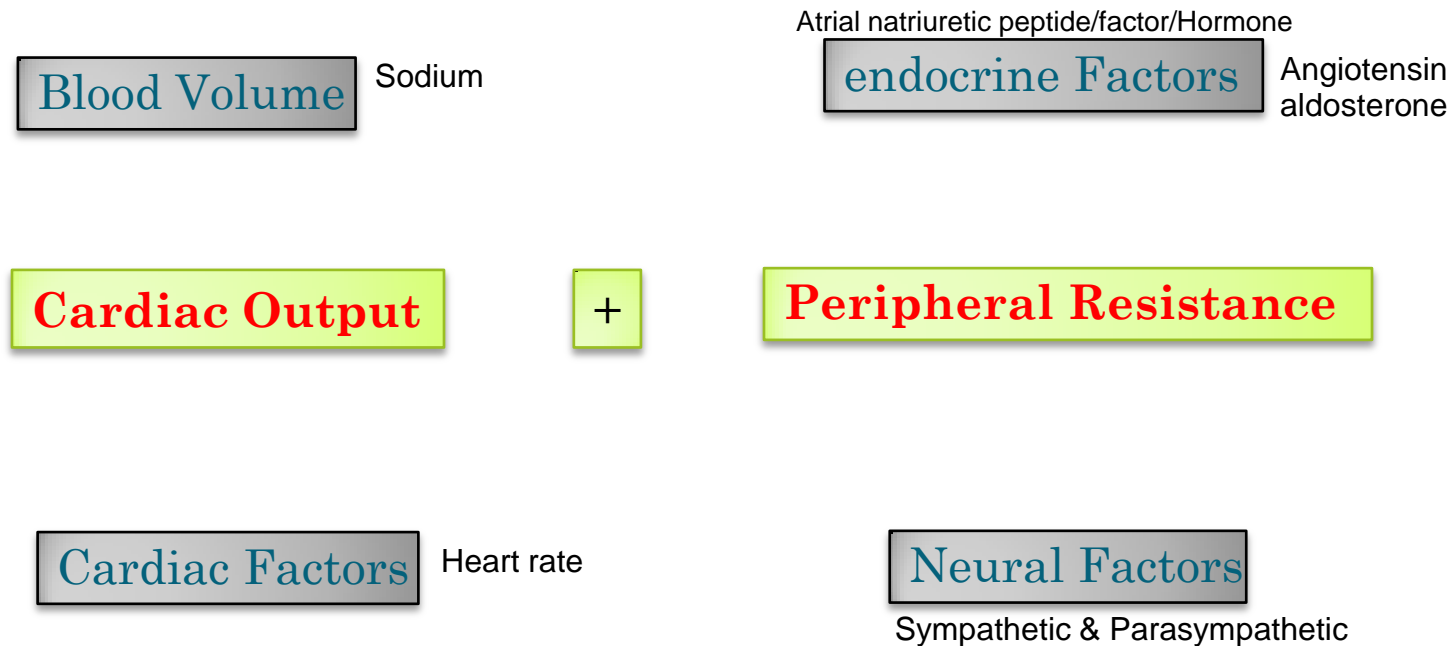
2. Defect in cell membrane function:

-Na/Ca transport

3. Increased sympathetic/ vasoconstrictive response



REGULATION OF BLOOD PRESSURE



MORPHOLOGY:

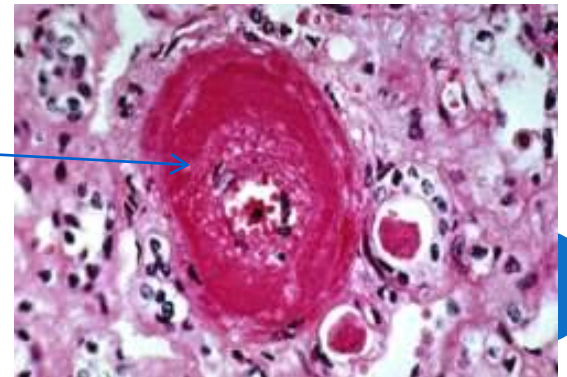
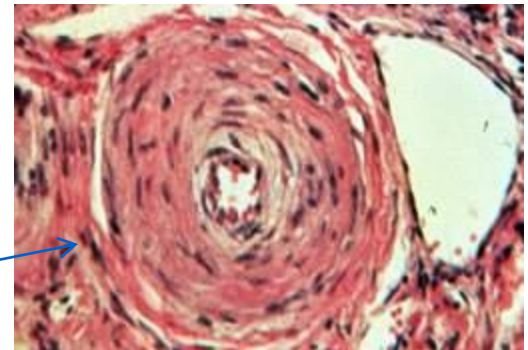
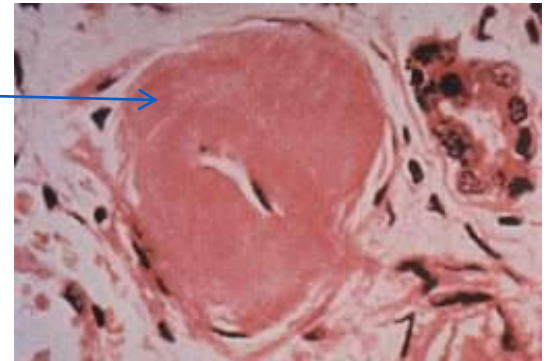
- Large Blood Vessels (Macroangiopathy)
 - Atherosclerosis. HT is a major risk factor in AS.
- Small Blood Vessels (Microangiopathy)
 - Arteriolosclerosis
 - Hyaline arteriolosclerosis
 - Hyperplastic arteriolosclerosis:



SMALL BLOOD VESSELS (MICROANGIOPATHY)

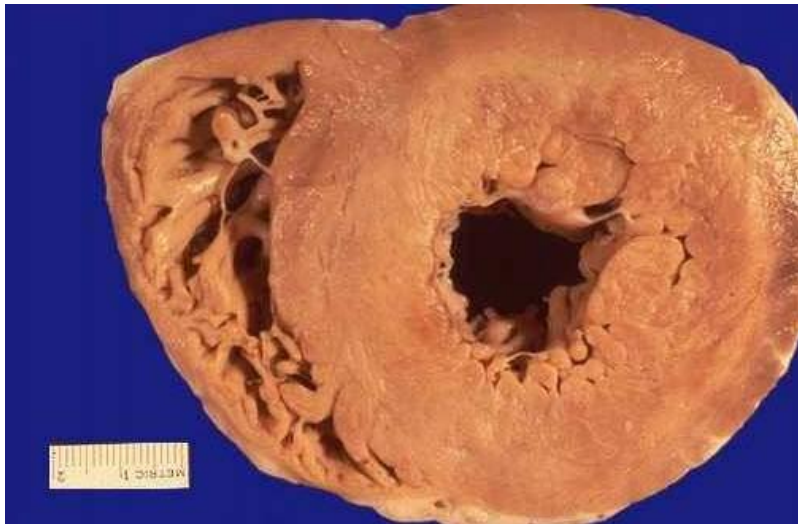ARTERIOLOSCLEROSIS

- Hyaline arteriosclerosis:
 - Characteristic of benign hypertension
 - Can also be seen in elderly without hypertension and in diabetic patients.
 - Leads to benign nephrosclerosis due to diffuse renal ischemia.
- Hyperplastic arteriosclerosis:
 - Characteristic of malignant hypertension.
 - (onionskinning) appearance
 - May be associated with necrotizing arteriolitis (fibrinoid necrosis)



Left ventricular cardiac hypertrophy (left sided hypertensive cardiomyopathy/ hypertensive heart disease)

- Longstanding poorly treated HTN leads to left sided hypertensive heart disease.
- Hypertrophy of the heart is an adaptive response to pressure overload due to HTN.
- HTN induces left ventricular pressure overload which leads to hypertrophy of the left ventricle with increase in the weight of the heart. The free LV wall is $> 2\text{cm}$ and the weight of the heart is > 500 grams



COMPLICATIONS/ORGAN DAMAGE IN HTN:

○ Cardiovascular

- Left ventricular hypertrophy
- Coronary heart disease
- Aortic dissection

○ Kidney

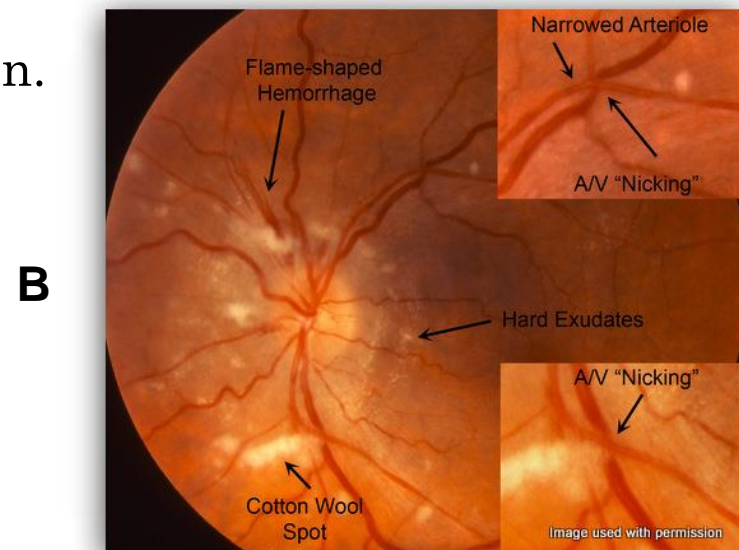
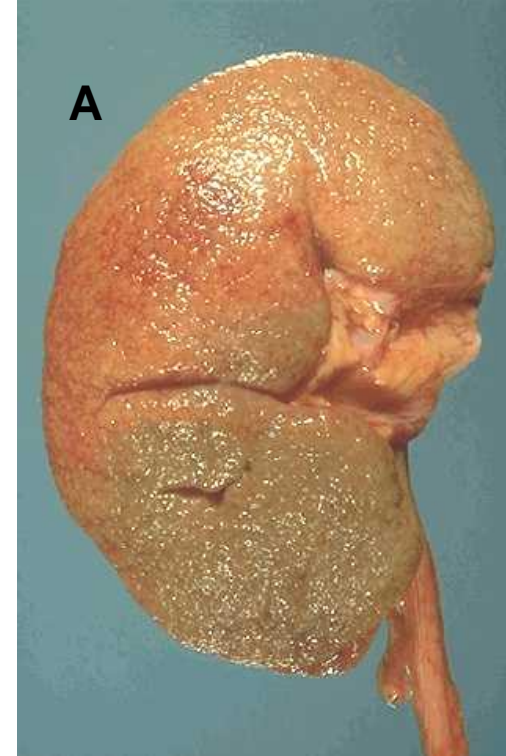- Benign nephrosclerosis (photo A)
- Renal failure in untreated or in malignant hypertension

○ Eyes

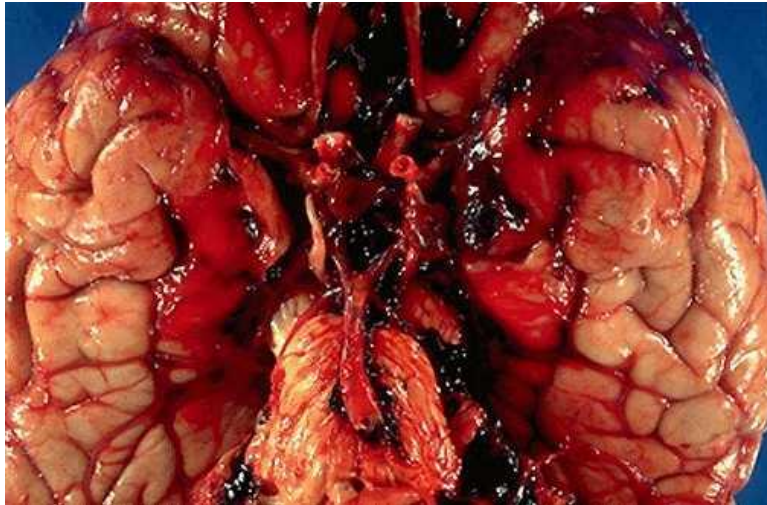
- Hypertensive retinopathy (photo B) is especially seen in malignant hypertension.

○ Brain

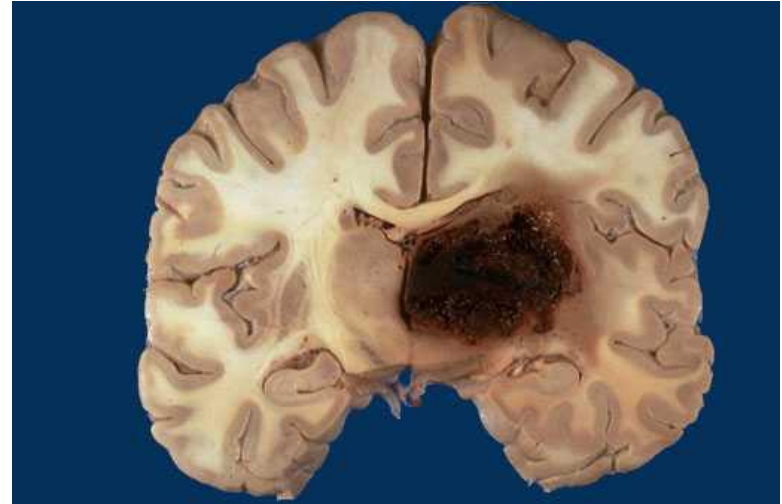
- Haemorrhage, infarction leading to Cerebrovascular accidents



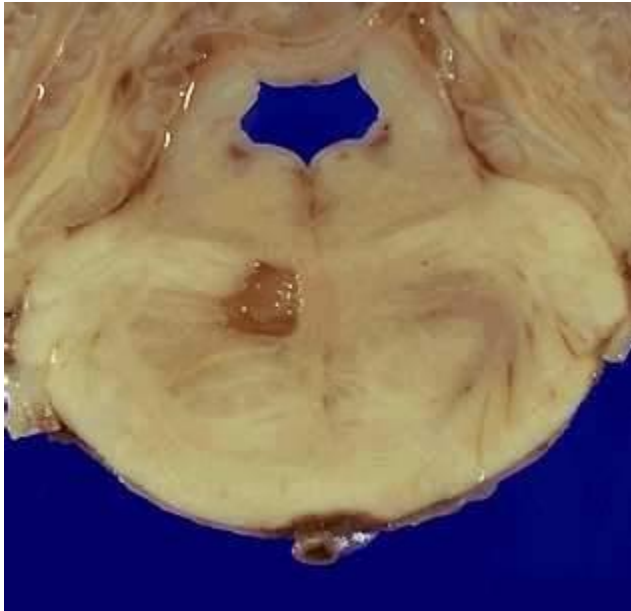
SUBARACHNOID HAEMORRHAGE



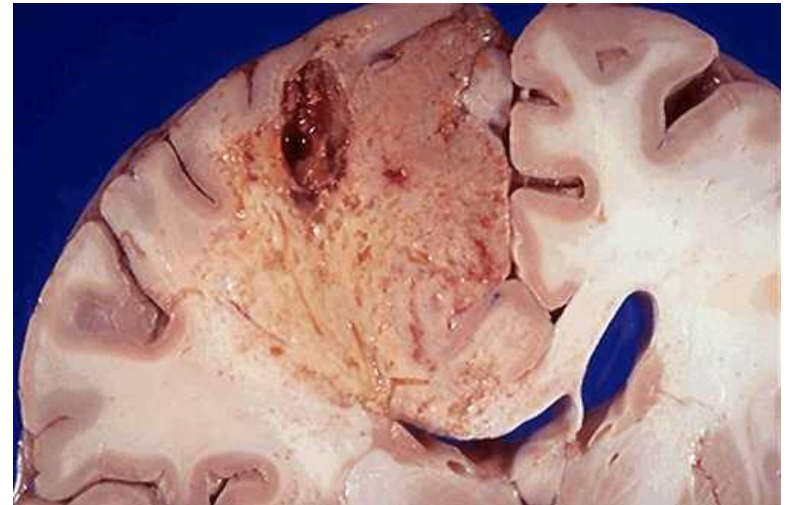CEREBRAL HEMORRHAGE



LACUNAR INFARCT



CEREBRAL INFARCTION



OBJECTIVES

- Know the etiology, risk factors of hypertension,
- Know the types of hypertension
- Know the possible complications of untreated hypertension

1. Benign
2. Malignant

Kidney
Retina
brain
Heart

1. Idiopathic 90 %
2. Secondary 10 %
 - Renal
 - Endocrine

- Genetics- Race. Gender. Age Obesity
- Diet, particularly sodium intake
- Lifestyle-stressful
- Heavy alcohol consumption
- Diabetes
- Use of oral contraceptives



A 50-year-old man experiences episodes of severe substernal chest pain every time he performs a task that requires moderate exercise. What is the diagnosis?

Typical angina pectoris

What is the finding in the coronary artery

Atherosclerosis narrowing exceeds 75%.

What are the risk factors for this disease

Diabetes mellitus hypertension hyperlipidemia smoking
Age male, genetics familial

What the pathogenesis for this disease

Endothelial cell injury

What are possible complications for this disease

Cerebral infarction, myocardial infarction, aortic aneurysm, gangreneect



After a period of time , The previous patient had chest pain even at rest?

Unstable (pre-infarction) angina

What do you expect the findings in the coronary artery?

plaque disruption and thrombosis

Now the patient suffer from Severe crushing sub-sternal chest pain, which radiate to the left shoulder and arm. ECG showed findings of myocardial infarction. What blood test support this diagnosis?

Troponin and CK-MB

After 4 days, which one of these blood tests is positive and which one is negative?

Troponin will be +ve and CK-MB will be -ve

What are the possible complications of myocardial infarction?

Arrhythmia, Left ventricular failure , Cardiogenic shock , Thromboembolism ...ect



What do expect the microscopic finding in the first 30 minutes of myocardial infarction?

No microscopic findings

Coagulation necrosis starts after which period of time of MI?

4 hours



- A 50-year-old man has sudden onset of severe substernal chest pain that radiates to the neck. Emergent coronary angiography shows a thrombotic occlusion of the left circumflex artery. Which of the following complications of this disease is most likely to occur within 1 hour of these events?
 - (A) Ventricular fibrillation
 - (B) Pericarditis
 - (C) Myocardial rupture
 - (D) Ventricular aneurysm
 - (E) Thromboembolism



- **(A)** In the period immediately after coronary thrombosis, arrhythmias are the most important complication and can lead to sudden cardiac death. It is believed that, even before ischemic injury manifests in the heart, there is greatly increased electrical irritability.
- Pericarditis and rupture occur several days later.
- An aneurysm is a late complication of healing of a large transmural infarction; a mural thrombus may fill an aneurysm and become a source of emboli.
- If portions of the coronary thrombus break off and embolize, they enter smaller arterial branches in the distribution already affected by ischemia.



- A 68-year-old man has had progressive dyspnea for the past year. An echocardiogram shows that the left ventricular wall is markedly hypertrophied. A chest radiograph shows pulmonary edema and a prominent left-sided heart shadow. Which of the following conditions has most likely produced these findings?
- (A) Centrilobular emphysema
- (B) Systemic hypertension
- (C) Tricuspid valve regurgitation
- (D) Chronic alcoholism
- (E) Silicosis



- **(B)** Hypertension is an important cause of left ventricular hypertrophy and failure. Left-sided heart failure leads to pulmonary edema with dyspnea.
- Obstructive (e.g., emphysema) and restrictive (e.g., silicosis) lung diseases lead to pulmonary hypertension with right-sided heart failure from cor pulmonale.
- Likewise, right-sided valvular lesions (tricuspid or pulmonic valves) predispose to right-sided heart failure.
- Alcoholism can lead to a dilated cardiomyopathy that affects heart function on both sides.



- A 55-year-old woman visits her physician for a routine health maintenance examination. On physical examination, blood pressure is 160/105 mm Hg. An abdominal ultrasound scan shows that the left kidney is smaller than the right kidney. A renal angiogram shows a focal stenosis of the left renal artery. Which of the following laboratory findings is most likely to be present in this patient?
- (A) Anti-double-stranded DNA titer 1 : 512
- (B) C-ANCA titer 1 : 256
- (C) Cryoglobulinemia
- (D) Plasma glucose level 200 mg/dL
- (E) HIV test positive
- (F) Plasma renin 15 mg/mL/hr
- (G) Serologic test for syphilis positive



- (F) This is a classic example of a secondary form of hypertension for which a cause can be determined. In this case, the renal artery stenosis reduces glomerular blood flow and pressure in the afferent arteriole, resulting in renin release by juxtaglomerular cells. The renin initiates angiotensin II–induced vasoconstriction, increased peripheral vascular resistance, and increased aldosterone, which promotes sodium reabsorption in the kidney, resulting in increased blood volume.



- For more than a decade, a 45-year-old man has had poorly controlled hypertension ranging from 150/90 mm Hg to 160/95 mm Hg. Over the past 3 months, his blood pressure has increased to 250/125 mm Hg. Laboratory studies show that his serum creatinine level has increased during this time from 1.7 mg/dL to 3.8 mg/dL. Which of the following vascular lesions is most likely to be found in this patient's kidneys?
- (A) Hyperplastic arteriolosclerosis
- (B) Granulomatous arteritis
- (C) Fibromuscular dysplasia
- (D) Polyarteritis nodosa
- (E) Hyaline arteriolosclerosis



- **(A)** This patient has malignant hypertension superimposed on benign essential hypertension. Malignant hypertension can suddenly complicate less severe hypertension. The arterioles undergo concentric thickening and luminal narrowing.
- A granulomatous arteritis is most characteristic of Wegener granulomatosis, which often involves the kidney.
- Fibromuscular dysplasia can involve the main renal arteries, with medial hyperplasia producing focal arterial obstruction. This process can lead to hypertension, but not typically malignant hypertension.
- Polyarteritis nodosa produces a vasculitis that can involve the kidney.
- Hyaline arteriolosclerosis is seen with long-standing essential hypertension of moderate severity. These lesions give rise to benign nephrosclerosis. The affected kidneys become symmetrically shrunken and granular because of progressive loss of renal parenchyma and consequent fine scarring.



- A 50-year-old man with a lengthy history of diabetes mellitus and hypertension has had pain in the left shoulder and arm for the past 12 hours. Over the next 6 hours, he develops shortness of breath, which persists for 2 days. On day 3, he visits the physician. On physical examination, his blood pressure is 160/100 mm Hg. Laboratory studies show that the total creatine kinase (CK) activity is within reference range, but the troponin I level is elevated. The patient is admitted to the hospital and continues to experience dyspnea for the next 3 days. On day 7 after the onset of shoulder pain, he has a cardiac arrest. Postmortem examination shows a large transmural infarction of the left anterior free wall with rupture and hemopericardium. Which of the following statements is best supported by these clinical and autopsy data?
- (A) Infarction did not develop until day 5 or day 6 after the episode of chest pain
- (B) The normal CK level obtained on day 3 excludes the possibility of infarction within the preceding 72 hours
- (C) He had an acute infarction occurring on the day he developed shoulder pain
- (D) A CK-MB fraction determination would have detected acute infarction on day 3
- (E) A second acute infarction on day 6 or day 7 caused myocardial rupture within several hours



- (C) The kinetics of creatine kinase (CK), CK-MB, and troponin I elevations after a myocardial infarction (MI) are important.
- Total CK activity begins to increase 2 to 4 hours after an MI, peaks at about 24 to 48 hours, and returns to normal within 72 hours.
- Troponin I levels begin to increase at about the same time as CK and CK-MB, but remain elevated for 7 to 10 days.
- Total CK activity is a sensitive marker for myocardial injury in the first 24 to 48 hours. CK-MB offers more specificity, but not more sensitivity.
- Myocardial rupture occurs 5 to 7 days after myocardial necrosis.

- This patient had an MI on the day of the shoulder pain. When he saw the physician on day 3, the CK levels had returned to normal, but troponin I levels remained elevated. Three days later, the infarct ruptured.



- A 60-year-old man has experienced angina on exertion for the past 6 years. A coronary angiogram performed 2 years ago showed 75% stenosis of the left anterior descending coronary artery and 50% stenosis of the right coronary artery. For the past 3 weeks, the frequency and severity of the anginal attacks have increased, and pain sometimes occurs even when he is lying in bed. Which of the following is most likely to explain these findings?
 - (A) Hypertrophy of ischemic myocardium with increased oxygen demands
 - (B) Increasing stenosis of right coronary artery
 - (C) Fissuring of plaque in left coronary artery with superimposed mural (partial) thrombosis
 - (D) Sudden complete thrombotic occlusion of right and left coronary arteries
 - (E) Reduction in oxygen-carrying capacity owing to pulmonary congestion



- (C) This patient has 75% stenosis of the left anterior descending branch of the coronary artery. This degree of stenosis prevents adequate perfusion of the heart when myocardial demand is increased, which occurs during exertion. The patient had angina on exertion. The patient has recently developed unstable angina, which is manifested by increased frequency and severity of the attacks and angina at rest. In most patients, unstable angina is induced by disruption of an atherosclerotic plaque followed by a mural thrombus and possibly distal embolization, vasospasm, or both.
- Hypertrophy of the heart is unlikely in this case because there is neither hypertension nor a valvular lesion.
- The remaining choices theoretically can give rise to a similar picture, but plaque disruption with mural thrombosis is the most common anatomic finding when the patient develops unstable angina.
- It is important to recognize this because unstable angina is a harbinger of myocardial infarction.



- A 50-year-old man with familial hyperlipidemia undergoes resection of an abdominal aneurysm. Signs of congestive heart failure develop shortly after surgery. Despite treatment, the patient becomes hypotensive and expires 2 days later. Autopsy reveals marked narrowing of coronary arteries, without thrombosis. Multiple foci of necrosis are found circumferentially around the inner walls of both ventricles. Which of the following is the most likely cause of congestive heart failure in this patient?
- (A) Calcific aortic stenosis
- (B) Dilated cardiomyopathy
- (C) Rupture of papillary muscle
- (D) Subendocardial myocardial infarction
- (E) Transmural myocardial infarction



- **The answer is D:**
- **Subendocardial myocardial infarction.** Subendocardial
- circumferential infarcts generally occur as a consequence
- of hypoperfusion of the heart secondary to poor
- coronary blood flow, often in the setting of hypotension.
- Coronary artery narrowing is common, but total occlusion is
- usually not seen. Subendocardial myocardial infarcts affect the
- inner one third to one half of the ventricle. They may arise
- within the territory of one of the major coronary arteries or
- may involve the subendocardial distribution of all coronary
- arteries. Transmural myocardial infarction (choice E)
- generally
- follows occlusion of a major coronary artery.
- **Diagnosis:** Subendocardial myocardial infarction



summary

- ❑ Systemic hypertension is one of the most prevalent and serious causes of coronary artery and myocardial disease.
- ❑ It is defined as a persistent increase in systemic blood pressure to levels above 140 mm Hg systolic or 90 mm Hg diastolic, or both.
- ❑ Chronic hypertension causes compensatory hypertrophy of the left ventricle as a result of the increased workload imposed on the heart muscle. The left ventricular wall and interventricular septum become uniformly thickened.
- ❑ Congestive heart failure is the most common cause of death in untreated hypertensive patients.
- ❑ Intracerebral hemorrhage is also a frequent fatal complication.
- ❑ In addition, death may result from coronary atherosclerosis and myocardial infarction, dissecting aneurysm of the aorta, or ruptured berry aneurysm of the cerebral circulation.
- ❑ Renal failure may supervene when nephrosclerosis induced by hypertension becomes severe.



summary

One theory behind essential hypertension is that there are defects in renal sodium homeostasis that reduce renal sodium excretion. The kidney retains sodium and water, increasing intravascular fluid volume, which drives increased cardiac output. Cardiac output is compensated by increasing peripheral vascular resistance, causing an increase in blood pressure.

If angiotensin converting enzyme (ACE) were absent, blood pressure would decrease because angiotensin I would not be converted to angiotensin II (drugs that act as ACE inhibitors are antihypertensives). An elevated plasma renin level is typical of renovascular hypertension, which can occur with narrowing of a renal artery.

Hypertensive patients with hypokalemia also can have hyperaldosteronemia, which can be caused by an aldosterone-secreting adrenal adenoma.

Increased urinary catecholamines can indicate increased catecholamine output from a pheochromocytoma.

