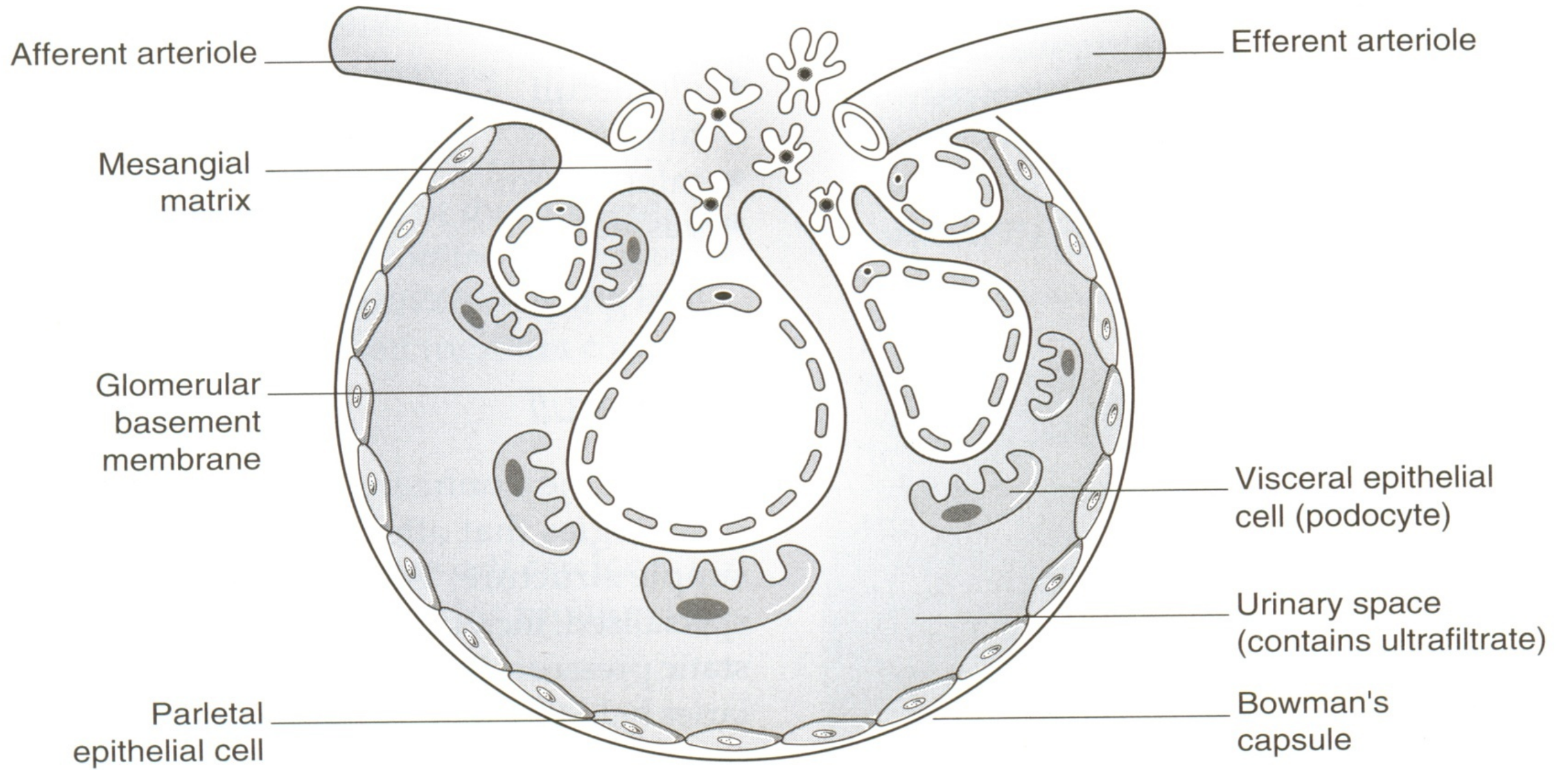


PATHOLOGY OF THE NEPHROTIC AND  
NEPHRITIC SYNDROMES.  
(GLOMERULAR DISEASES)

HALA KFOURY, MD

# Objectives:

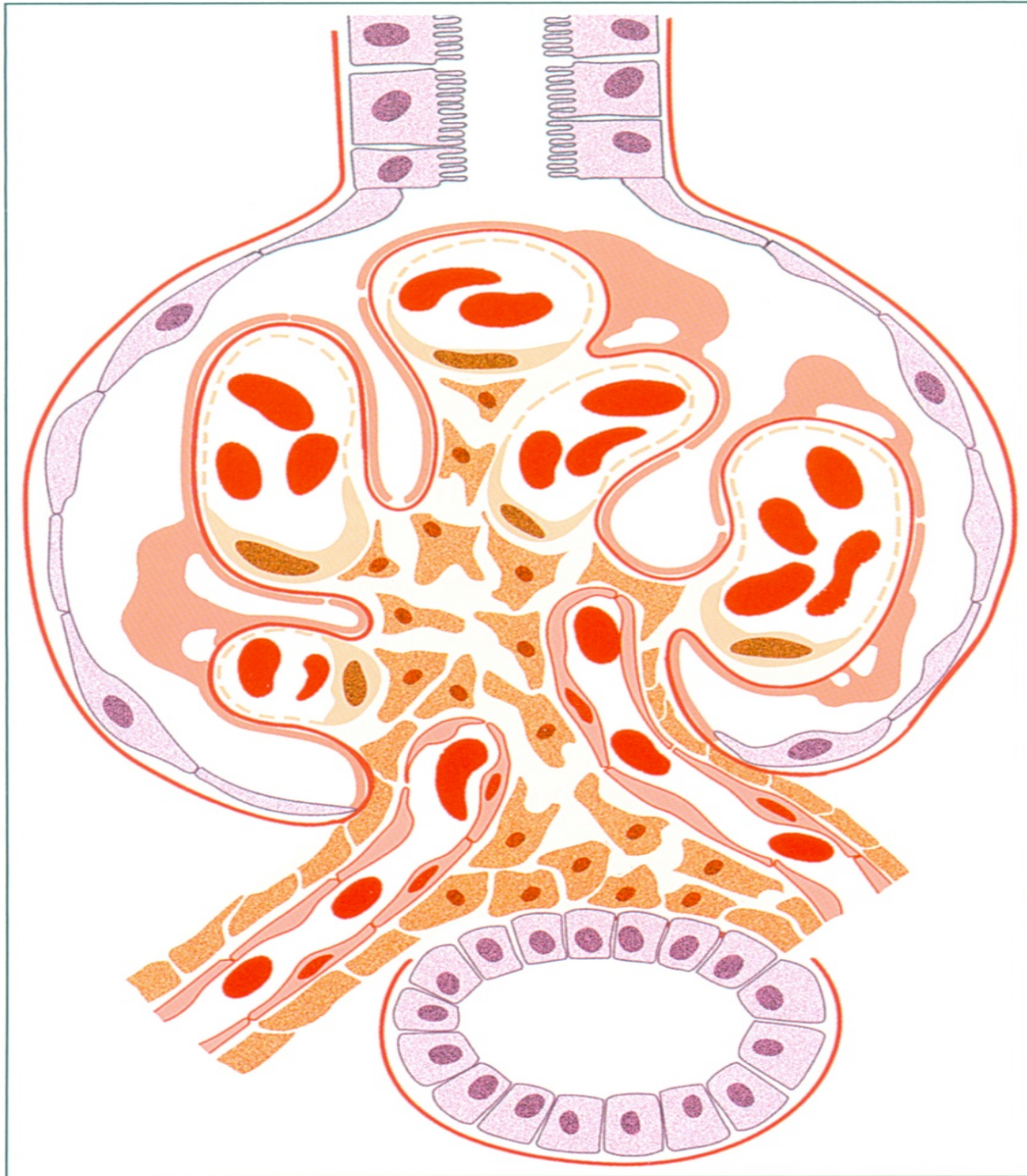
- Recognize the five major renal clinical syndromes.
- Describe the main differential pathological diagnosis for each syndrome.
- Perform a clinico-pathological correlation.
- Describe the patterns of injury of each syndrome.



# Clinical Syndromes

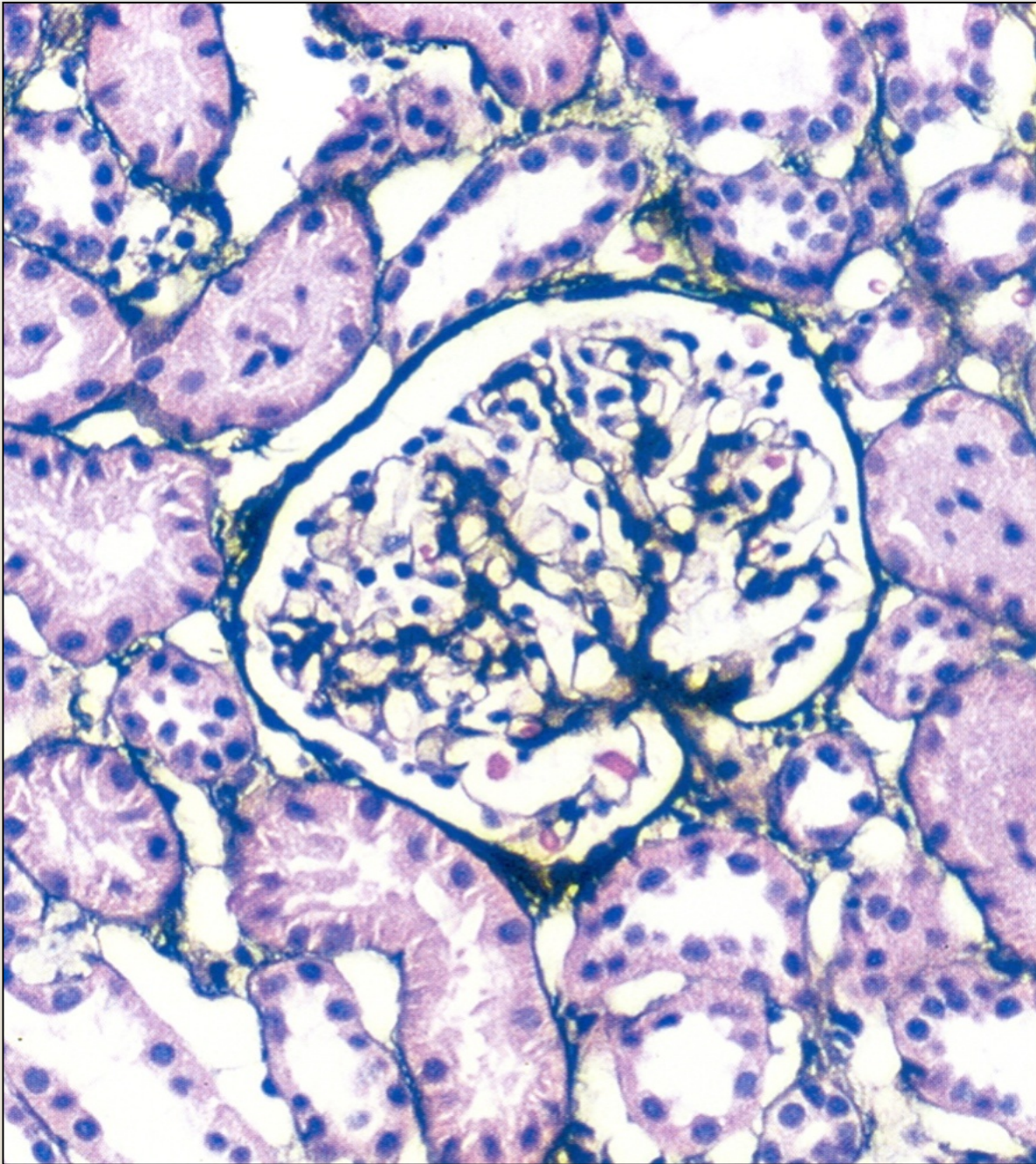
**1. Nephrotic syndrome = heavy proteinuria = proteins in urine = loss of 3,5 g/day**





Minimal change disease/  
glomerulonephritis.

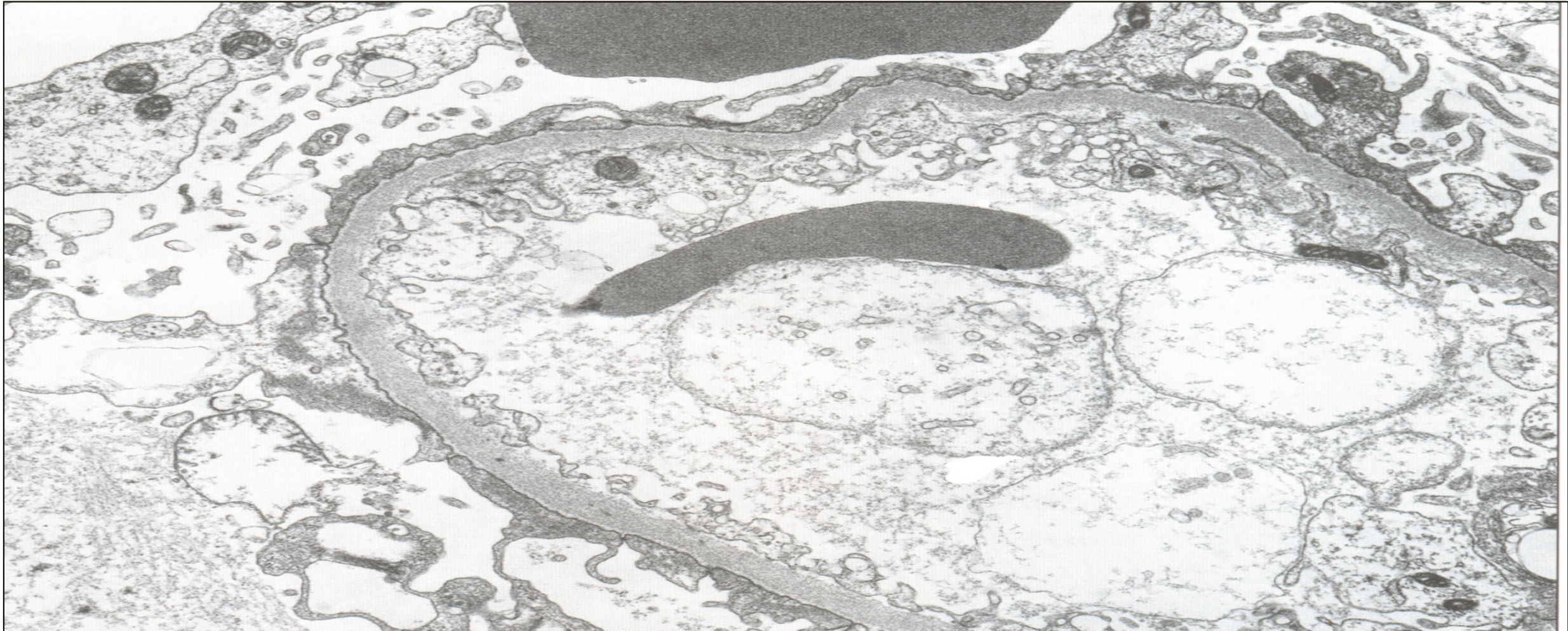
The glomeruli are normal by  
LM, but with diffuse  
effacement of foot  
processes by EM.



Minimal change disease. Glomeruli appear unremarkable by light microscopy, and in young patients there is no tubulointerstitial fibrosis, as in this patient.



Minimal change disease. Extensive foot process effacement and microvillous transformation of visceral epithelial cells in MCD



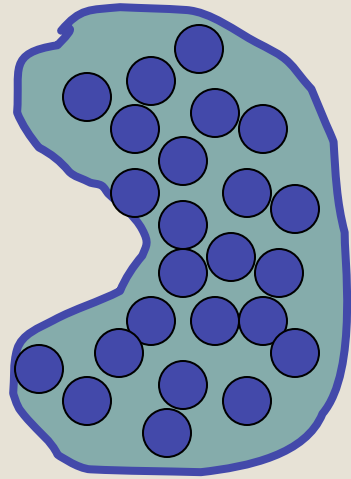
**MINIMAL CHANGE DISEASE**

**DIFFUSE EPITHELIAL CELL  
DISEASE**



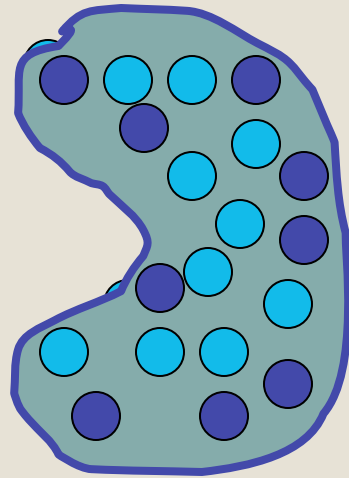
# Pathology of the kidney

## Glomerular diseases



**Diffuse :**

**all  
glomeruli**

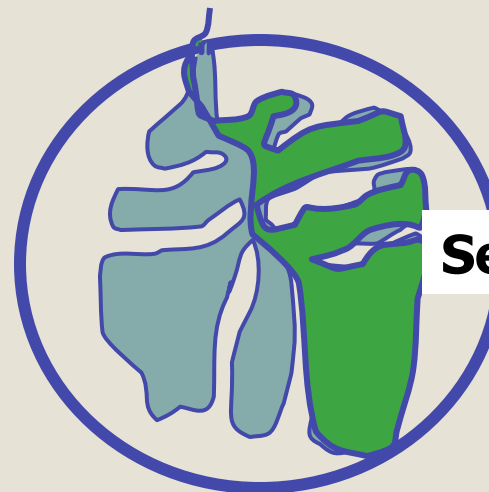

**Focal:**

**some  
glomeruli**

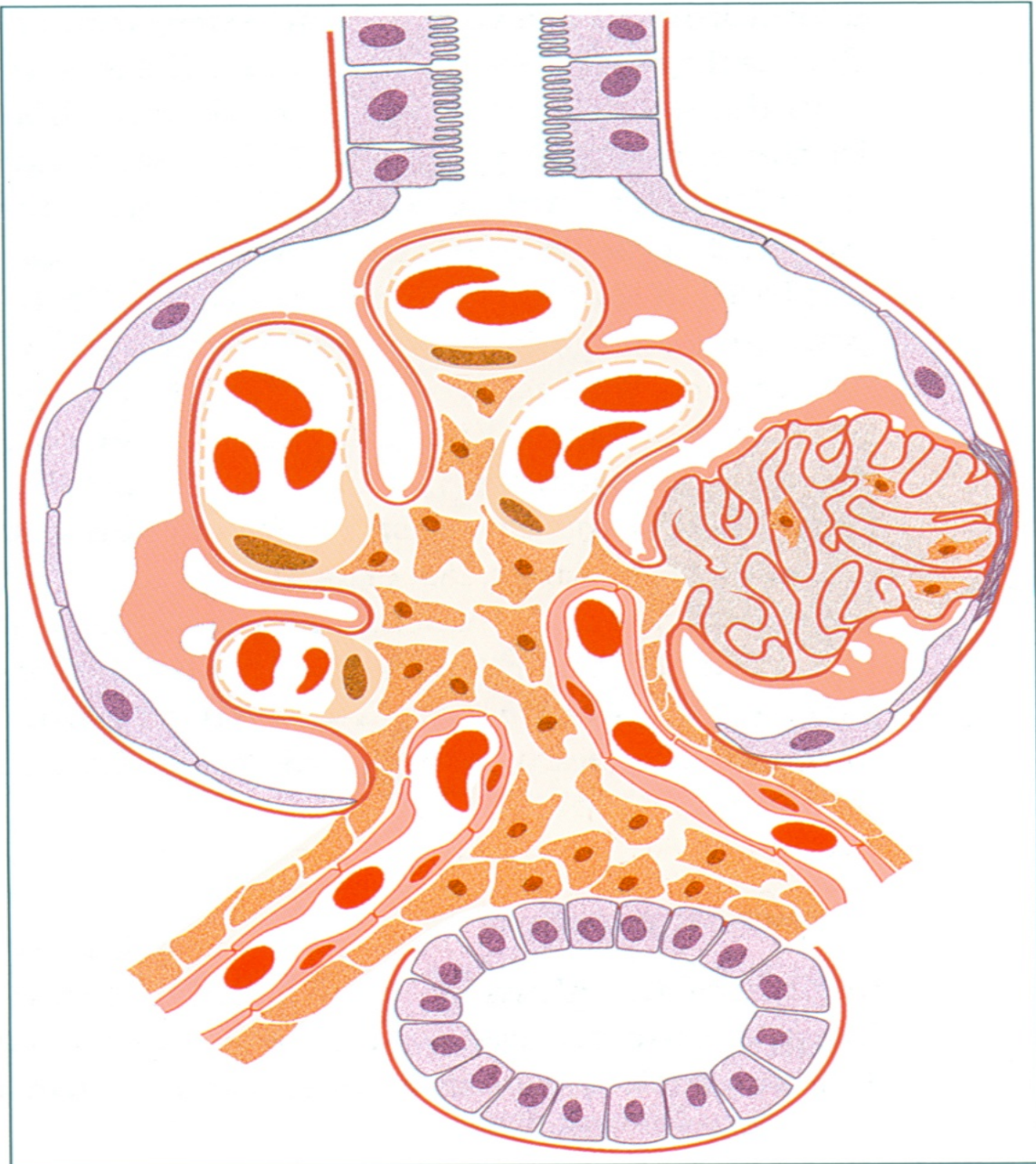


**Global**



**Segmental**

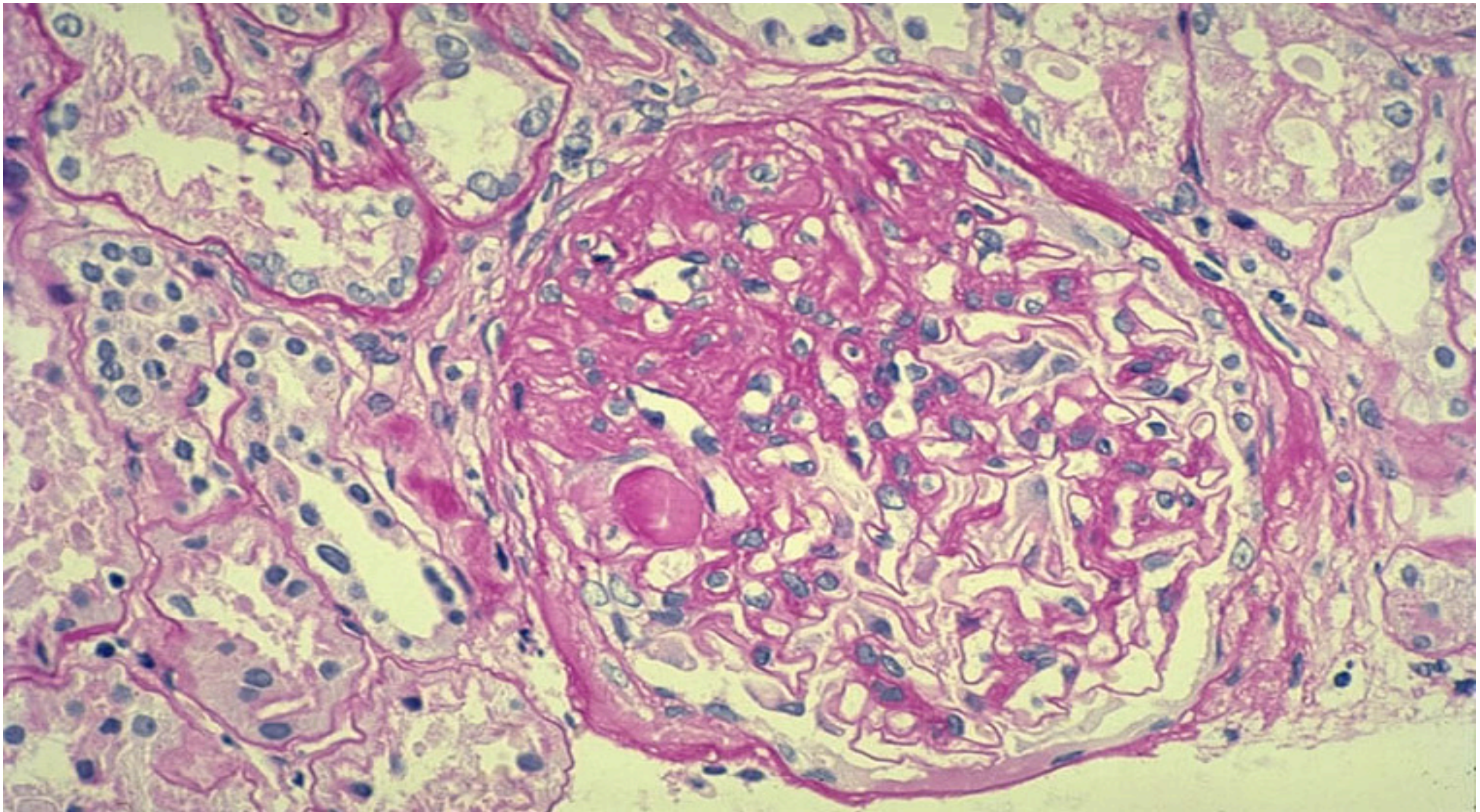




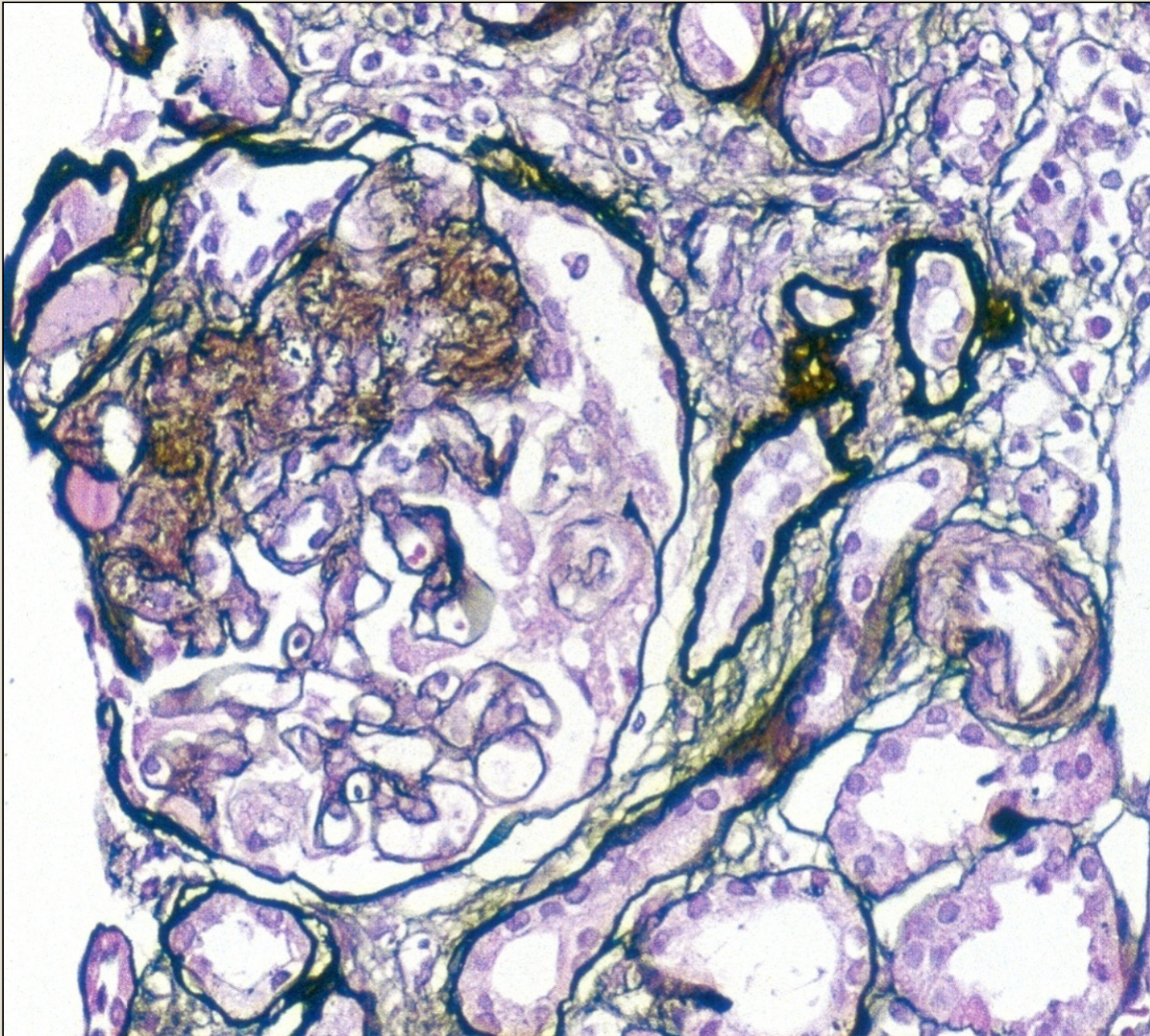
## Focal segmental glomerulosclerosis

FSGS. There is sharply defined segmental sclerosis, defined as obliteration of capillary loops and increased matrix, without deposits and with diffuse foot process effacement by EM. Adhesions can also be present.



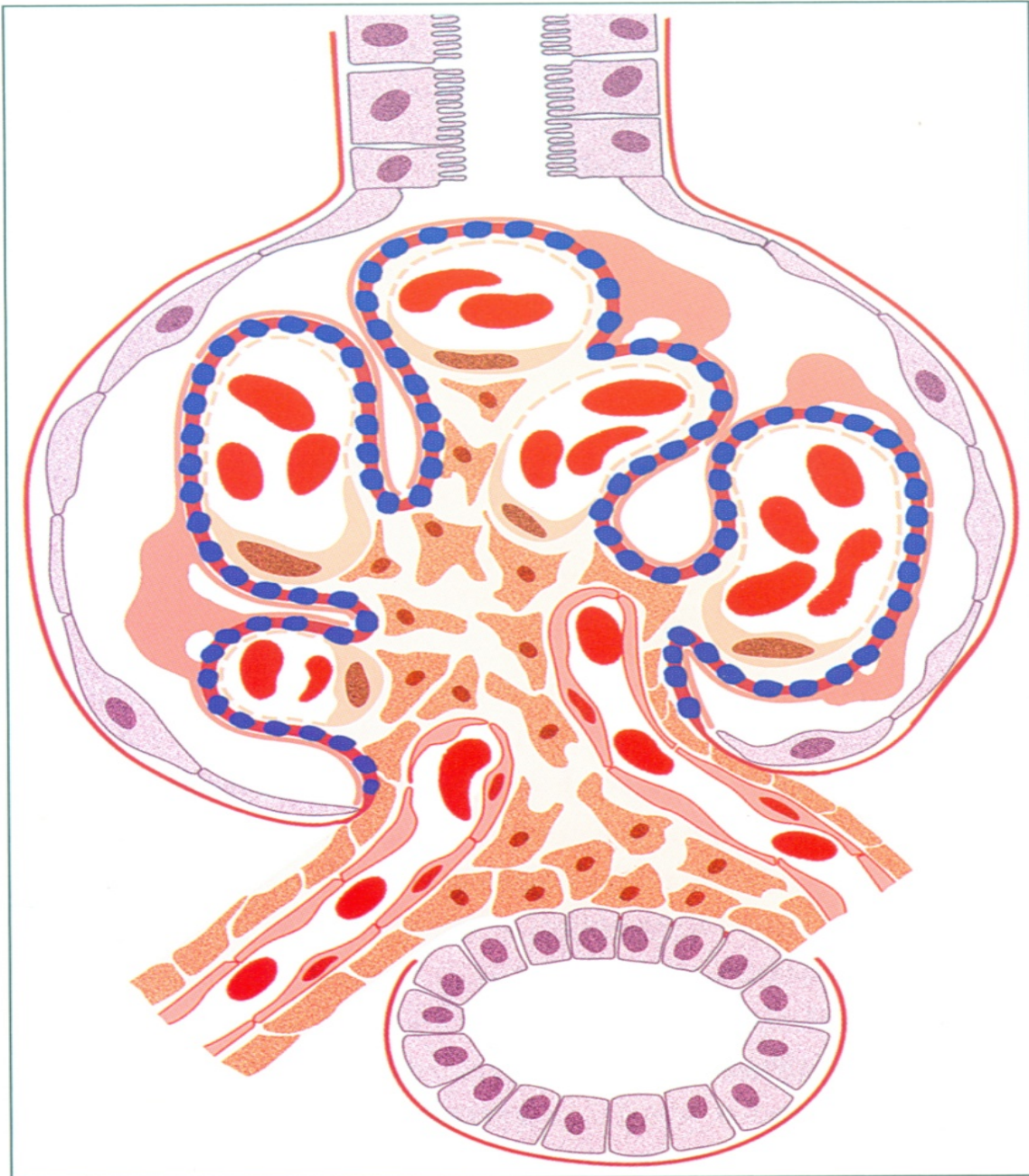






FSGS. The typical segmental sclerotic lesion in FSGS is characterized by increased matrix and obliteration of capillary lumina, frequently with hyalinosis and adhesions, as illustrated here.



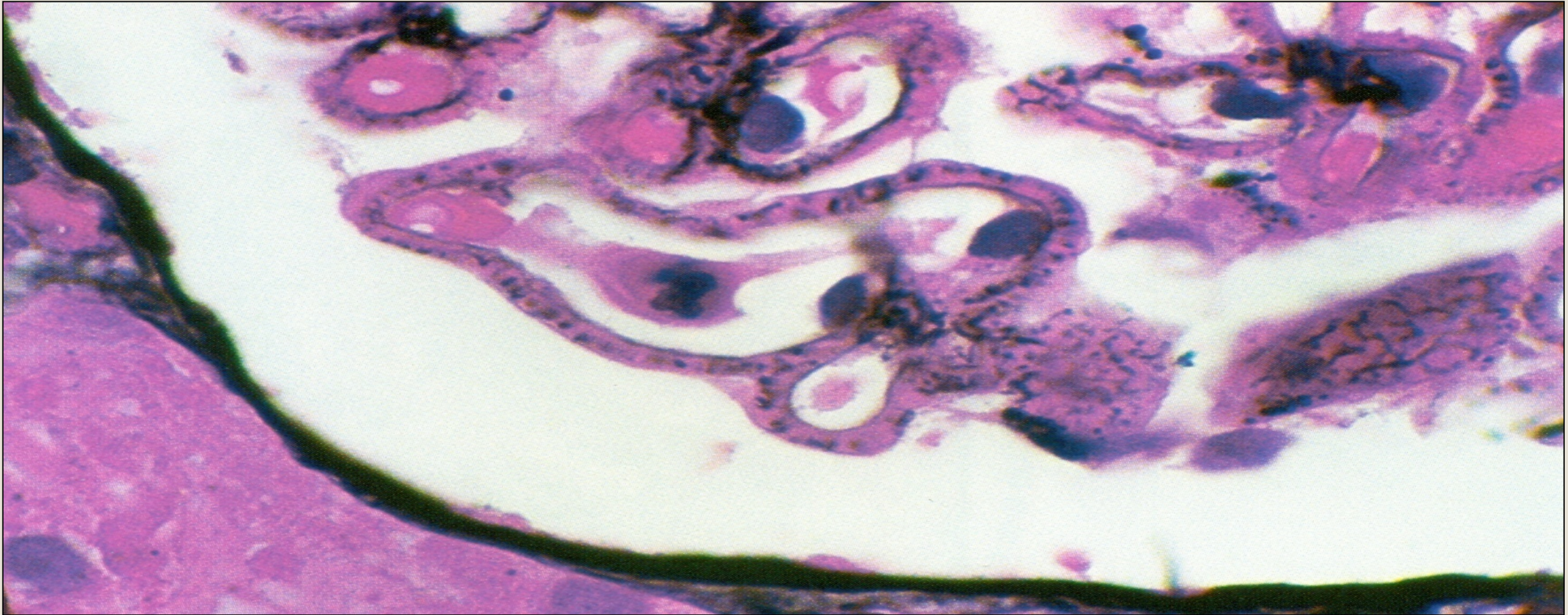


## Membranous glomerulopathy

Membranous glomerulopathy. There is no evident proliferation by light microscopy, with global subepithelial deposits, which may be visualized by light microscopy by the glomerular basement membrane spike reaction on silver stain.



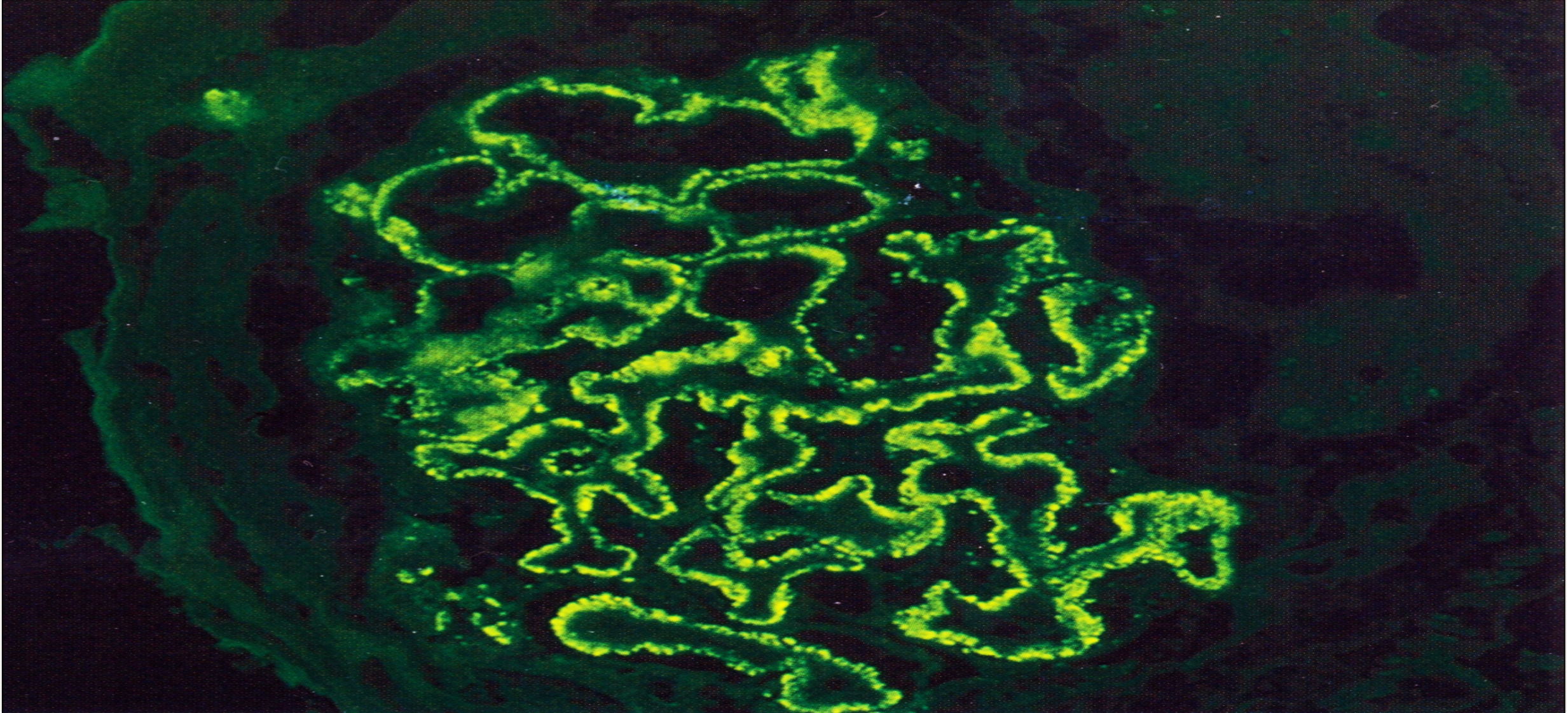
Membranous glomerulopathy. There are well-developed spikes and holes in tangential sections in stage-2 membranous glomerulopathy.



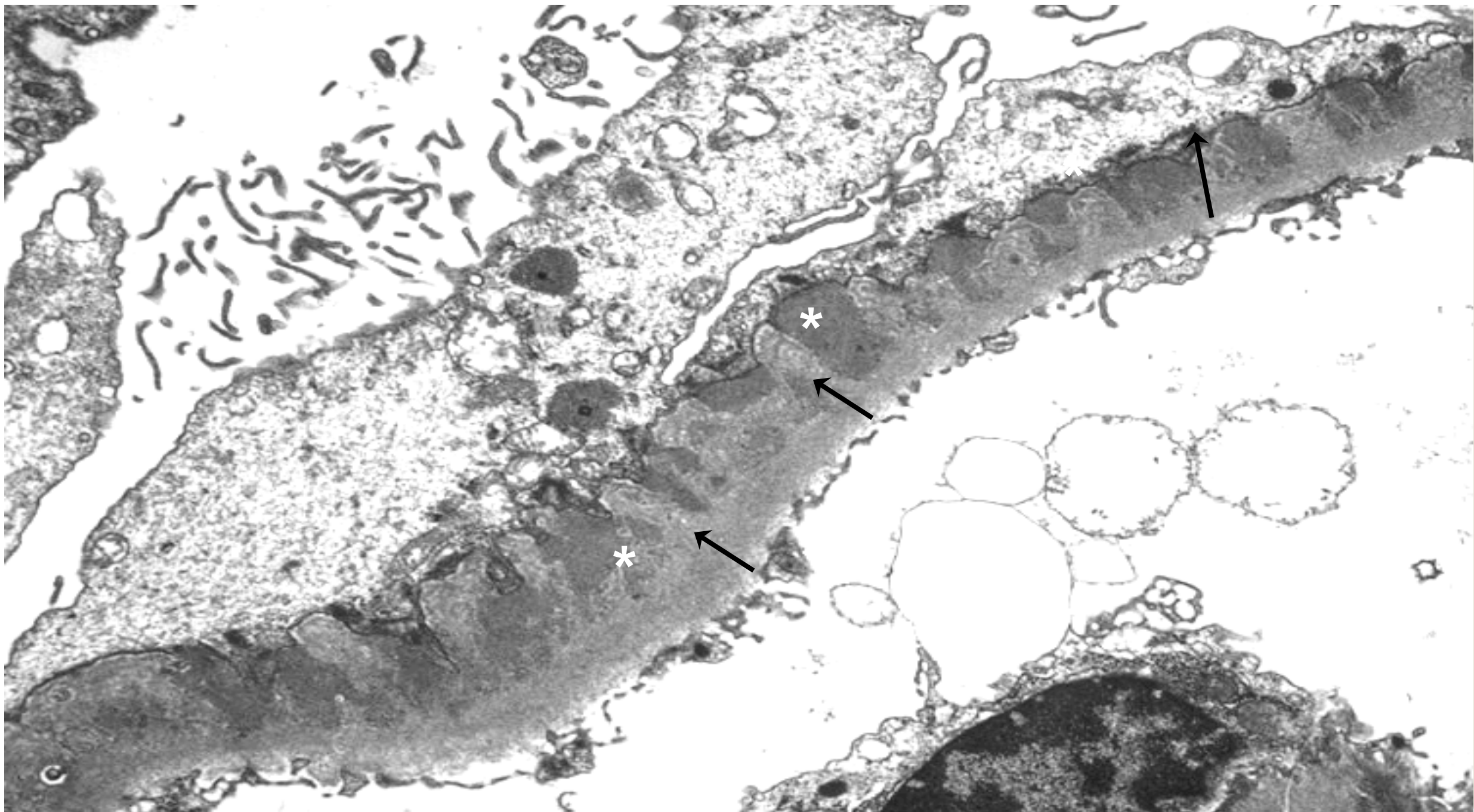


## **Membranous glomerulopathy.**

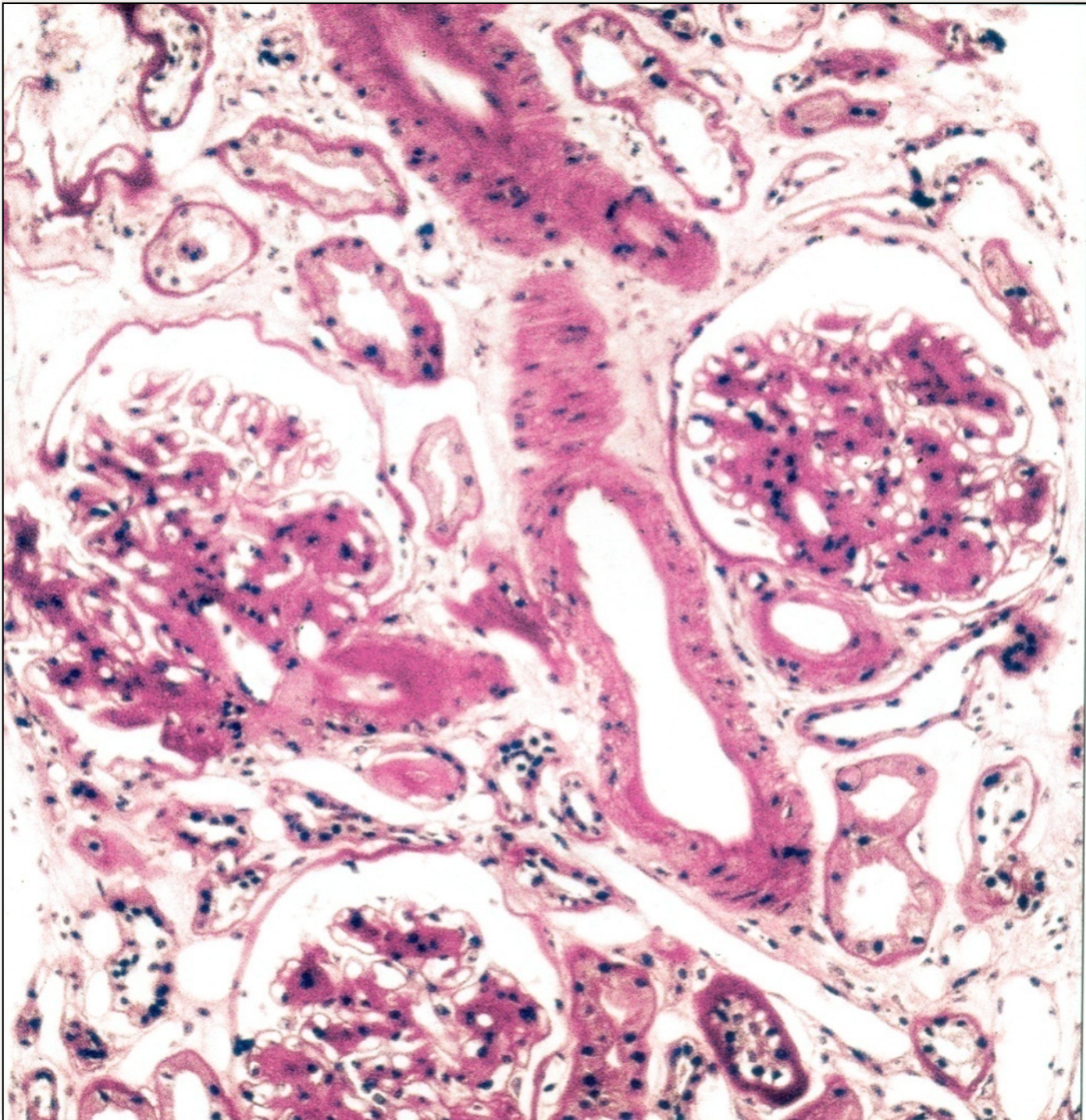
There is an evenly distributed granular capillary loop pattern of positivity in membranous glomerulopathy.









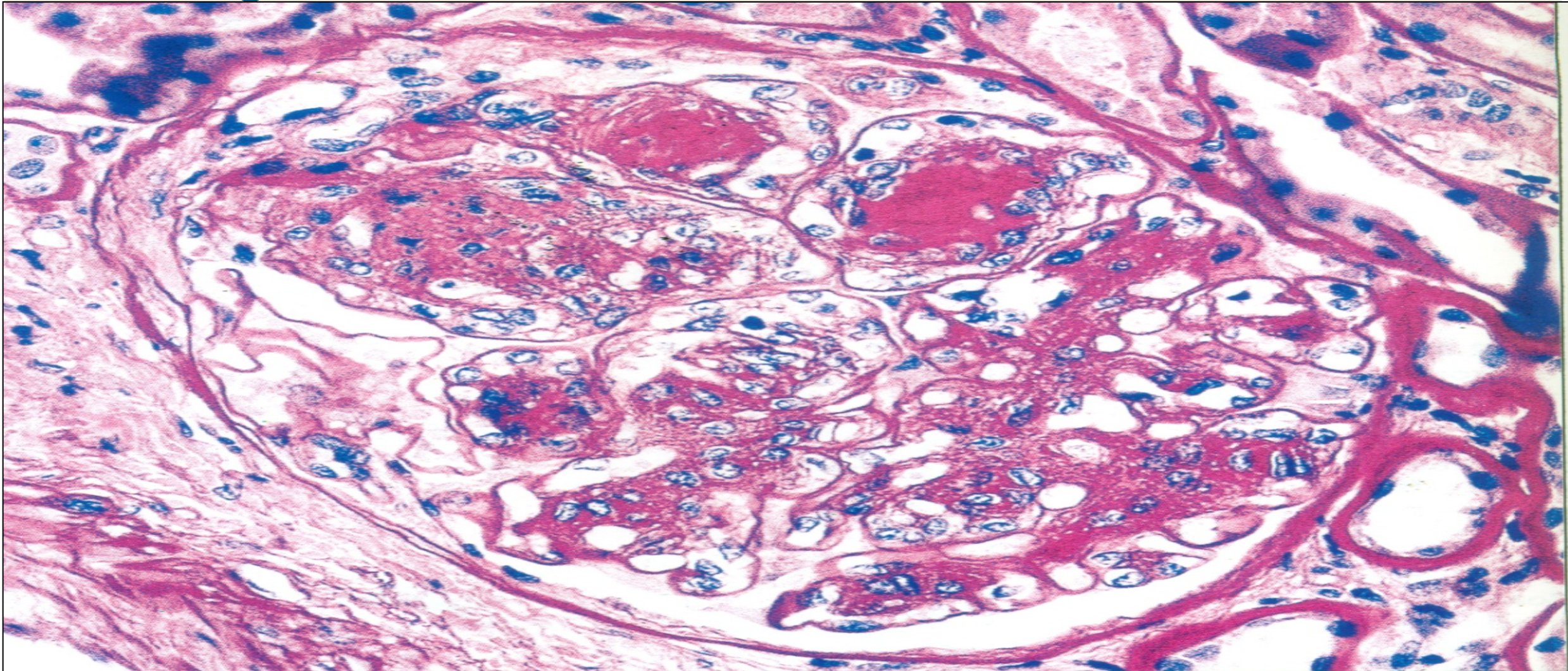


Diabetic nephropathy.

The lesions in diabetic nephropathy are characterized by arteriolar hyalinization, mesangial matrix expansion and glomerular basement thickening.

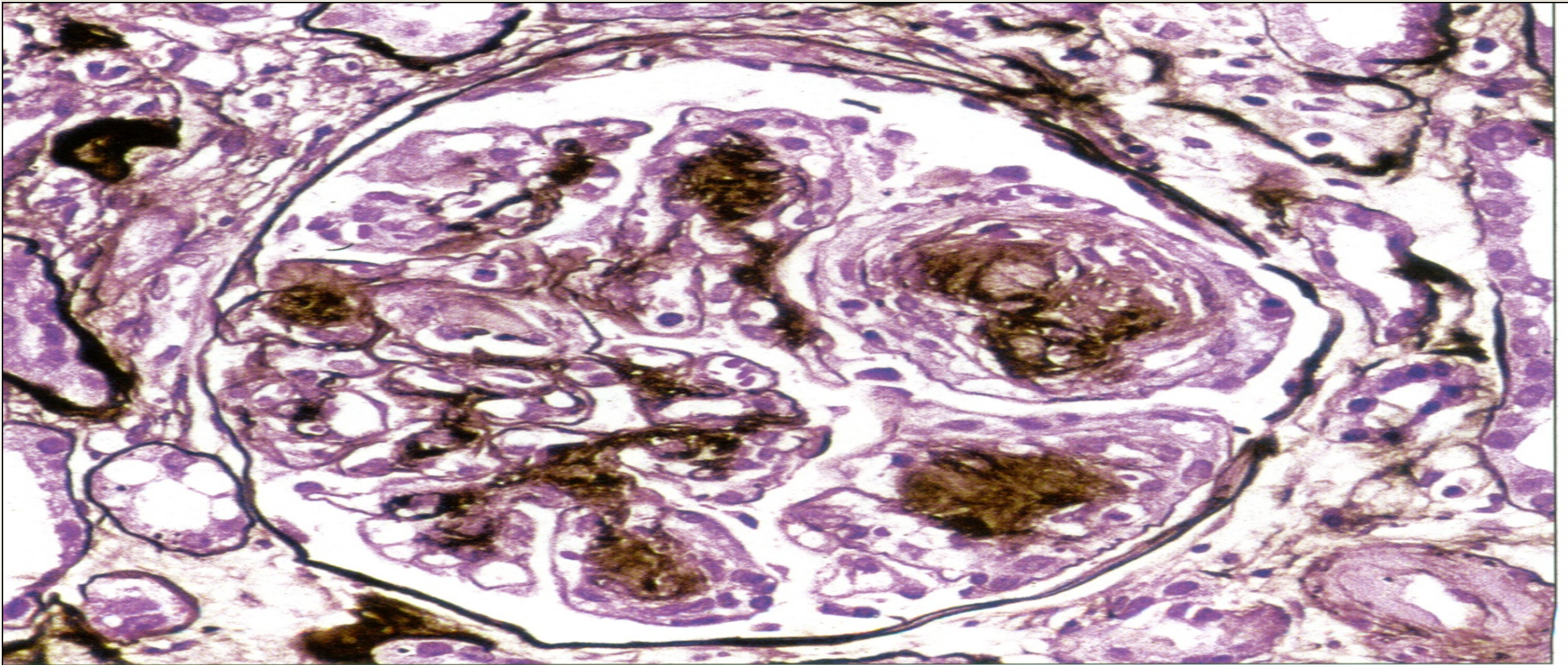


Diabetic nephropathy. Diabetic nephropathy may manifest either as diffuse mesangial increase, or with nodular glomerulosclerosis as in this case.



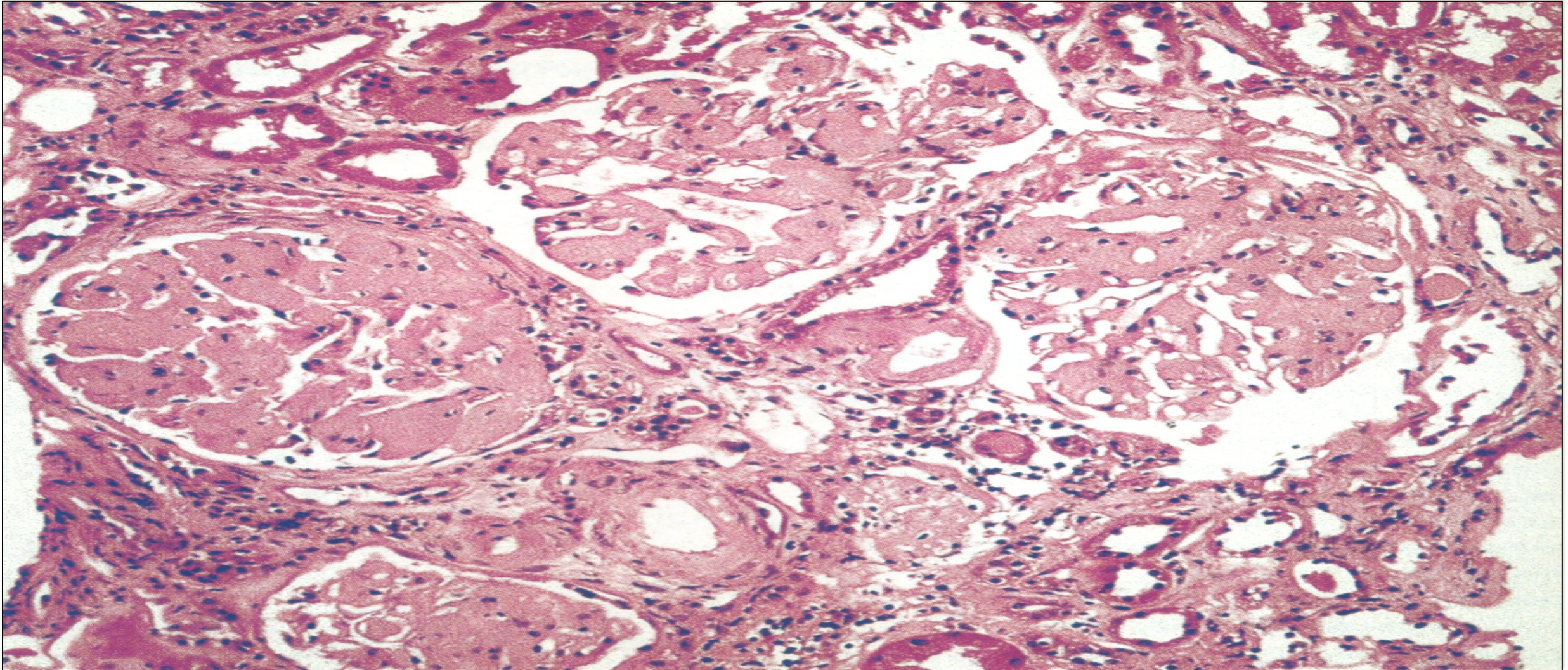


Diabetic nephropathy. The lamellated appearance of the Kimmelstiel-Wilson nodule characteristic of the nodular sclerosis form of diabetic nephropathy is shown, along with arteriolar hyalinization and surrounding tubulointerstitial fibrosis.



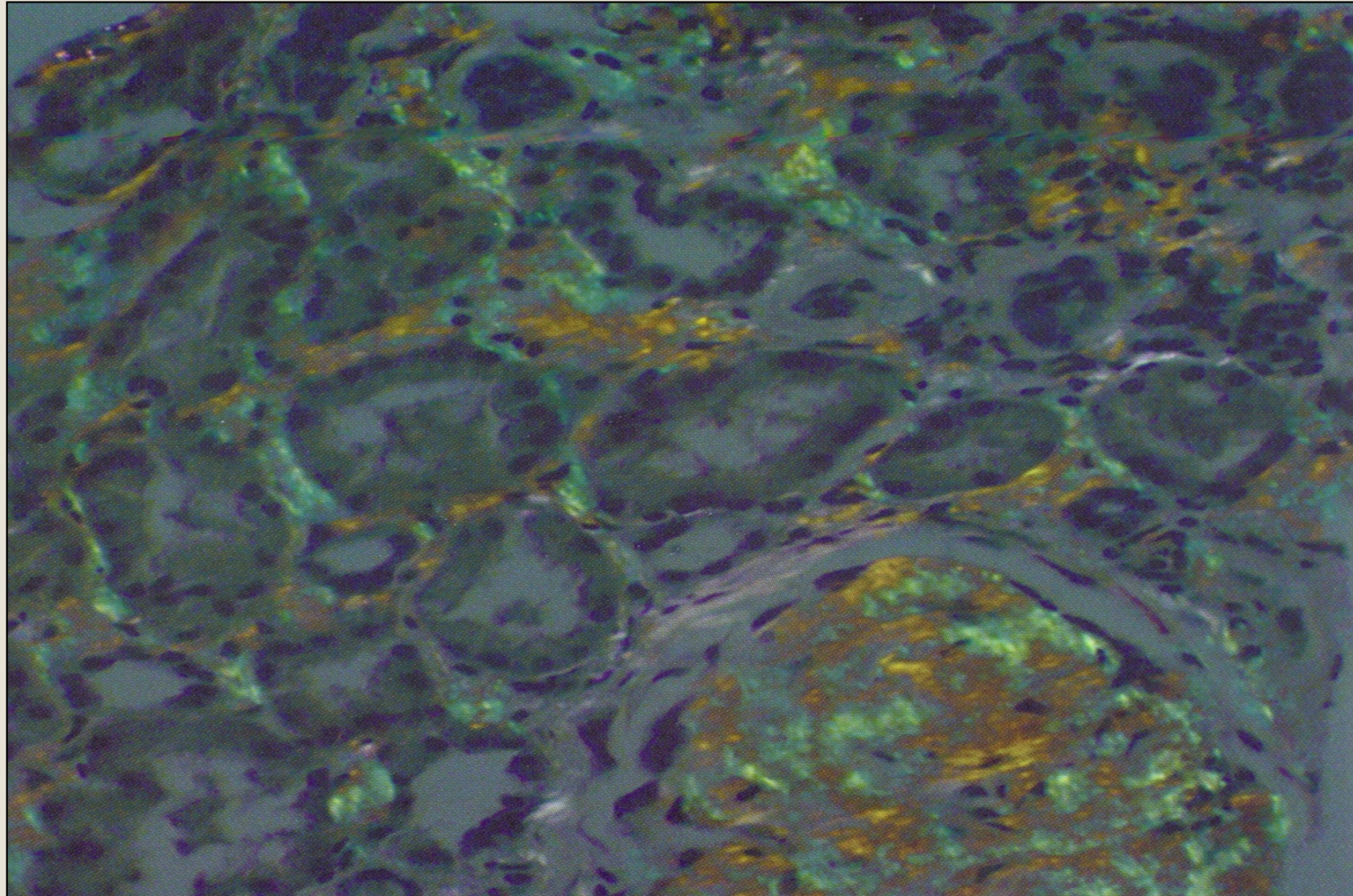


**Amyloidosis.** Massive amyloid deposits are present in glomeruli and arterioles.






**Amyloidosis.** Tubular involvement with amyloid is verified by apple-green birefringence under polarized light.

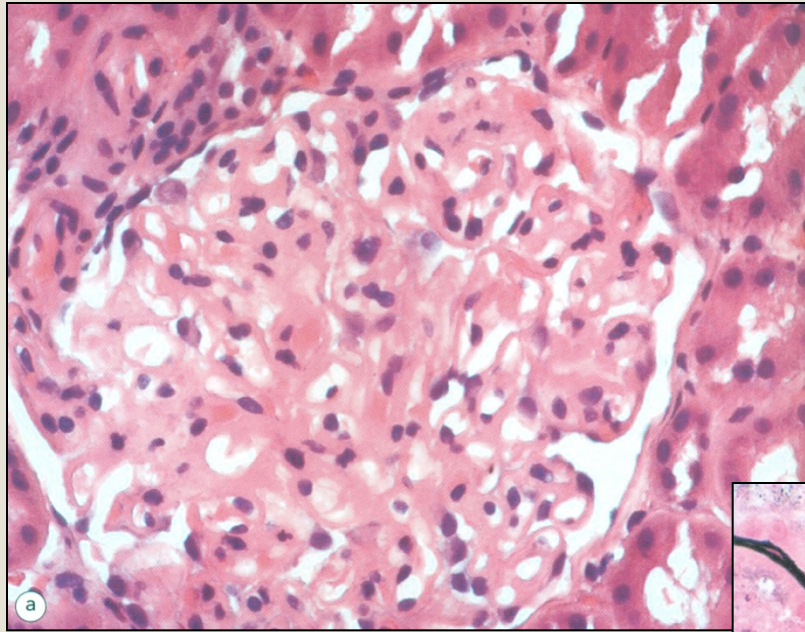




**Amyloidosis.** Randomly oriented, 8-10nm fibrils, typical of amyloid within the mesangium.



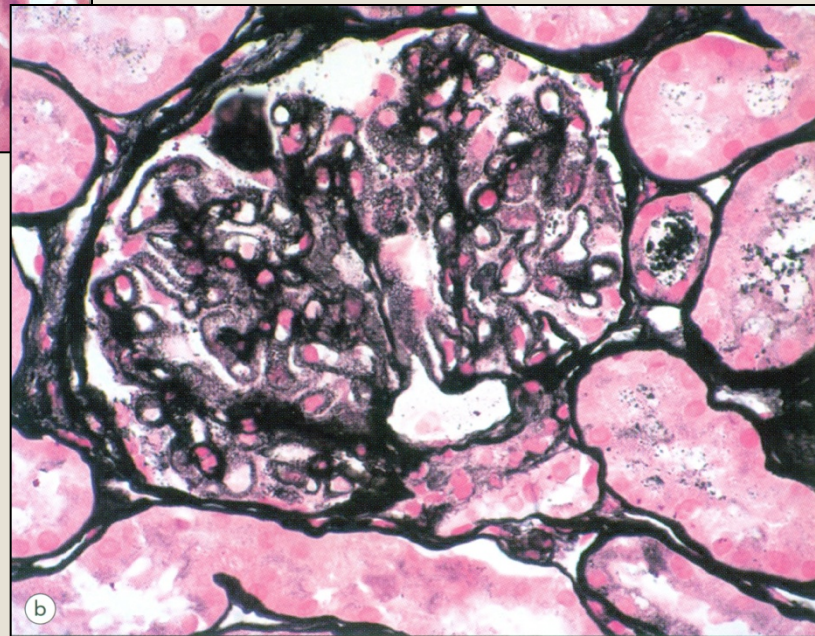



## Lupus nephritis.

(a) Class V lesion or lupus membranous glomerulopathy. There is diffuse thickening of the peripheral capillary walls associated with an increase in mesangial matrix.

(b) Silver methenamine (Jones) stains reveal a spike and dome pattern to be present along the peripheral capillary loops where the wall of the capillaries cut tangentially; there is a moth-eaten appearance of the capillary wall.



# Clinical Syndromes

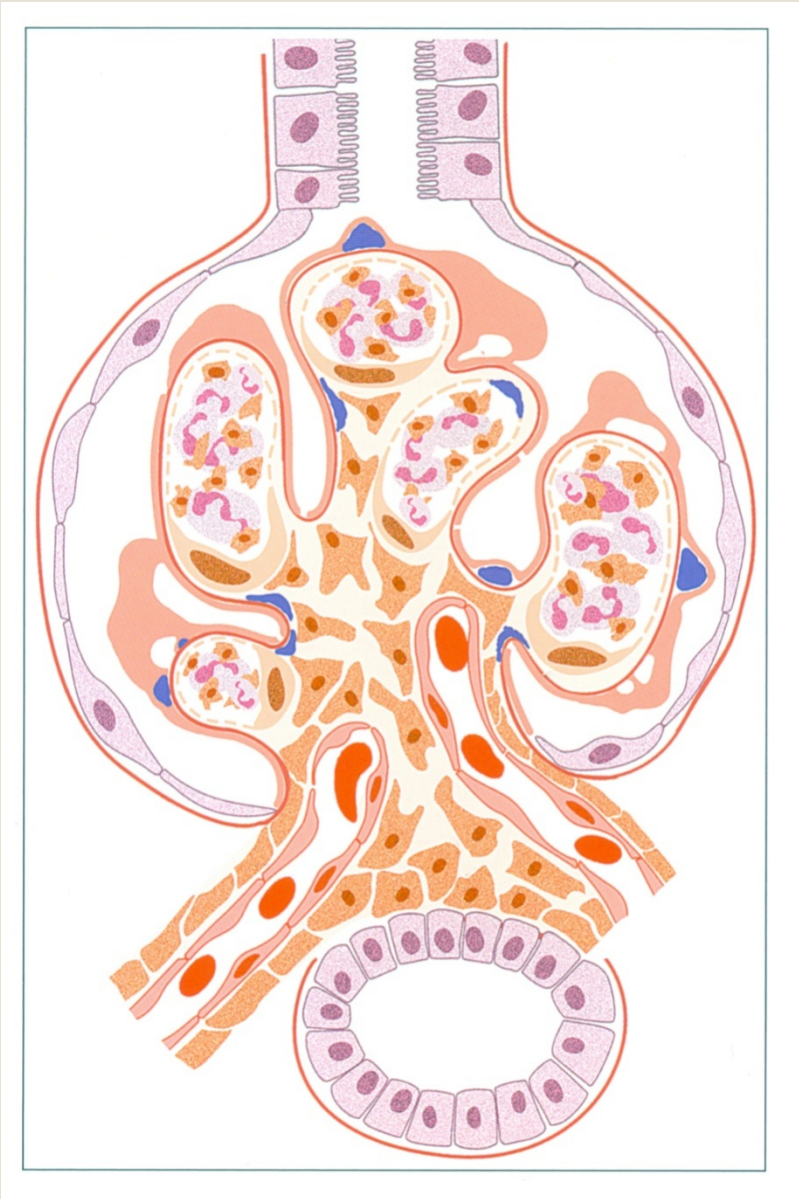
**2. Nephritic syndrome = grossly visible hematuria = red blood cells in urine = red blood cell casts, edema, hypertension, abnormal renal function .**



Lecture - 3 and 4  
Part 2

(continued- **Nephritic Syndrome**)



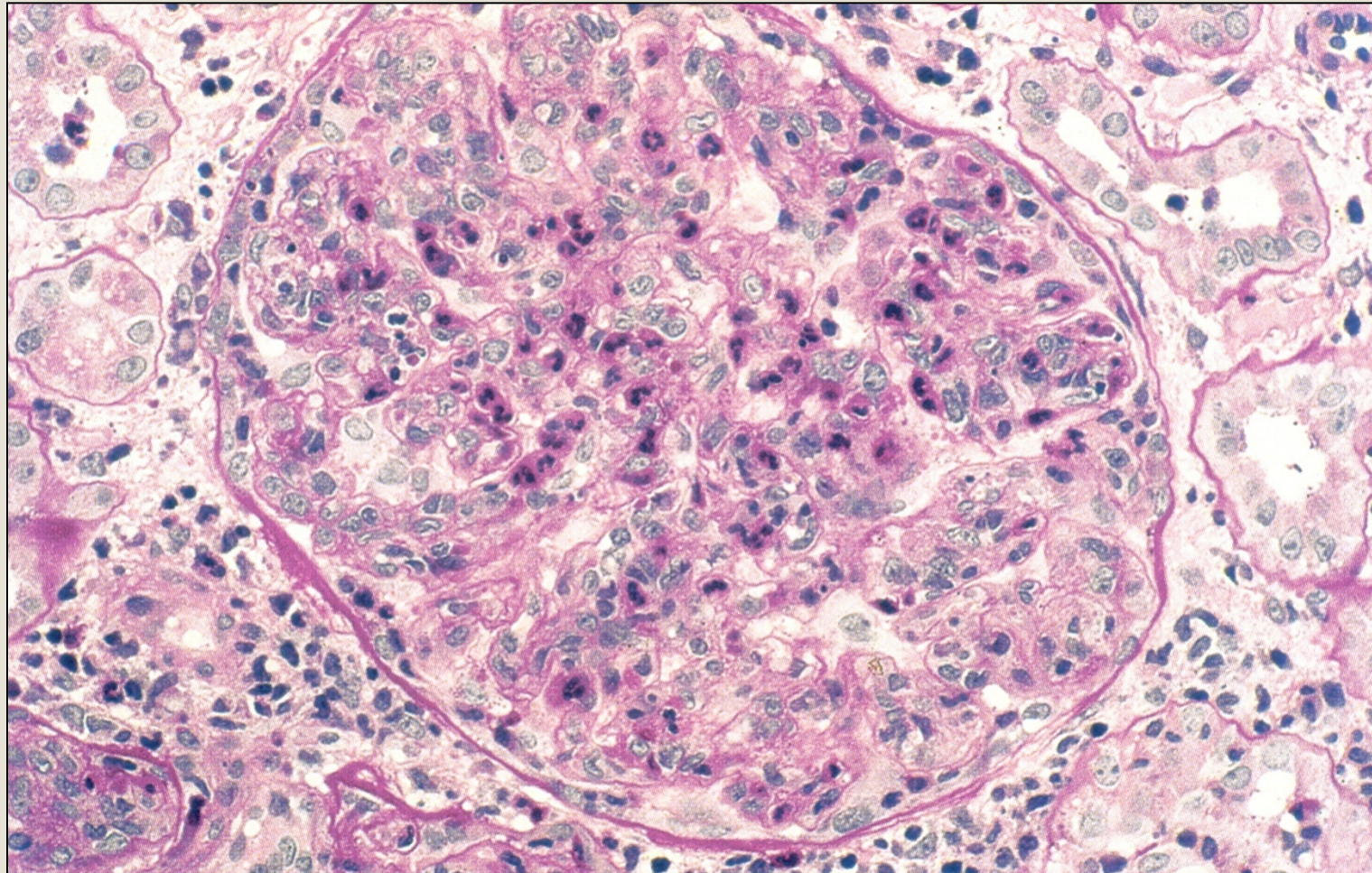


## Acute post-infectious glomerulonephritis.

There is an exudative proliferation with numerous PMNs and endocapillary proliferation, with scattered mesangial and large hump-shaped sub-epithelial deposits.

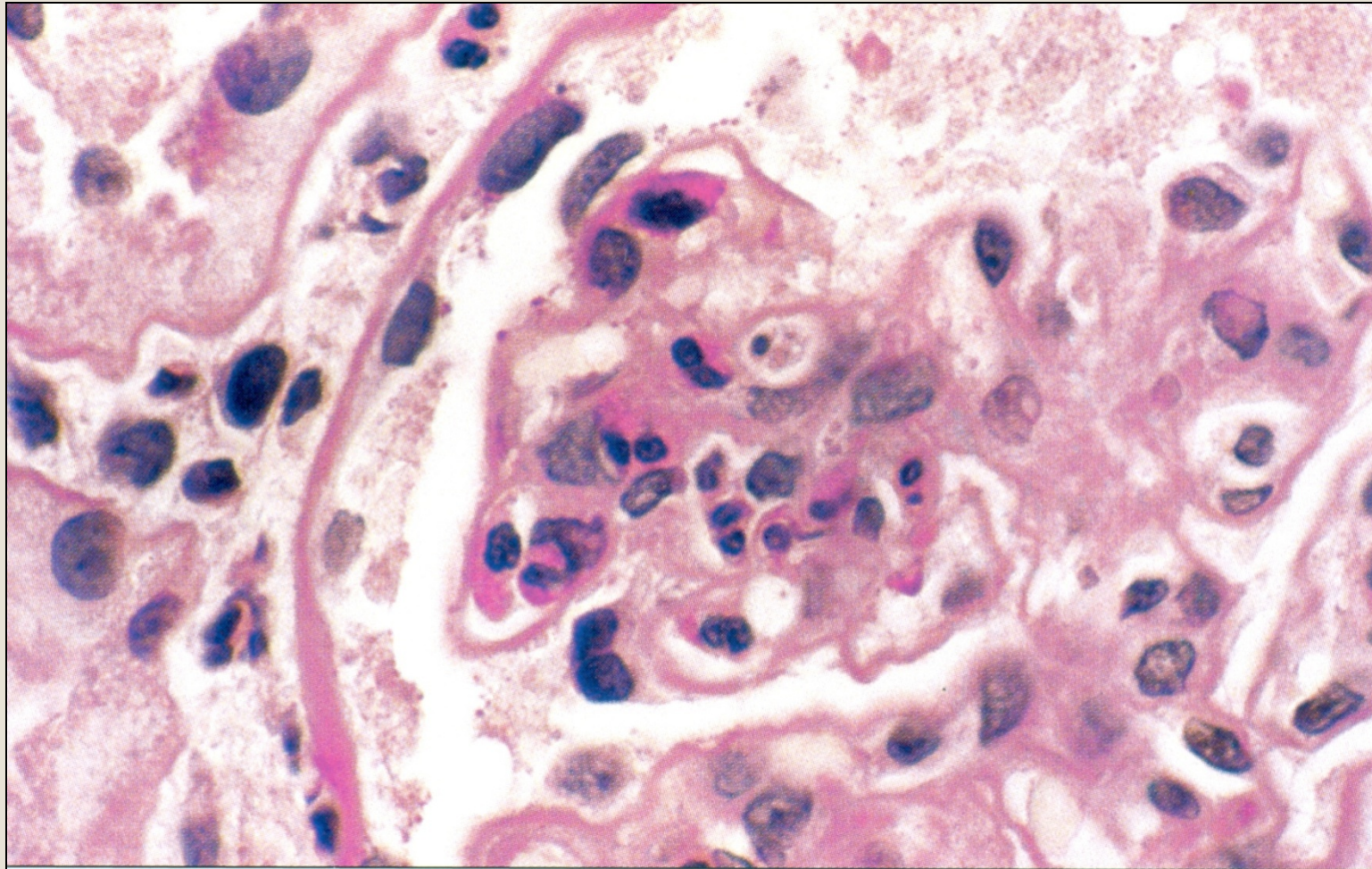


Acute post-infectious glomerulonephritis. There is diffuse, global exudative proliferation with prominent endocapillary proliferation and numerous neutrophils.



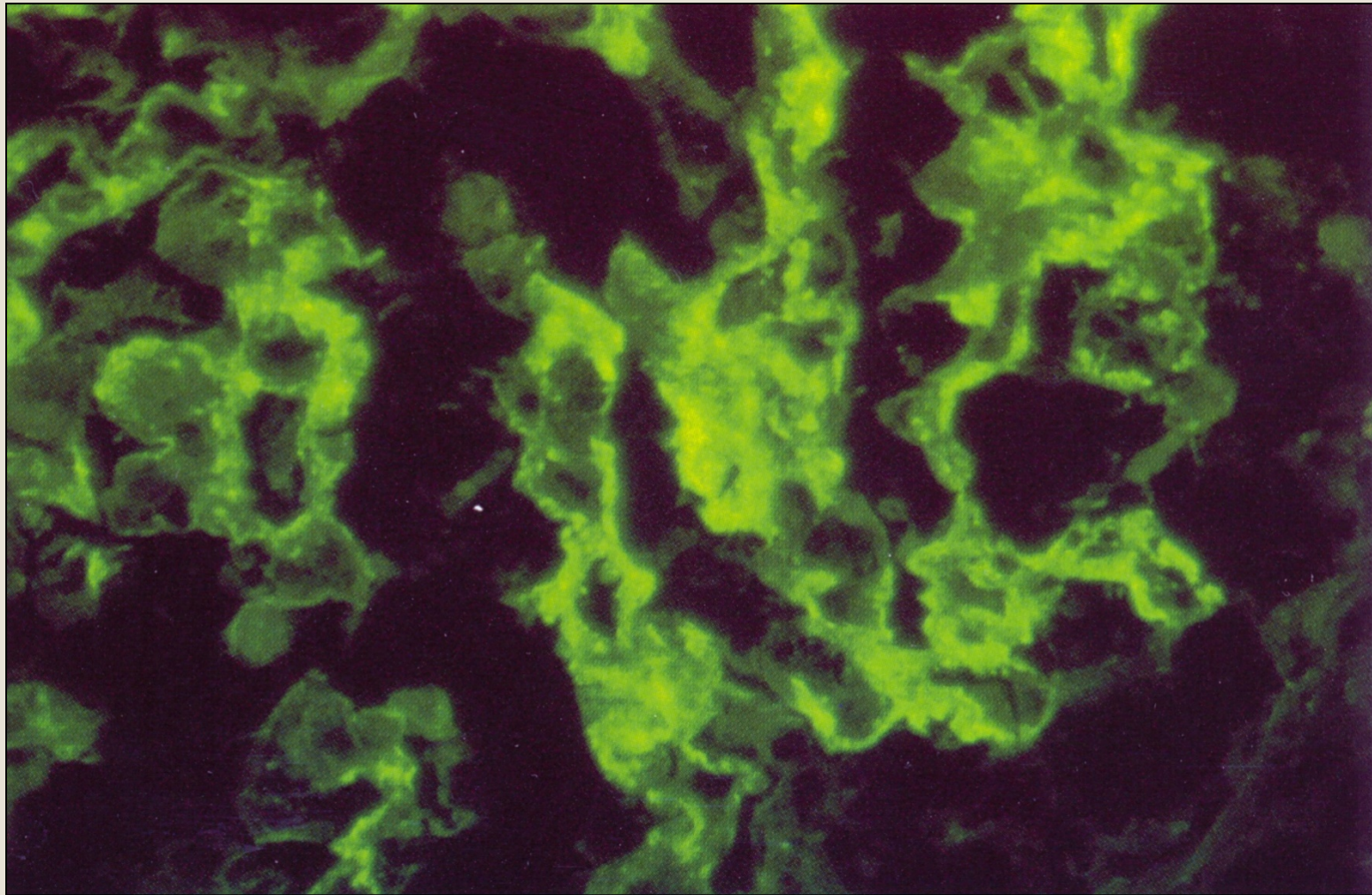


Acute post-infectious glomerulonephritis. Endocapillary proliferation and numerous PMNs both within capillary loops and within the mesangial area are present.





Acute post-infectious glomerulonephritis. A more extensive garland pattern with elongated peripheral loop deposits is illustrated, along with occasional small mesangial deposits.





## Clinical Syndromes

**4. Rapidly progressive GN = rapid deterioration of renal function**



# CRESCENTIC GLOMERULONEPHRITIS

Idiopathic or primary crescentic glomerulonephritis:

Type I, anti-GBM disease

Type II, immune complex-mediated

Type III, pauci immune (ANCA-associated)

Vasculitides (ANCA-associated):

microscopic form of polyarteritis nodosa,

Wegener's granulomatosis

Churg-Strauss syndrome

Drug-induced vasculitides

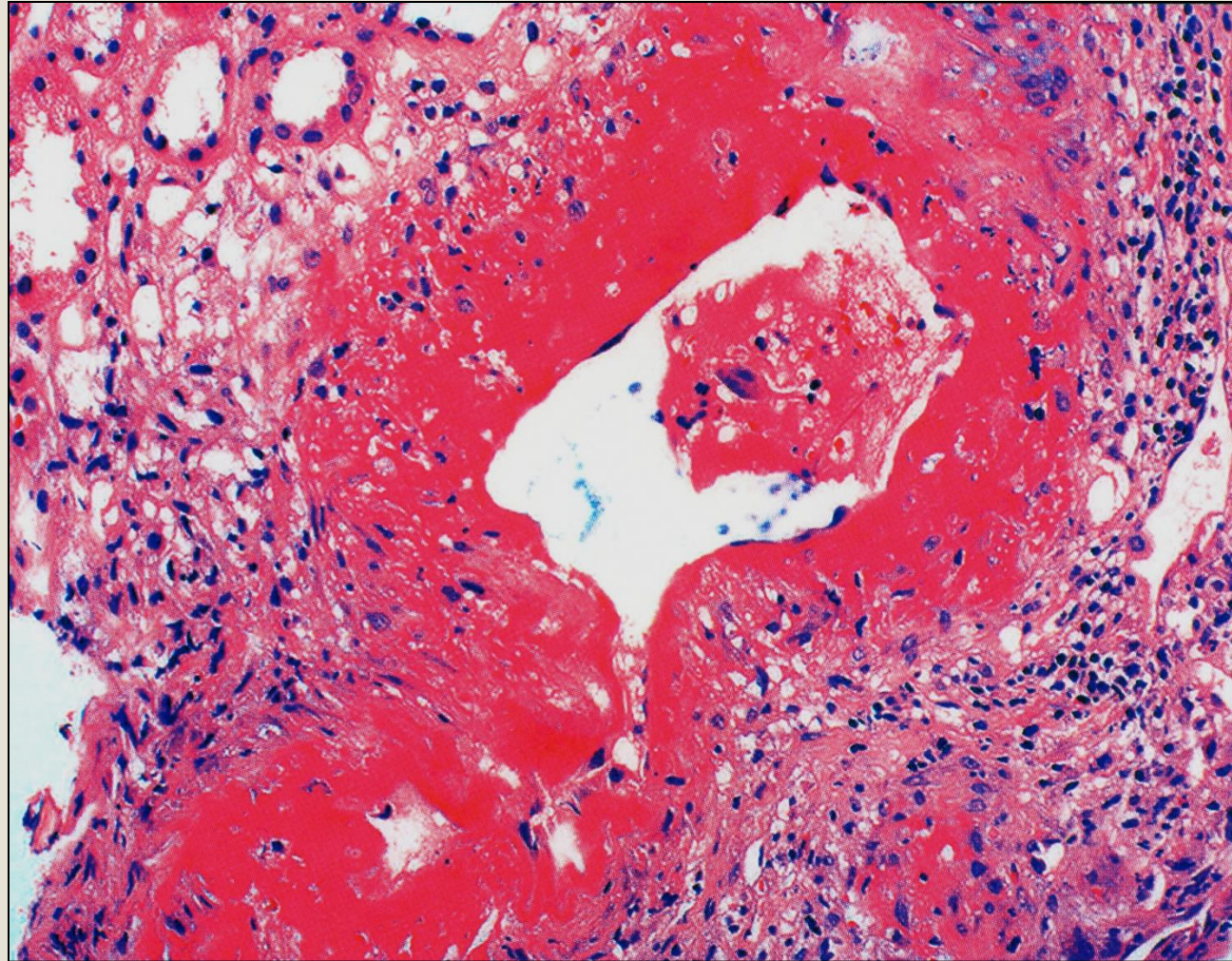
Other primary glomerulonephritides:

post-infectious GN, IgA nephropathy, MPGN, etc.

Systemic diseases (SLE, RA, H-S purpura)

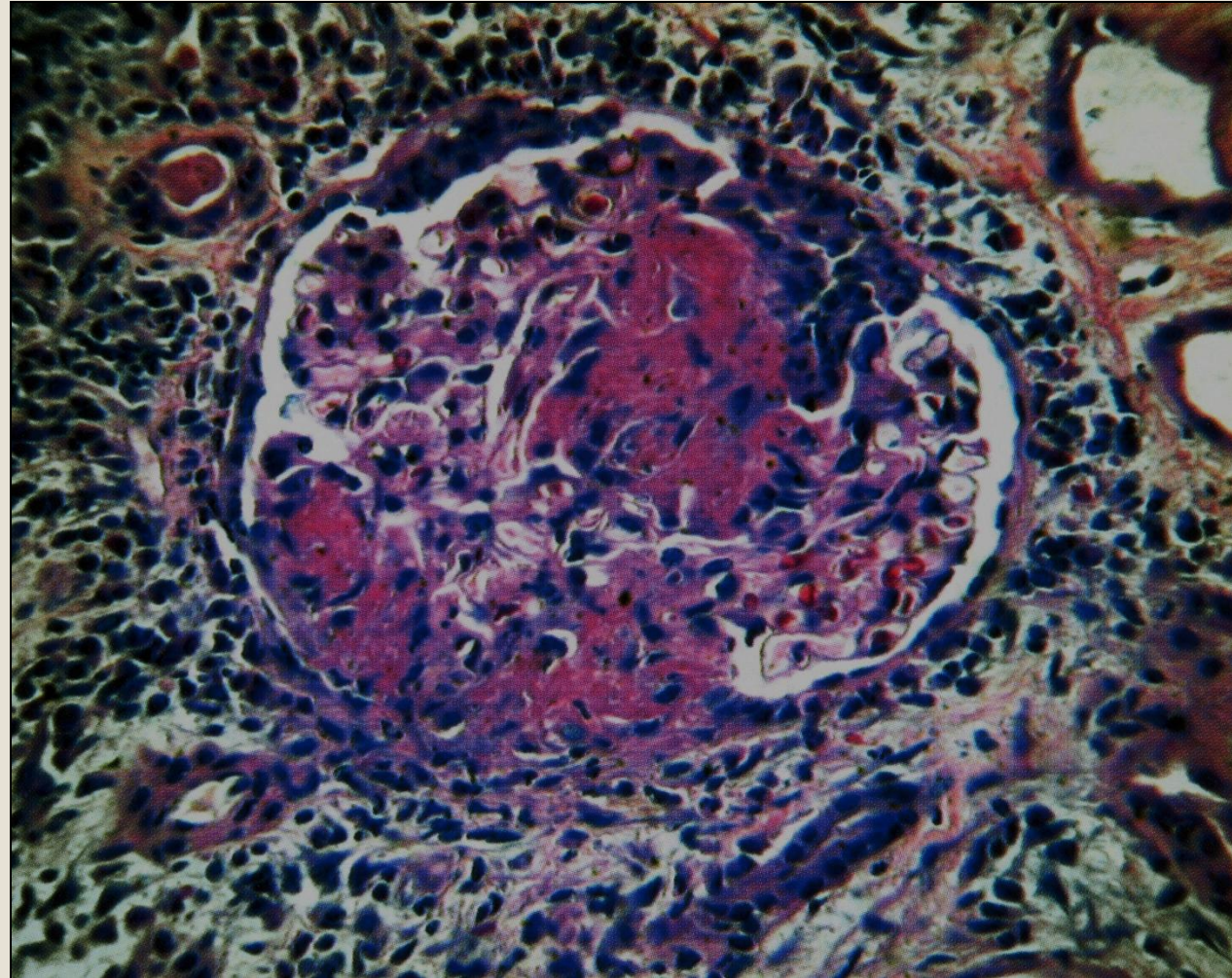


**Wegener's granulomatosis / microscopic polyangiitis.** Vessel with transmural necrosis involving the vessels circumferentially with a significant inflammatory infiltrate with mixed polymorphonuclear leukocytes and mononuclear cells.

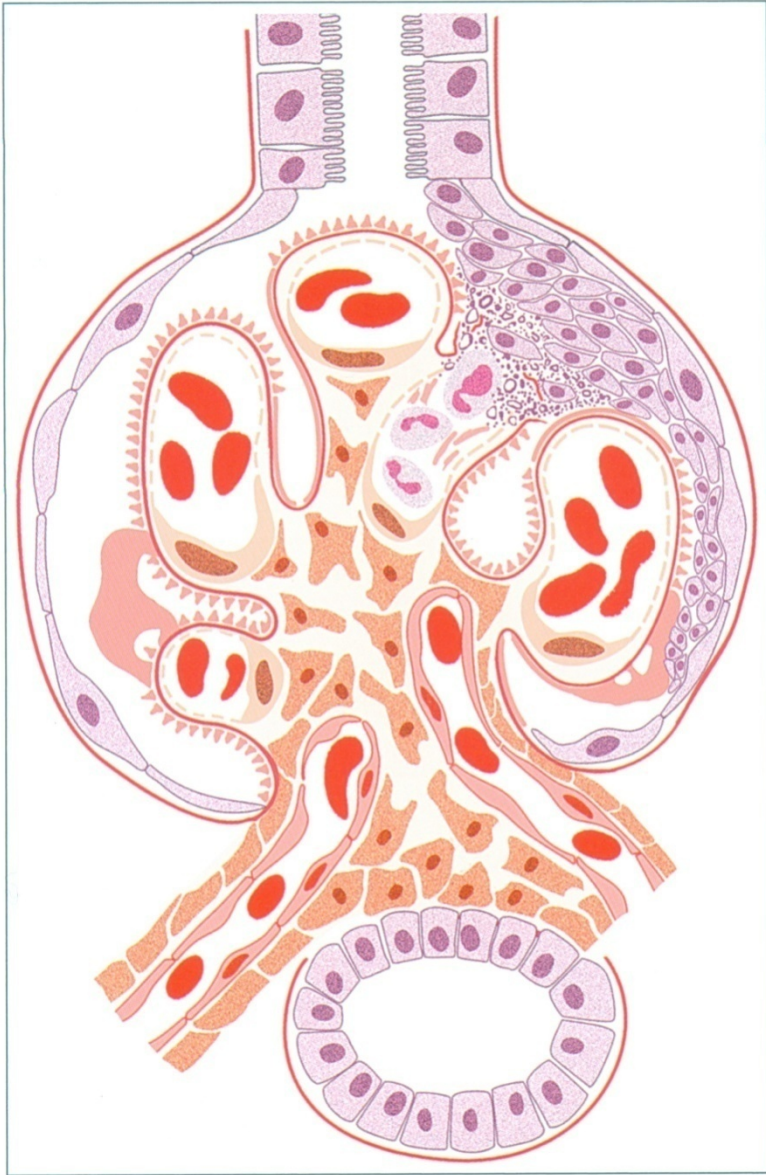



**Wegener's granulomatosis / microscopic polyangiitis.** Glomerulus demonstrating focal and segmental necrosis with adhesion to Bowman's capsule and proliferation of parietal epithelium.



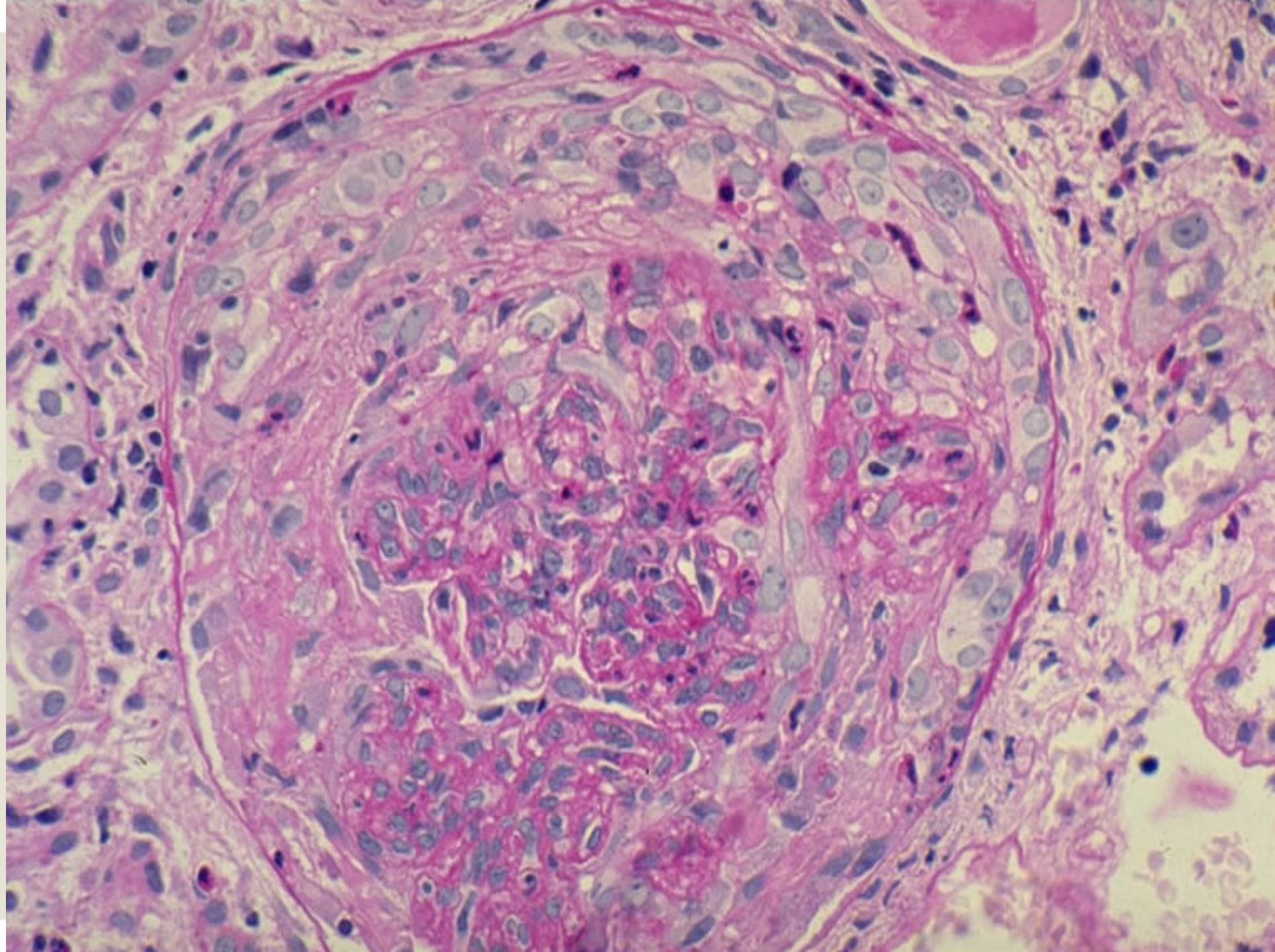




Anti-GBM-antibody mediated glomerulonephritis (Goodpasture's Syndrome).

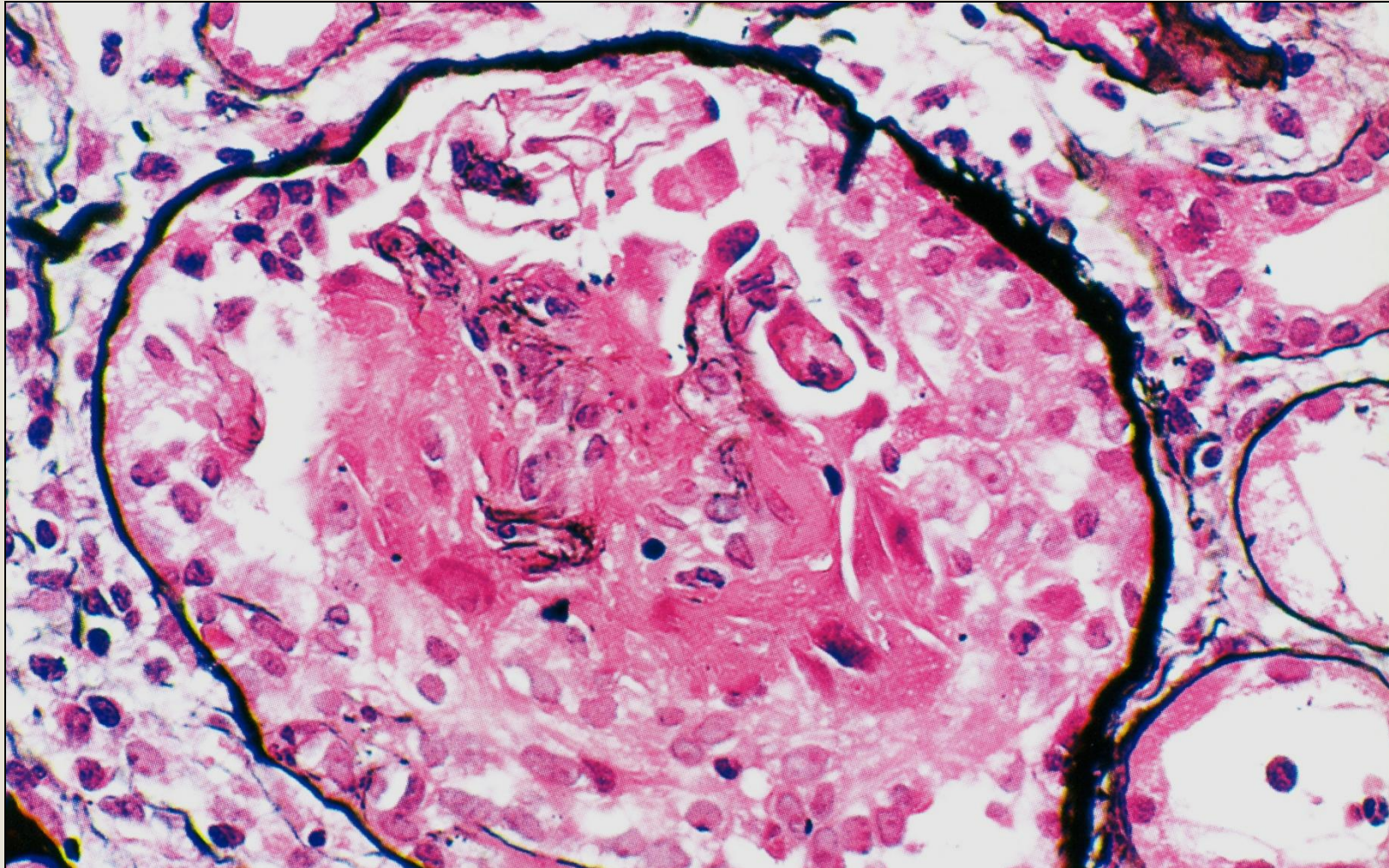
There is segmental necrosis with a break of the glomerular basement membrane, and fibrinoid necrosis and PMNs in the area, with a cellular crescent developing in response to this GBM break.





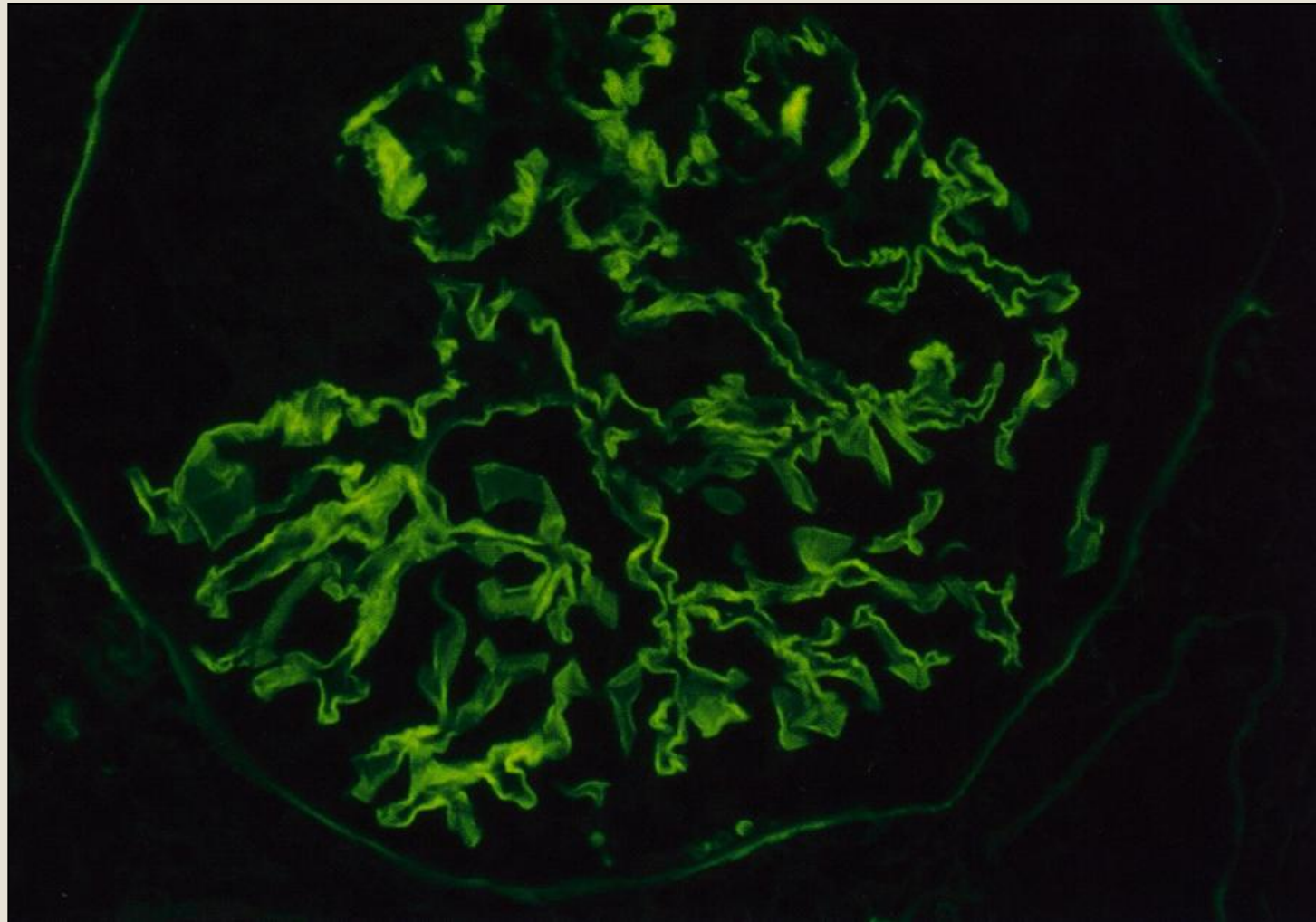


**Anti-GBM antibody-mediated glomerulonephritis** with karyorrhexis and ruptured fragments of GBM, with a small remaining intact portion of the glomerulus at the top.

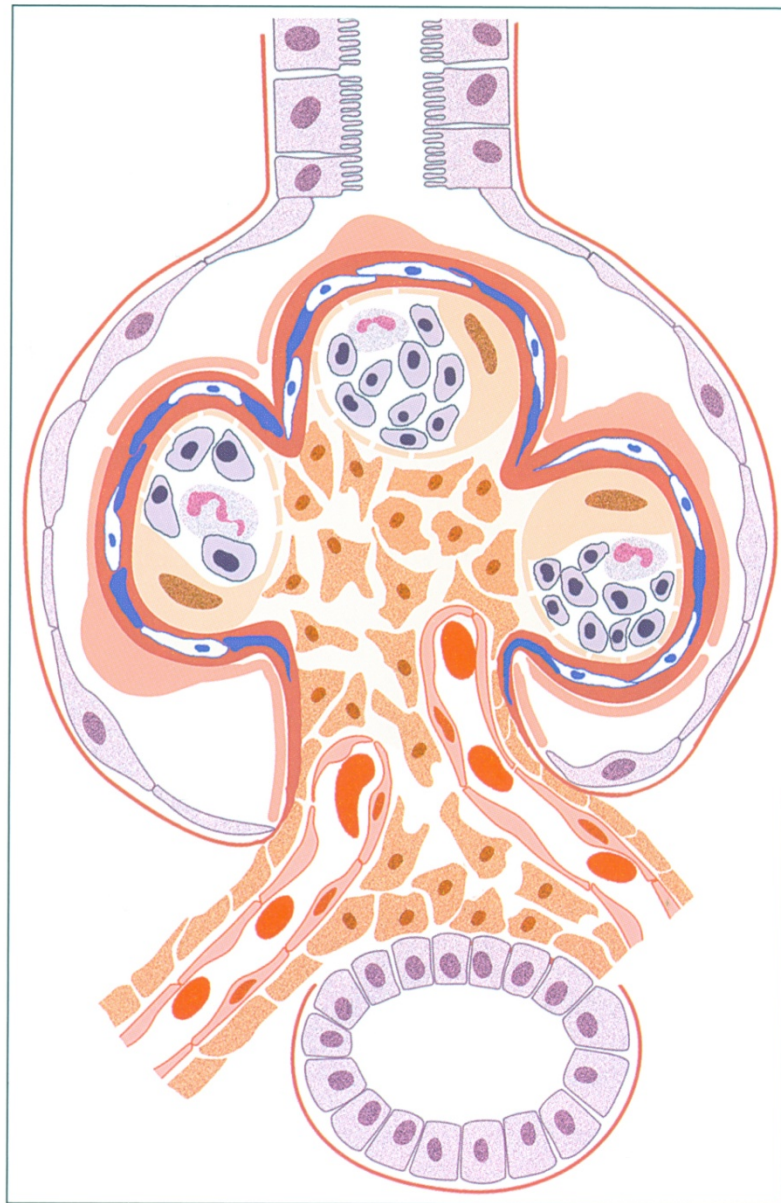




**Anti-GBM antibody-mediated glomerulonephritis.** Linear glomerular basement membrane staining with IgG is diagnostic of this disease in this setting.



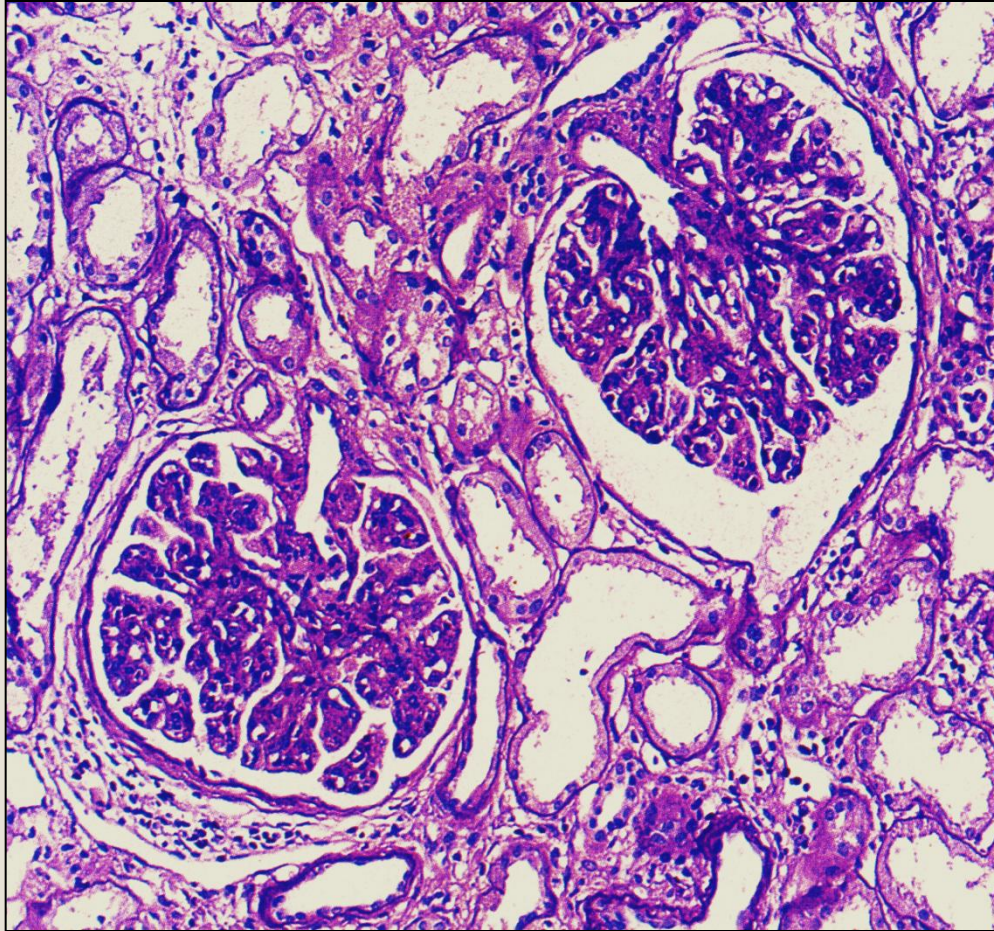




## Membranoproliferative glomerulonephritis

There is endocapillary proliferation and glomerular basement membrane splitting, due to mesangial and subendothelial deposits, with resultant interposition and new basement membrane being laid down, causing the split appearance.

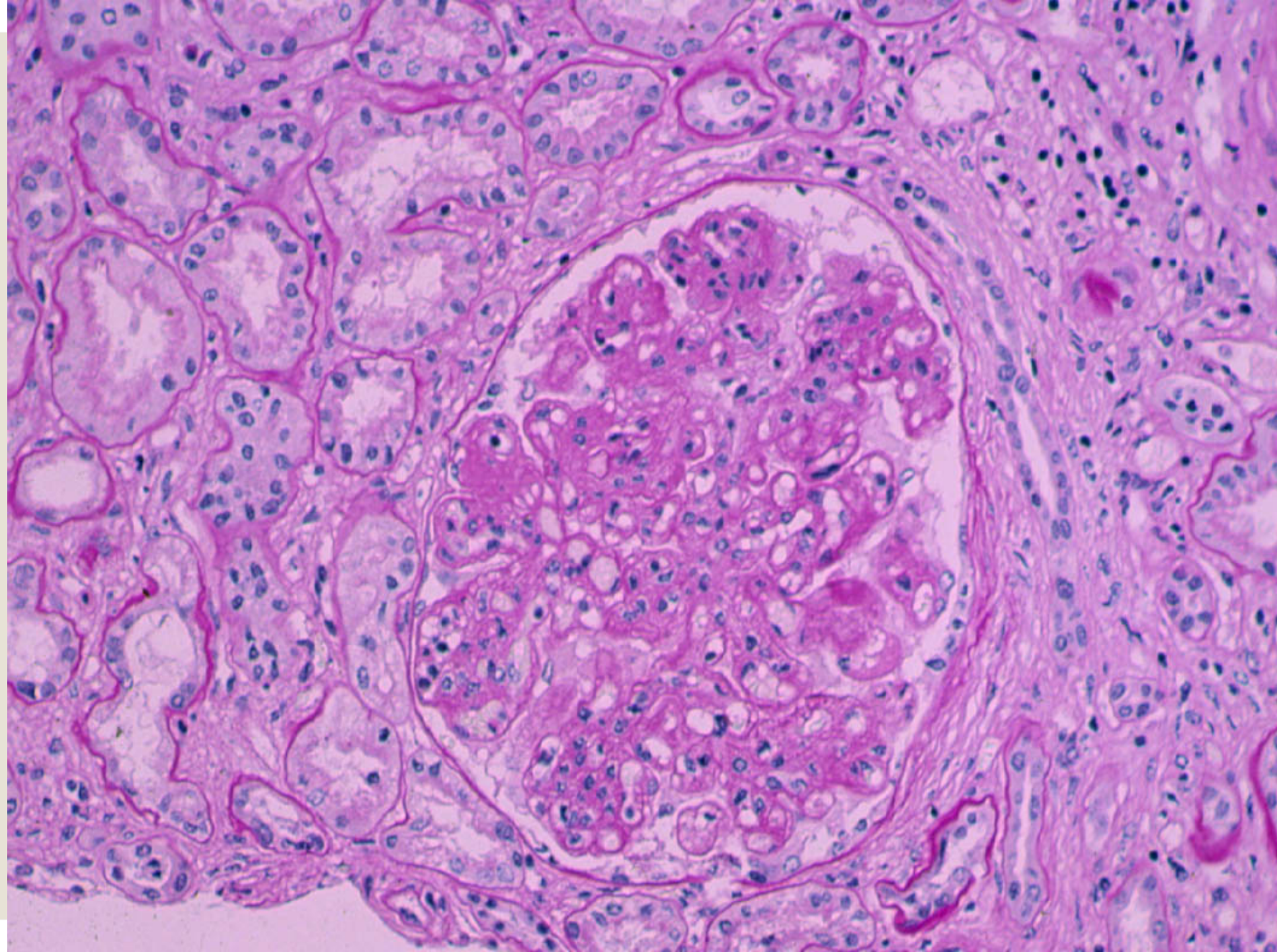




**MPGN type I.**

MPGN is characterized by diffuse endocapillary proliferation, which results in a lobular, uniform appearance of glomeruli.

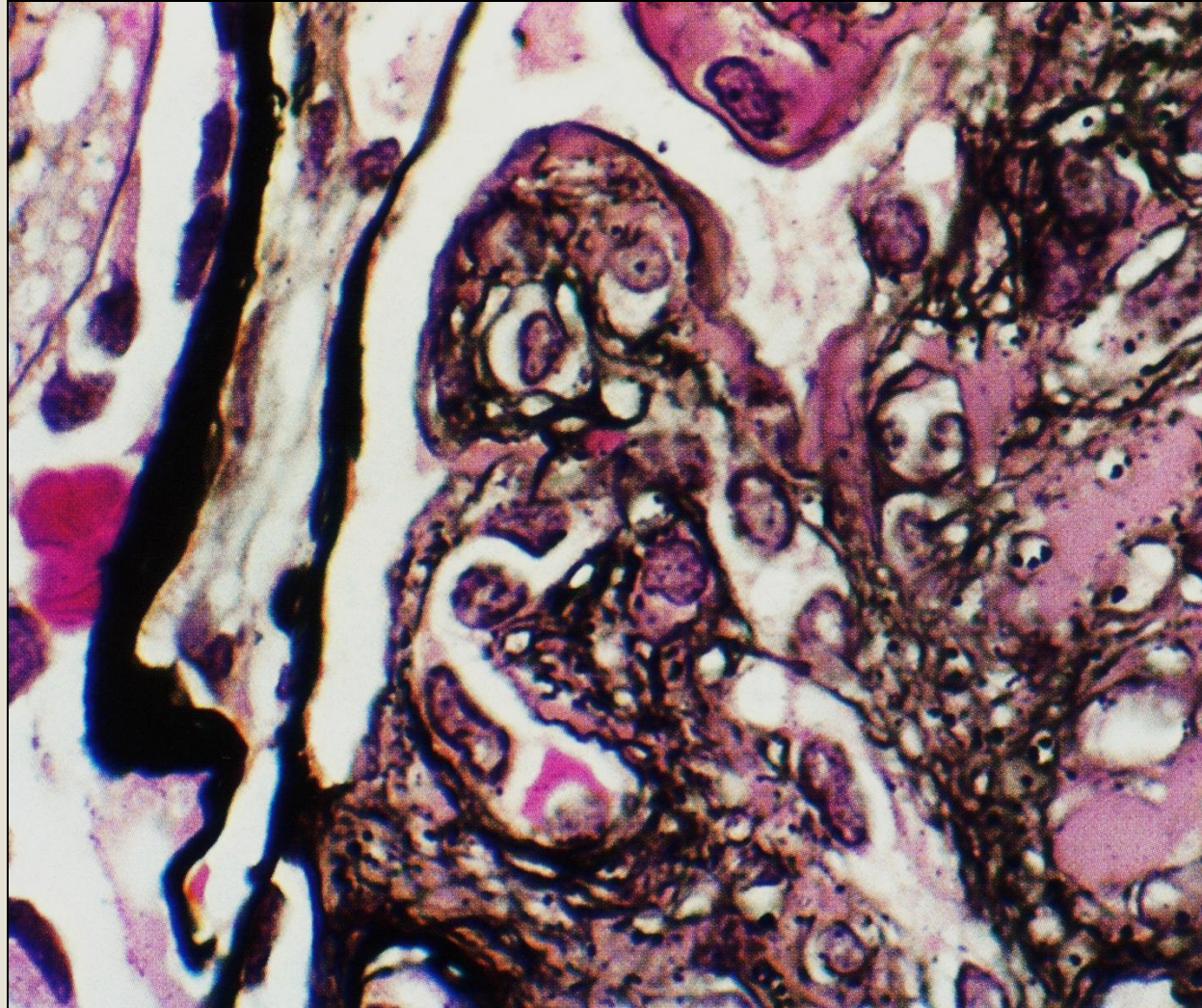






**MPGN type I.**

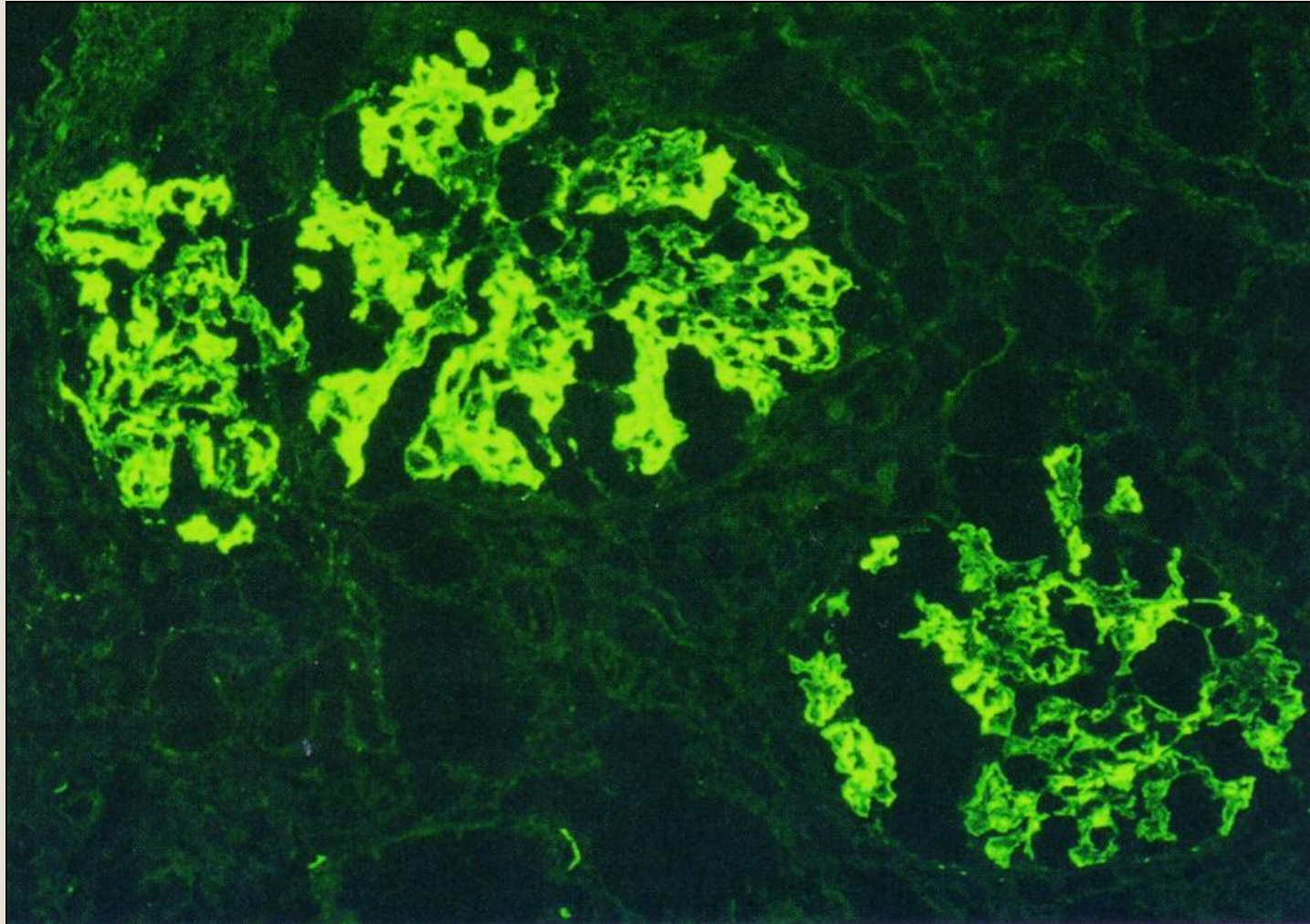
There is segmental interposition of cells which splitting of peripheral capillary GBM along with subendothelial deposits.



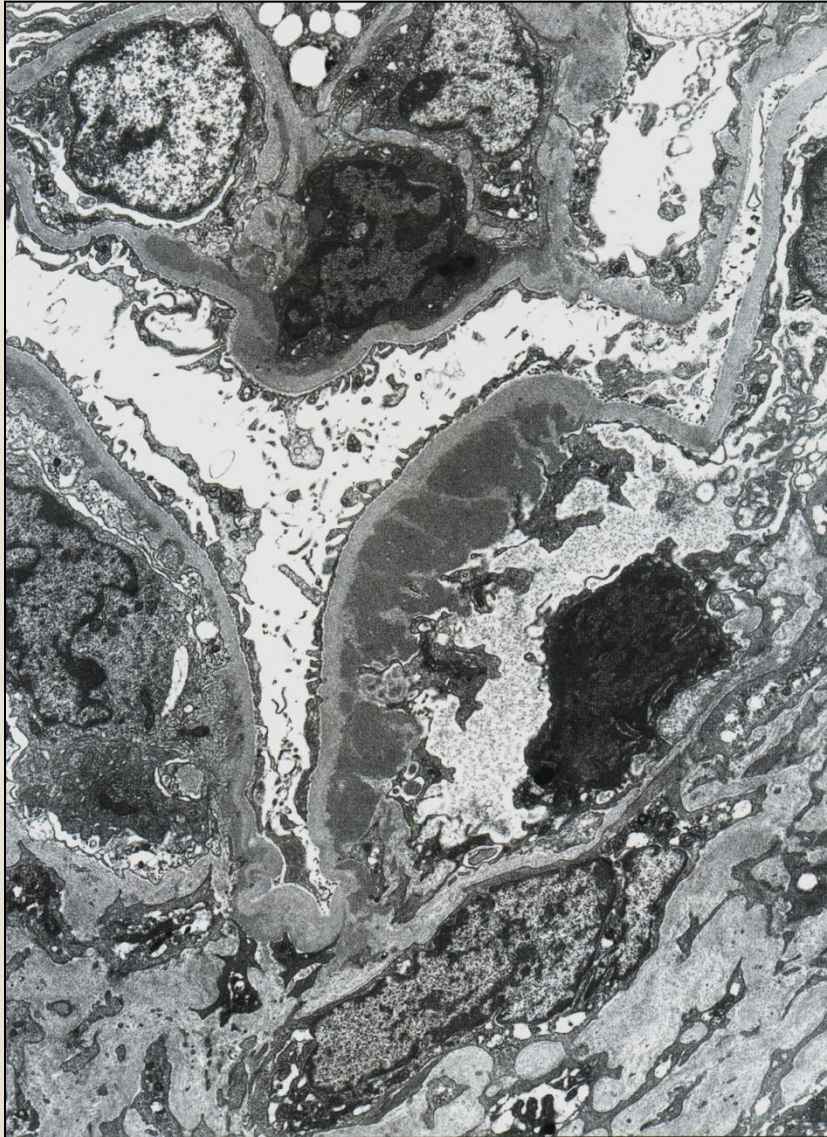


**MPGN type I.**

in addition to IgG, there is often very prominent complement deposition in MPGN with prominent mesangial and coarse, chunky peripheral loop deposits, corresponding to the subendothelial deposits.



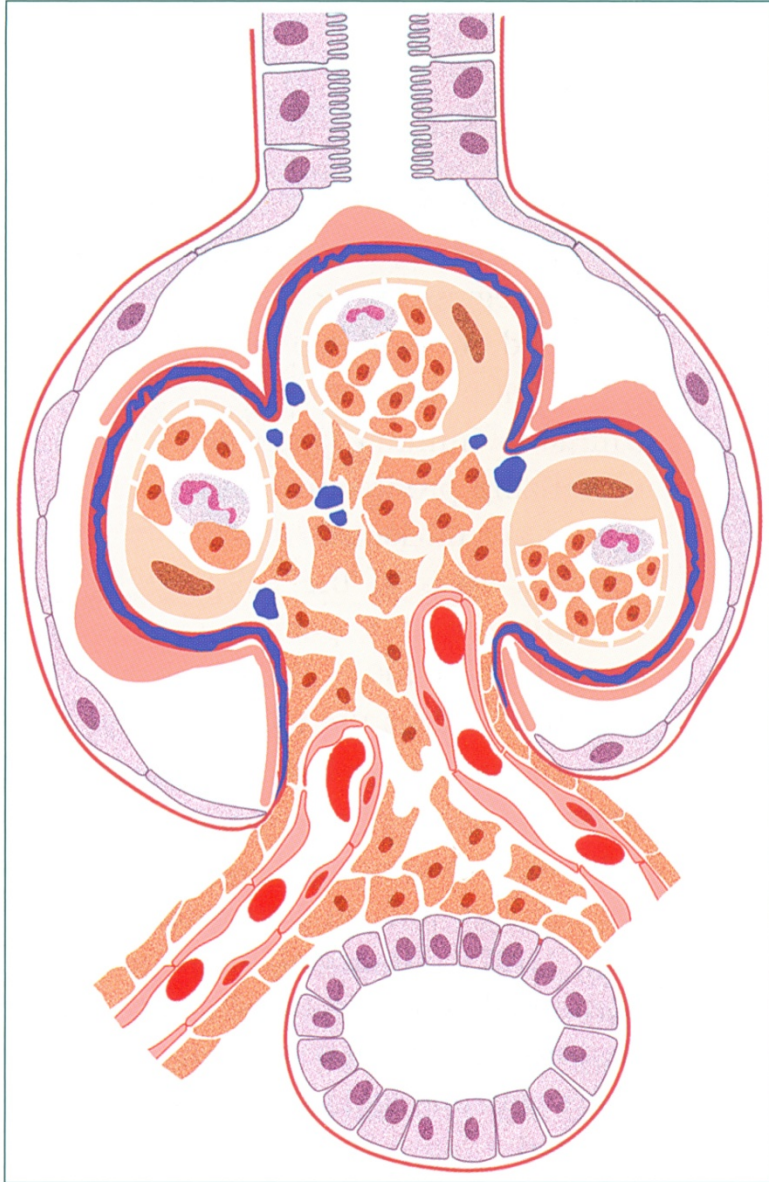




### **MPGN type I**

There are massive subendothelial deposits in the right loop, with minimal endocapillary proliferation, and small, silver-like deposits on the left and top loops, with associated proliferation.





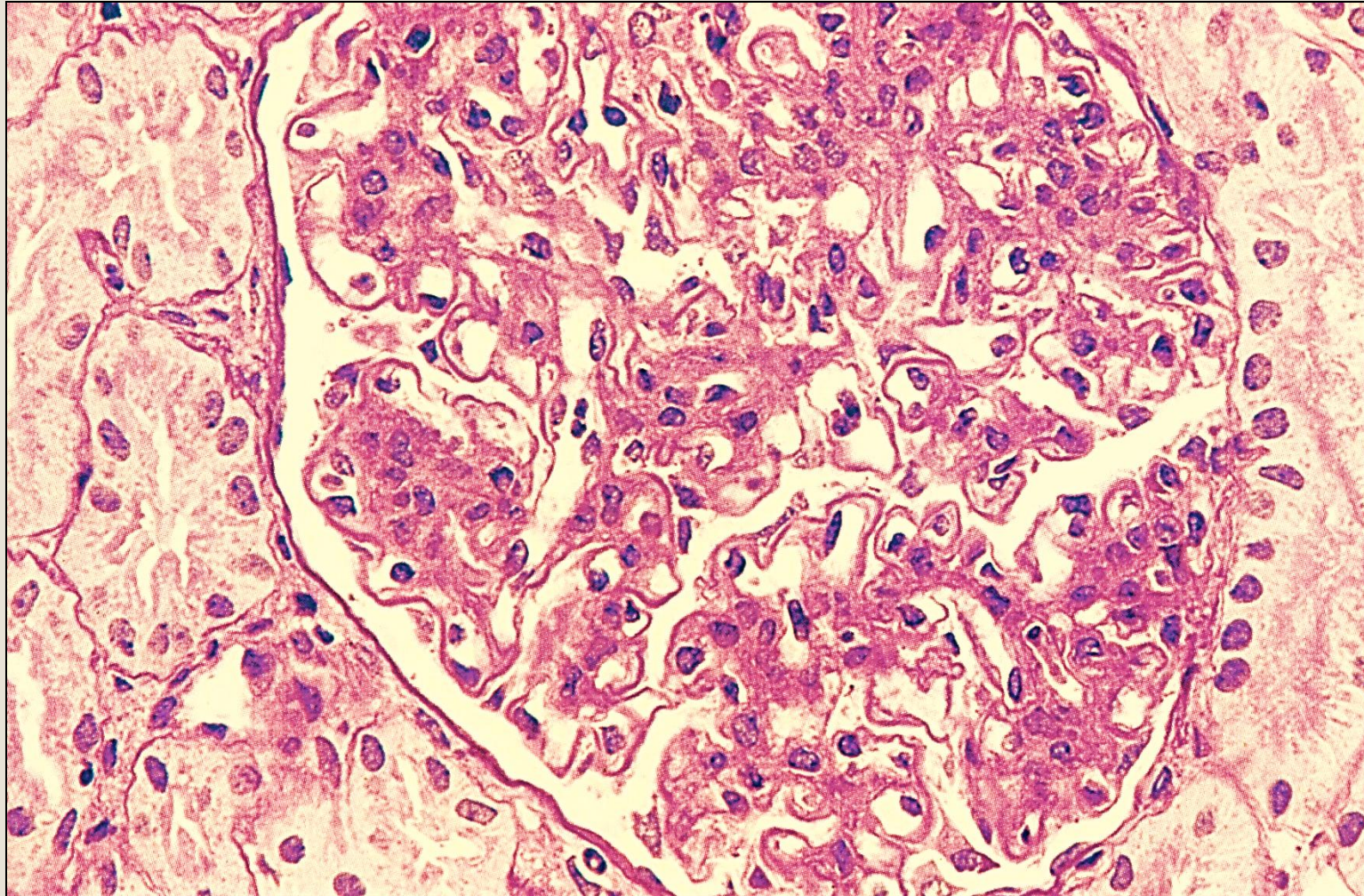
## Dense deposit disease (DDD).

The glomerulus shows a membranoproliferative pattern, with endocapillary proliferation and GBM splitting

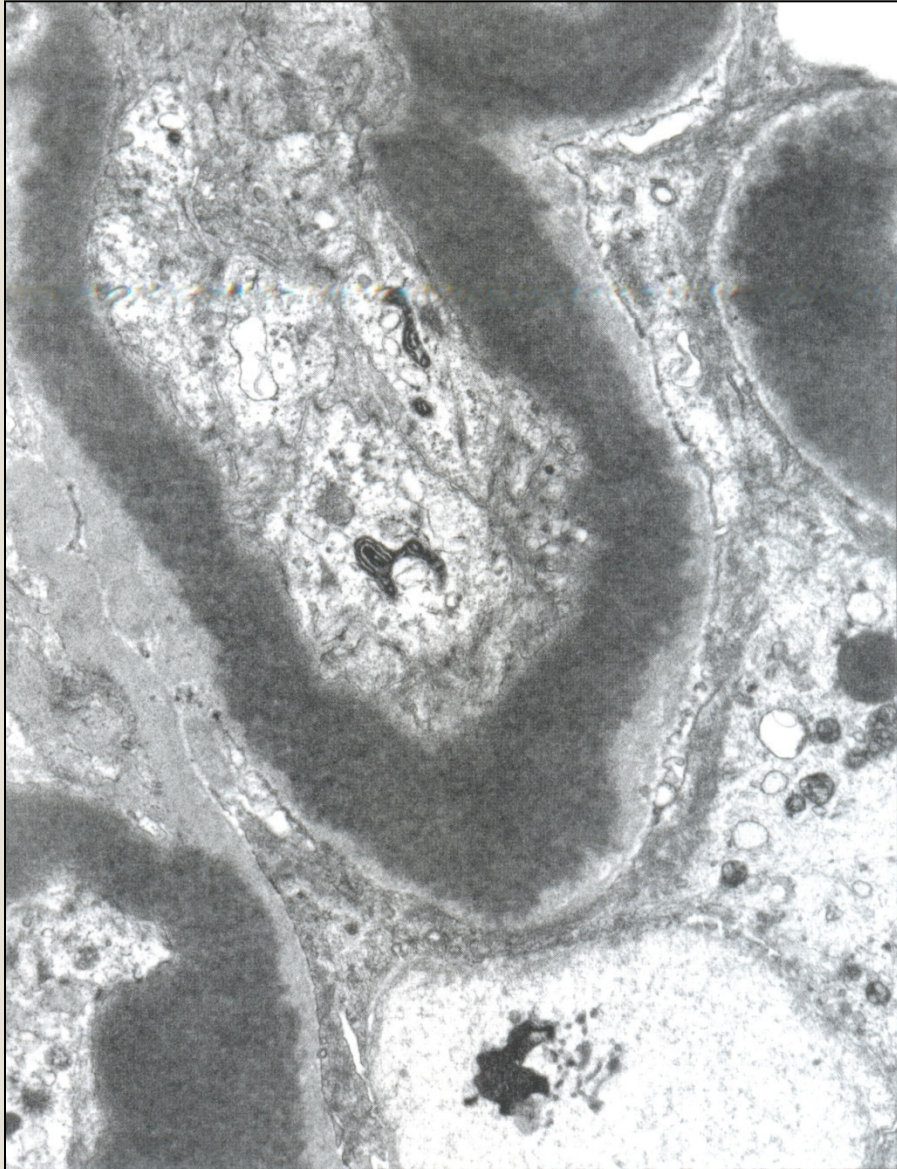


### **DDD**

Dense deposit disease has membranoproliferative features by light microscopy, with diffuse, global mesangial and often endocapillary proliferation, and frequent glomerular basement membrane splitting.







**DDD.**

There is dense transformation of nearly the entire thickness of the glomerular basement membrane, with associated endocapillary proliferation.



# Clinical Syndromes

**3. Asymptomatic hematuria/proteinuria = microscopic hematuria with red cell casts; proteinuria usually <1 gram/24 hours; normal renal function**

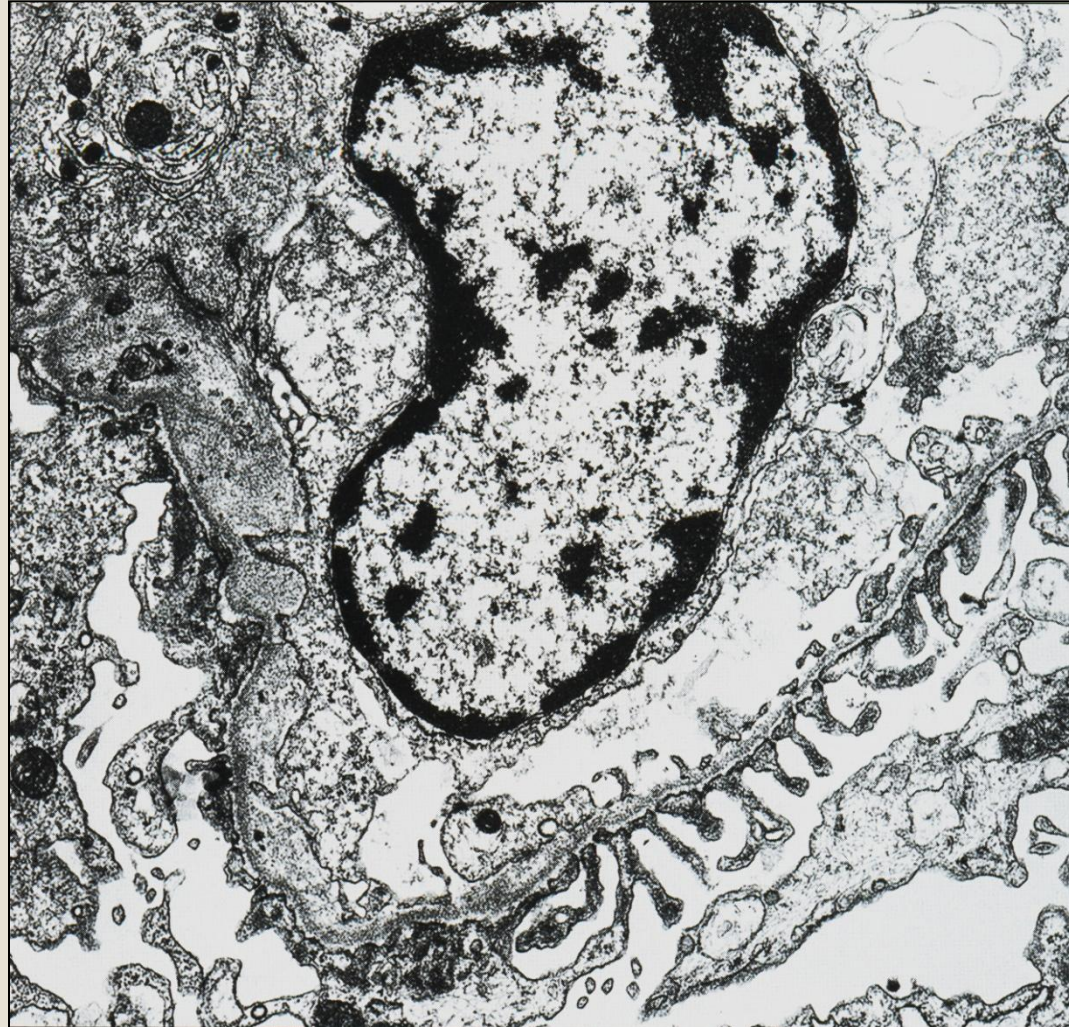


# ASYMPTOMATIC HEMATURIA/PROTEINURIA

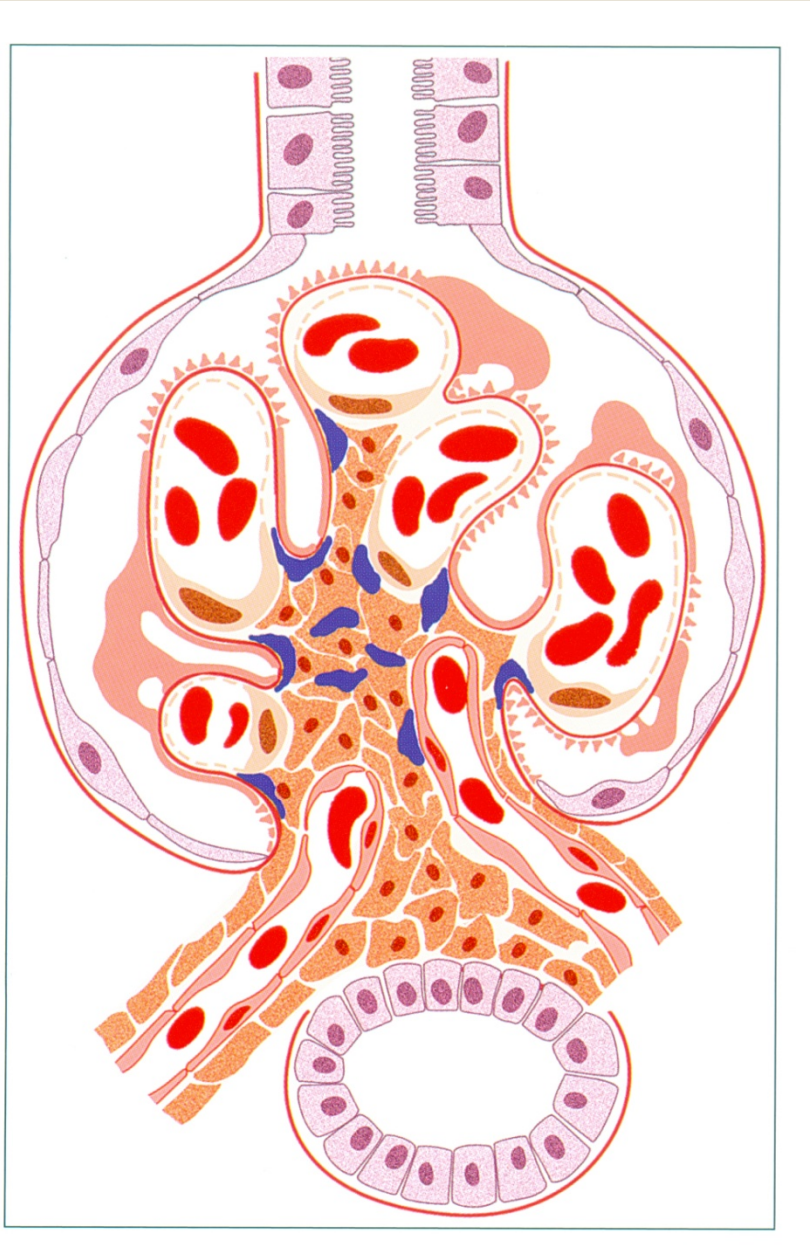
These conditions are characterized morphologically either by focal necrotizing and/or inflammatory lesions of the glomeruli or by basement membrane anomalies that result in greater capillary fragility.



**Alport syndrome.** Alternating areas of extreme thinning of the glomerular basement membrane (~120 nm) with thick, irregular areas with basket weaving are shown.



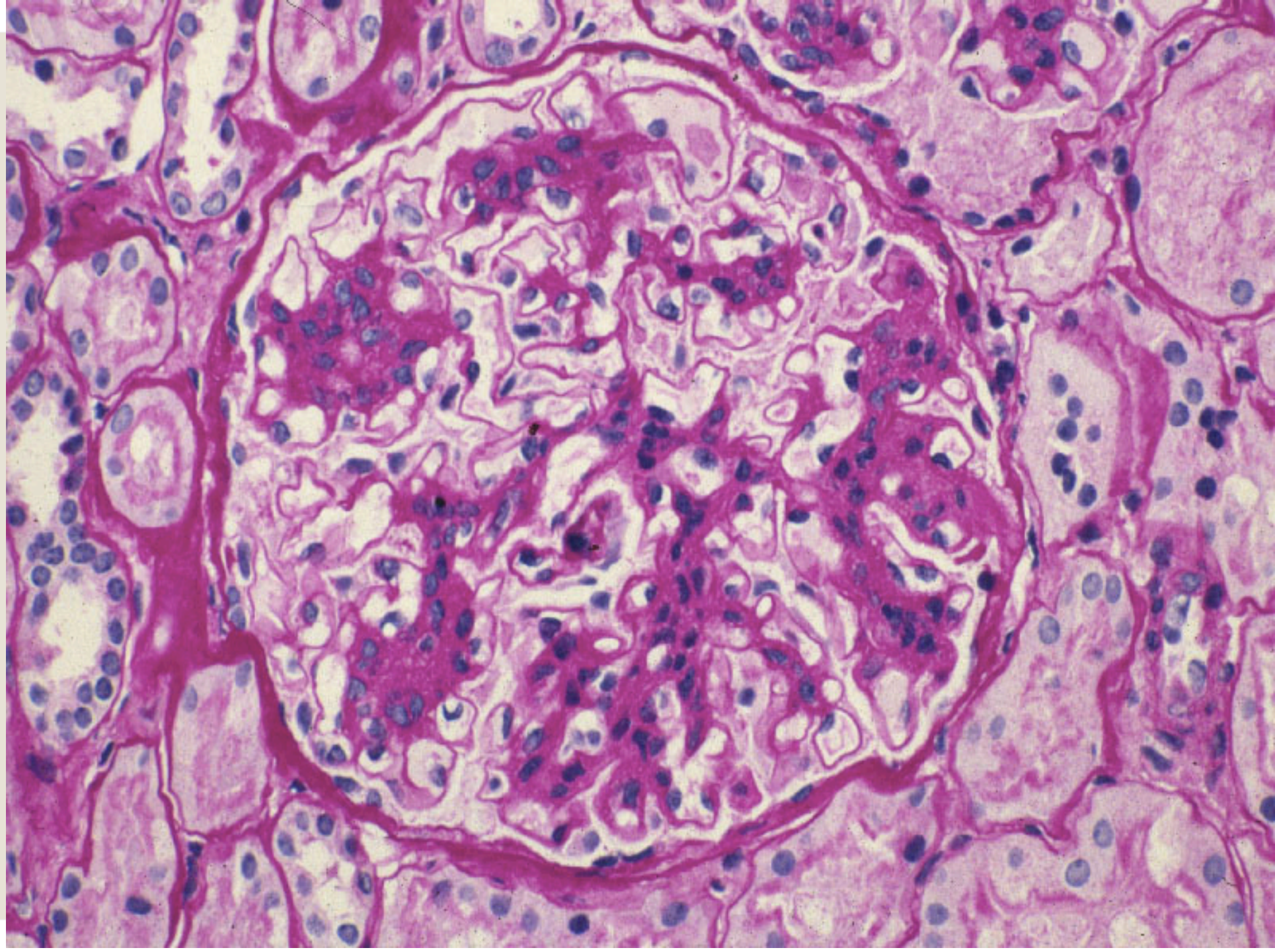




## IgA nephropathy.

There is mesangial cell and matrix increase, with mesangial deposits.

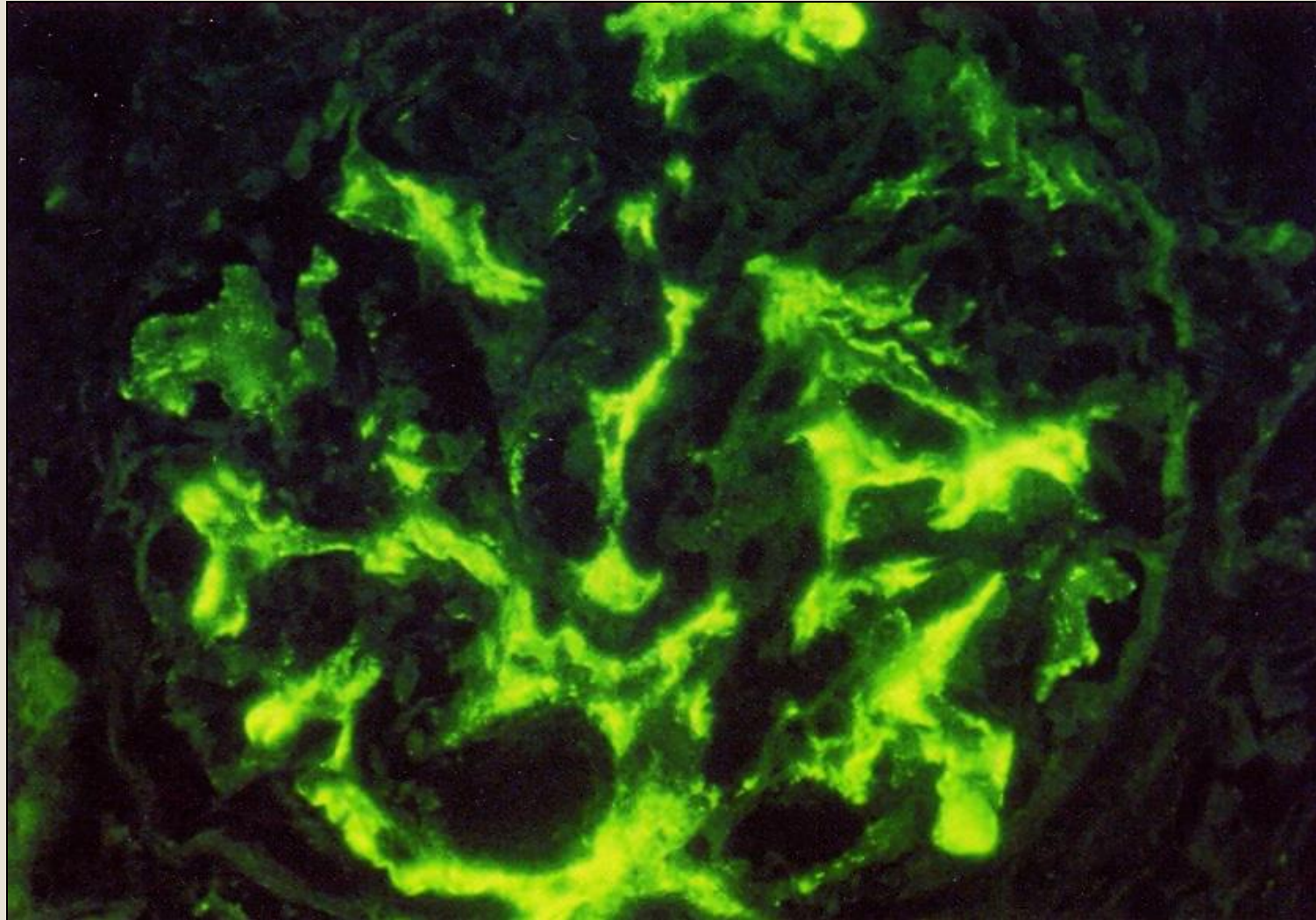






**IgA nephropathy.**

Definitive diagnosis is made by immunofluorescence, showing dominant or codominant staining with IgA in a predominantly mesangial pattern, as shown here.





## Clinical Syndromes

**5. Chronic renal failure = chronic uremia = end of all renal diseases = end stage renal disease - (ESRD; uremia)**



# CHRONIC NEPHRITIC SYNDROME

**Azotemia**

**Active urine sediment (variable)**

**Proteinuria (variable)**

**Past history of RPGN, nephrotic syndrome,  
or nephritic syndrome**

**Hypertension**

# CHRONIC RENAL FAILURE

## CHRONIC NEPHRITIC SYNDROME

The structural equivalent of this syndrome is end-stage renal disease, with widespread global glomerular obsolescence (sclerosis), tubular atrophy, interstitial fibrosis, and variable degree of arterial and arteriolar sclerosis. A more precise diagnosis can often be established by immunohistochemical and ultrastructural studies.



# ***END STAGE RENAL DISEASE***

Chronic Renal Failure

## ***END STAGE RENAL DISEASE***

### I. Chronic Renal Failure

A. Extent of the problem; medical costs and ESRD

B. Uremic syndrome - definition

1. Skin manifestations - pruritus, uremic "frost", skin
2. Cardiac manifestations - uremic pericarditis
3. Neurological manifestations - peripheral neuropathy
4. Pulmonary complications - pneumonitis and hemorrhage
5. Hematopoietic manifestations - anemia, bleeding diathesis
6. Skeletal abnormalities - renal osteodystrophy (secondary hyperparathyroidism)
7. Other - metabolic imbalances



## ***END STAGE RENAL DISEASE***

Chronic Renal Failure

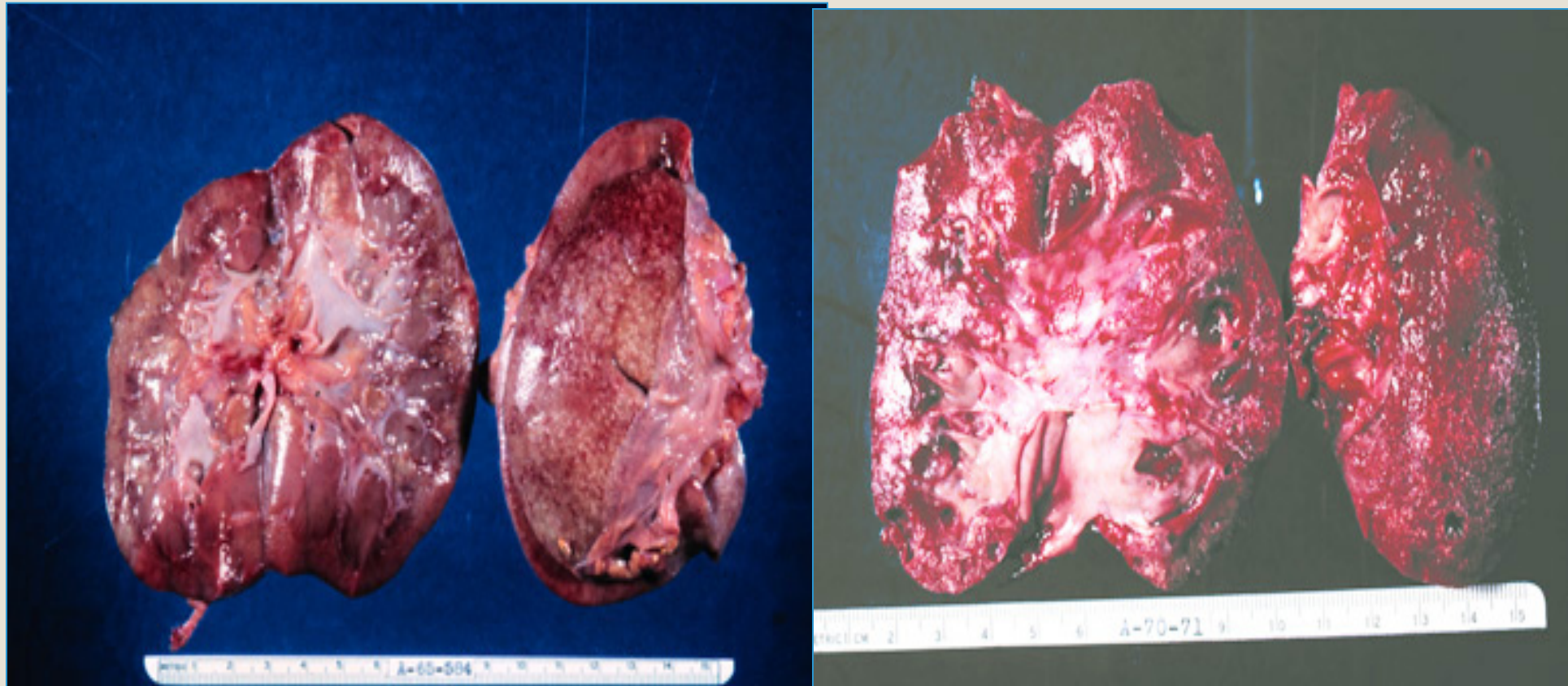
C. Pathogenesis of uremic syndrome

- 1. Uremic "Toxins"**
- 2. Middle molecules**
- 3. The "Trade off" hypothesis**

II. Treatment of End Stage Renal Disease

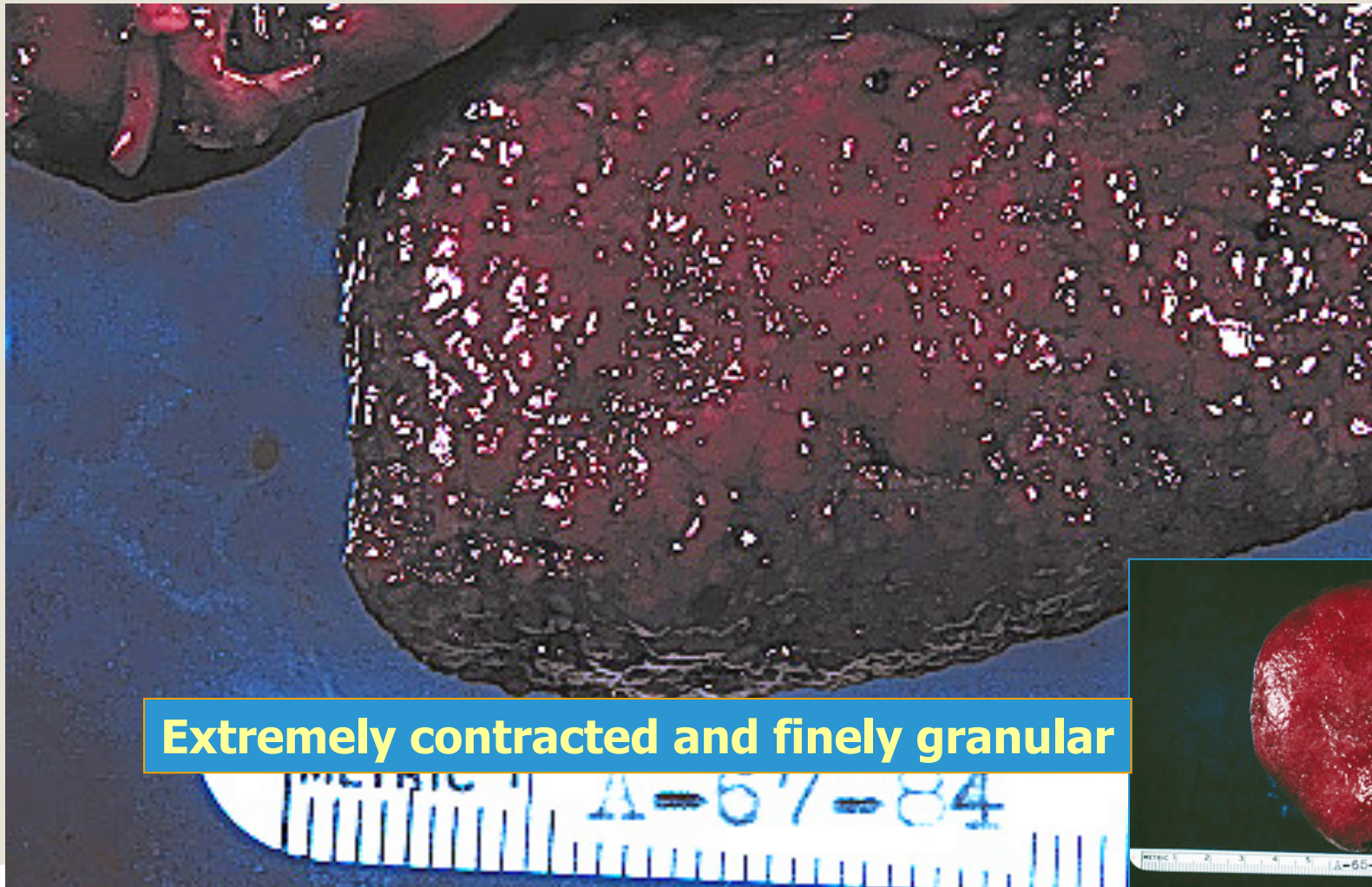- A. Supportive therapy**
- B. Dialysis**
- C. Renal transplantation**

**“End stage kidney” of chronic glomerulonephritis.** These are severely contracted kidneys each measure about 2 x 3".. Notice the cortices small amount of parenchyma and the finely granular surfaces. Such kidneys are incompatible with life.

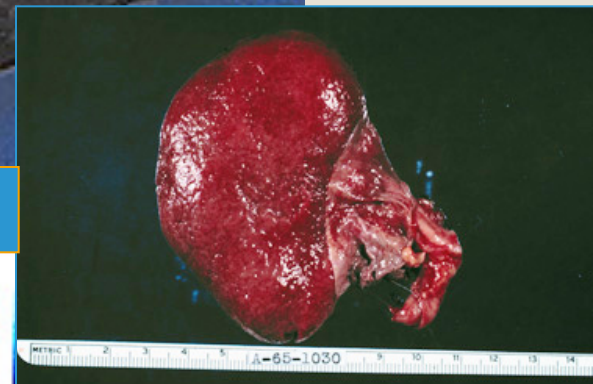




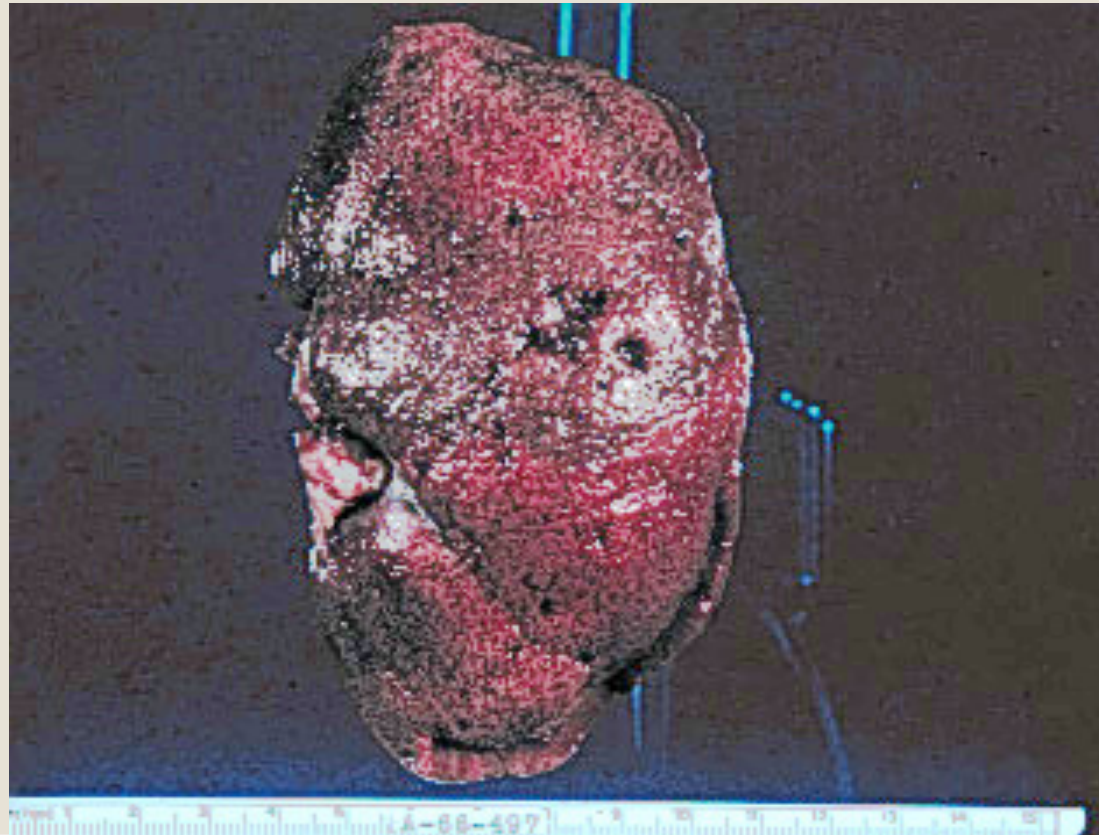**“End stage kidney” of chronic glomerulonephritis. This is the kidney of a 38 year old man who presented with an insidious onset of the three signs of uremia, that is loss of appetite, lethargy, and the laboratory finding of an increased BUN. He had no antecedent history of acute glomerulonephritis.**



**Extremely contracted and finely granular**



Contracted kidney with a finely granular surface representing another glomerular disease, Kimmelsteil-Wilson disease or diabetic glomerulosclerosis. Grossly is indistinguishable from chronic glomerulonephritis. Notice larger scars rather shallow pits on the surface: these represent chronic pyelonephritis another disease that diabetics are apt to develop.





This is a close-up photograph of a cross-section of a kidney with chronic glomerulonephritis. The cortex has largely turned to scar tissue and there is a poor demarcation between cortex and medulla due to the glomerular scarring.

