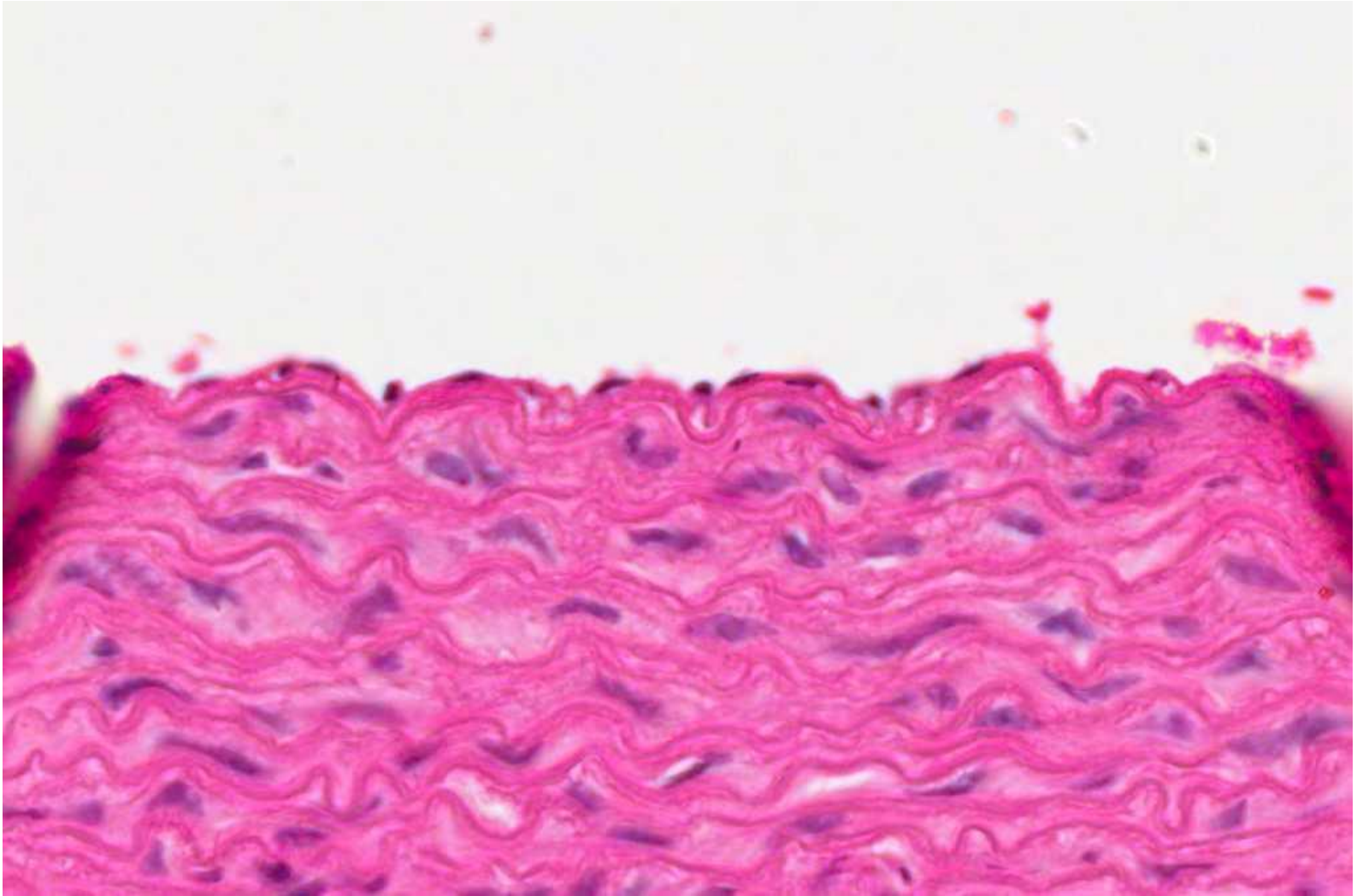
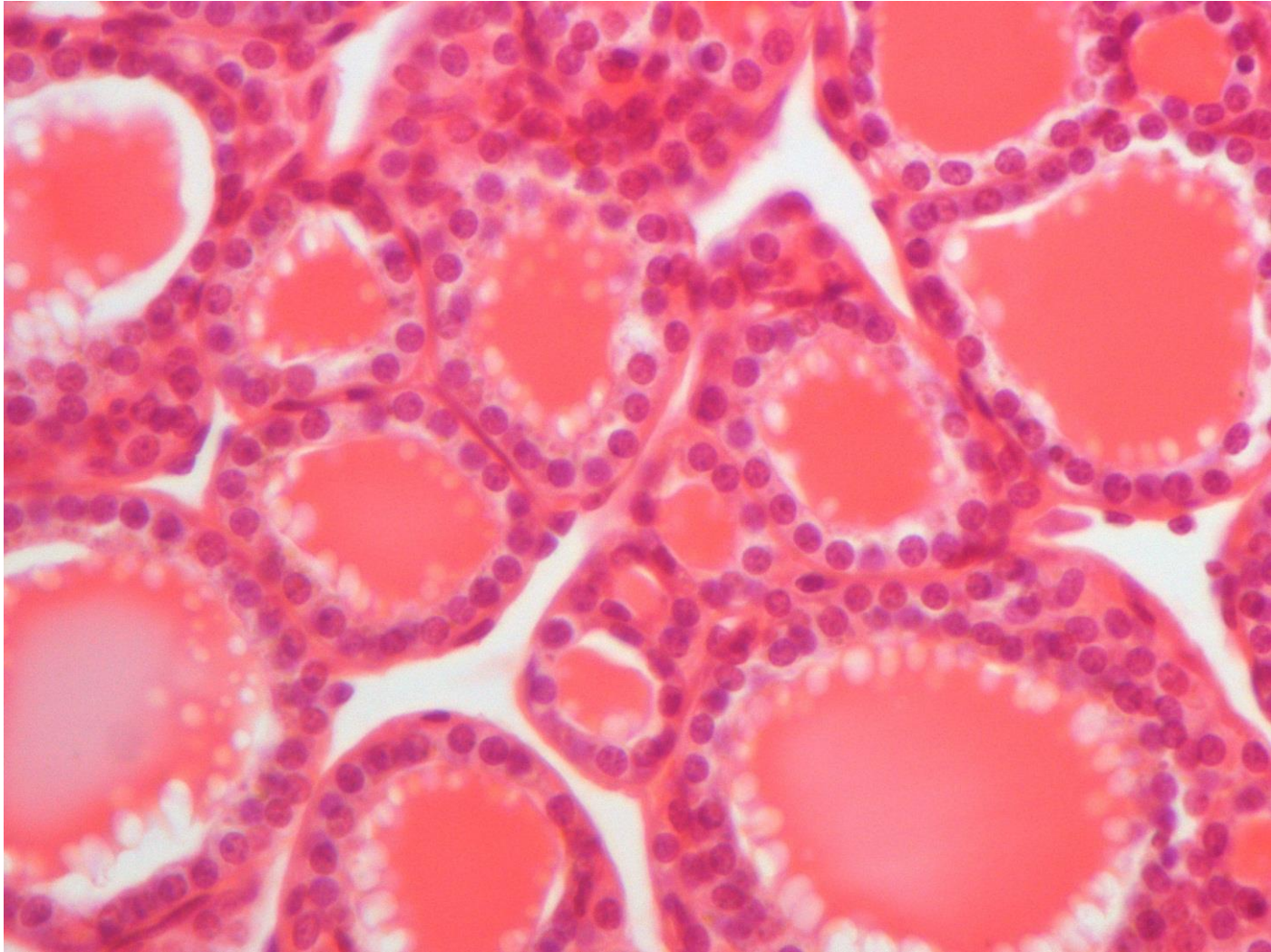


# Practical Histology of Epithelium

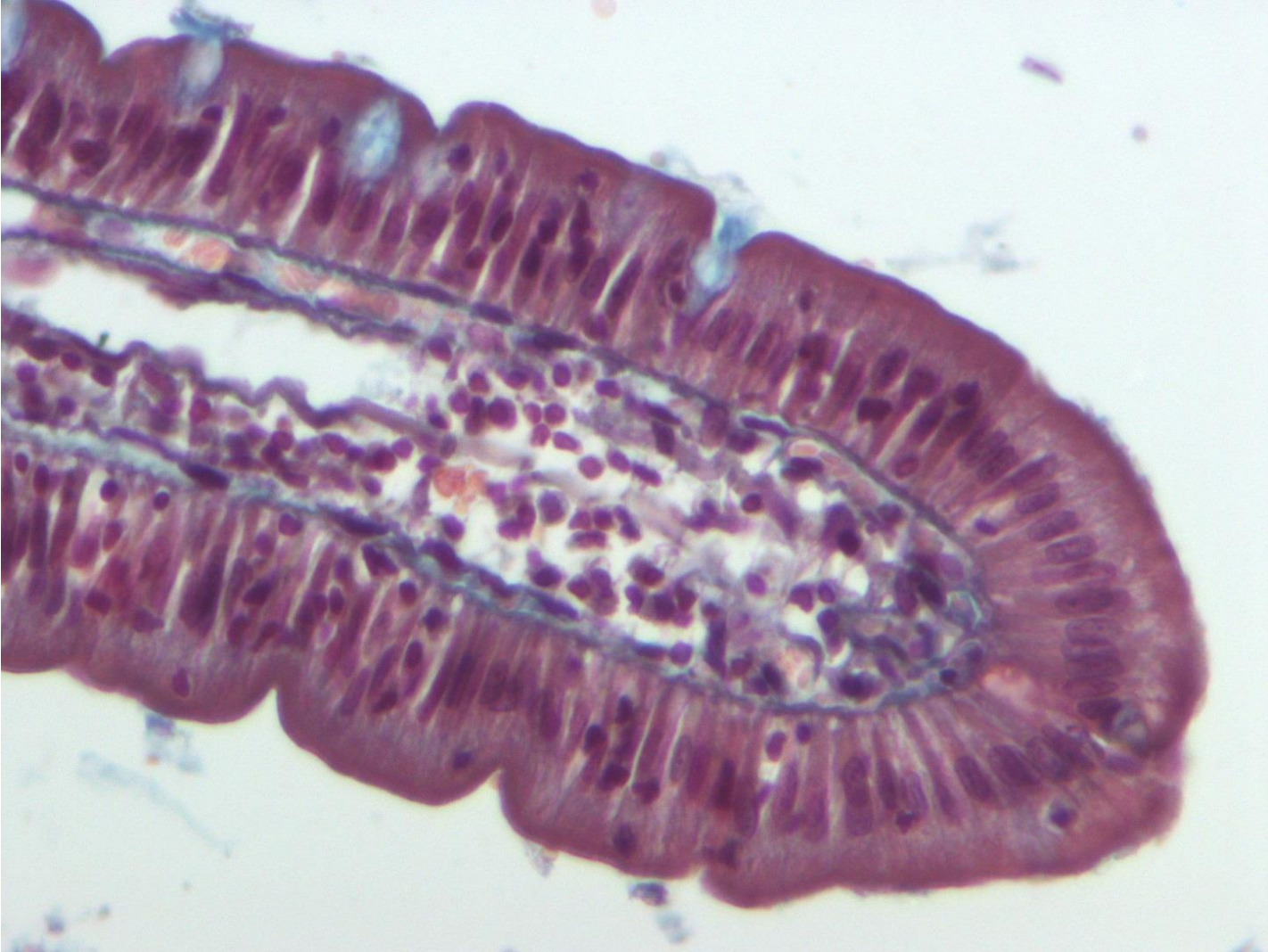
# Simple squamous



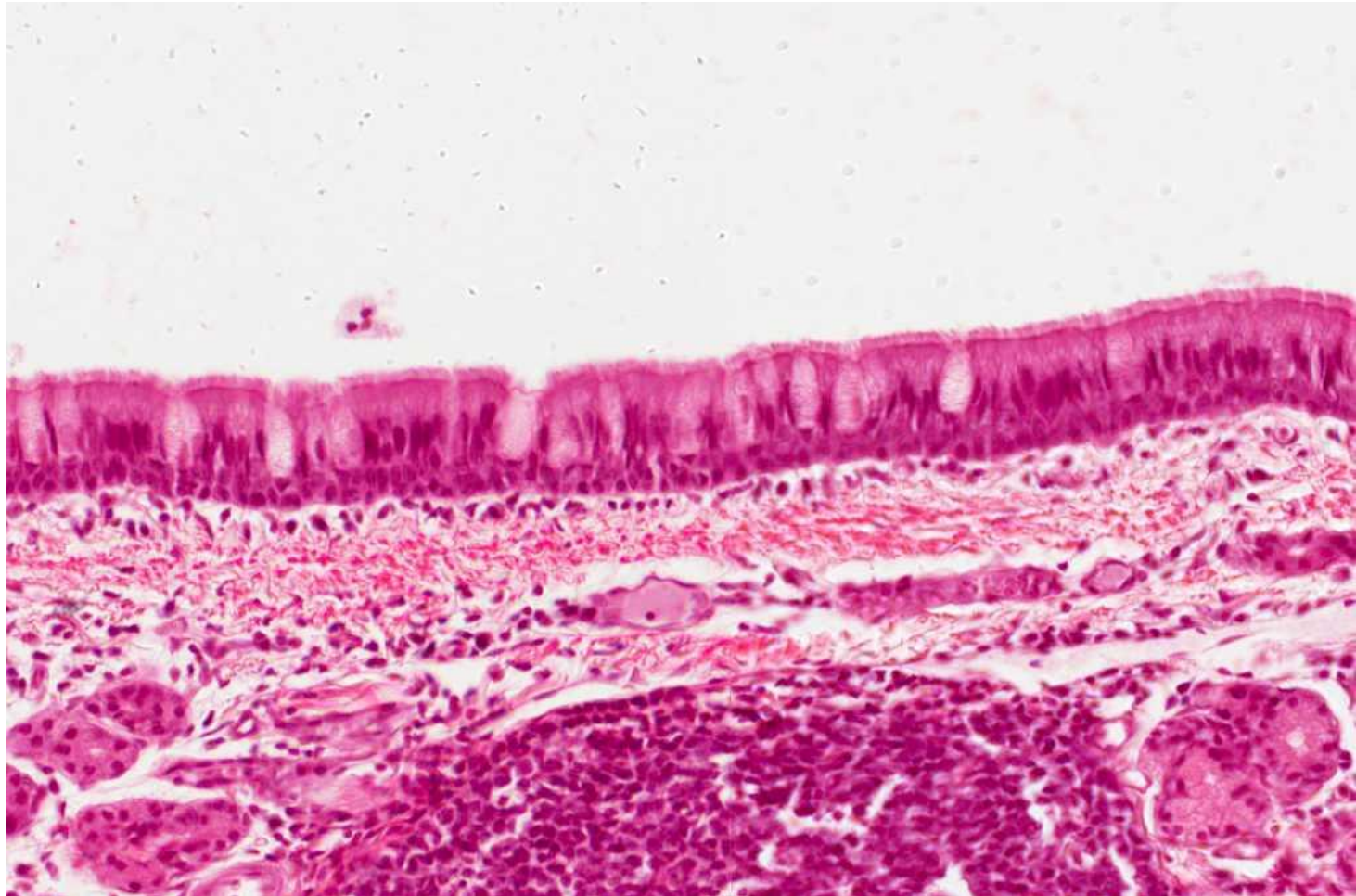
# Simple cuboidal



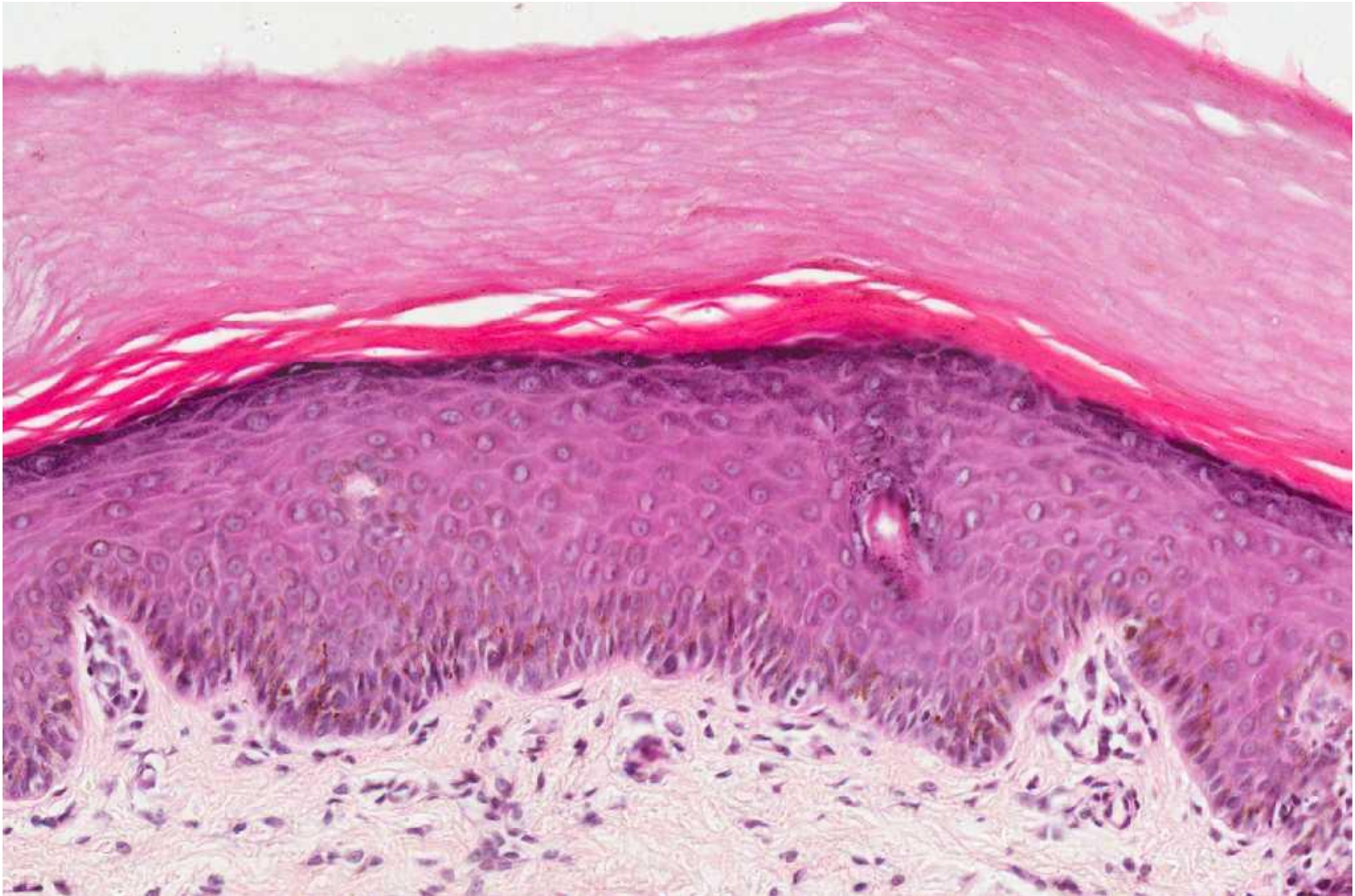# Simple columnar



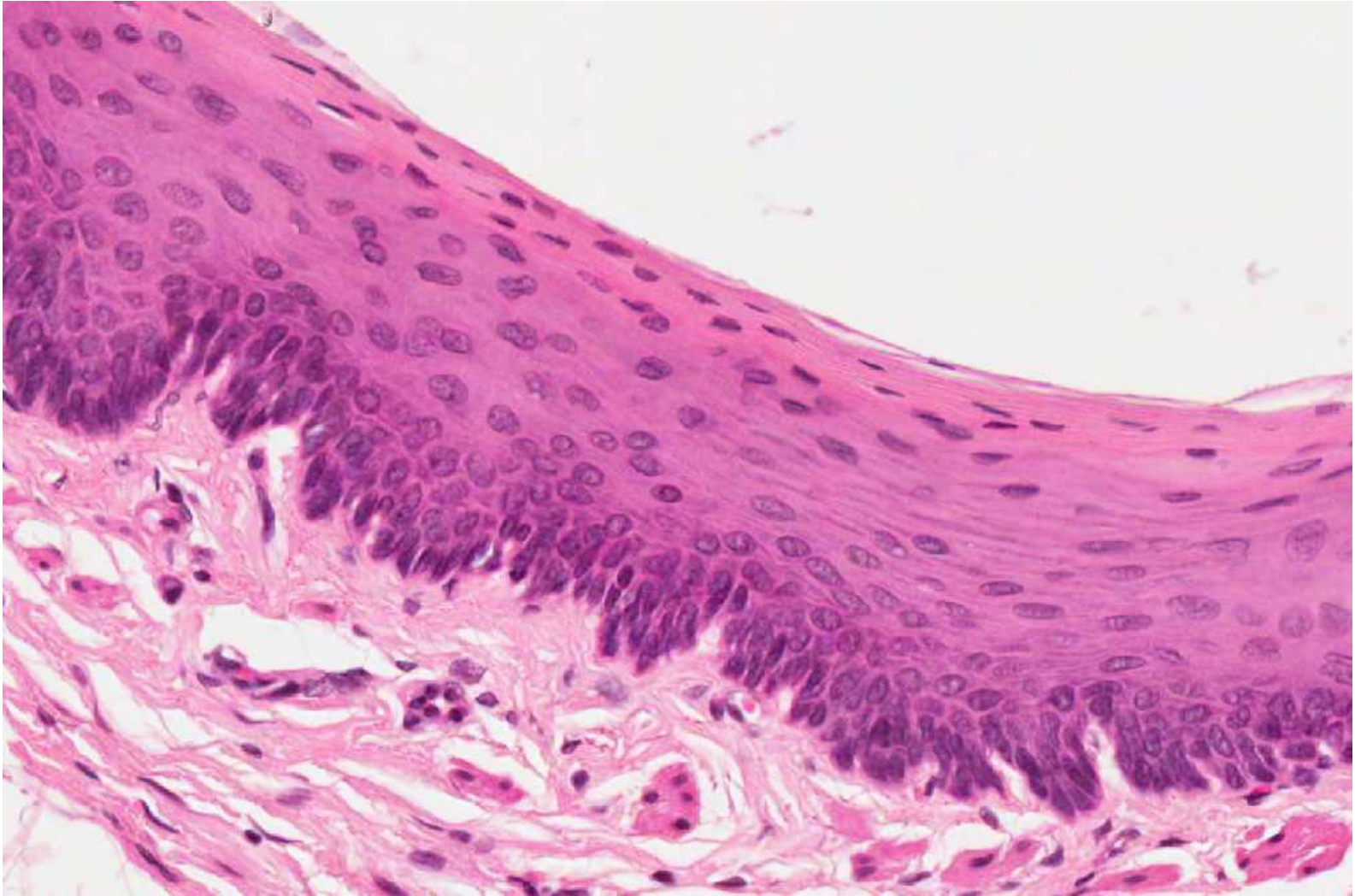
# Pseudostratified columnar ciliated with goblet cells



# Stratified squamous-keratinized



# Stratified squamous non-keratinized



# Transitional epithelium

