



Anatomy OSPE 437

Preparation

Before you read this preparation:

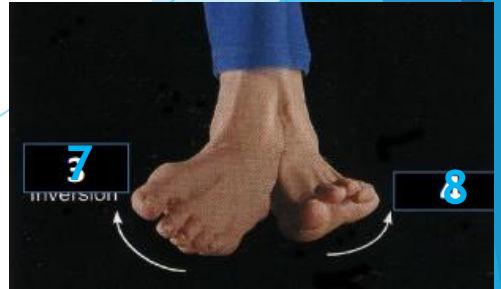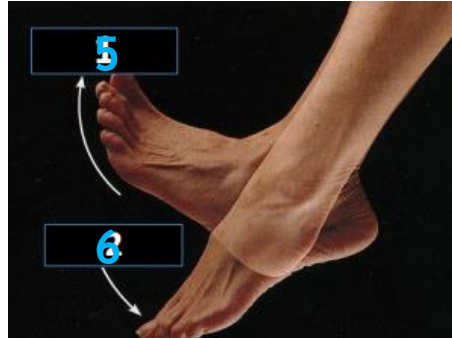

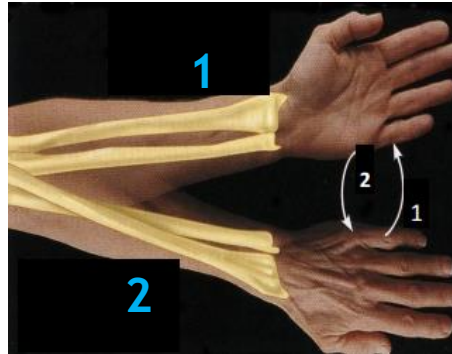
- ✓ Make sure you understand the difference between the term's NAME & TYPE which have completely different answers.
- ✓ Make sure your SPELLING is correct or relatively similar to ensure your grade on each question.

CASE 1

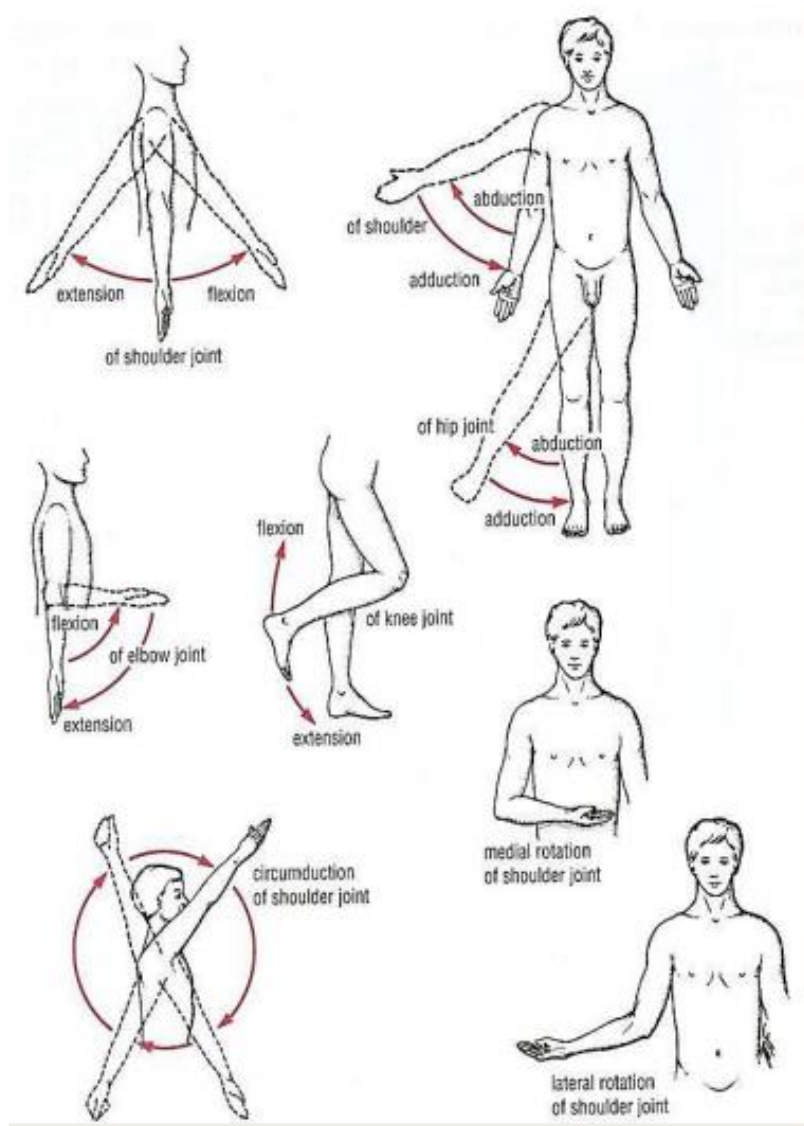
Identify the numbered movements & the lateral bone in figure 1.

- 1. Supination
 - 2. Pronation
 - 3. Flexion
 - 4. Extension
 - 5. Dorsiflexion (ترفع رجلك عن البنزين)
 - 6. Plantarflexion (فرامل)
 - 7. Inversion (inside)
 - 8. Eversion (Outwards)
- Lateral bone in figure 1: Radius

Fig(1)



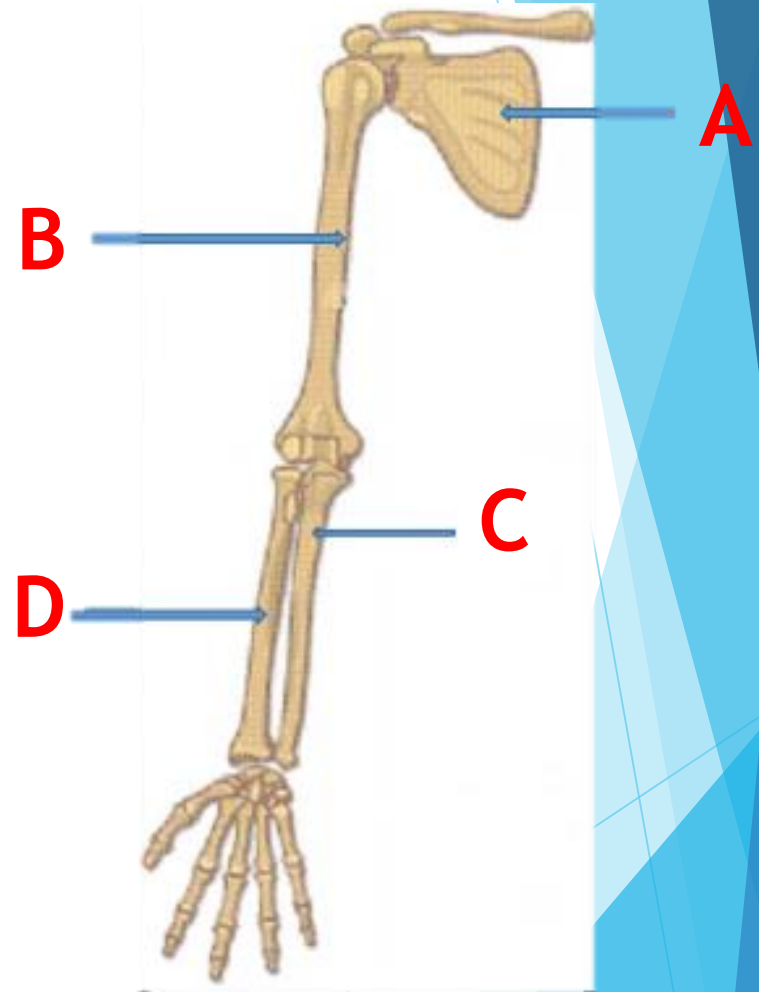
الصورة للتوضيح فقط!



CASE 2

Identify: A,B,C&D

- A. Scapula
- B. Humerus
- C. Ulna (Medial)
- D. Radius (Lateral)



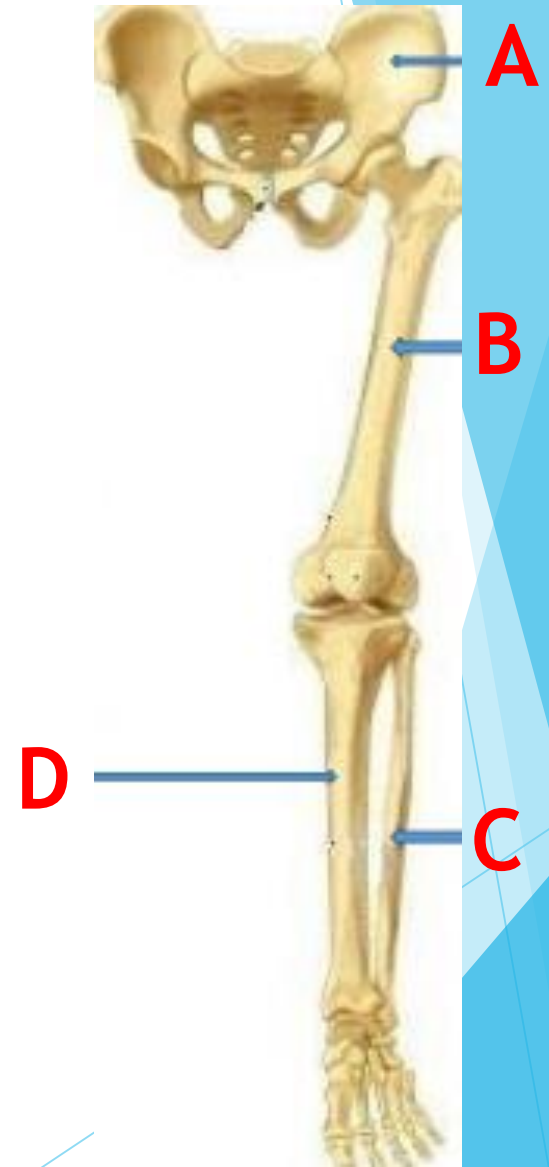
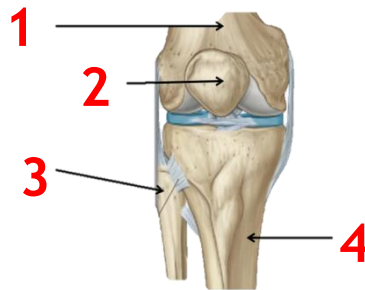
CASE 3

Identify: A, B, C, &D

- A. Hip Bone
 - B. Femur
 - C. Fibula (smaller & lateral)
 - D. Tibia (bigger & medial)
-

Identify the labeled bones:

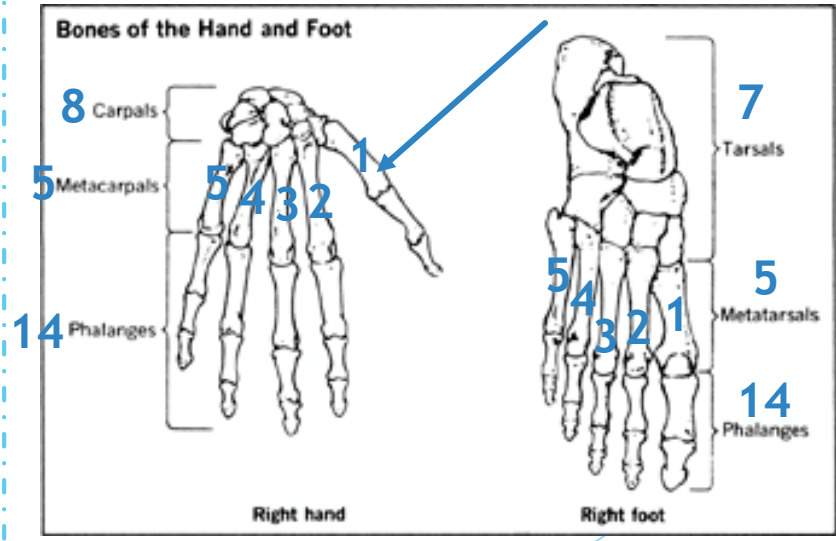
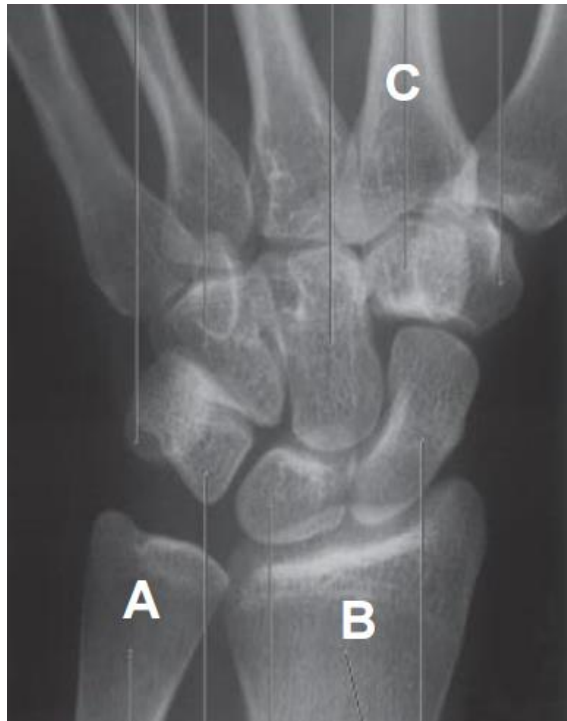- 1. Femur
- 2. Patella
- 3. Fibula (lateral)
- 4. Tibia (medial)



CASE 4

Identify the bones : A, B, &C

- A. Ulna
- B. Radius
- C. 2nd Metacarpal bone



**باليد نبدأ العد من اللاترل الى الميديال.
عكس القدم نبدأ العد من الميديال الى اللاترل.**

To count the metacarpal/metatarsal bones, we start from the thumb/big toe.

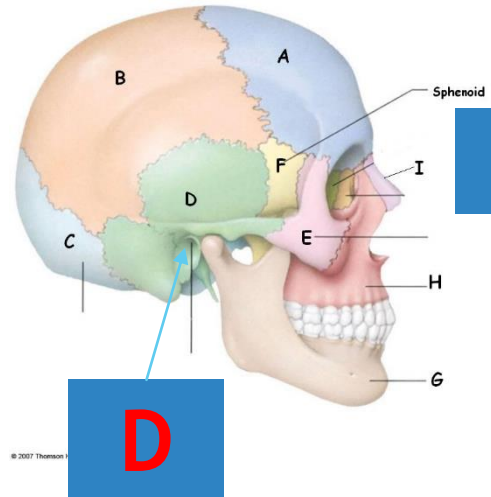
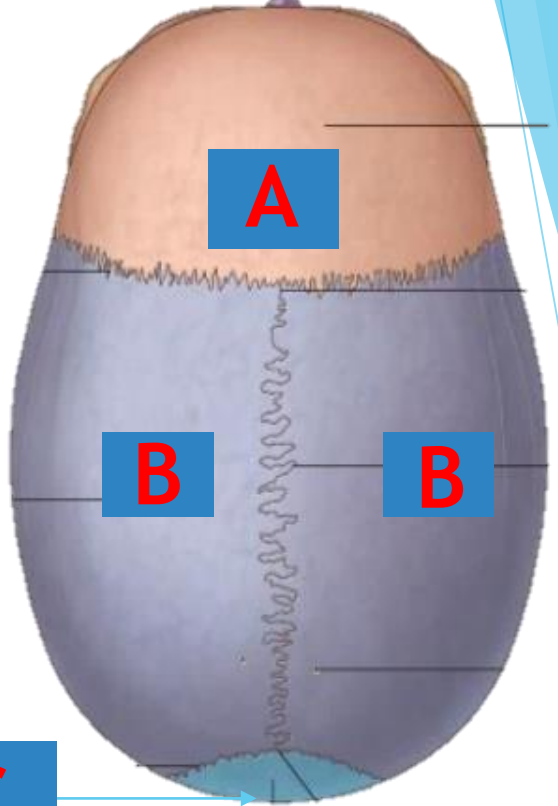
CASE 5

Identify the type & name of bone A

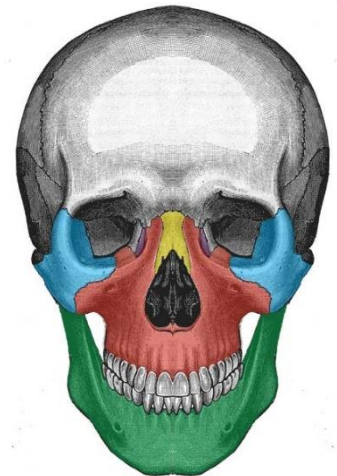
A. Flat bone - Frontal

Identify the name of bone B,C&D

- B. Parietal
- C. Occipital
- D. Temporal



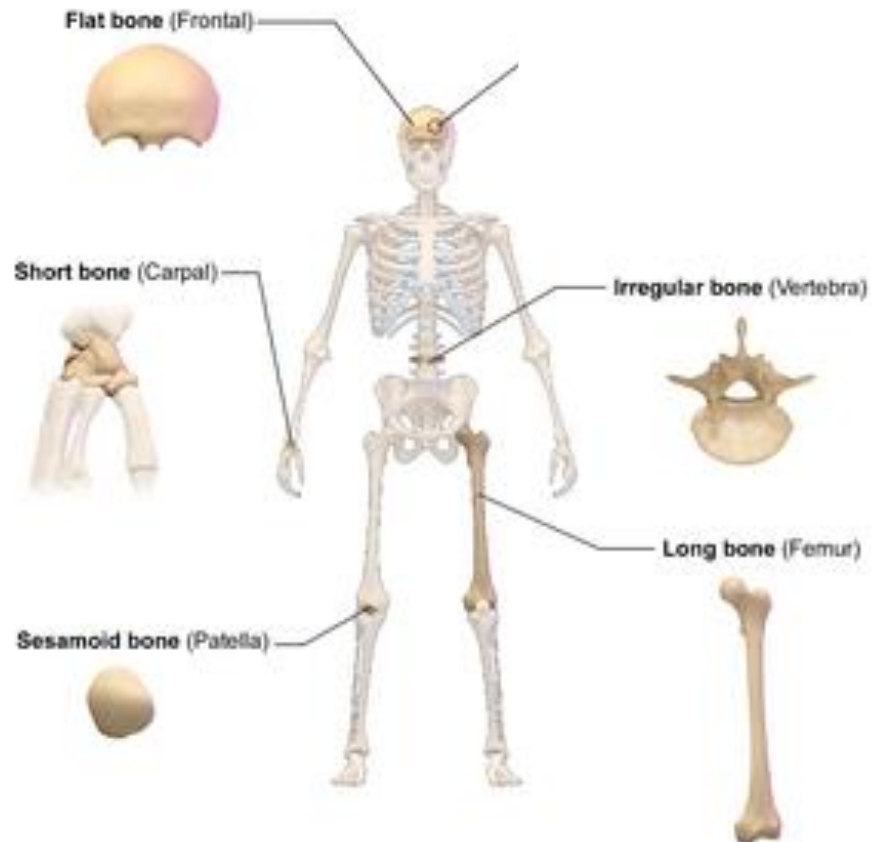
Extra:
The Facial
Bones



- Zygomatic
- Maxilla
- Nasal
- Lacrimal
- Mandible

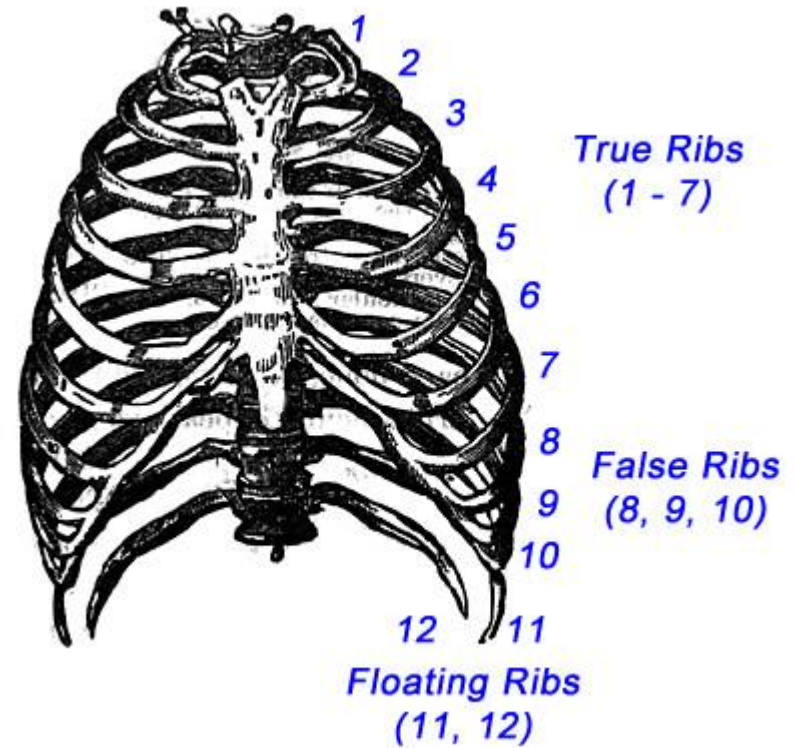
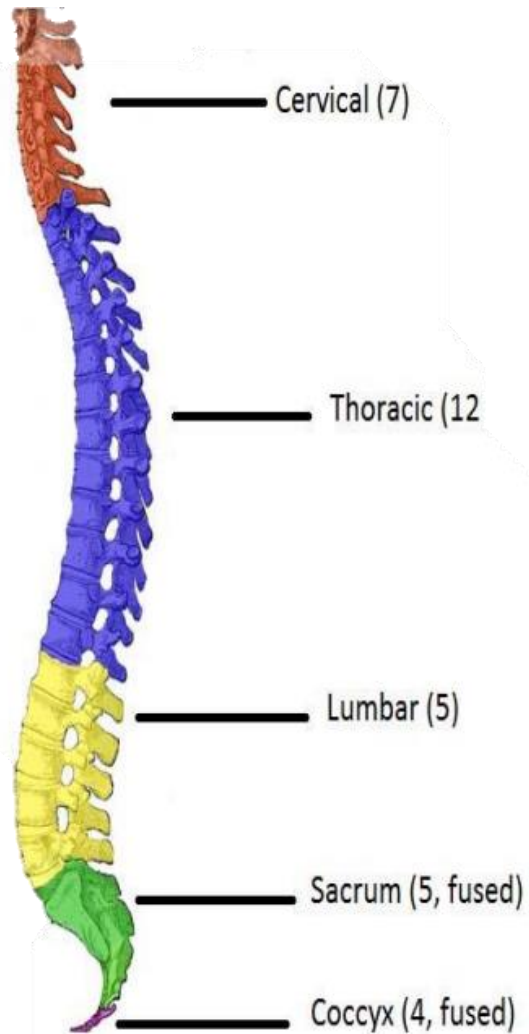
Types of bones:

- ▶ Flat (sternum/skull bones/Scapula/Hip bone)
- ▶ Irregular (vertebra)
- ▶ Long (humerus of the arm) *could be any other long bone
- ▶ Short (carpals of the wrist /Tarsals of the foot)
- ▶ Sesamoid (patella)
- ▶ Pneumatic (العظام الهوائية مثل الموجود بقلب الجمجمة)



Classification of Bones by Shape

The region & number of vertebrae

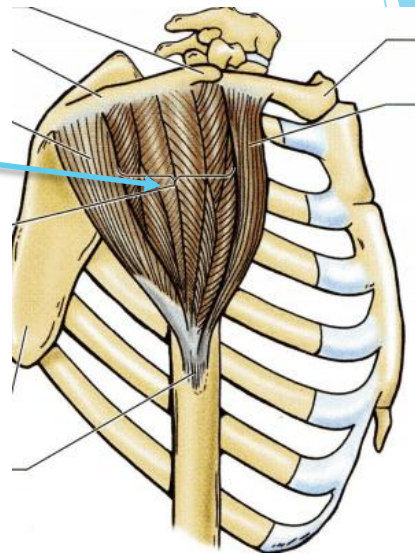


Types of ribs (True, False & Floating)

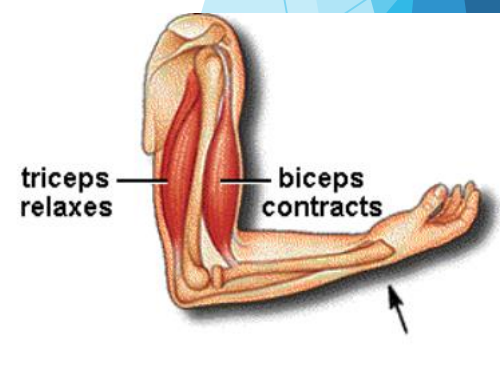
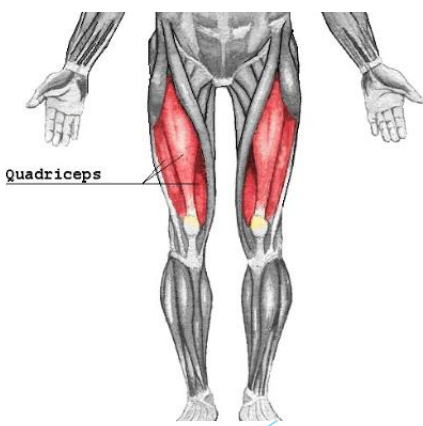
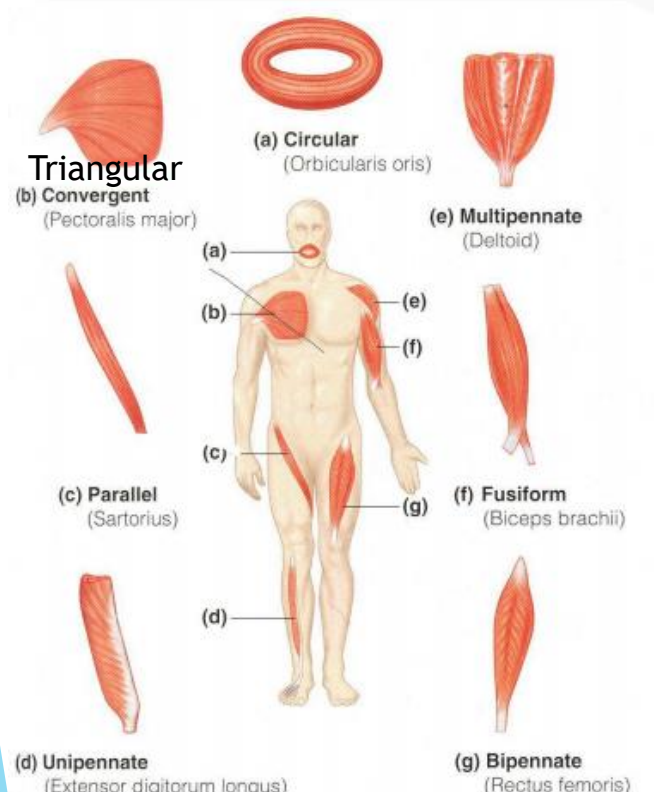
CASE 6

Identify the following type & name of skeletal muscle:

Multipennate - Deltoid Muscle



مهم تحفظون مثال على كل نوع



CASE 7

Identify the labeled structures:

A. Midbrain

B. Pons

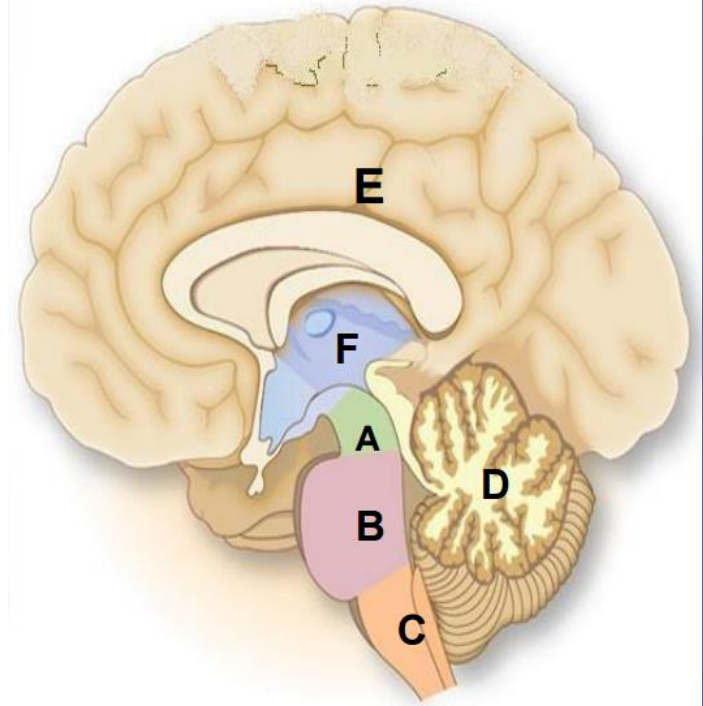
C. Medulla Oblongata

D. Cerebellum

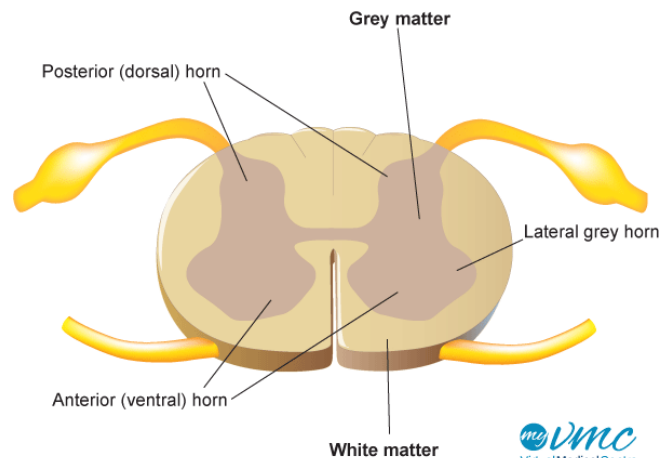
E. Cerebrum

F. Diencephalon

Brain stem



Extra:





MED437
KING SAUD UNIVERSITY



Done By:

Faisal Fahad ALsaif

Lamia Abdullah AlKuwaiz

Fahad Abdullah Alfaiz

Good Luck