

HAND & WRIST

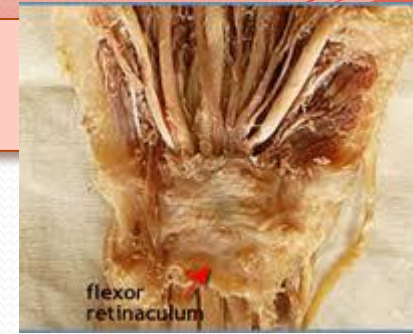Dr. Saeed Vohra

Dr. Jamila El-Medany

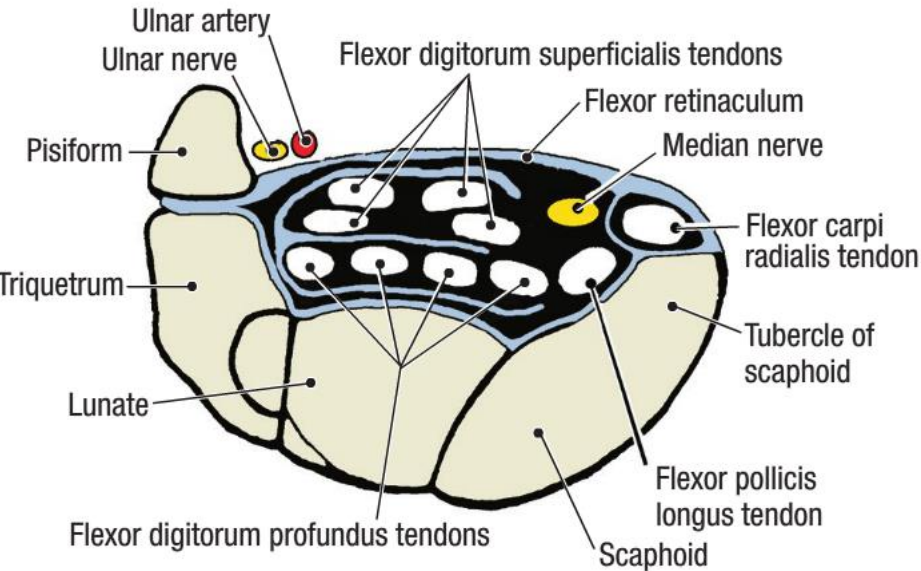
OBJECTIVES

- **At the end of the lecture, students should be able to:**
- **Describe the anatomy of the deep fascia of the wrist & hand (flexor & extensor retinaculae & palmar aponeurosis).**
- **List the structures passing superficial & deep to flexor retinaculum.**
- **Describe the anatomy of the insertion of long flexor & extensor tendons.**
- **Describe the anatomy of the small muscles of the hand (origin, insertion action & nerve supply)**

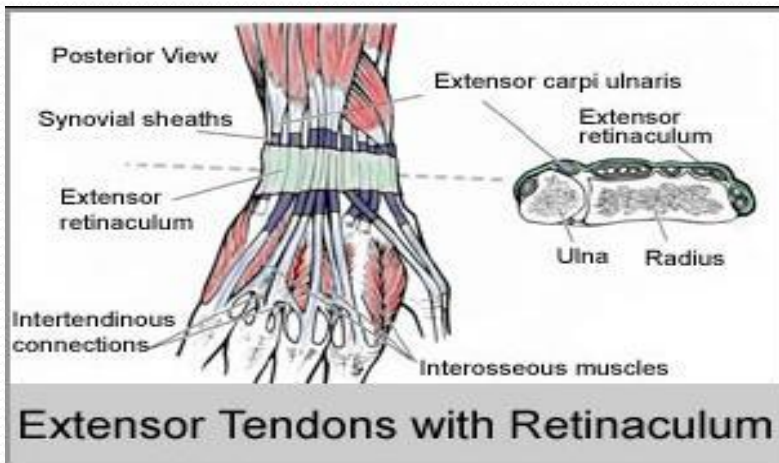
Retinacula



CARPAL TUNNEL WITH CONTENTS



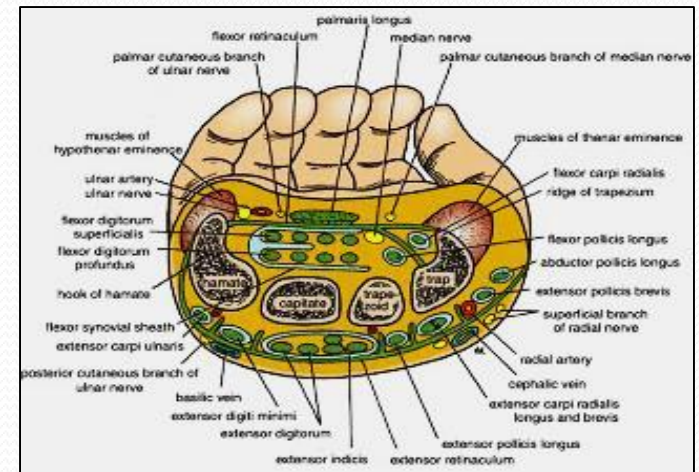
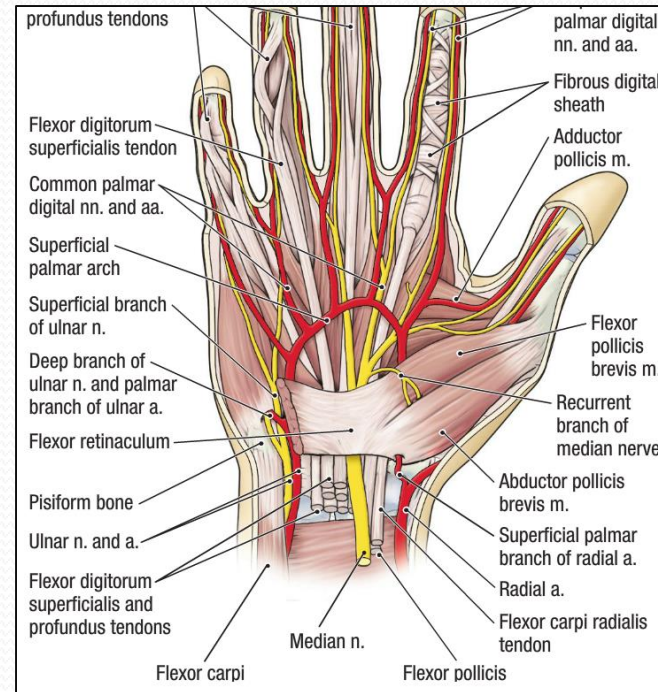
- **Flexor & Extensor Retinacula:**
- ***Bands of Deep Fascia at the Wrist***
- **Function:**
 - *Hold the long flexor and extensor tendons at the wrist in position.*
- **Attachments:**
 - **Medially:** *Both retinacula attached to Pisiform & Hook of Hamate.*
 - **Laterally:**
 - ***Flexor Retinaculum attached to Tubercle of Scaphoid & Trapezium.***
 - ***Extensor Retinaculum attached to Distal end of Radius***



Structures Superficial to Flexor Retinaculum

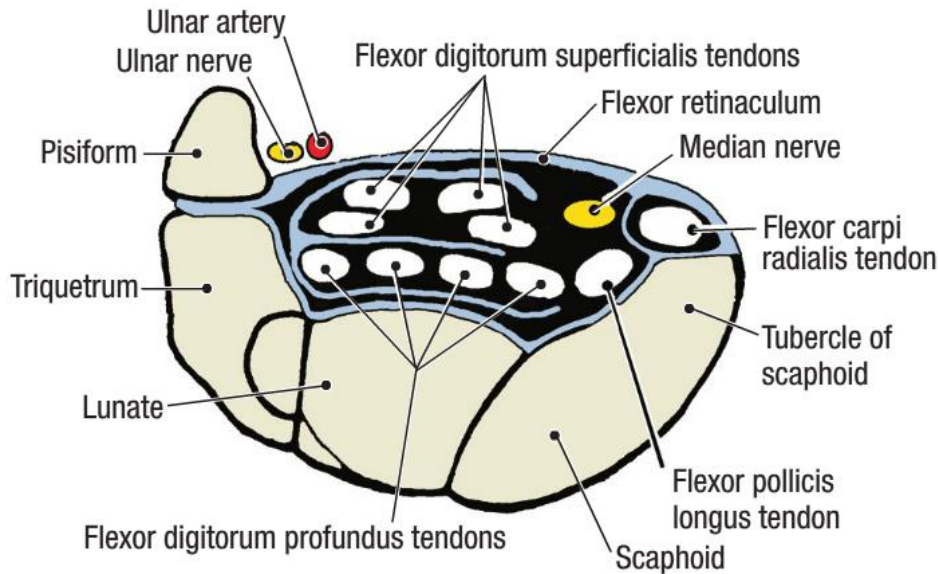
From Medial to Lateral

1. **Tendon of Flexor carpi ulnaris.**
2. **Ulnar nerve.**
3. **Ulnar artery.**
4. **Palmar cutaneous branch of ulnar nerve.**
5. **Palmaris longus tendon.**
6. **Palmar cutaneous branch of median nerve.**



Carpal Tunnel

CARPAL TUNNEL WITH CONTENTS



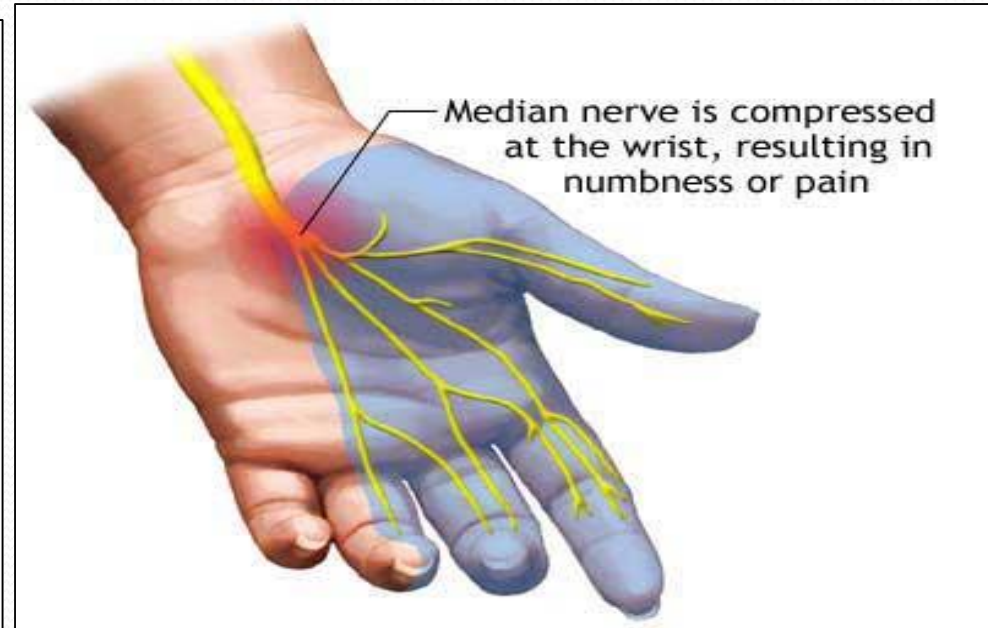
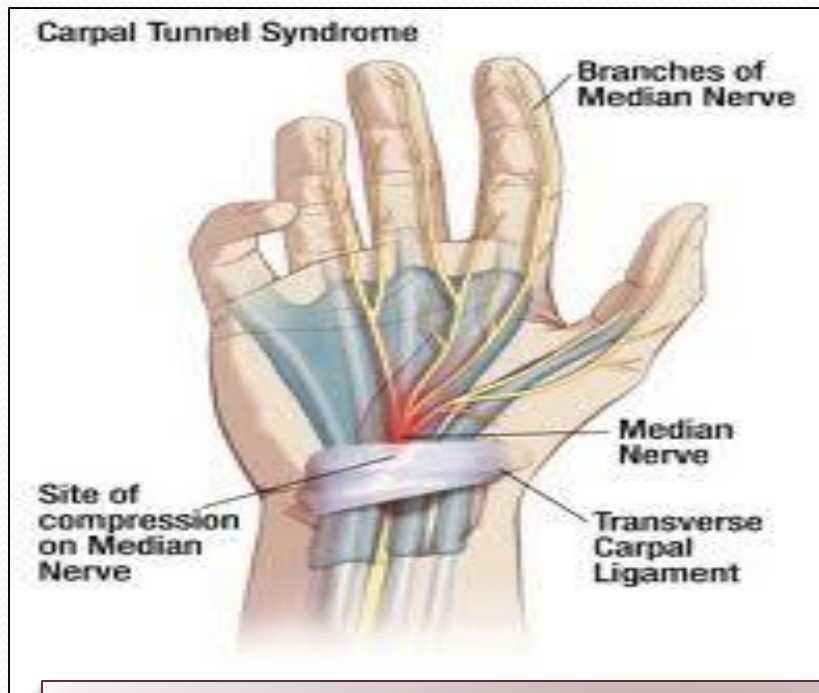
Formed from Concave anterior surface of the Carpus covered by Flexor Retinaculum

Contents

From Medial to Lateral

- Tendons of flexor digitorum superficialis & profundus
- Median nerve
- Flexor Pollicis Longus
- (Flexor carpi radialis)

Carpal Tunnel Syndrome



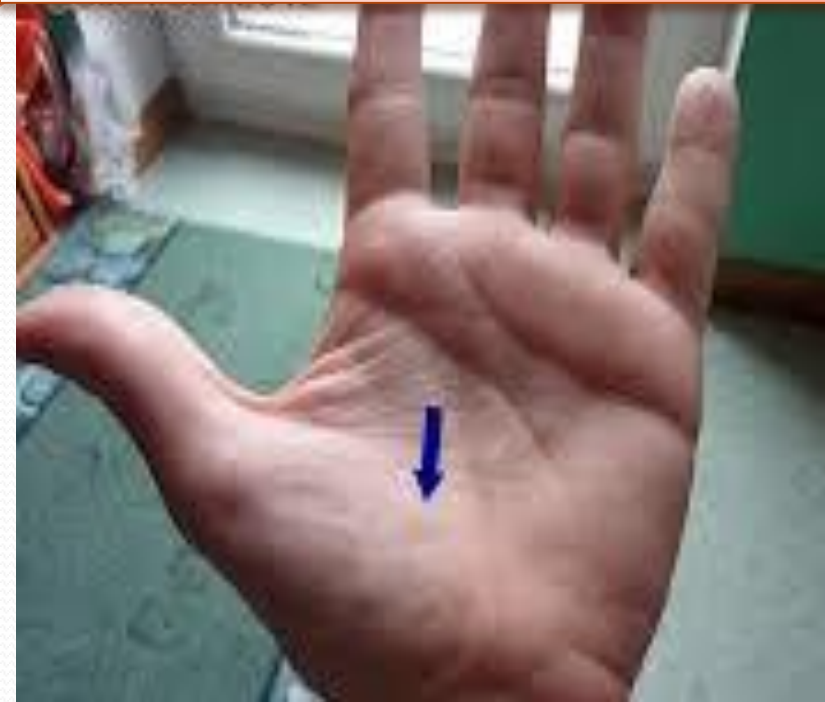Causes :

- *Compression of the median nerve within the carpal tunnel*

Manifestations:

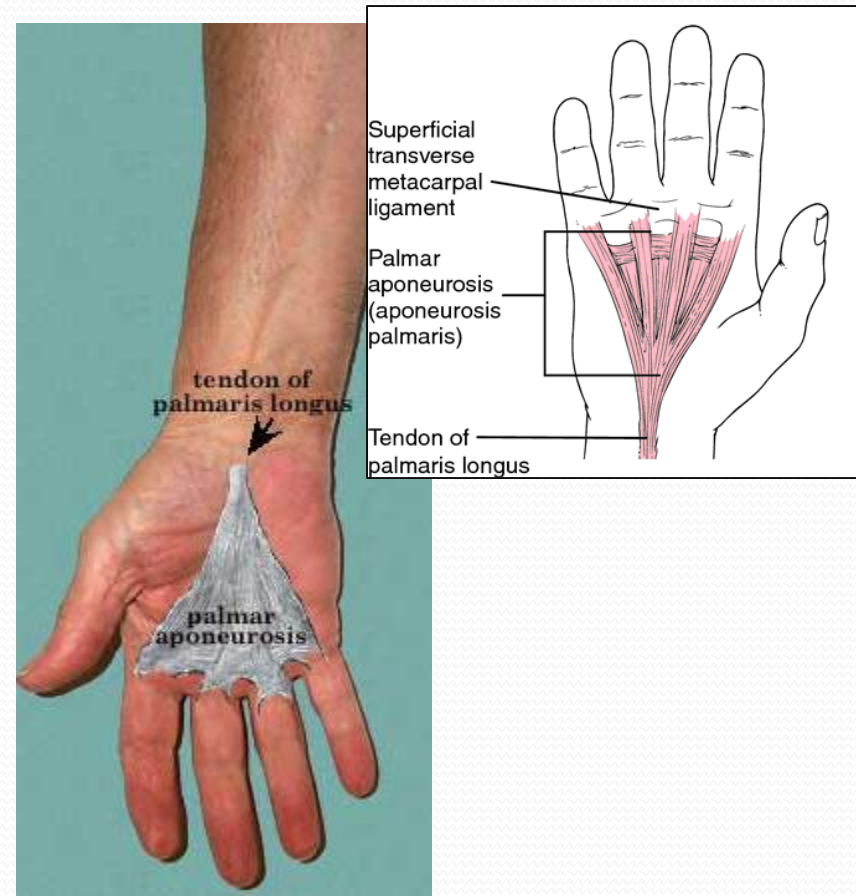
- *1. Burning pain (pins and needles) in the lateral three and half fingers.*
- *No paresthesia over the thenar eminence?*

Carpal Tunnel Syndrome



- *2. Weakness or atrophy of the thenar muscles (**Ape Hand**).*
- *Inability to Oppose the thumb.*

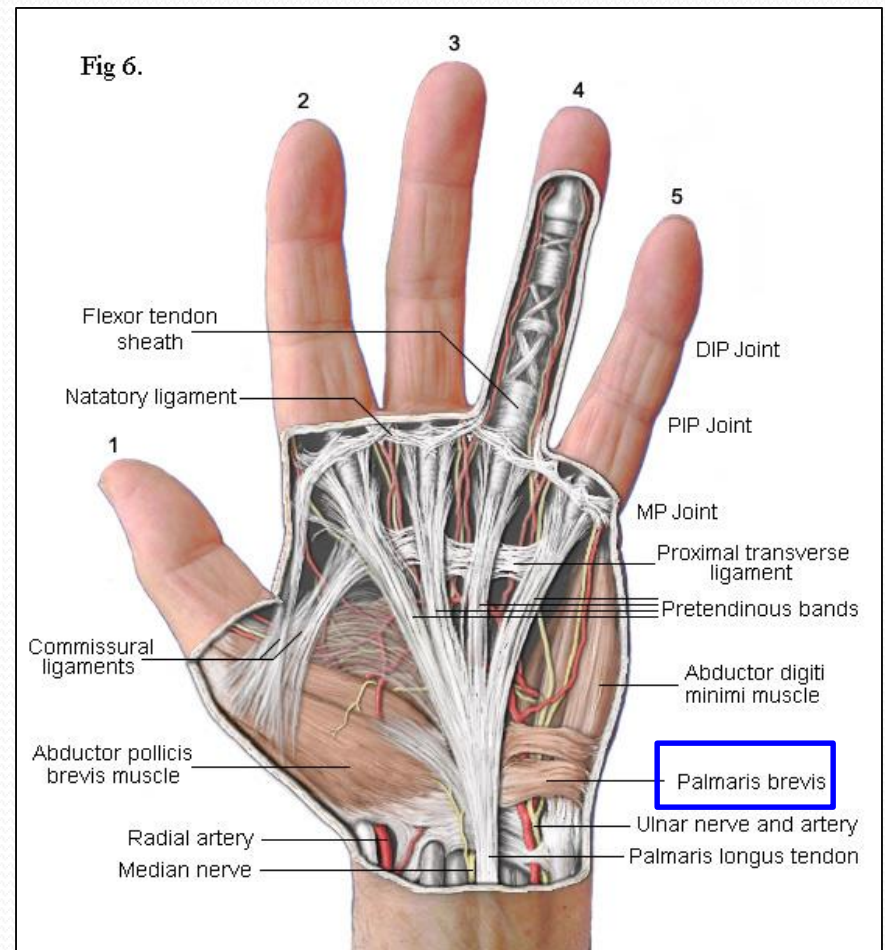
Palmar Aponeurosis



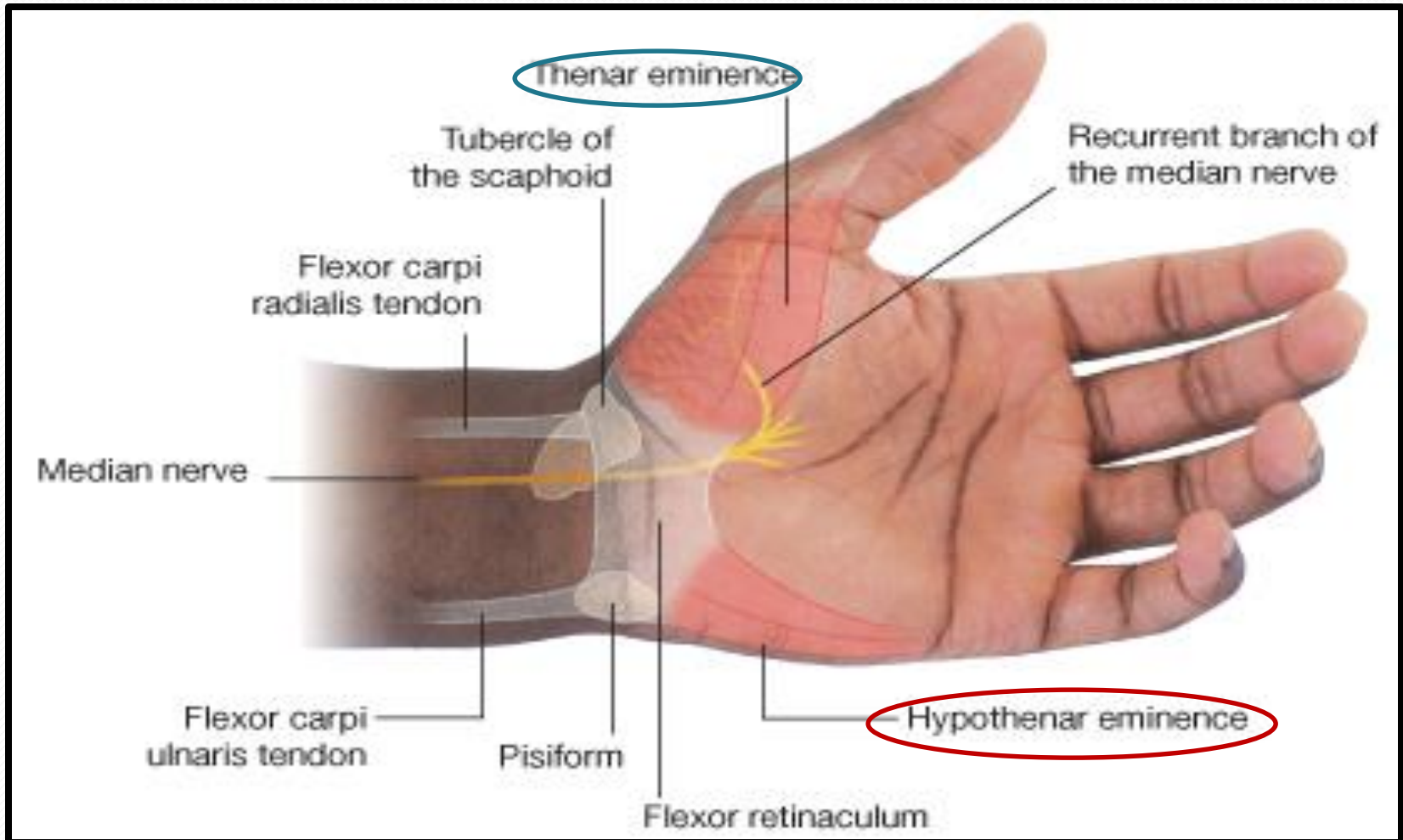
- **The Thickened deep fascia of the Palm.**
- It is Triangular in shape , occupies the central area of the palm.
- **Apex:**
 - Attached to the distal border of flexor retinaculum and receives the insertion of palmaris longus tendon.
- **Base:**
 - Divides at the bases of the fingers into four slips that pass into the fingers.
- **Functions:**
 - 1. Firmly attached to the overlying skin and improves the grip.
 - 2. Protects the underlying tendons, vessels & nerves.
 - 3. Gives origin to palmaris brevis muscle.

Palmaris Brevis

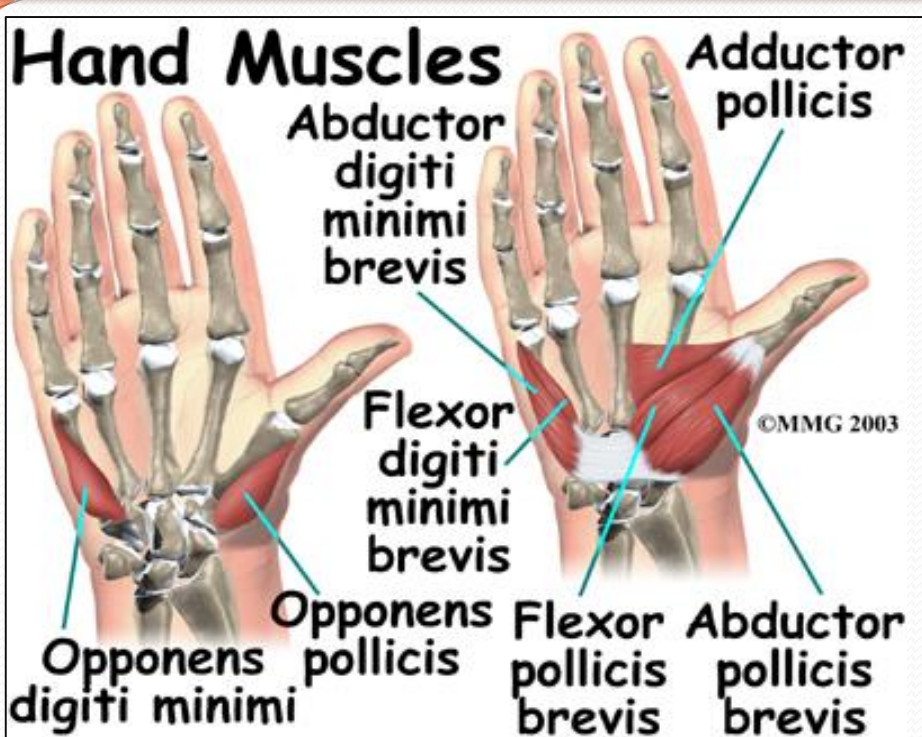
Origin	Insertion	NS	Action
FR and PA.	Skin of Palm	UN <i>(Superficial). Branch</i>	<i>Corrugation of skin to improve grip</i>



Short Muscles of Thumb & Little Finger

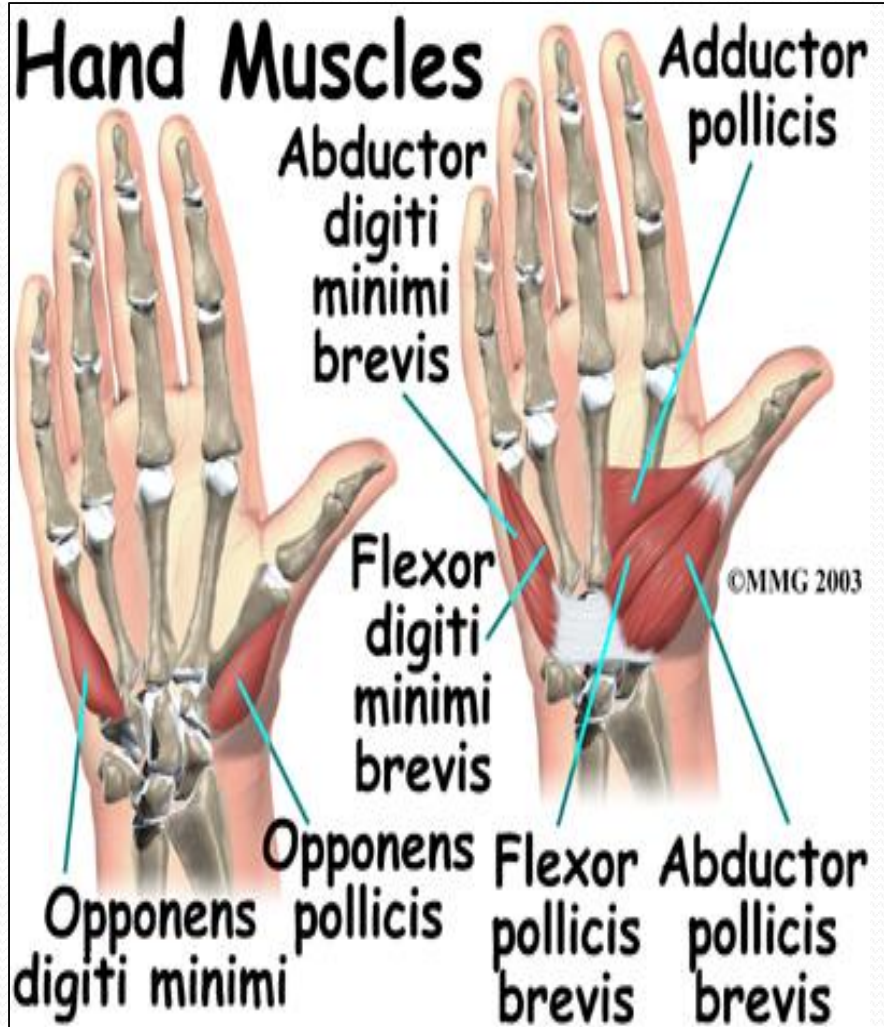


Hypothenar Eminence (3)



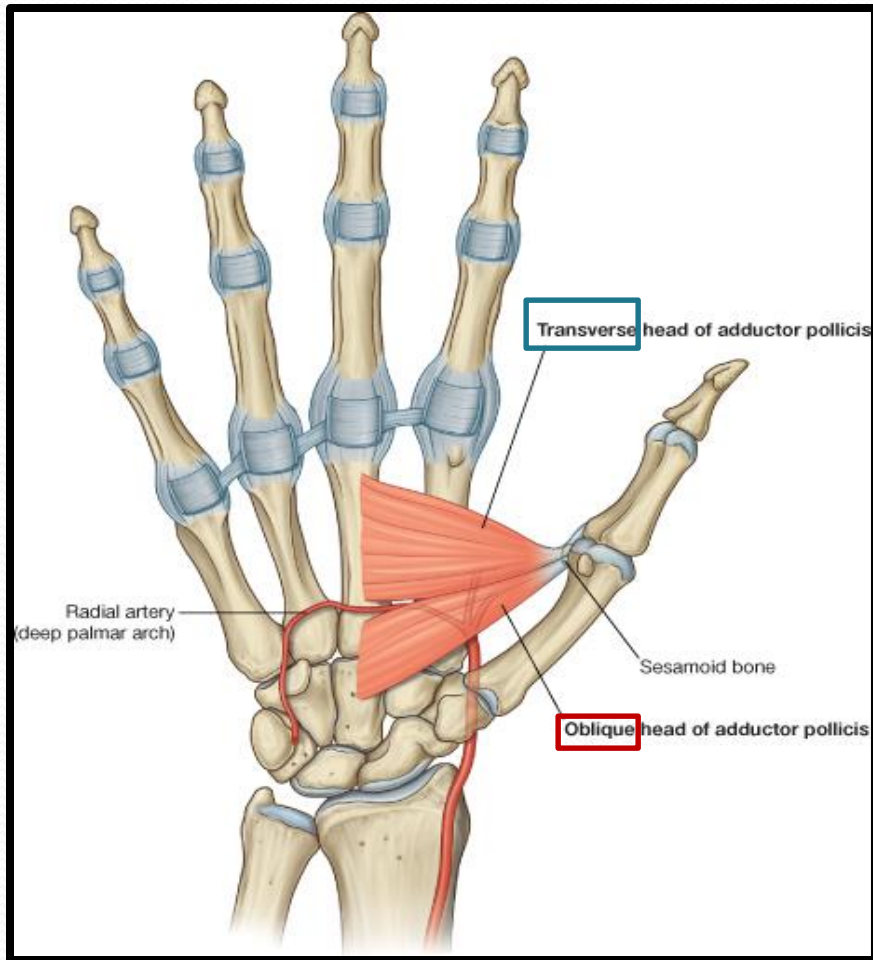
	<i>Origin</i>	<i>Insertion</i>	<i>NS</i>	<i>Action</i>
<i>Ab Dig Min</i>	Pisiform	Base of Prox ph	All by Deep branch of Ulnar	Abduction
<i>Flx Dig Min</i>	FR	<i>With AB DIG MIN</i>		Flexion
<i>Opp Dig Min</i>	Palmar surface of 5 th metacarpal			<i>Pulls the 5th metacarpal forward (Cup the palm)</i>

Thenar Eminence (3)



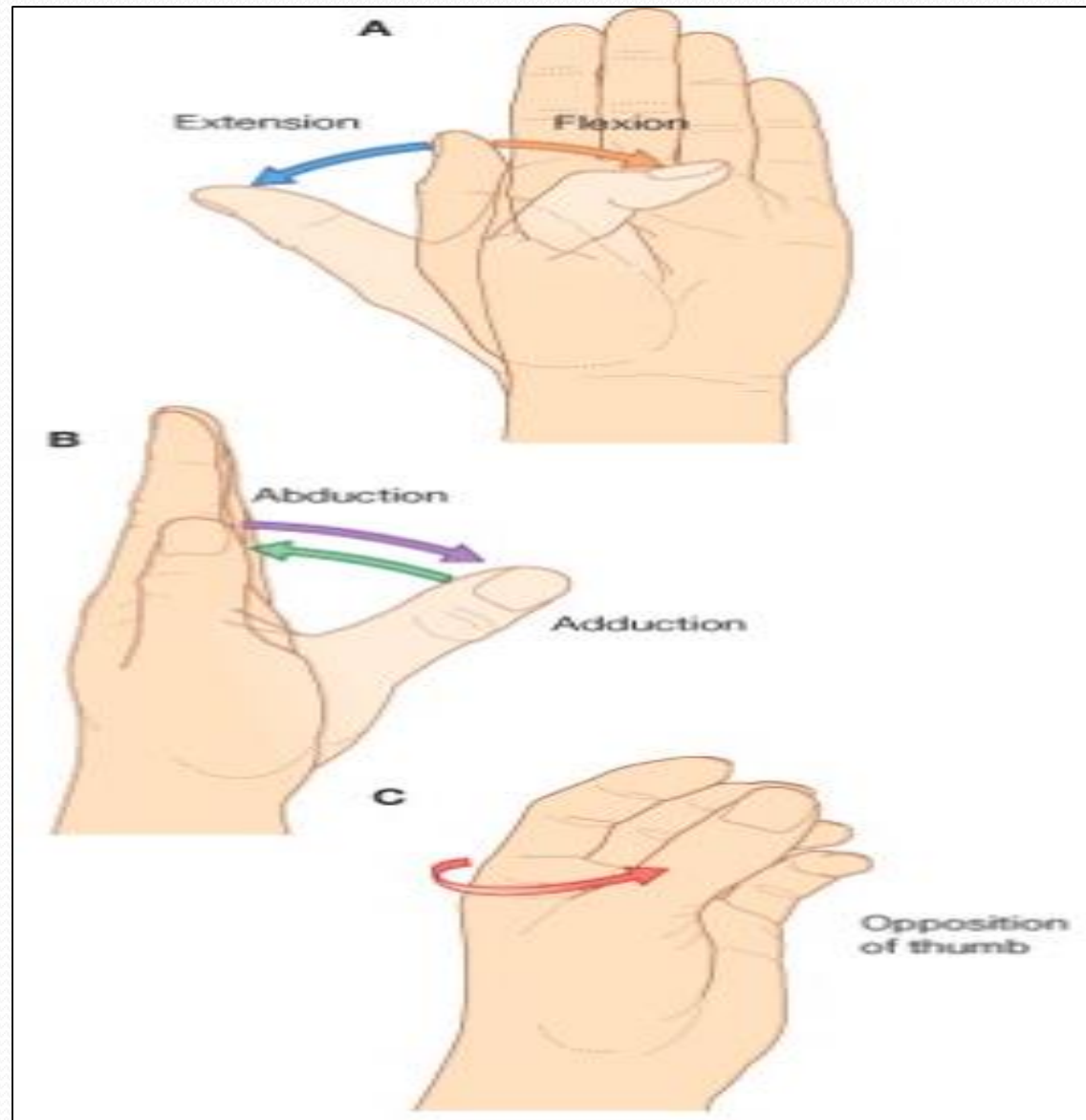
	Origin	Insertion	NS	ACT
Ab Poll B	FR Scaphd & Trapez	(Base of Prox ph)	All from Median N	AB
Flex Poll B	FR	With AB Poll B		FLX
Opp Poll	FR	Lateral part of 1 ST Met		Opp

Adductor Pollicis



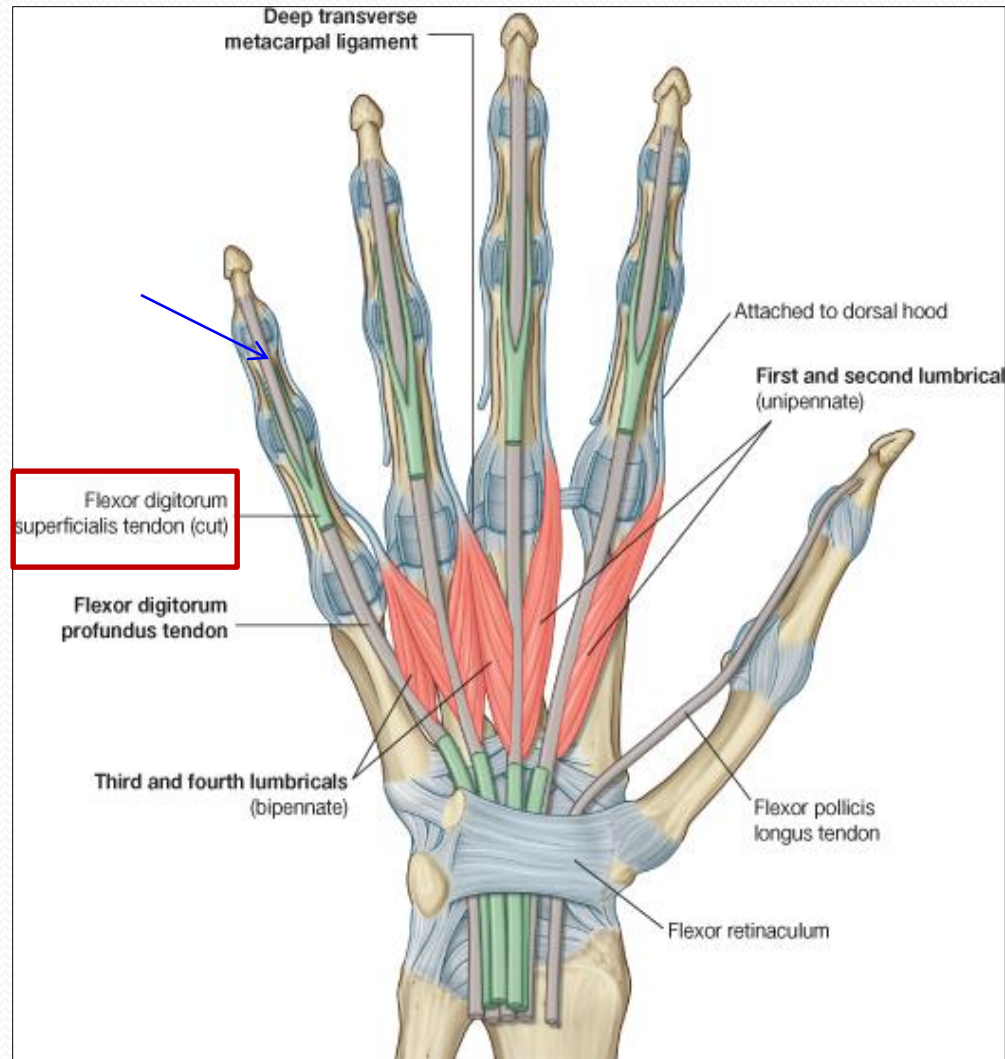
Origin	Insertion	Action	NS
Oblique Head: Ant. bases of 2 nd & 3 rd meta	Medial side of base of prox.ph of thumb	Add	Deep branch of Ulnar
Trans H: 3 rd meta			

Movements of Thumb

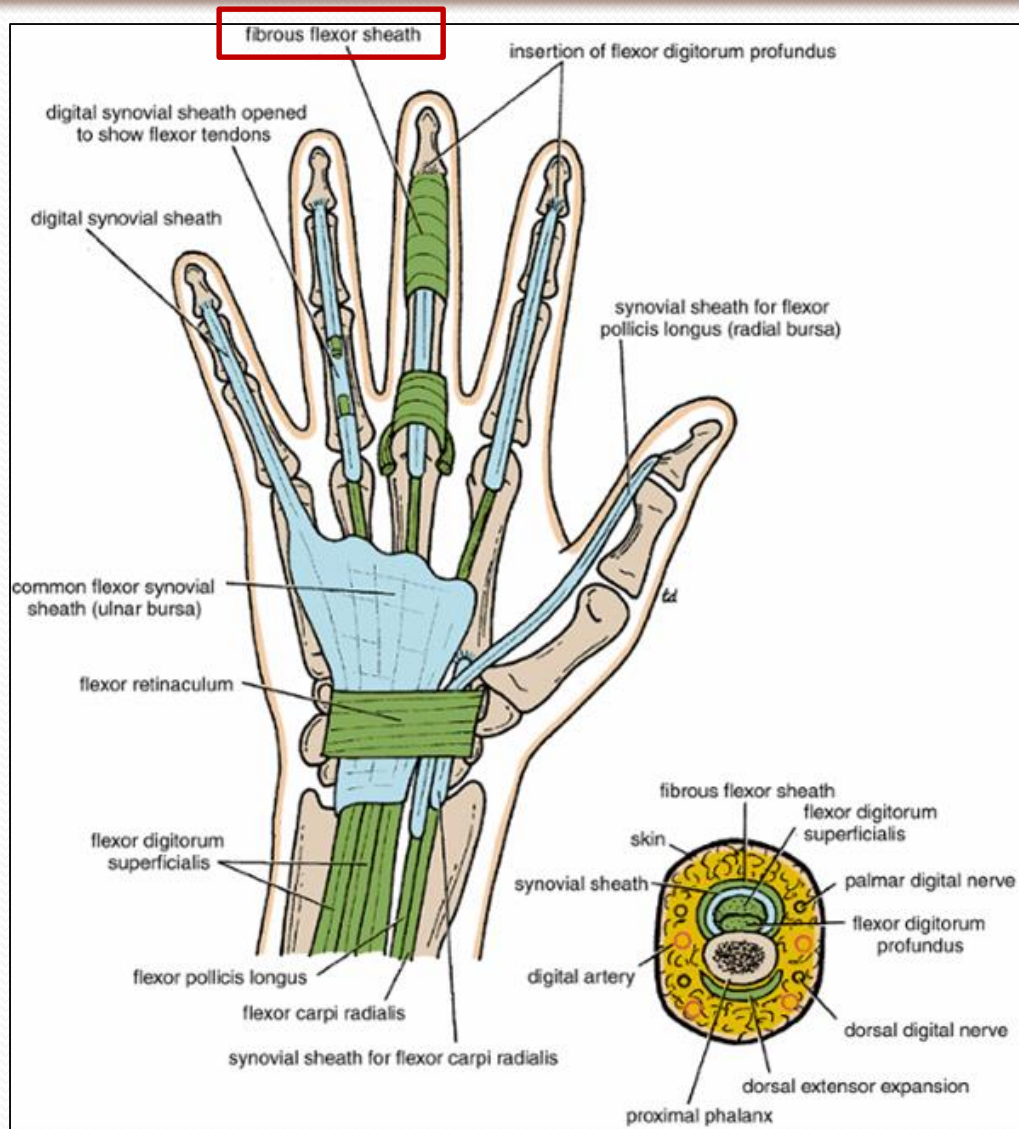


Insertion of Flexor Dig Superficialis & Profundus

- **Flexor dig superficialis**
- *Each tendon:*
 - **Divides** into two halves & pass around the Profundus Tendon.
 - The two halves **Meet** on the posterior aspect of Profundus tendon (partial decussation of fibers).
 - **Reunion** of the two halves.
 - **Further Division into two slips** attached to the **Borders of Middle Phalanx**.
- **Flexor dig Profundus**
 - Inserted into the **Base of the Distal Phalanx**.



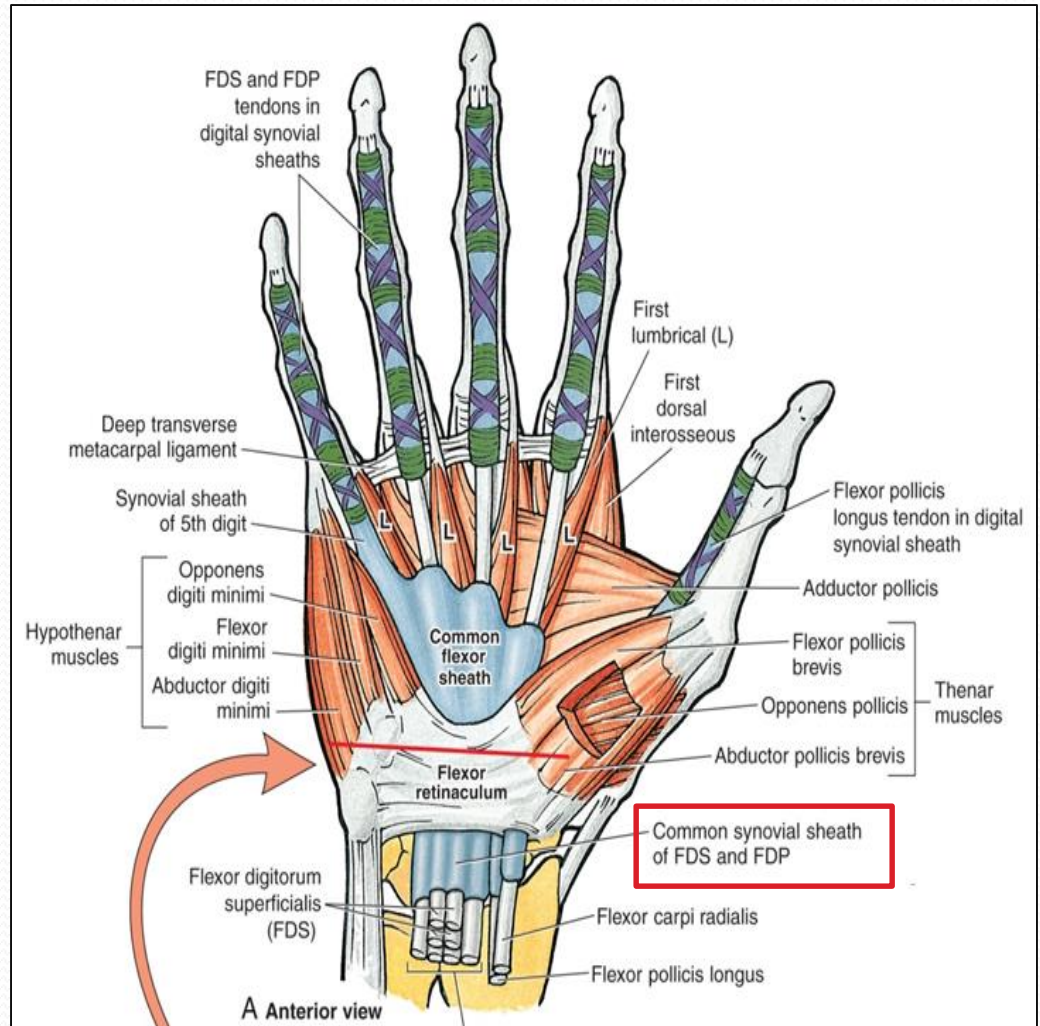
Fibrous Flexor (Digital) Sheath



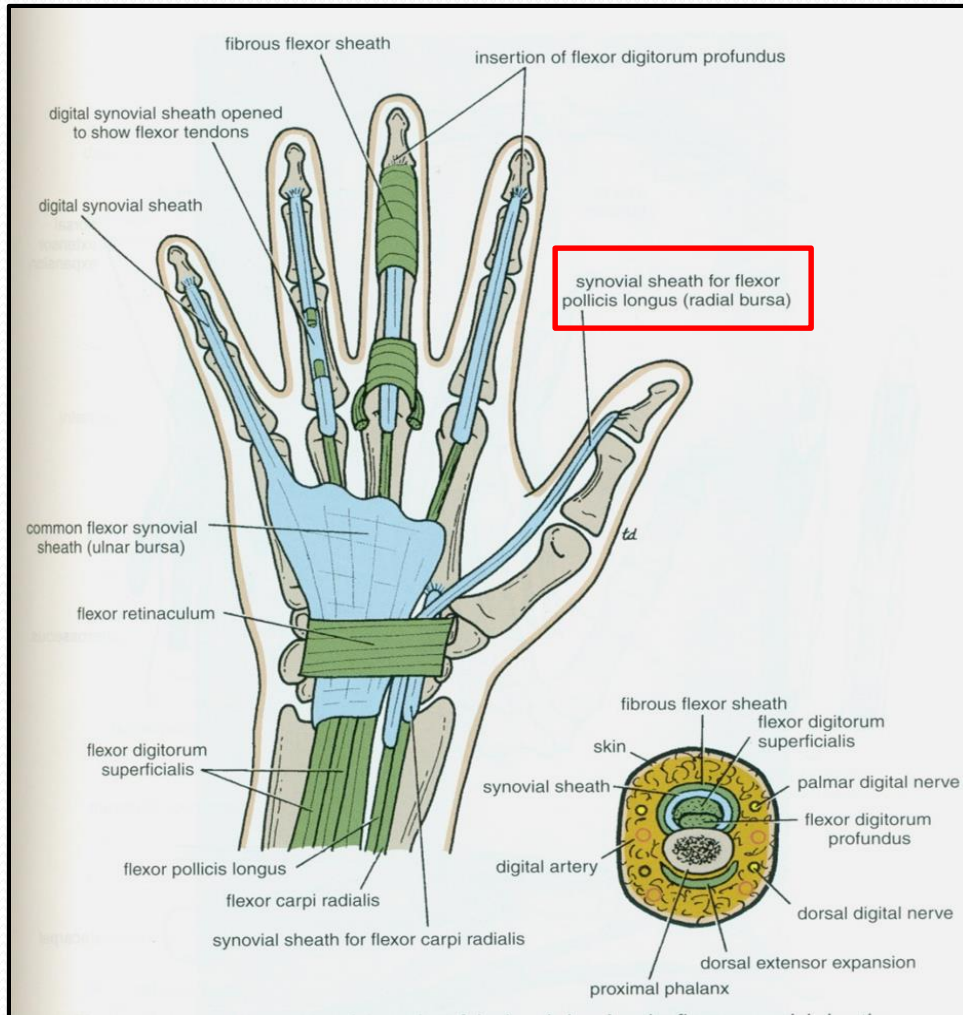
- **A Strong Fibrous Sheath**, which covers the anterior surface of the fingers and attached to the sides of the phalanges.
- Its Proximal end is **opened**
- Its Distal end is **closed**
- The Sheath with the anterior surfaces of the phalanges & the interphalangeal joints form an **Osteofibrous blind Tunnel** for the long flexor tendons of the fingers.

Synovial Flexor Sheaths

- [Common Synovial sheath](#) (*Ulnar Bursa*)
 - Contains tendons of Flexor Digitorum Superficialis & Profundus
 - The **Medial** part of the sheath extends distally (without interruption) on the tendons of the *little finger*.
 - The **Lateral part** of the sheath **stops** on the middle of the palm.
 - The distal ends of the long flexor tendons to (*Index, Middle & Ring*) fingers acquire *Digital Synovial Sheaths*.

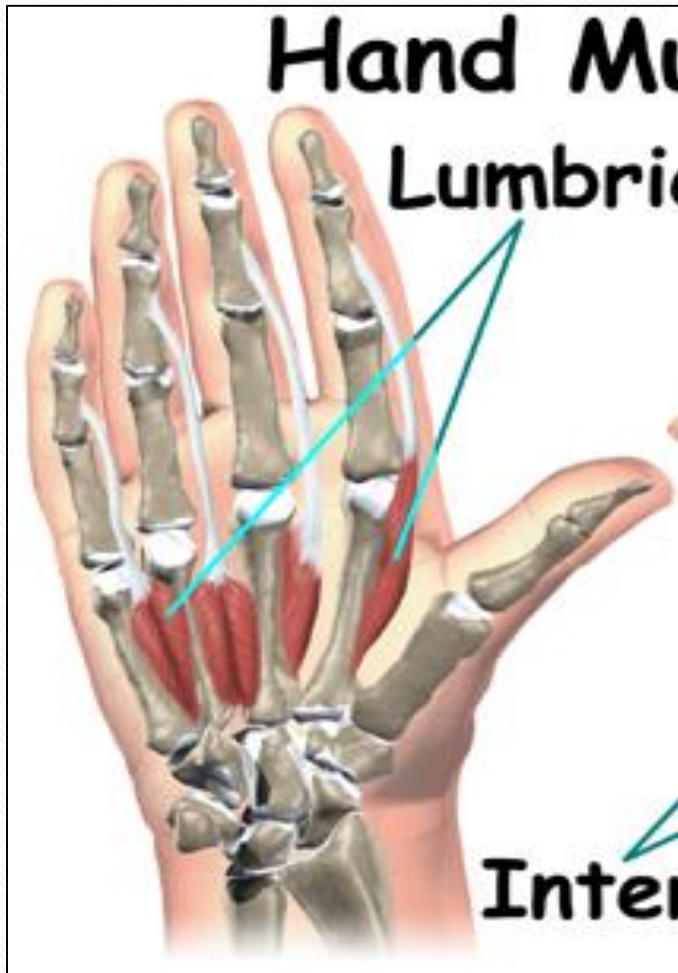

Synovial Flexor Sheaths

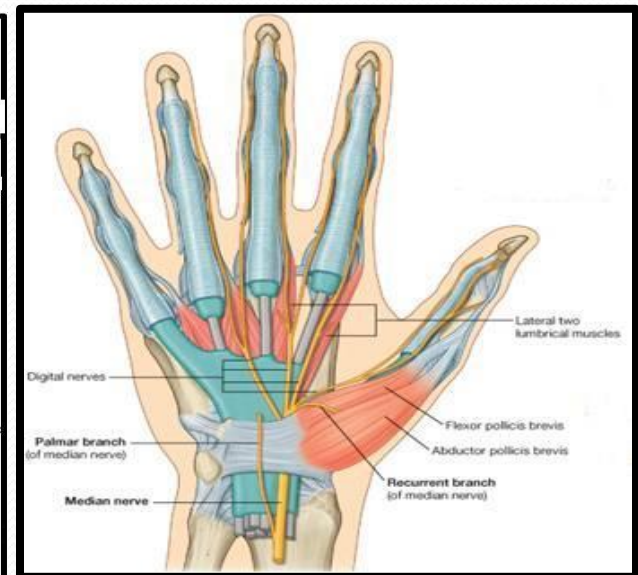
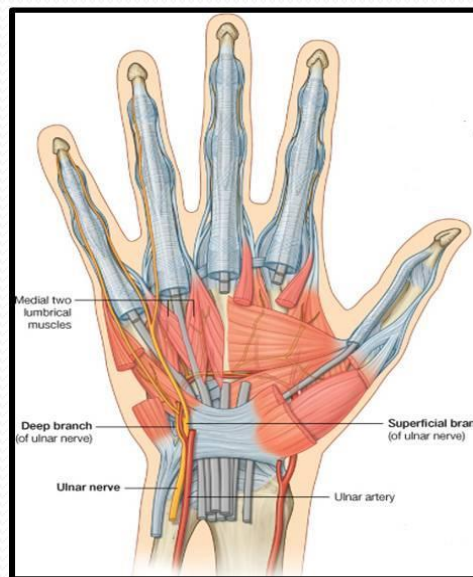


- ***Flexor Pollicis Longus*** tendon has its own synovial sheath (**Radial Bursa**)
- **Function of Synovial Sheaths:**
- ***They allow the long tendons to move smoothly with a minimum of friction beneath the flexor retinaculum and the fibrous flexor sheaths.***

Lumbrical Muscles (4)



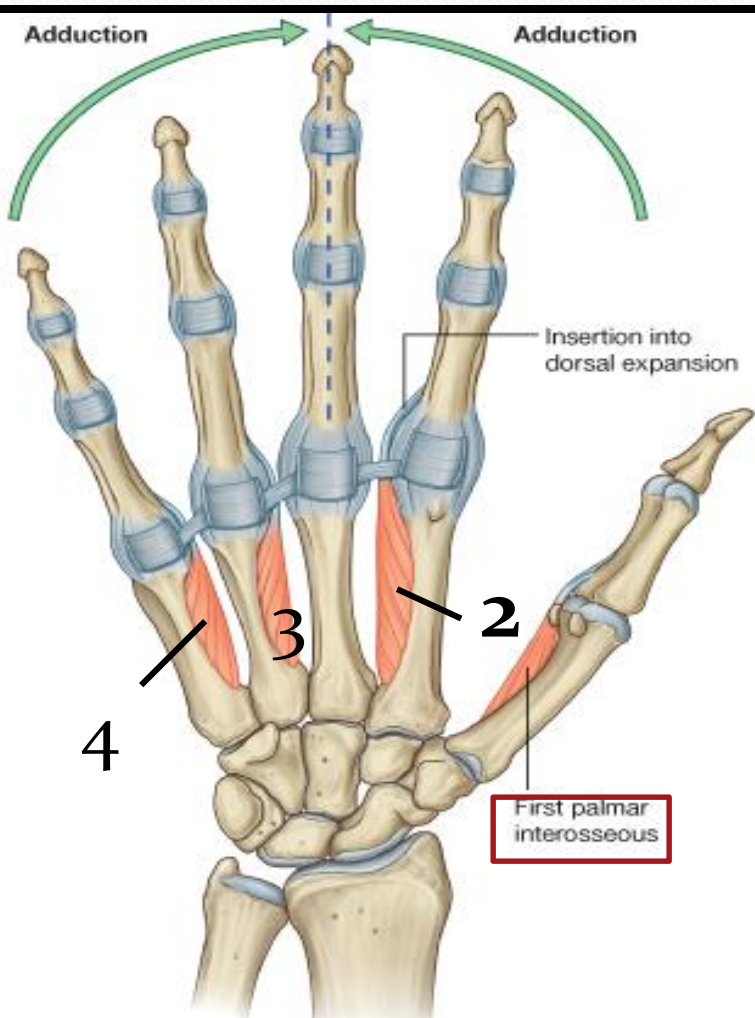
Origin	Insertion	NS
Tendons of Flex.dig. profundus	EXT. EXP of medial four fingers	1 ST & 2 ND (Lateral two) : Median N. 3 RD & 4 TH : Ulnar N (Deep branch)



Action:

Flex metacarpophalangeal joints and extend interphalangeal joints of fingers **Except thumb**

Palmar Interossei (4)

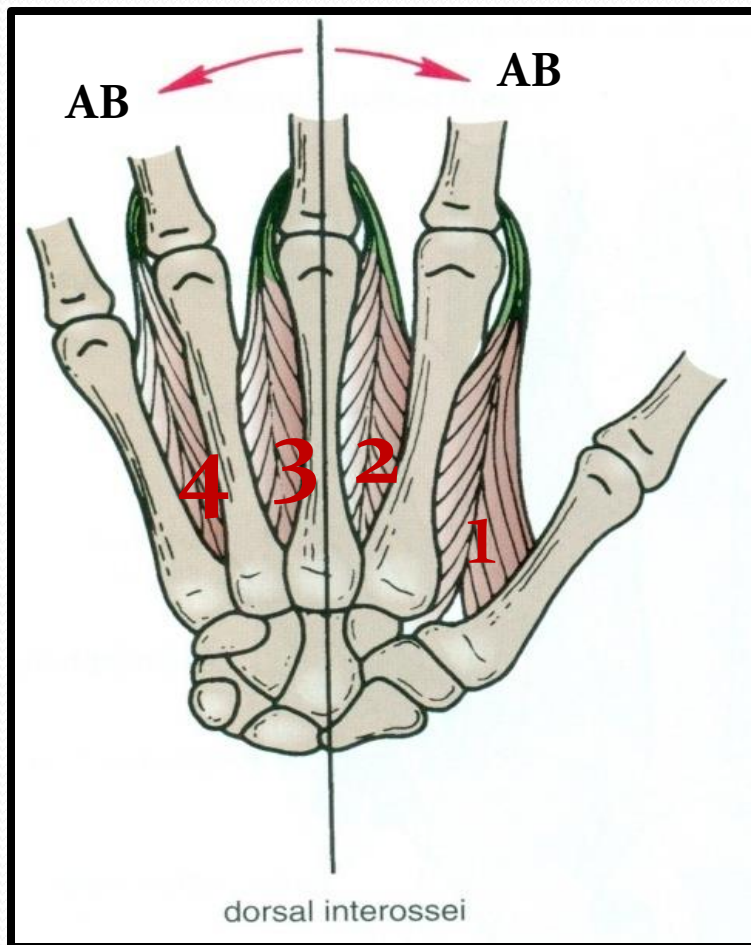


Origin	Insertion	NS
<p>1st : Base of 1st metacarpal.</p> <p>Other three: Ant. Surface of Shafts of 2nd , 4rd & 5th metacarpals.</p>	<p>Proximal phalanges of thumb ,index, ring, & little fingers and</p> <p>Extensor expansion</p>	<p>Un: deep Branch</p>

Action:

Adduction of fingers toward center of the 3rd one.

Dorsal Interossei (4)

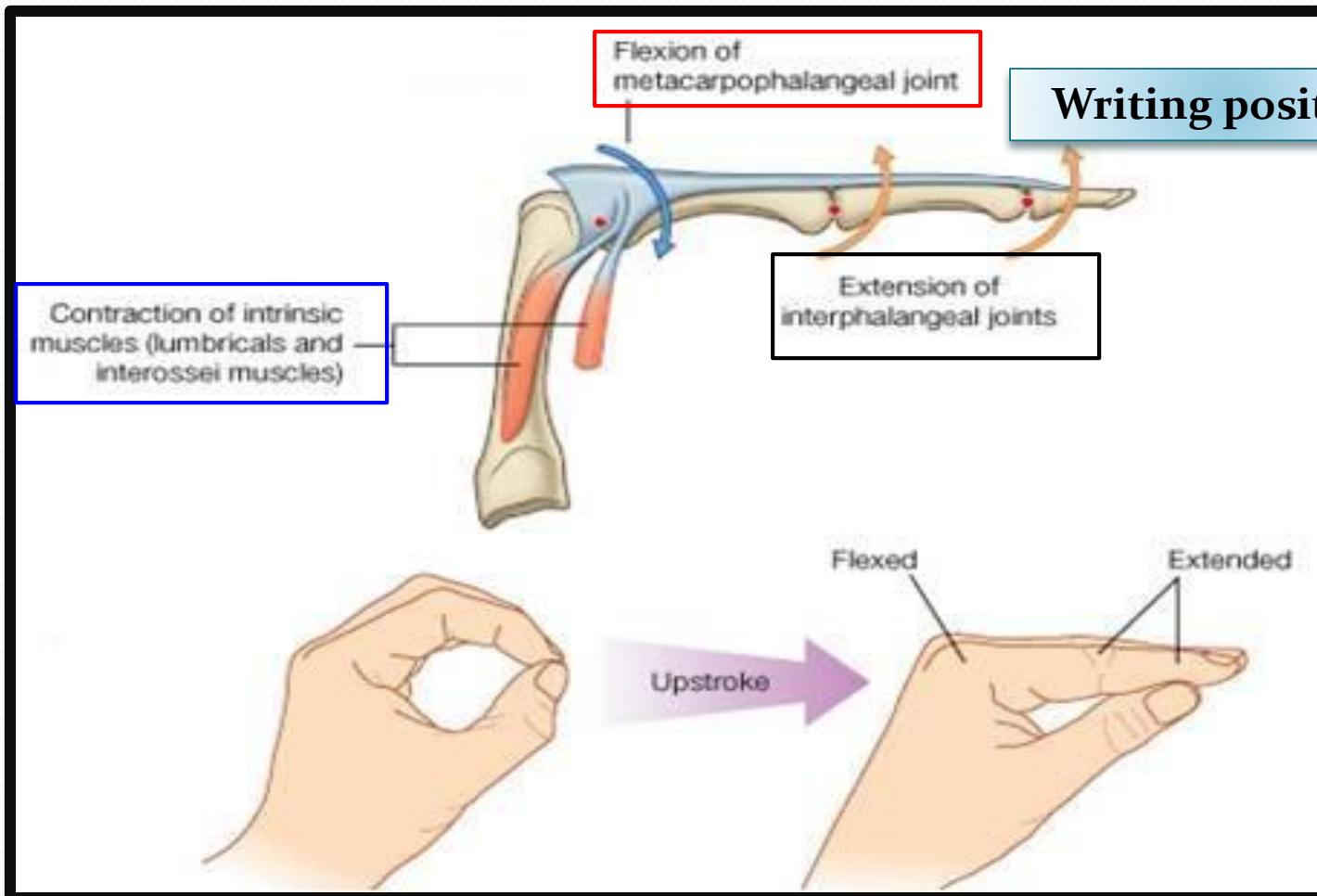


Origin	Insertion	NS
Contiguous sides of shafts of Metacarpals	Proximal Phalang of index, ring, mid finger & EX	Un deep Branch

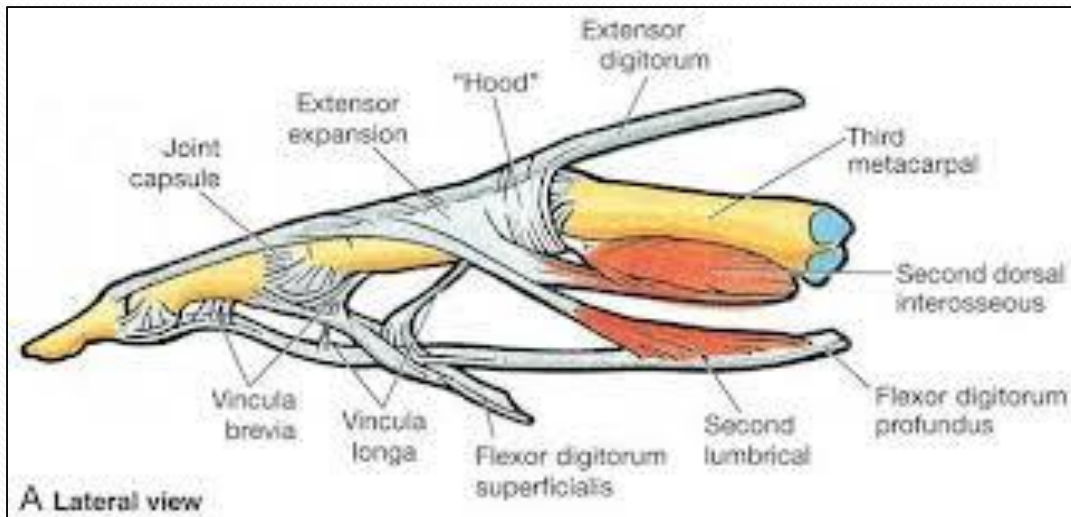
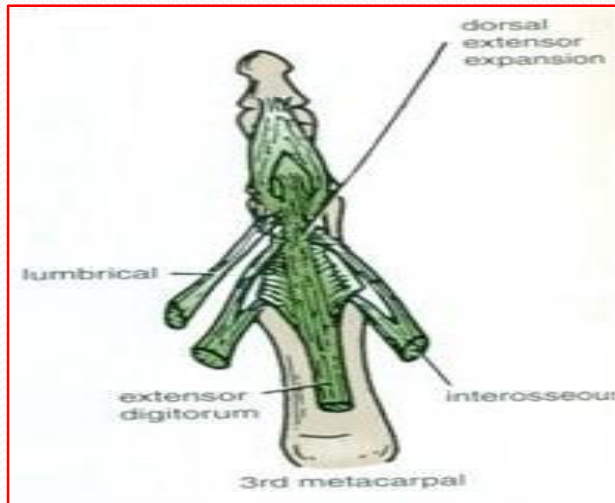
Action:

Abduction of fingers away from the 3rd one.

Action of Lumbricals & Interossei



Extensor Expansion



- Formed from the expansion of the tendons of extensor dig. at the PIJ,
- The tendon splits into three parts:
 - **One Central:** inserted into the base of **Middle phalanx**.
 - **Two laterals:** inserted into the base of the **Distal phalanx**.
- The Expansion Receives the insertions of:
 - Corresponding **Interosseous** muscle (on each side).
 - **Lumbrical** muscle (on the lateral side).



Thank You