

**Popliteal fossa,
Posterior compartment of leg
&
Sole of foot**

BY ANATOMY DEPARTMENT

DR.SANAA AL- SHAARAWY

DR.SAEED VOHRA

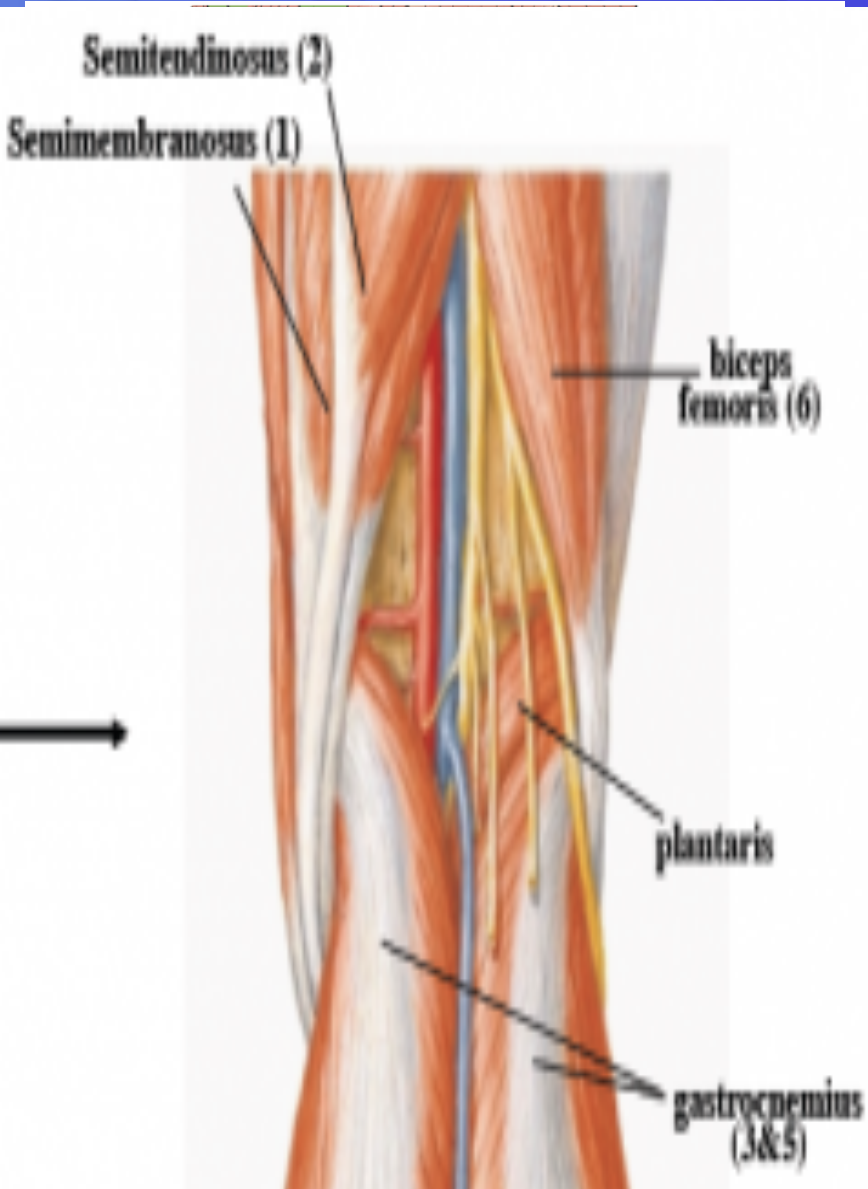
OBJECTIVES

At the end of this lecture the students should be able to know:

- The location, boundaries & contents of the popliteal fossa
- The contents of posterior fascial compartment of Leg.
- The structures held by retinacula at ankle.
- Layers forming in the sole of foot & bone forming the arches of the foot.

Popliteal Fossa

Is a diamond-shaped intermuscular space at the back of knee



Boundaries :

Laterally: above: biceps femoris.

Below: lateral head of gastrocnemius & plantaris

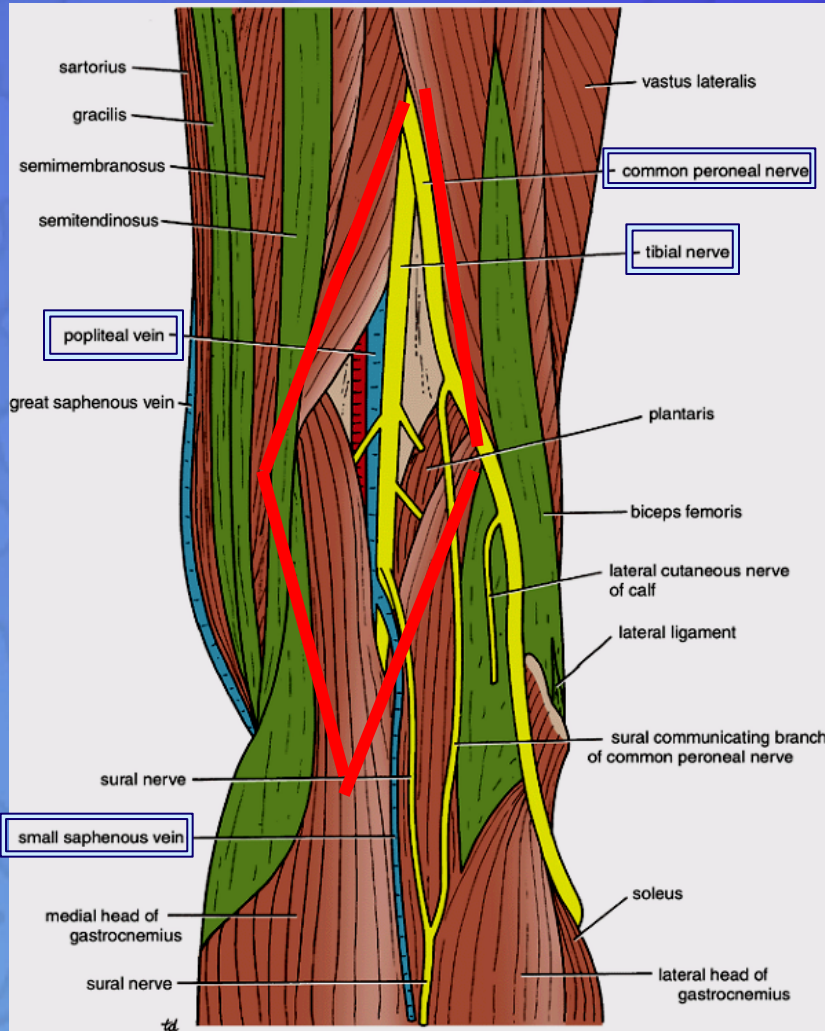
Medially: above: semimembranosus & semitendinosus.

Below: medial head of gastrocnemius

Roof: Skin, superficial fascia and deep fascia of the thigh.

Floor: popliteal surface of femur, posterior ligament of knee joint and popliteus muscle.

Popliteal Fossa



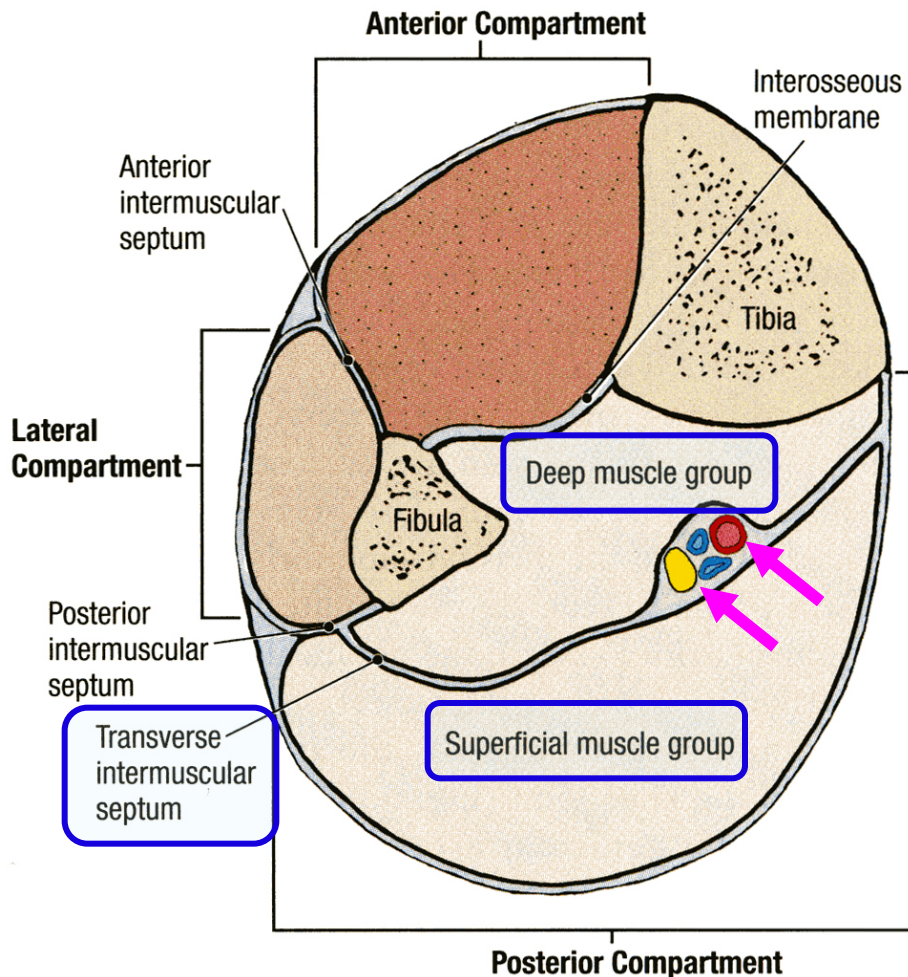
Contents:

From medial to lateral

1. Popliteal vessels
2. Small saphenous vein
3. Tibial nerve.
4. Common peroneal nerve.
5. Posterior cut. nerve of thigh.
6. Connective tissue & popliteal lymph nodes.

The deepest structure is popliteal artery.

CONTENTS OF THE POSTERIOR FASCIAL COMPARTMENT OF THE LEG



The transverse intermuscular septum of the leg is a septum divides the muscles of the posterior compartment into superficial and deep groups.

Contents:

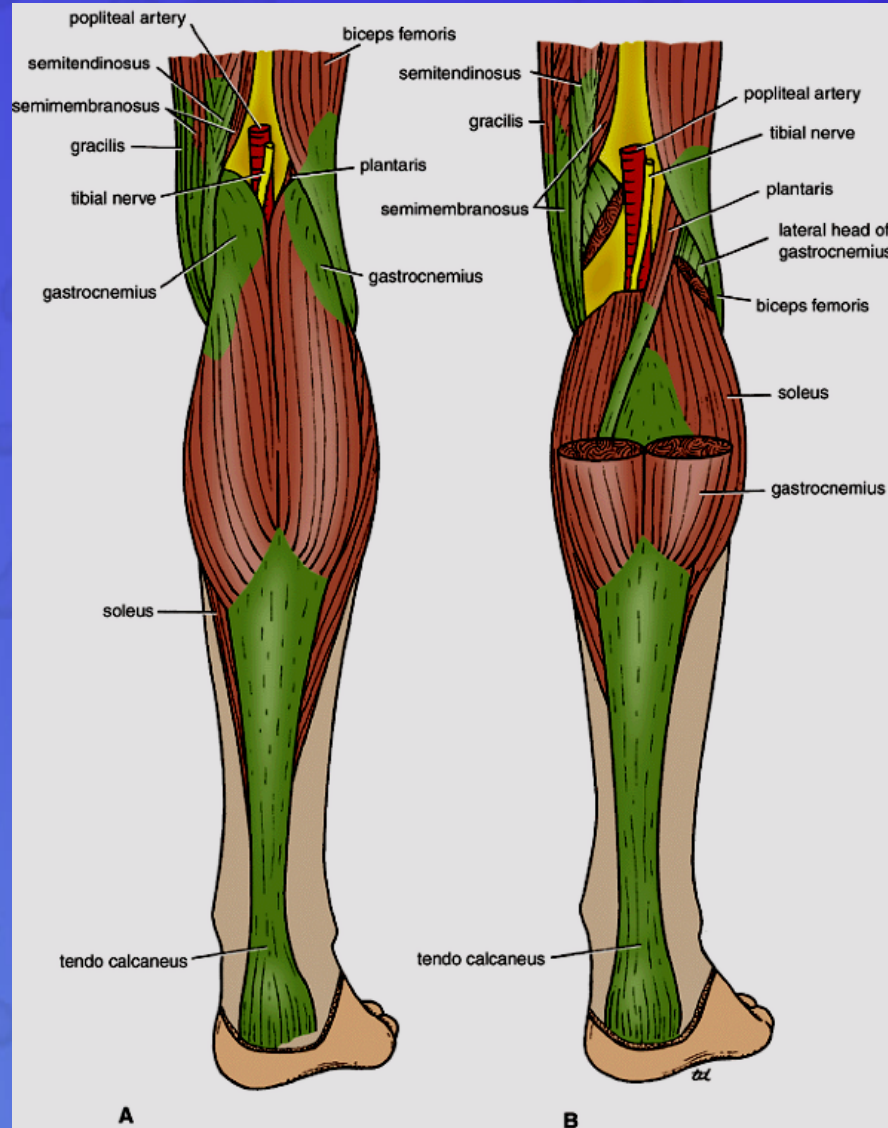
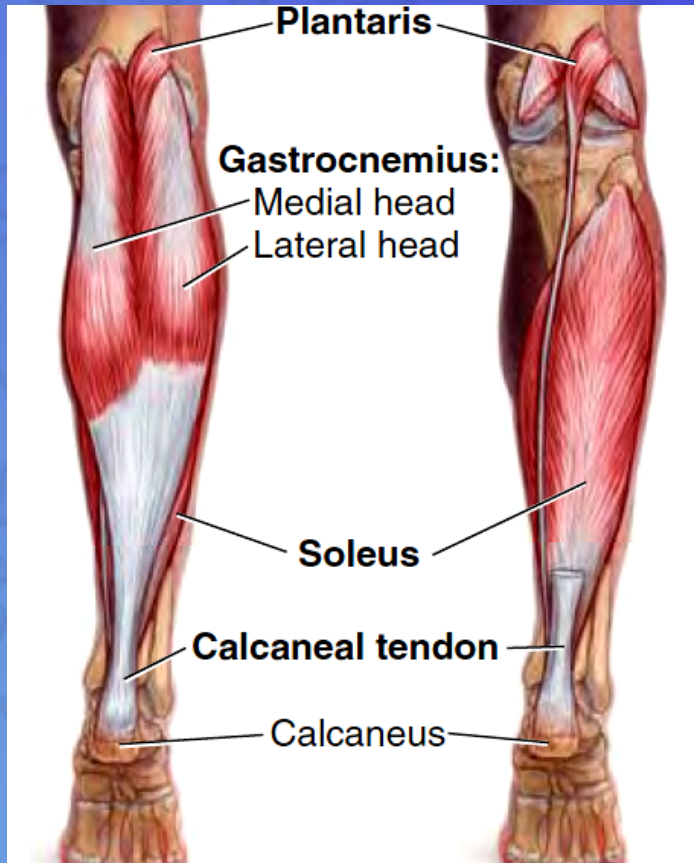
1. Superficial group of muscles
2. Deep group of muscles
3. Posterior tibial artery
4. Tibial nerve

SUPERFICIAL GROUP

1. Gastrocnemius

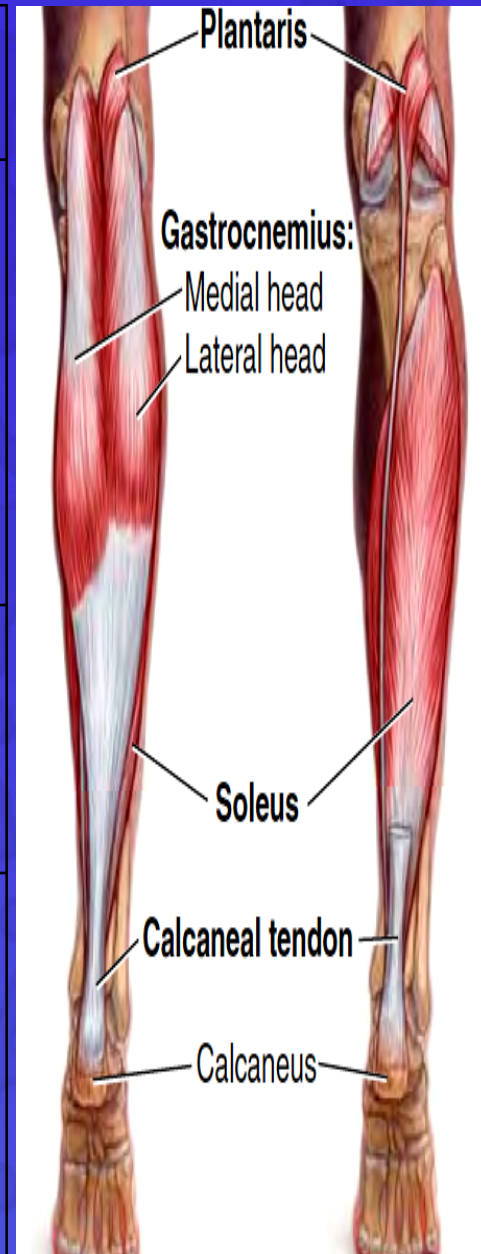
2. Plantaris

3. Soleus



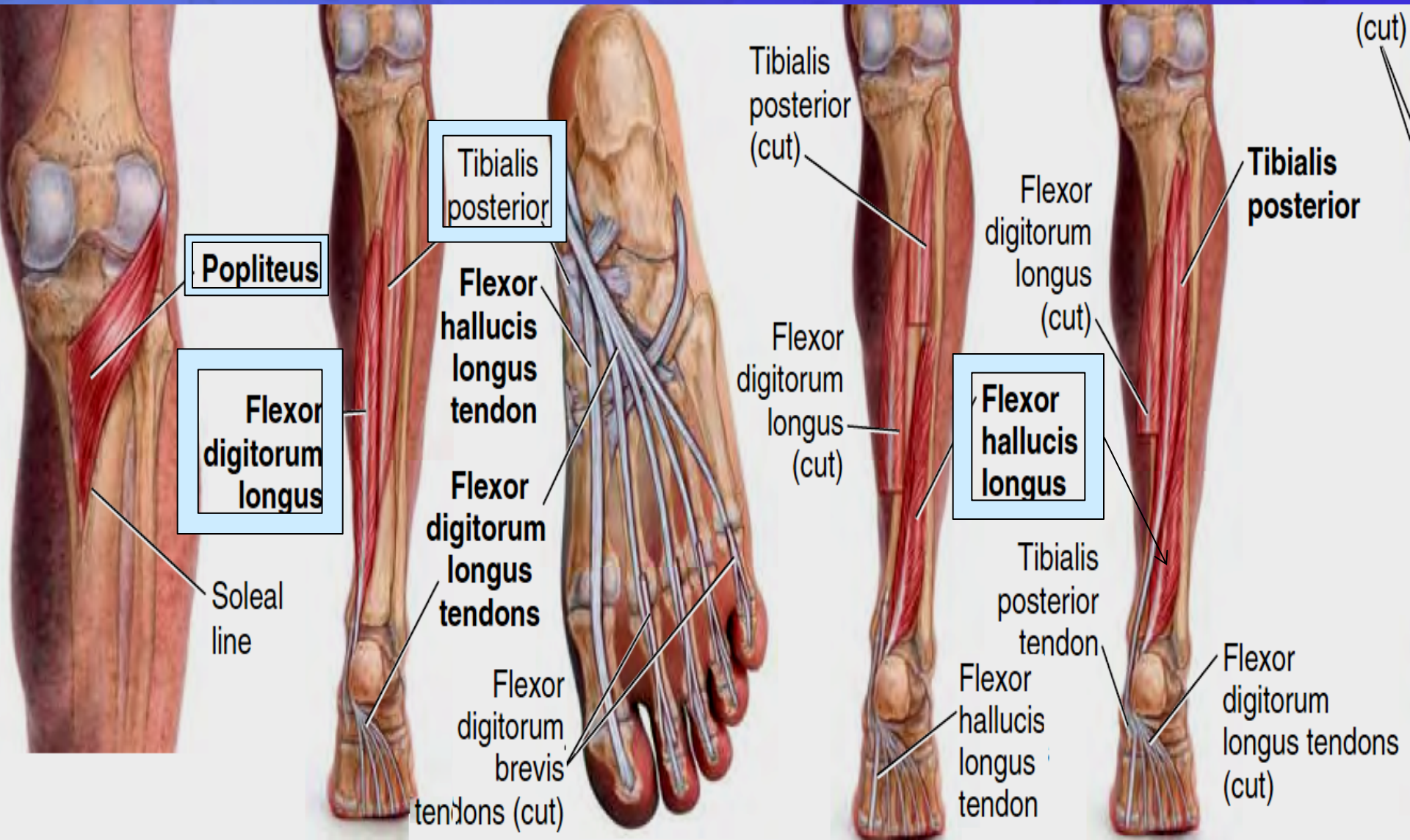
SUPERFICIAL GROUP

Muscle	Origin	Insertion	Nerve	Action
Gastrocnemius	Lateral head from lateral condyle of femur & medial head from above medial condyle	Posterior surface of calcaneum via tendo calcaneus	Tibial	Plantar flexes foot at ankle joint; flexes knee joint
Plantaris	Lateral supracondylar ridge of femur	Posterior surface of calcaneum	Tibial	Plantar flexes foot at ankle joint; flexes knee joint
Soleus	Shafts of tibia and fibula	Posterior surface of calcaneum via tendo calcaneus	Tibial	Together with gastrocnemius and plantaris is powerful plantar flexor of ankle joint; provides main propulsive force in walking and running



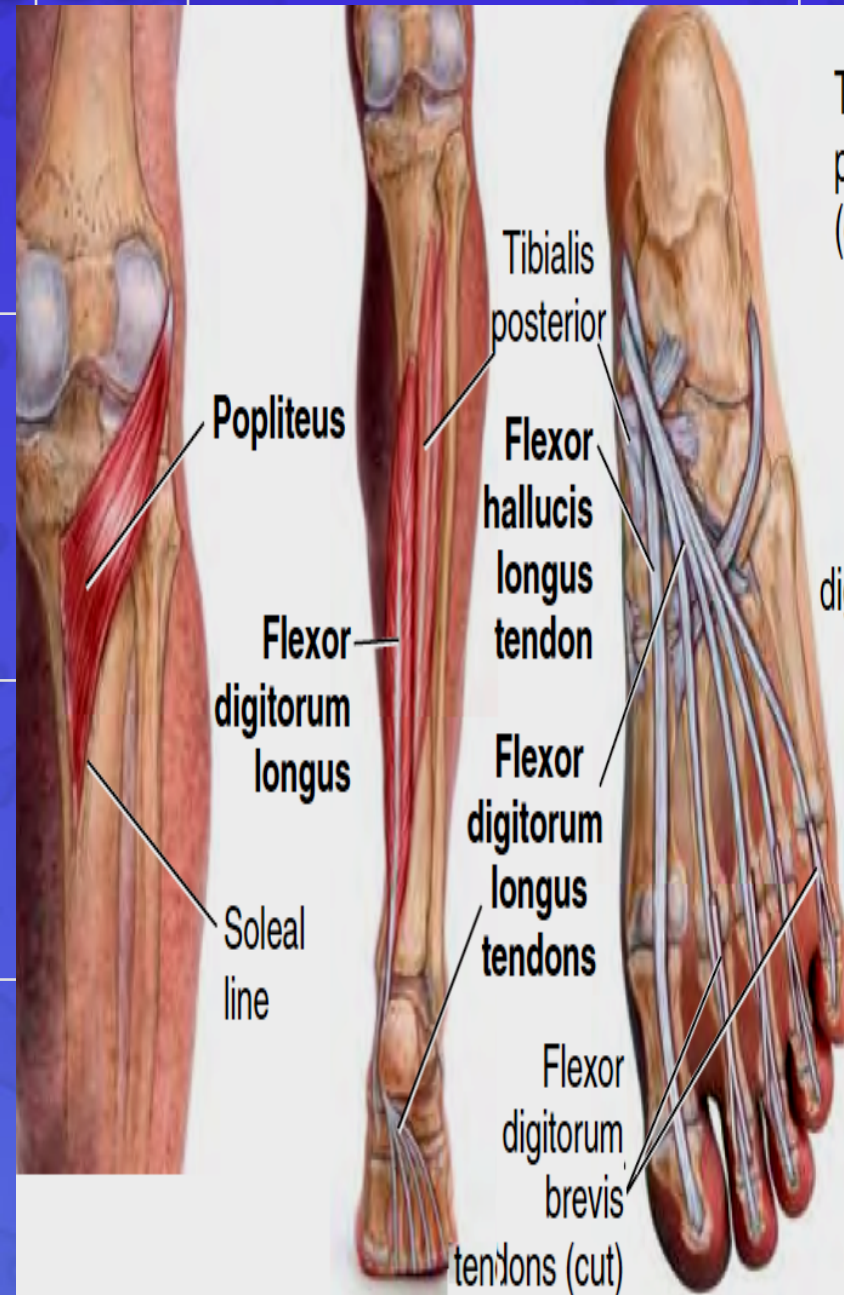
DEEP GROUP

1. Popliteus
2. Flexor digitorum longus
3. Tibialis posterior
4. Flexor hallucis longus



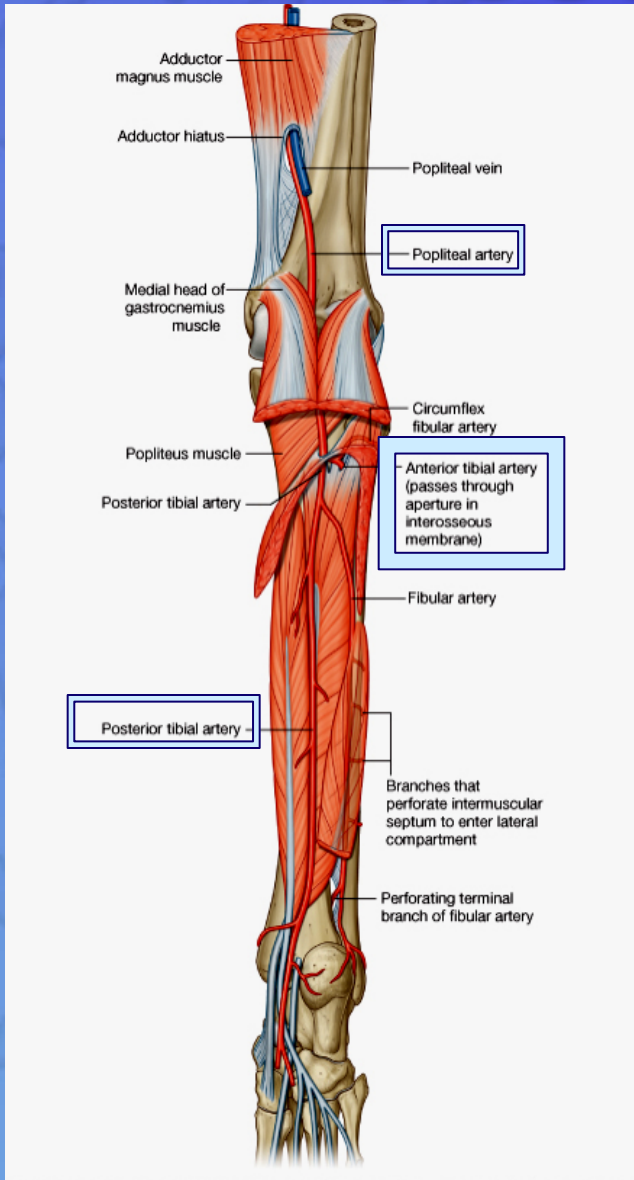
DEEP GROUP

Popliteus	Groove on Lateral surface of lateral condyle of femur (Intracapsular)	Post surface of shaft of tibia above soleal line
Flexor digitorum longus	Posterior surface of shaft of tibia	Bases of distal phalanges of lateral 4 toes
Flexor hallucis longus	Posterior surface of shaft of fibula	Base of distal phalanx of big toe
Tibialis posterior	Posterior surface of shafts of tibia and fibula and interosseous membrane	Tuberosity of navicular bone and other neighboring tarsal bones.

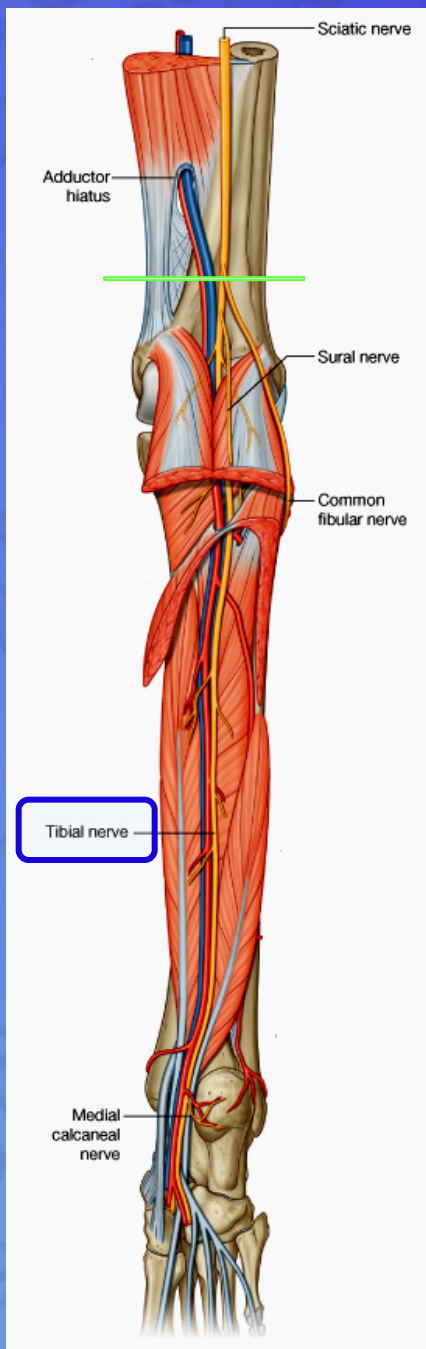


POSTERIOR TIBIAL ARTERY

- It is one of the terminal branches of the popliteal artery.



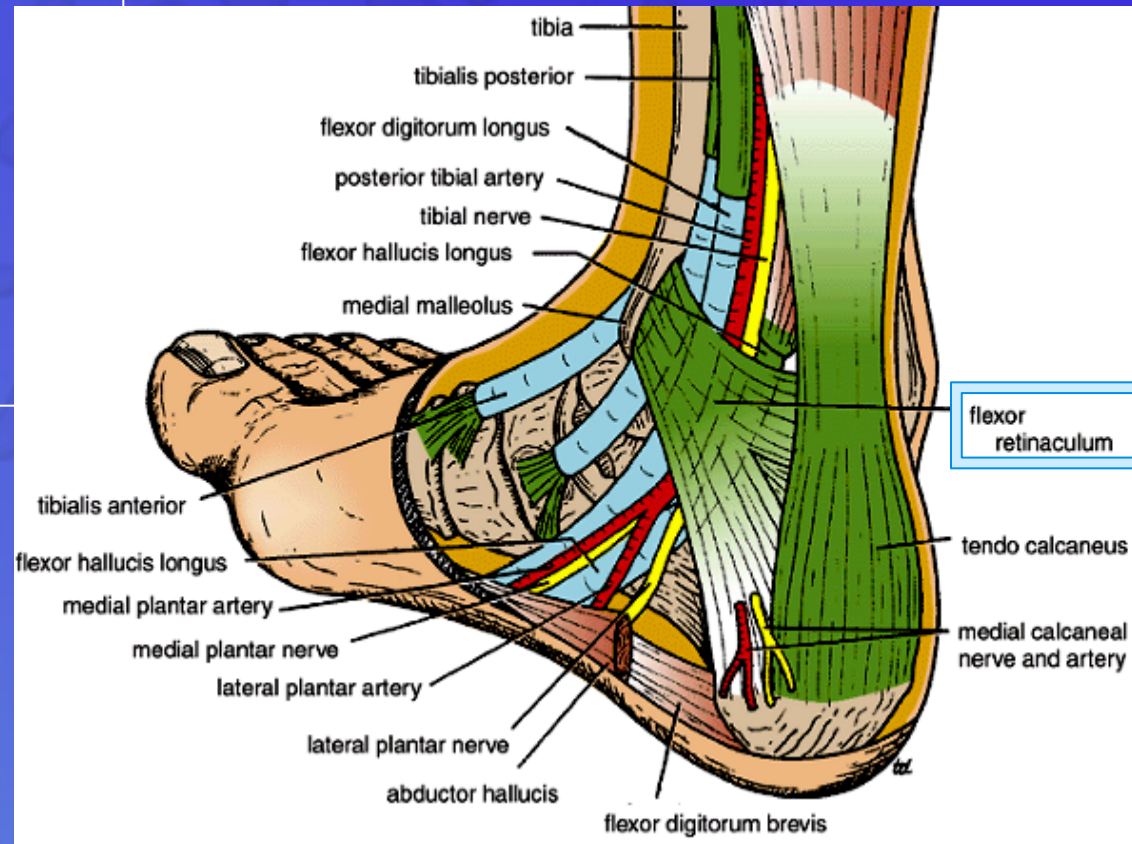
TIBIAL NERVE



- It is the larger terminal branch of the sciatic nerve in the lower 1/3 of the back of the thigh

Flexor Retinaculum

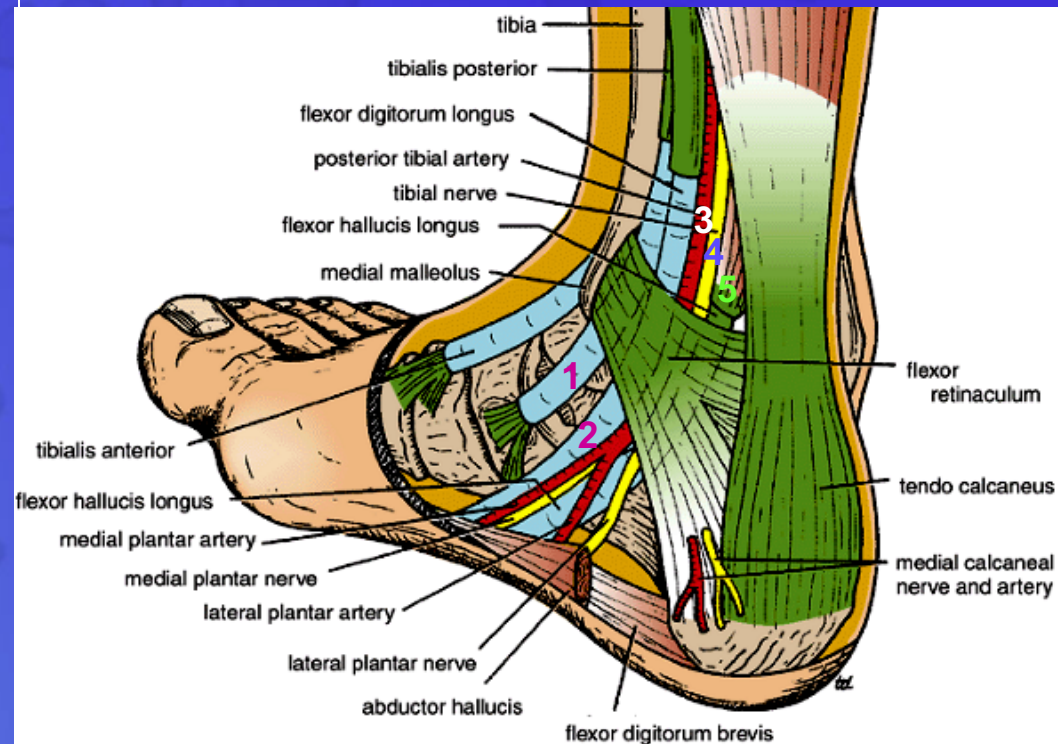
Extends from back of
medial malleolus of
tibia to
medial side of
calcaneum

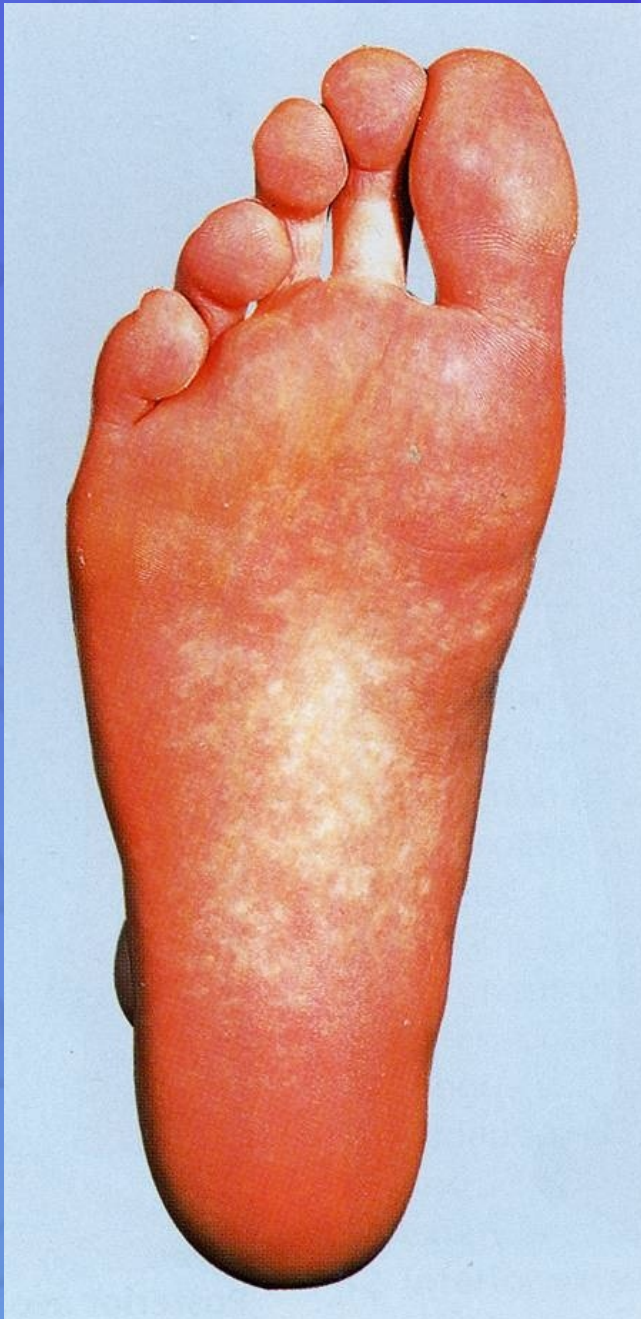


Structures passing posterior to medial malleolus, deep to flexor retinaculum

- *Medial to lateral*
- Tibialis posterior tendon
- Flexor digitorum longus tendon
- Posterior tibial artery with venae comitantes
- Tibial nerve
- Flexor hallucis longus tendon

All the tendons are surrounded by a synovial sheath



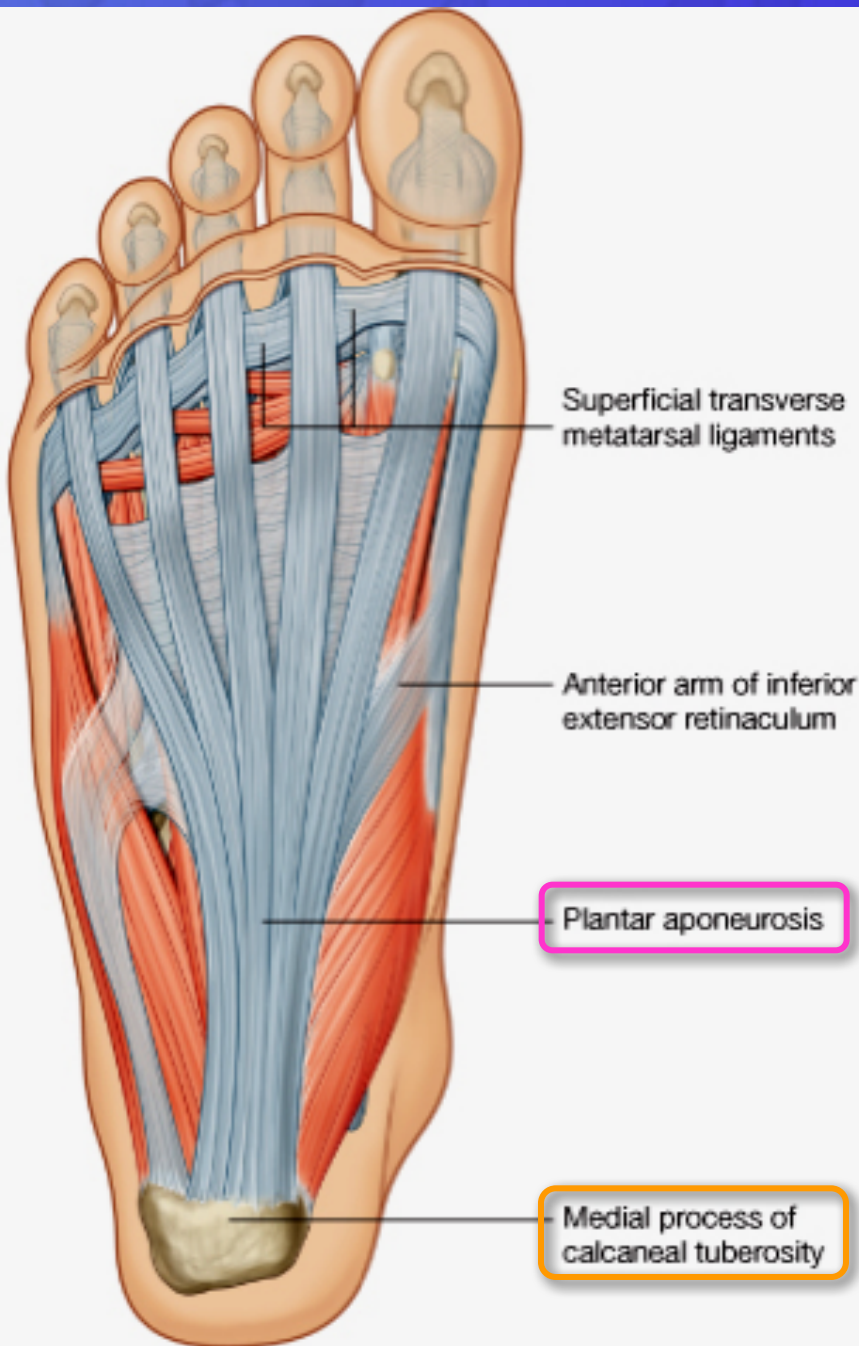


SOLE OF THE FOOT

- **The skin** of the sole of the foot is **thick and hairless**
- It shows a **few flexure creases** at the sites of skin movement
- **Sweat glands** are present in large numbers

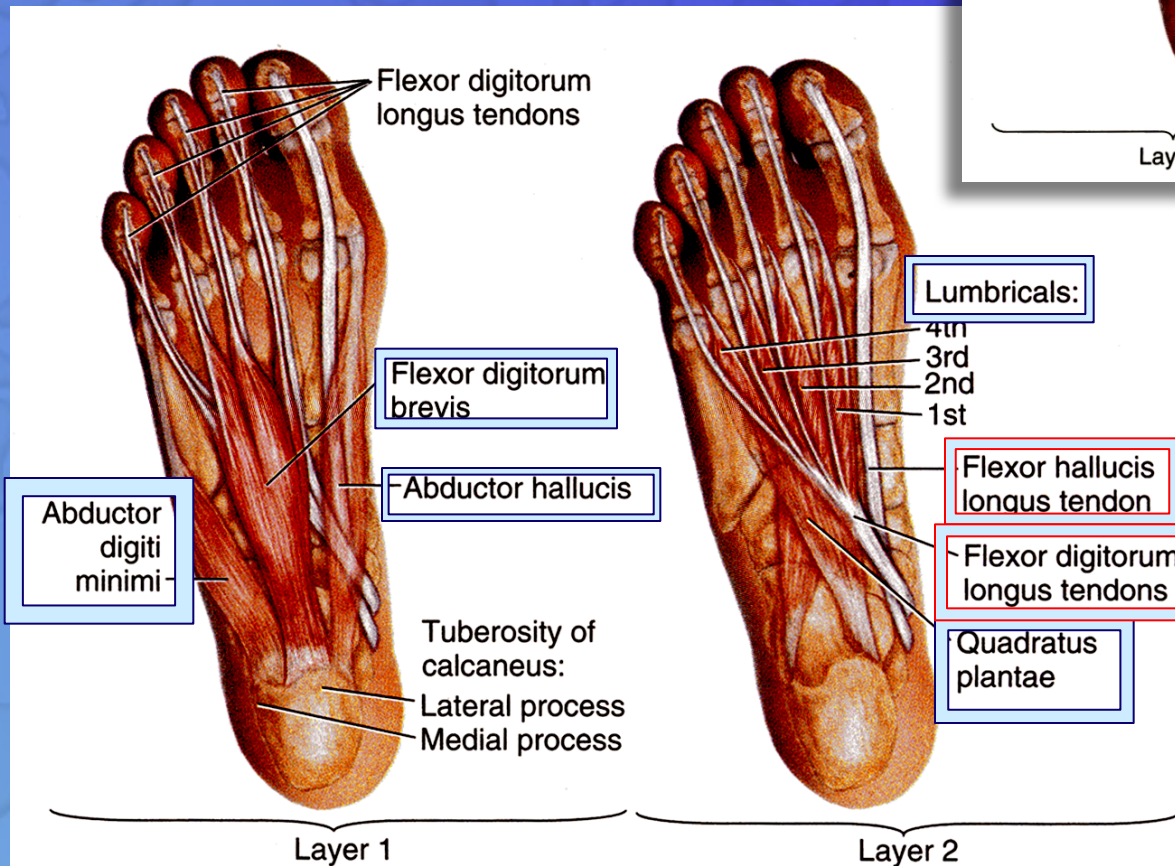
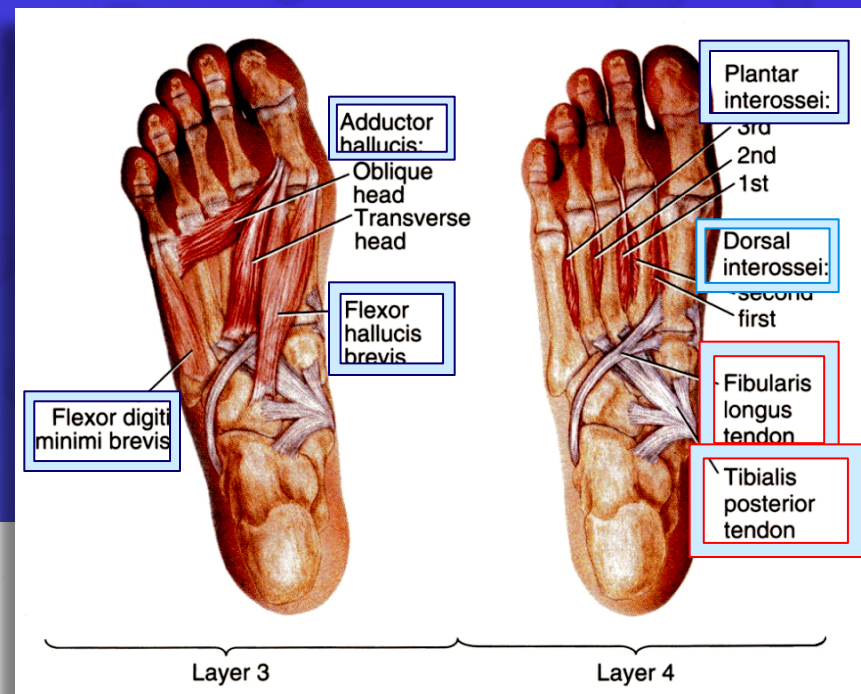
DEEP FASCIA

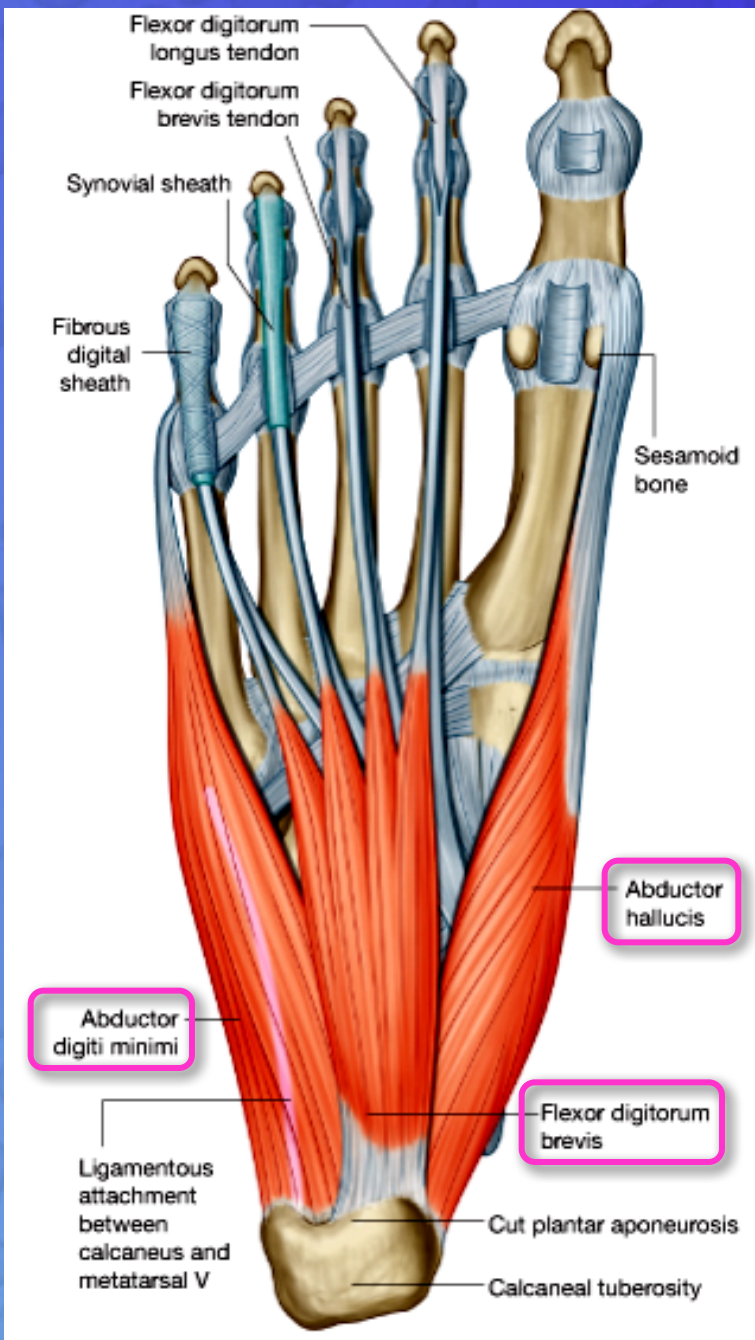
- The **plantar aponeurosis** is a triangular thickening of the deep fascia that protects the underlying nerves, blood vessels, and muscles.
- Its **apex** is attached to the *medial and lateral tubercles* of the **calcaneum.**
- The **base** of the aponeurosis divides into **five slips** that pass into the **toes.**



MUSCLES OF THE SOLE OF THE FOOT

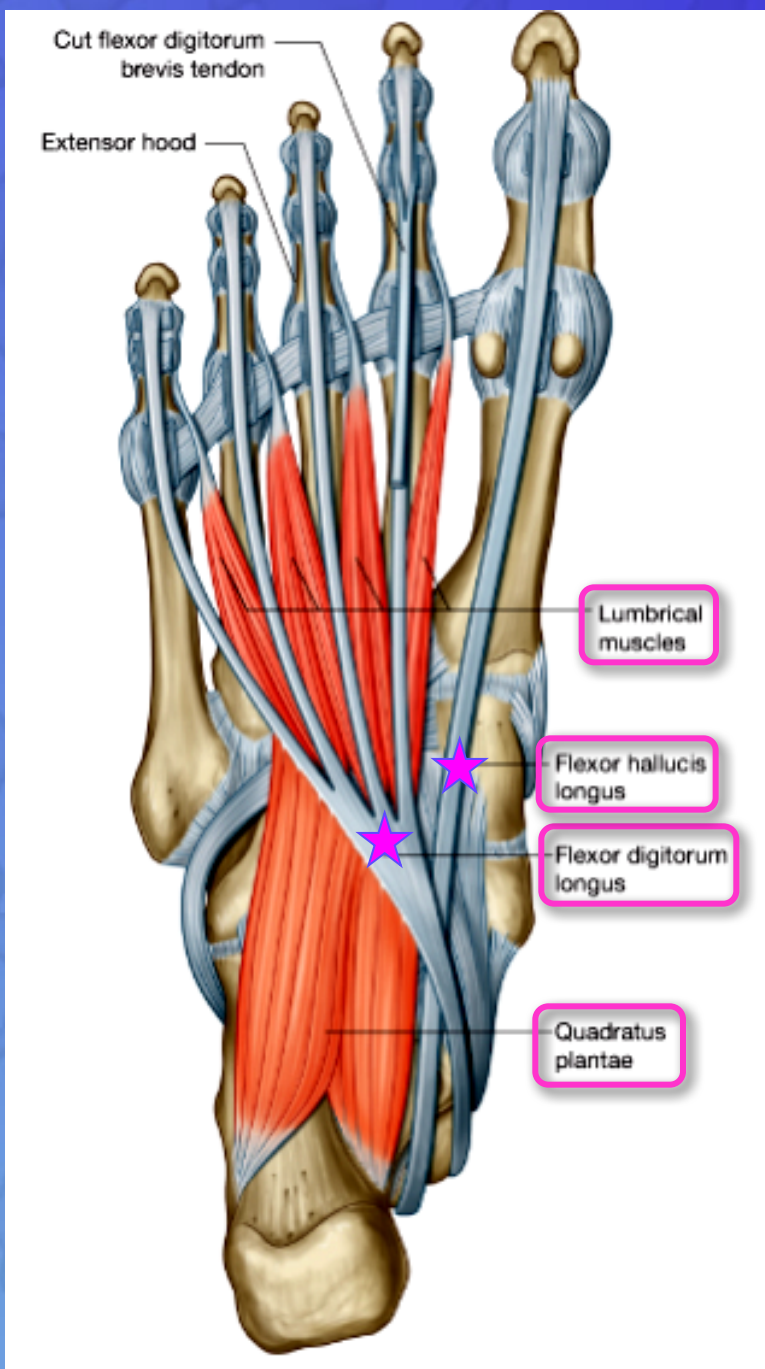
The muscles of the sole are conveniently described in **four layers** from superficial to deep.





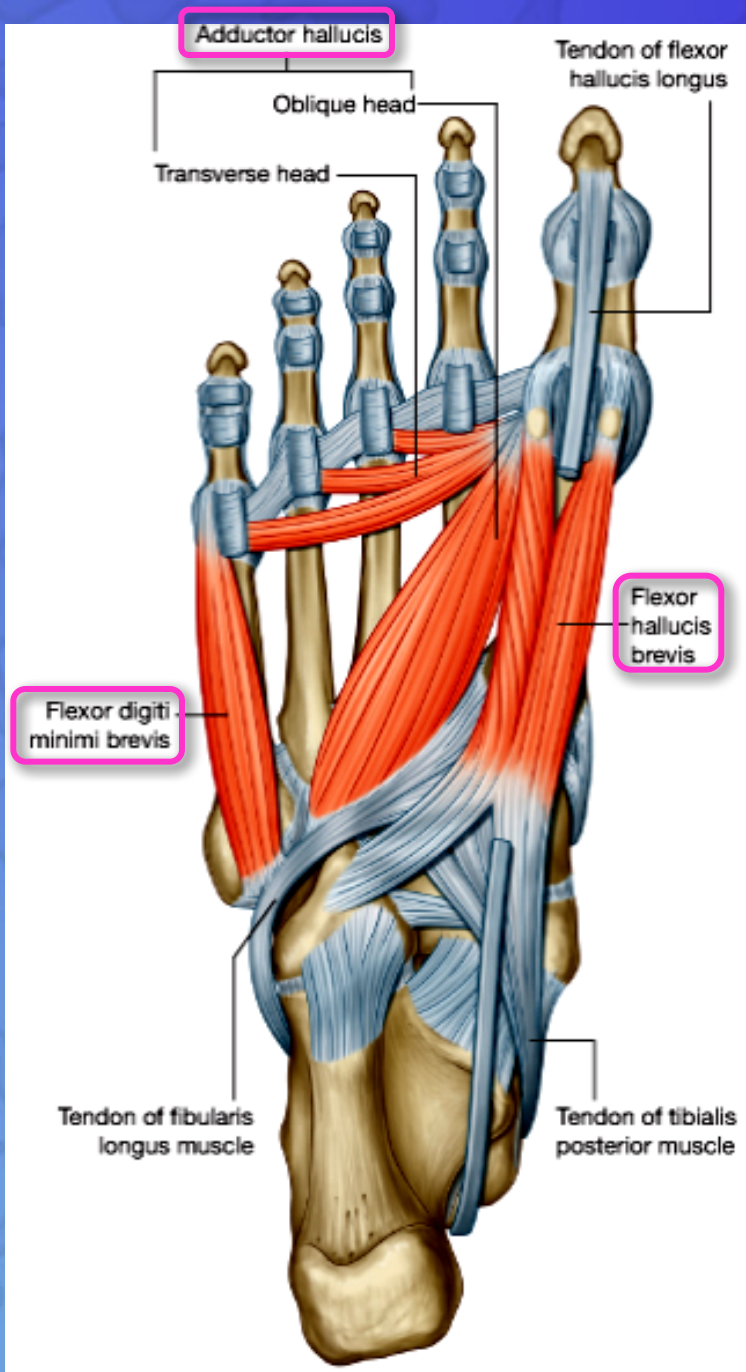
First Layer

1. Abductor hallucis,
2. Flexor digitorum brevis,
3. Abductor digiti minimi



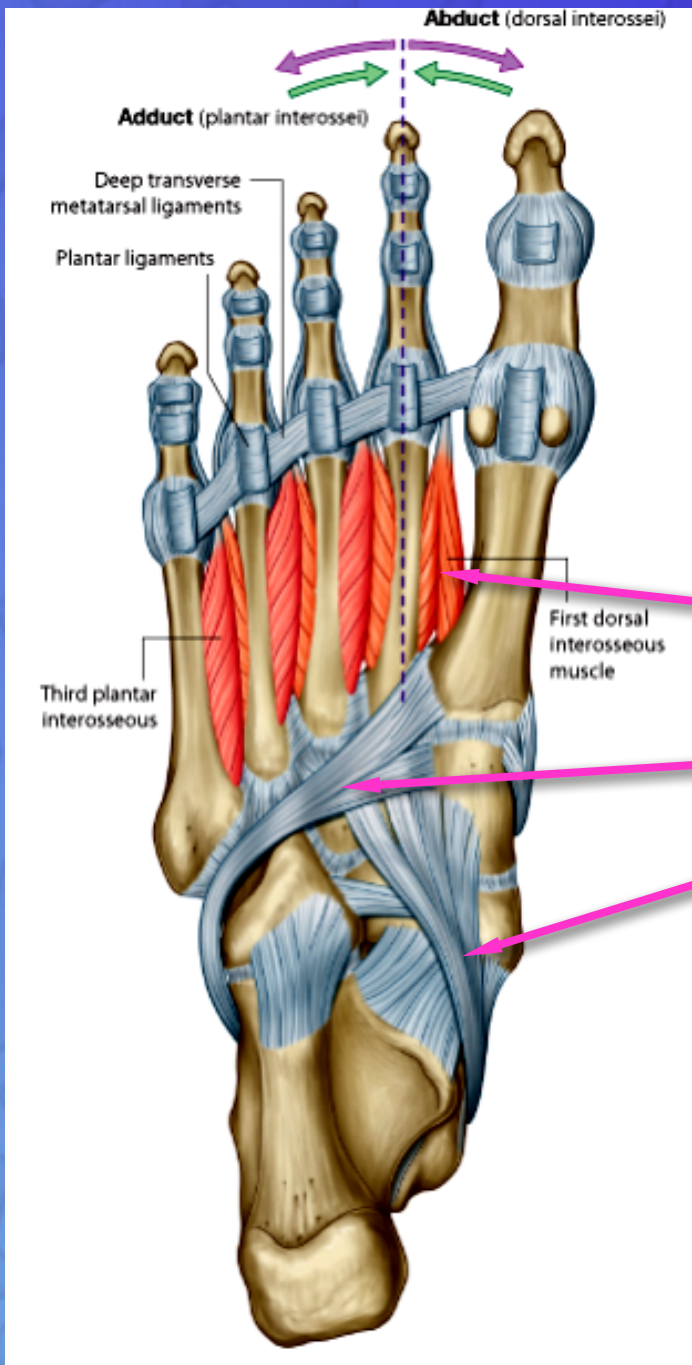
Second Layer

1. Quadratus plantae,
2. Lumbricals,
3. Flexor digitorum longus tendon,
4. Flexor hallucis longus tendon



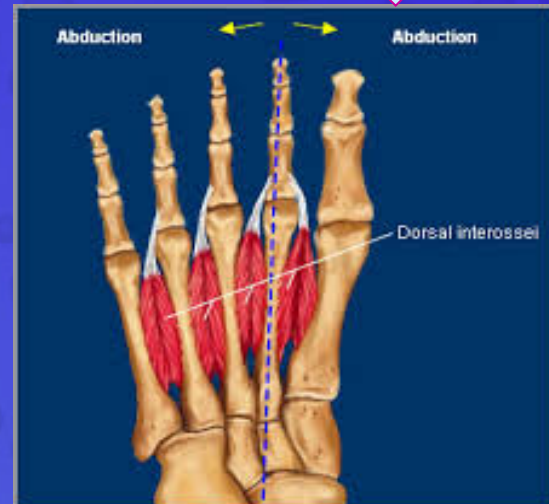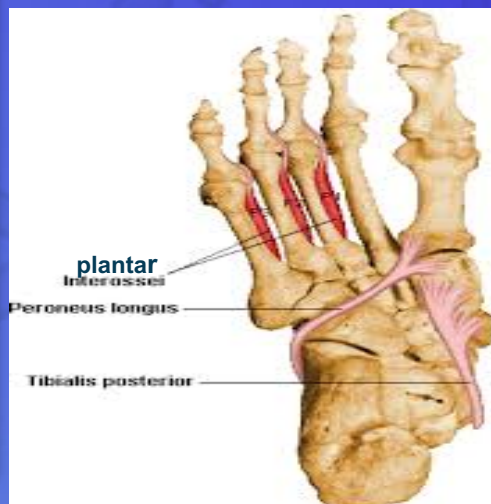
Third Layer

1. Flexor hallucis brevis
2. Adductor hallucis
3. Flexor digiti minimi brevis

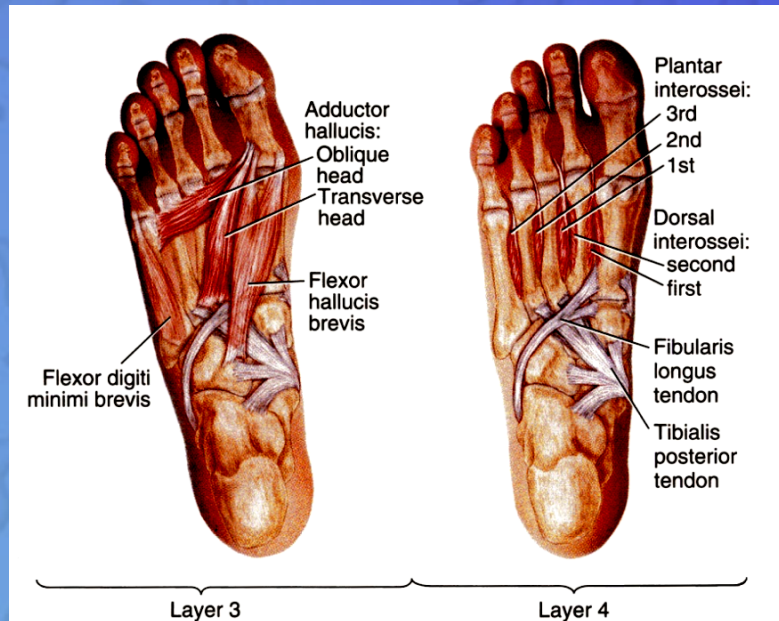
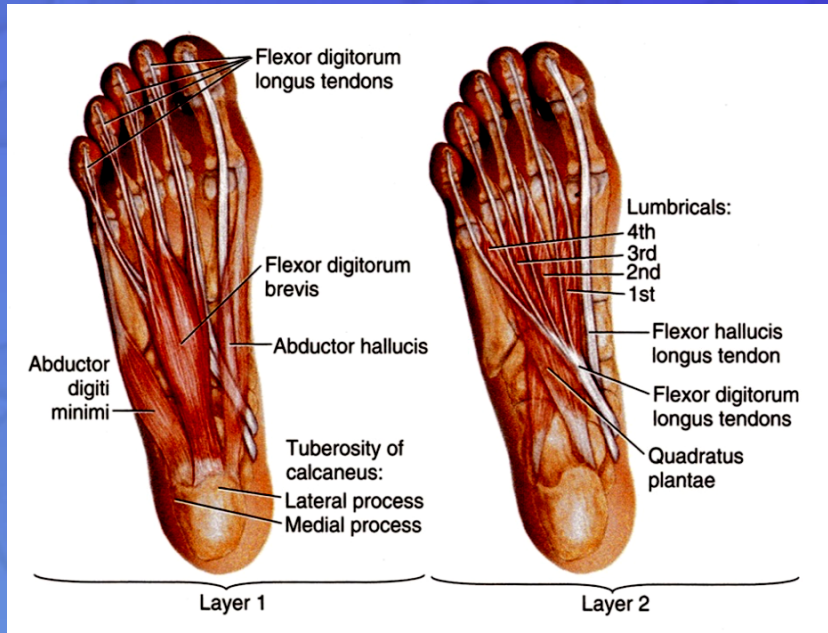


Fourth Layer

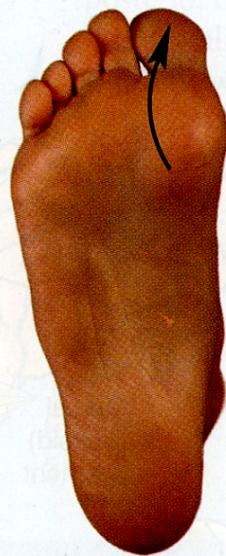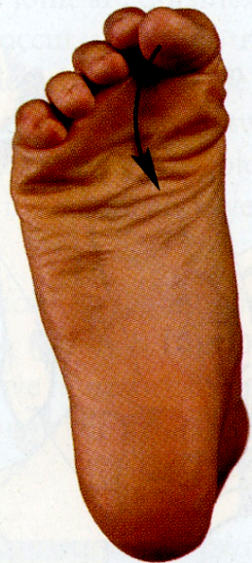1. Interossei, (3 plantar + 4 dorsal).
2. Peroneus longus tendon
3. Tibialis posterior tendon



Function of small muscles of sole of Foot

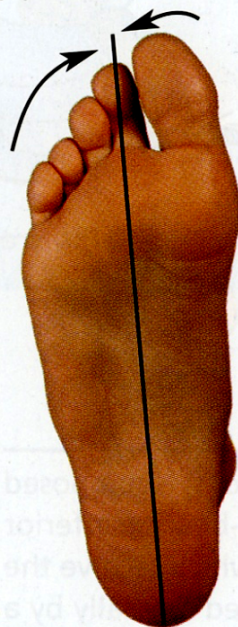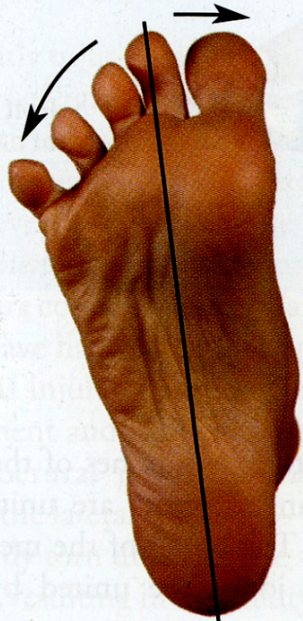


- Unlike the small muscles of the hand, the **sole muscles** have few delicate functions and are chiefly concerned with supporting the arches of the foot.
- Although their names would suggest control movements of individual toes, this function is rarely used in most people



(A) Flexion

(B) Extension

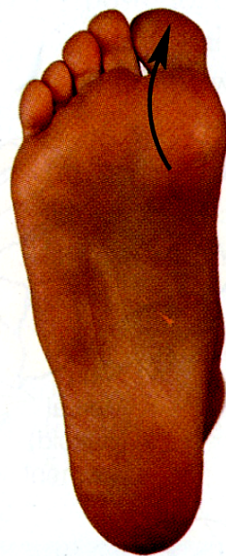
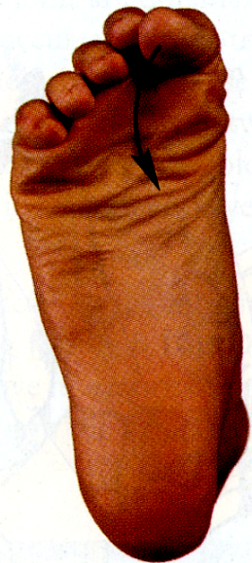
(C) Abduction

(D) Adducted
(relaxed position)

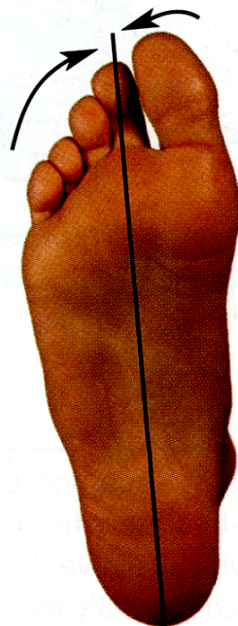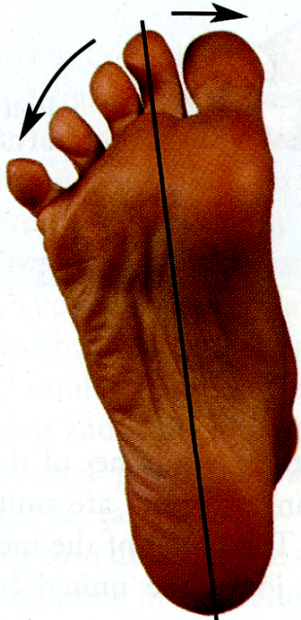
Movement	Muscles ^a
Metatarsophalangeal joints	
Flexion (A)	Flexor digitorum brevis Lumbricals Interossei Flexor hallucis brevis Flexor hallucis longus Flexor digit minimi brevis Flexor digitorum longus
Extension (B)	Extensor hallucis longus Extensor digitorum longus Extensor digitorum brevis
Abduction (C)	Abductor hallucis Abductor digiti minimi Dorsal interossei
Adduction (D)	Adductor hallucis Plantar interossei

^aMuscles in boldface are chiefly responsible for the movement; the other muscles assist them.



(A) Flexion

(B) Extension



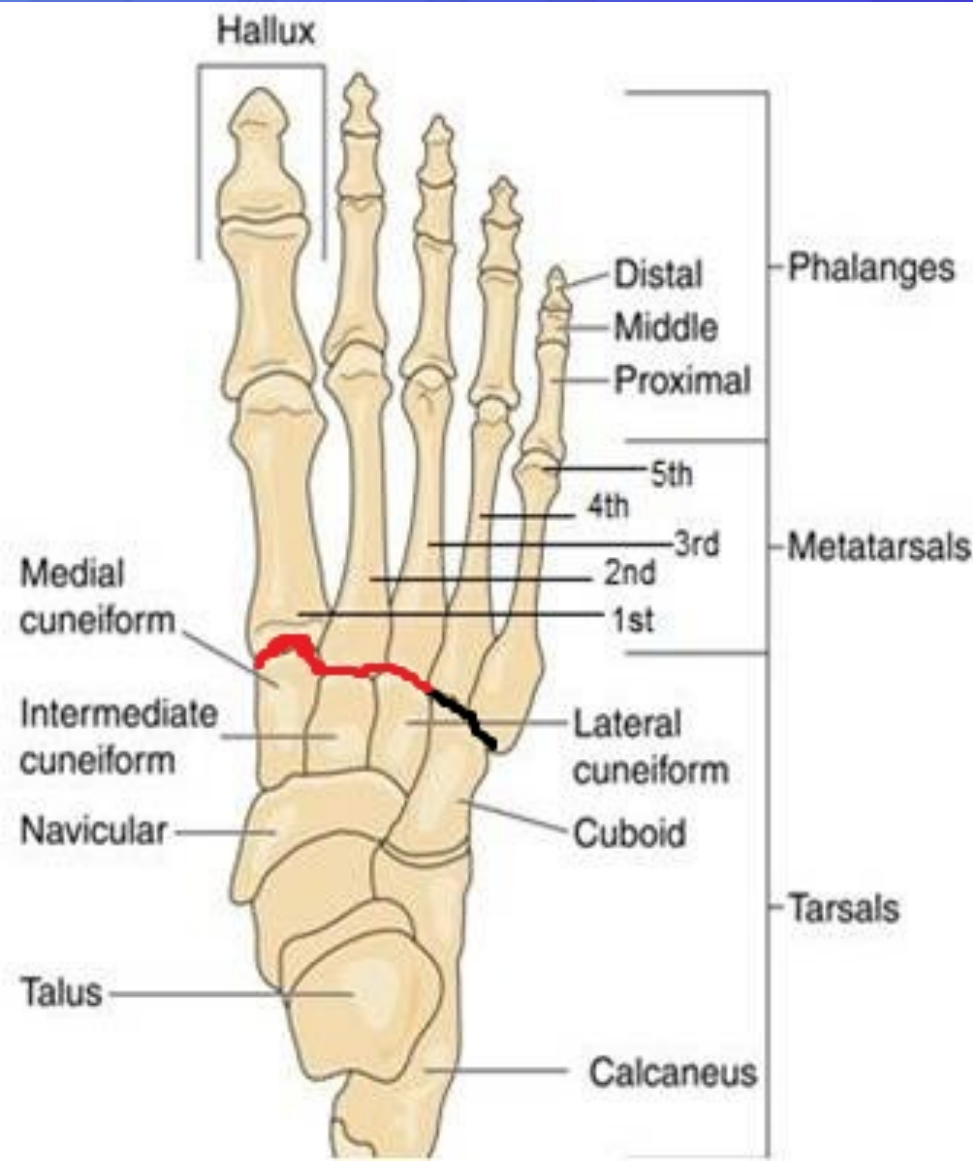(C) Abduction

(D) Adducted
(relaxed position)

Movement	Muscles ^a
Interphalangeal joints	
Flexion (fig. A)	Flexor hallucis longus Flexor digitorum longus Flexor digitorum brevis Quadratus plantae
Extension (fig. B)	Extensor hallucis longus Extensor digitorum longus Extensor digitorum brevis

^aMuscles in boldface are chiefly responsible for the movement; the other muscles assist them.

Arches of Foot



➤ Medial longitudinal arch

Is formed of calcaneum, talus, navicular, 3 cuneiform bones, and 3 medial metatarsal bones.

➤ Lateral longitudinal arch

Is formed of calcaneum, cuboid & lateral 4th & 5th metatarsal bones

➤ Transverse arch

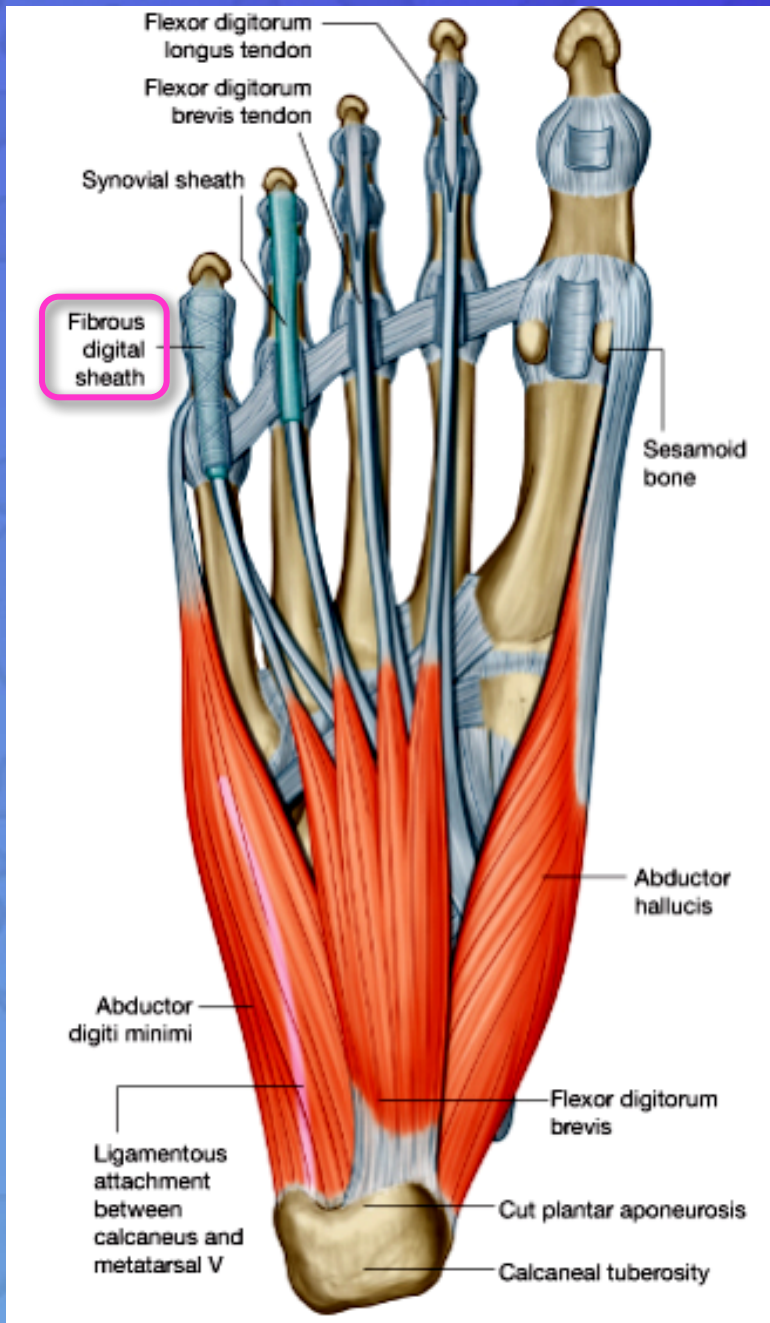
Lies at the level of **tarso-metatarsal joints**, formed of bases of metatarsal bones, cuboid & 3 cuneiform bones.

Function of Arches of the Foot

- Weight bearing
- Support walking & running
- Provide potential space for neurovascular bundle of the sole
- Act as shock absorber
- *In young child, the foot appears to be flat because of presence of a large amount of subcutaneous fat on the sole of foot*

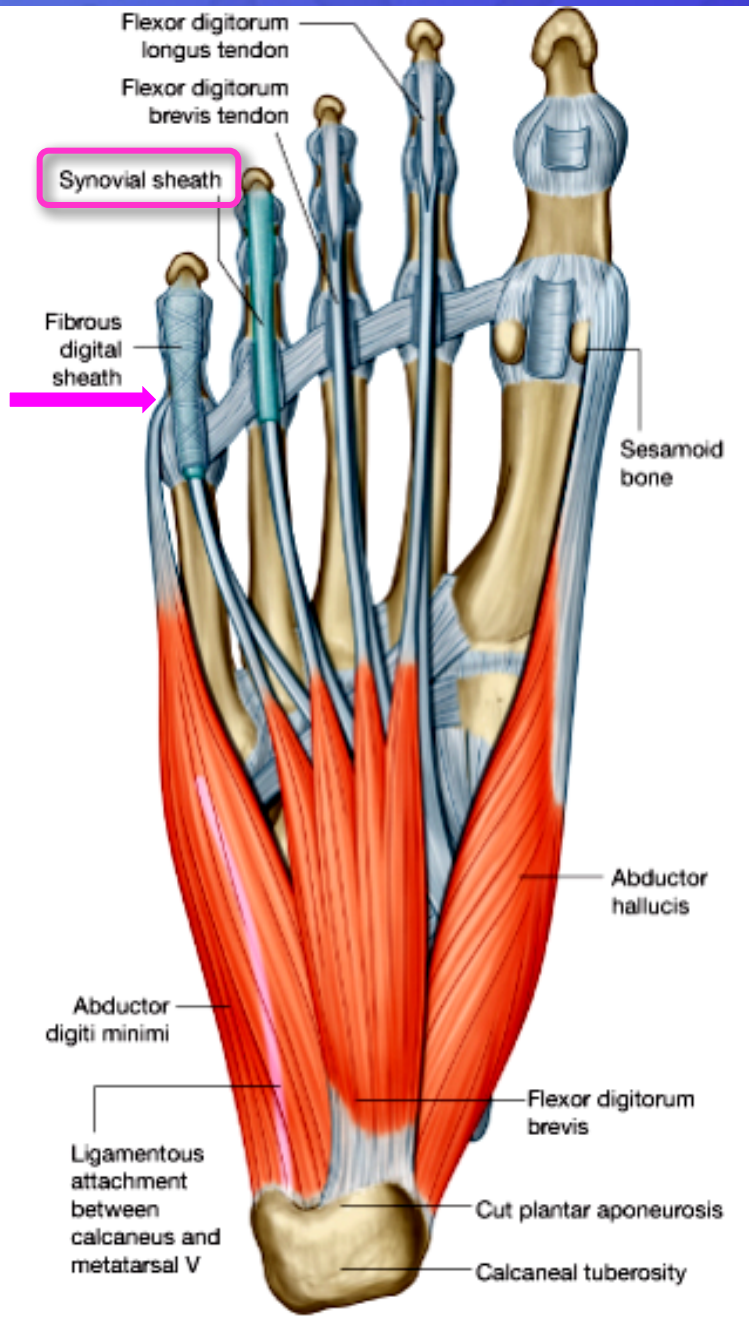
Fibrous Flexor Sheaths

- The inferior surface of each toe, from the head of the metatarsal bone to the base of the distal phalanx, is provided with a **strong fibrous sheath**, which is attached to the **sides of the phalanges**.
- **The fibrous sheath**, together with the inferior surfaces of the phalanges and the interphalangeal joints, **forms a blind tunnel** in which lie the **flexor tendons of the toes**.



Synovial Flexor Sheaths

The tendons of the **flexor hallucis longus** and the **flexor digitorum longus** are surrounded by **synovial sheaths**



THANK YOU