

***ANTERIOR, LATERAL COMPARTMENTS OF THE  
LEG & DORSUM OF THE FOOT***

**Dr JAMILA  
EL MEDANY**

**&**

**Dr SAEED  
VOHRA**

# OBJECTIVES

*At the end of the lecture, student should be able to*

**Identify the deep fascia of leg**

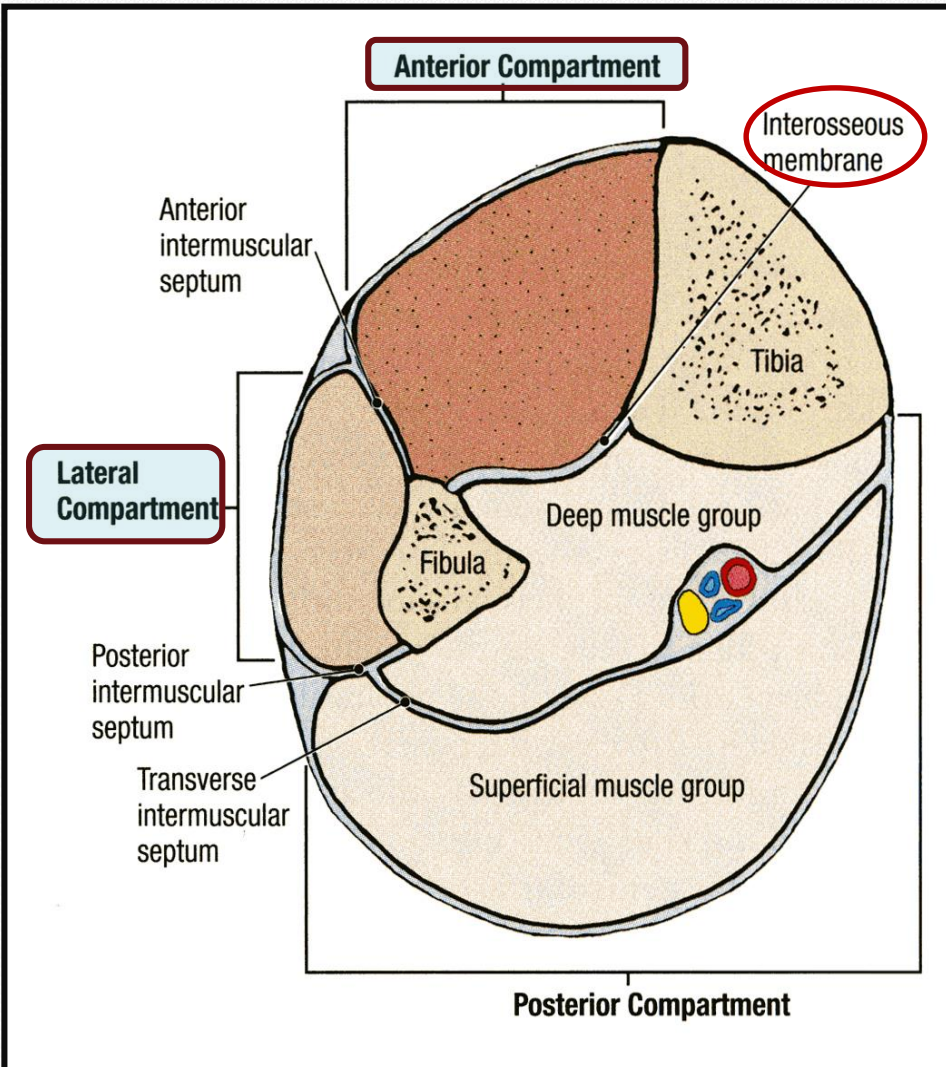
**Identify the fascial compartments of the leg**

**Describe the anatomy of the anterior & lateral compartments**

**List the contents of each compartment (muscles, vessels & nerves)**

**Describe the anatomy and contents of the dorsum of the foot**

# Fascia of the Leg



- The deep fascia surrounds the leg and attached to Anterior & Medial borders of Tibia.

- Two Intermuscular Septa**

Pass from the deep aspect of this fascia to be attached to :

Anterior border of fibula (**Anterior intermuscular septum**)

Posterior border of fibula (**Posterior intermuscular septum**)

- Interosseous membrane:**

A thin & strong membrane, that binds the interosseous borders of tibia & fibula. It binds the two bones and provides attachment for muscles.

# Fascial Compartments of Leg

Together with the interosseus membrane, the two intermuscular septa divide the leg into

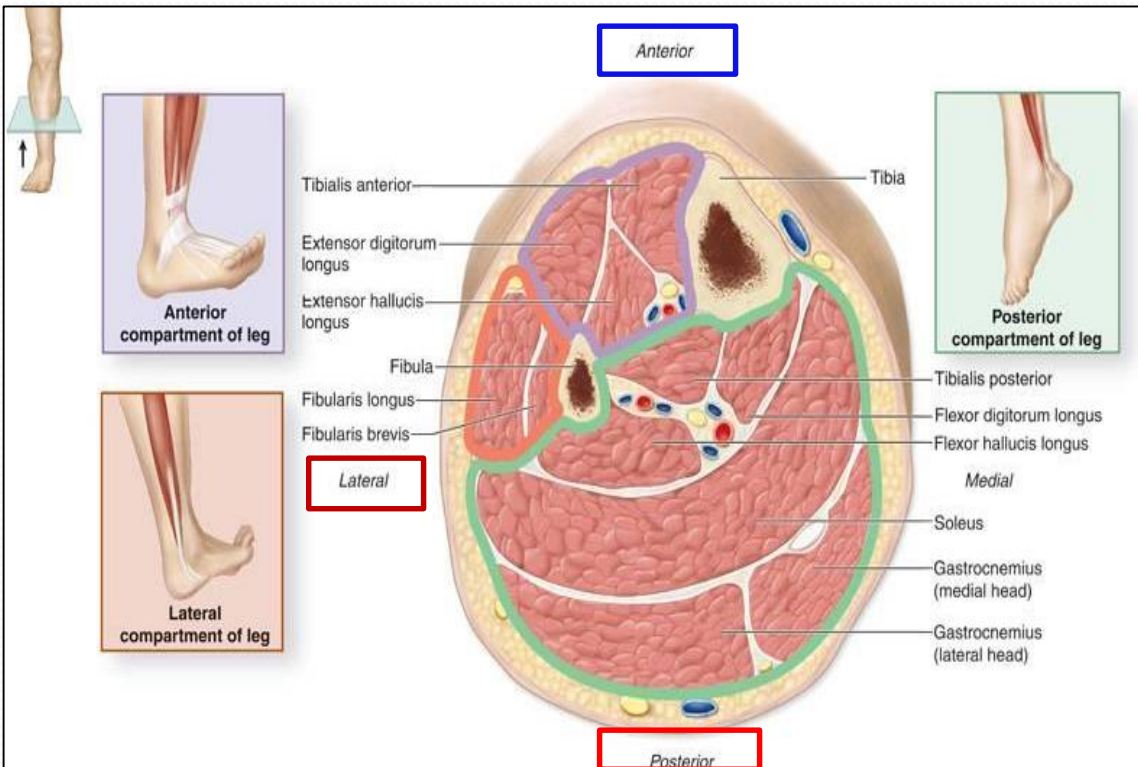
**(3) Compartments :**

**1-Anterior**

**2-Lateral (peroneal)**

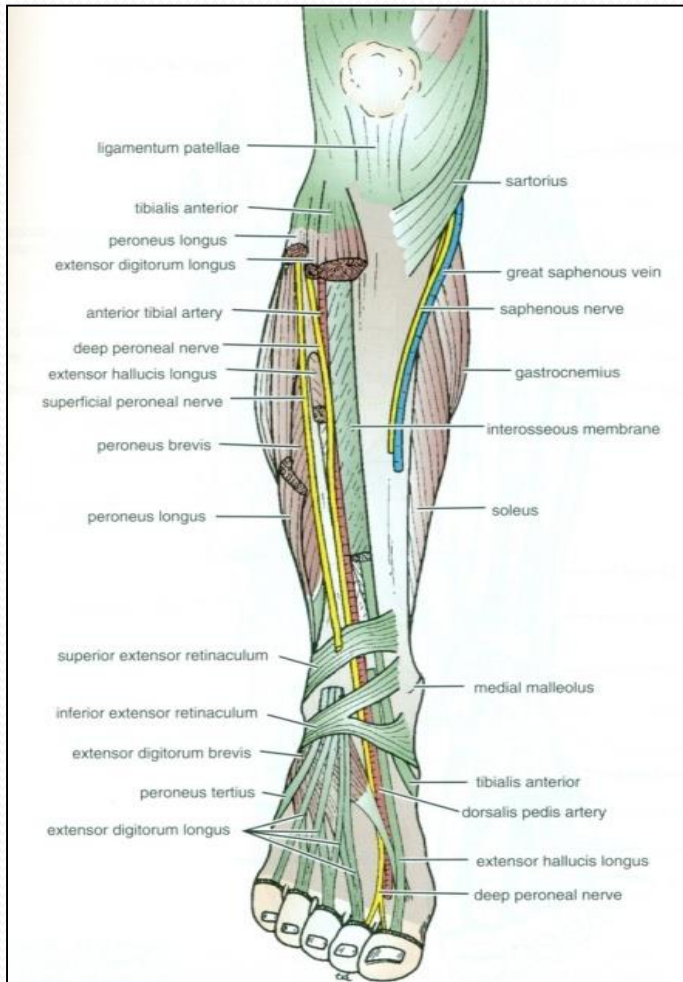
**3-Posterior**

Each one has its own **Muscles** (with specific action), **Blood vessels** and **Nerves**.

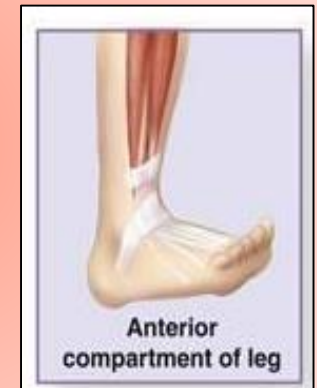




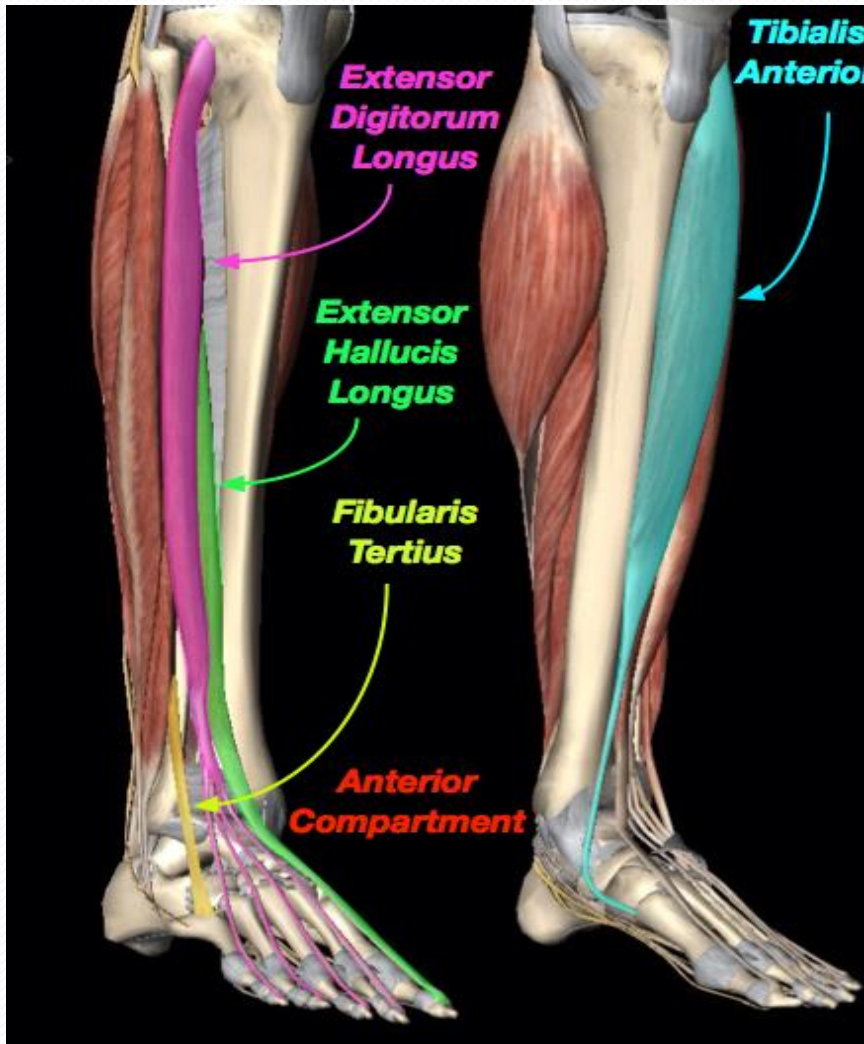
# Criteria of the Anterior Compartment



- **Muscles :**
- All muscles take origin from the fibula EXCEPT **Tibialis Anterior**.
- **Nerve supply:**
- **Deep**
- **Peroneal.**
- **Blood Supply:**
- **Anterior tibial.**
- **Action: Dorsiflexion of the ankle joint & Extension of the toes & (Inversion).**



# Muscles of Anterior Compartment



**Tibialis  
Anterior**

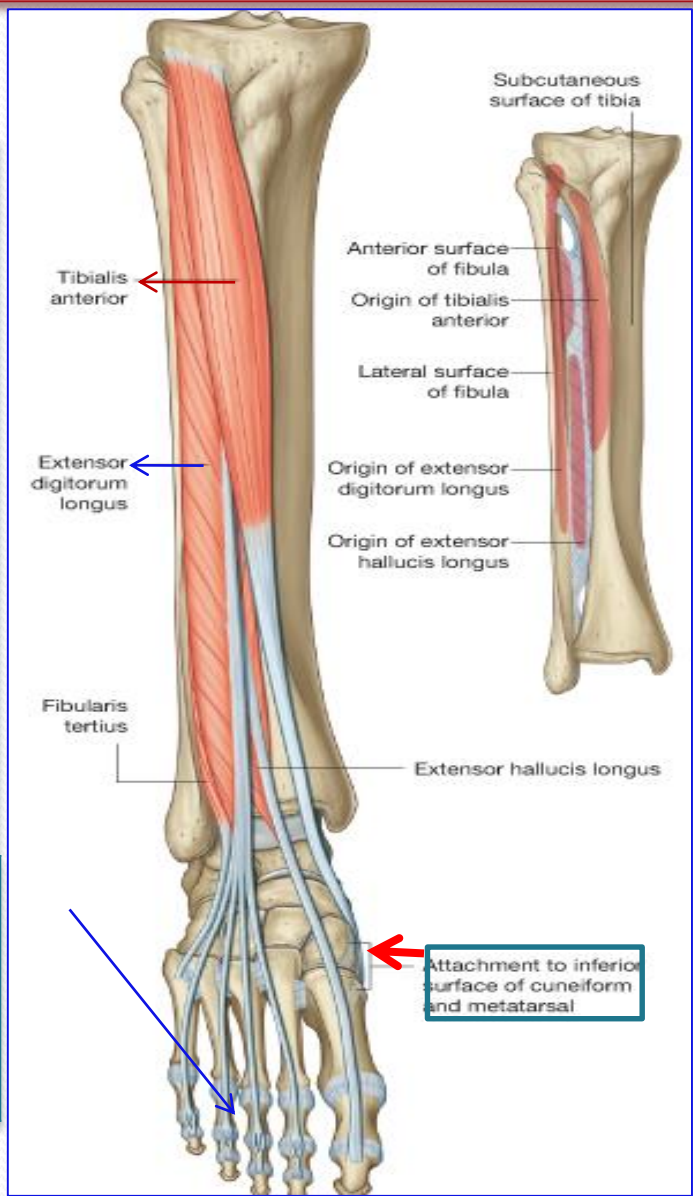
**Extensor Hallucius  
Longus**

**Extensor Digitorum  
Longus**

**Peroneus Tertius**

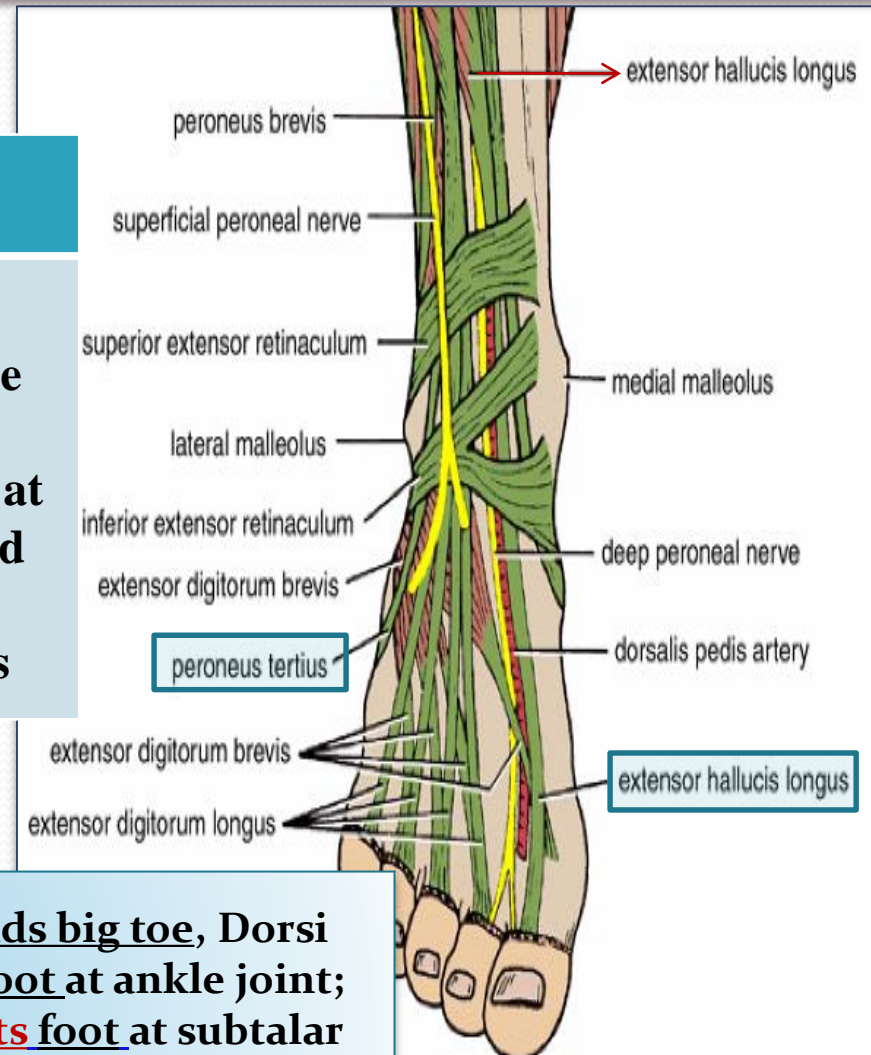
# Tibialis Anterior & Extensor Digitorum Longus

Muscle	Origin	Insertion	Action
<b>Tibialis Anterior</b>	<u>Lateral</u> surface of shaft of <u>tibia</u> & interosseous membrane	Medial cuneiform & base of 1 <sup>st</sup> metatarsal bone	<u>Extends</u> foot at ankle joint; <u>Inverts</u> foot at subtalar & transverse tarsal joints & <u>Holds up</u> <u>medial longitudinal arch of foot</u>
<b>Extensor Digitorum Longus</b>	<u>Anterior</u> surface of shaft of <u>fibula</u>	Extensor expansion of lateral four toes	<u>Extends</u> toes; <u>Dorsi flex</u> foot at ankle joint



# Peroneus Tertius, & Extensor Hallucis Longus

Muscle	Origin	Insertion	Action
<b>Peroneus tertius</b>	<u>Anterior</u> surface of shaft of <u>fibula</u>	<u>Base</u> of <u>5<sup>th</sup></u> <u>metatarsal</u> bone	<b>Dorsi flex</b> foot at ankle joint; <b>Everts</b> foot at subtalar and transverse tarsal joints

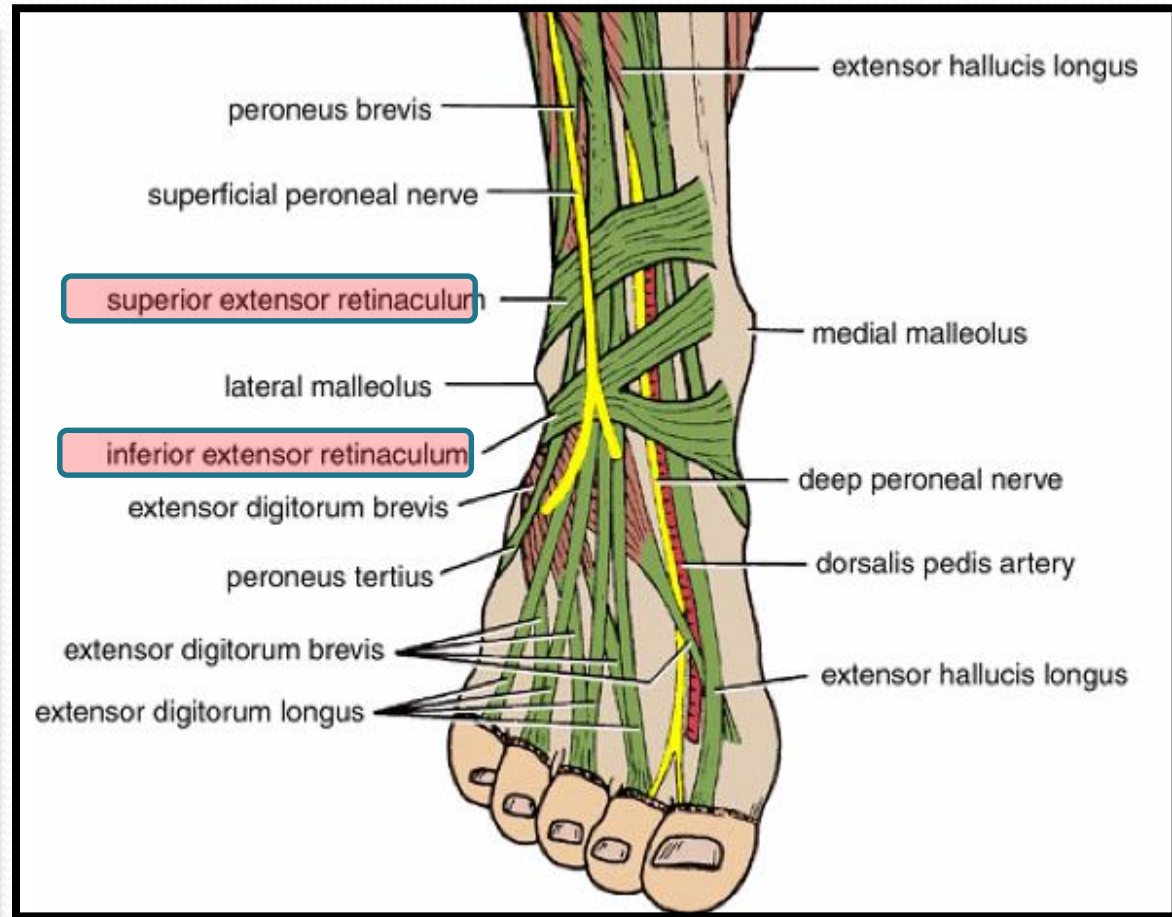


<b>Extensor hallucis longus</b>	<u>Anterior</u> surface of shaft of <u>fibula</u>	Base of distal phalanx of great toe	<u>Extends big toe</u> , Dorsi flex <u>foot</u> at ankle joint; <b>Inverts</b> foot at subtalar and transverse tarsal joints
---------------------------------	---	-------------------------------------	--

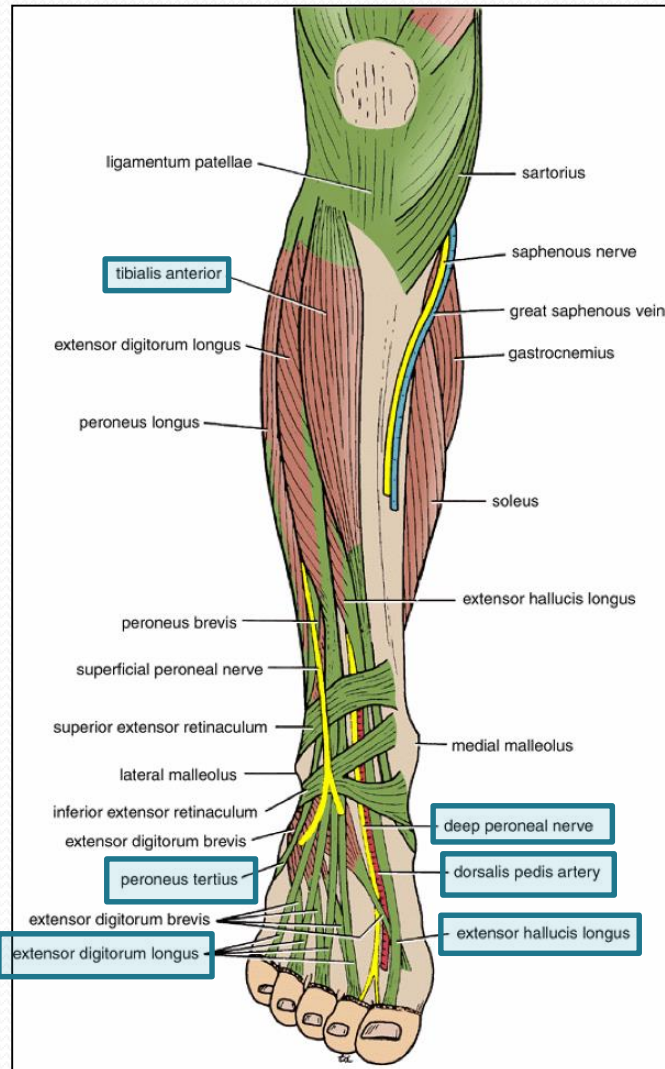


# Extensor Retinacula

- A thickening of deep fascia that keep the long tendons around ankle joint in position
- **Superior Extensor retinaculum :**
- *Attached to anterior borders of tibia & fibula above ankle*
- **Inferior Extensor retinaculum:**
- *Y-shaped band located inferior to ankle*



# Structures Passing Deep to Extensor Retinacula



*From medial to lateral:*

1. Tom

2. Has

3. Very (vessels)

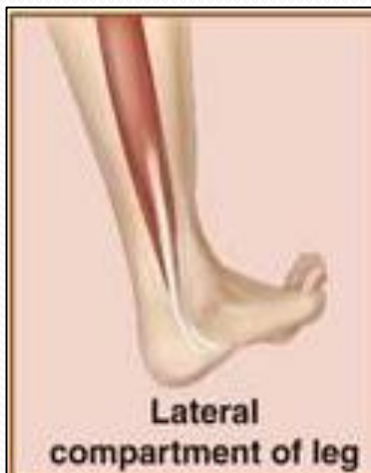4. Nice (nerve)

5. Dog &

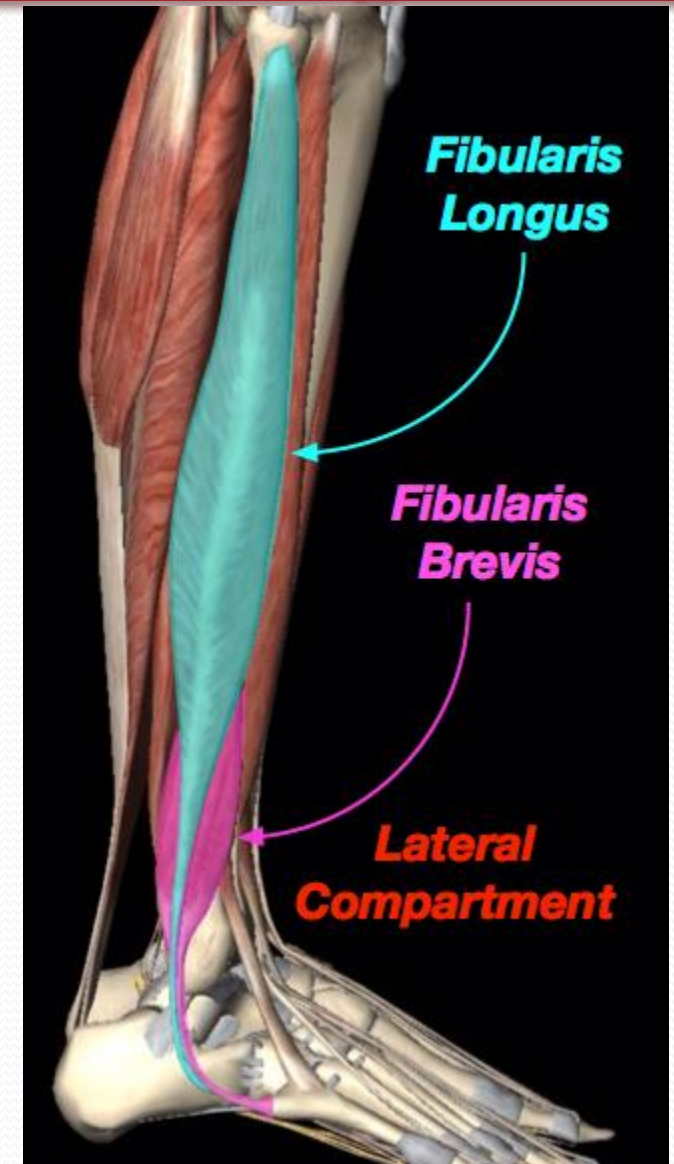
6. Pigion

# Lateral Compartment of Leg

MUSCLES	NERVE	BLOOD SUPPLY
PERONEUS LONGUS	Superficial Peroneal	Peroneal A
PERONEUS BREVIS		



Action:  
Plantar flexion &  
Eversion



# Peroneus Longus

## Origin

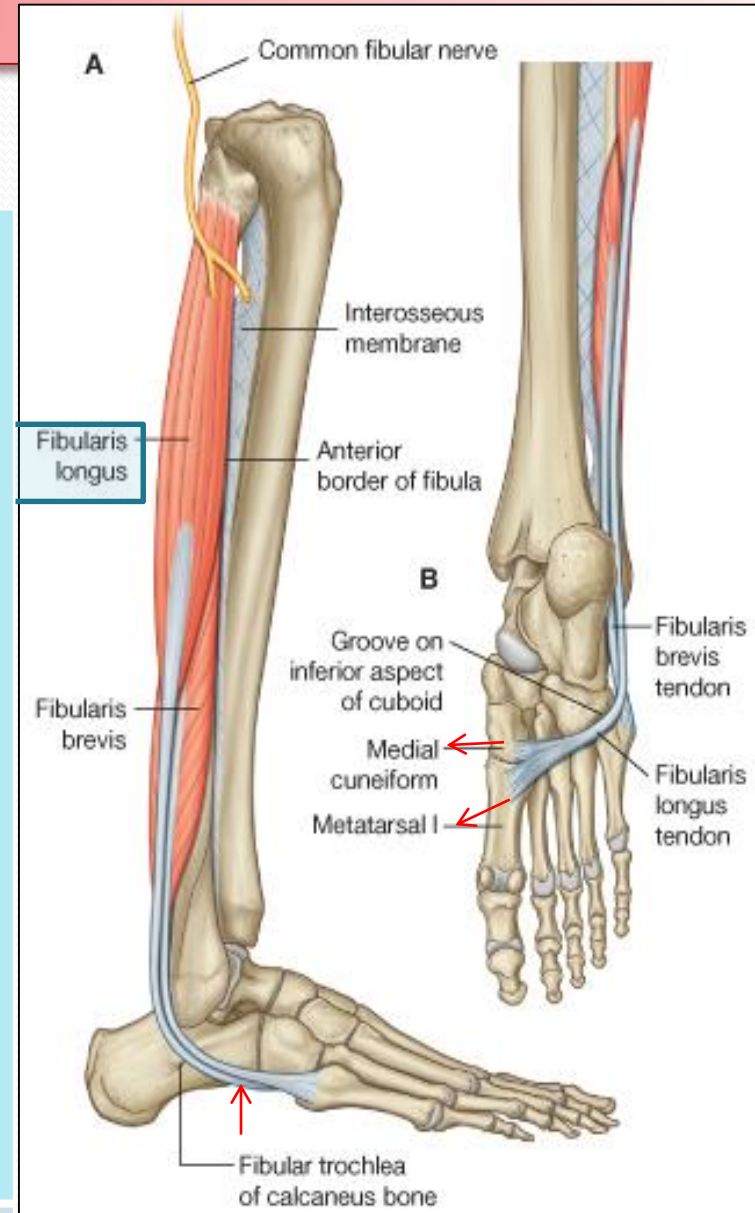
## Insertion

## Action

Lateral surface of shaft of fibula

Base of first metatarsal & the medial cuneiform  
(Insertion of?)

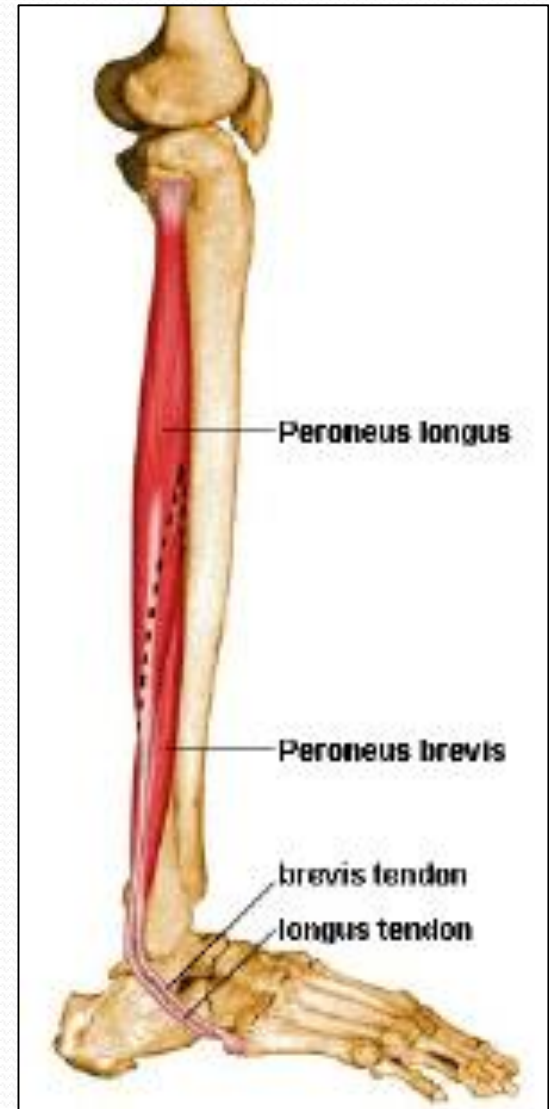
Plantar flexes foot at ankle joint;  
Everts foot at subtalar and transverse tarsal joints;  
Supports Lateral longitudinal & Transverse arches





# Peroneus Brevis

Origin	Insertion	Action
Lateral surface of shaft of fibula	Base of fifth metatarsal bone ( <b>Insertion of?</b> )	<b>Plantar flexes</b> foot at ankle joint; <b>Everts foot</b> at subtalar and transverse tarsal joint; <b>Supports Lateral longitudinal arch</b> of foot



# Peroneal Retinacula

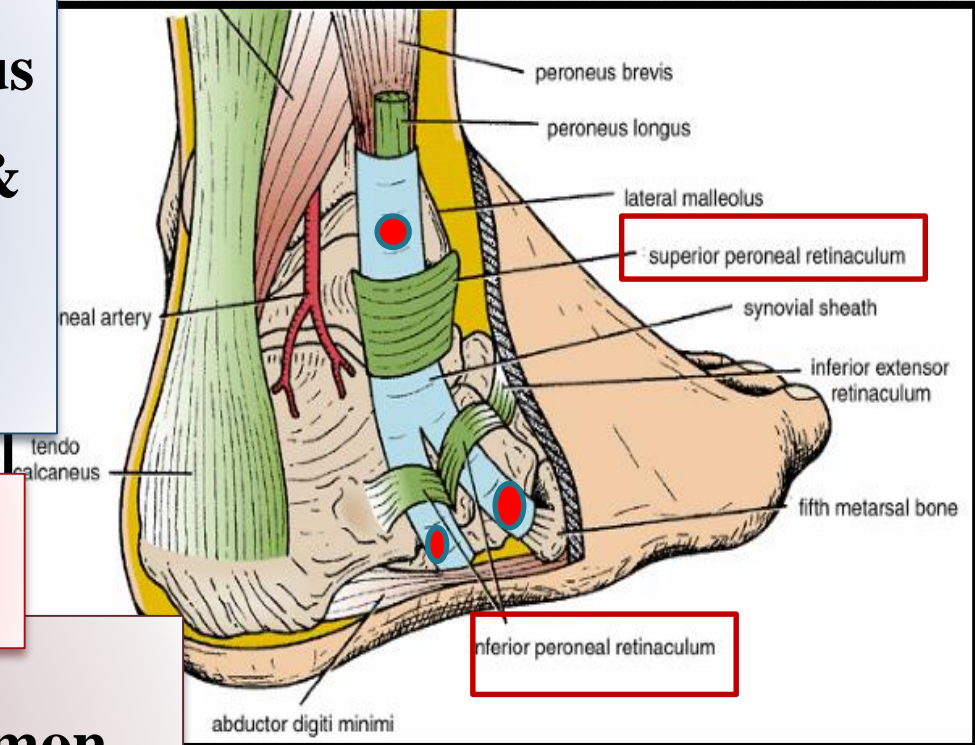
## Superior peroneal retinaculum

Connects the lateral malleolus to calcaneum & holds the tendons of peroneus longus & brevis

## Inferior peroneal retinaculum

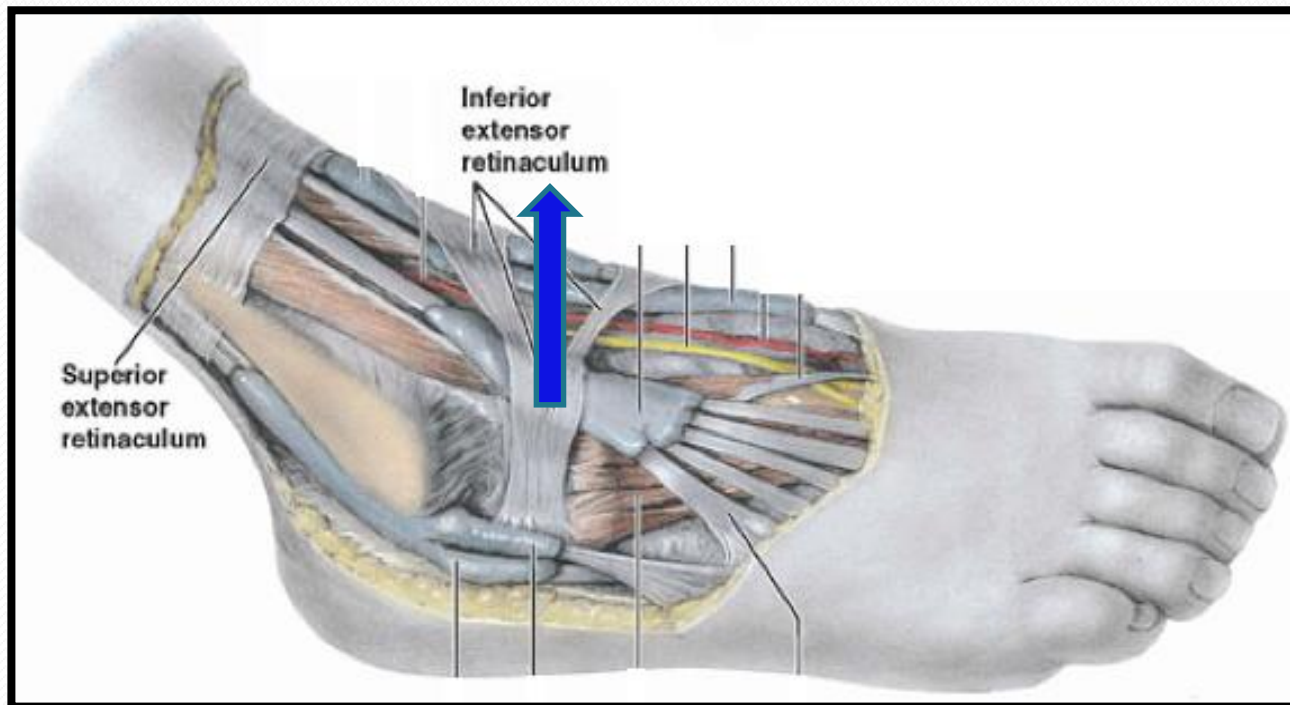
## Synovial Sheaths of Peroneal Longus & Brevis:

Tendons of peronei are surrounded by a single common tubular synovial sheath, deep to inferior peroneal retinaculum, they have separate sheaths



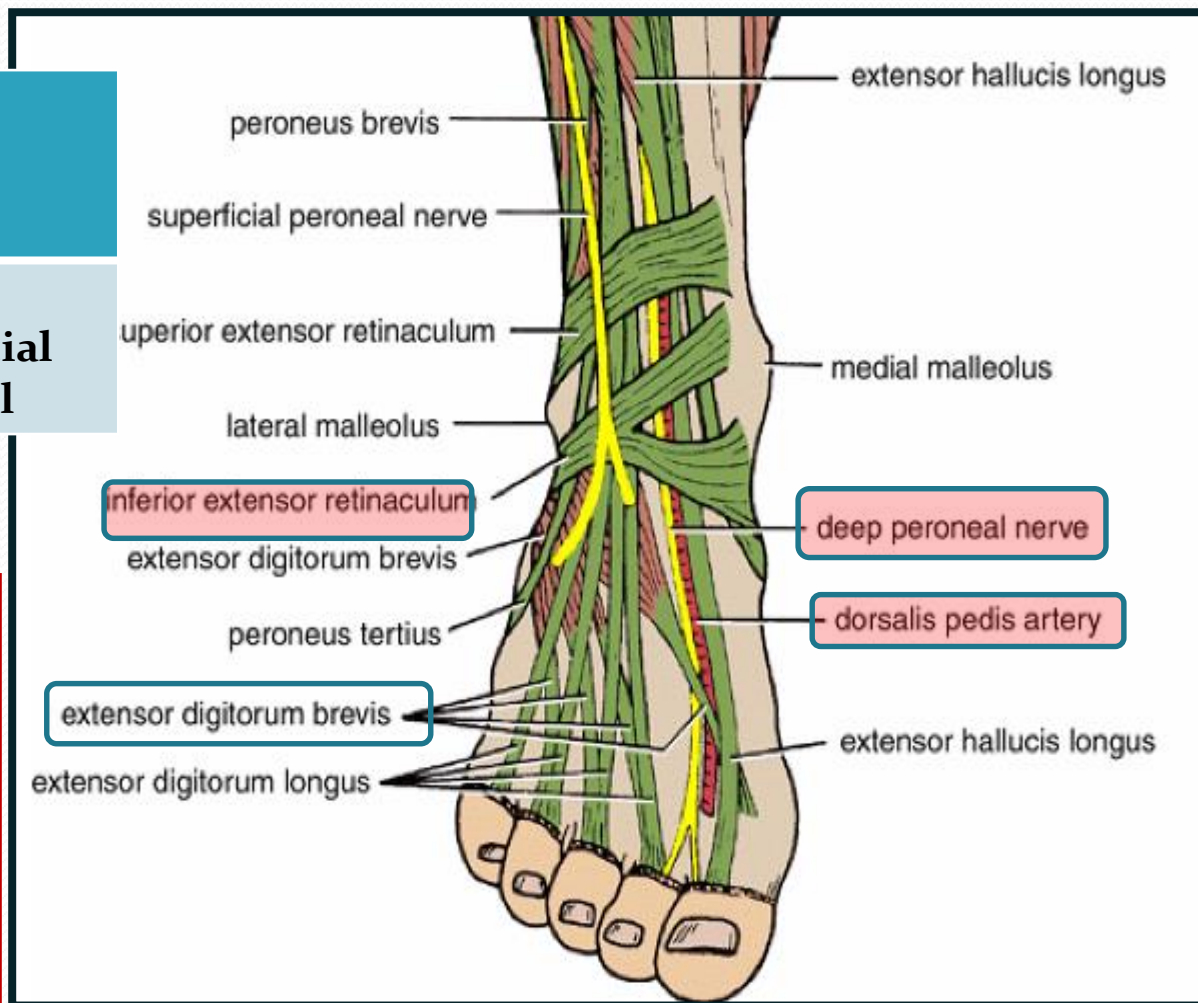
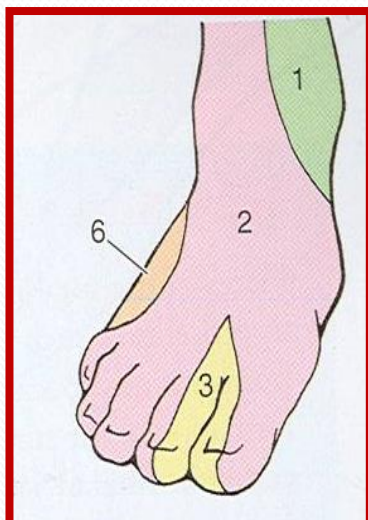
# Deep Fascia of Dorsum of Foot

It is very thin, but just distal to ankle joint, it is thickened to form **Inferior extensor retinaculum**



# Dorsum of Foot

MUSCLE	BLOOD VESSEL	NERVE
Extensor Digitorum Brevis	Dorsalis Pedis	<u>DEEP &amp; Superficial Peroneal</u>





# Extensor Digitorum Brevis

## Origin

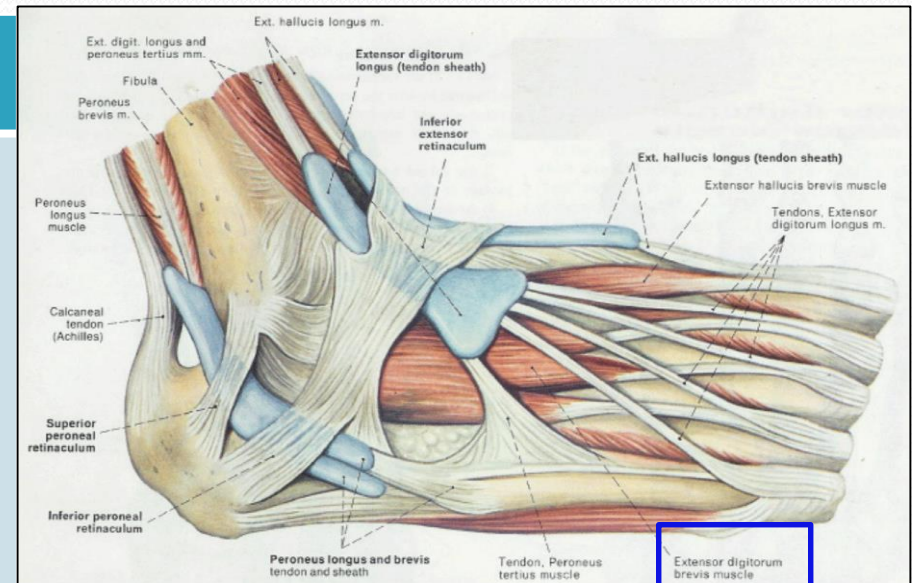
Anterior part of upper surface of the Calcaneum & from the **Inferior extensor retinaculum**

## Insertion

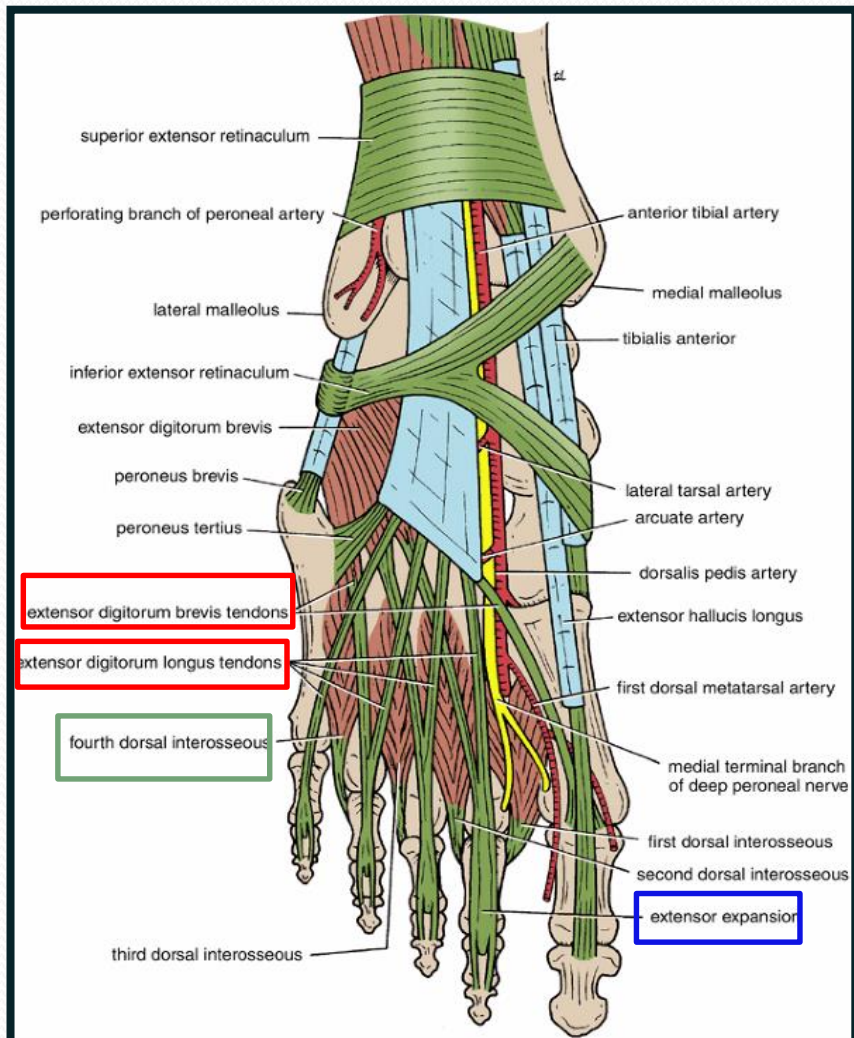
four tendons into the **proximal phalanx of big toe** (ex hall brevis) and second, third, and fourth toes

## Action

Extend toes



# Insertion of Long Extensor Tendons (Extensor Expansion)



- The tendons of Extensor digitorum longus pass **to the lateral four toes.**
- Each tendon to the 2<sup>nd</sup>, 3<sup>rd</sup> & 4<sup>th</sup> toes is joined on its lateral side by a tendon of **Extensor digitorum brevis.**
- The extensor tendons form
- a **Fascial Expansion (Extensor Expansion)** on the dorsum of each toe.
- The expansion divides into **(3) parts.**
- **Central part:** inserted into the **Base of Middle ph.**
- **Two Lateral parts:** inserted into the **Base of Distal ph.**
- The (Extensor Expansion) **receives insertion of :**
- **Interossei & Lumbrical** muscles.

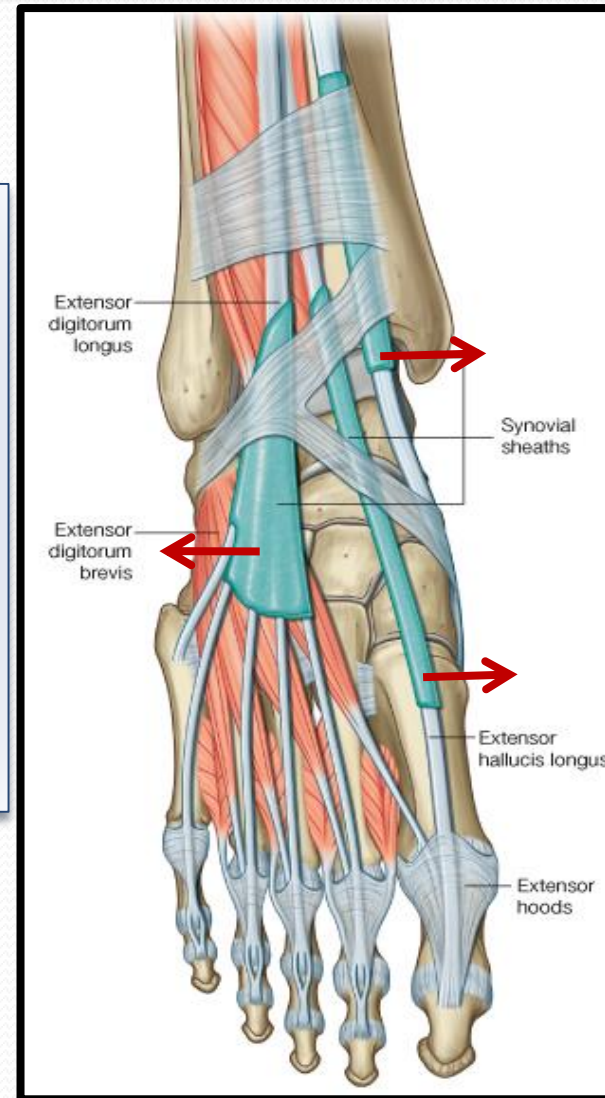
# Synovial Sheaths of Extensor Tendons on the Dorsum of Foot

**Tibialis anterior**

**Extensor hallucis longus**

**(Both have their own synovial sheath)**

**Extensor digitorum longus & peroneus tertius** : have a common sheath, it extends to the level of **Base of 5<sup>th</sup> Metatarsal bone.**





***THANK YOU***