



MUSCULOSKELETAL BLOCK

Pathology

Congenital ,developmental and metabolic
bone diseases

Amany Fathaddin, MD
Assistant professor and consultant of pathology

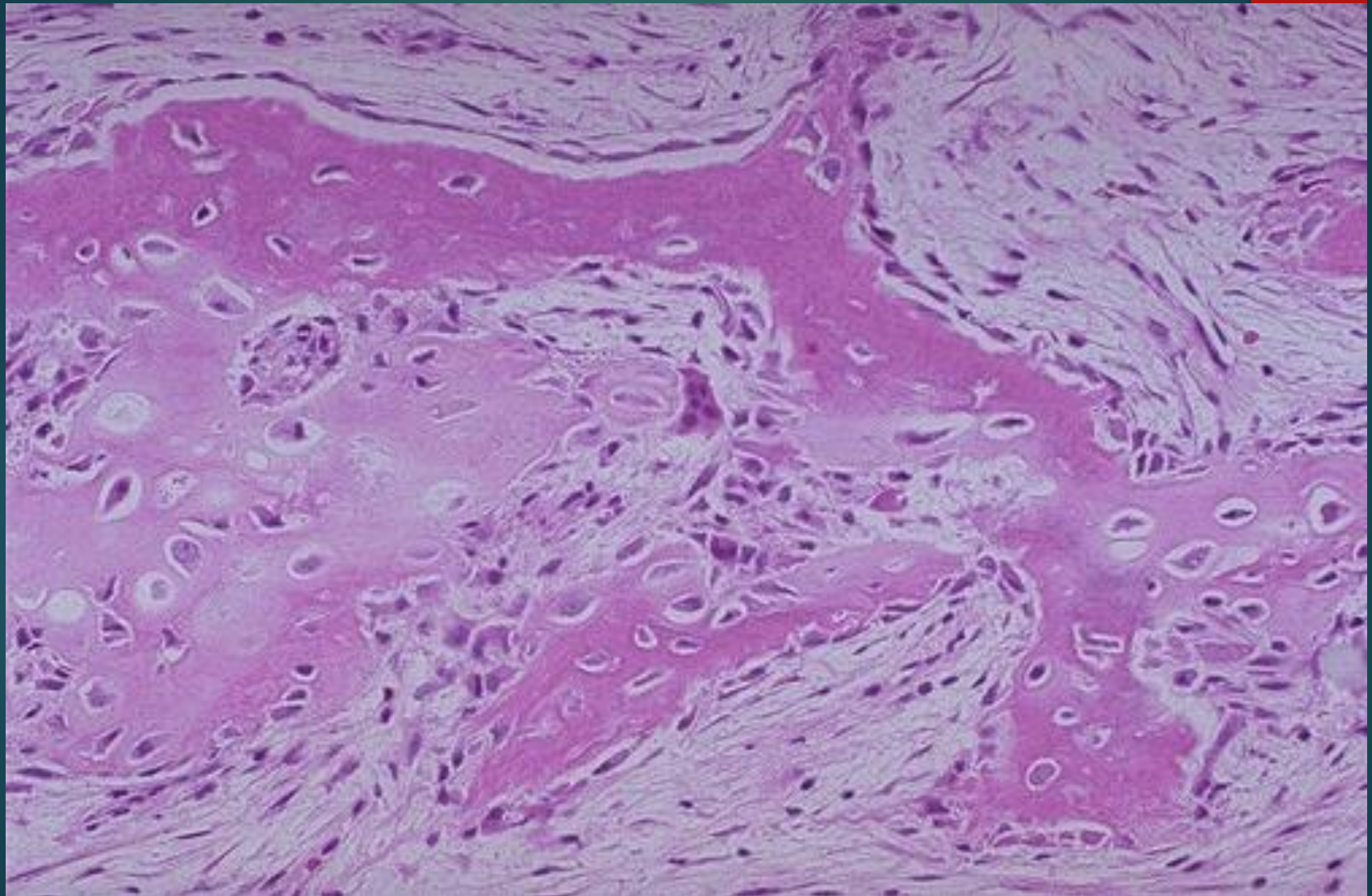
Diseases of Bones

▶ Objectives

- ▶ Be aware of some important congenital and developmental bone diseases and their principal pathological features
- ▶ Be familiar with the terminology used in some important developmental and congenital disorders.
- ▶ Understand the etiology, pathogenesis and clinical features of osteoporosis

Bone

- ▶ 206 bones
- ▶ organic matrix (35%) and inorganic elements (65%): calcium hydroxyapatite $[\text{Ca}_{10}(\text{PO}_4)_6(\text{OH})_2]$
- ▶ The bone-forming cells include osteoblasts and osteocytes, while cells of the bone-digesting lineage are osteoclasts
- ▶ is very dynamic and subject to constant breakdown and renewal: **remodeling**



Diseases of Bones

- ▶ Congenital
- ▶ Acquired
 - ▶ Metabolic
 - ▶ Infections
 - ▶ Traumatic
 - ▶ Tumors

Congenital Diseases of Bones

Localized or entire skeleton

□ Dysostoses:

- *aplasia* : e.g *congenital absence of a digit*
- extra bones
- abnormal fusion of bones e.g : premature closure of cranial sutures

□ Dysplasia:

- Osteogenesis imperfecta
- Achondroplasia
- Osteopetrosis

Osteogenesis imperfecta



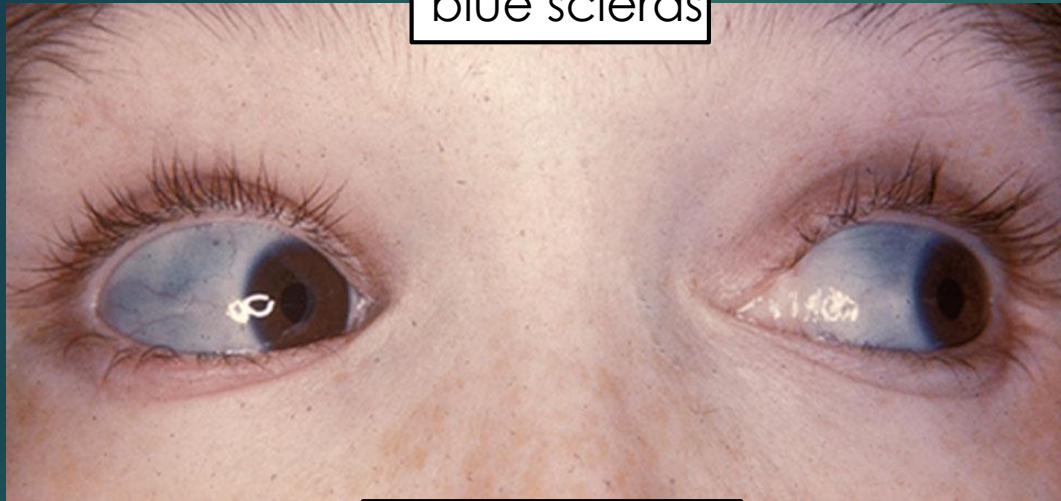Congenital Diseases of Bones

Osteogenesis imperfecta (brittle bone disease)

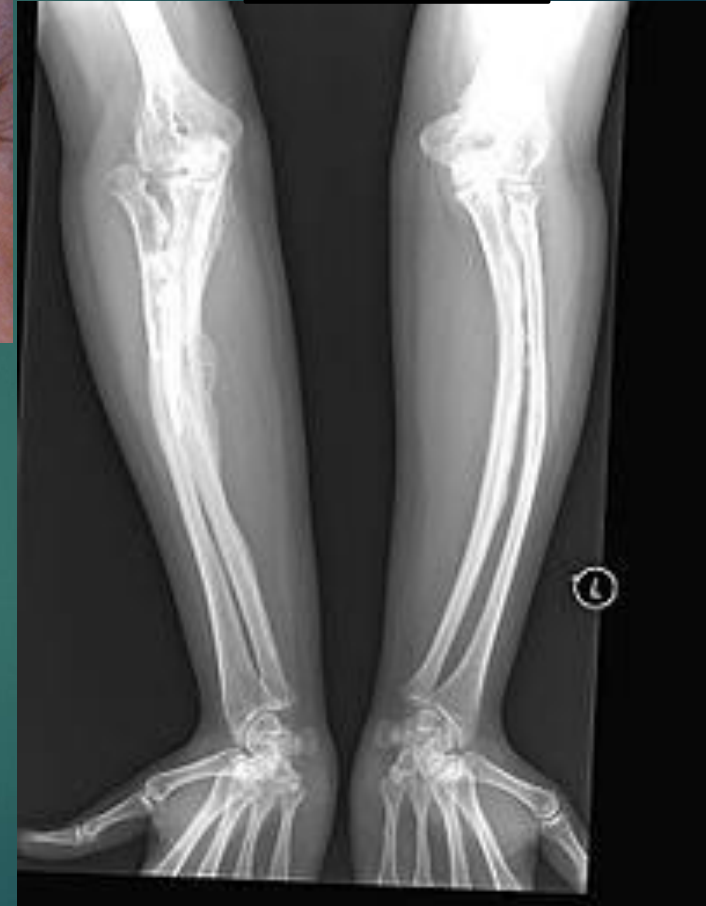- ❑ Osteogenesis imperfecta is a group of genetic disorders characterized by brittle bones
- ❑ Defect in the synthesis of type I collagen leading to too little bone resulting in extreme skeletal fragility with susceptibility to fractures
- ❑ Four main types with different clinical manifestations classified according to the severity of bone fragility, the presence or absence of blue sclera, hearing loss, abnormal teeth, and the mode of inheritance, some are fatal.
 - Type 1: blue sclera in both eye, deformed teeth and hearing loss

Osteogenesis imperfecta, type 1

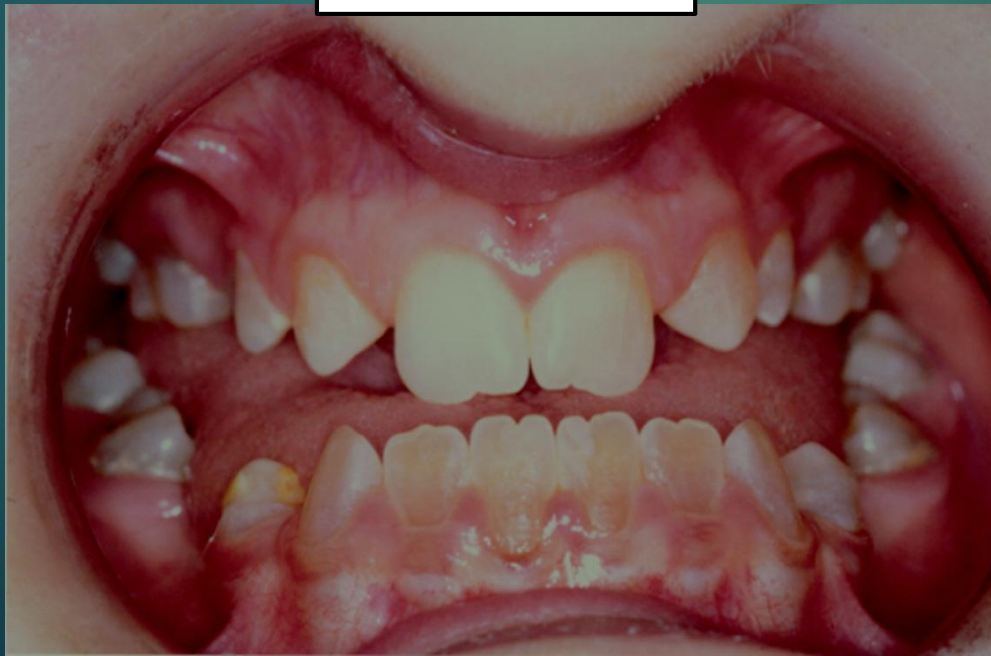blue scleras



brittle bones



deformed teeth





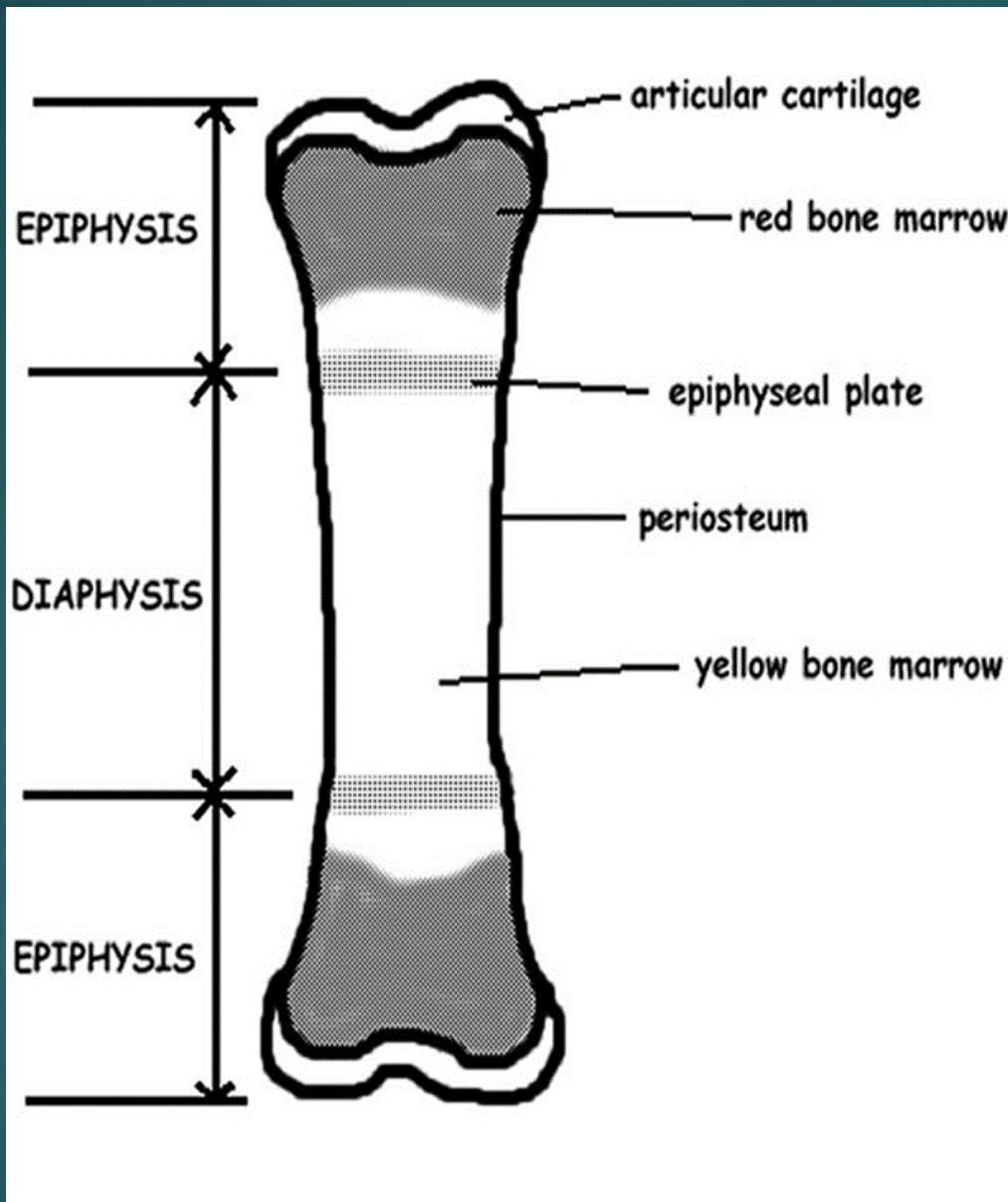
Achondroplasia

ACHONDROPLASIA IS THE MOST COMMON SKELETAL DYSPLASIA AND A MAJOR CAUSE OF DWARFISM.

Congenital Diseases of Bones

Achondroplasia

- Is transmitted as an **autosomal dominant trait but many cases arise from spontaneous mutation** resulting from:
 - Defect in the cartilage synthesis at growth plates due to **gain-of-function mutations in the FGF receptor 3 (FGFR3)**.
- It is characterized by failure of cartilage cell proliferation at the epiphysial plates of the long bones, resulting in failure of longitudinal bone growth and subsequent short limbs.
- Membranous ossification is not affected, so that the skull, facial bones, and axial skeleton develop normally.



Bones Congenital Diseases of

Achondroplasia

- ▶ Affected individuals have shortened proximal extremities, a trunk of relatively normal length, and an enlarged head with bulging forehead and conspicuous depression of the root of the nose.
- ▶ General health, intelligence, or reproductive status are not affected, and life expectancy is normal





METABOLIC BONE DISESES

Metabolic bone disease

comprises four fairly common conditions in which there is an imbalance between osteoblastic (bone forming) and osteoclastic (bone destroying) activity:

- ▶ **Osteoporosis**
- ▶ **Osteomalacia**
- ▶ **Paget's disease of bone**
- ▶ **Hyperparathyroidism**

OSTEOPOROSIS

OSTEOPOROSIS

Osteoporosis is an acquired condition characterized by reduced bone mass, leading to bone fragility and susceptibility to fractures

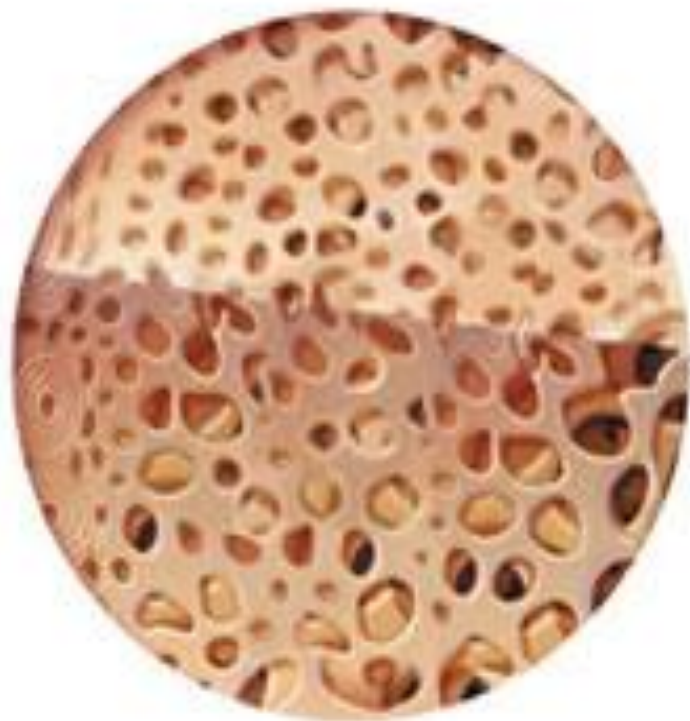➤ The cortical bone is thinned, and the bone trabeculae are thinned and reduced in number

→ increased porosity of the skeleton leading to reduction in the bone mass but without distortion of architecture.

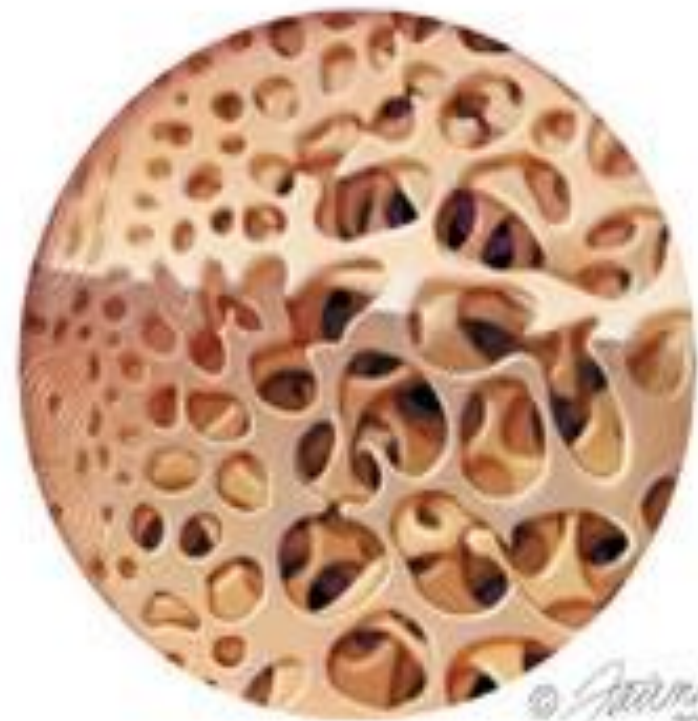□ It may be localized → disuse osteoporosis of a limb.

or

may involve the entire skeleton, as a metabolic bone disease.

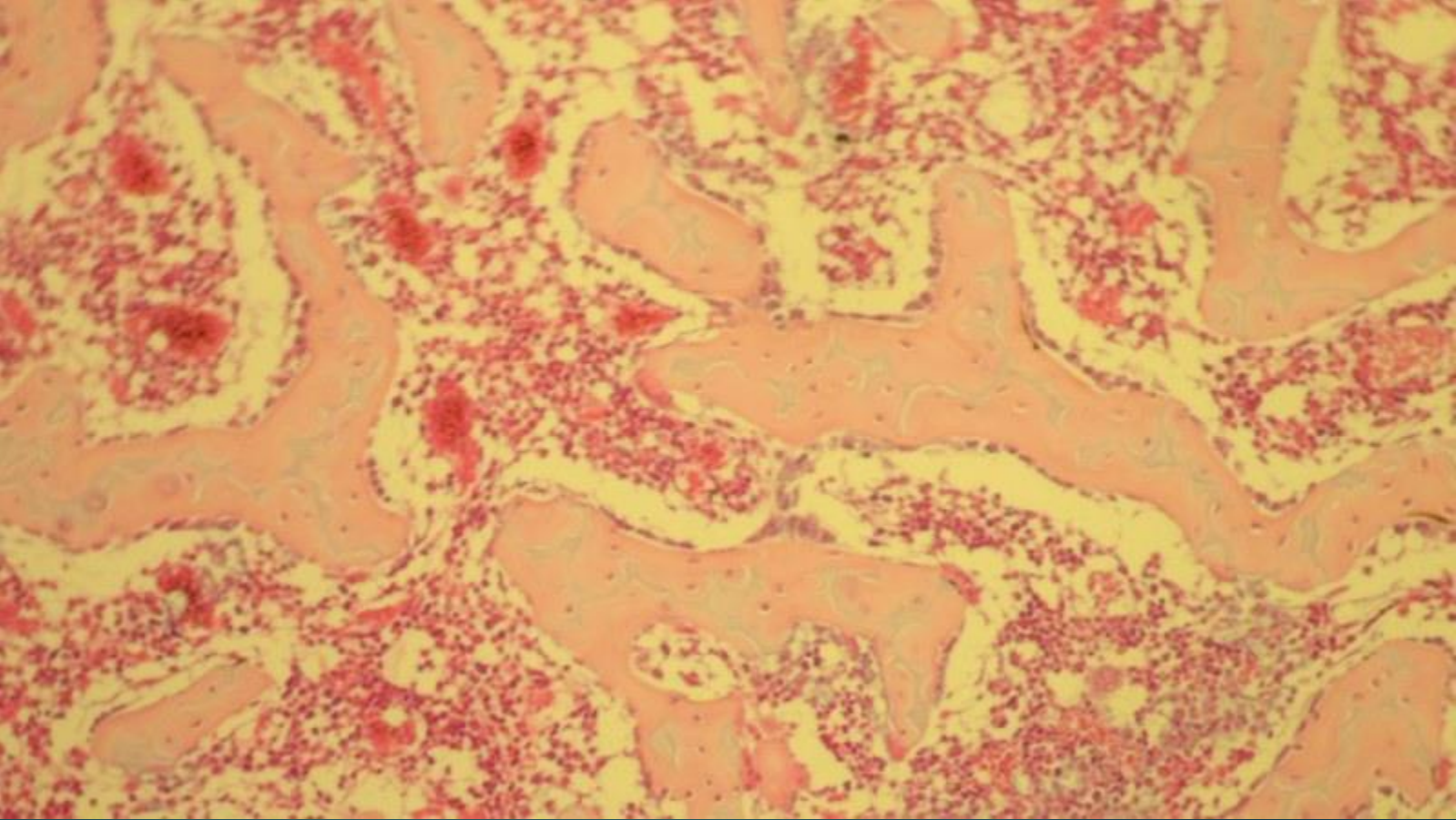
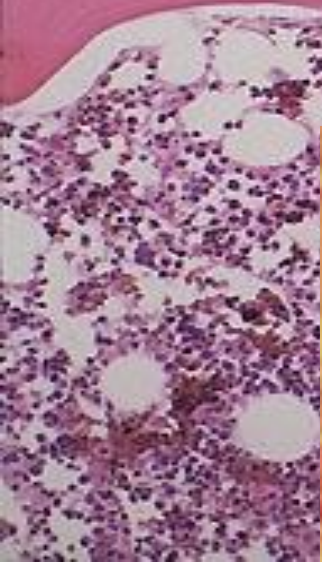
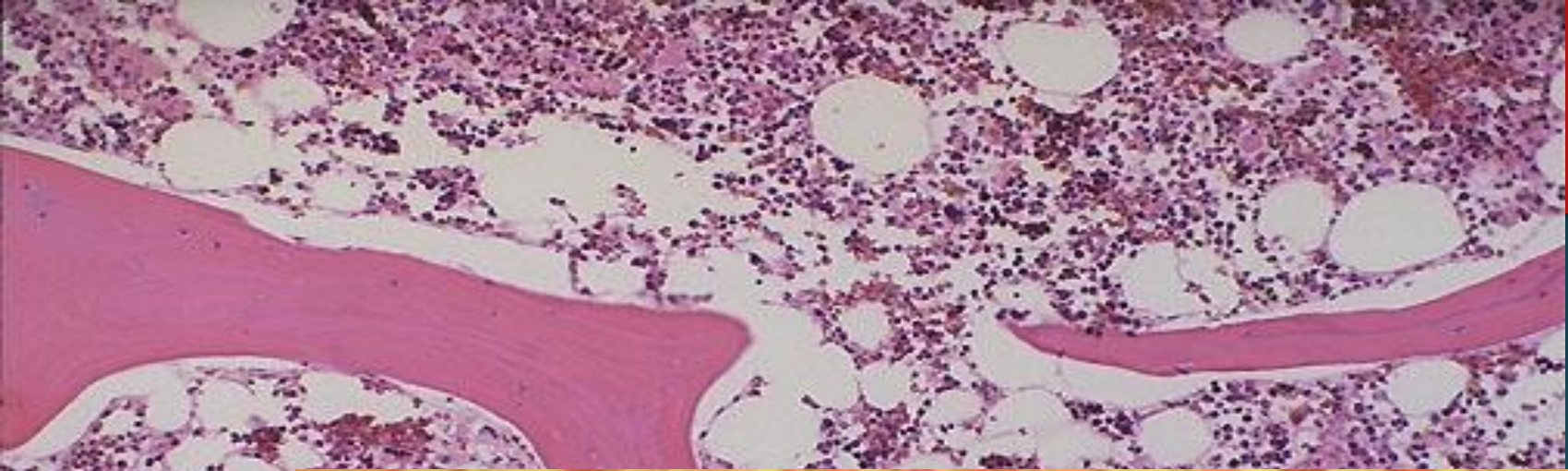


Normal



Osteoporotic bone

© *Freeman*
2004





OSTEOPOROSIS

Categories of Generalized Osteoporosis

- ▶ Primary
- ▶ Secondary

OSTEOPOROSIS

PRIMARY:

- ▶ Idiopathic
- ▶ Post menopausal probably a consequence of declining levels of estrogen
- ▶ Senile

Environmental factors may play a role in osteoporosis in the elderly: decreased physical activity and nutritional protein or vitamin deficiency (1,25-dihydroxycholecalciferol)

Post menopausal Osteoporosis

- ▶ In the decade after menopause, yearly reductions in bone mass may reach up to 2% of cortical bone and 9% of cancellous bone. Women may lose as much as 35% of their cortical bone and 50% of their cancellous bone by 30 to 40 years after menopause.

OSTEOPOROSIS

- ▶ Secondary:
 - ▶ Endocrine Disorders
 - ▶ Gastrointestinal disorders
 - ▶ Neoplasia
 - ▶ Drugs
 - ▶ Others (Smoking, Immobilization, Anemia, Pulmonary disease)

such as Addison disease, DM type 1, hypo or hyperthyroidism, and

Chronic renal failure

Malnutrition
Malabsorption
Hepatic insufficiency
Vitamin C, D

deficiencies

Drugs:

Anticoagulant
s
Chemotherap
y
Corticosteroid

s

Neoplasia:

Multiple myeloma
Carcinomatosis

OSTEOPOROSIS

- ▶ The most common forms of osteoporosis are the senile and postmenopausal types.

OSTEOPOROSIS

Pathophysiology:

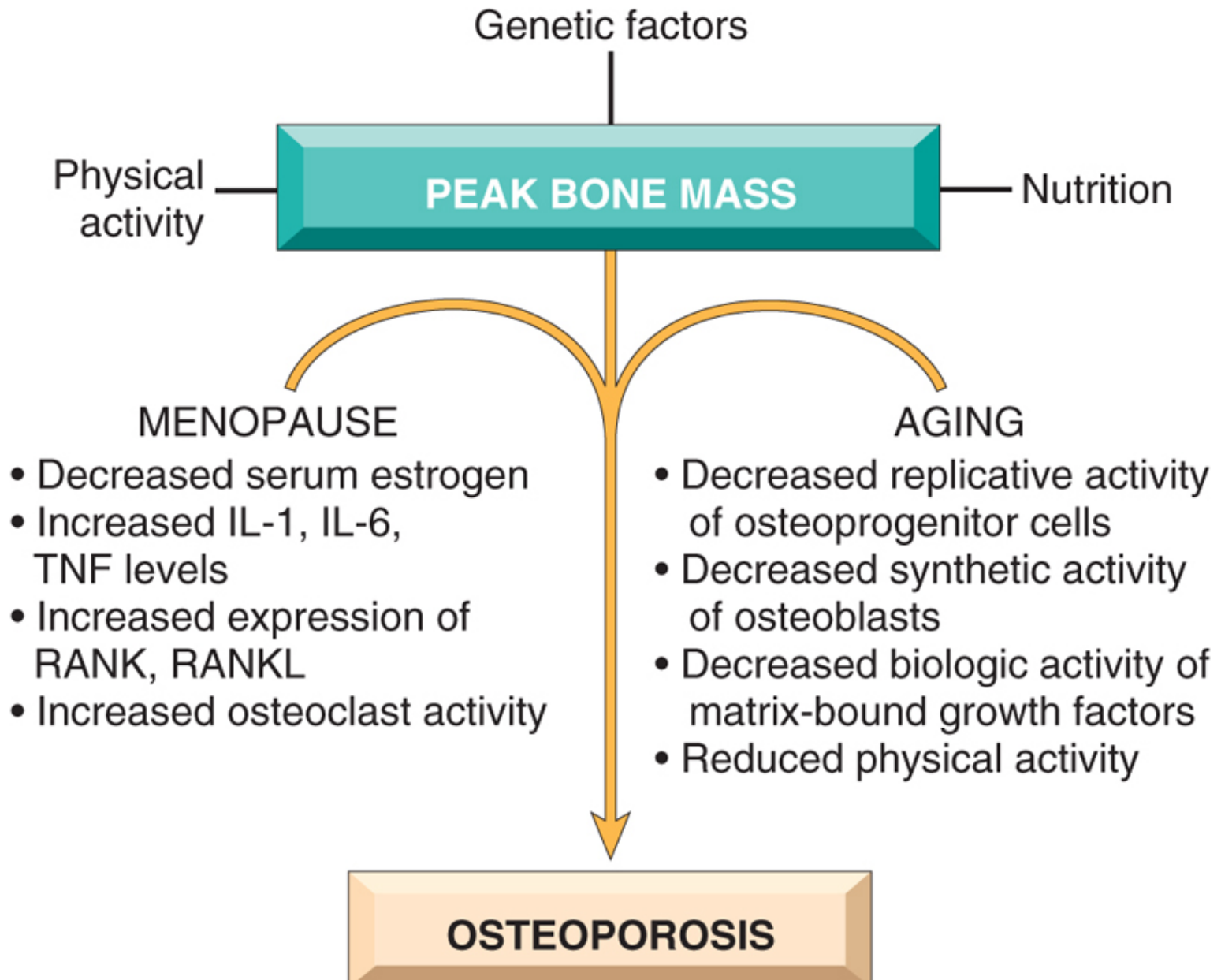
- ▶ Occur when the balance between bone formation and resorption tilts in favor of resorption

OSTEOPOROSIS

- ▶ **Pathophysiology:**
 - ▶ Genetic factors
 - ▶ Nutritional effects
 - ▶ Physical activity
 - ▶ Aging
 - ▶ Menopause


The postmenopausal drop in estrogen leads to increased cytokine production (especially IL-1, IL-6, and TNF), presumably from cells in the bone. These suppress OPG production

Bone mass peaks during young adulthood; the greater the peak bone mass, the greater the delay in onset of osteoporosis. In both men and women, beginning in the third or fourth decade of life, bone resorption begins to outpace bone formation.



OSTEOPOROSIS

- ▶ Clinical features
 - ▶ Difficult to diagnose
 - ▶ Remain asymptomatic ----fracture
 - ▶ Fractures
 - ▶ Vertebrae
 - ▶ Femoral neck
- ▶ Patients with osteoporosis have normal serum levels of calcium, phosphate, and alkaline phosphatase

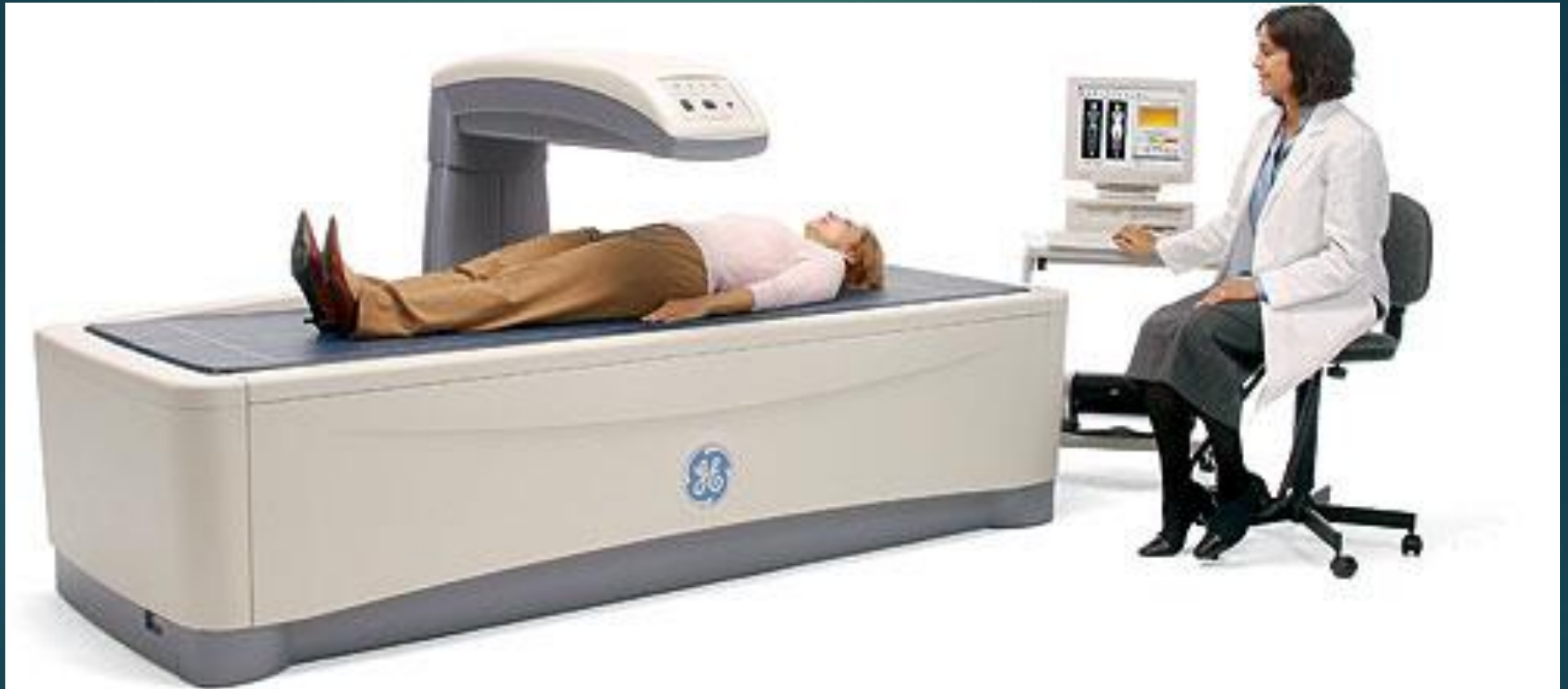

Diagnosis

Bone density by radiographic measures

- ▶ Plain X ray: cannot detect osteoporosis until 30% to 40% of bone mass has already disappeared.
- ▶ Dual-emission X-ray absorptiometry (DXA scan): is used primarily to evaluate bone density, to diagnose and follow up pt. with osteoporosis.

DXA scan



Prognosis

- Osteoporosis is rarely lethal.
- Patients have an increased mortality rate due to the complications of fracture.
 - e.g. hip fractures can lead to decreased mobility and an additional risk of numerous complications: deep vein thrombosis, pulmonary embolism and pneumonia

OSTEOPOROSIS

Prevention Strategies

- ▶ The best long-term approach to osteoporosis is prevention.
- ▶ children and young adults, particularly women, with a good diet (with enough calcium and vitamin D) and get plenty of exercise, will build up and maintain bone mass.
- ▶ This will provide a good reserve against bone loss later in life. Exercise places stress on bones that builds up bone mass



International Osteoporosis
Foundation

LOVE YOUR BONES



embrace an active lifestyle



embrace calcium rich foods




embrace vitamin D

World Osteoporosis Day & Unbreakable Embrace

Metabolic bone disease

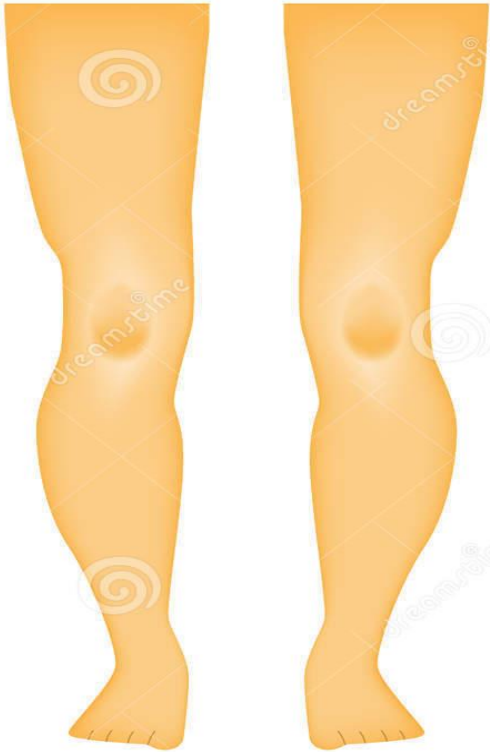- In **osteomalacia and Rickets**, osteoblastic production of bone collagen is normal **but mineralization is inadequate**. It is a manifestations of vitamin D deficiency

- 
- ▶ Rickets refers to the disorder in children, in which it interferes with the deposition of bone in the growth plates.
 - ▶ Osteomalacia is the adult counterpart, in which bone formed during remodeling is undermineralized, resulting in predisposition to fractures.

Leg bowing

Rickets

Normal



Rickets

