

Musculoskeletal Block

Pathology of Musculoskeletal System

Practical Classes

Prepared by:

- Prof. Ammar Al Rikabi
- Dr. Sayed Al Esawy

Head of Pathology Department: Dr. Hisham Al Khalidi

Objectives:

At the end of the practical sessions for this block, the students will be able to:

- Describe the normal structure of the musculoskeletal system.
- Identify the morphological features (gross and microscopic) of bone and joints' diseases and muscular dystrophies.

Contents:

- **Study of the anatomical and histological structure of bones and muscles.**
- **Study of the gross and histopathological features of the following disorders through case discussion:**

1st Practical:

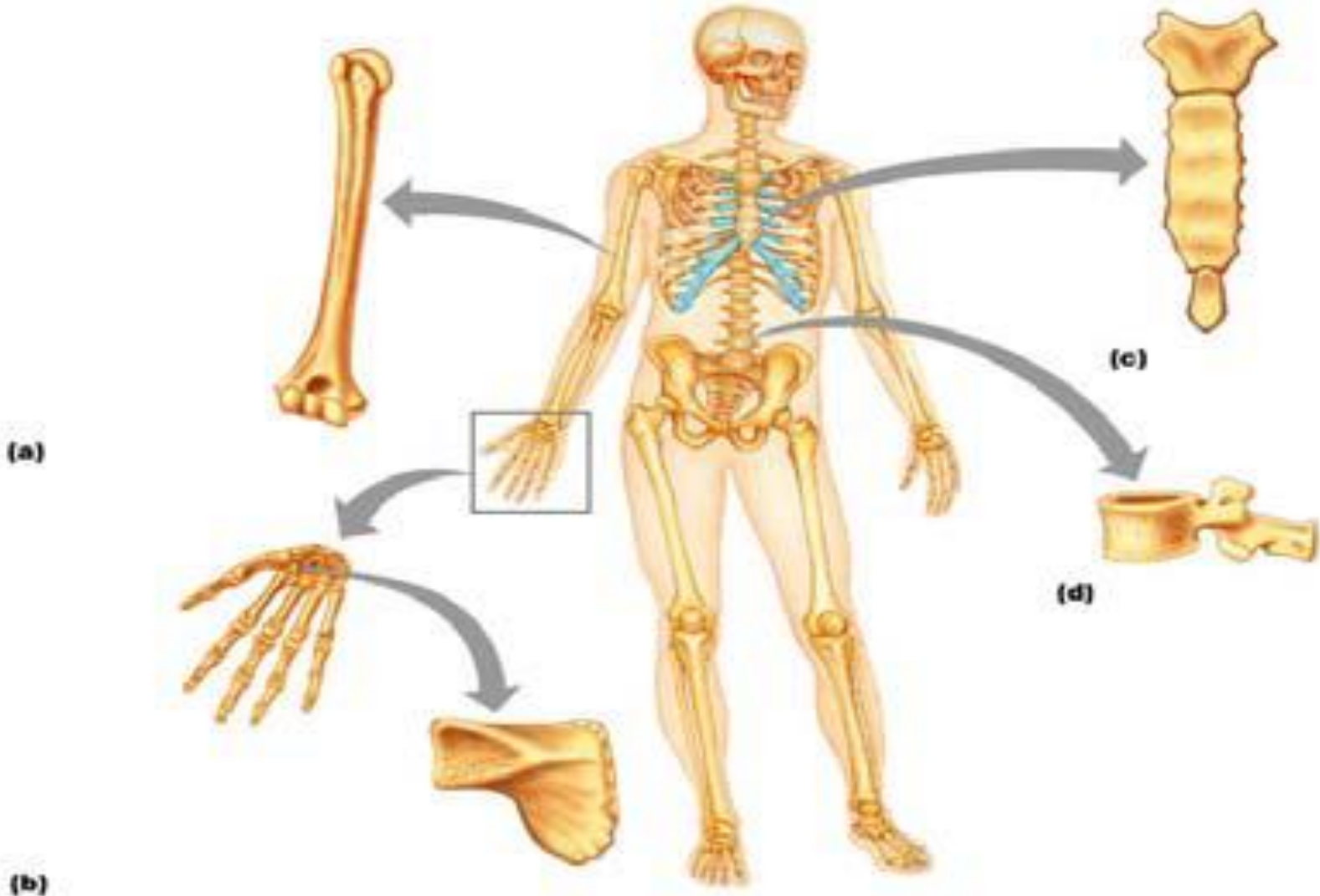
- **Duchenne Muscular Dystrophy.**
- **Dermatomyositis.**
- **Myasthenia Gravis.**
- **Myotonic Dystrophy.**
- **Osteoporosis.**

2nd Practical:

- **Osteoarthritis.**
- **Rheumatoid arthritis.**
- **Gout.**
- **Osteomyelitis.**
- **Pott's disease.**
- **Osteochondroma.**
- **Osteosarcoma.**

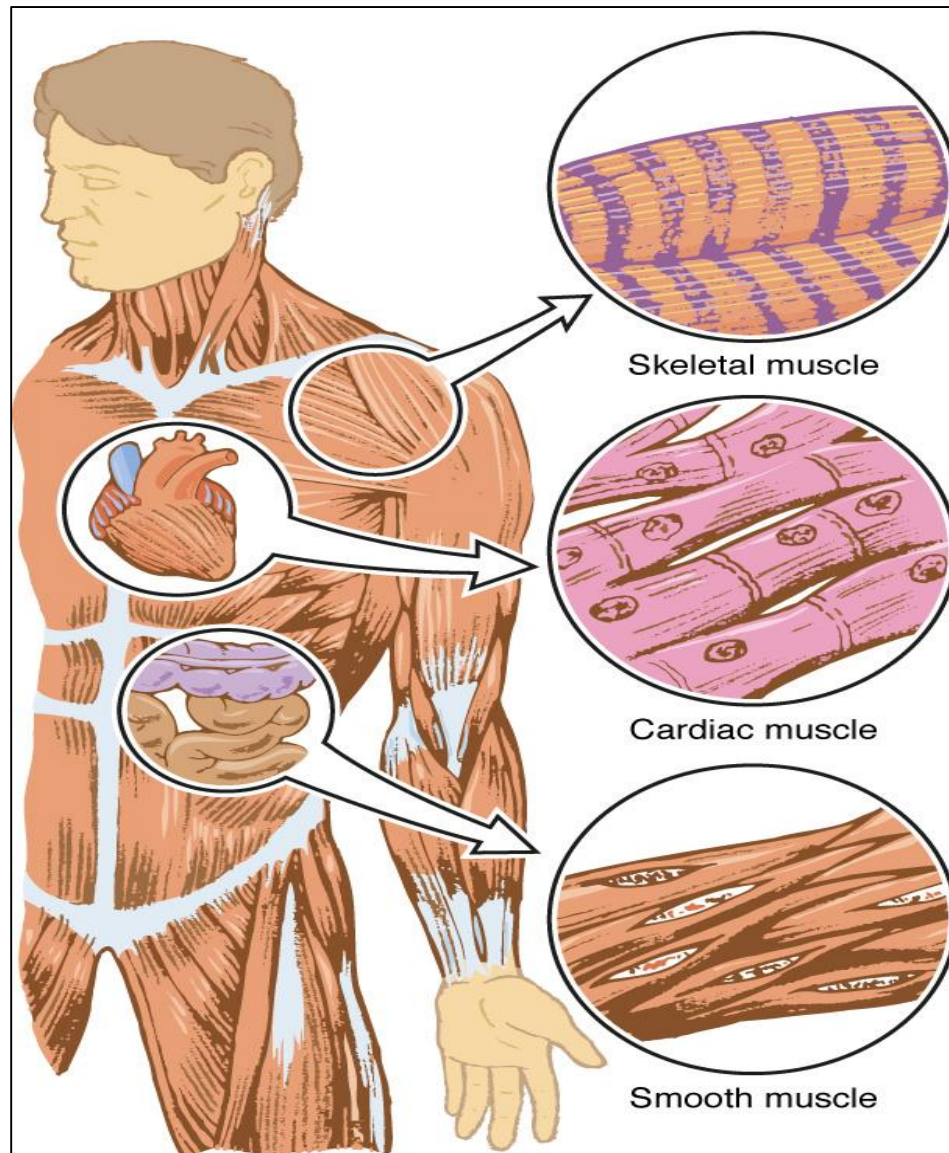
ANATOMY AND HISTOLOGY

Body Skeleton

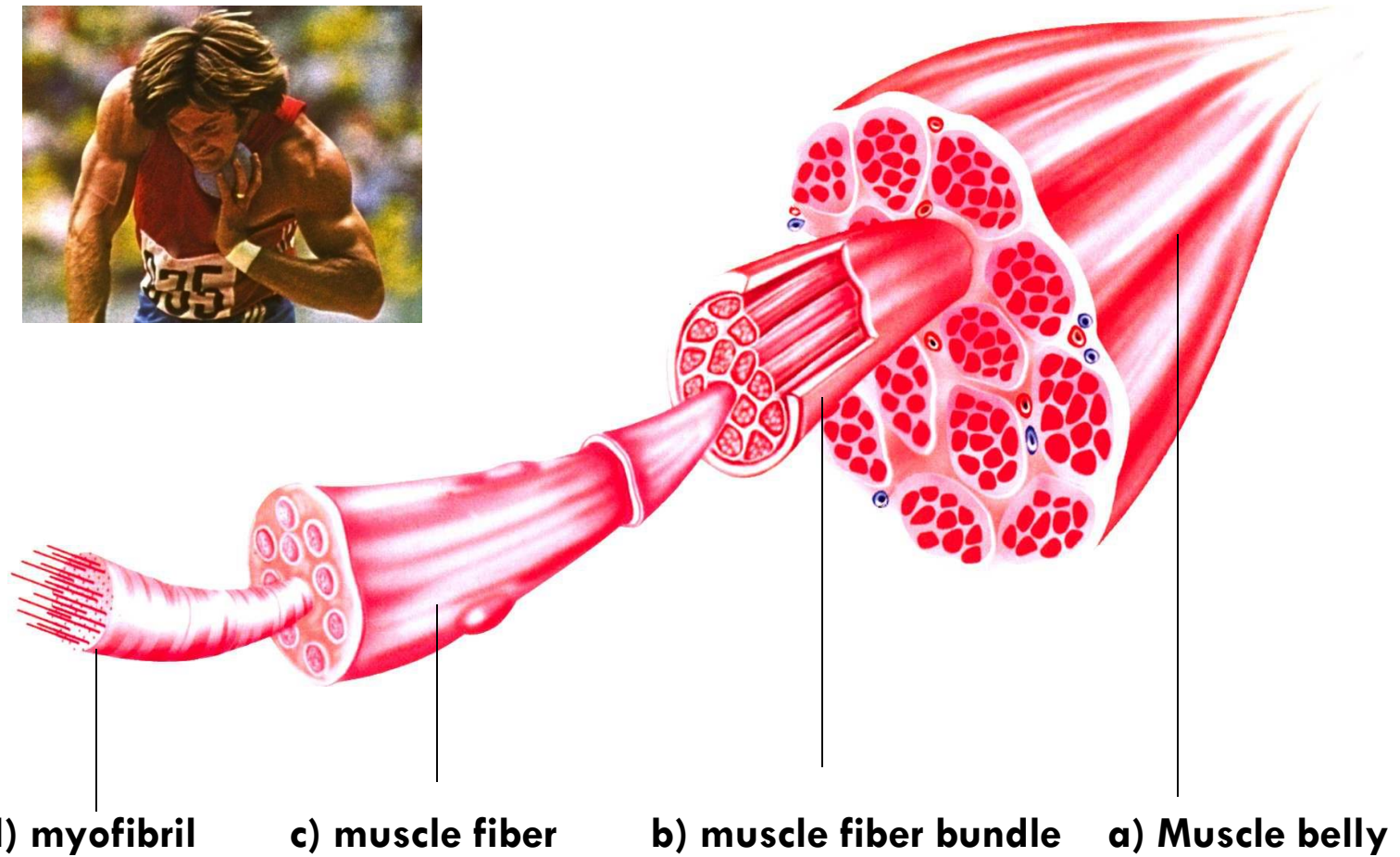



Copyright © 2004 Pearson Education, Inc., publishing as Benjamin Cummings.


Types of muscles



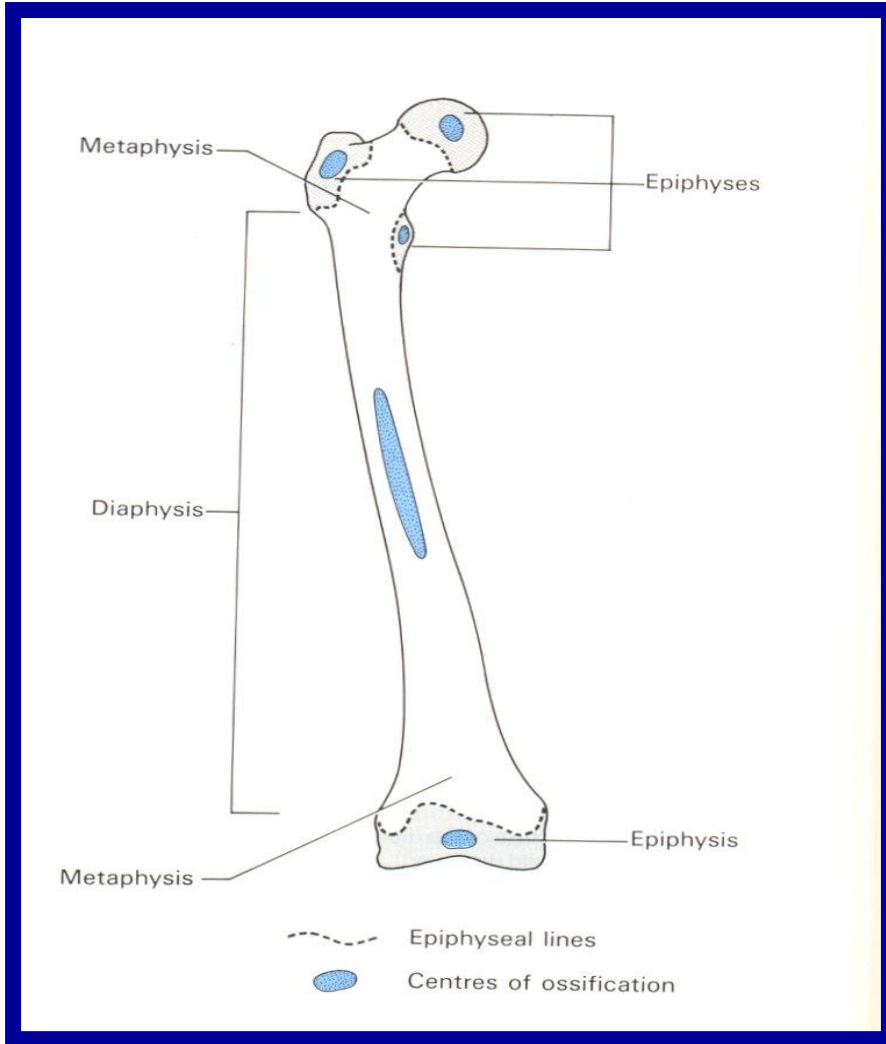
Components of skeletal muscle



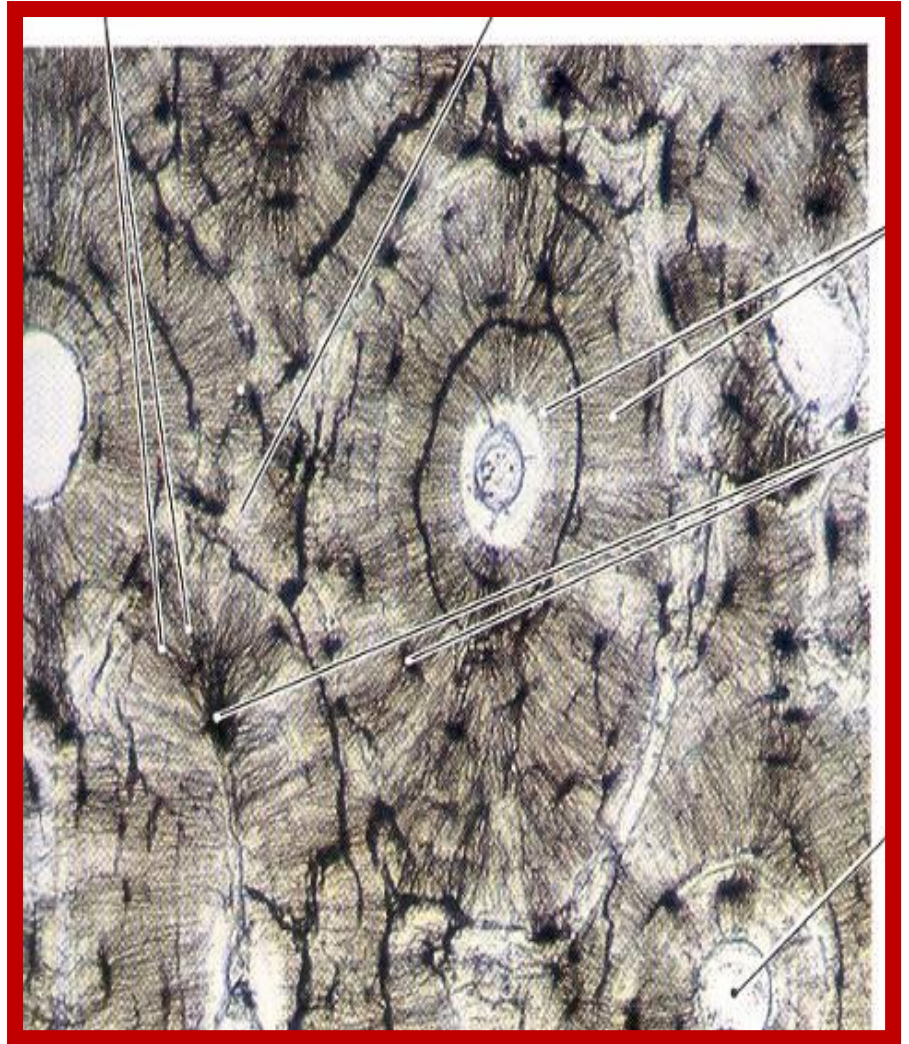
Sarcomeres within a myofibril - HPF



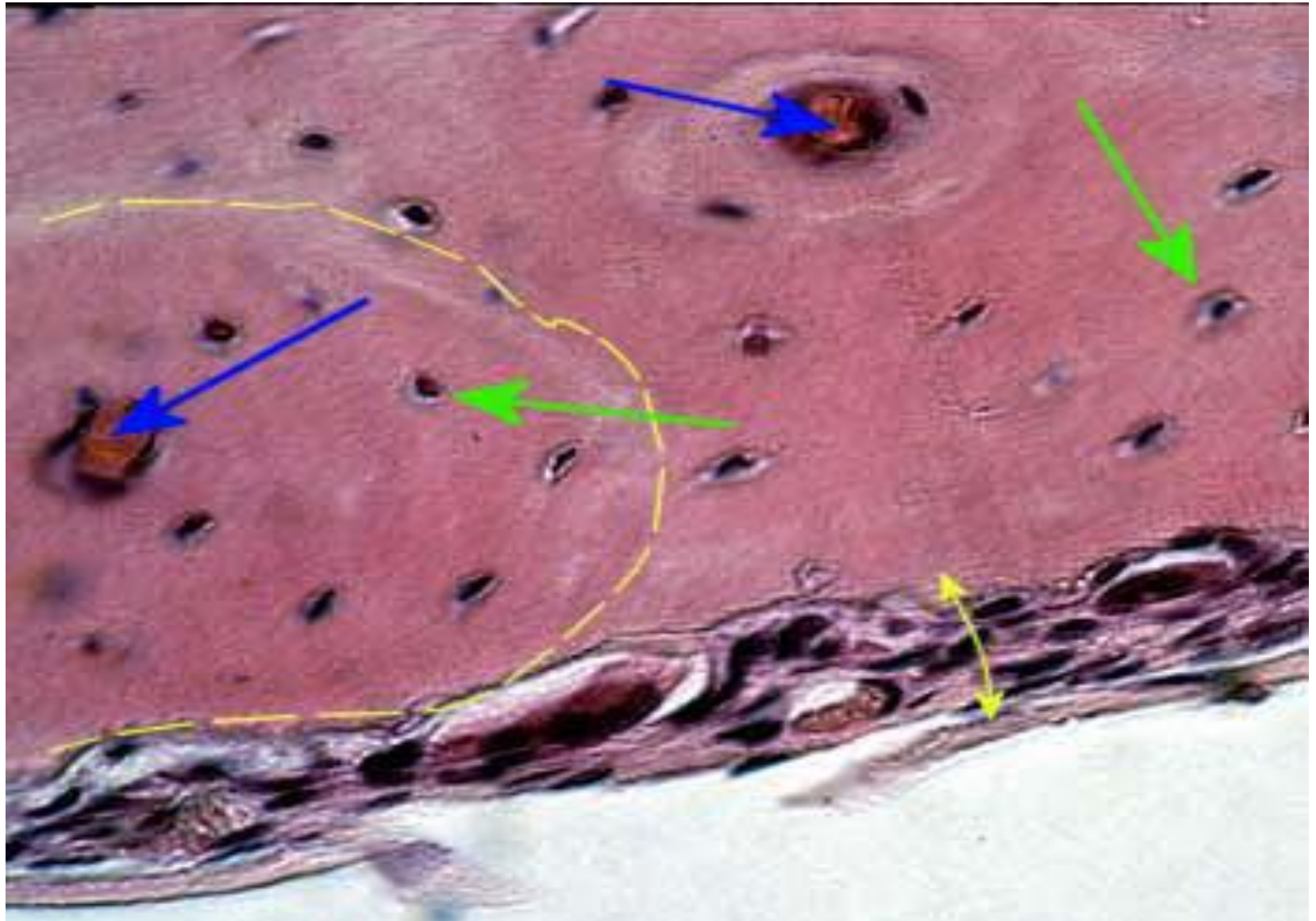
Structure of a long bone



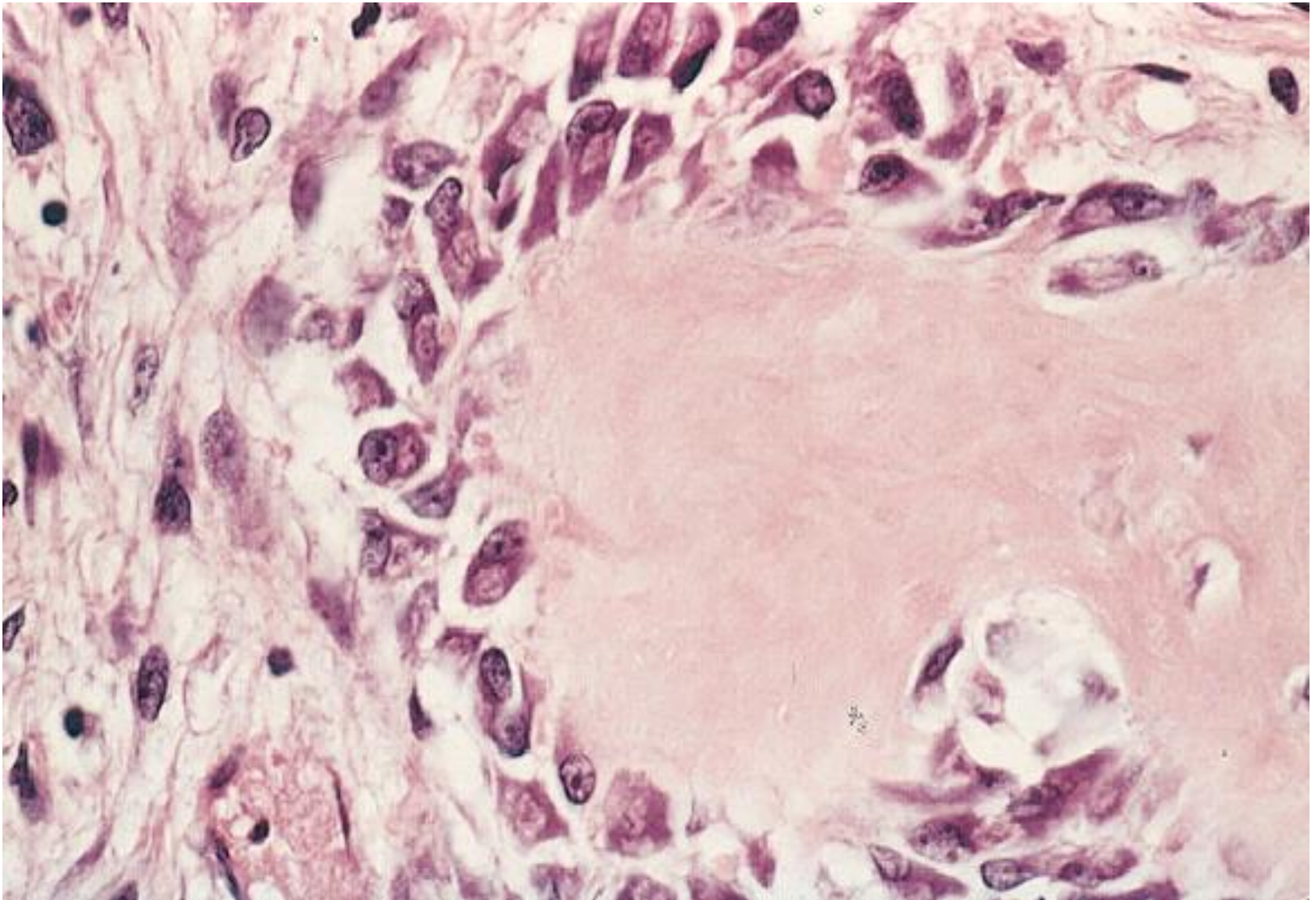
Thin Section of Compact Bone



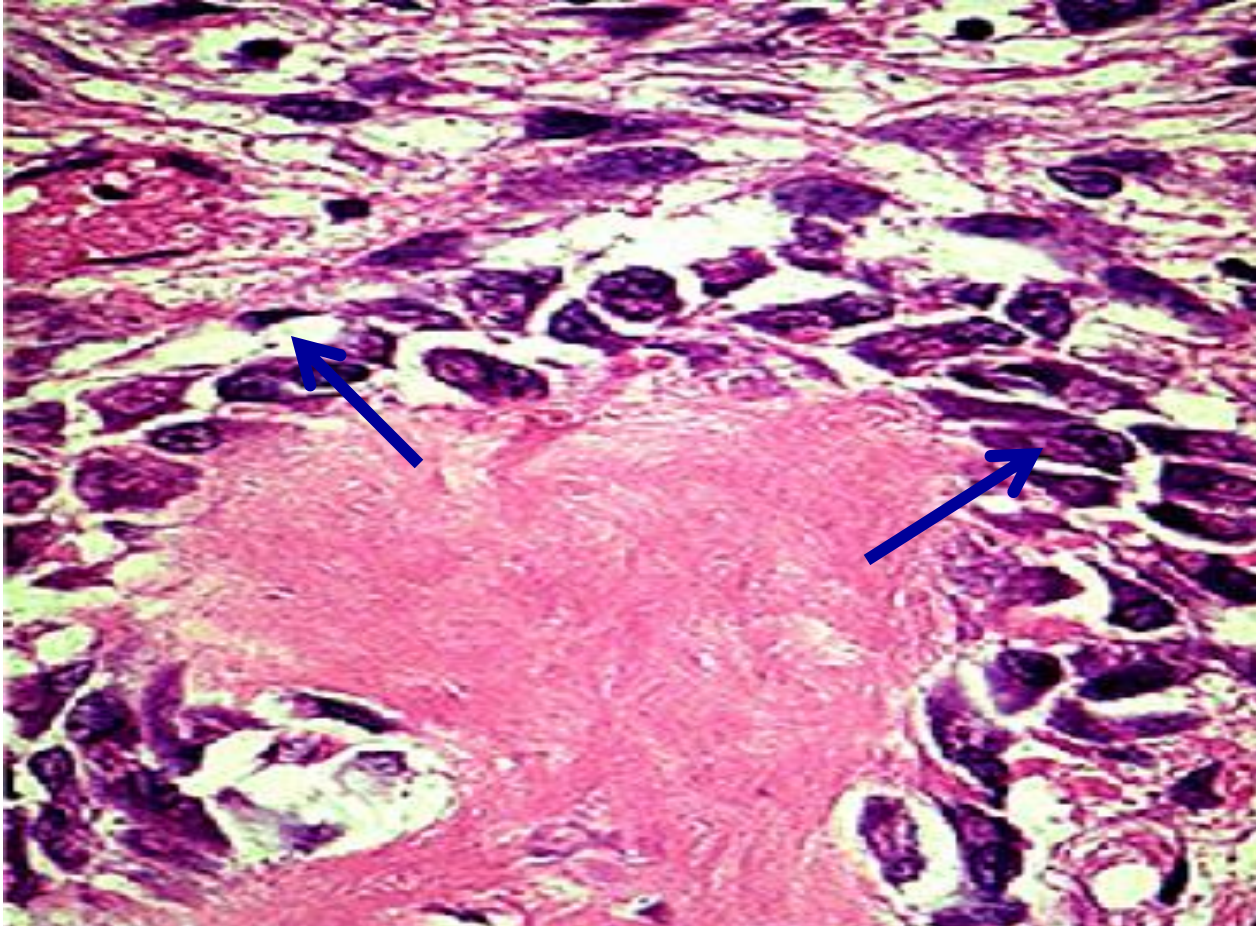
BONE STRUCTURE - LPF



BONE STRUCTURE - HPF

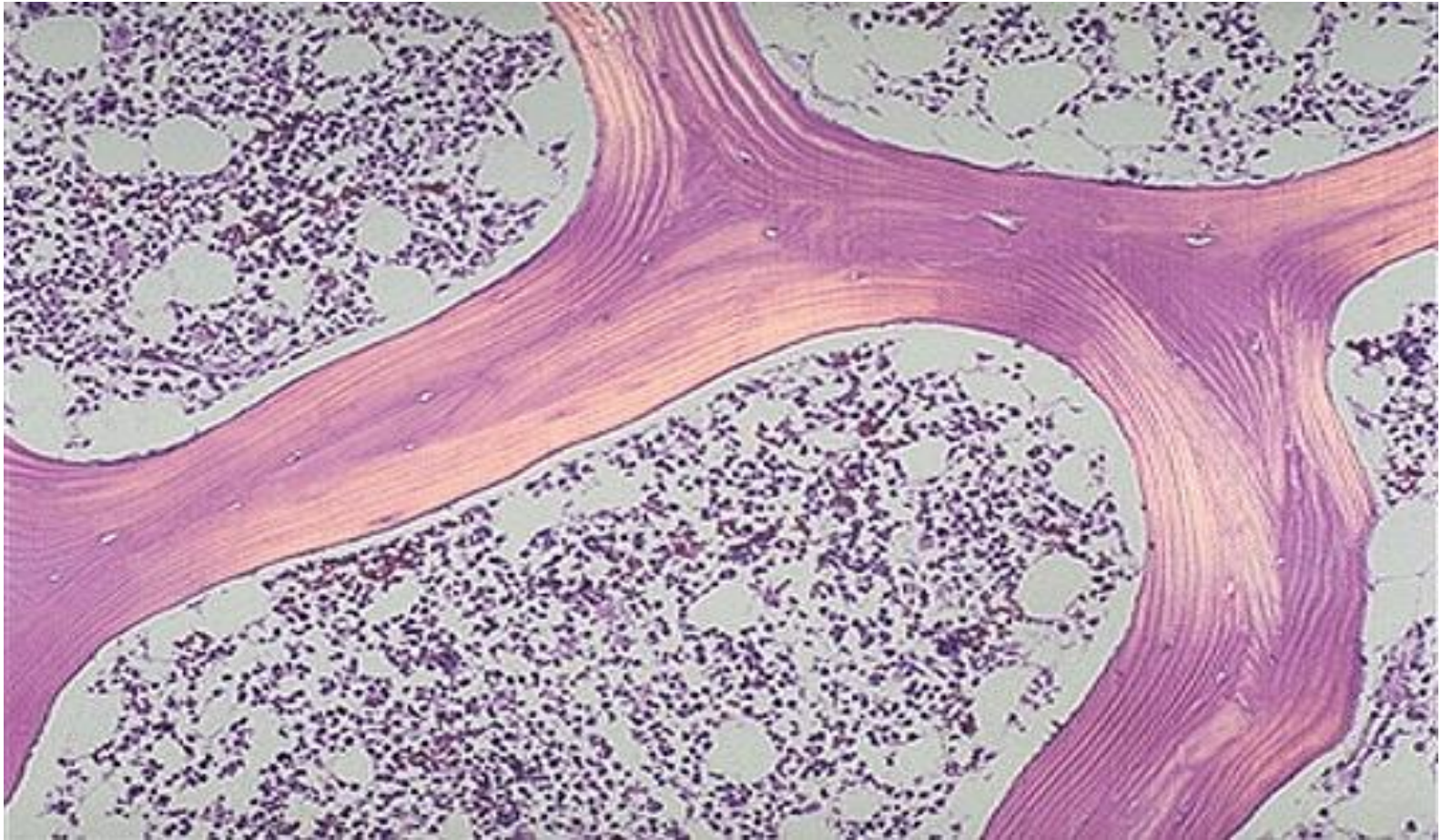

BONE STRUCTURE - HPF



Active osteoblasts synthesizing bone matrix. The surrounding spindle cells represent osteoprogenitor cells

Normal Cancellous Bone - LPF

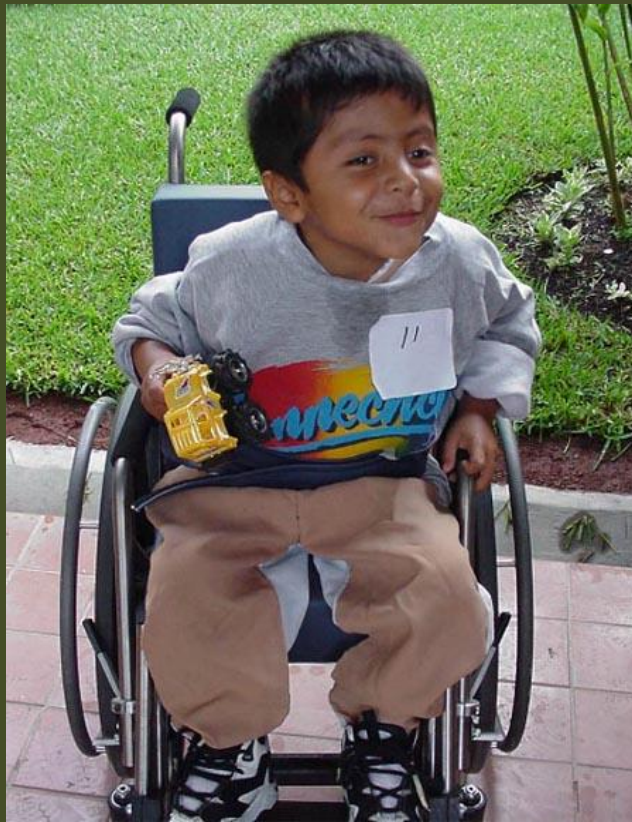

Normal cancellous bone as seen under polarized light microscopy, which highlights the lamellar structure.
The bony spicules are even, with occasional lacunae containing osteocytes.
Cellular marrow is seen between the spicules of bone.



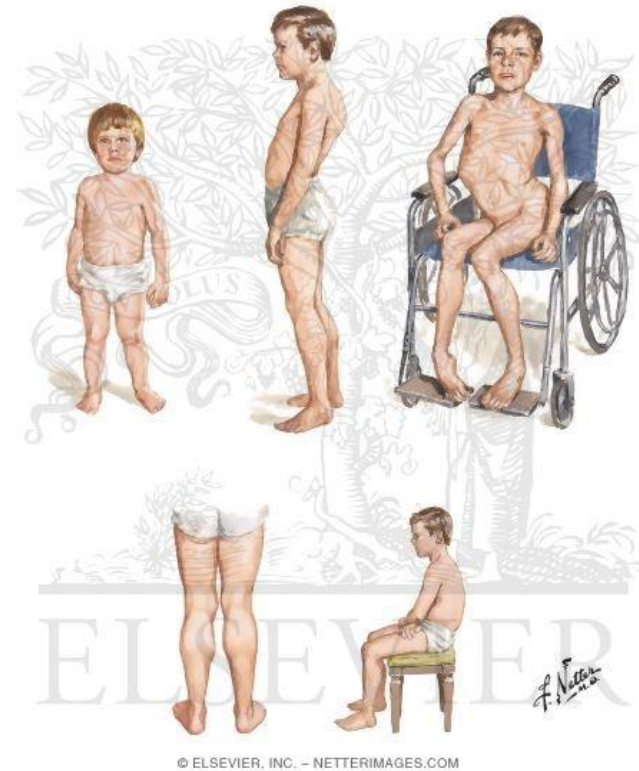
Muscular Dystrophies

Duchenne Muscular Dystrophy (DMD)



Case # 1

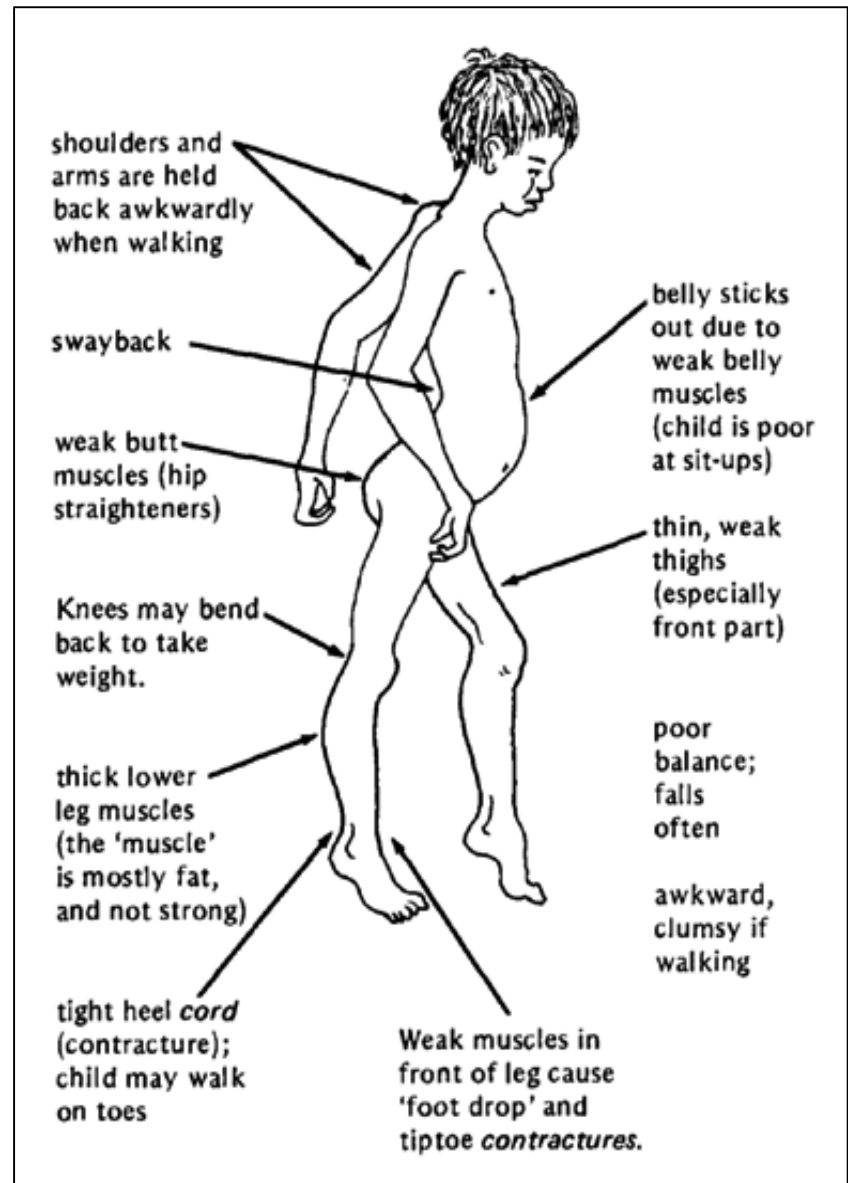
- A 3 - year- old boy presented to his pediatrician with complaint of his parents from difficulty in walking , poor balance , and frequent falls .
- Laboratory investigation shows elevated creatine kinase .
- Muscle biopsy show absence of dystrophin by western blot analysis



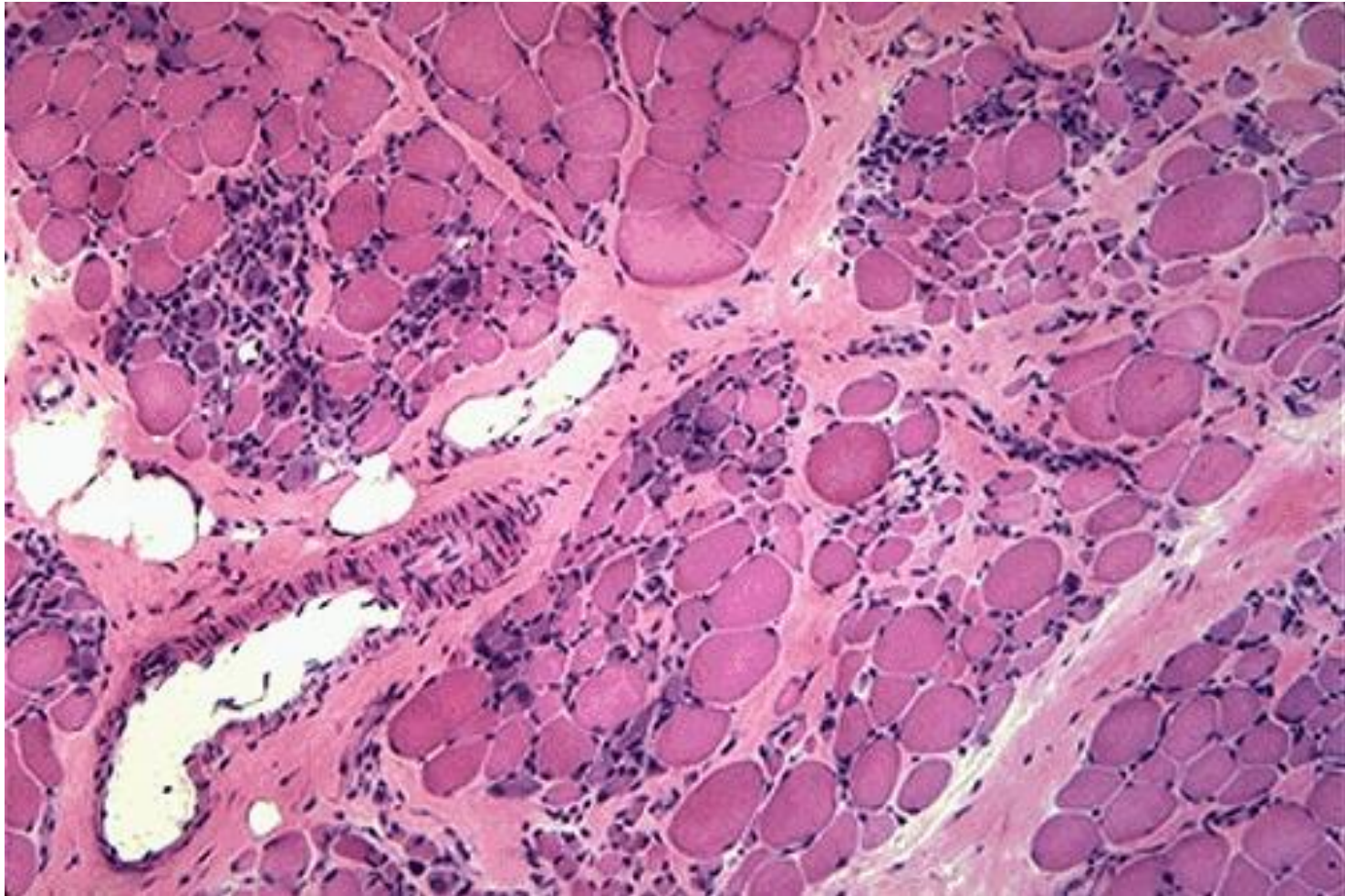
What is your provisional diagnosis?

Duchenne Muscular Dystrophy (DMD)

- **DMD is the most severe and common type of muscular dystrophy.**
- **DMD is characterized by the wasting away of muscles.**
- **DMD affects mostly males at a rate of 1 in 3,500 births**
- **Diagnosis in boys usually occurs between 16 months and 8 years.**
- **Death from DMD usually occurs by age of 30.**



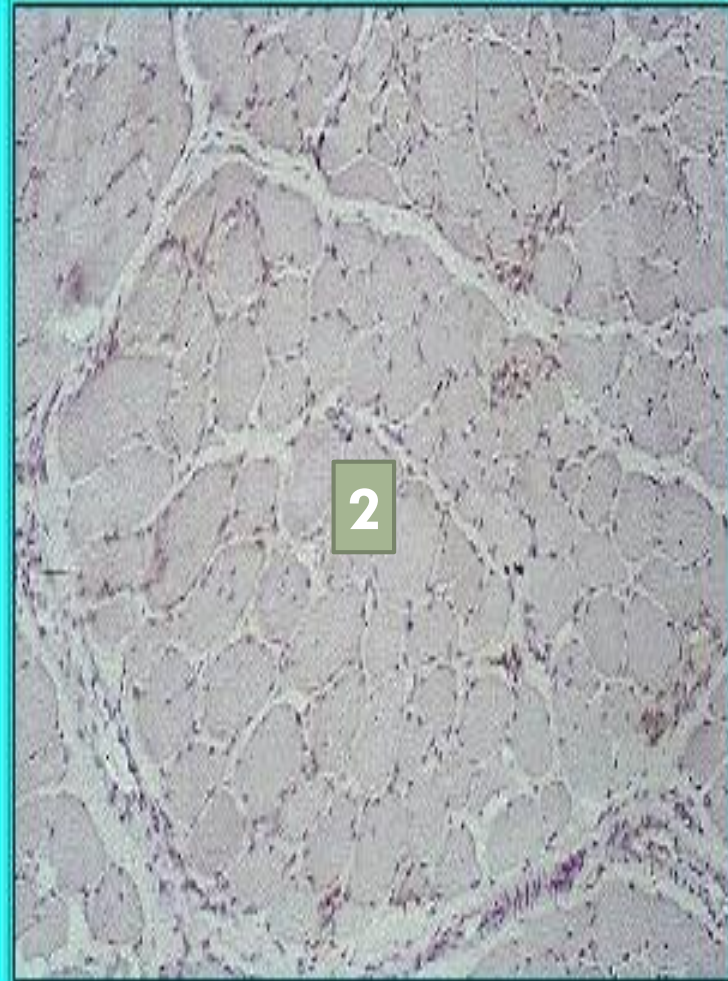
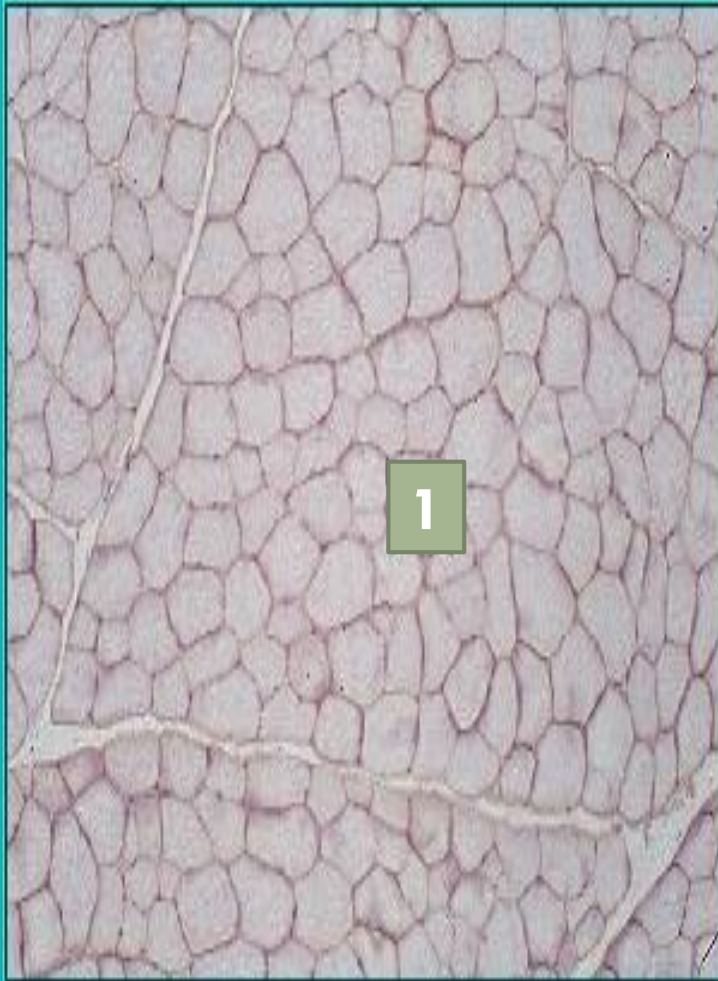Duchenne Muscular Dystrophy - LPF



Duchenne muscular dystrophy showing variations in muscle fiber size ,
increased endomysial connective tissue , and regenerating fibers
(blue tint) / hypercontracted fibres (hyaline fibres).

NORMAL Ms

DMD



In DMD : Dystrophin, an intracellular protein, forms an interface between the cytoskeletal proteins and a group of transmembrane proteins

Dermatomyositis

Case # 2

A 52-year-old woman presents with 6-month history of progressive muscle weakness and a skin rash.

Physical examination is remarkable for a diffuse purple/red discoloration of the skin over her cheeks, nose, and eyelids. Examination confirms proximal muscle weakness.

Laboratory findings show an increase in creatine kinase (10 times the normal).

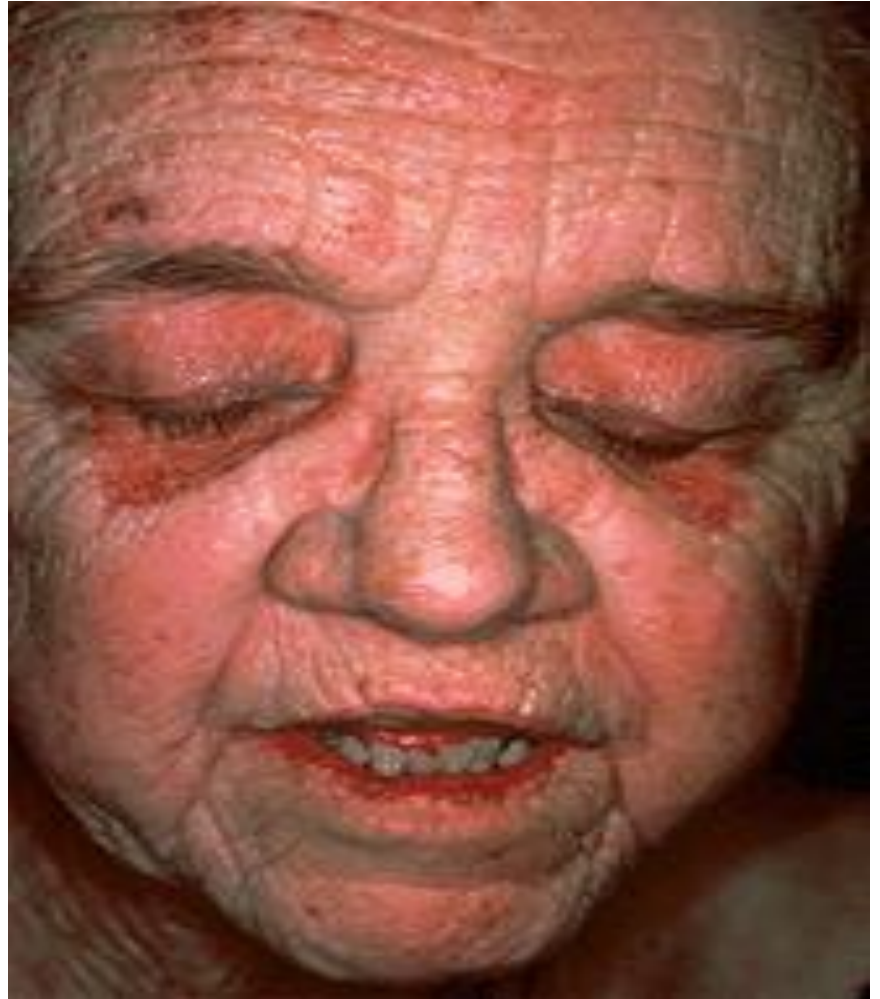Dermatomyositis

is an inflammatory myopathy characterized by inflammation of muscle tissue and a skin rash.

-Can occur in any individual with peak age patterns at: 5-15 years of age 40-60 years of age.

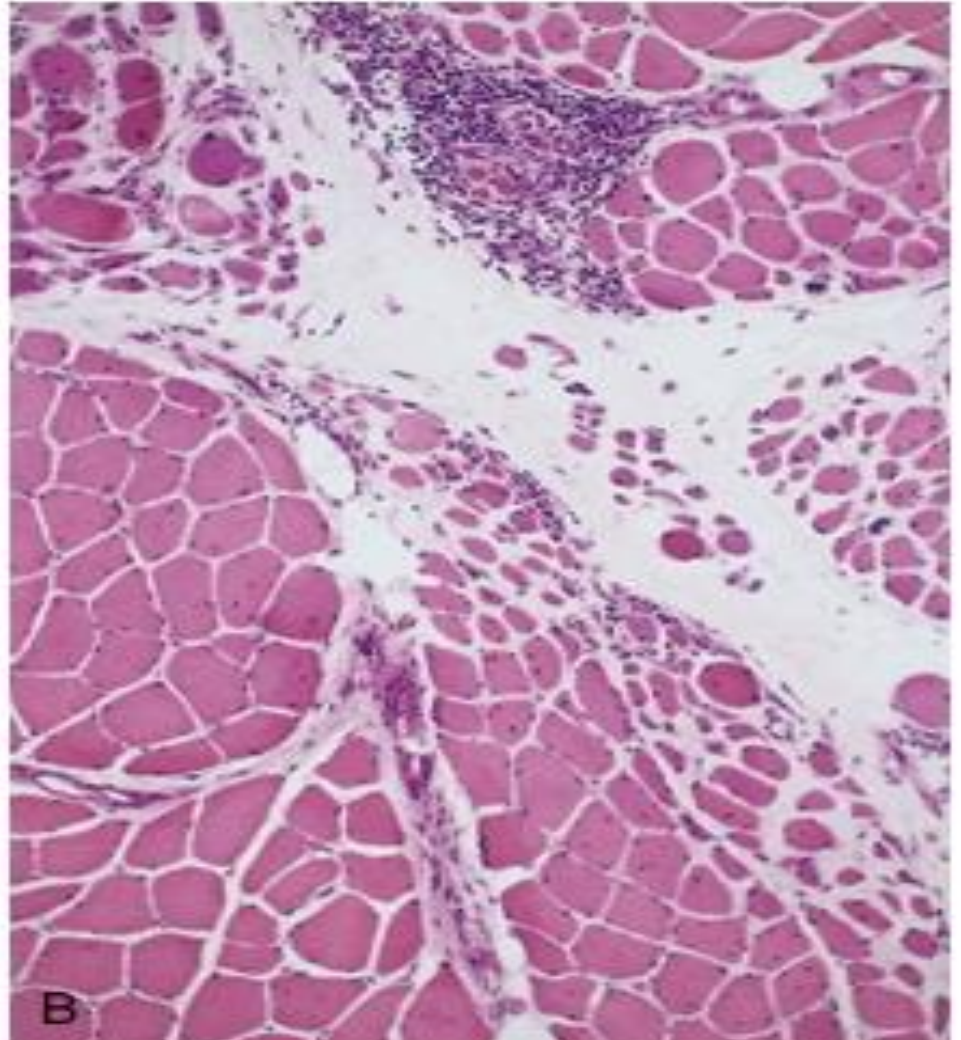
- Occurs more frequently in women.

-Purple/violet colored upper eyelids Purple-red skin rash

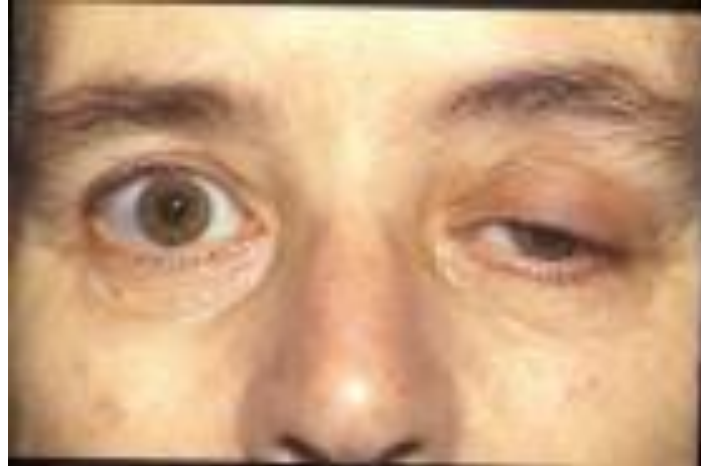

Dermatomyositis

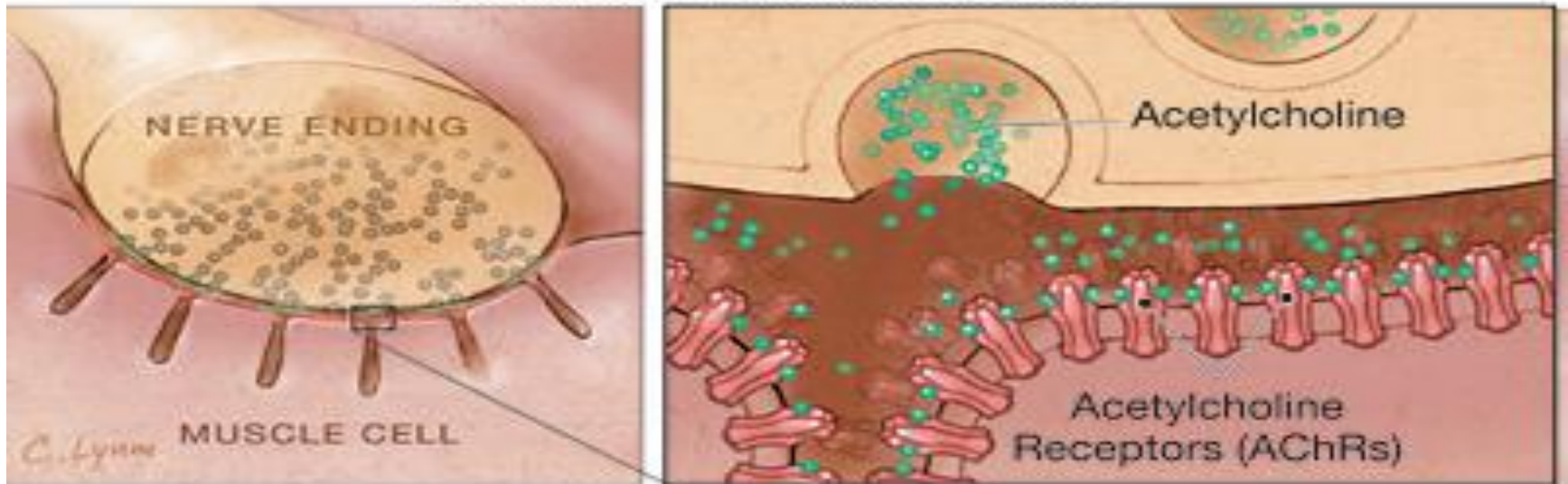
- The histologic appearance of muscle shows perifascicular atrophy of muscle fibers and inflammation .



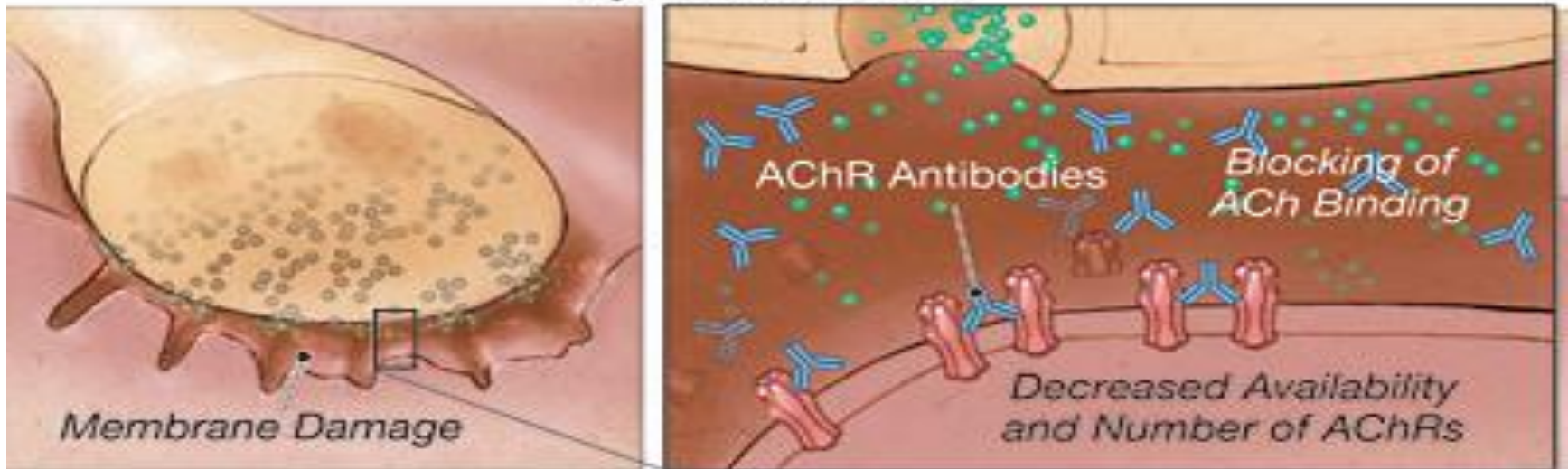
Myasthenia Gravis



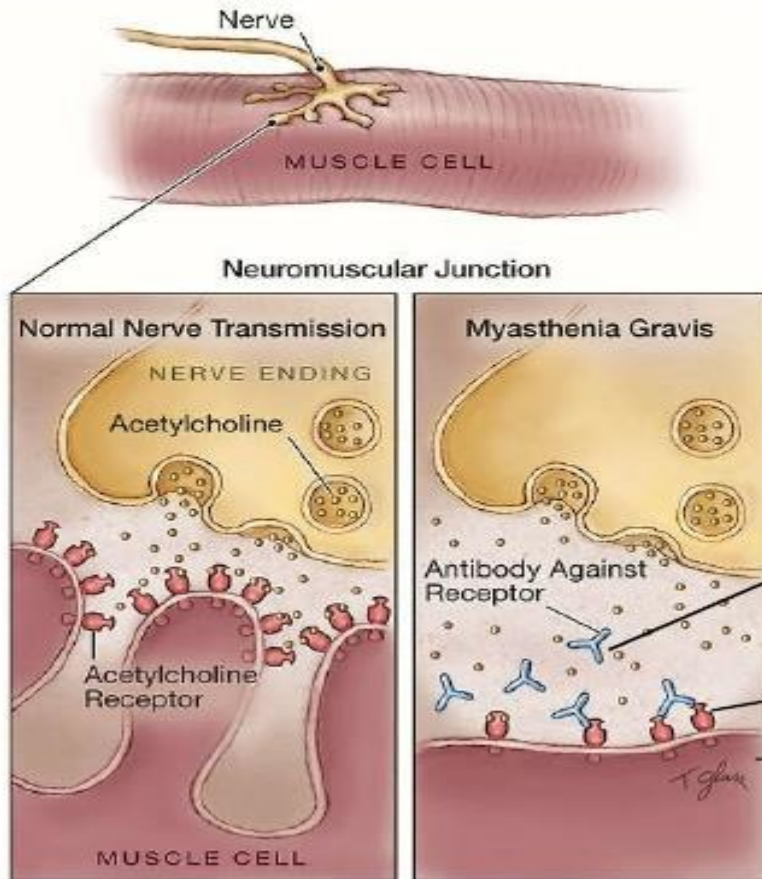
Normal Neuromuscular Junction



Myasthenia Gravis



Myasthenia Gravis



Antibodies

AChRs

Simplified Motor Endplates

Myasthenia Gravis

- **Several Types of Myasthenia Gravis**
 - **Neonatal Myasthenia Gravis:** A transient condition in 10% to 15% of infants born to mothers with MG.
 - **Congenital Myasthenia**
 - **Juvenile Myasthenia:** Onset is around 10 years of age.
 - **Ocular Myasthenia**
 - **Generalized Autoimmune Myasthenia**
- **Acquired autoimmune disorder**
 - **fundamental defect is a decrease in the number of available AChRs at the postsynaptic muscle membrane**
 - **simplification of the postsynaptic folds and widening of the synaptic cleft**
- **Clinically characterized by:**
 - **Weakness of skeletal muscles**
 - **Fatigability on exertion.**

Pathology of MG

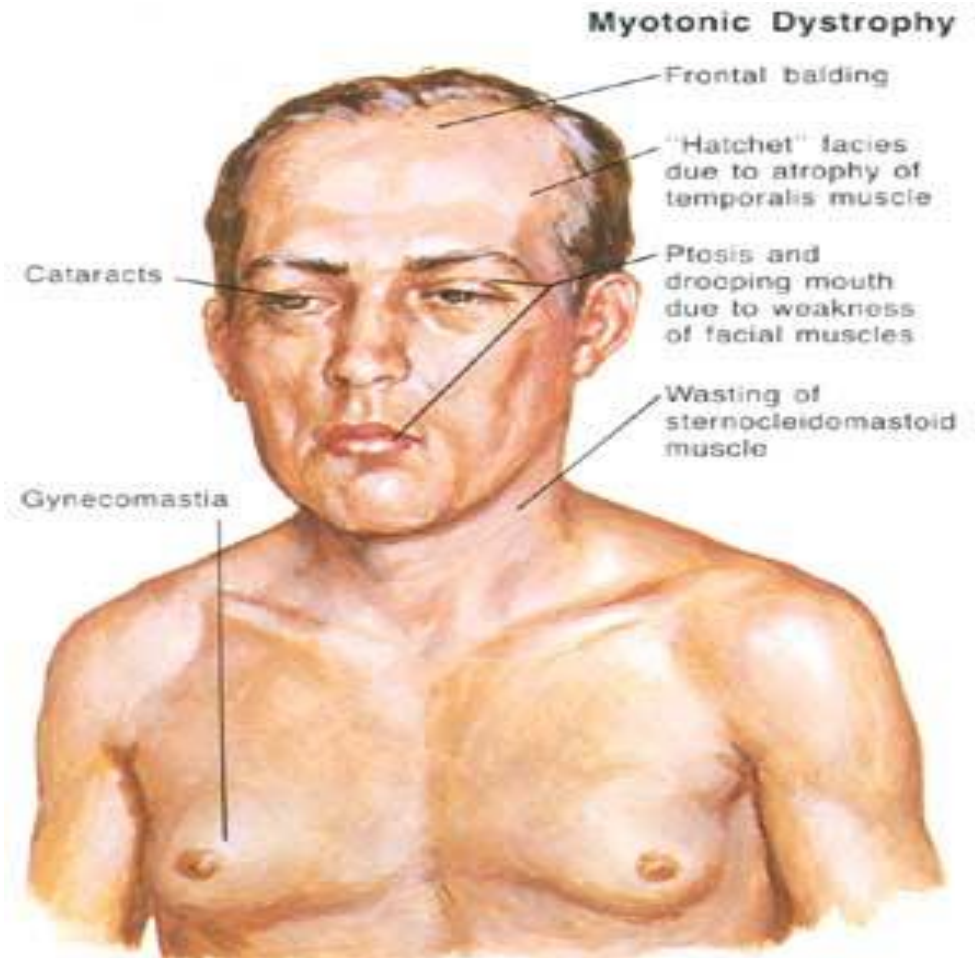
- The neuromuscular abnormalities in MG are brought about by an autoimmune response mediated by specific anti-AChR antibodies
- These antibodies reduce the available AChR's at neuromuscular junctions
- the thymus is abnormal in approximately 75% of patients with MG
- In 65% of patients the thymus is hyperplastic



Myotonic dystrophy

Myotonic Dystrophy

- Also known as *dystrophia myotonica*
- Composed of 2 clinical disorders with overlapping phenotypes & distinct molecular genetic defects:
 1. DM1- the classic disease
 2. DM2- proximal myotonic myopathy
- Autosomal dominant disease





OSTEOPOROSIS

OSTEOPOROSIS

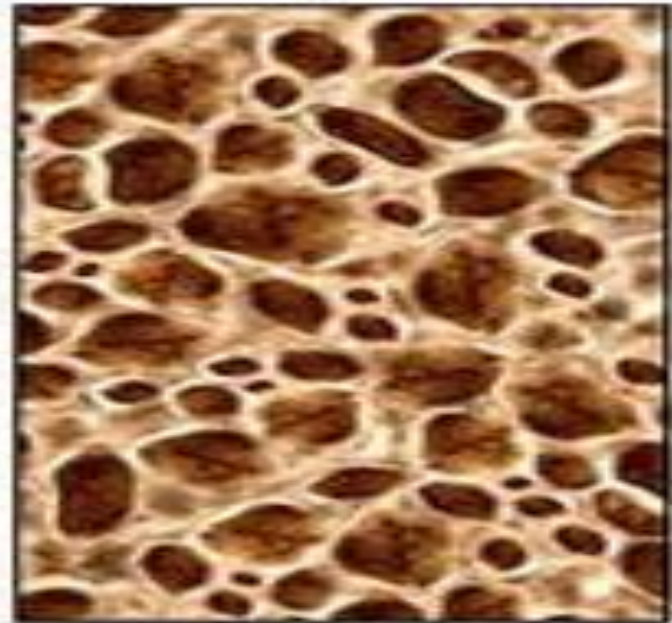
A disease characterized by low bone mass and microarchitectural deterioration of the bone tissue

Leading to: enhanced bone fragility and increase in fracture risk

Normal bone



Bone with Osteoporosis



In osteoporosis, the rate of formation is inadequate to offset the rate of resorption and maintain the structural integrity of the skeleton

STAGES OF FRACTURE HEALING

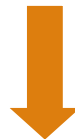Inflammation



Necrosis Tissue and Exudate Resorbed



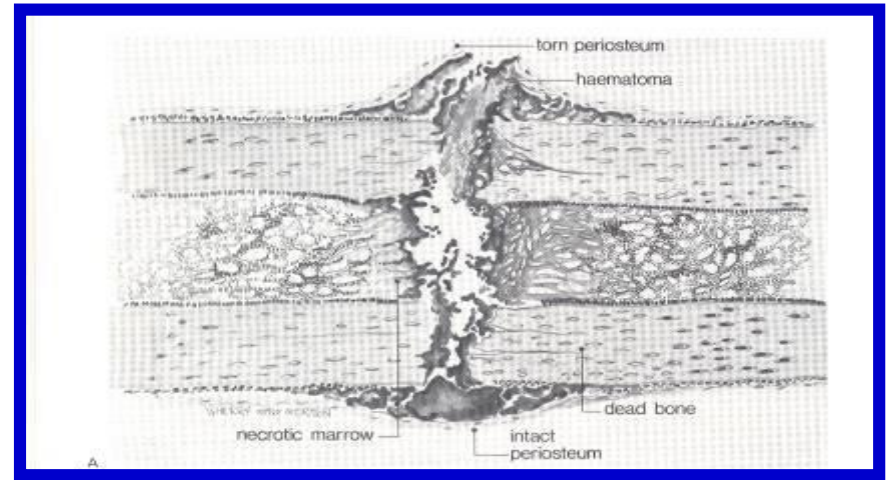
Fibroplasty & Chondrocytes Appears



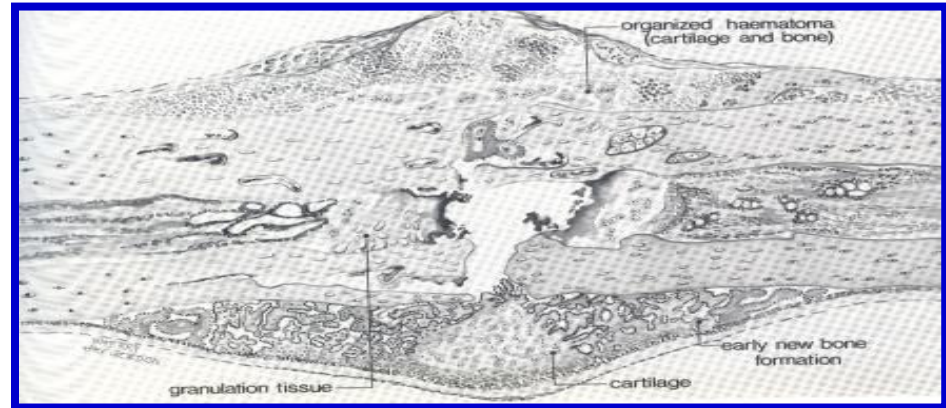
**Produce new matrix
(The fracture callus)**

STAGES OF FRACTURE HEALING

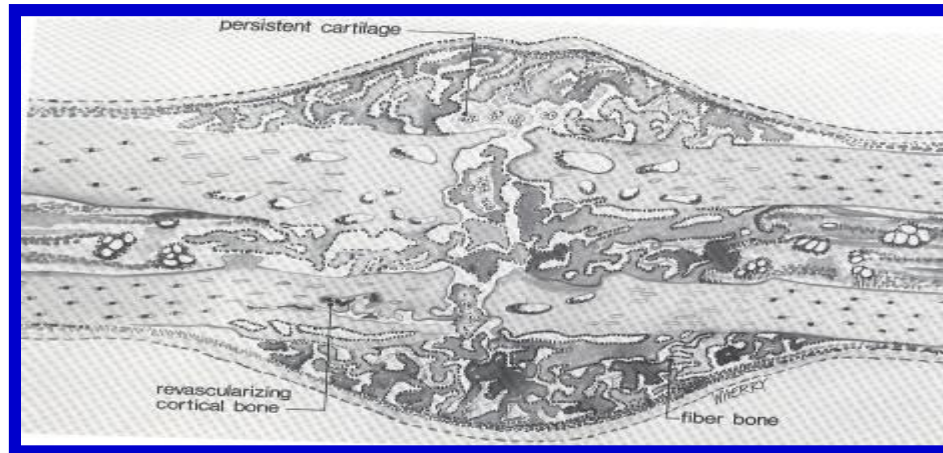
INFLAMMATION



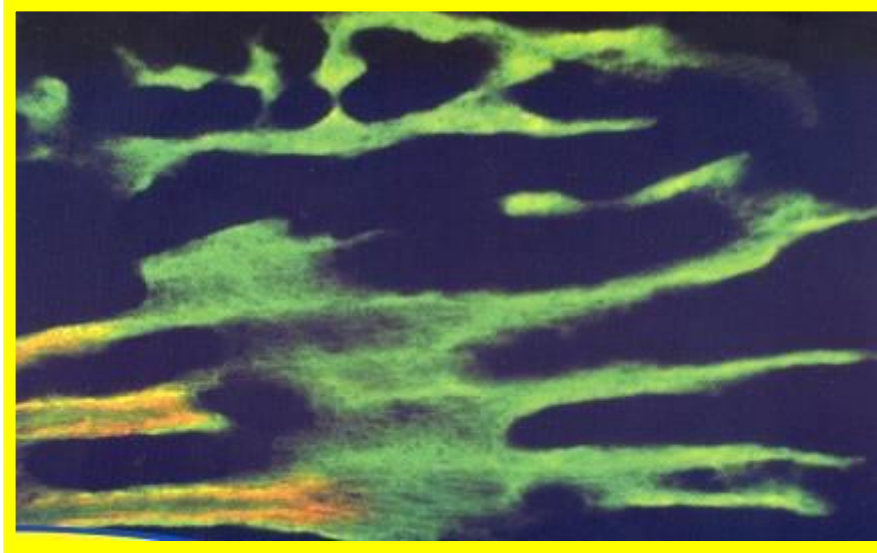
BONE HEALING



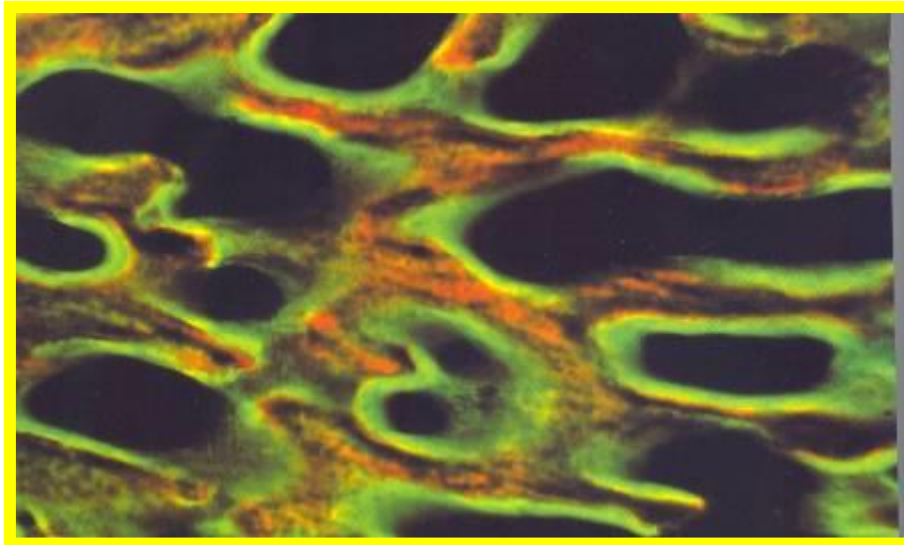
REPAIR



First phase of woven bone formation



Later phase in woven bone formation



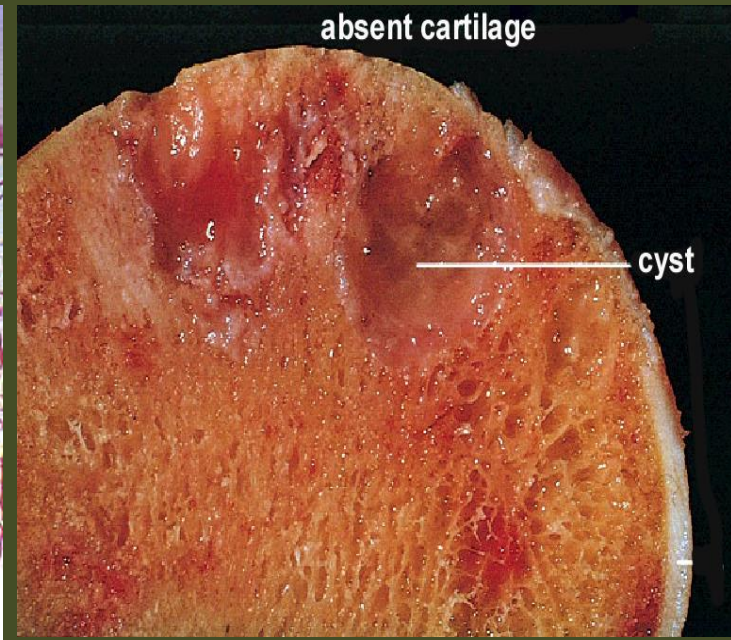
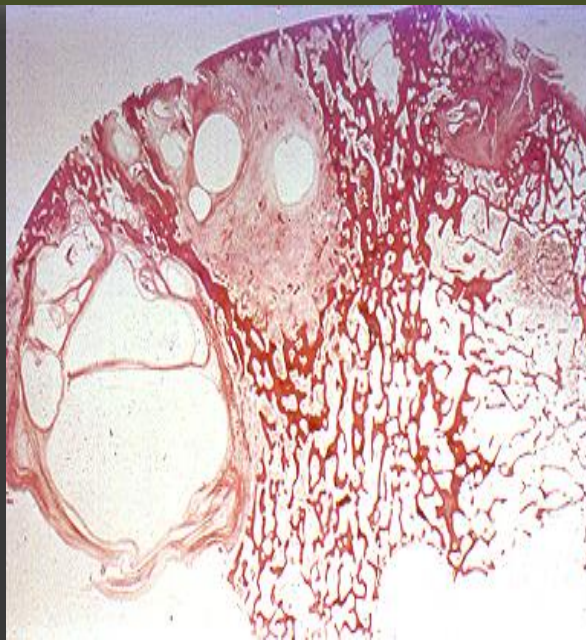
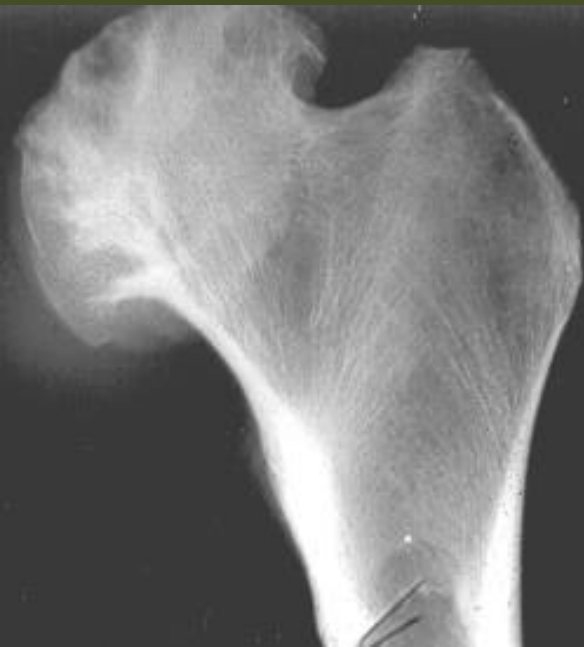

**SECOND
PRACTICAL
SESSION**



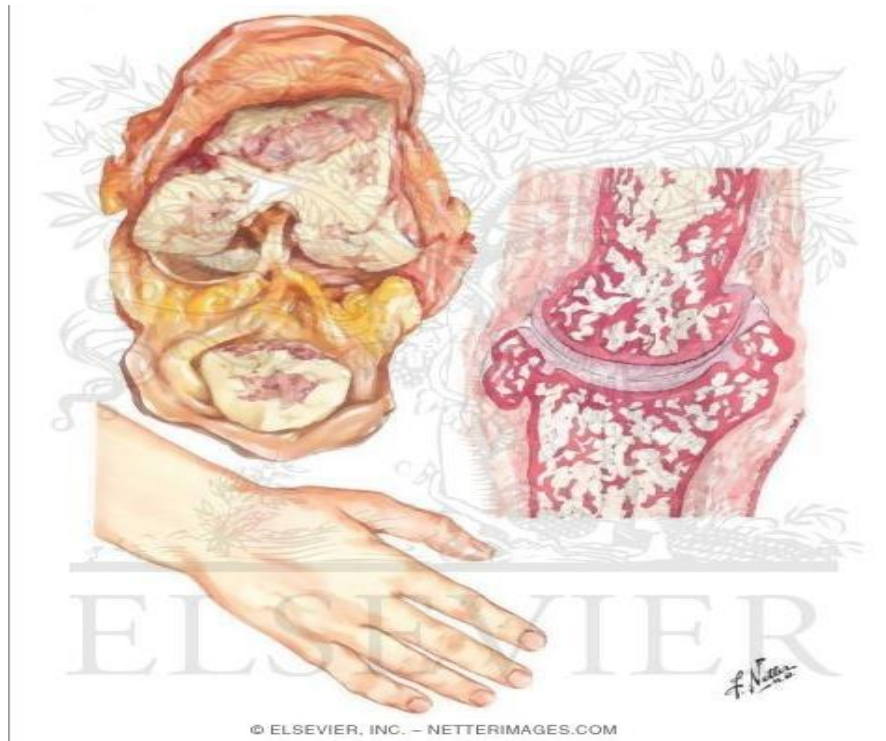
NON INFECTIOUS ARTHRITIS

Osteoarthritis

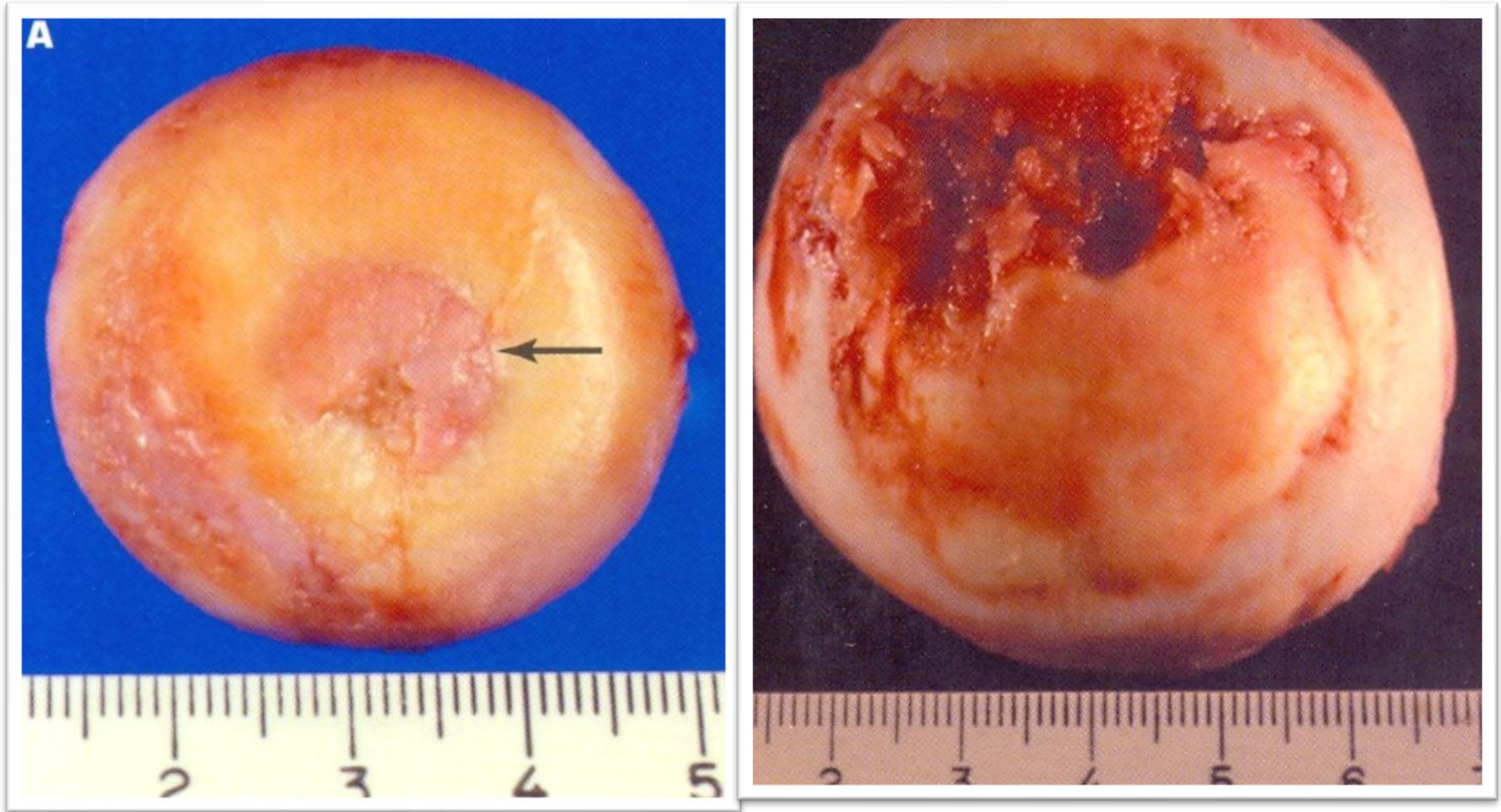


Case # 3

- **An obese 56-year-old woman presented with bilateral localized pain to her knees, hands and difficulty in walking .**

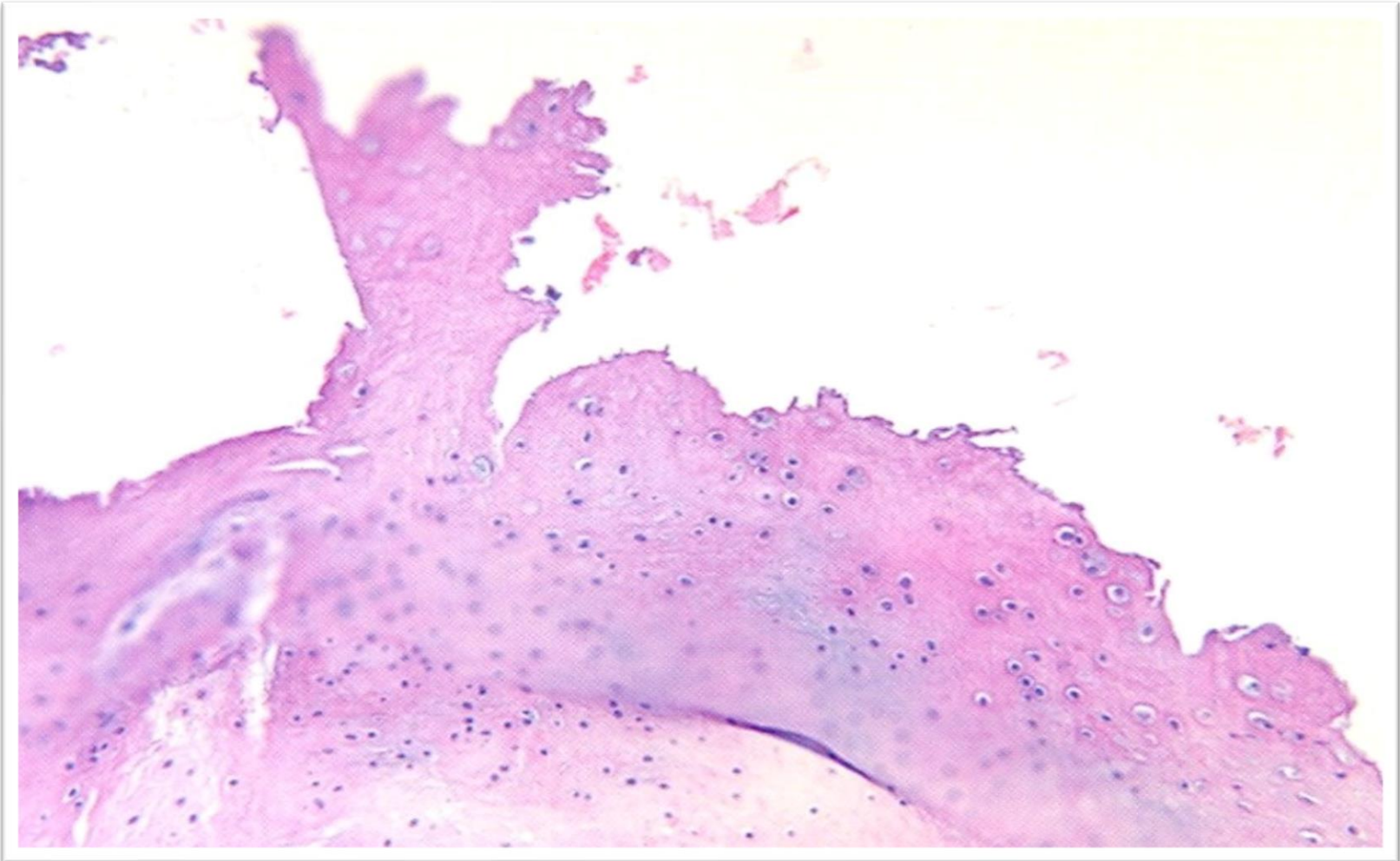


Osteoarthritis - Gross



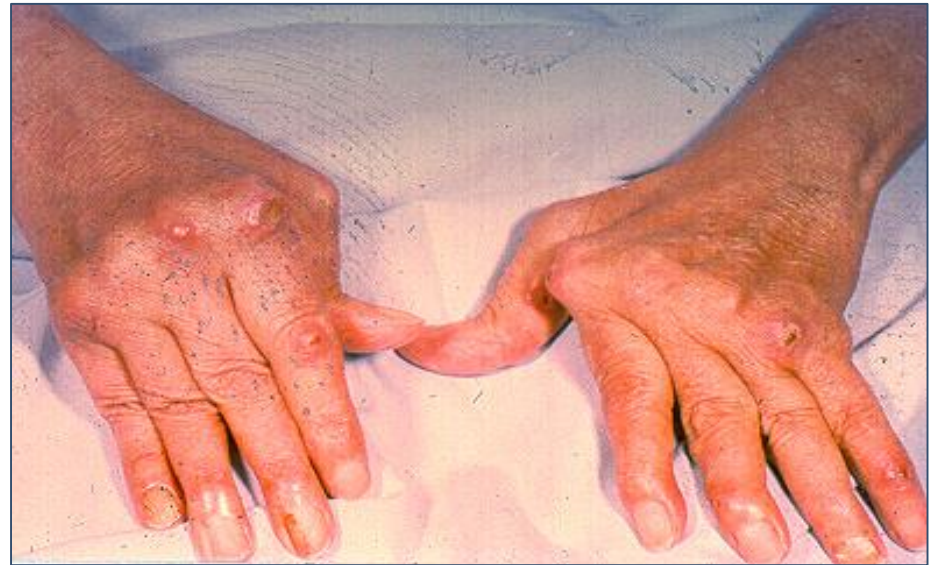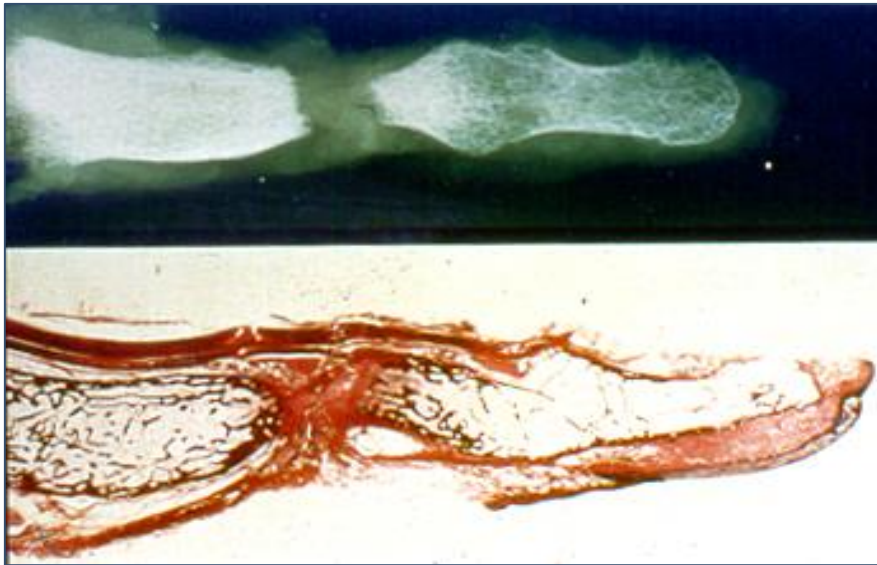Progressive erosion of articular cartilage, eburnated articular surface , subchondral cyst and residual articular cartilage (Osteoarthritis)

Osteoarthritis - LPF



Mushroom-shaped osteophytes (bony outgrowths) develop at the margins of the articular surface and are capped by fibrocartilage and hyaline cartilage that gradually ossify . Note the absence of inflammation . (Osteoarthritis)

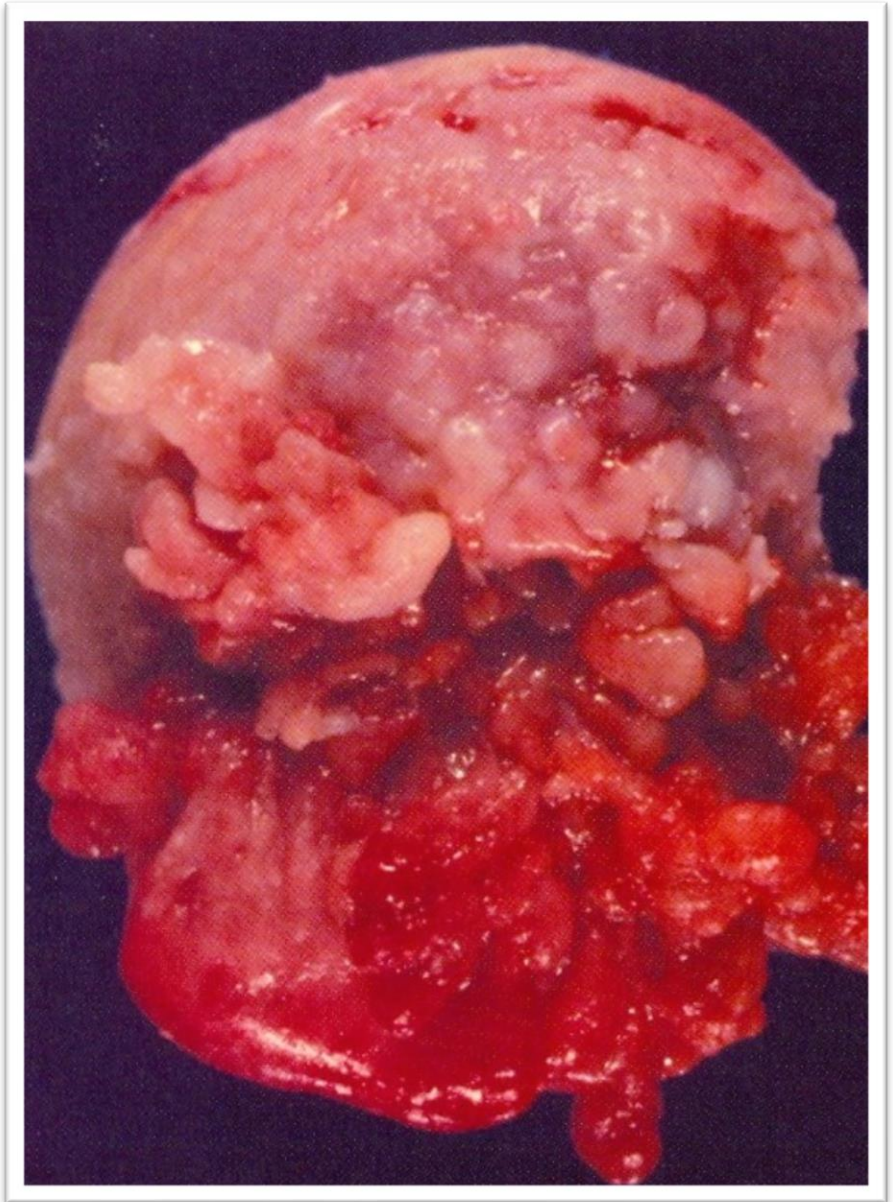
Rheumatoid Arthritis



Rheumatoid arthritis

affecting the head of the femur.

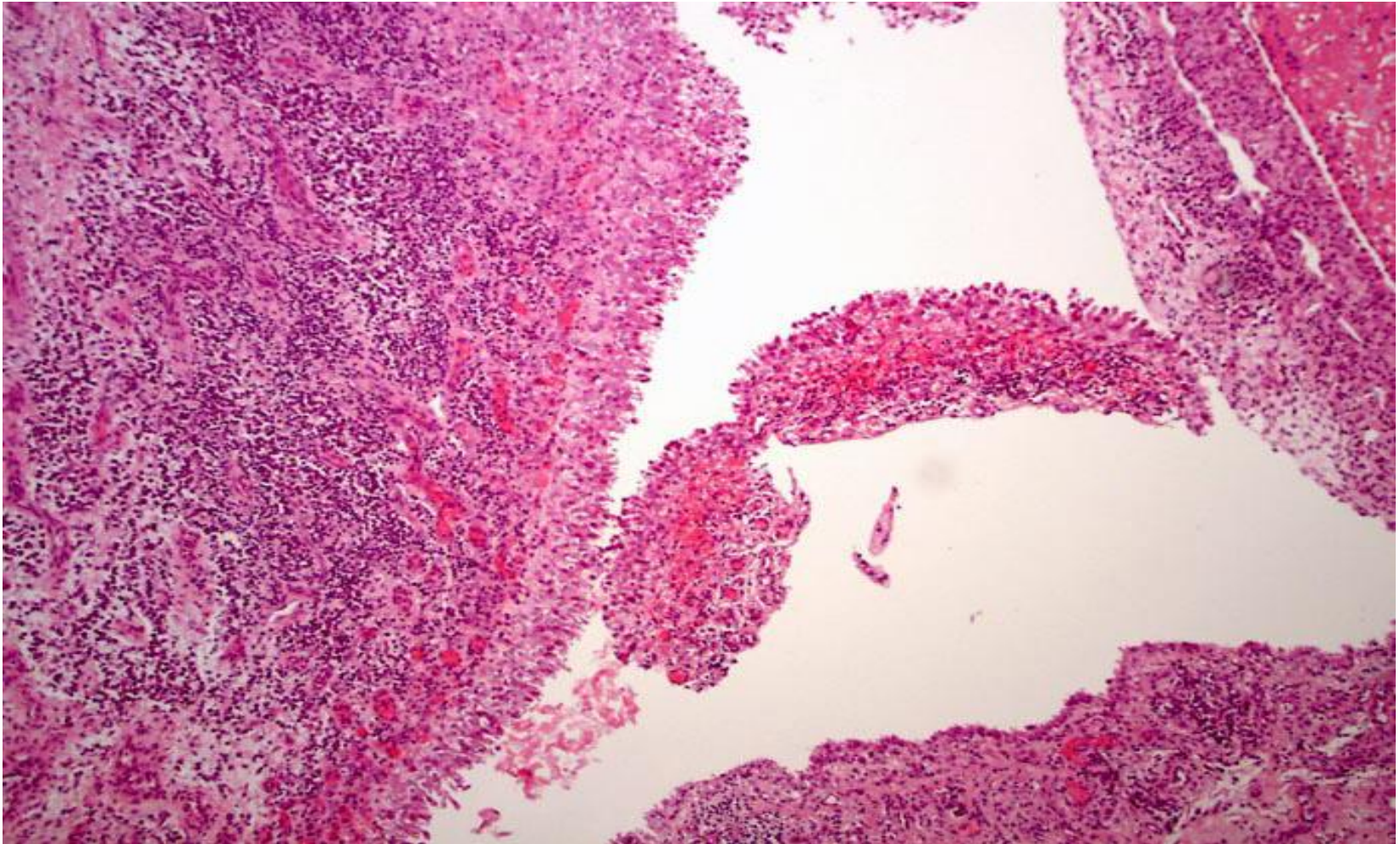
The synovium becomes edematous, thickened and hyperplastic and transforming its smooth contour to one covered by delicate and bulbous fronds .



Case # 4

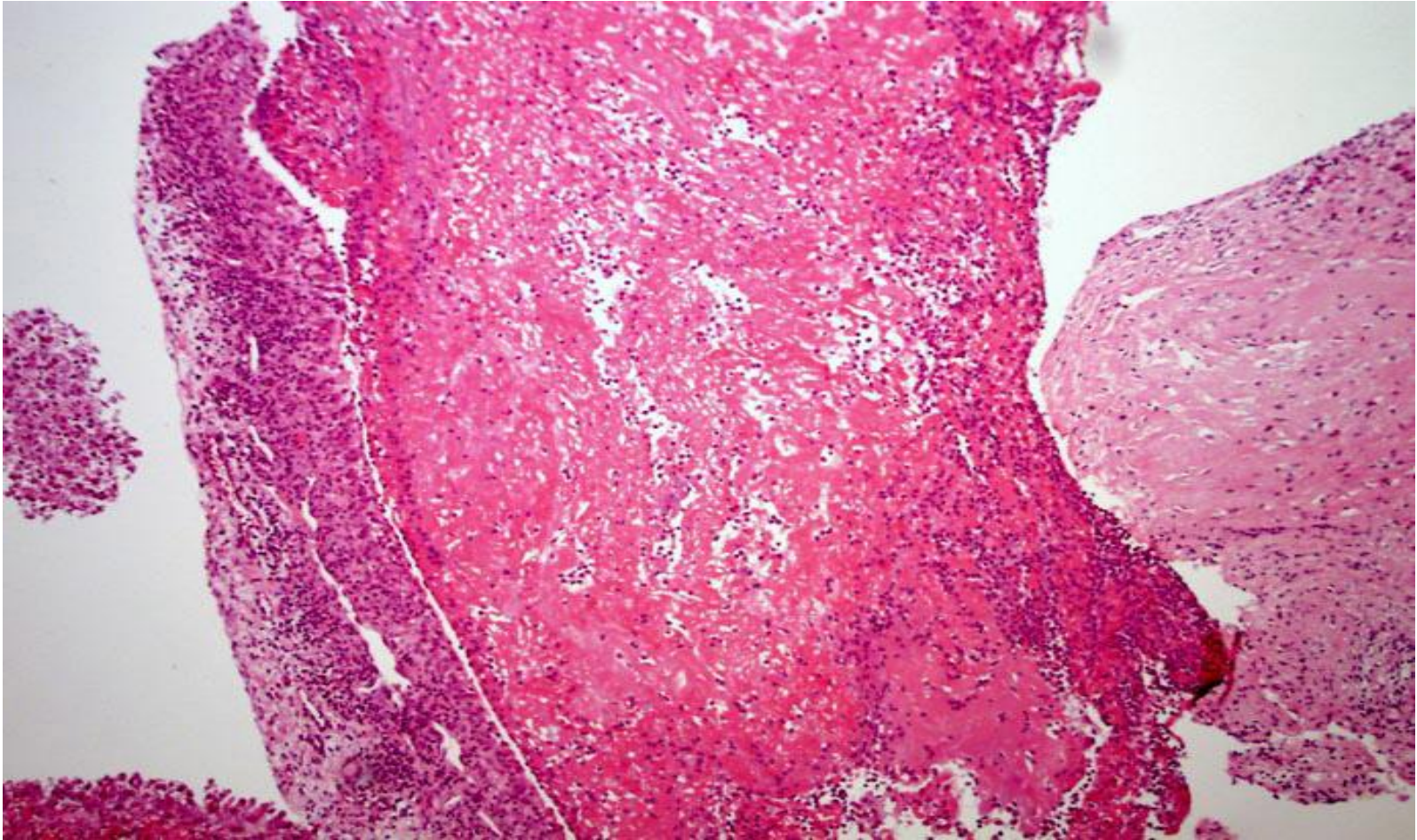
- **A 45 -year- old woman complains of low grade fever , malaise and stiffness in her joints each morning .**

Hyperplastic Synovium - LPF



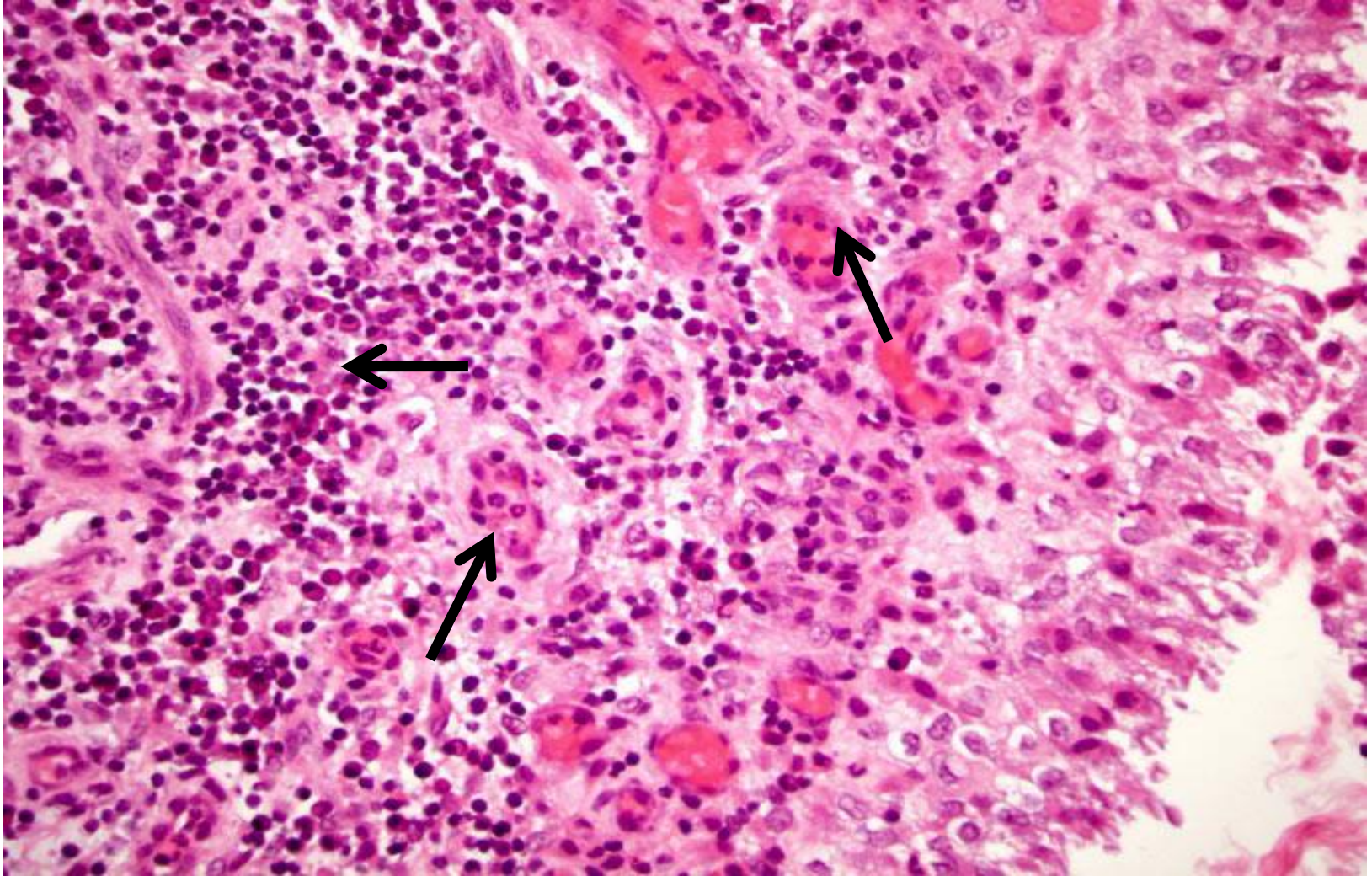
Hyperplastic synovial lining with villous like projections , underlying dense lymphocytic infiltration and vascular congestion

Hyperplastic Synovium - LPF



Section shows a pannus consisting of fibrinous inflammatory exudates with underlying markedly inflamed synovium . Later on, the pannus may fill the joint space and undergo fibrosis , calcification and causes permanent ankylosis adhesions

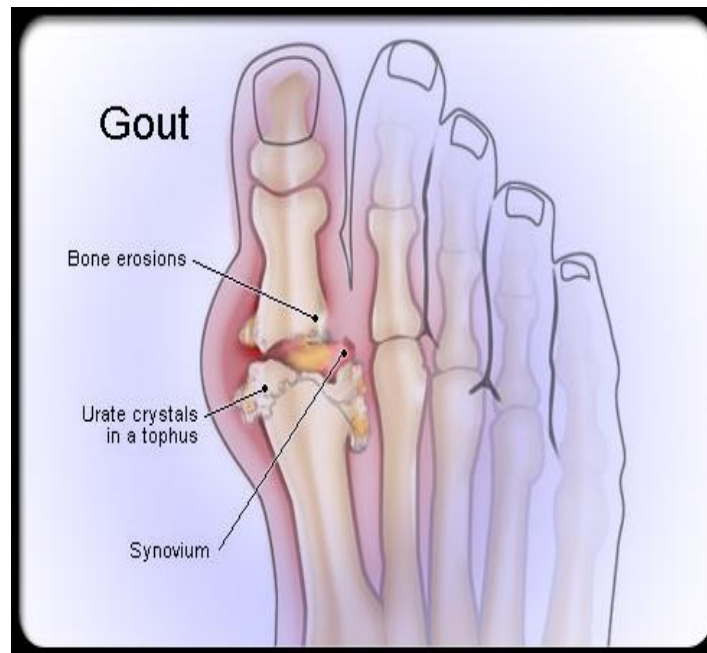
Hyperplastic Synovium - HPF



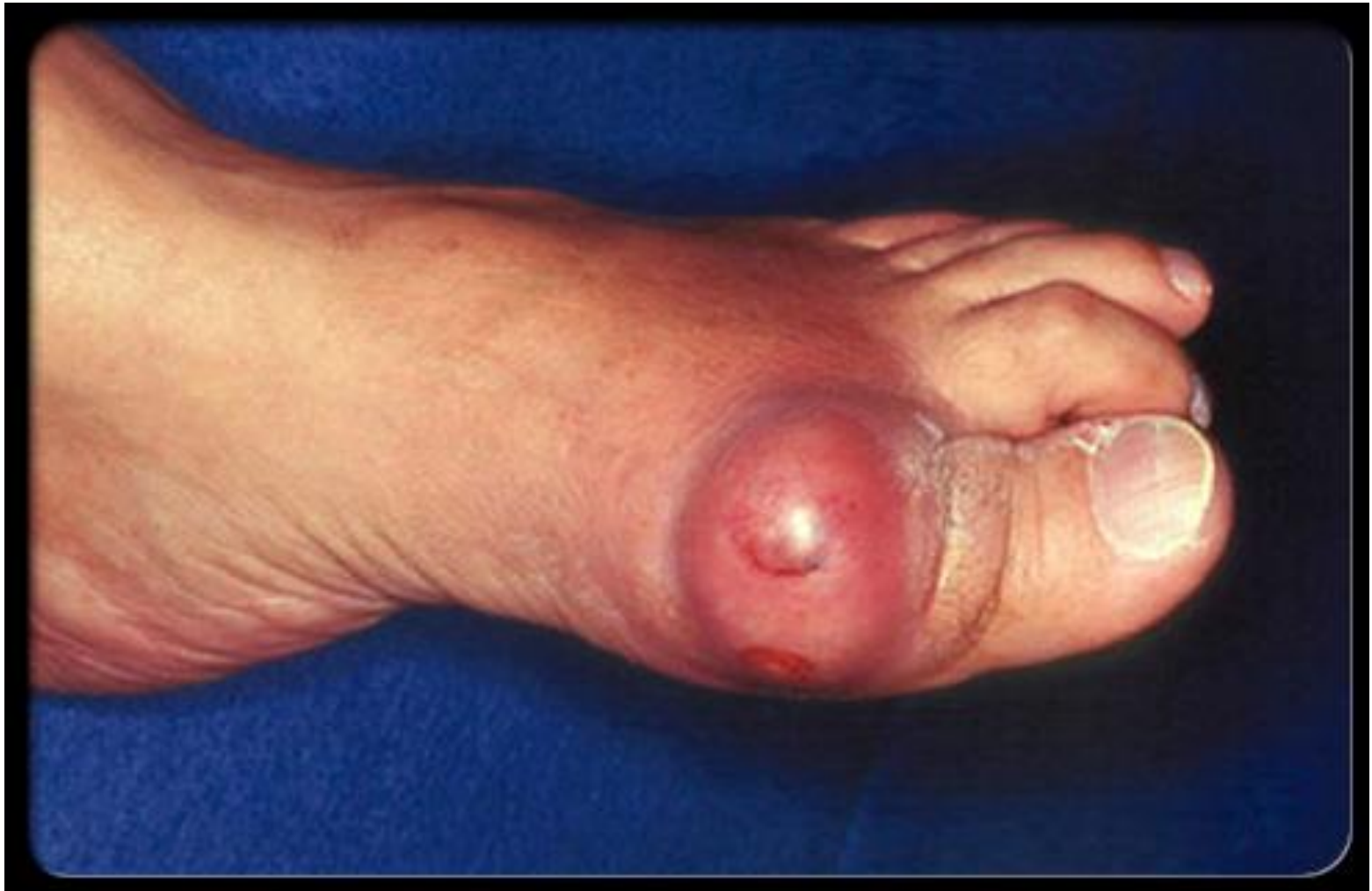Hyperplastic synovium with underlying plasma cells and lymphocytes including many congested blood vessels in **Rheumatoid arthritis**

GOUT

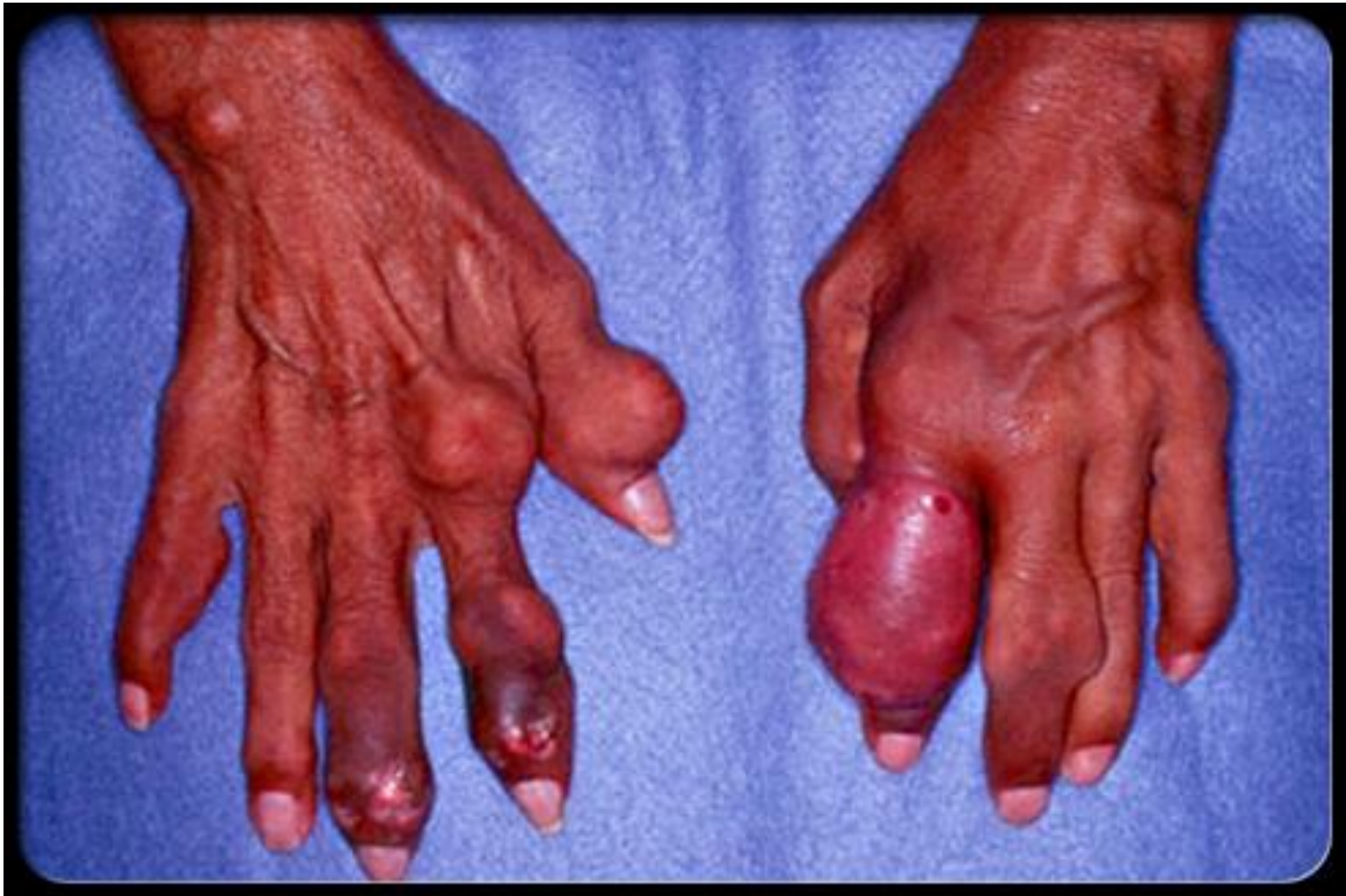Gout is a syndrome caused by the inflammatory response to tissue deposition of monosodium urate crystals (MSU).



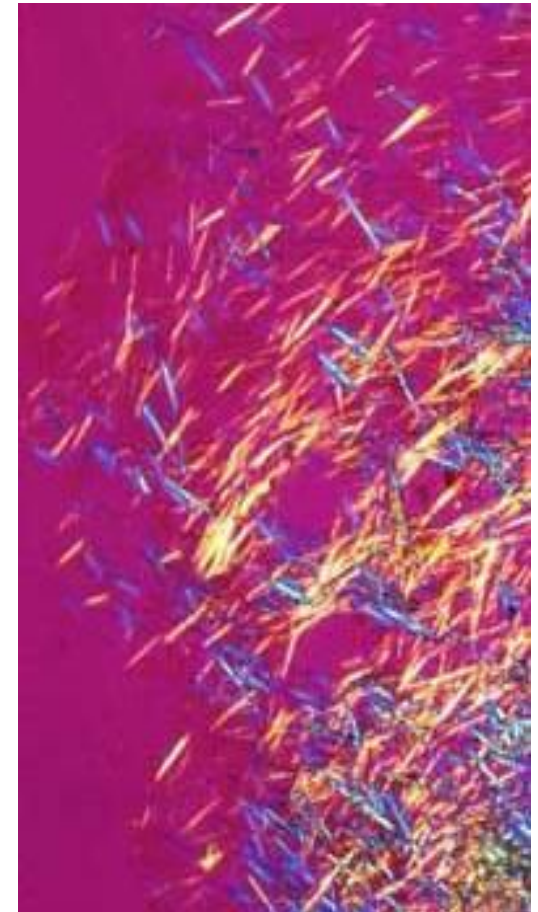
Acute gouty arthritis on the big toe of an elderly man.



Severe gout in the fingers resulting in large, hard deposits of crystals of uric acid. These deposits are called Tophi

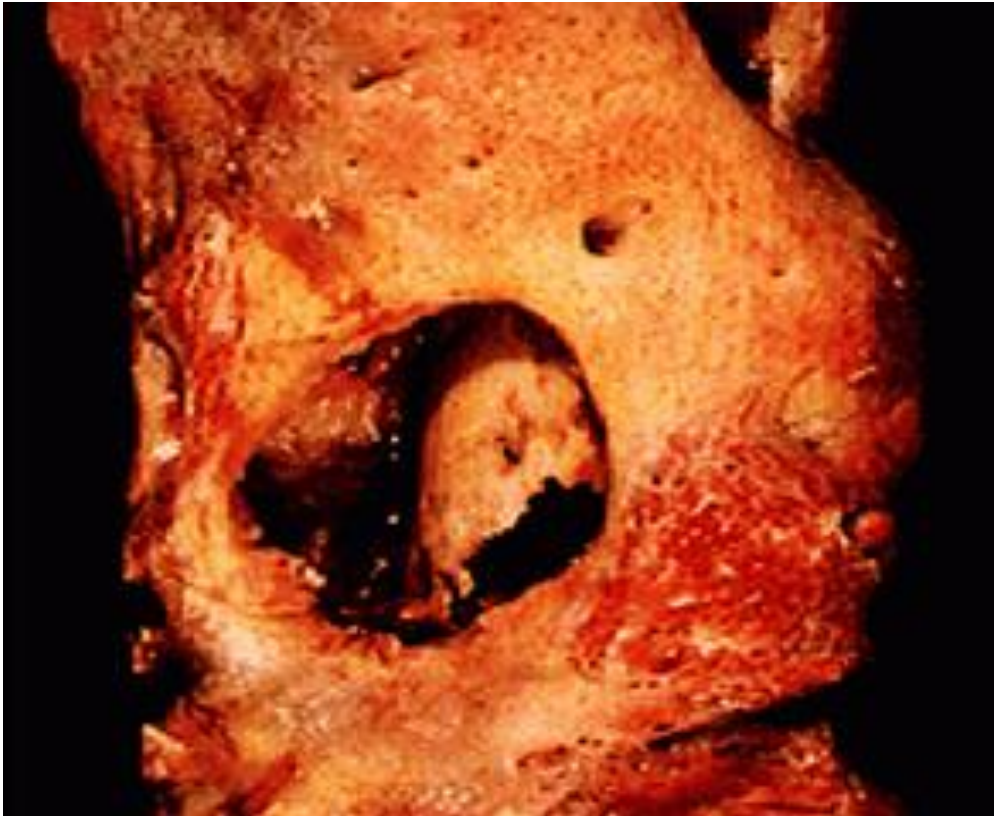

Needle-shaped urate crystals diagnostic of gout from an acutely inflamed joint (left) as seen under polarized microscopy and unpolarized microscopy (right)



Osteomyelitis

Osteomyelitis



Resected femur in a patient with draining osteomyelitis. The drainage tract in the subosteal shell of viable new bone (involucrum) reveals the inner native necrotic cortex (sequestrum)

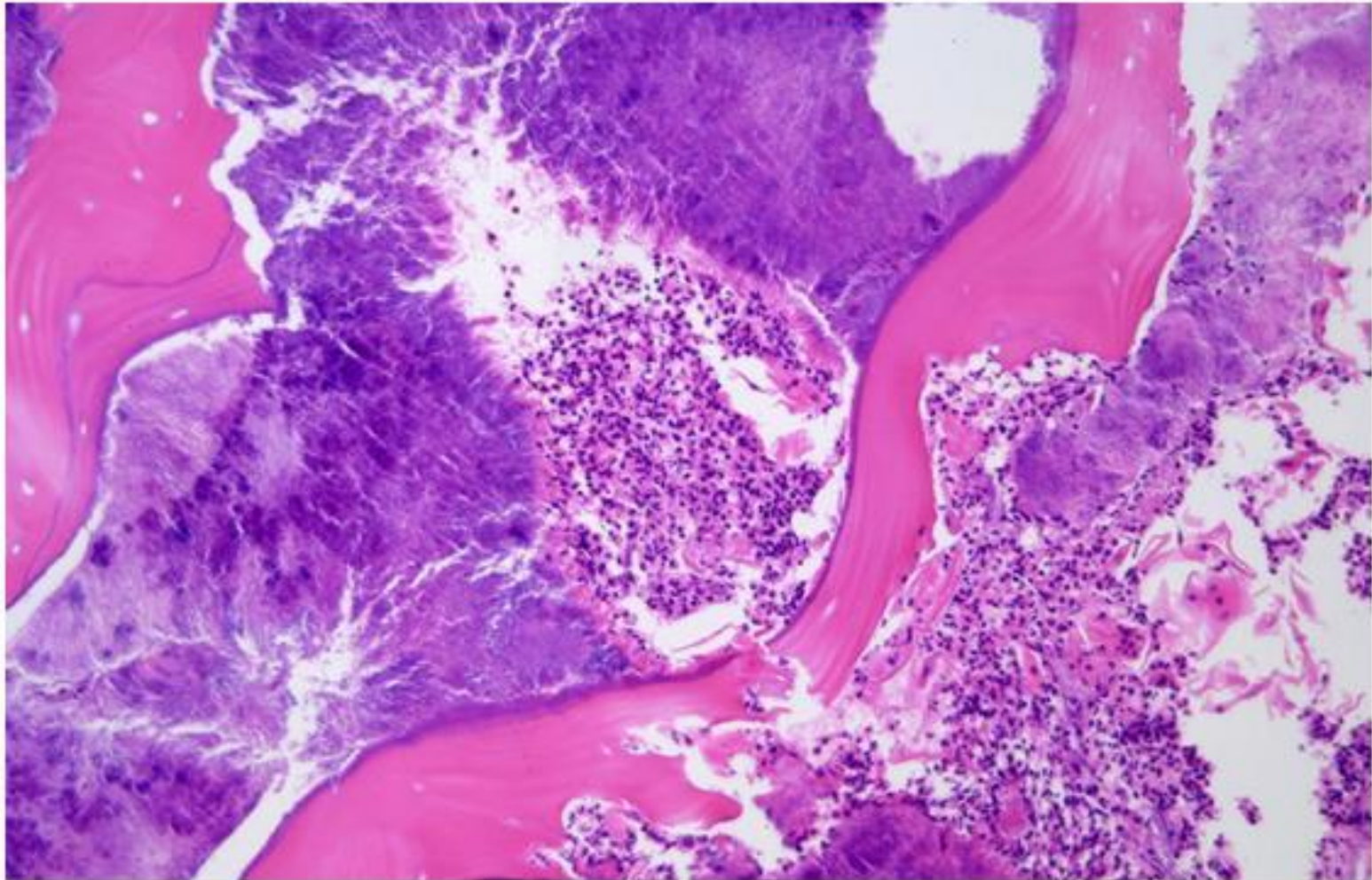
- Direct infection of bone.
- Bacterial most often
 - Staphylococcus
 - Salmonella
 - Sickle Cell Disease
 - Tuberculosis
 - Spine first
- Syphilis
 - Periosteum

Case # 5

- **A 22- year- old male presented with localized pain above his right knee joint with recurrent fever. Later, he had a discharging sinuses from the skin overlying the right knee.**

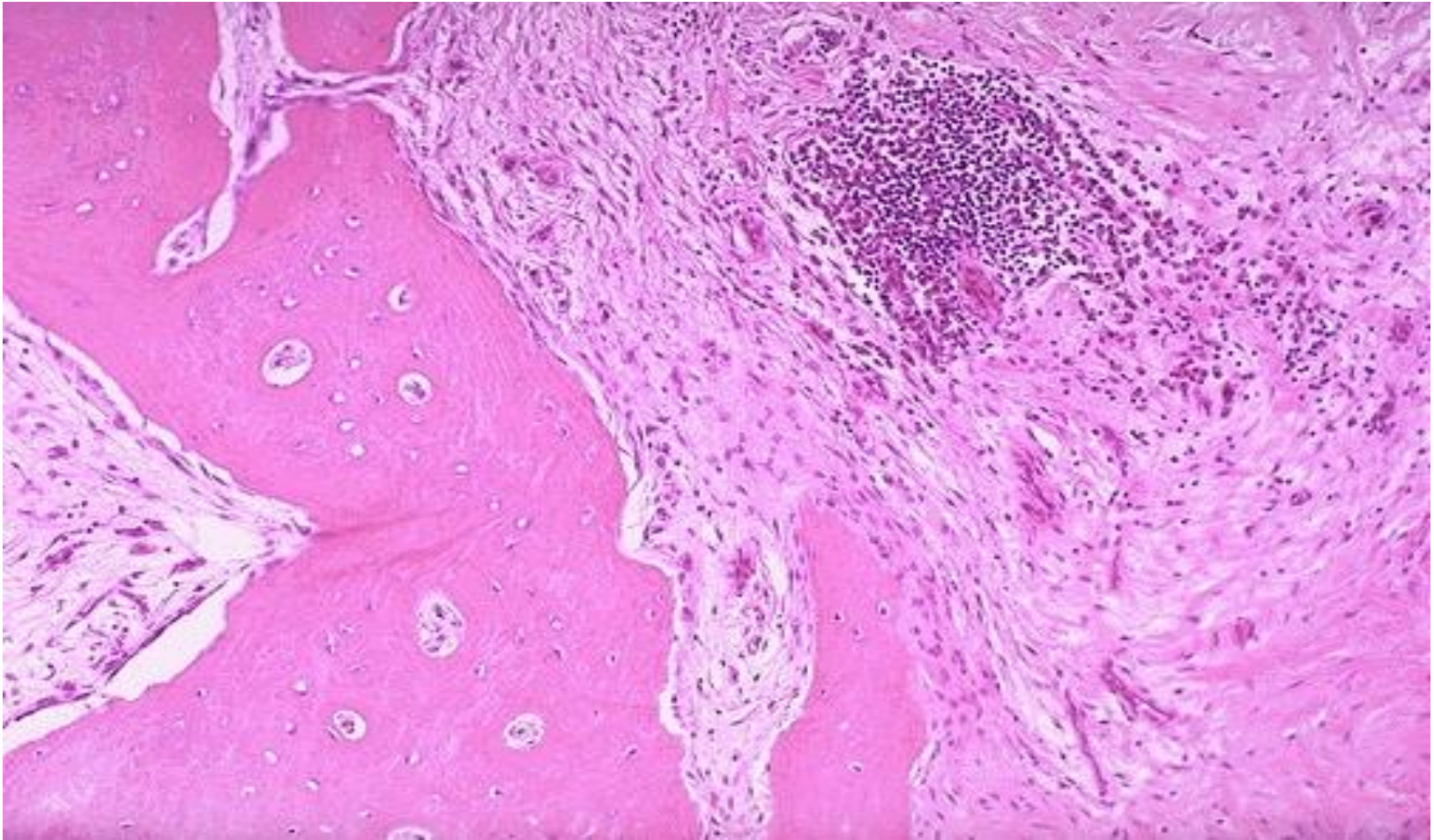
What is the most likely diagnosis ?

Acute Osteomyelitis - LPF



Acute Osteomyelitis. Bony sequestrae are surrounded by colonies of bacteria as well as purulent infiltrate.

Chronic Osteomyelitis - LPF



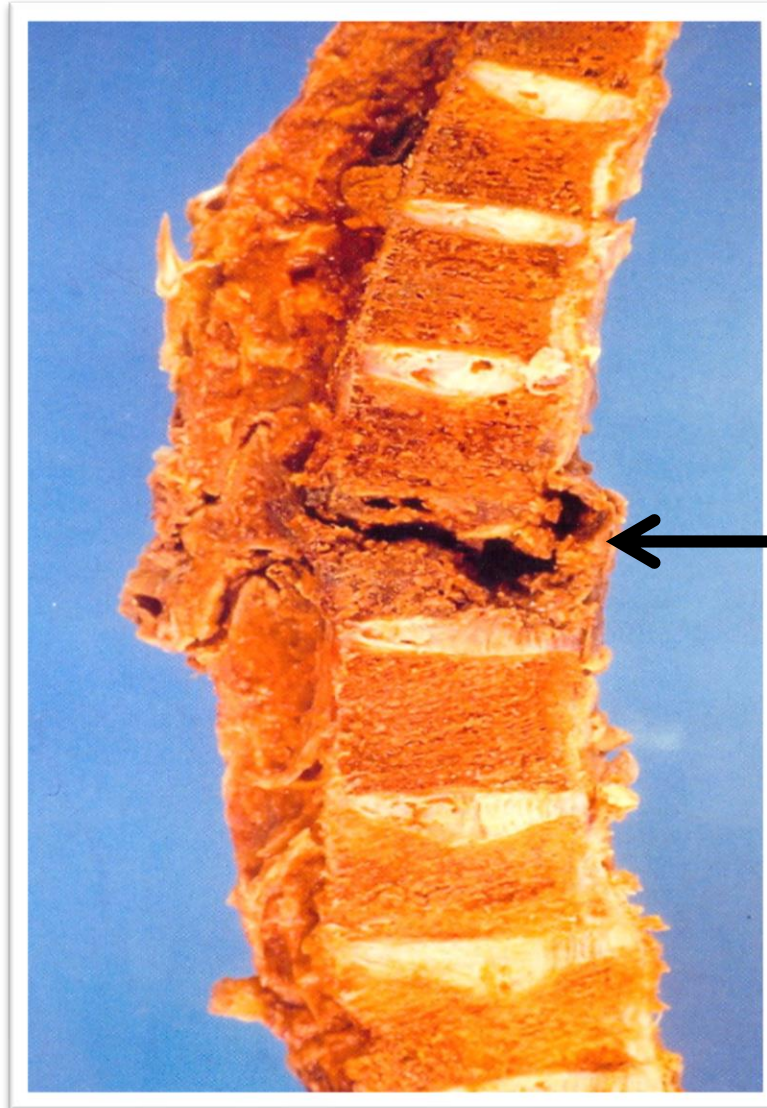
Chronic Osteomyelitis. Note the fibrosis of the marrow space accompanied by chronic inflammatory cells. There can be bone destruction with remodeling.

Spinal TB – Pott's Disease (Tuberculous Osteomyelitis)

Case # 6

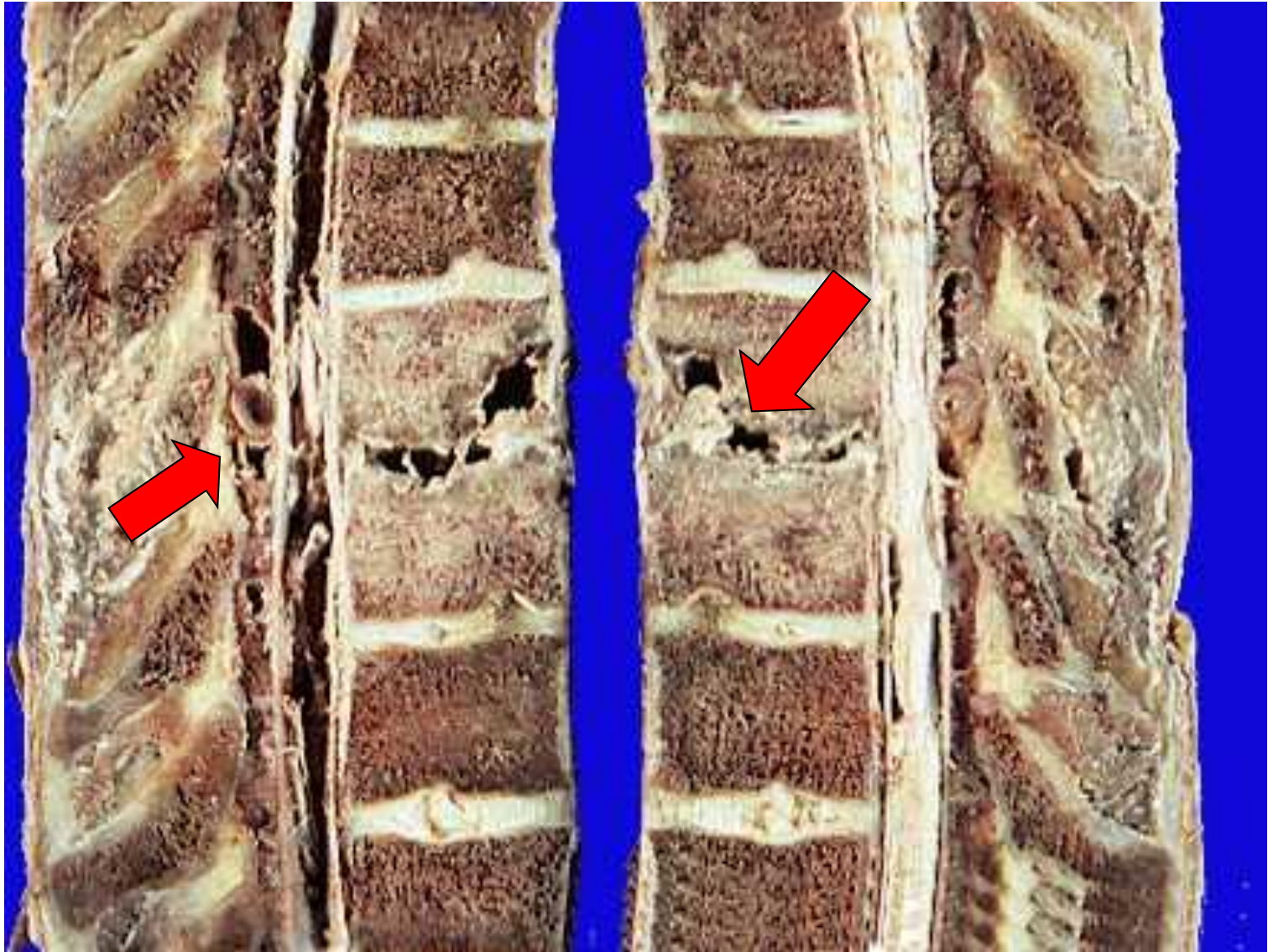
- **A 30 -year-old debilitated man presented to the orthopedic clinic with back pain, low grade fever, marked elevation of sedimentation rate and recent kyphosis and scoliosis .**
- **The patient has a history of coughing up blood, fever, chills, night sweats, weight loss, pallor, and often a tendency to fatigue very easily.**

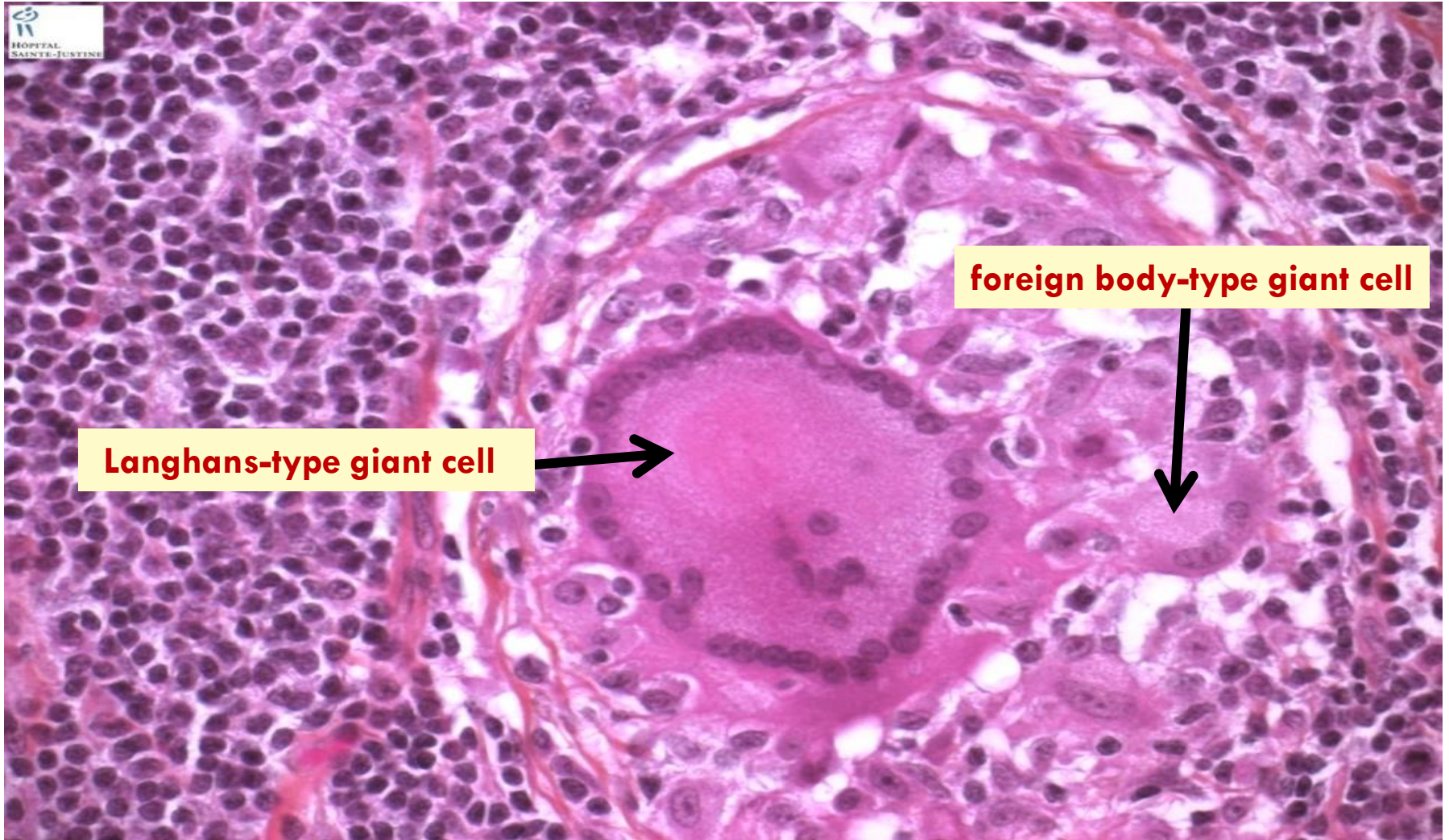Gross pathology of T.B Osteomyelitis of the vertebral Column (Pott's Disease)



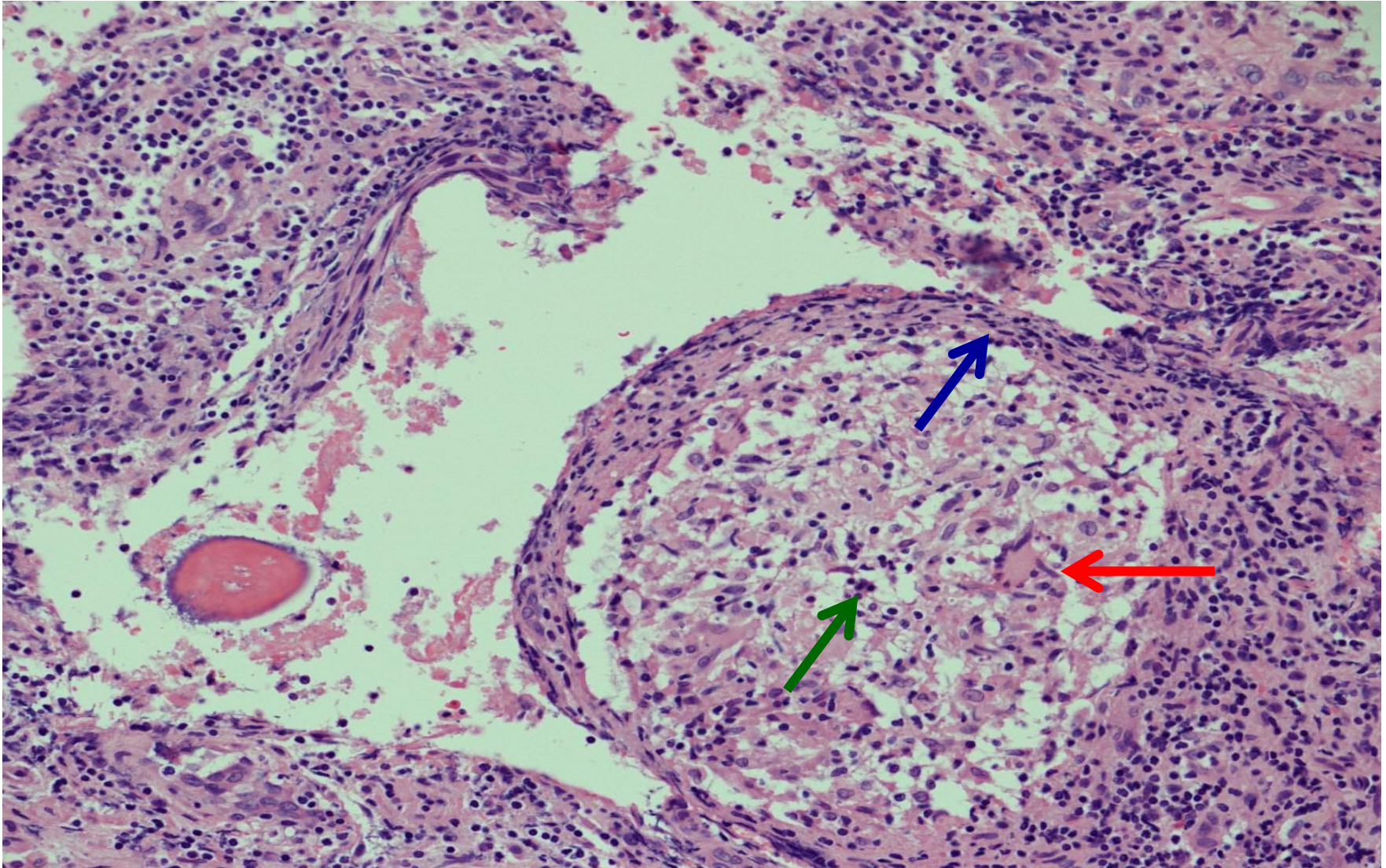
**Granulomatous
necrosis of
vertebral column**

Gross pathology of T.B. Osteomyelitis of the vertebral spines (Pott's Disease)

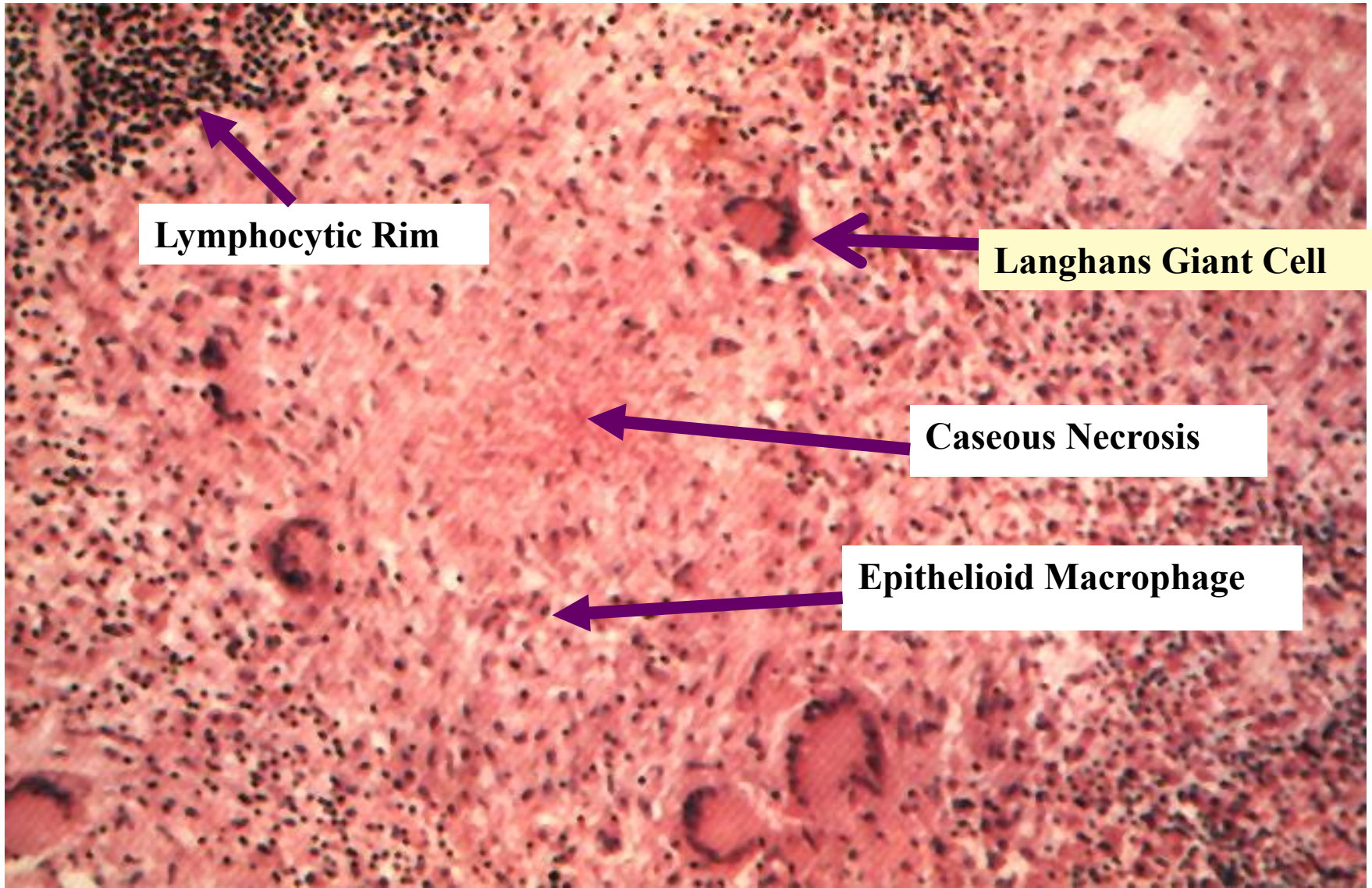




- **Bone section shows *Epithelioid cells fuse to form giant cells* containing 20 or more nuclei. The nuclei arranged either peripherally (*Langhans-type giant cell*) or haphazardly (*foreign body-type giant cell*). These giant cells can be found either at the periphery or the center of the granuloma.**



Section of bone shows granuloma formation with **epithelioid like cells** , **langhans-type giant cells** and rim of **lymphocytes**

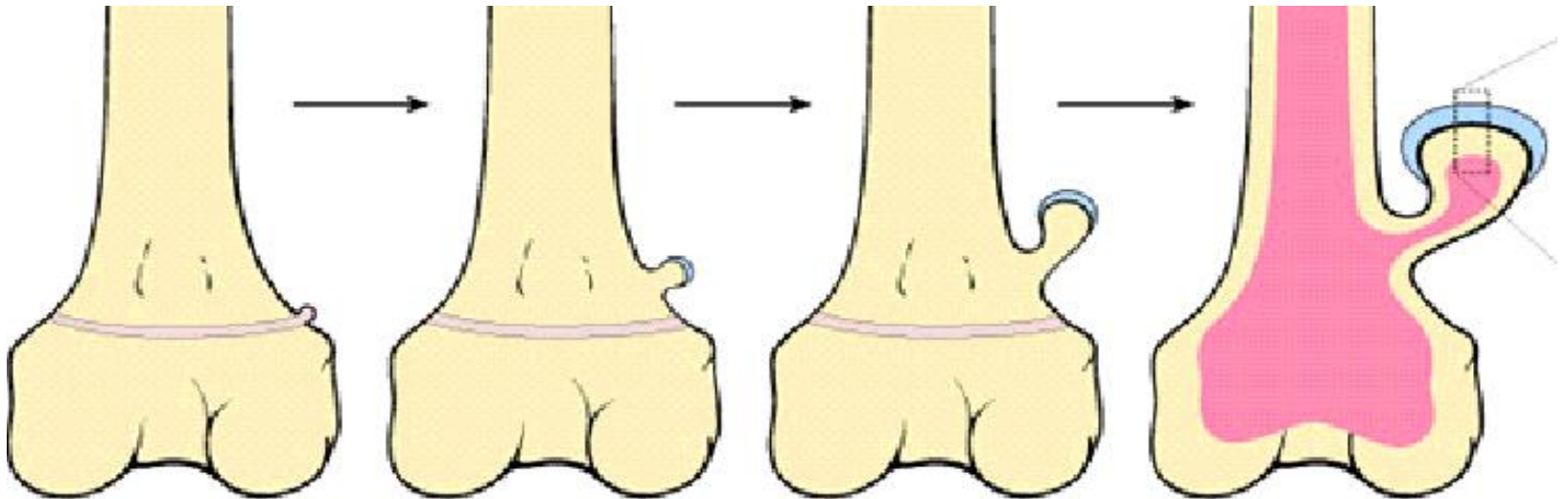


Section of bone shows granuloma formation with epithelioid like cells , langhans-type giant cells and rim of lymphocytes

BONE TUMORS

Osteochondroma **(osteochondroma exostosis)**

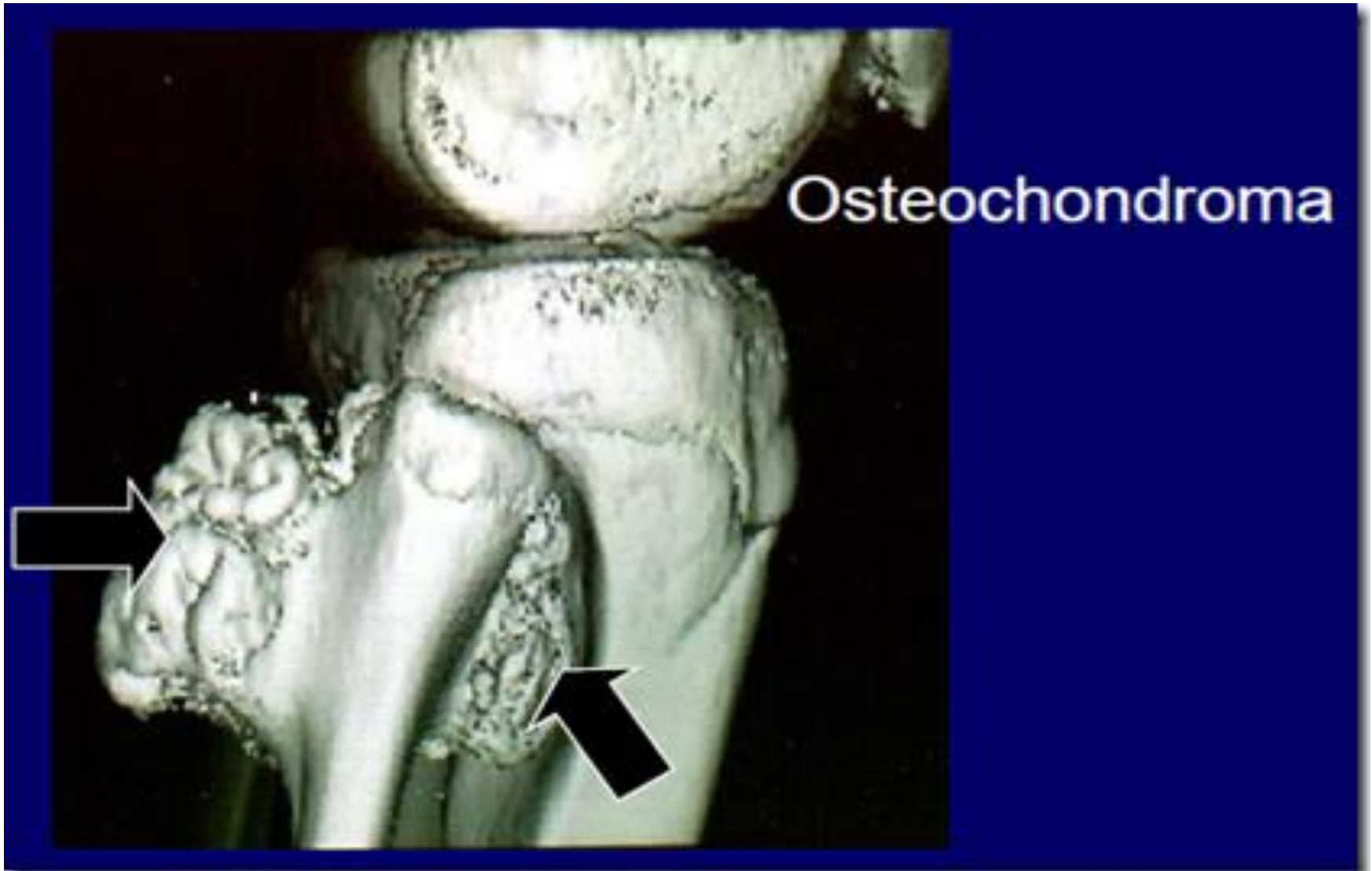
Osteochondroma (osteochondroma exostosis)



- **The solitary osteochondroma is the most common benign bone tumors**
- **Seen in patients aged from 10-30 years**
- **Arise during skeletal growth**
- **Equally in males and females**
- **Etiology is unknown**

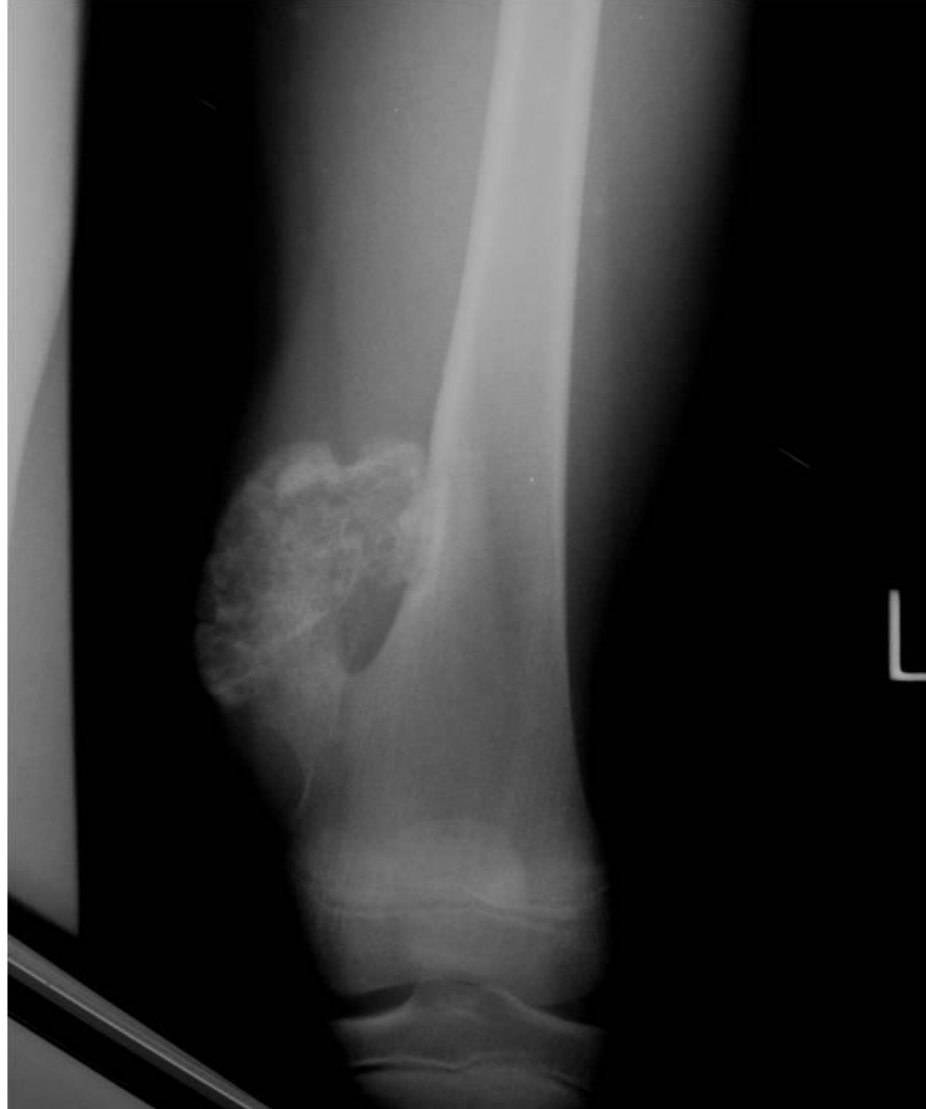Case # 7

- **A 16 -year-old male was found to have a small swelling protruding from upper part of his leg with local pain .**

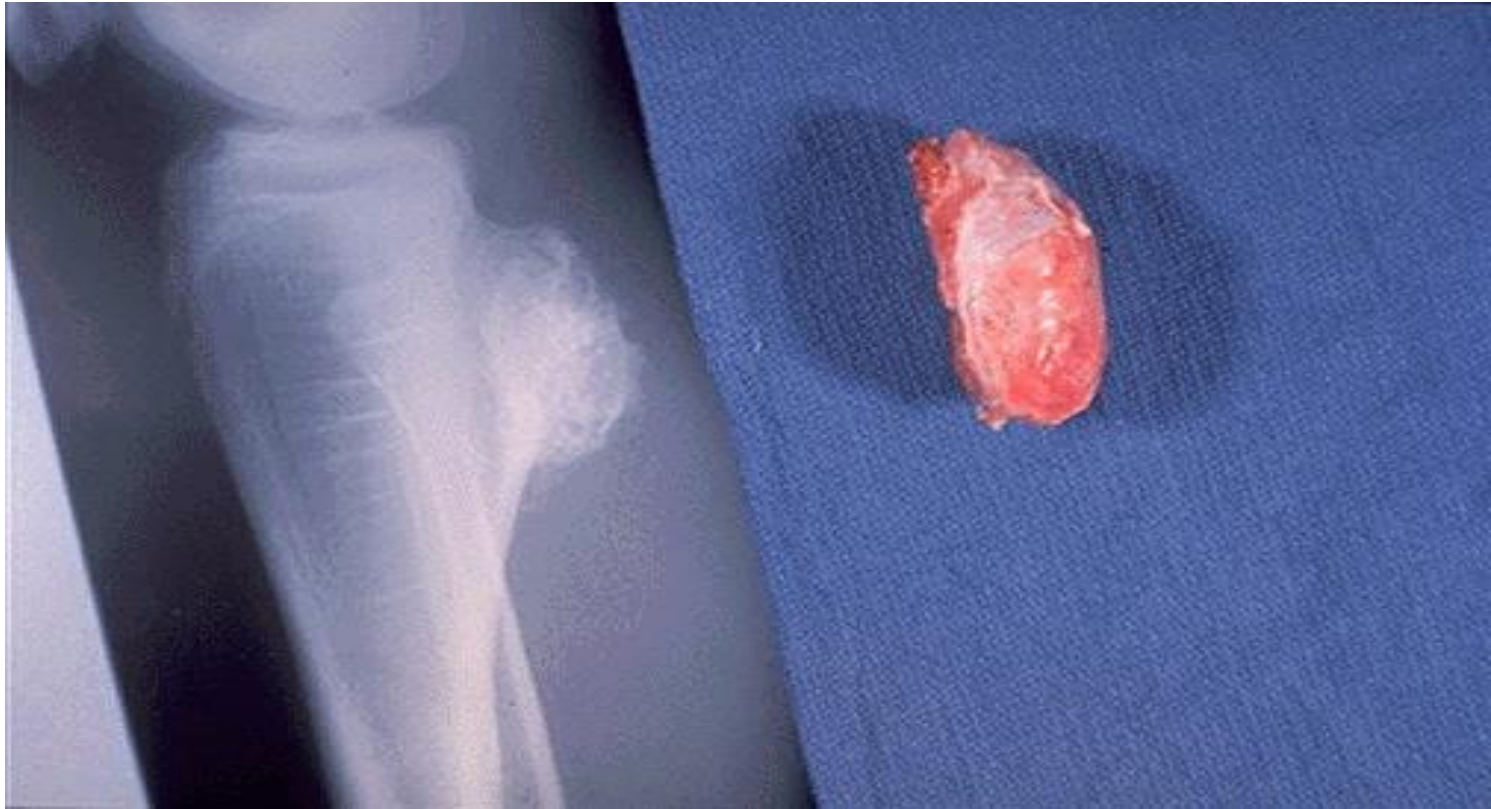


MRI picture showing two osteochondromatous exostosis which are arising from the upper third of fibula .

Osteochondroma: X-ray

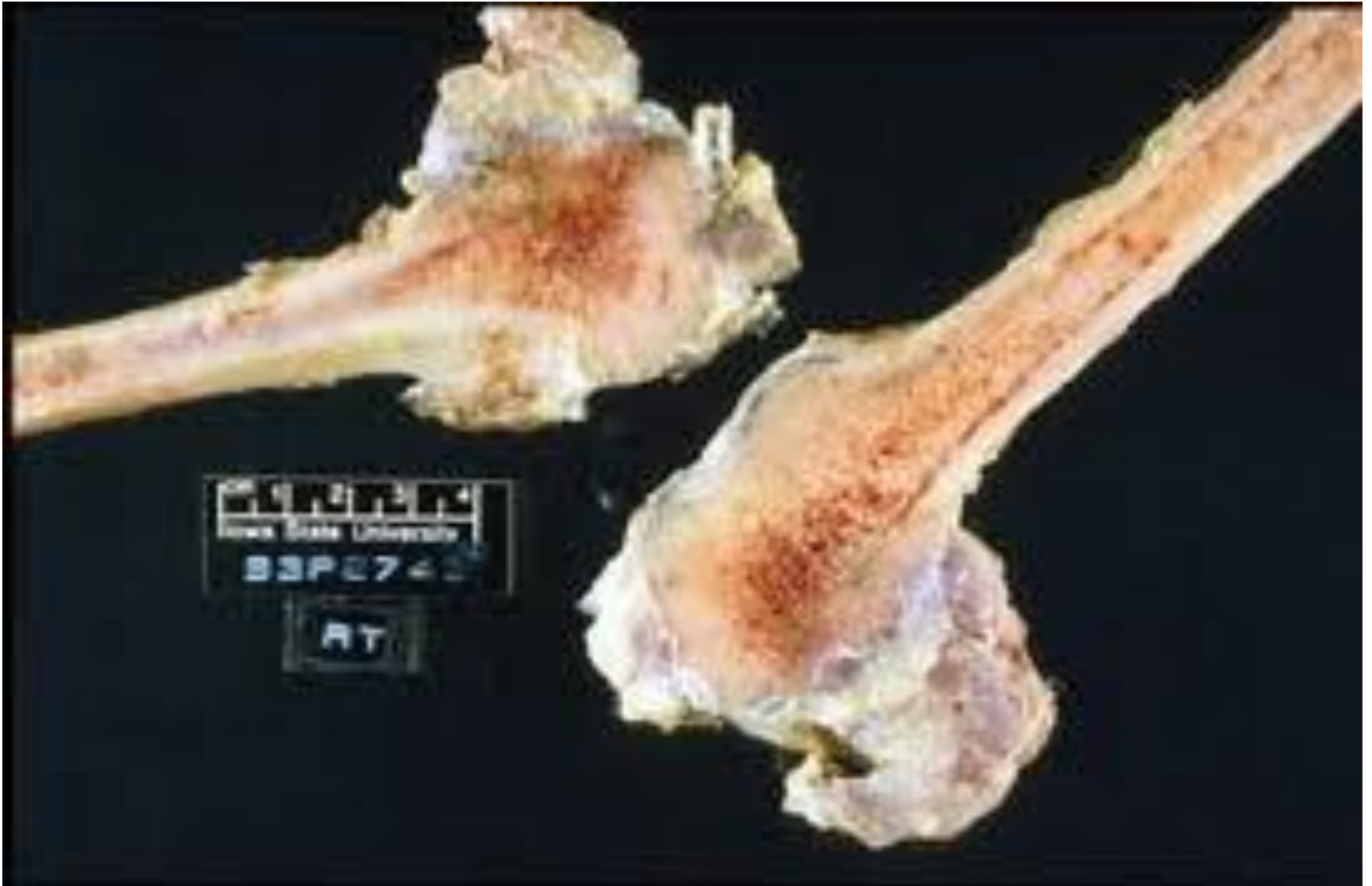

Osteochondroma: Gross & X-ray

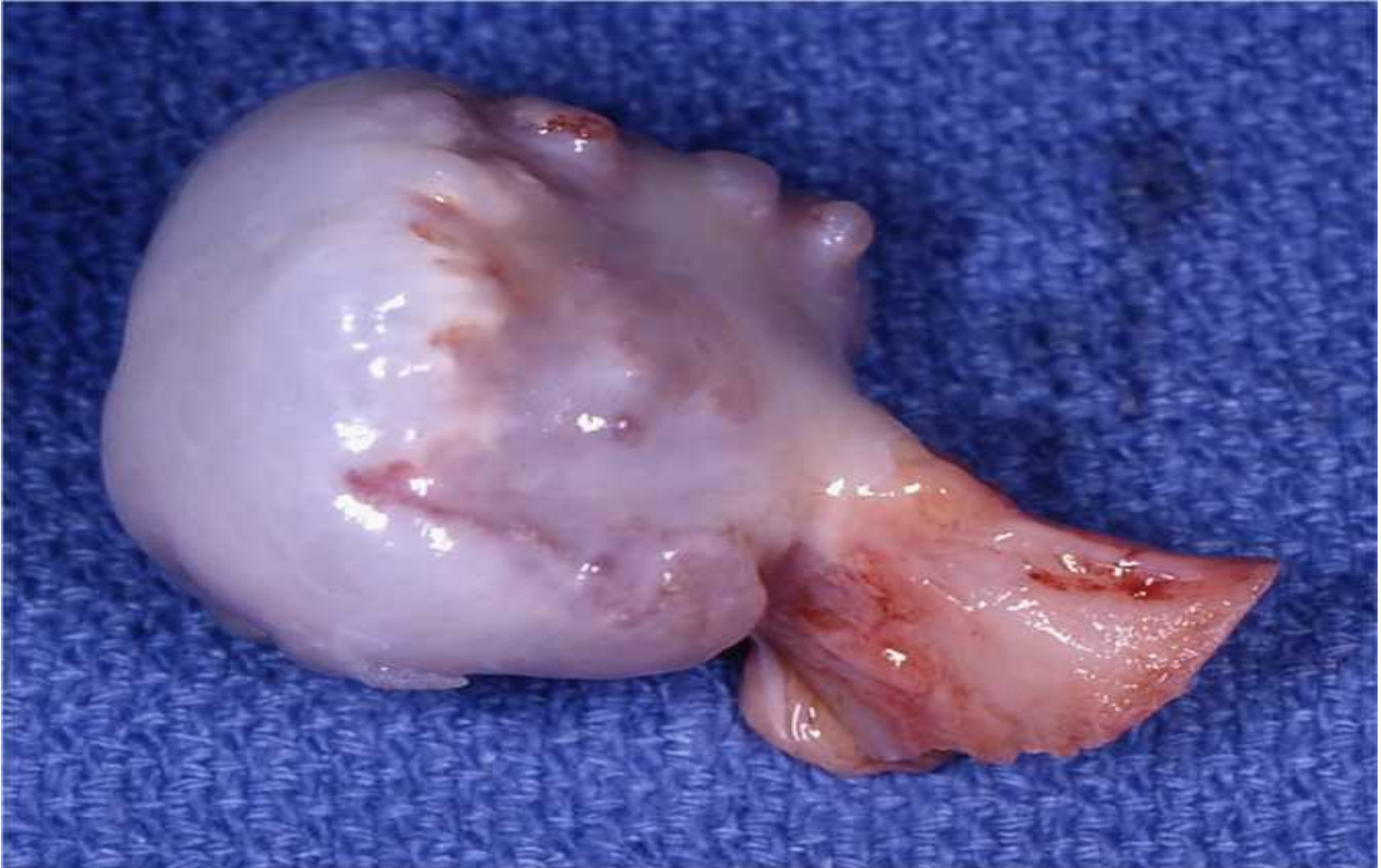

This is an osteochondroma of bone. This benign lesion appears as a bony projection (exostosis). Most are solitary, incidental lesions that may be excised if they cause local pain. There is a rare condition of multiple osteochondromatosis marked by bone deformity and by a greater propensity for development of chondrosarcoma.

Multiple Cartilaginous Exostoses - Gross

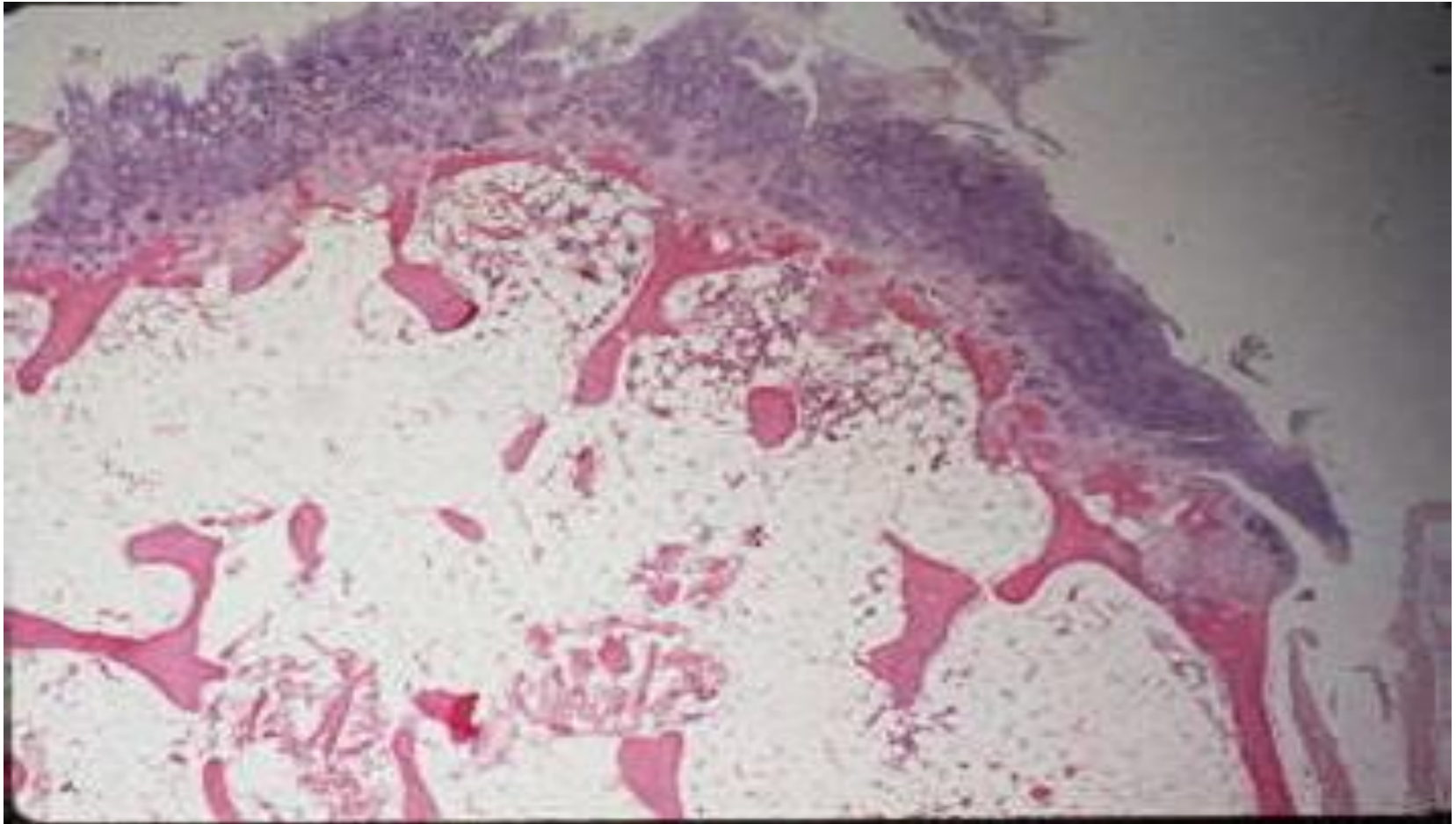


Osteochondroma - Gross



Solitary osteochondroma. Gross osteochondroma specimen at the time of resection. Bone stalk and overlying membrane on cartilage cap.

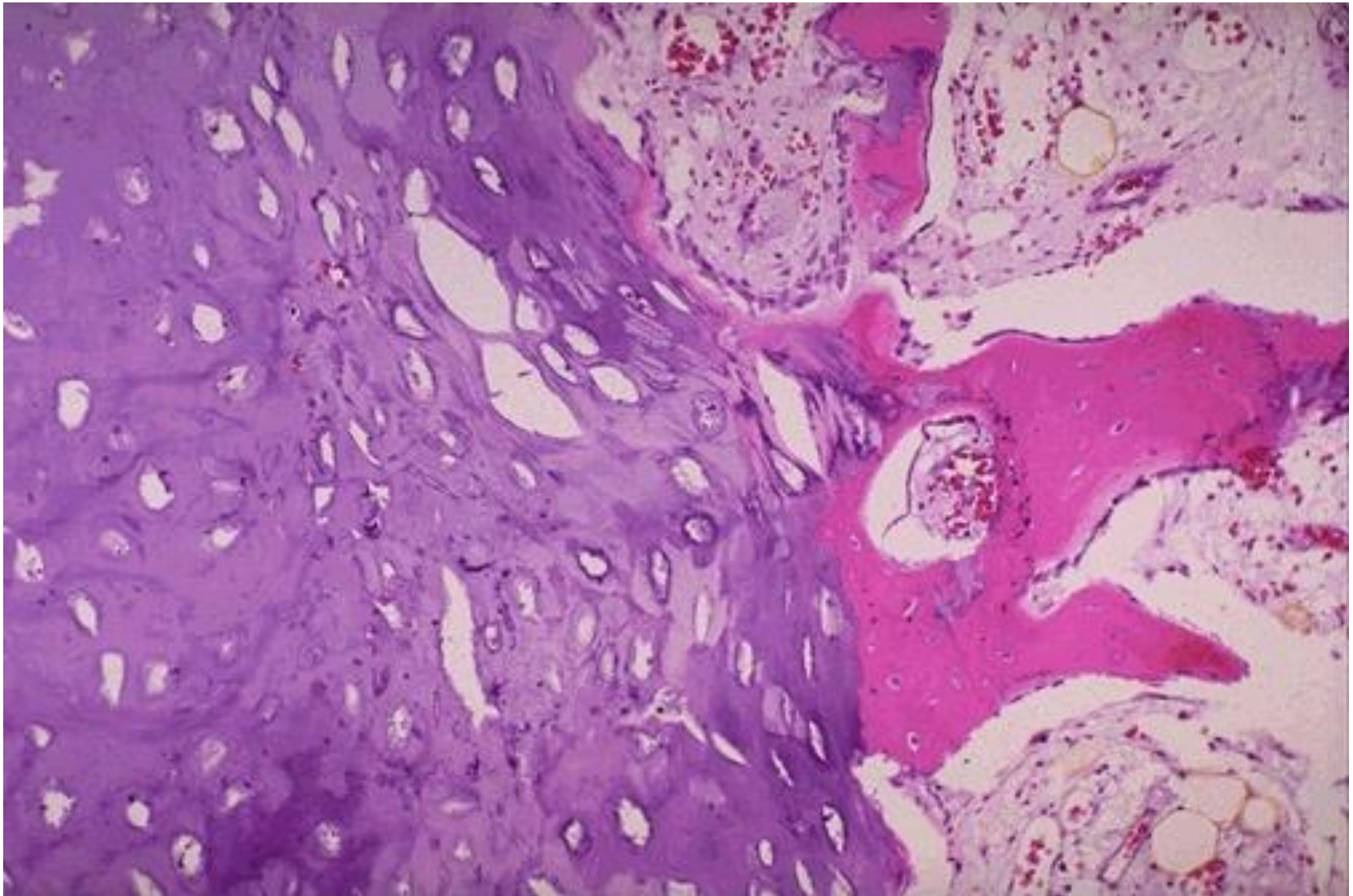
Osteochondroma - LPF



The microscopic appearance of an osteochondroma displays the benign cartilagenous cap at the upper and the bony cortex at the left lower.

This bone growth, though benign, can sometimes cause problems of pain and irritation that leads to removal surgically.

Osteochondroma - HPF

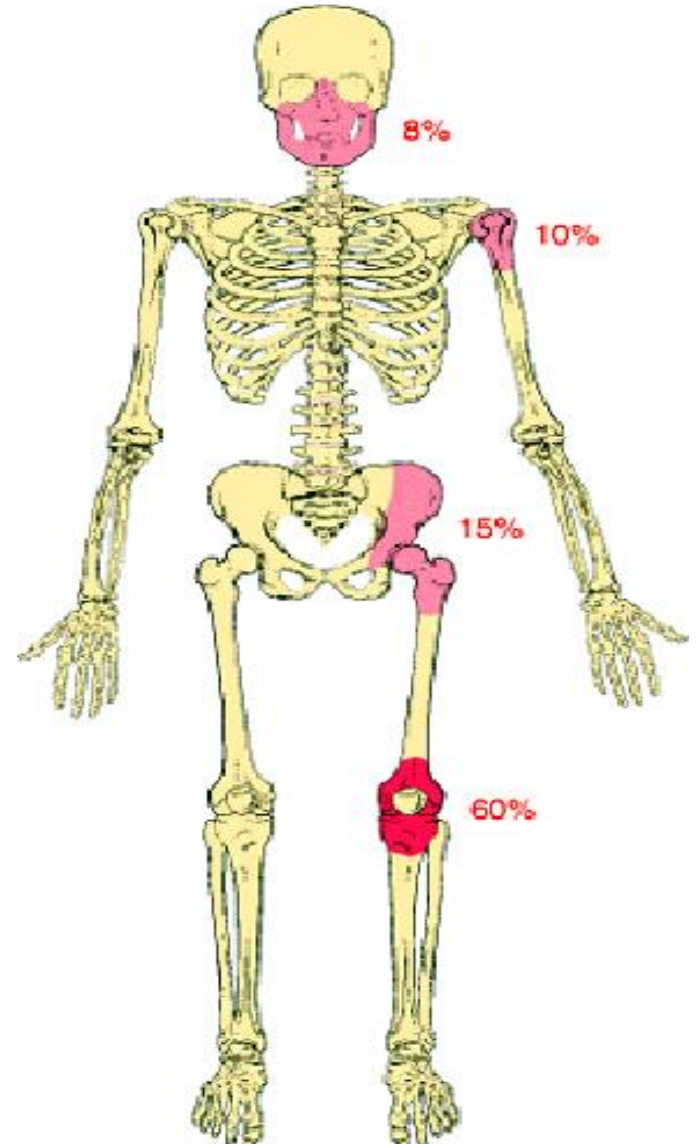


Osteosarcoma

Osteosarcoma, Primary Malignancy

DISTRIBUTION OF OSTEOSARCOMA

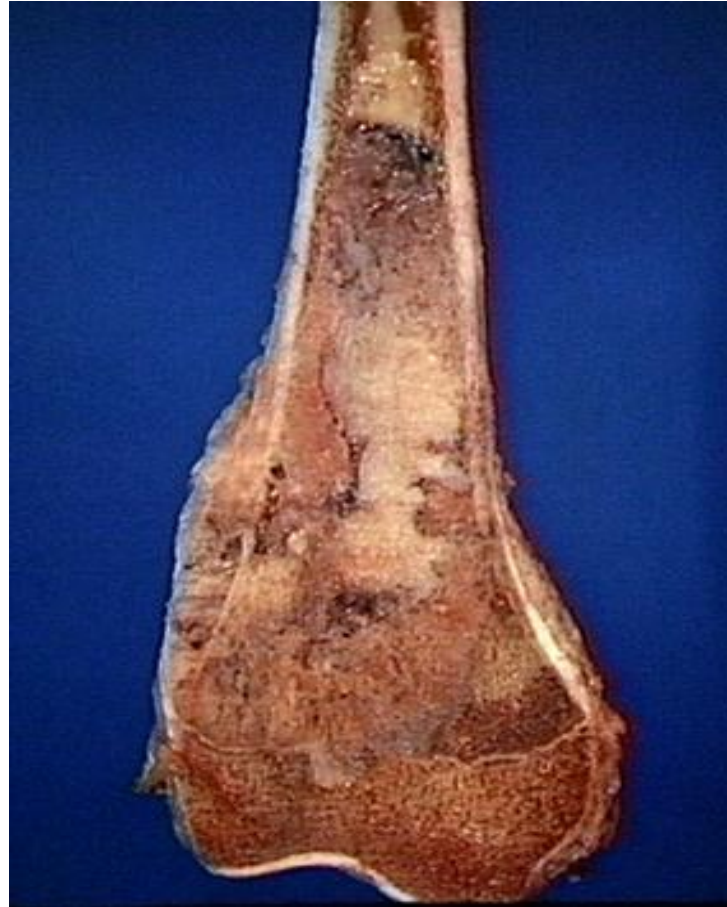- **Weight bearing**
- **Long bones**
- **Young people**
- **Osteoblast is malignant cell**
- **Genetics of tumor being unraveled**



Case # 8

- **An 18-year-old female presented to the rheumatology clinic with 2 months history of pain and swelling in her upper thigh with weight loss .**

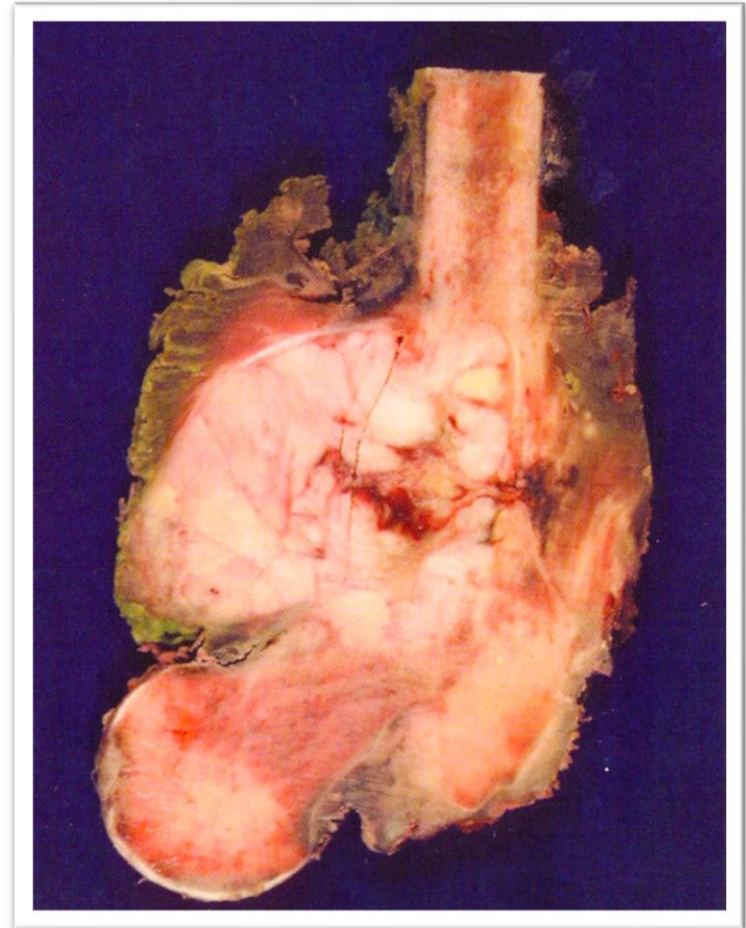
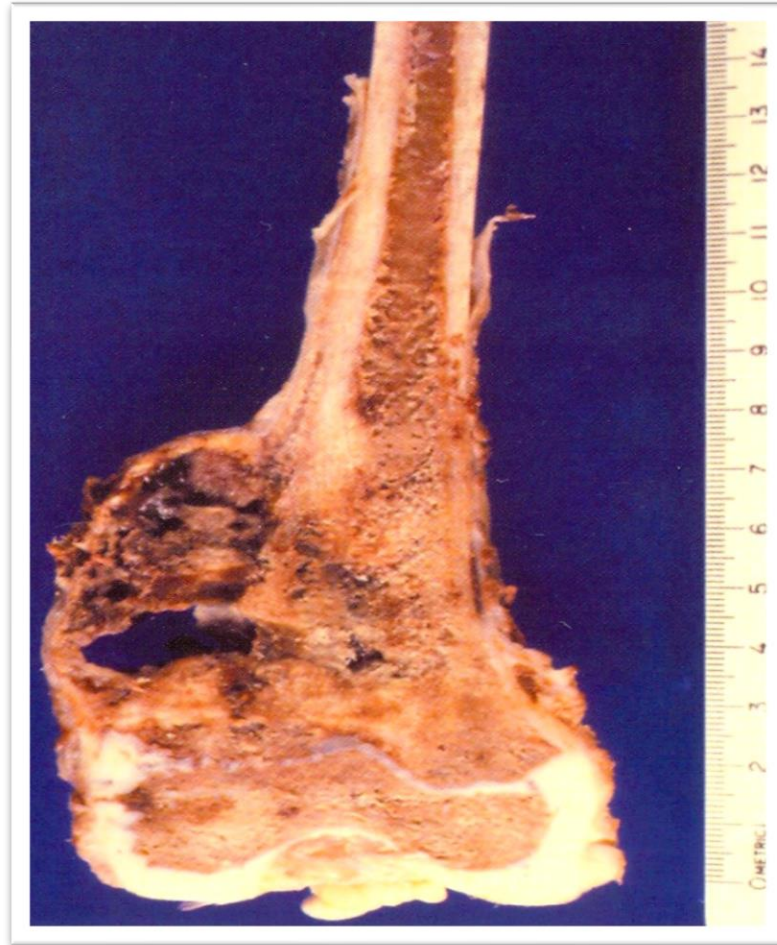
- **2nd most common primary bone tumor**
- **Malignant tumor of mesenchymal origin**



Osteosarcoma of the upper end of the tibia.

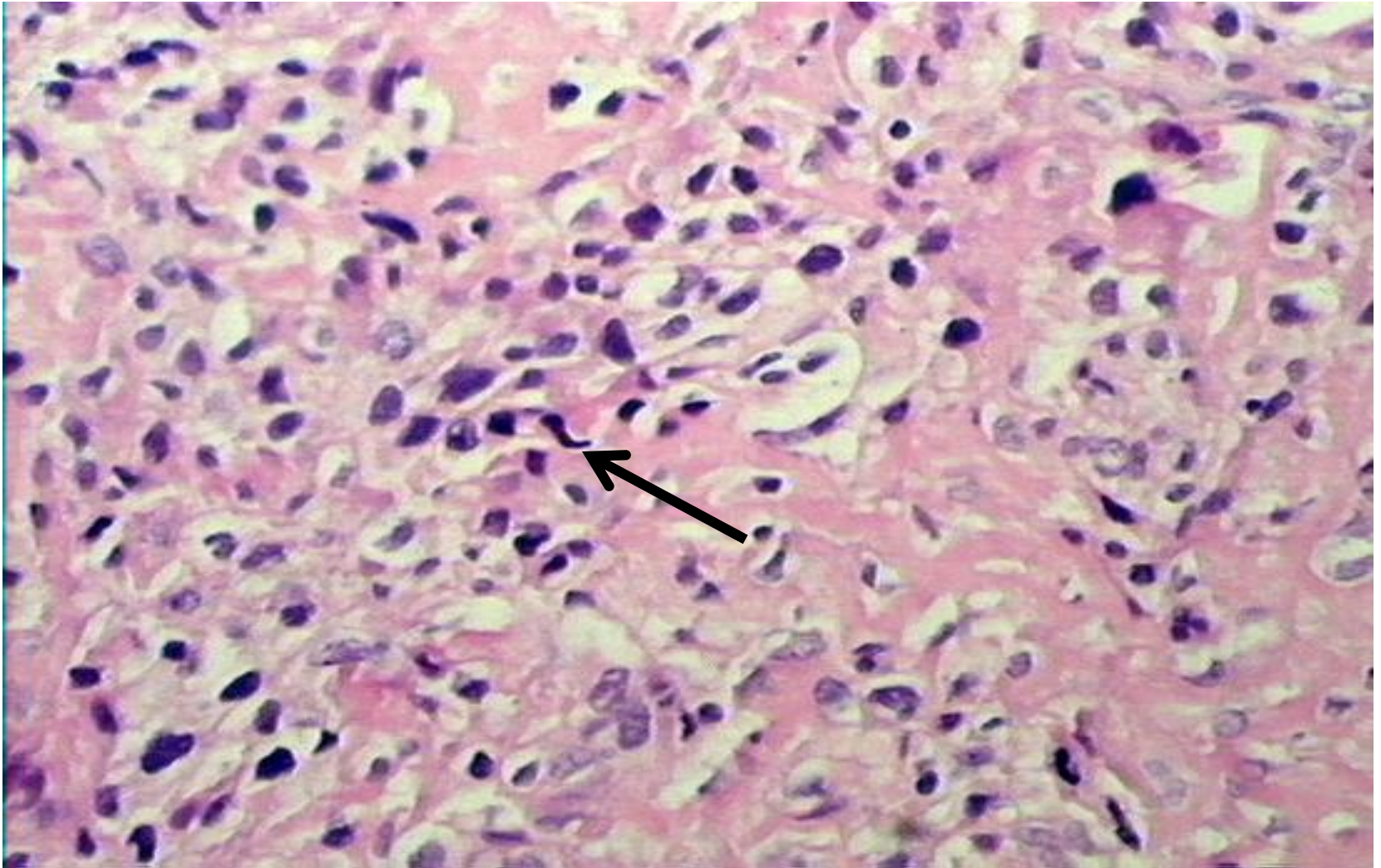
The tan-white tumor fills most of the medullary cavity of the metaphysis and proximal diaphysis. It has infiltrated through the cortex, lifted the periosteum, and formed soft tissue masses on both sides of the bone.

Conventional Osteosarcoma - Gross



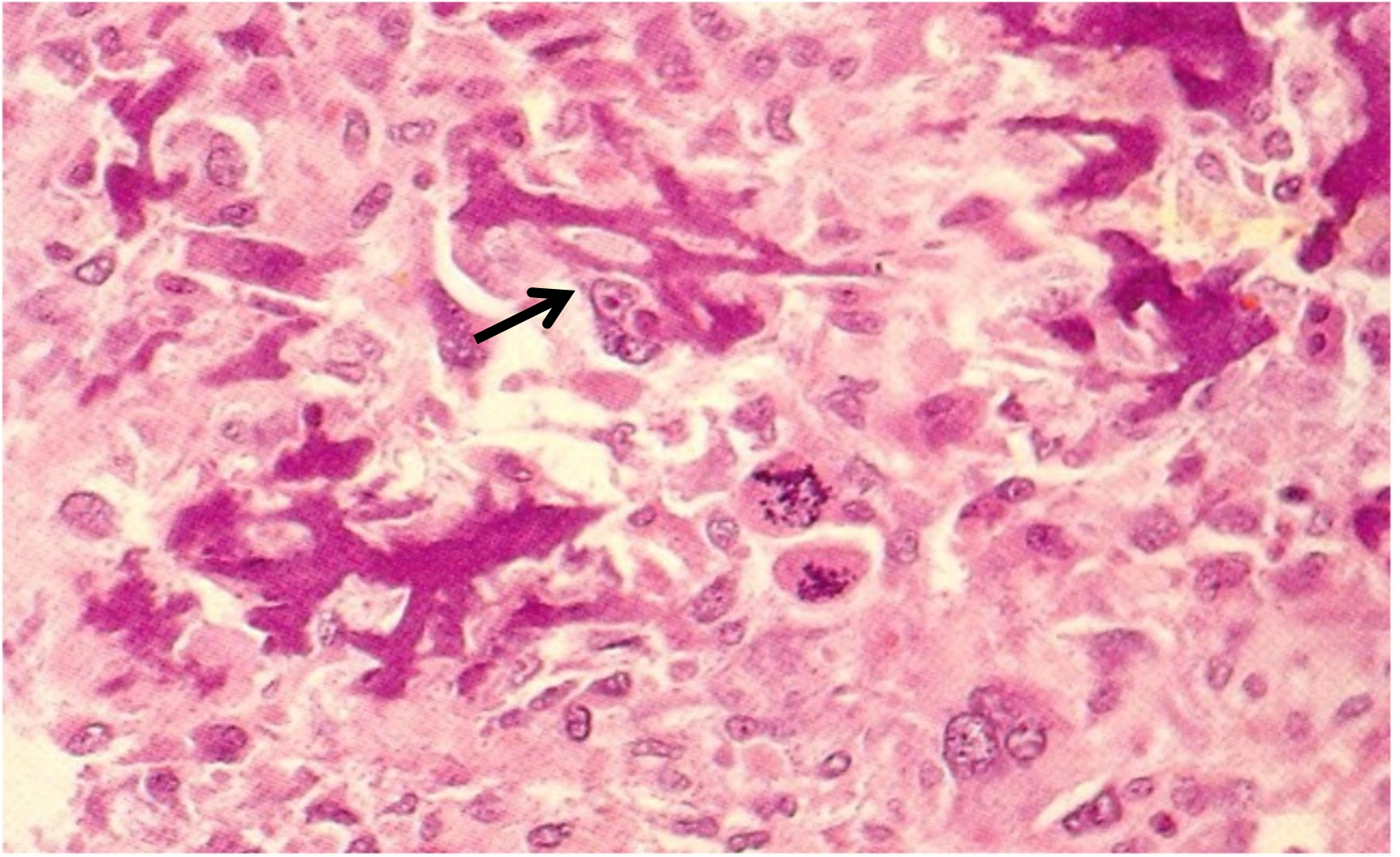
Mixture of osteoid, fibrous, cartilaginous, necrotic, hemorrhagic, cystic areas

Osteosarcoma - LPF



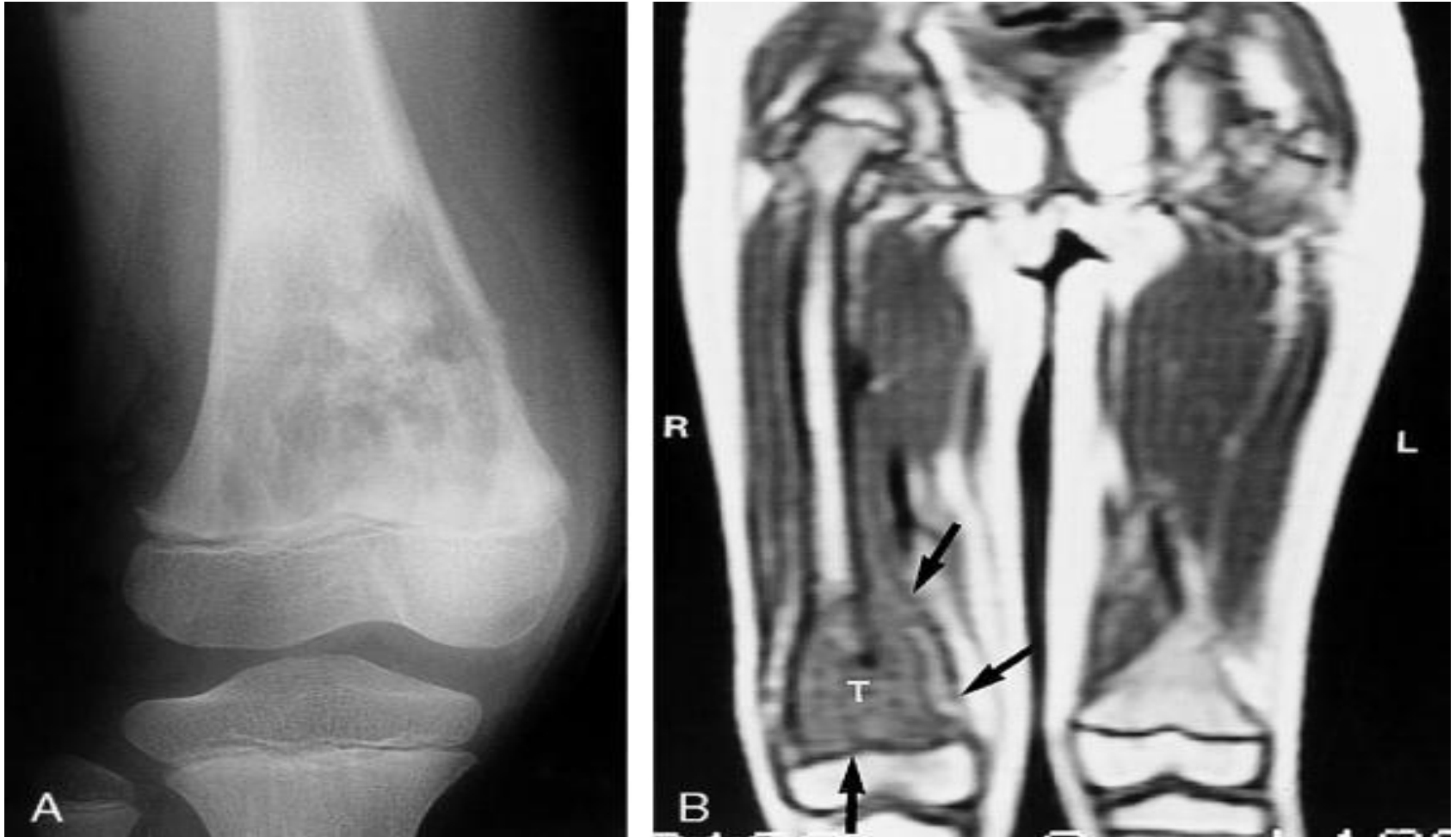
Spindle shaped cells producing osteoid

Osteosarcoma - HPF



Spindle shaped cells that produce osteoid

Central Osteosarcoma



A: destructive lesion is seen in the metaphysis on this anteroposterior view of the knee in a young teenager with pain.

B: magnetic resonance scan of both legs shows soft tissue extent of the tumor (arrows).

THE END