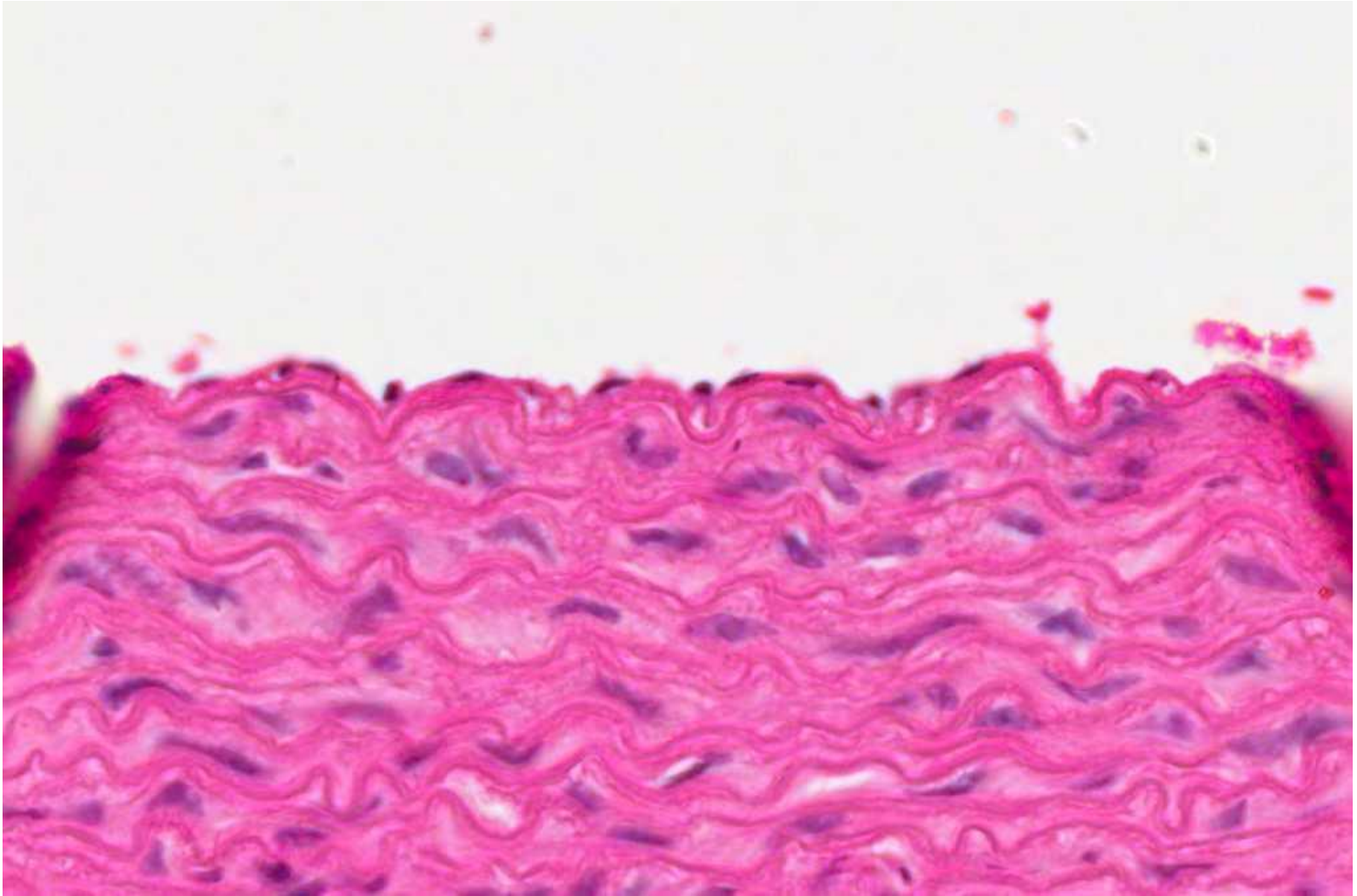
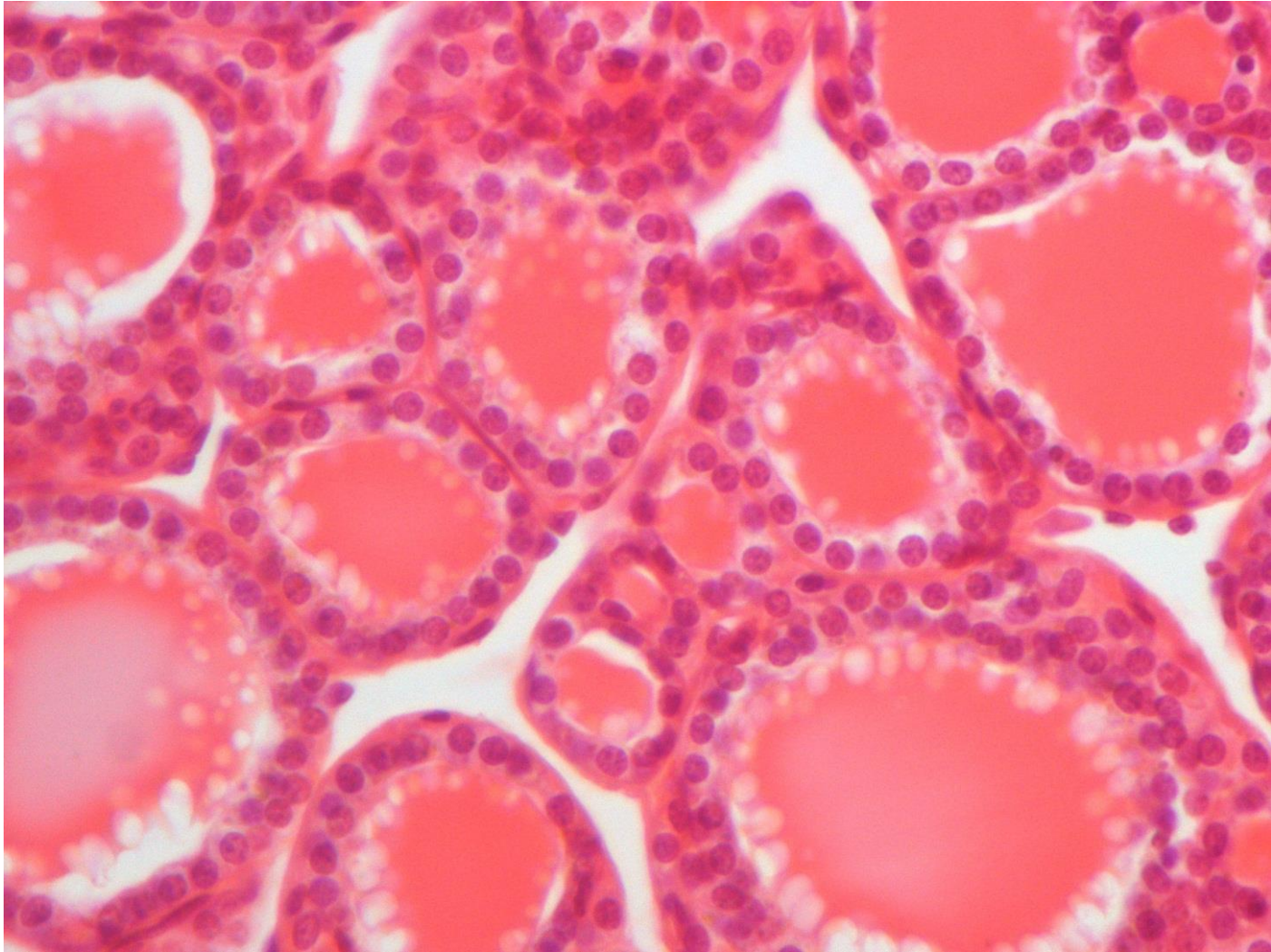


# Practical Histology of Epithelium

# Simple squamous

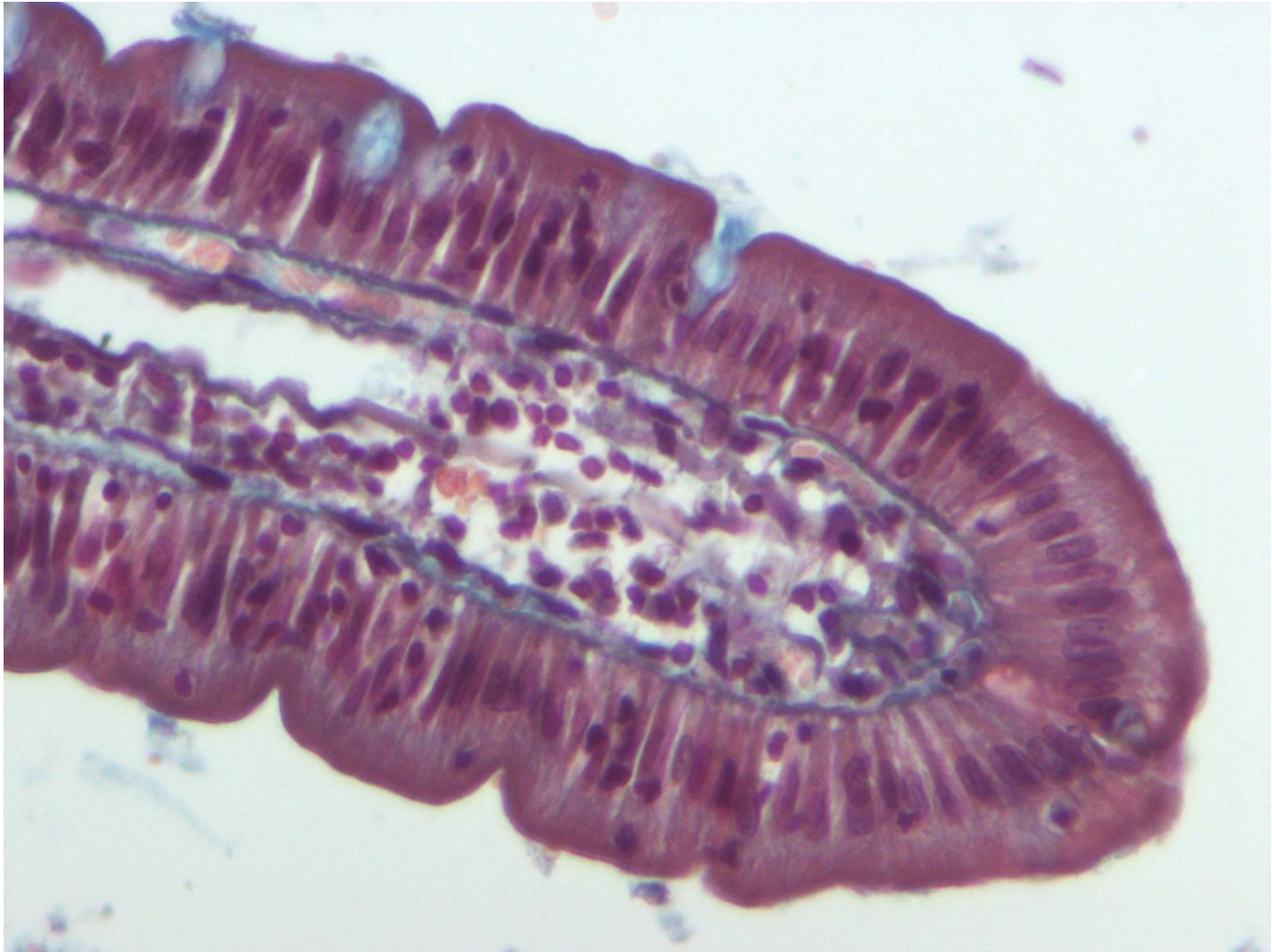


# Simple cuboidal

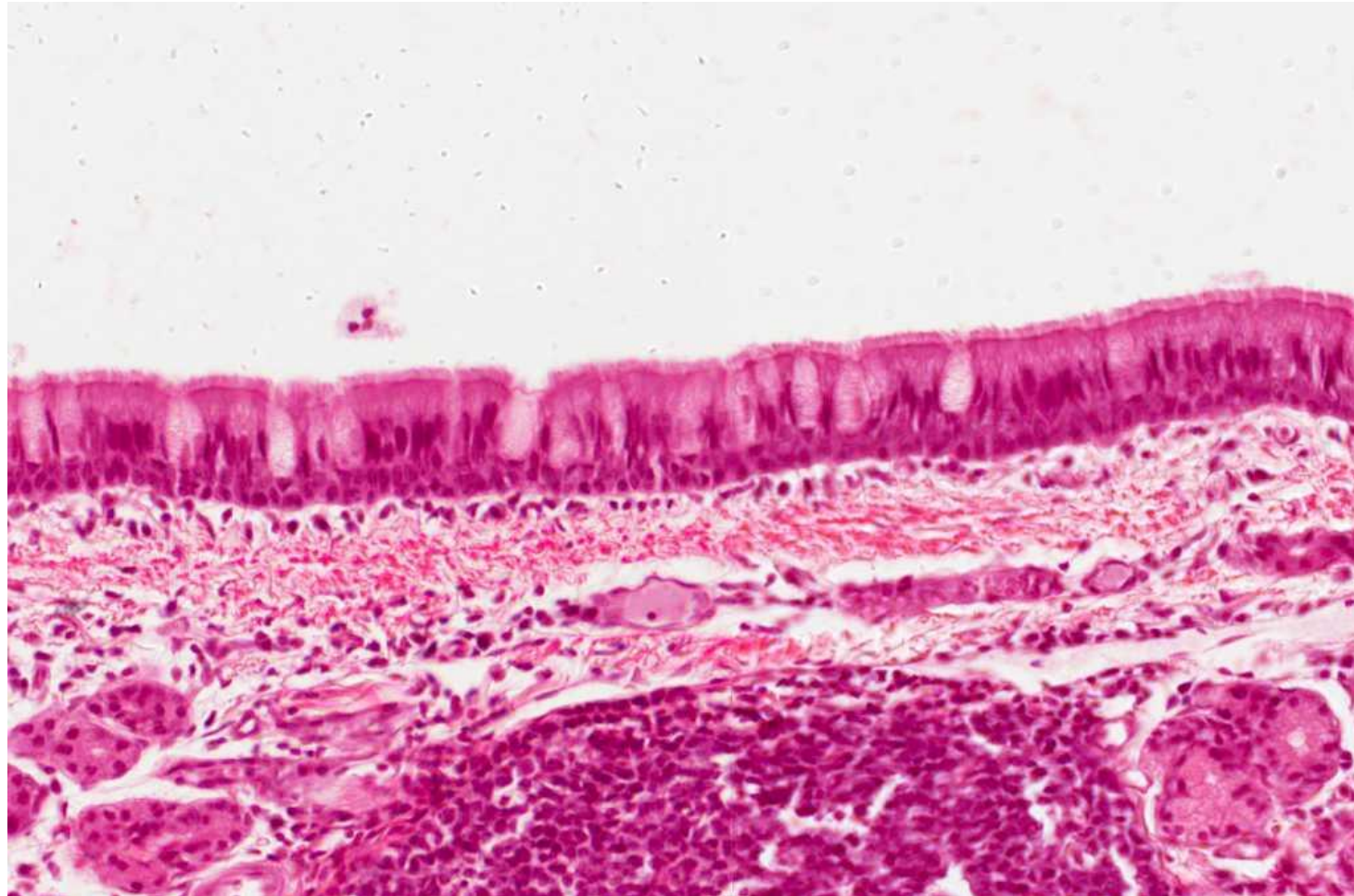




# Simple columnar

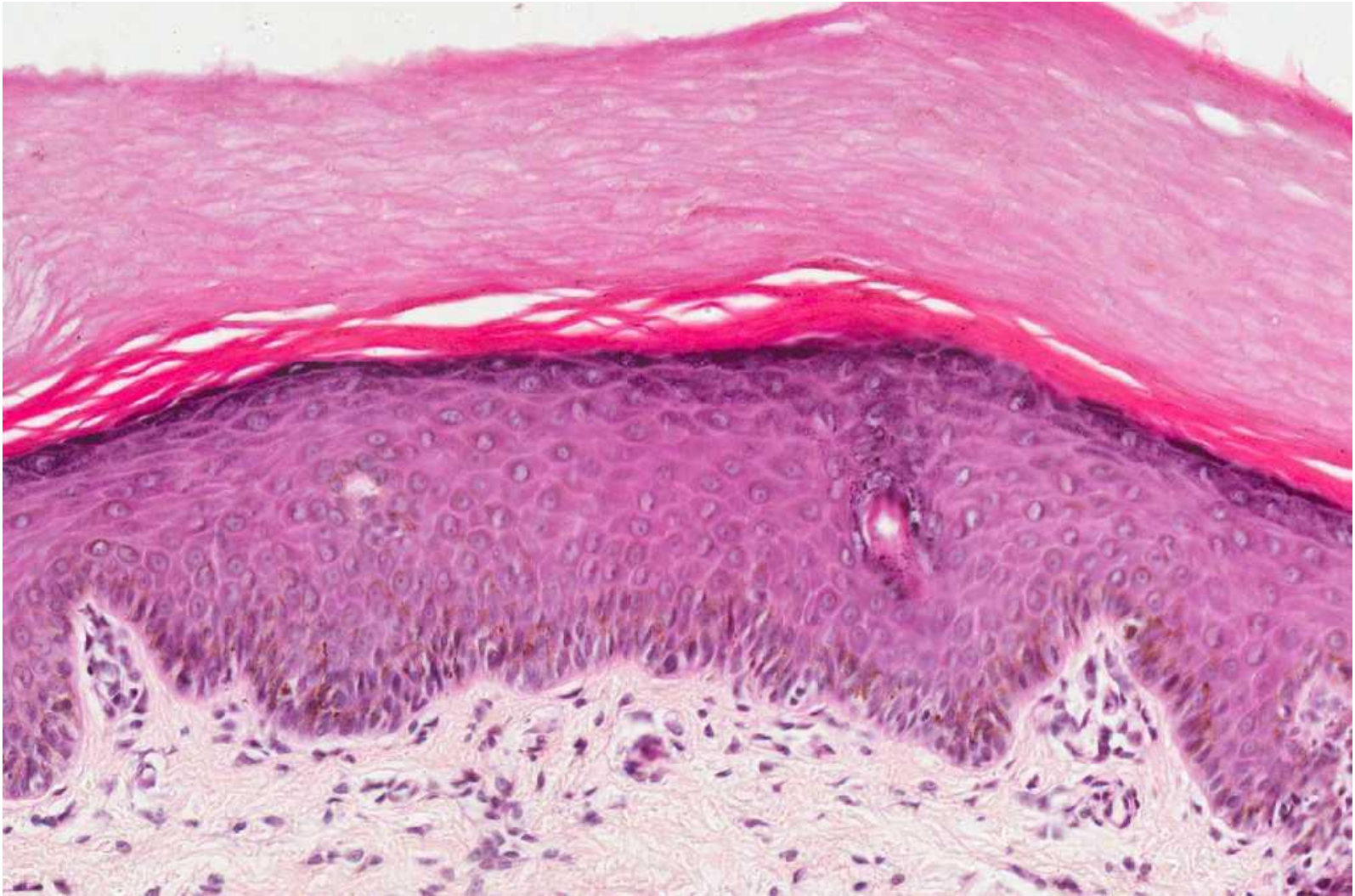

# Pseudostratified columnar ciliated with goblet cells

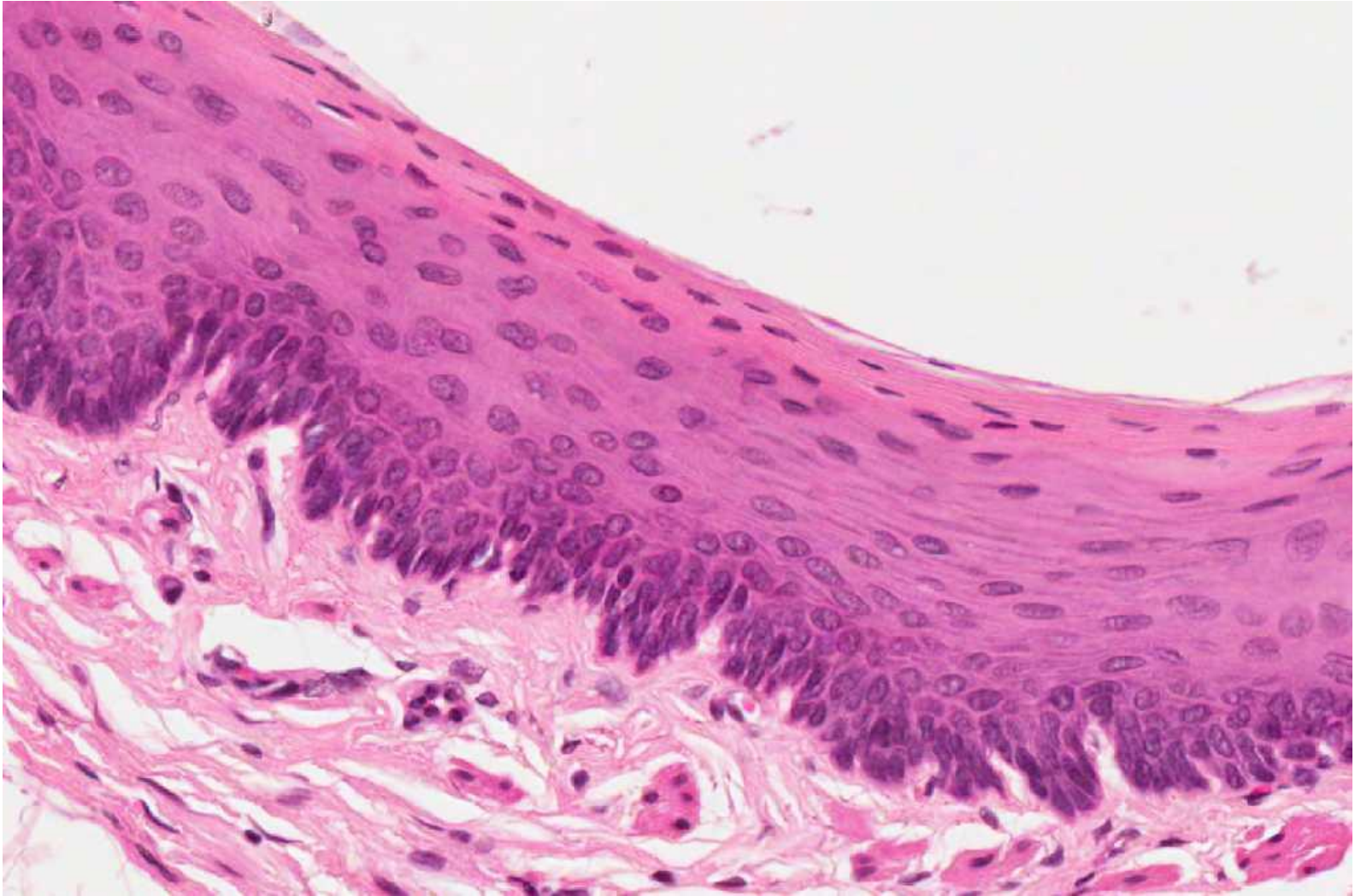




# Stratified squamous-keratinized



# Stratified squamous non-keratinized





# Transitional epithelium

