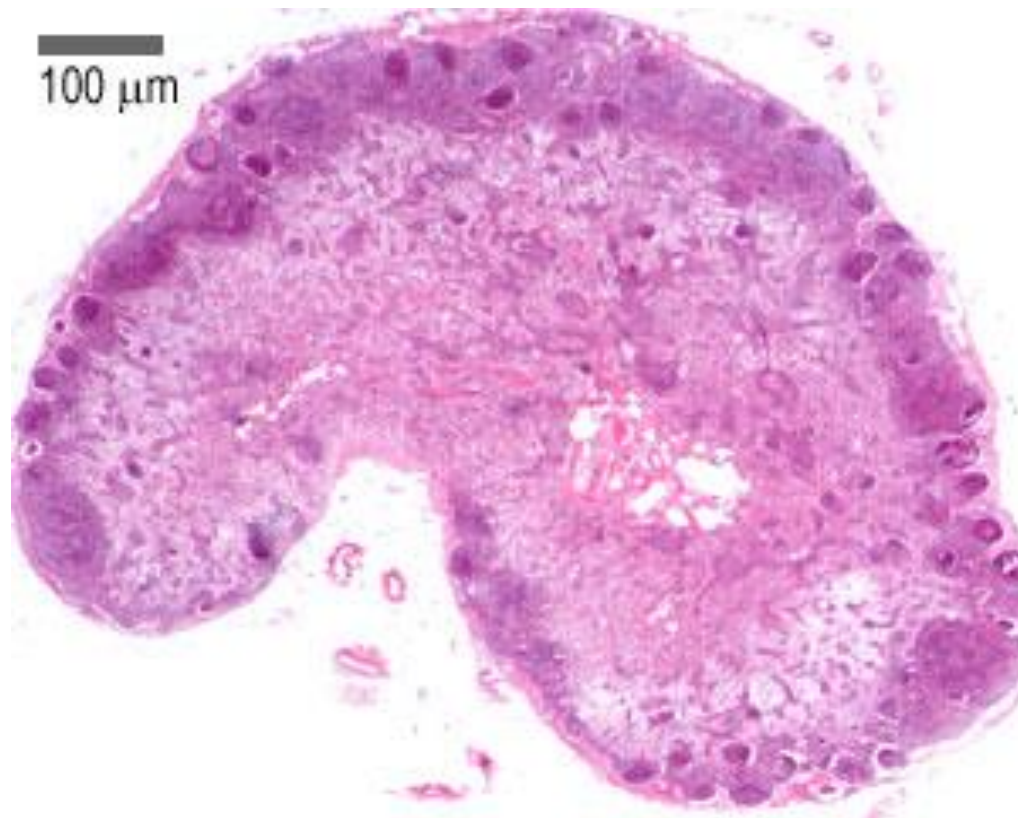
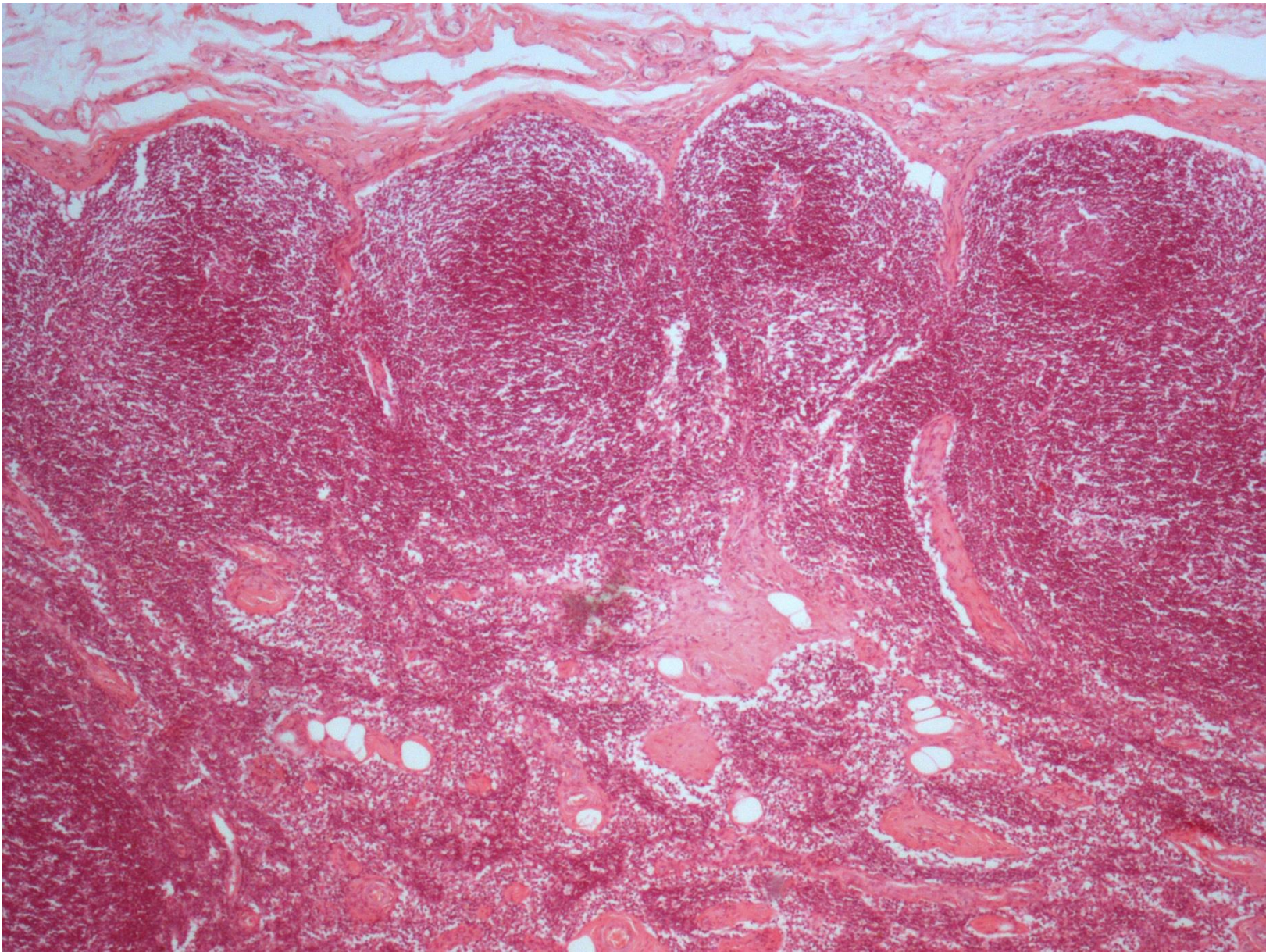


Lymphoid Tissue

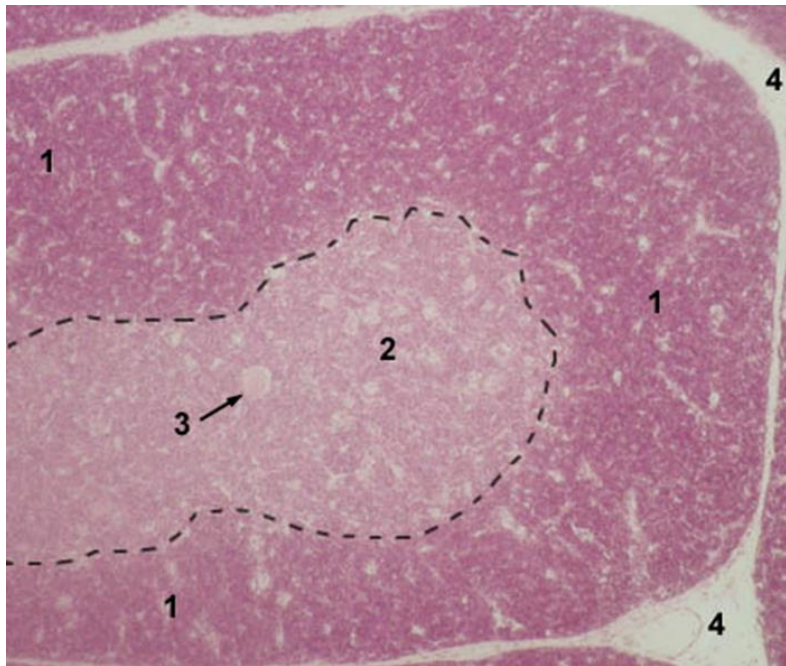
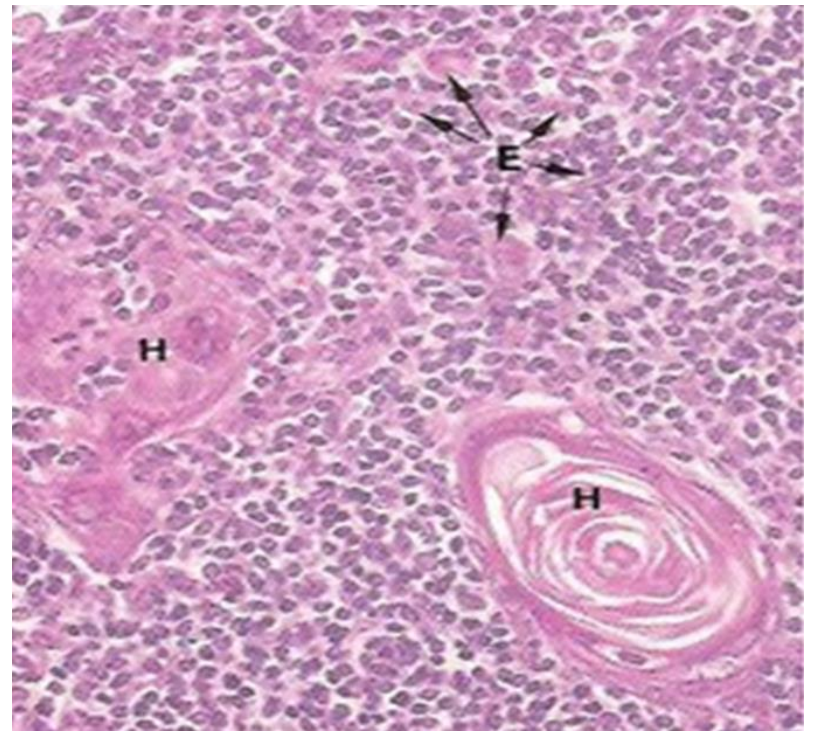
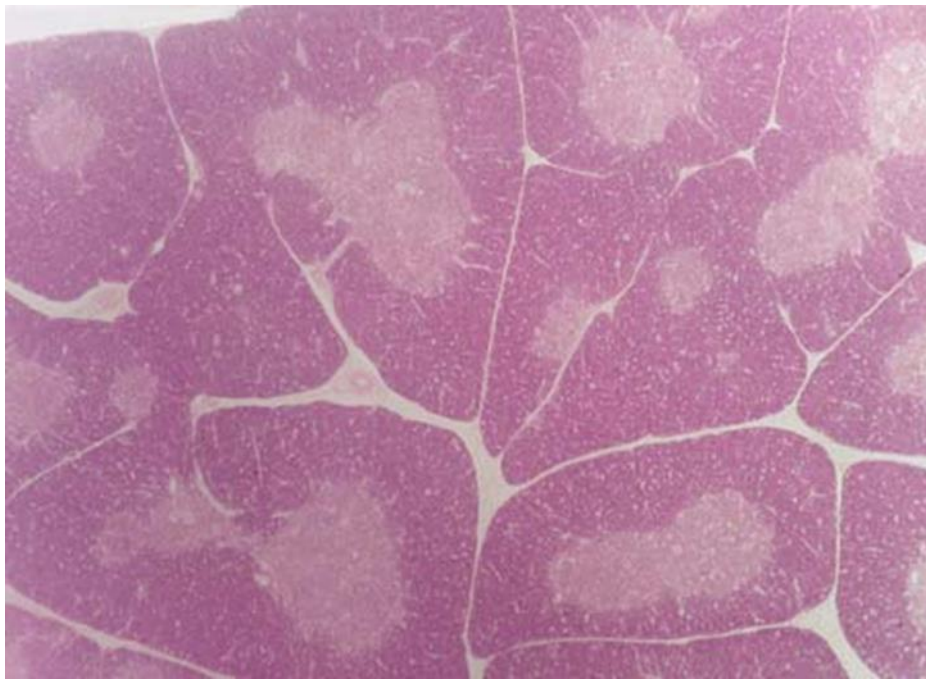
Practical Pictures

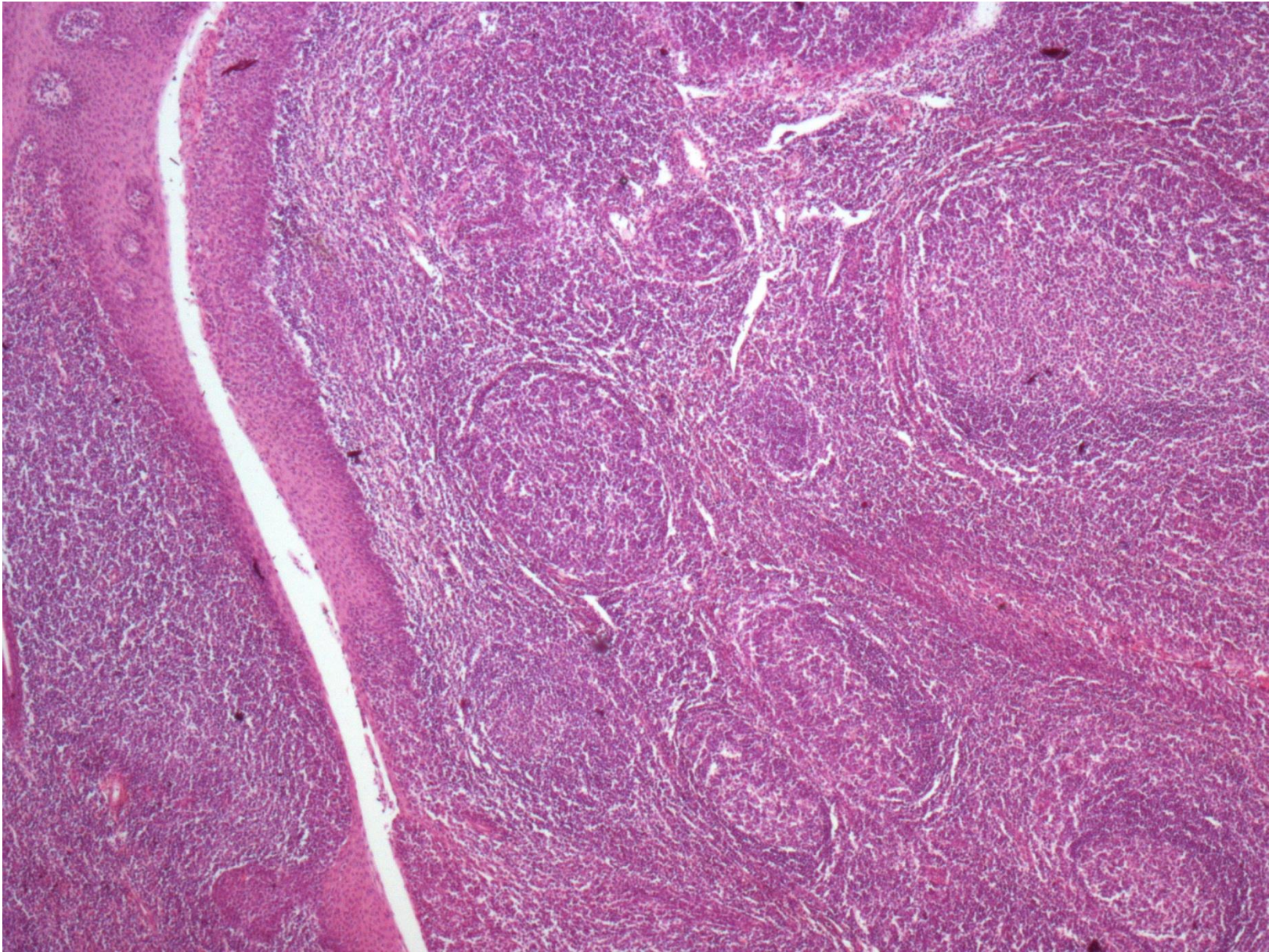
Lymph Node



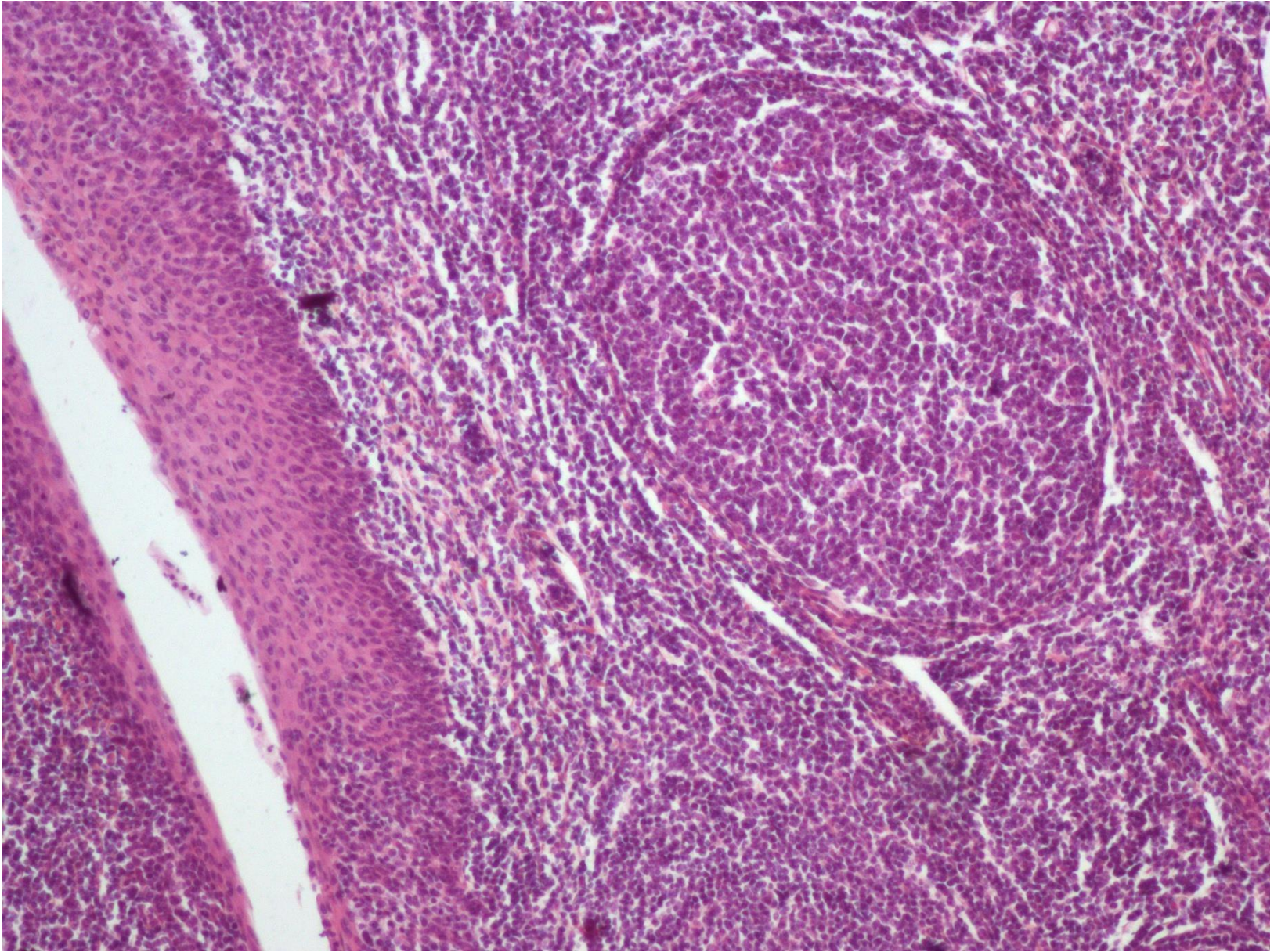


Lymph Node



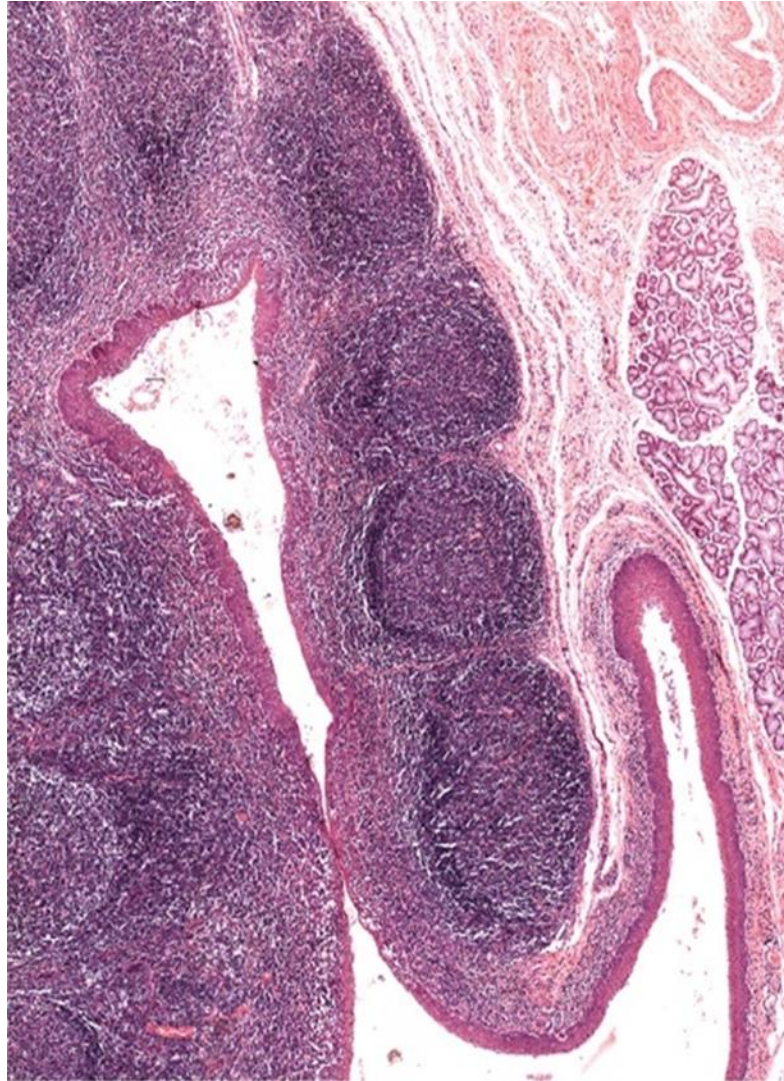


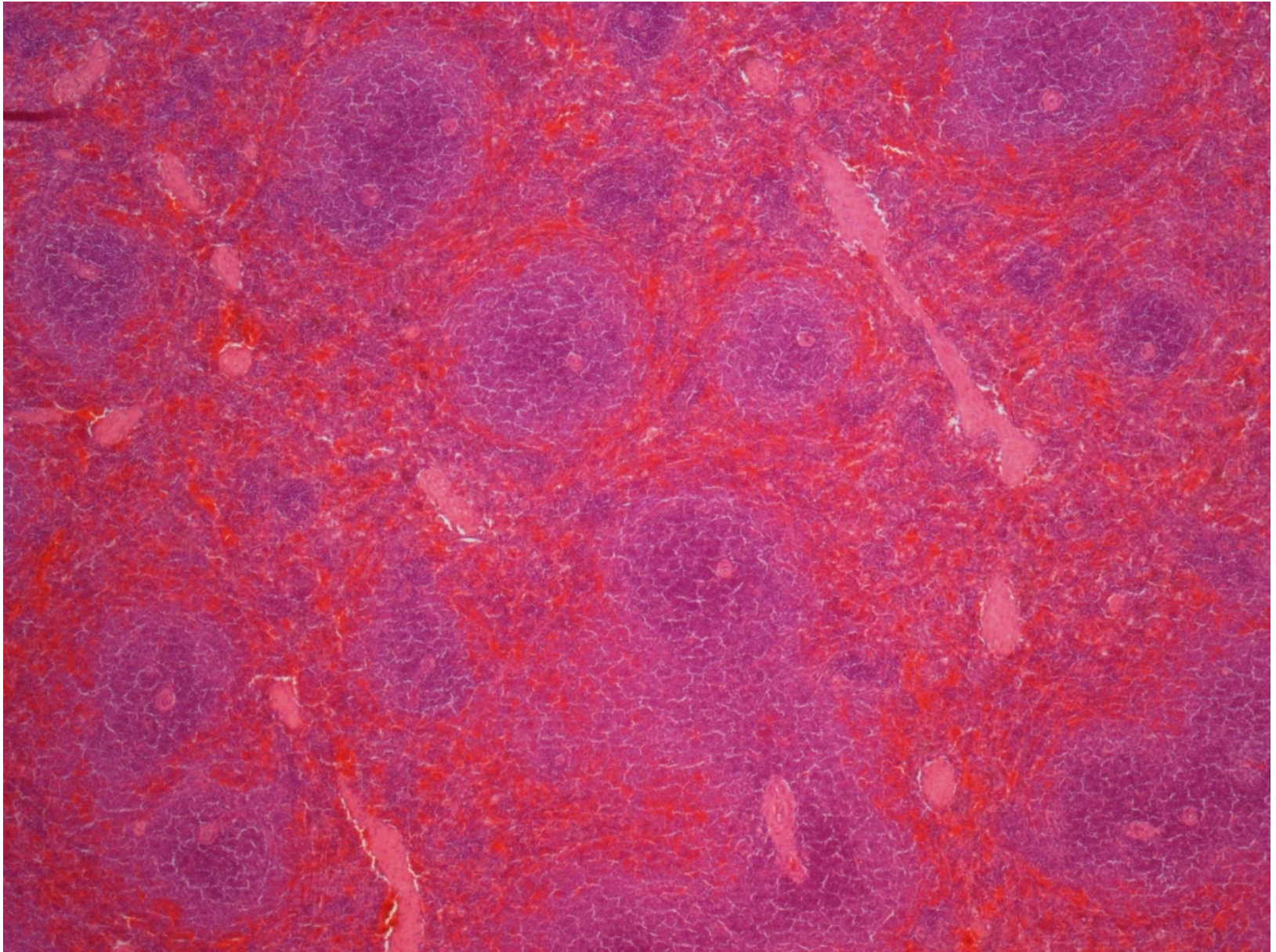
Palatine Tonsil



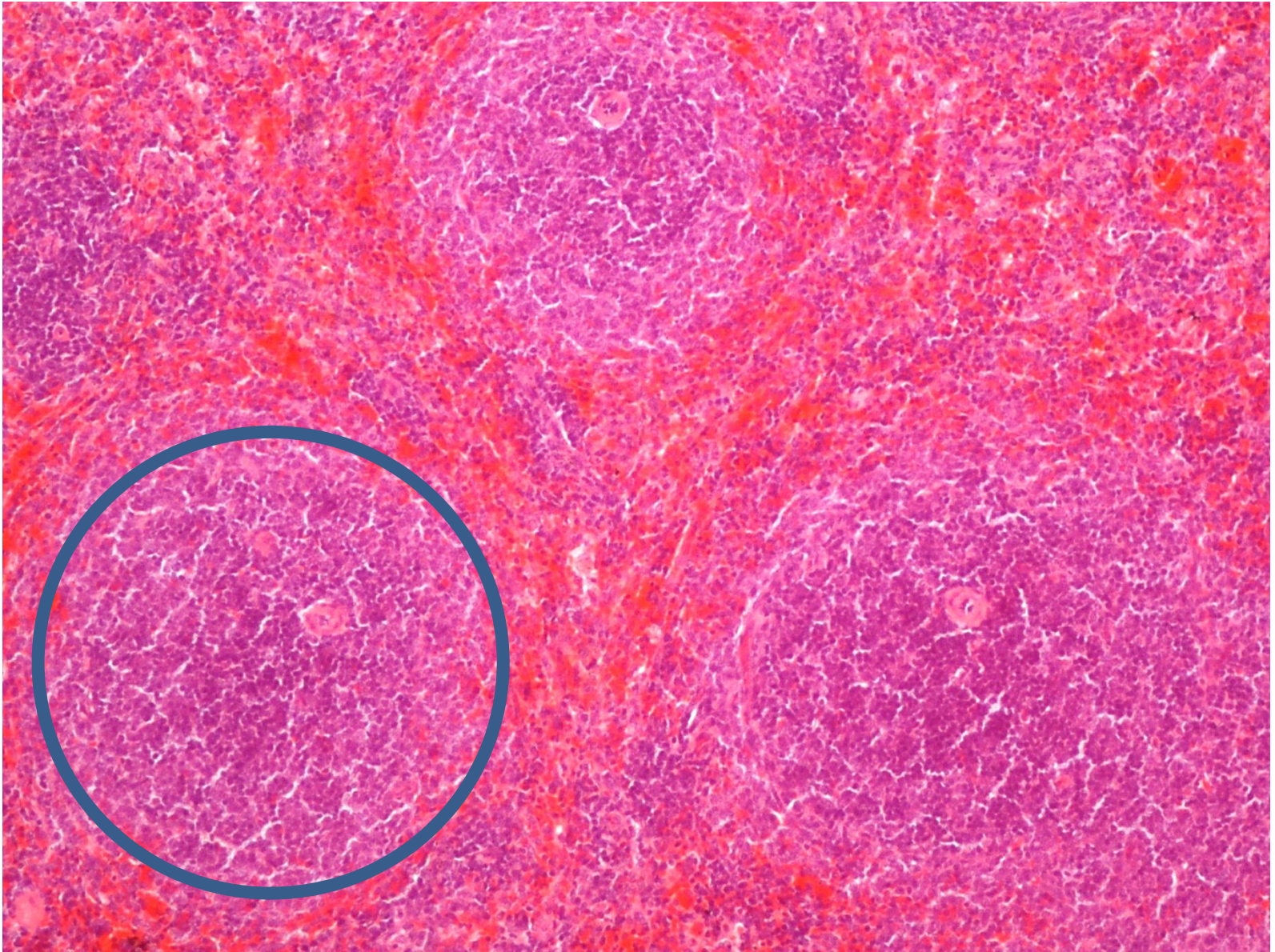
Palatine Tonsil

Palatine
Tonsil

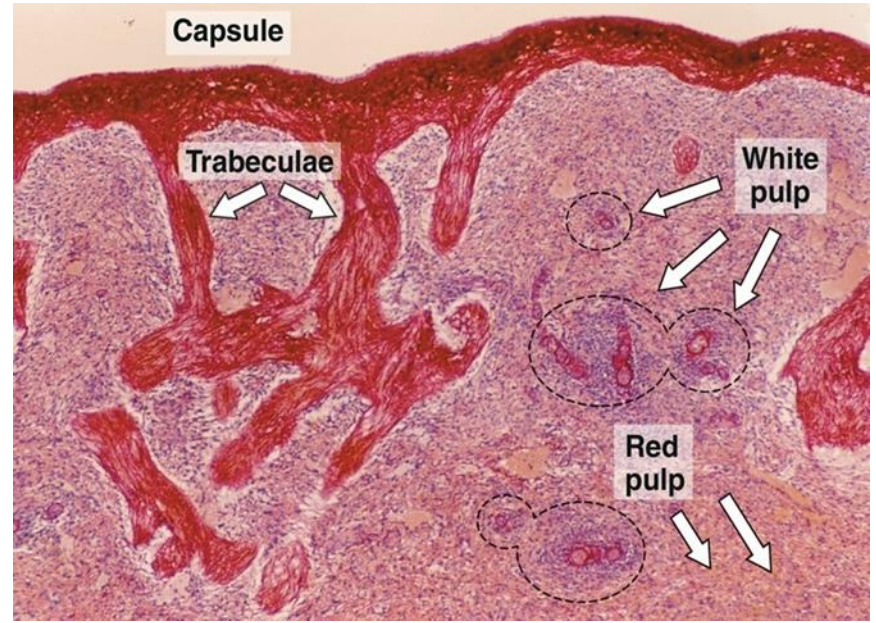
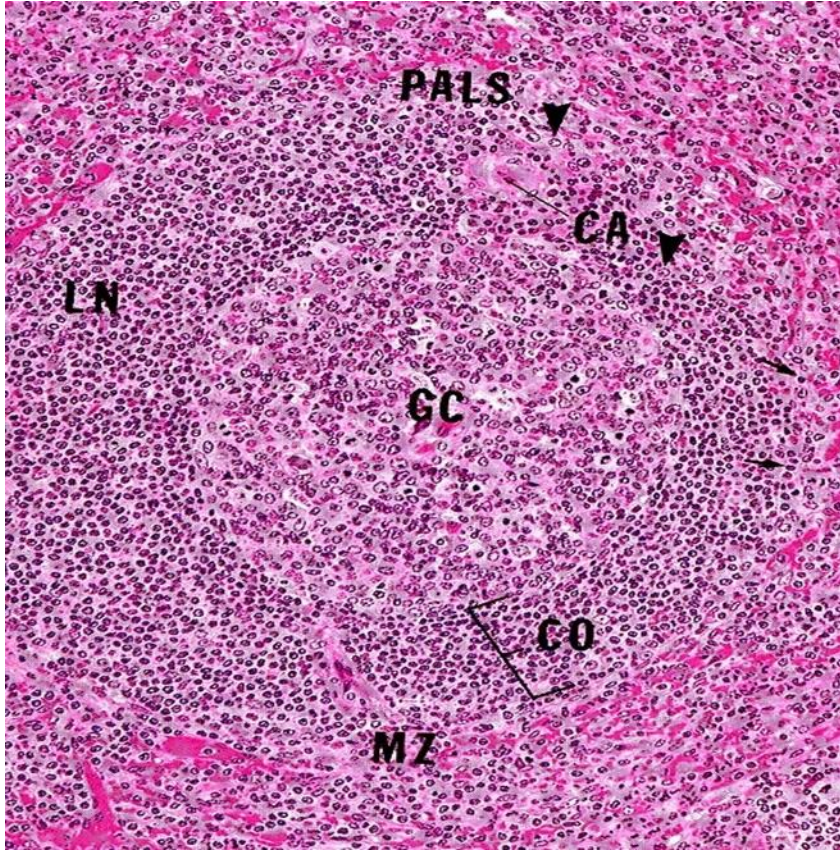




Spleen (low power)



Spleen (high power)



Spleen