

FOUNDATION BLOCK

Pathology Practical on Cell injury

Prepared by:

- *Prof. Ammar Al Rikabi*
- *Dr. Sayed Al Esawy*
- *Dr. Marie Mukhashin*
- *Dr. Shaesta Zaidi*

Objectives:

By the end of these practical sessions, every student will be able to:

- Describe the pathological changes (both macro and micro) which can occur and are seen in the diseases and lesions studied in the foundation block.
- Identify the clinical manifestations of each pathological lesion.
- Correlate the morphological features with the clinical manifestations seen in the lesions and diseases studied.
- Differentiate between the normal structure and the pathological changes of the given tissue.

PRACTICAL

CELL INJURY

Contents:

Basic introduction to the anatomy and histology of the lung, liver, kidney and heart in order to enable the student to understand the related pathology.

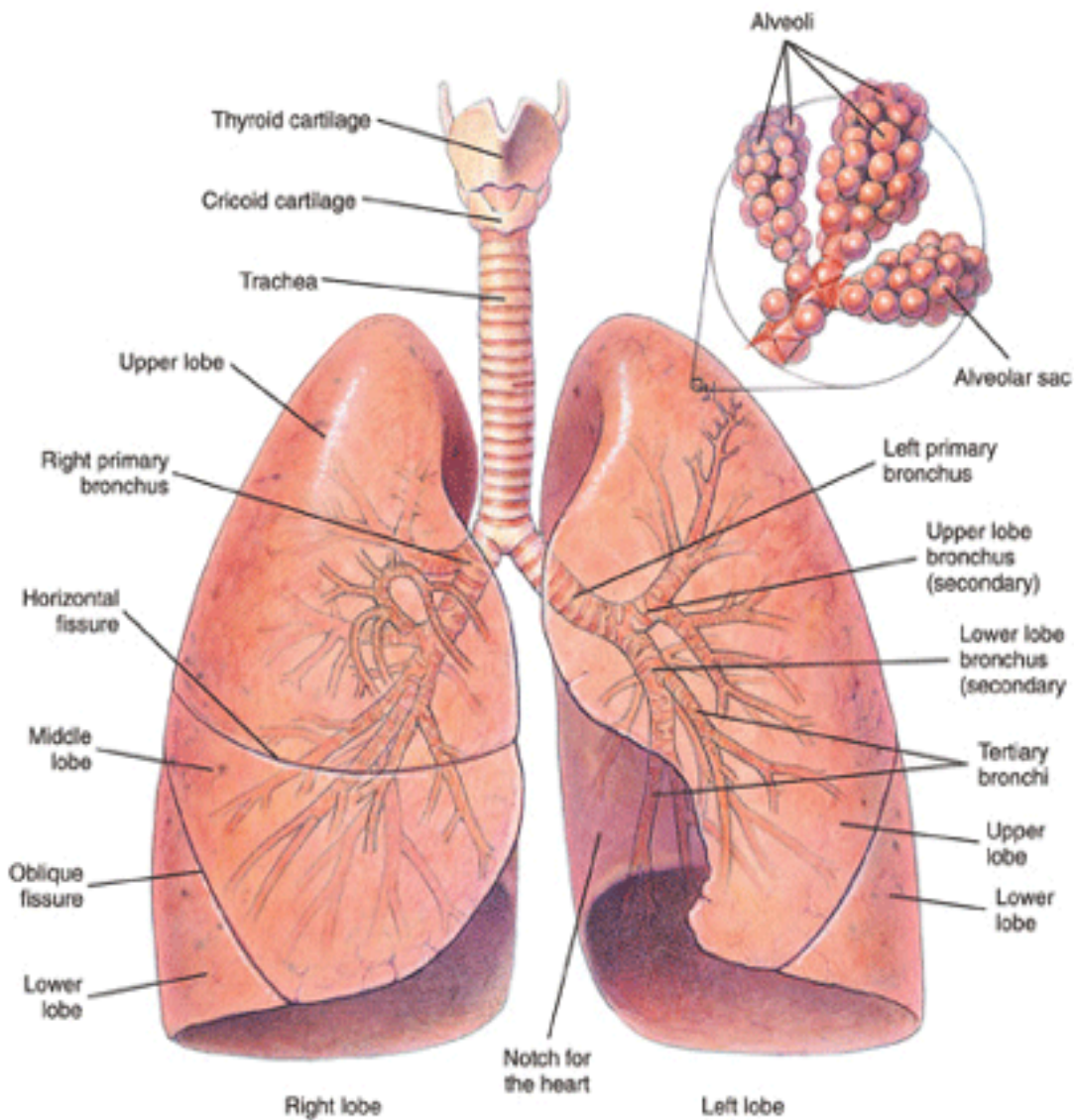
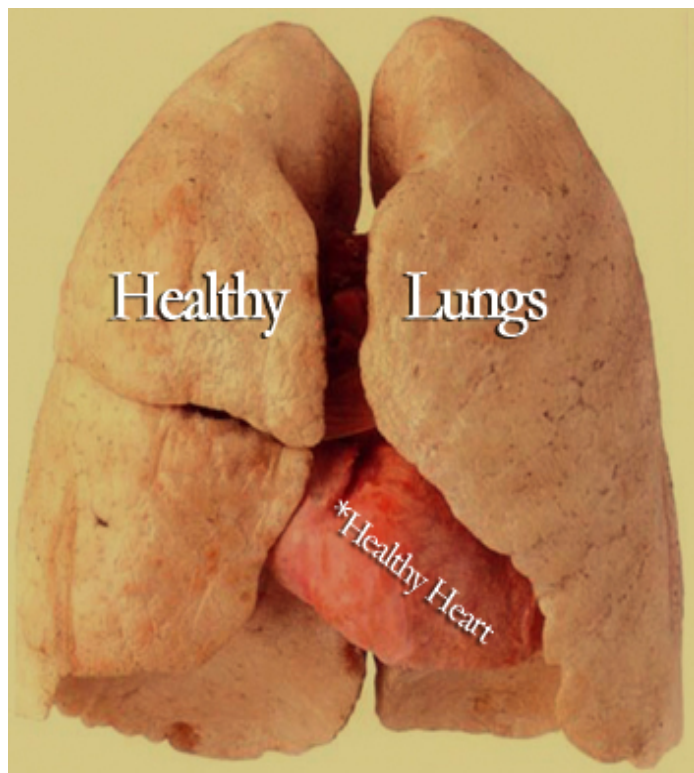
Cell injury

□ Pictures of:

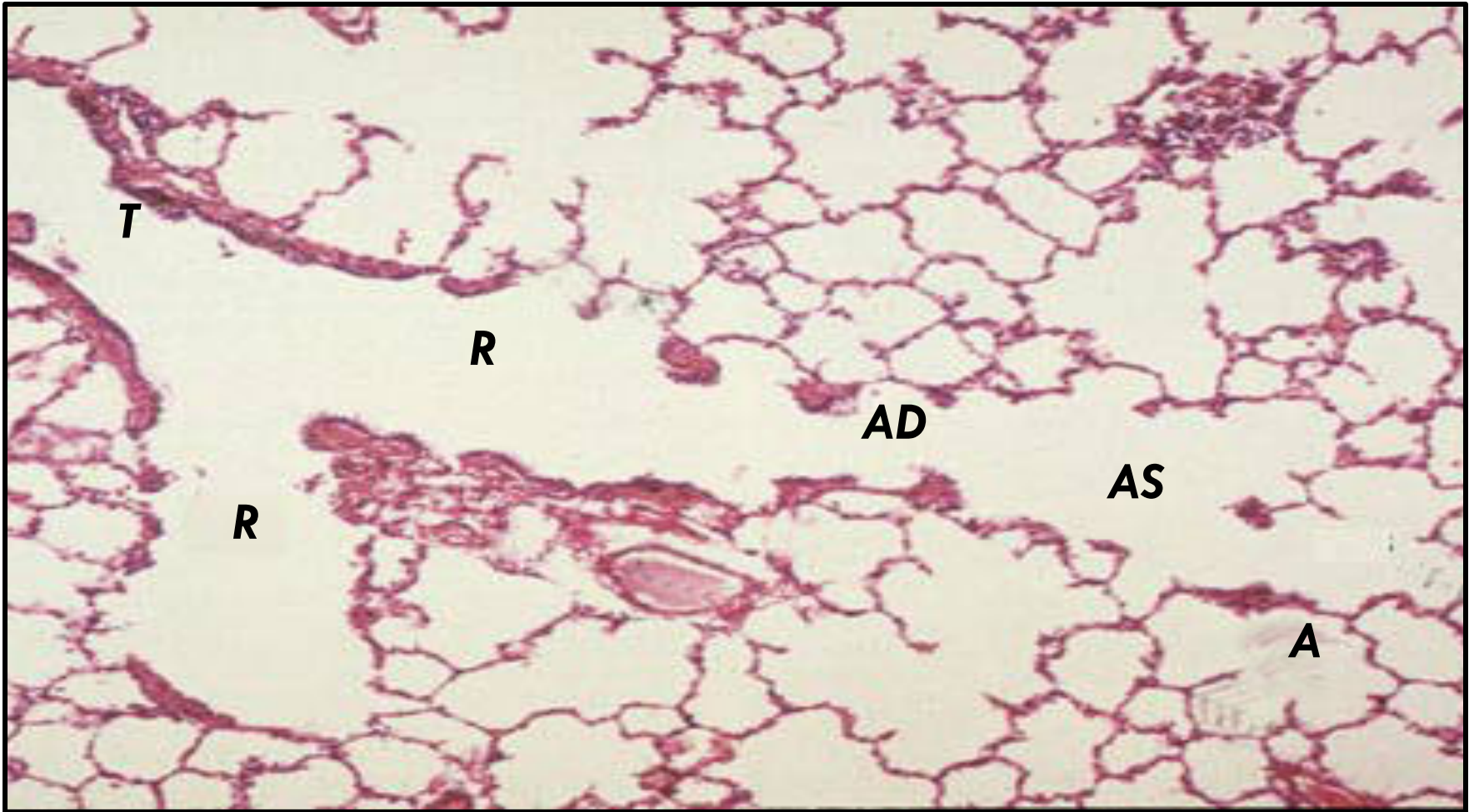
1. Fatty change of the liver.
2. Coagulative necrosis in an infarcted kidney, spleen and myocardium.
3. Liquefactive necrosis
4. Caseous necrosis
5. Fibrinoid necrosis
6. Fat necrosis
7. Dystrophic calcification in the aorta, stomach and skin.
8. Atrophy of brain and testis
9. Left ventricular hypertrophy
10. Hyperplasia of the prostate.
11. Squamous metaplasia.

***NORMAL ANATOMY AND
HISTOLOGY OF ORGANS RELATED
TO THIS CHAPTER***

Anatomy of the Respiratory System

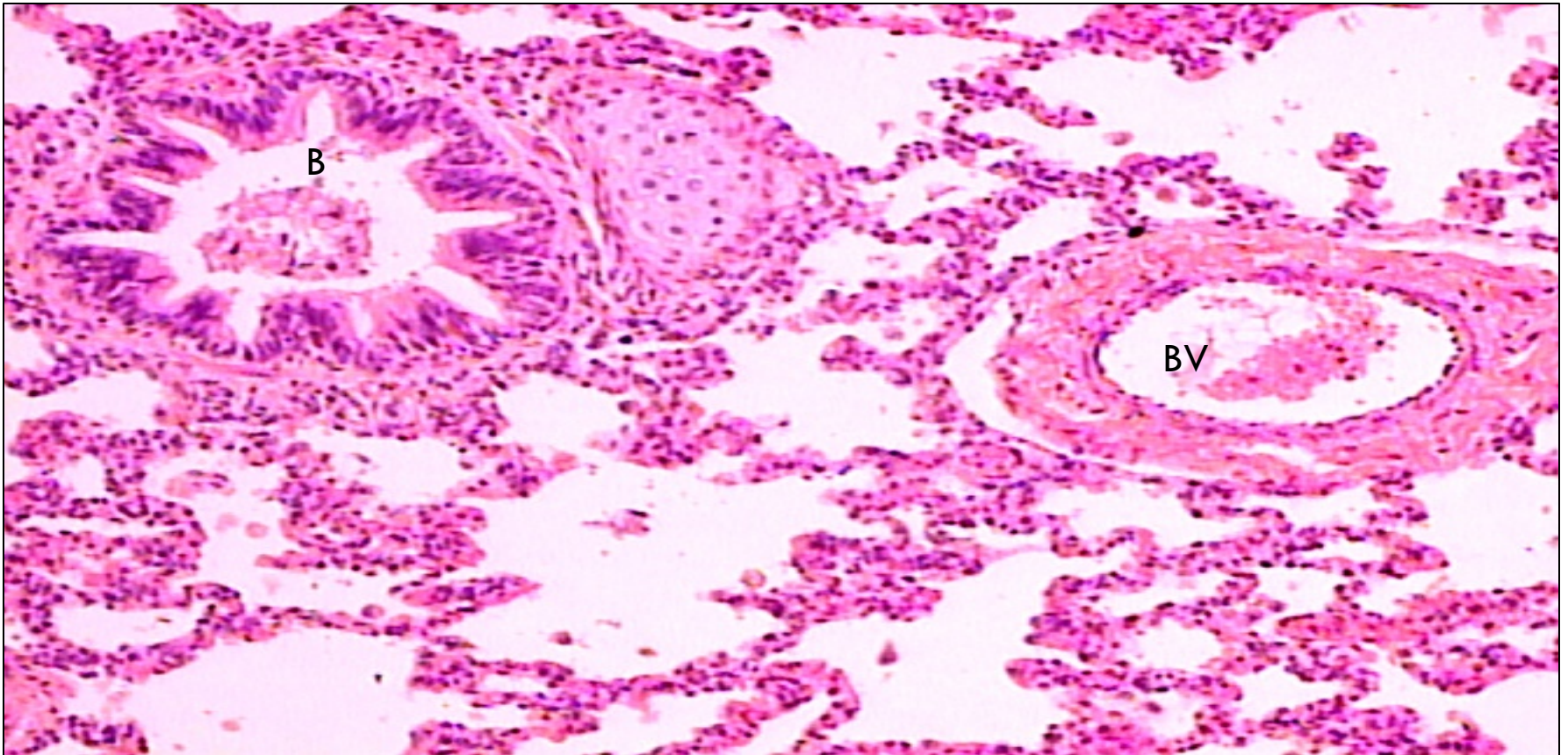


Normal Histology of the Lung (Bronchiole, alveolar duct and alveoli)



**Microscopic section of normal lung showing:
terminal bronchiole (T) , respiratory bronchiole (R), alveolar duct (AD),
alveolar sac (AS), and alveoli (A).**

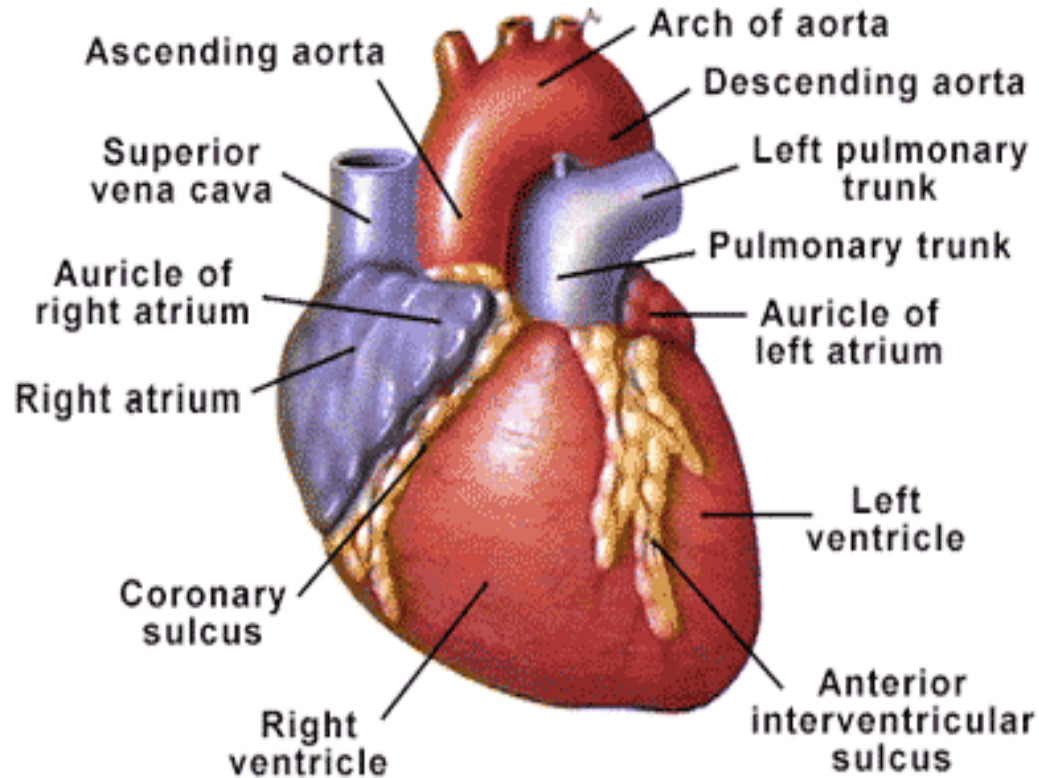
Normal Histology of the Lungs - Bronchiole



This view shows a BRONCHIOLE (right) and Blood Vessel (left) in cross-section as well as numerous ALVEOLI in The bronchiole inner membrane is composed of pseudostratified columnar epithelium.

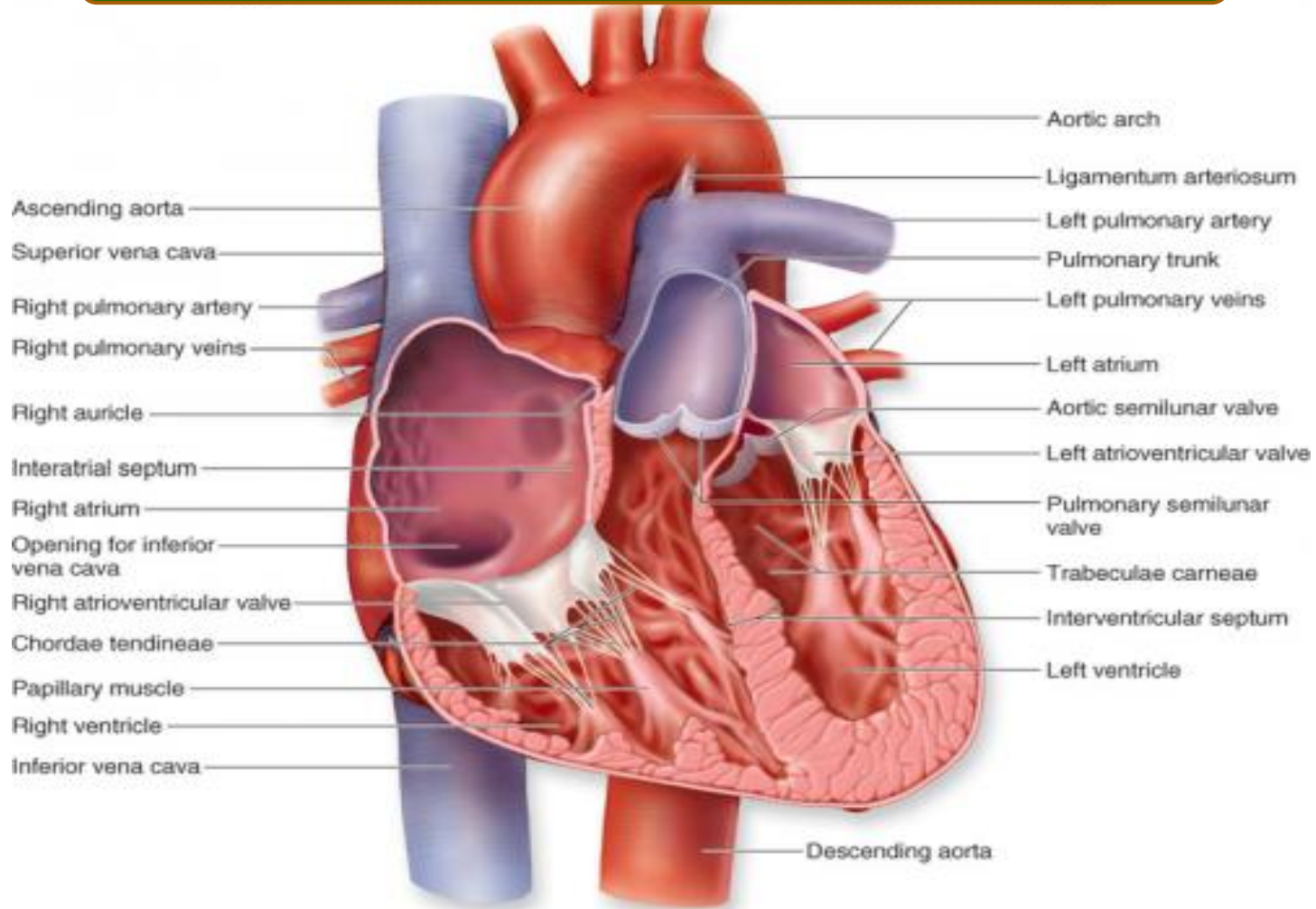
Portions of hyaline cartilage rings can also be seen outside of the bronchiole.

Anatomy of the Heart



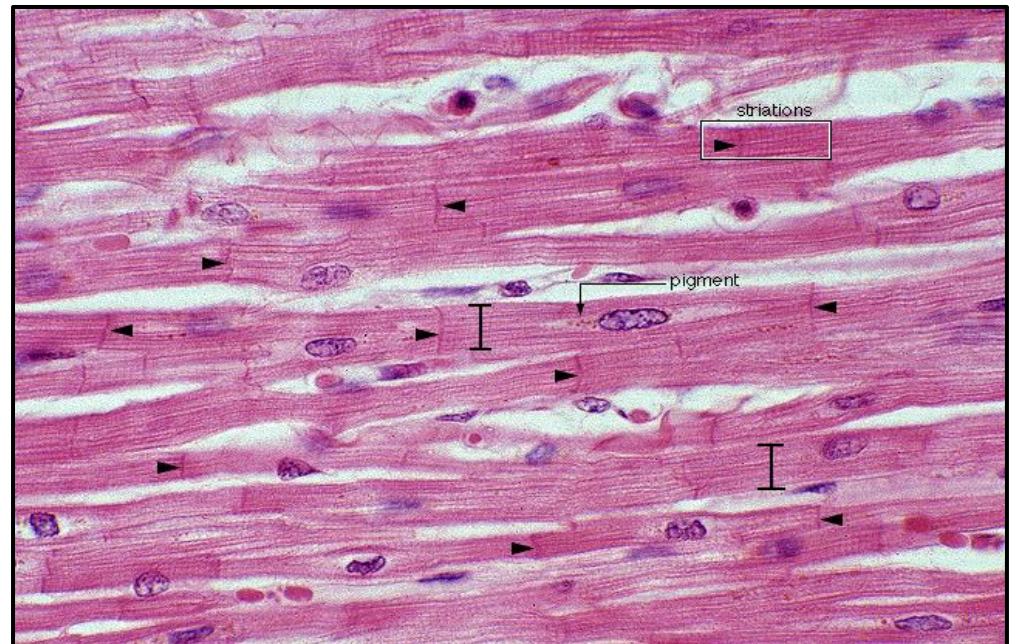
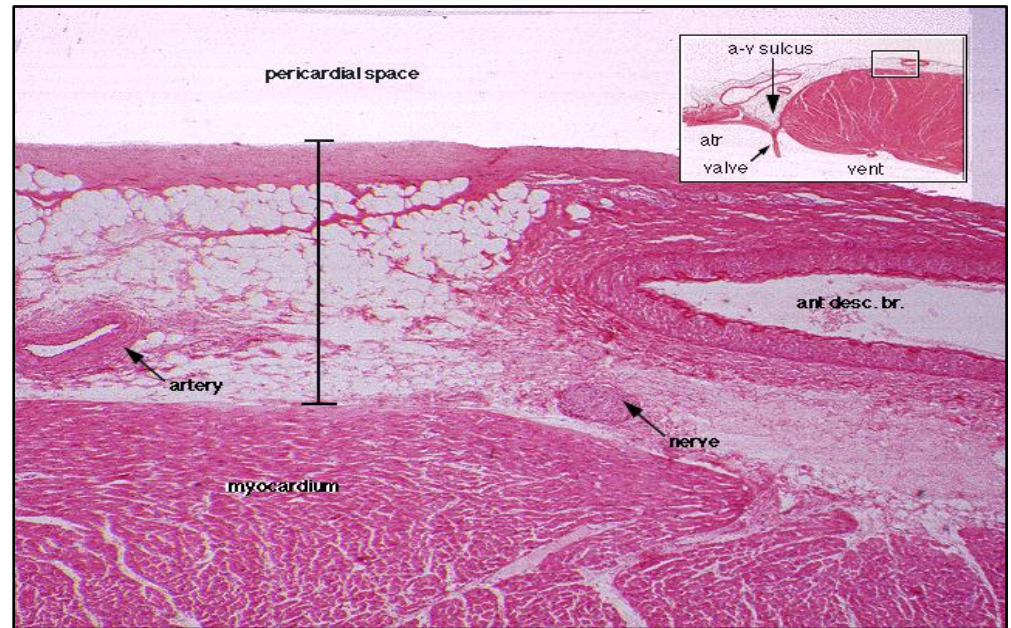
- ***The heart serves as a mechanical pump to supply the entire body with blood, both providing nutrients and removing waste products.***
- ***The great vessels exit the base of the heart.***
- ***Blood flow: Body → venae cavae → right atrium → right ventricle → lungs → left atrium → left ventricle → Aorta → body***

Anatomy of the Heart – inside view



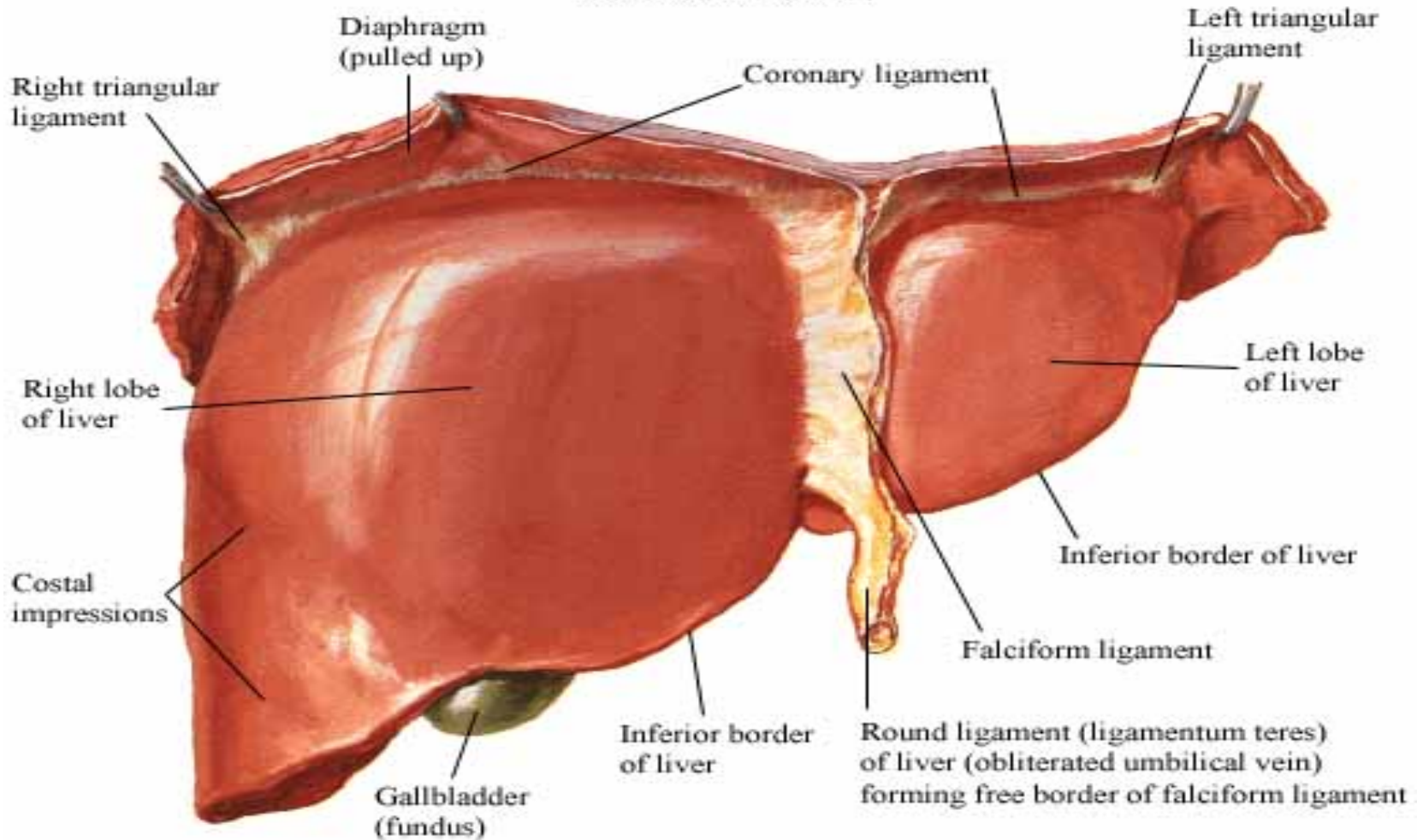
Histology of the Heart

- The heart consists of 3 layers
 - the **endocardium**,
 - the **myocardium**, and
 - the **epicardium**.
- The **epicardium** consists of arteries, veins, nerves, connective tissue, and variable amounts of fat.
- The **myocardium** contains **branching, striated muscle cells with centrally located nuclei**. They are connected by **intercalated disks** (arrowheads).



Anatomy of the Normal Liver

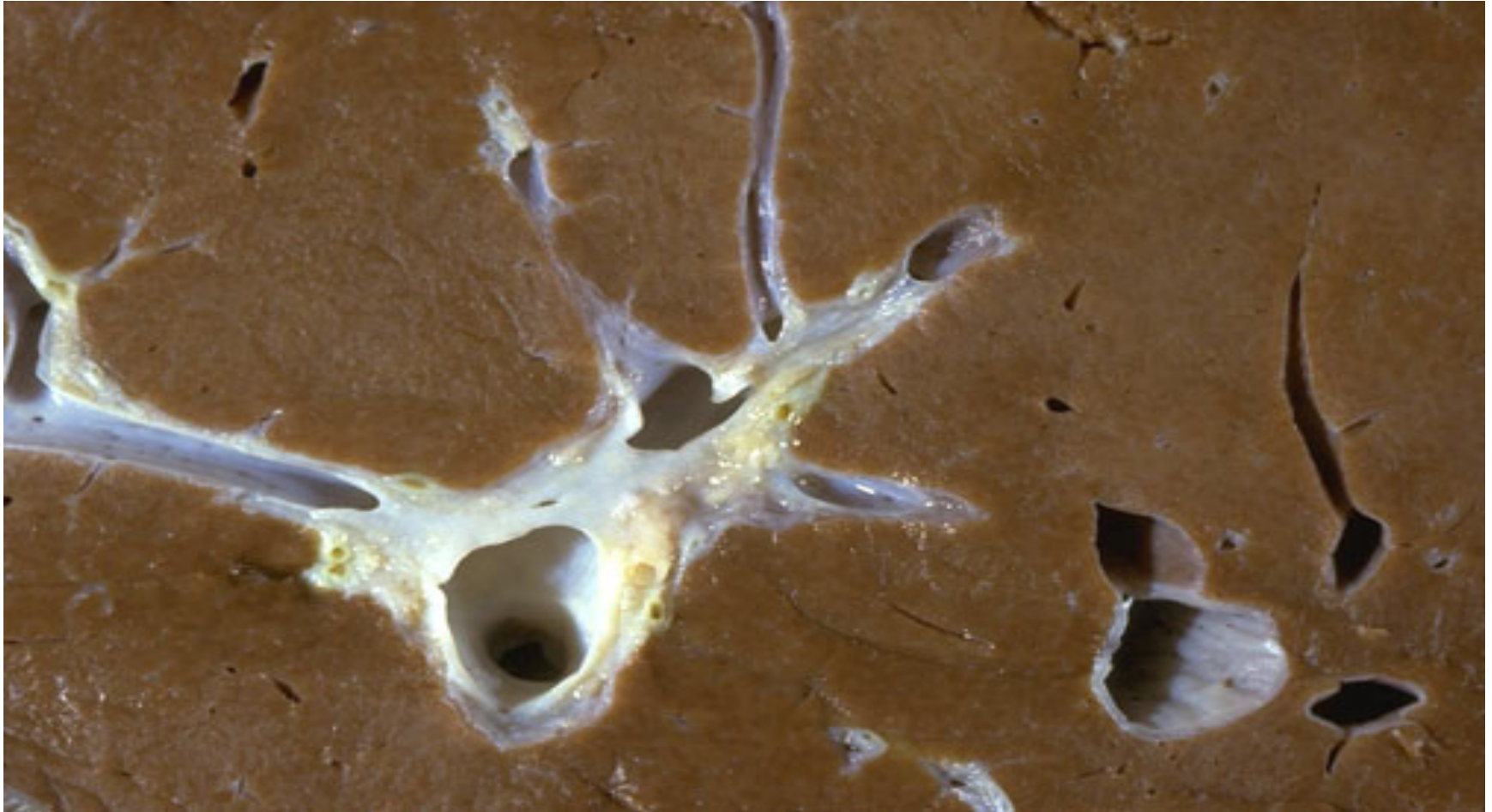Surfaces and Bed of Liver Anterior View



Rt

Cut surface of a Normal Liver

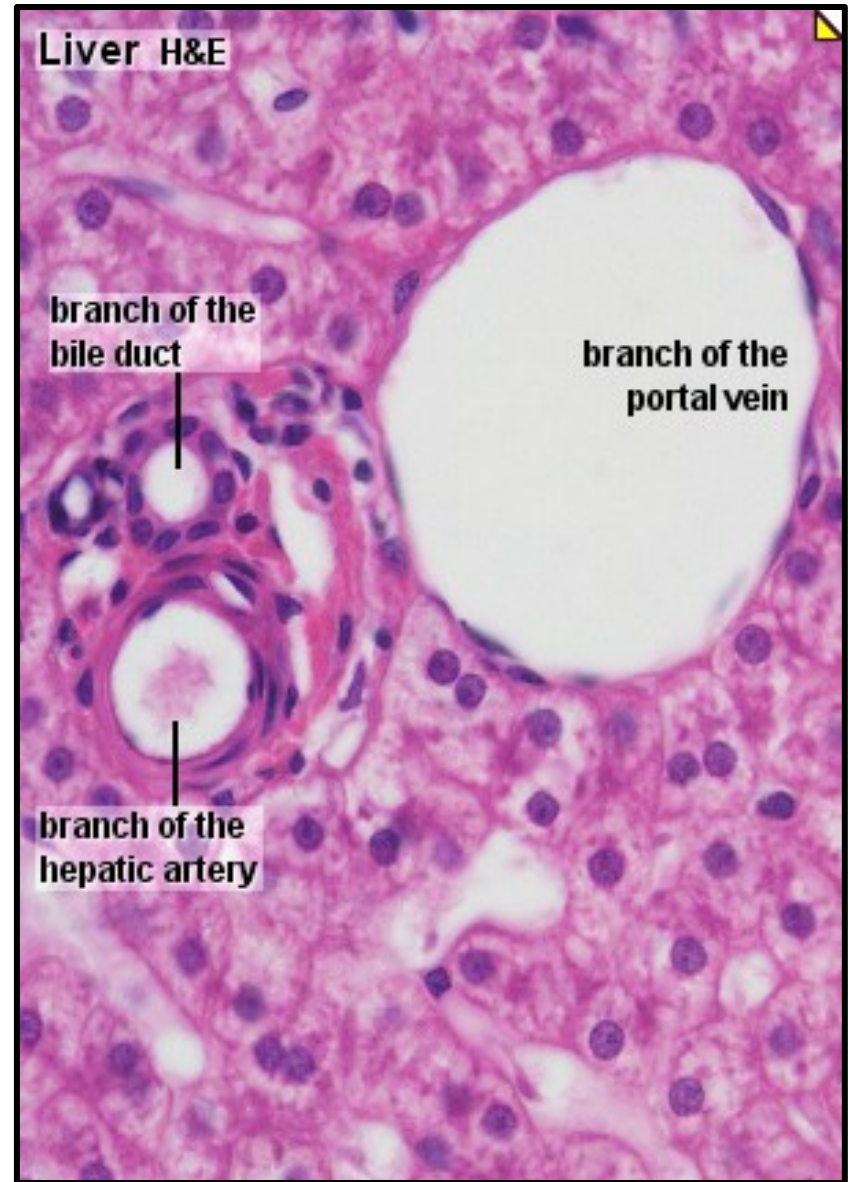
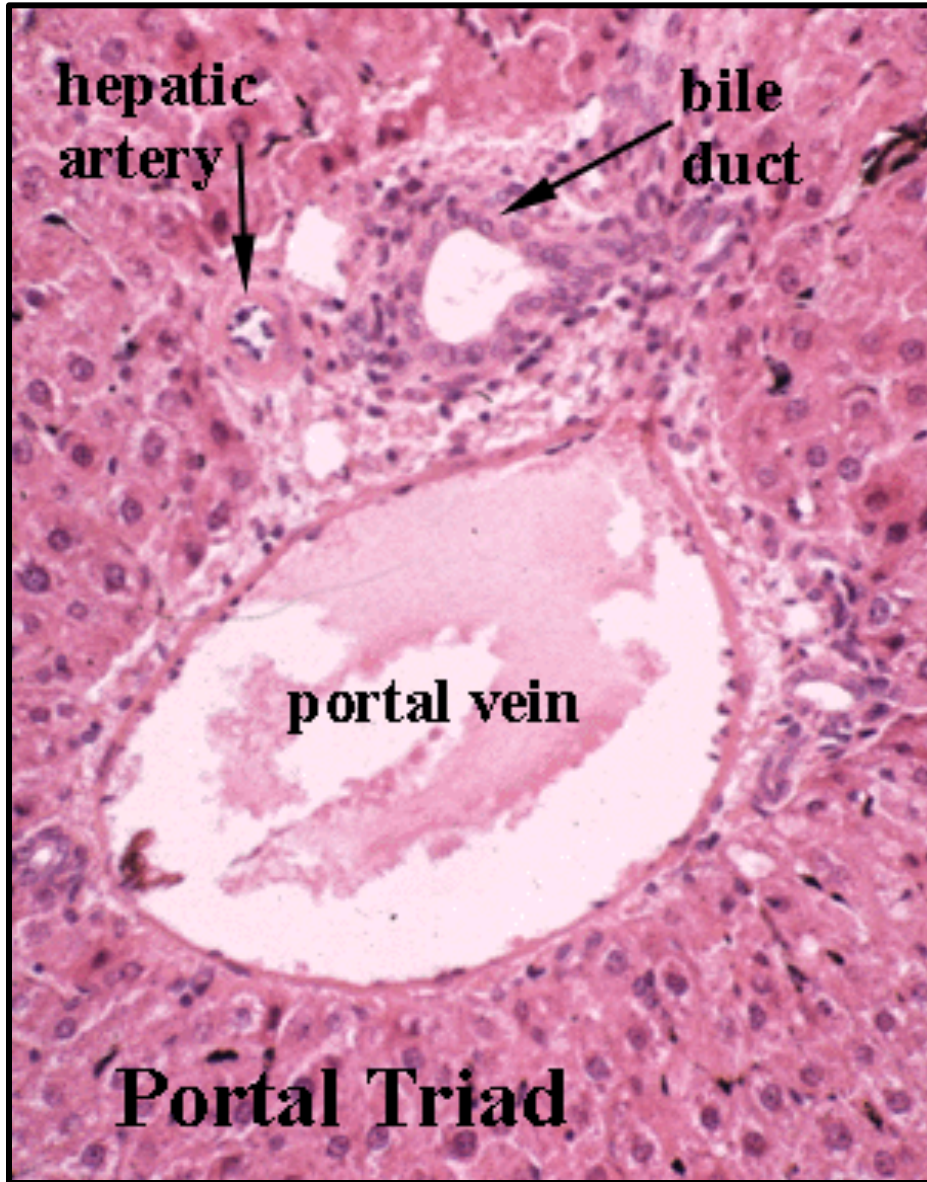
Lt



The cut surface of a normal liver has a brown color. Near the hilum here, note the portal vein carrying blood to the liver, which branches at center right, with accompanying hepatic artery and bile ducts.

At the lower left is a branch of hepatic vein draining blood from the liver to the inferior vena cava

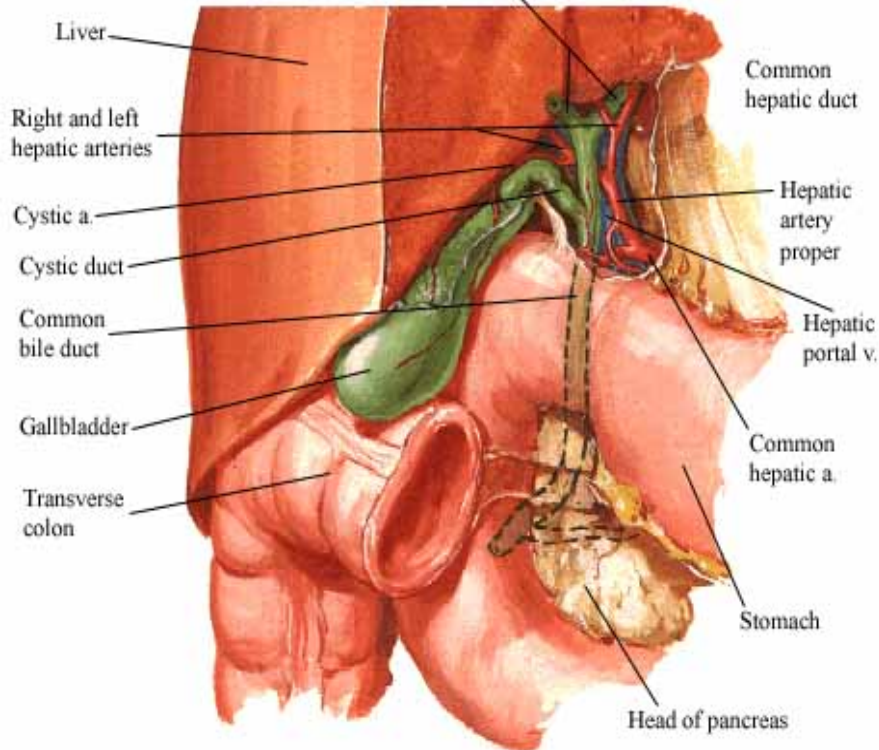
Histology of Normal Liver



Gall Bladder & Extrahepatic Bile Duct

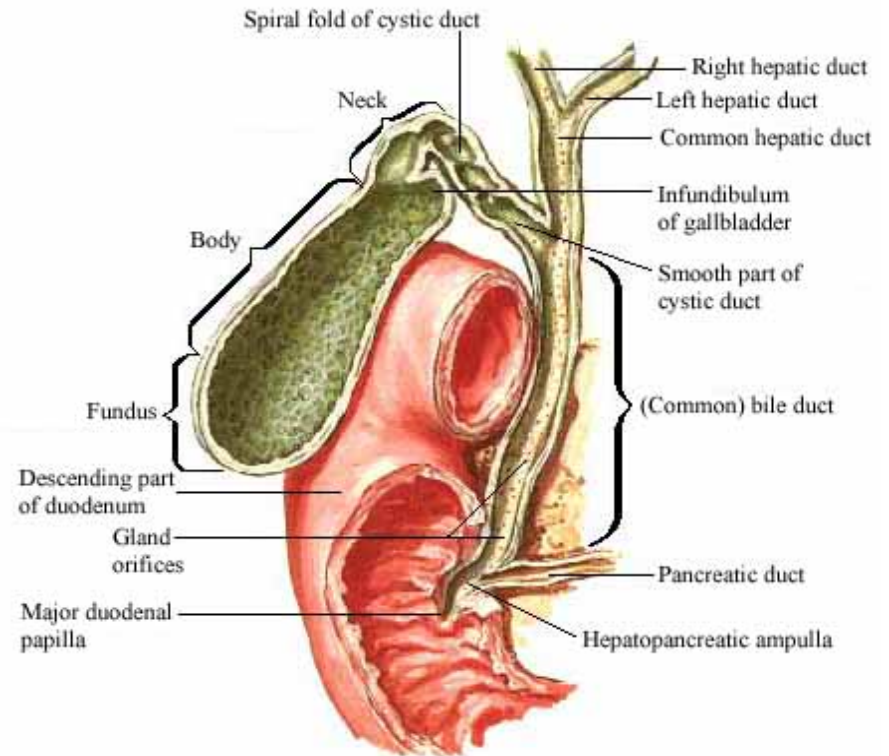
Gallbladder and Extrahepatic Bile Ducts

Right and left hepatic ducts

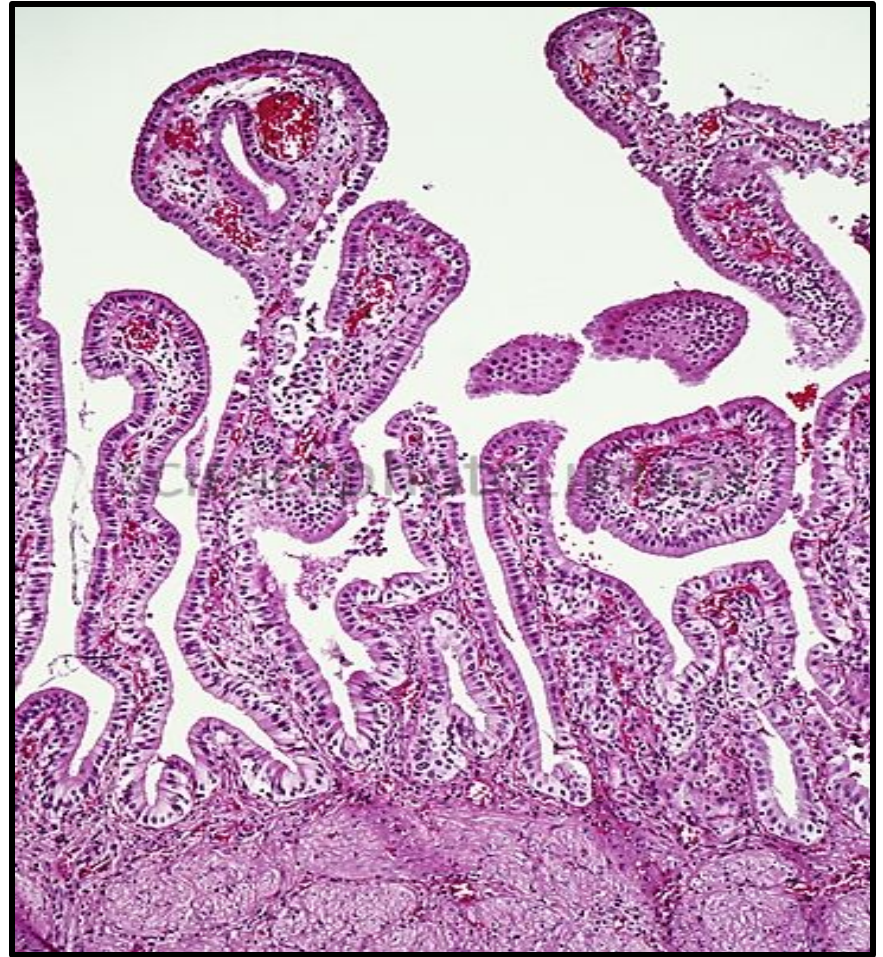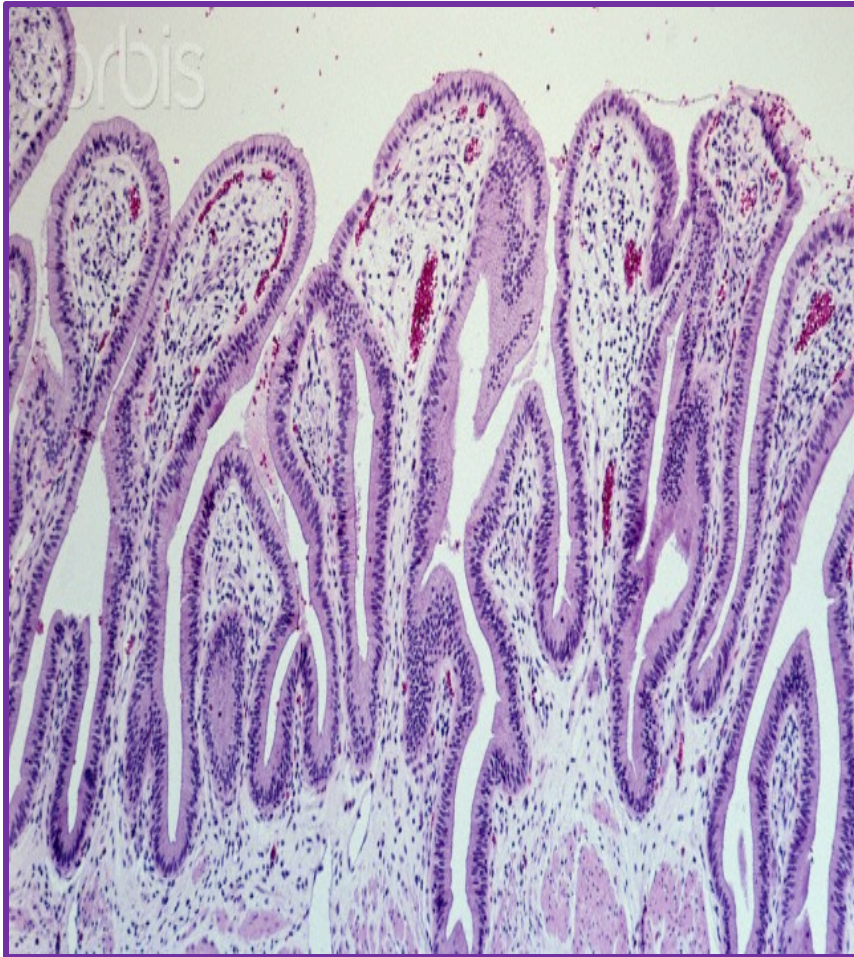


Gallbladder and Extrahepatic Bile Ducts

Sectioned

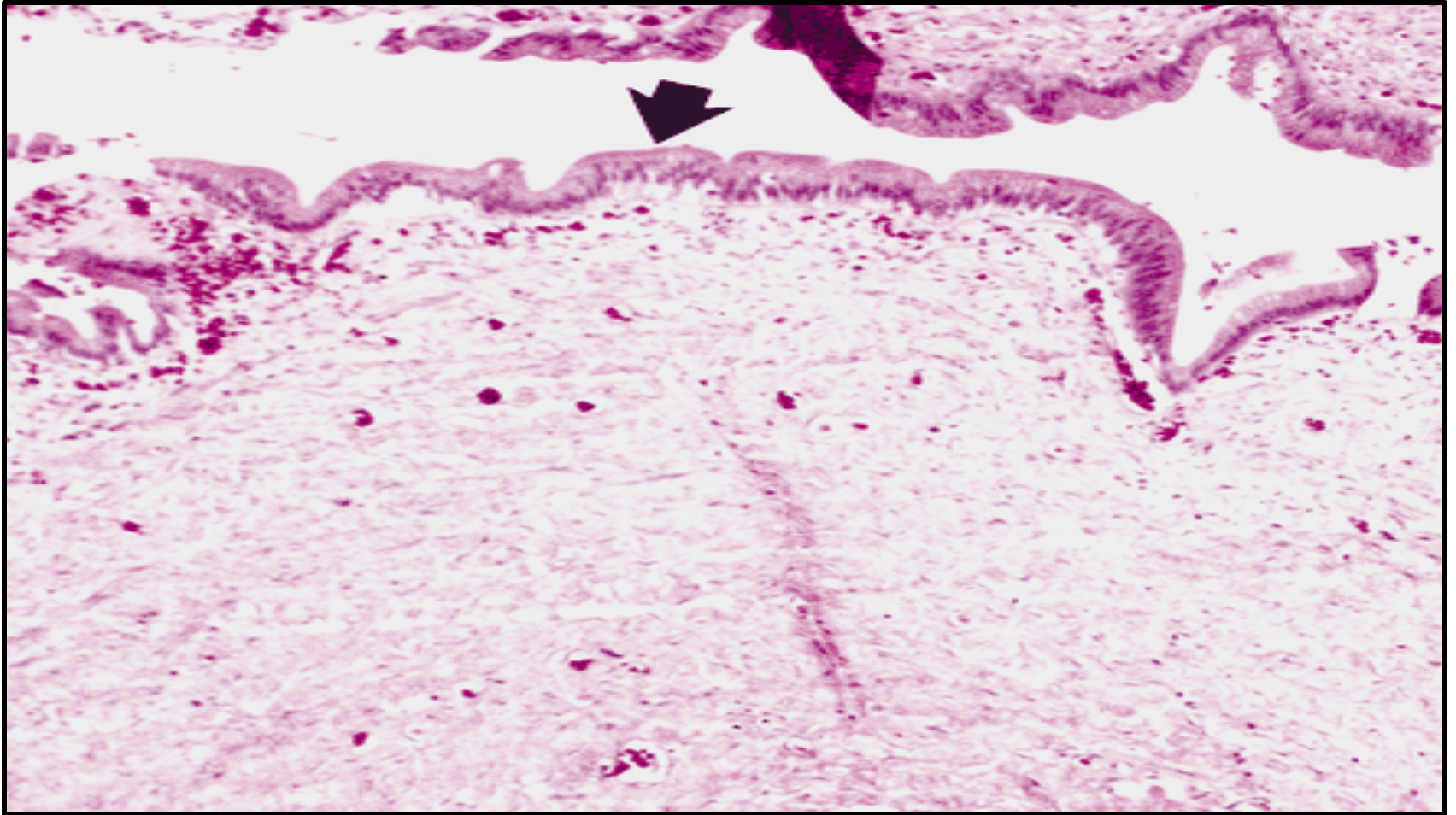


Histology of Gall Bladder



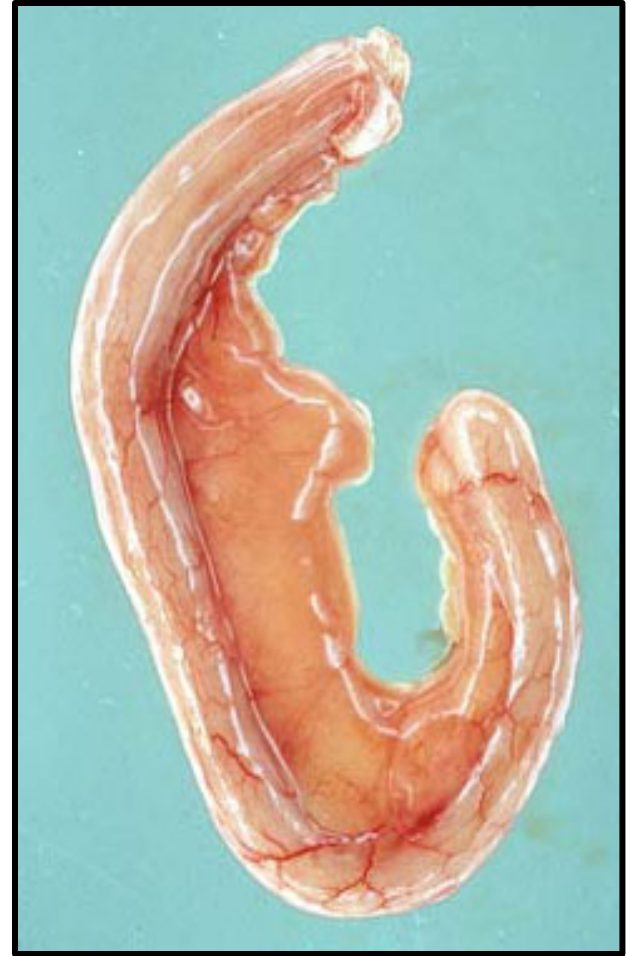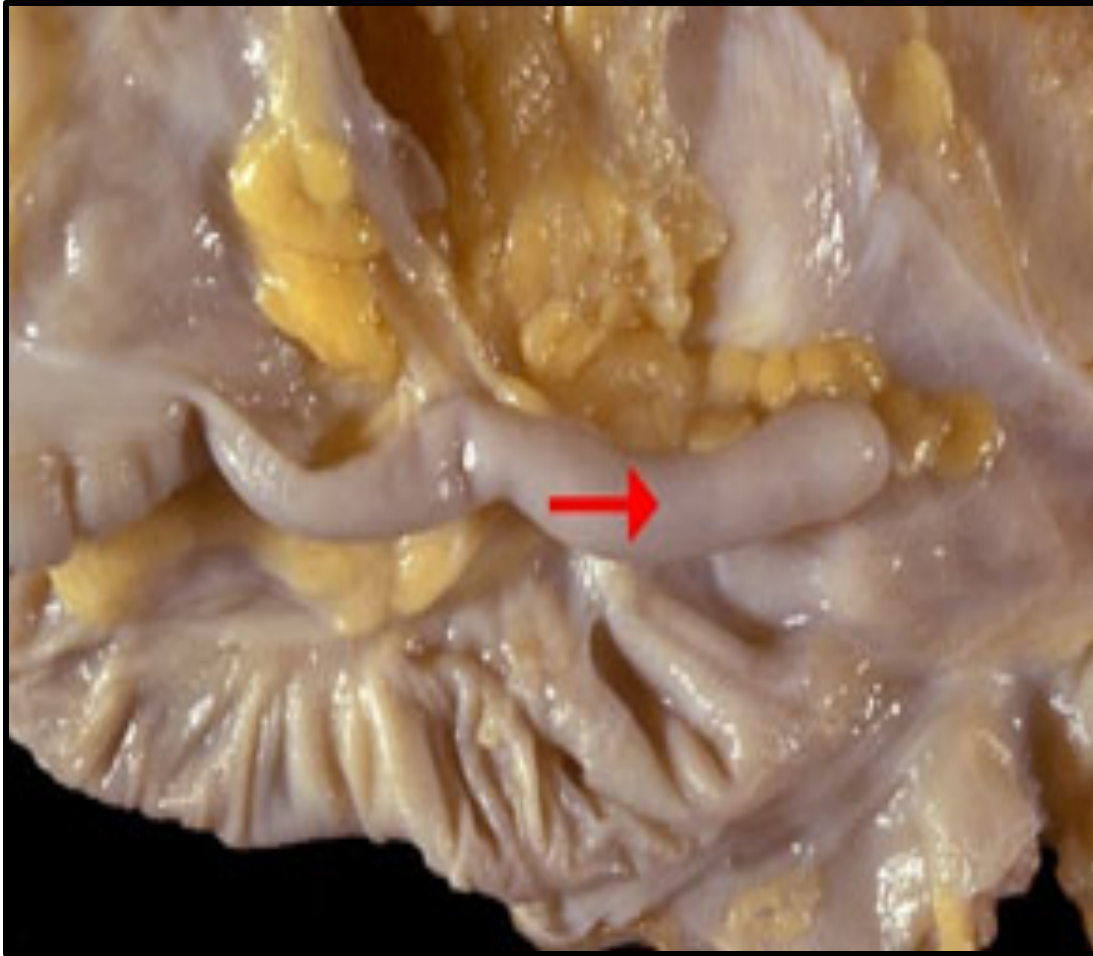The gallbladder is a distensible sac and, when not distended, its mucosa is thrown into many folds. The lumen of the gallbladder is lined with a high columnar epithelium. The connective tissue wall contains abundant elastic fibers and layers of smooth muscle which predominantly run obliquely

Histology of Extra Hepatic Bile Duct



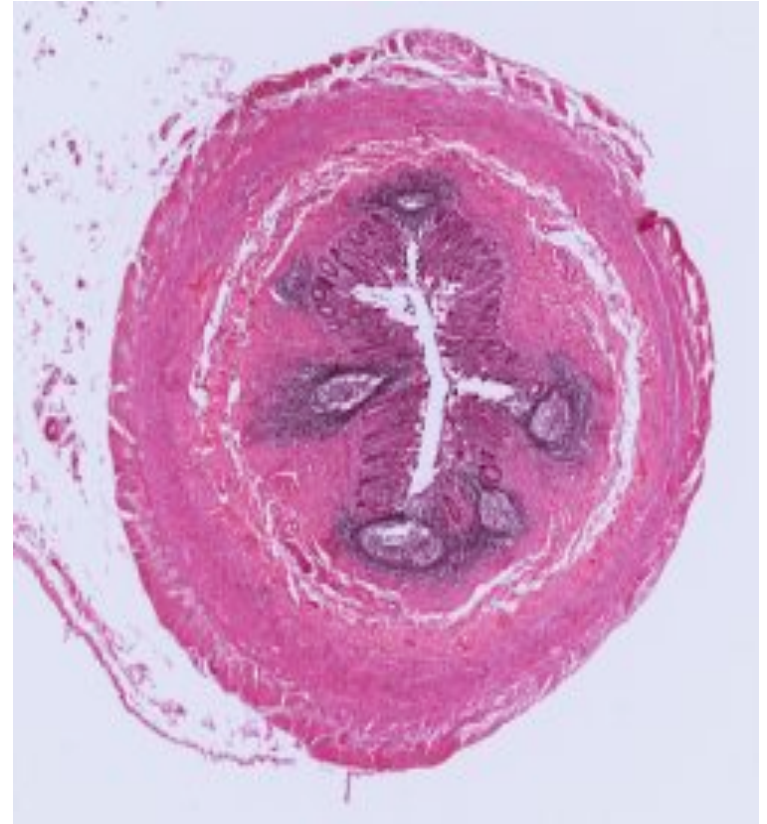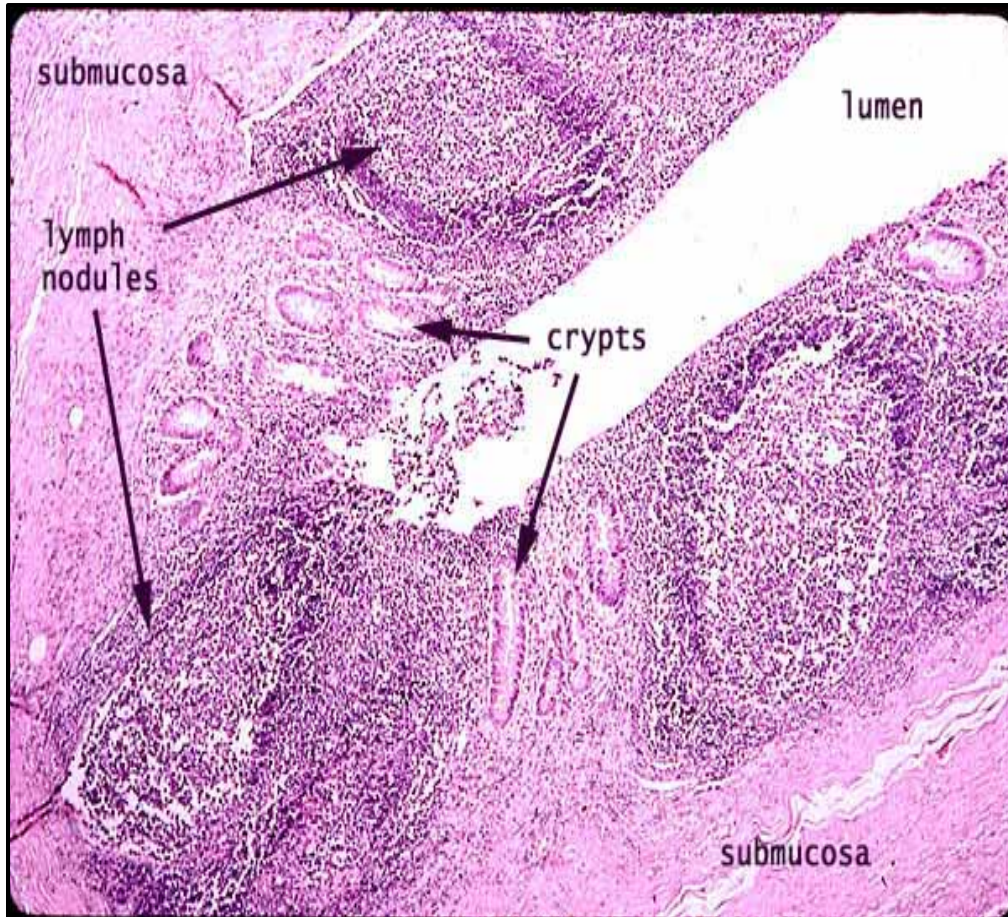
Normal histologic characteristics of the extra-hepatic bile duct. Photomicrograph (H&E stain) shows the epithelium as a single layer of columnar cells (arrow) with an underlying dense connective tissue wall.

Normal Appendix - Gross



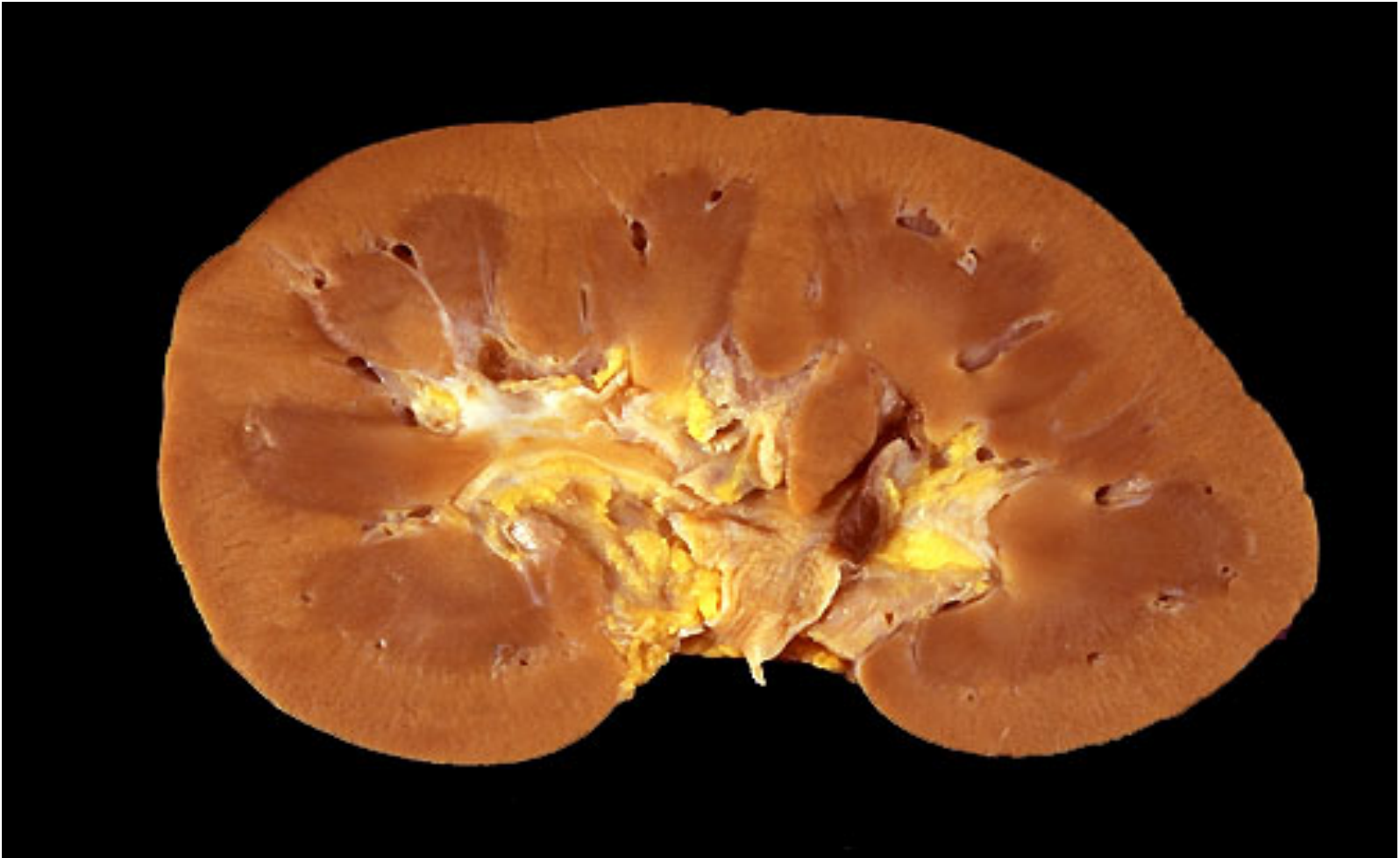The appendix (arrow) is a coiled 8-12 cm tube attached to the caecum, usually located in the right lower abdominal quadrant.

Histology of the appendix



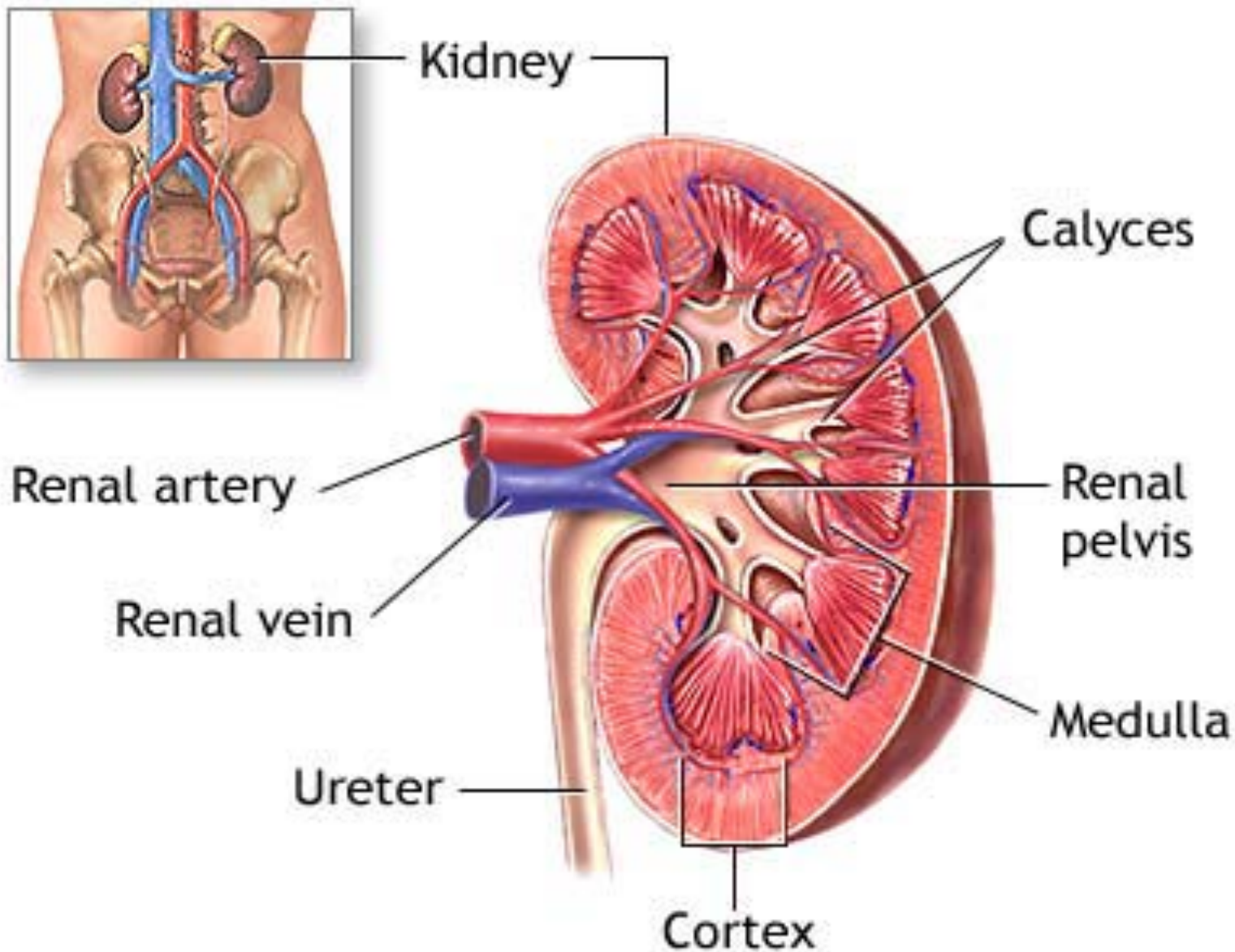
The mucosa of the appendix, like that of the colon, is characterized by straight crypts with no villi. It is also characterized by an abundance of lymphoid tissue, including numerous well-organized lymph nodules.

Normal Kidney - Gross

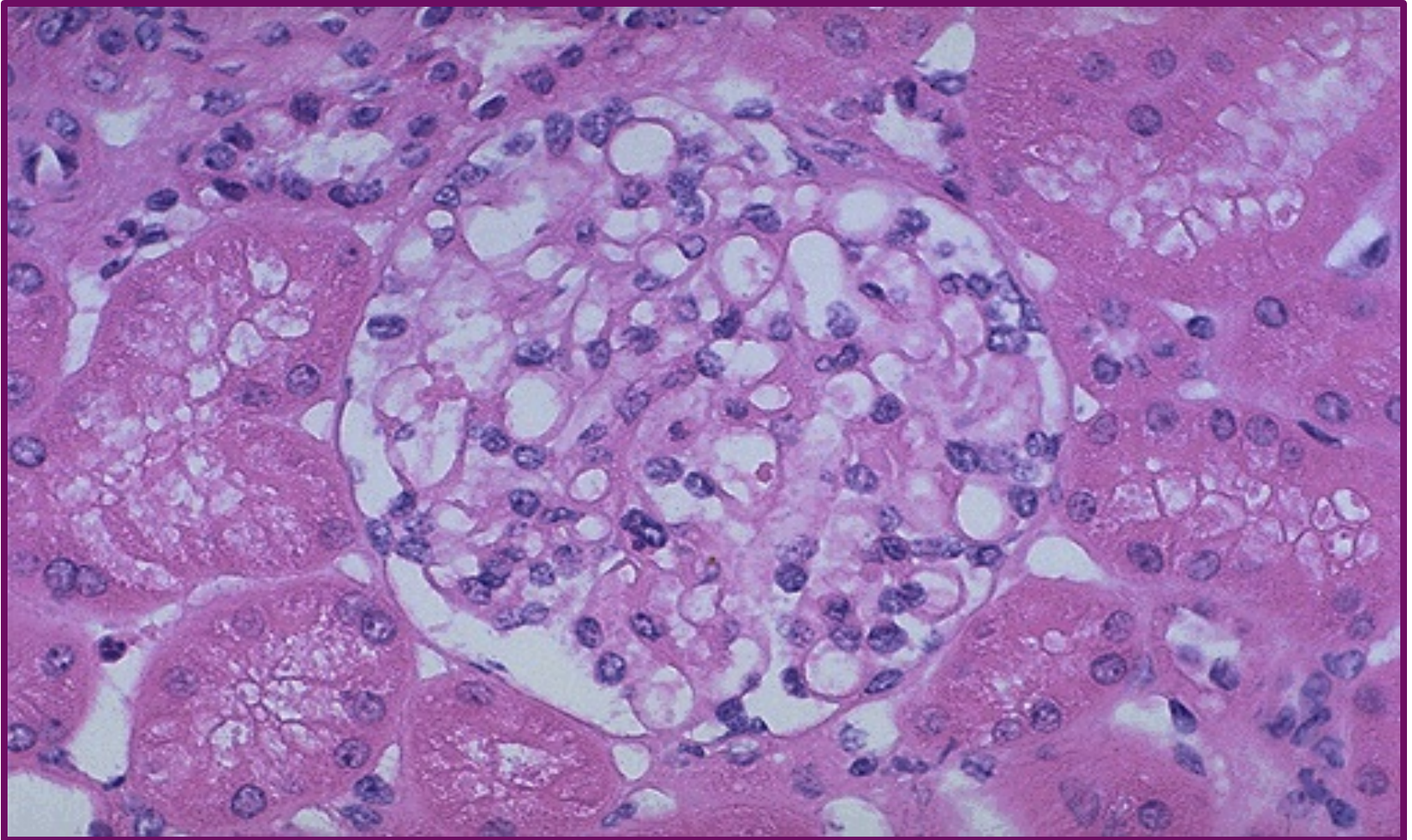


In cross section, this normal adult kidney demonstrates the lighter outer cortex and the darker medulla, with the renal pyramids into which the collecting ducts coalesce and drain into the calyces and central pelvis.

Anatomy of the Kidney

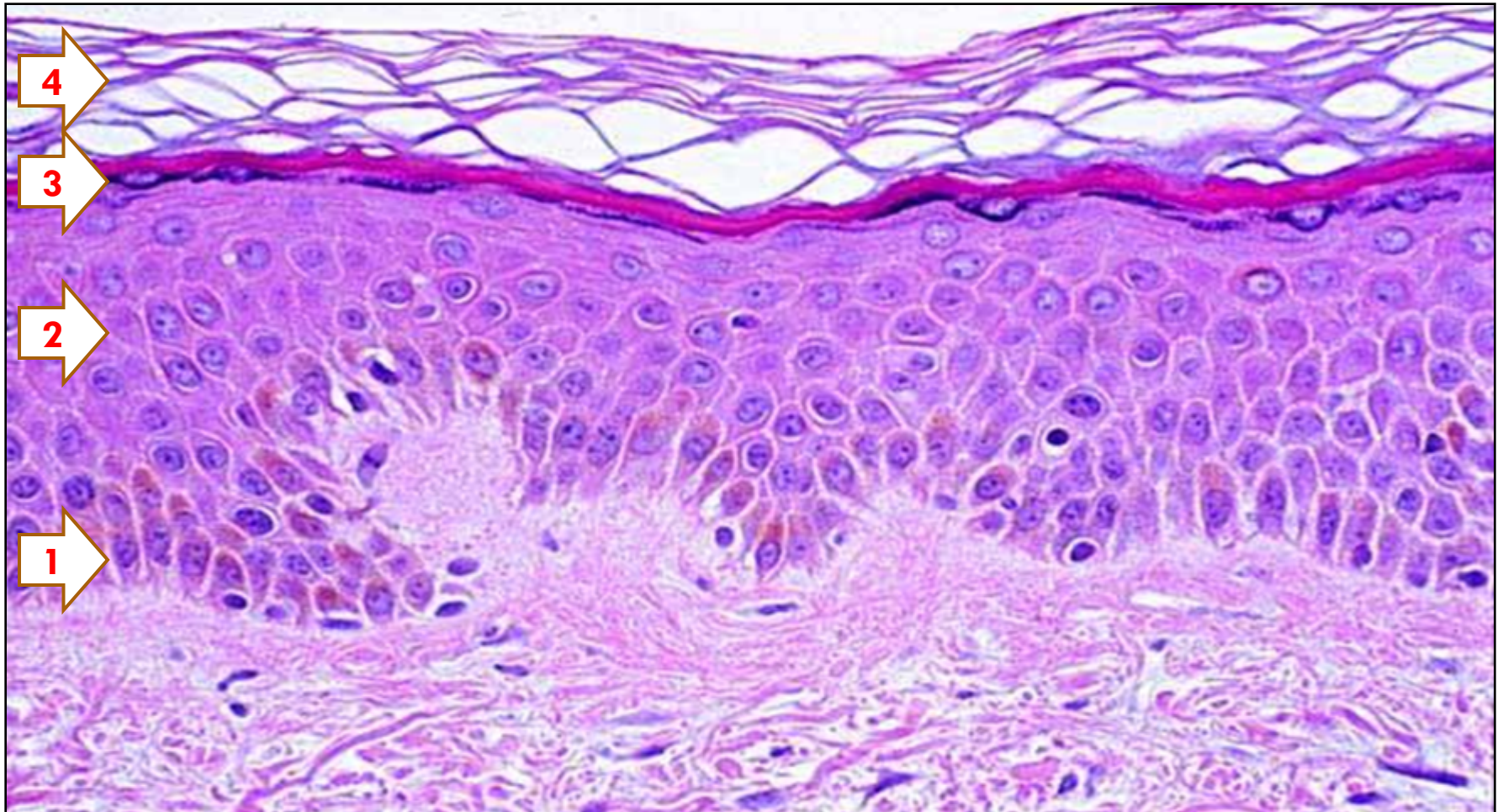


Renal Corpuscle – Normal Histology



Normal glomerulus by light microscopy. The glomerular capillary loops are thin and delicate. Endothelial and mesangial cells are normal in number. The surrounding tubules are normal

Histology of the SKIN

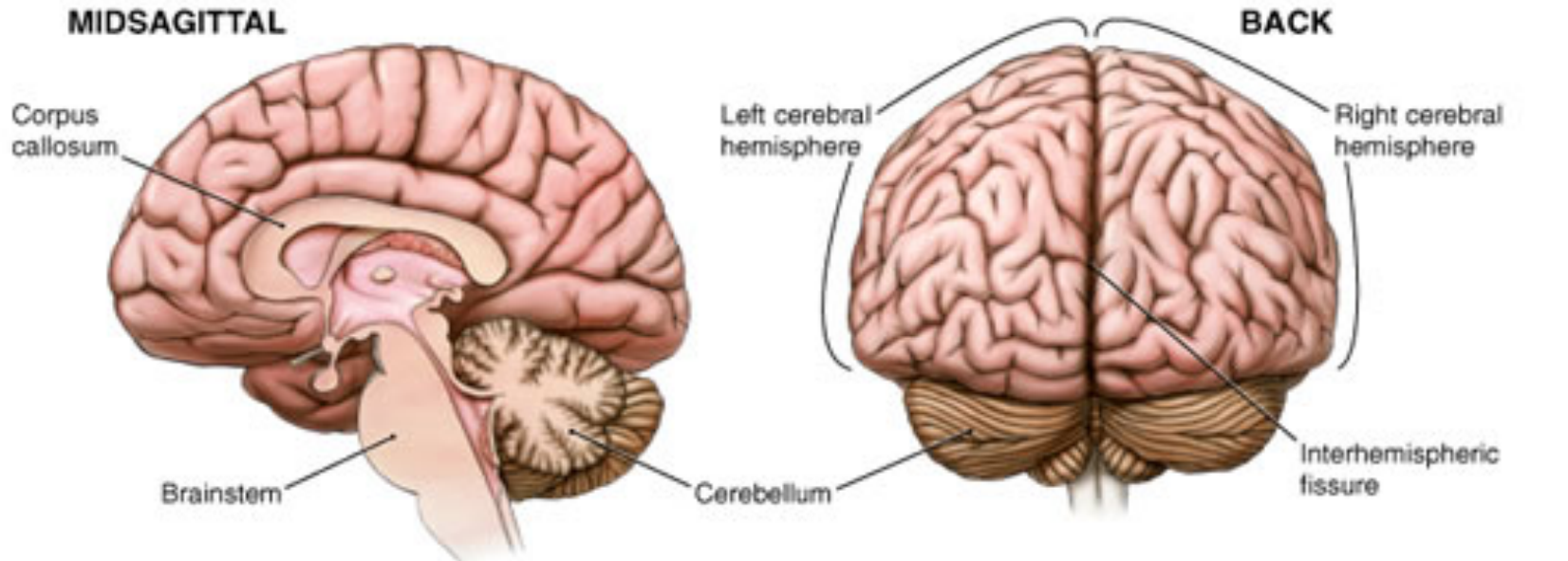
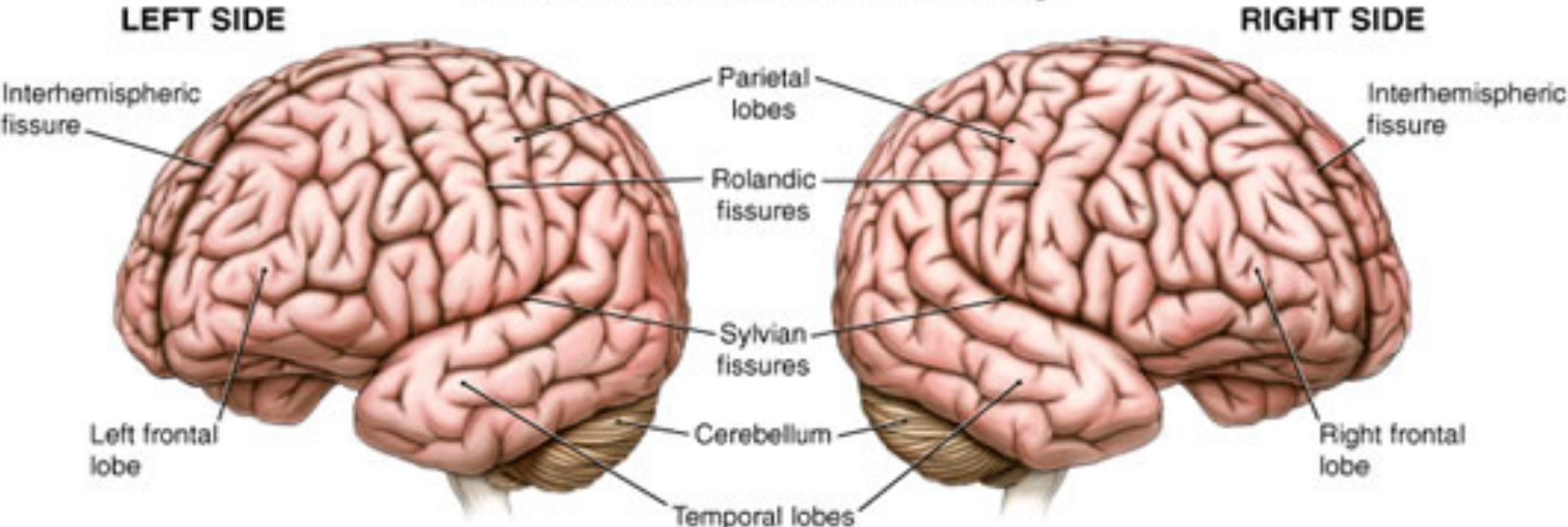


Normal Skin. Epidermis has 4 layers :

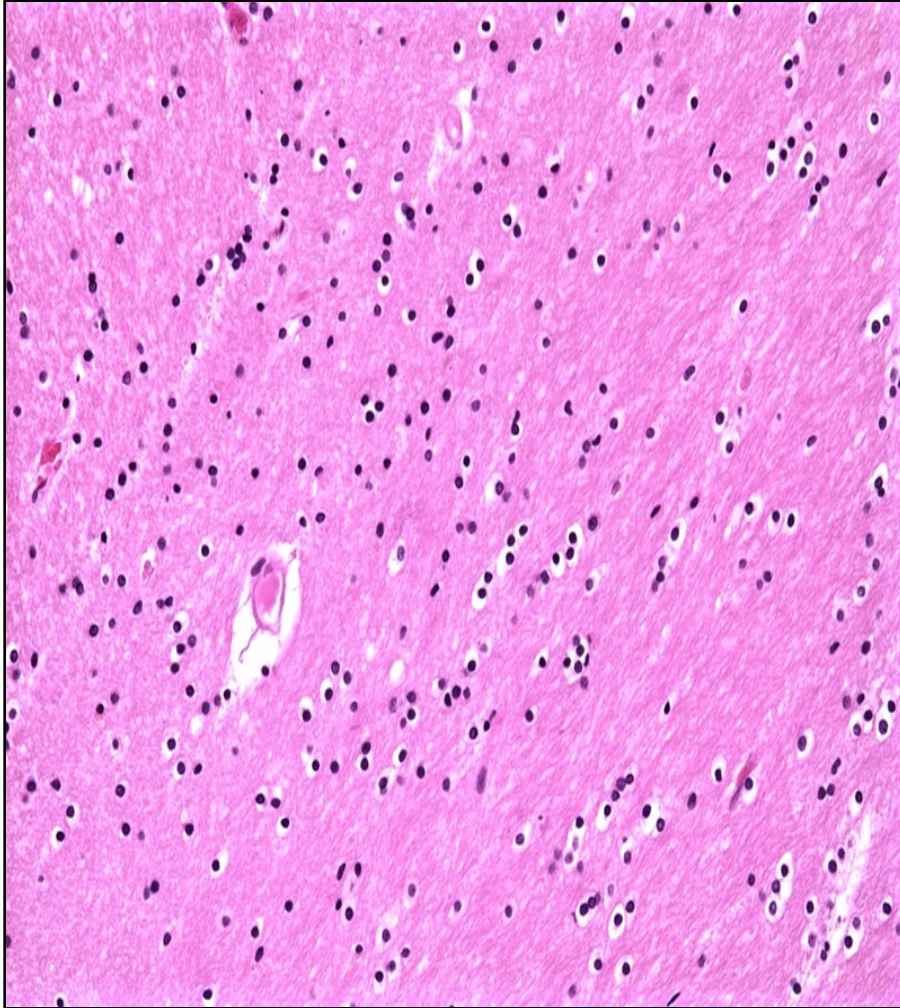
- 1. Stratum basale**
- 2. Stratum spinosum (cells gain more cytoplasm)**
- 3. Stratum granulosum**
- 4. Stratum corneum (anucleate layer)**

Anatomy of the Brain

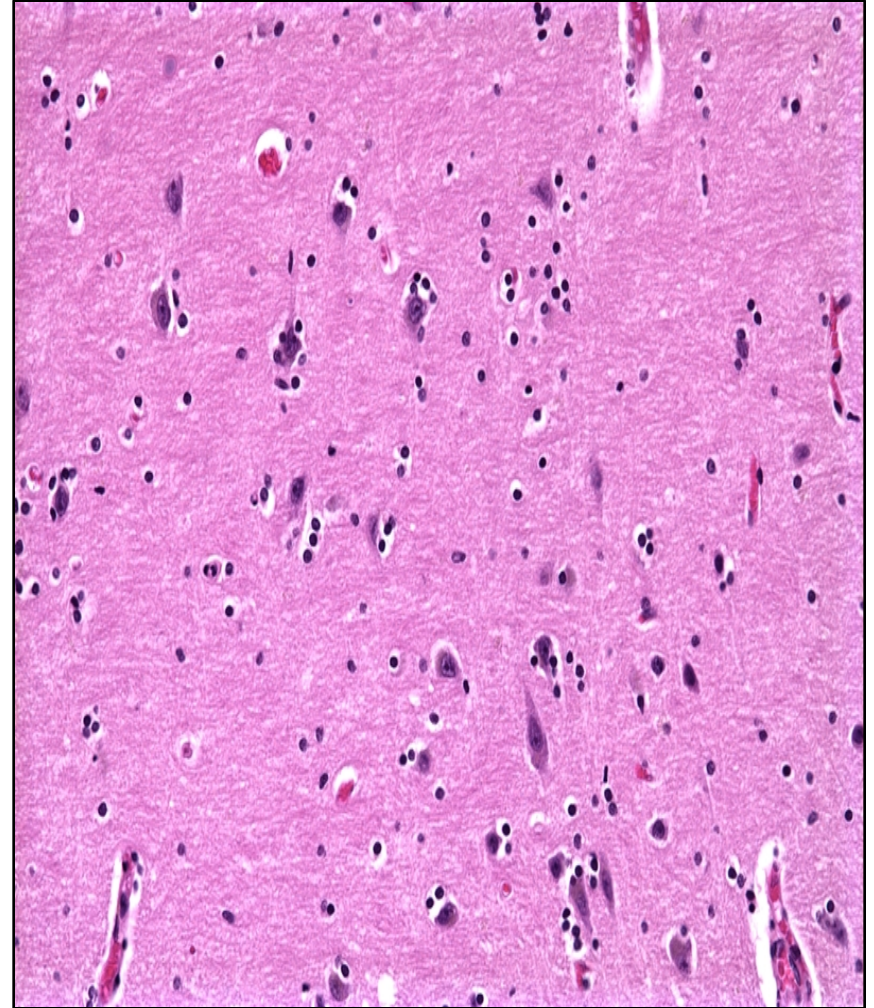
Brain Surface Anatomy



Histology of the Brain

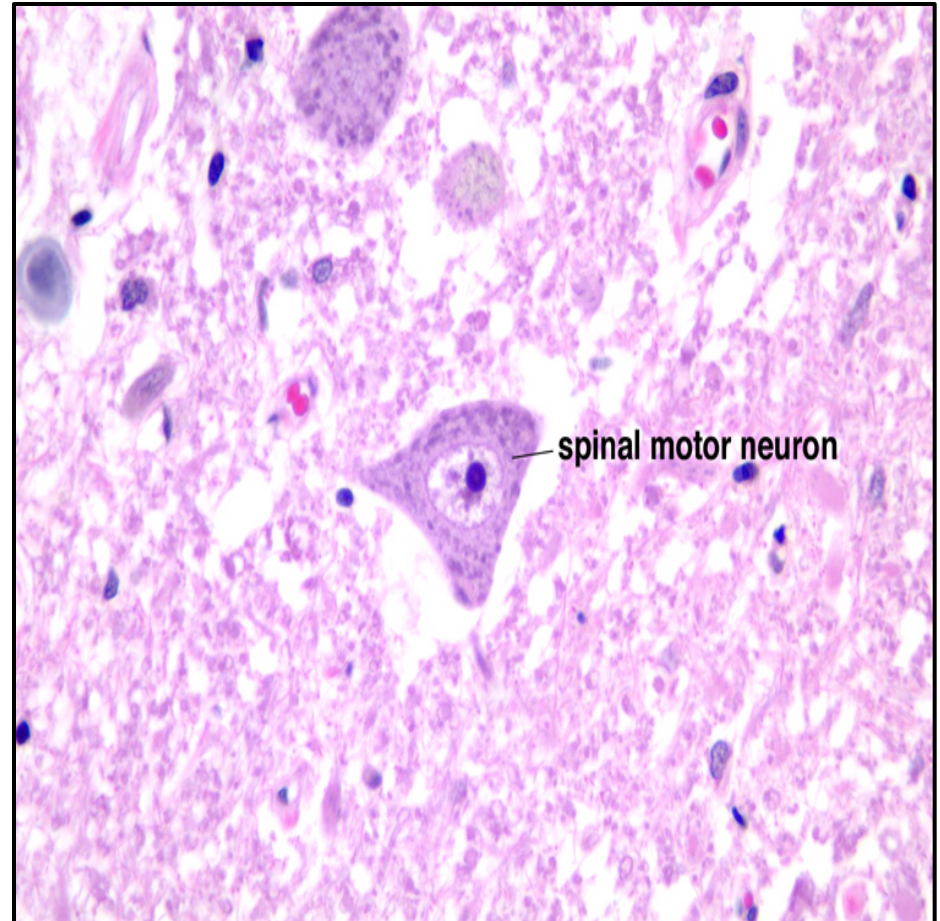
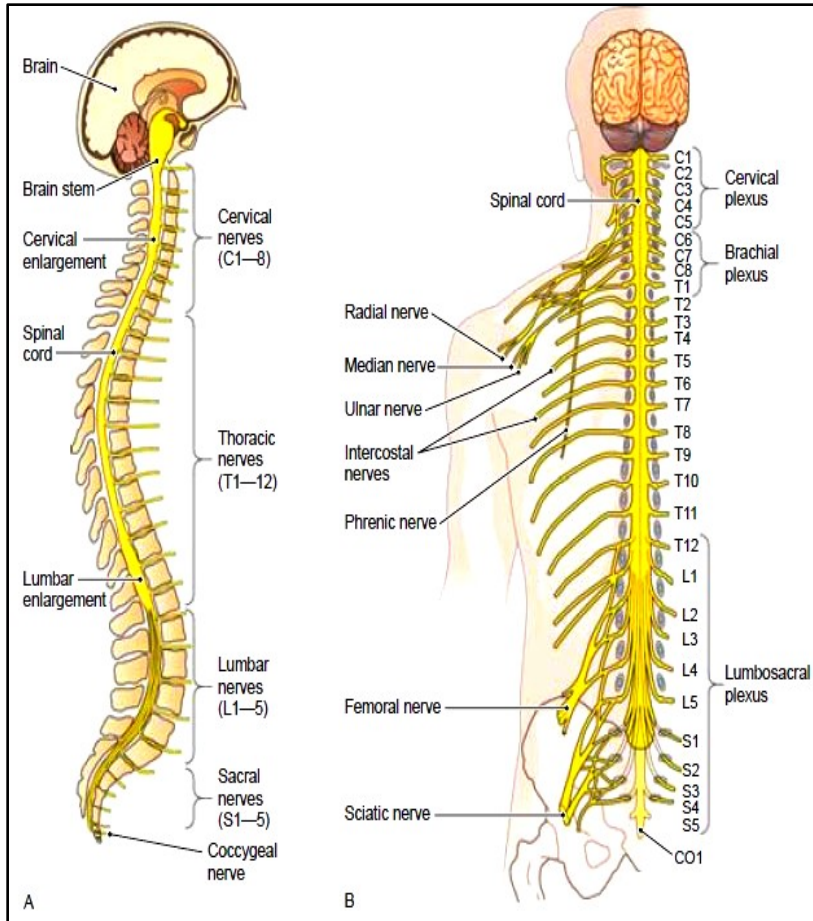


Normal white matter: 85% of the cells are oligodendrocytes. Note some tendency for the oligodendrocytes to line up in rows



Cerebral cortex: some degree of satellitosis (i.e., oligodendrocytes surrounding neurons) is a normal finding

Spinal Cord Nerve Branches and Histology



Spinal motor neuron, with its prominent nucleolus in the nucleus and the basophilic tigroid appearance of its cytoplasm, which is due to the presence of abundant ribosomes

CELL INJURY

Gross and Histopathology

Cell injury

□ Pictures of:

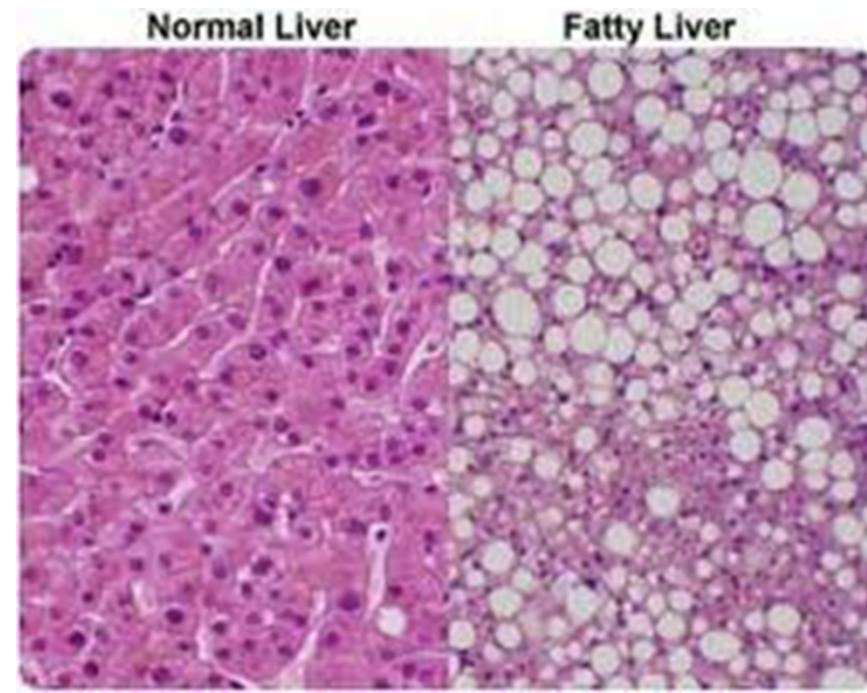
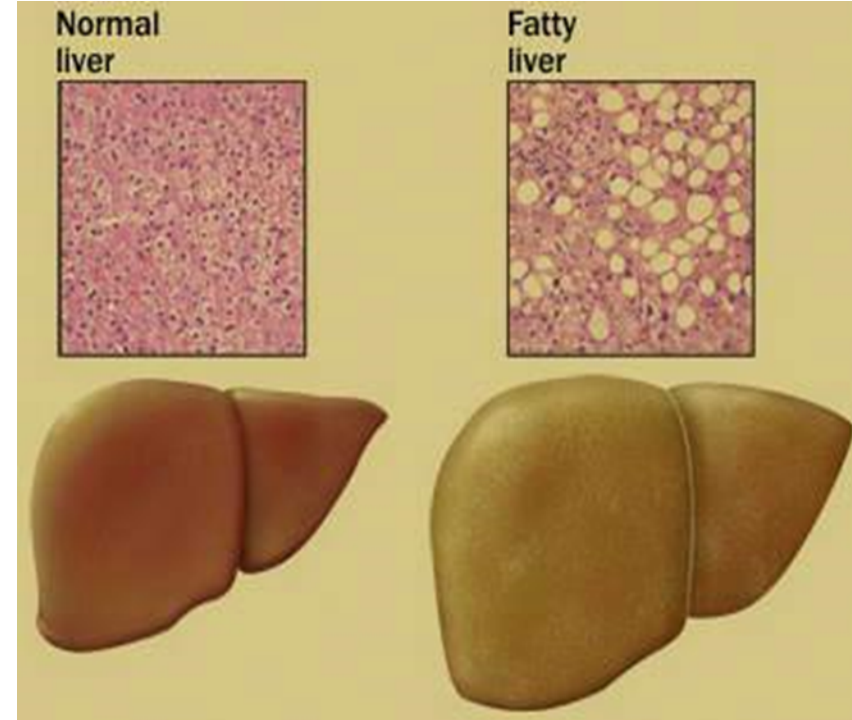
1. Fatty change of the liver.
2. Coagulative necrosis in an infarcted kidney, spleen and myocardium.
3. Liquefactive necrosis
4. Caseous necrosis
5. Fibrinoid necrosis
6. Fat necrosis
7. Dystrophic calcification in the aorta, stomach and skin.
8. Atrophy of brain and testis
9. Left ventricular hypertrophy
10. Hyperplasia of the prostate.
11. Squamous metaplasia.

1 - FATTY LIVER (STEATOSIS)

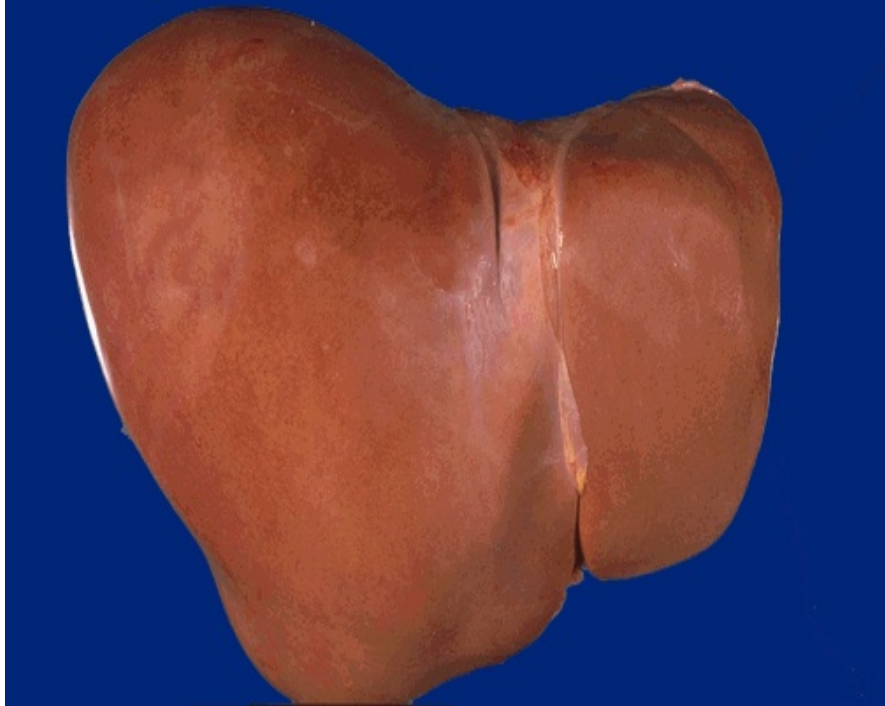Steatosis (Fatty Change)

Morphology of Steatosis in liver:

- **Gross:** In mild cases liver looks normal. In severe cases liver is enlarged, yellow and greasy.
- **Light microscopy:** clear vacuoles in the cytoplasm displacing the nucleus to the periphery of the cell. Occasionally, cells rupture, and the fat globules merge, producing a so-called fatty cysts. The lipid stains orange-red with Sudan IV or Oil Red-O stains.



Normal Liver & Cut Section of Fatty Liver

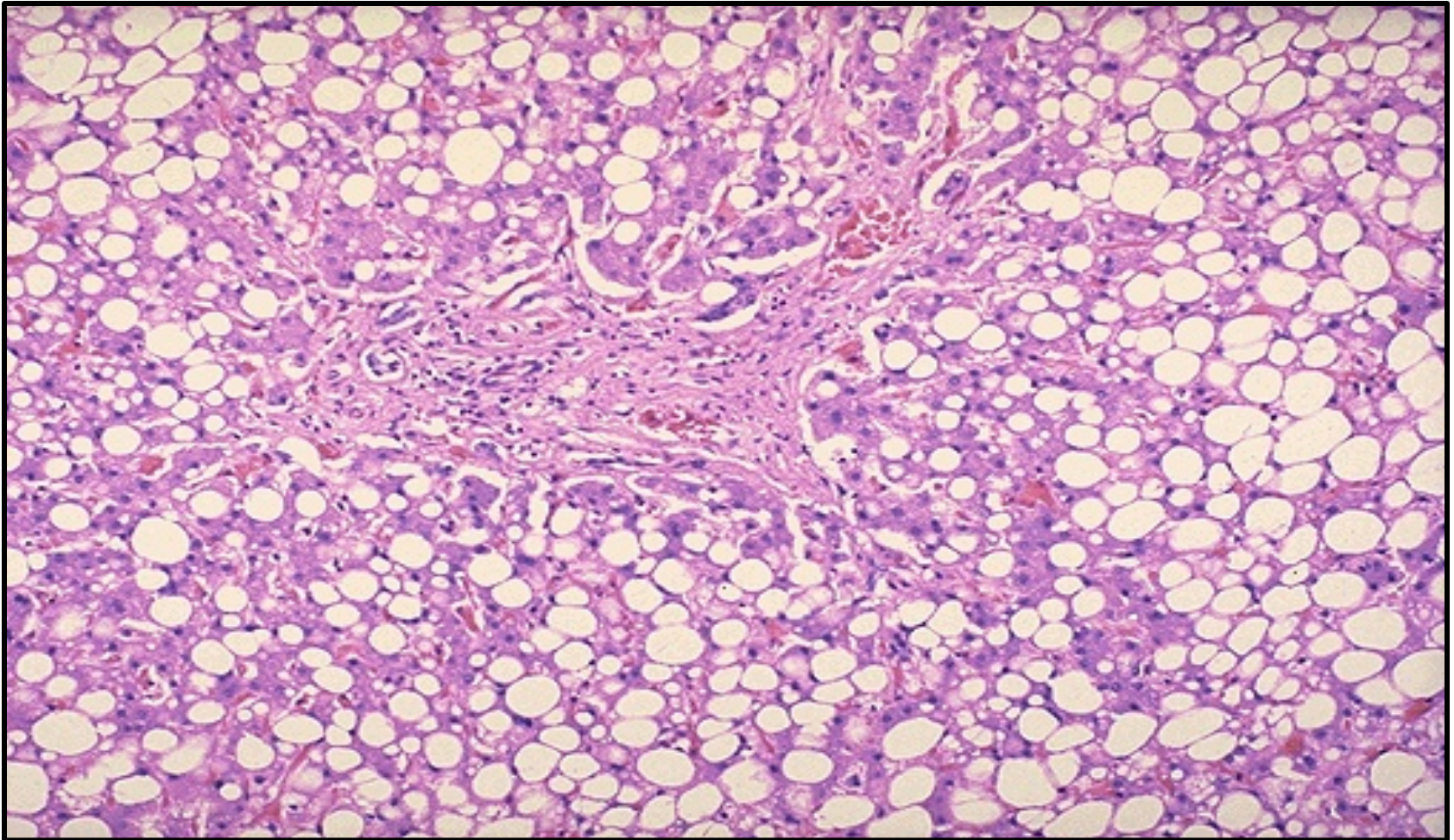


Normal Liver : This is the external surface of a normal liver. The color is brown and the surface is smooth



Steatosis : This liver is slightly enlarged and has a pale yellow appearance, seen both on the capsule and cut surface

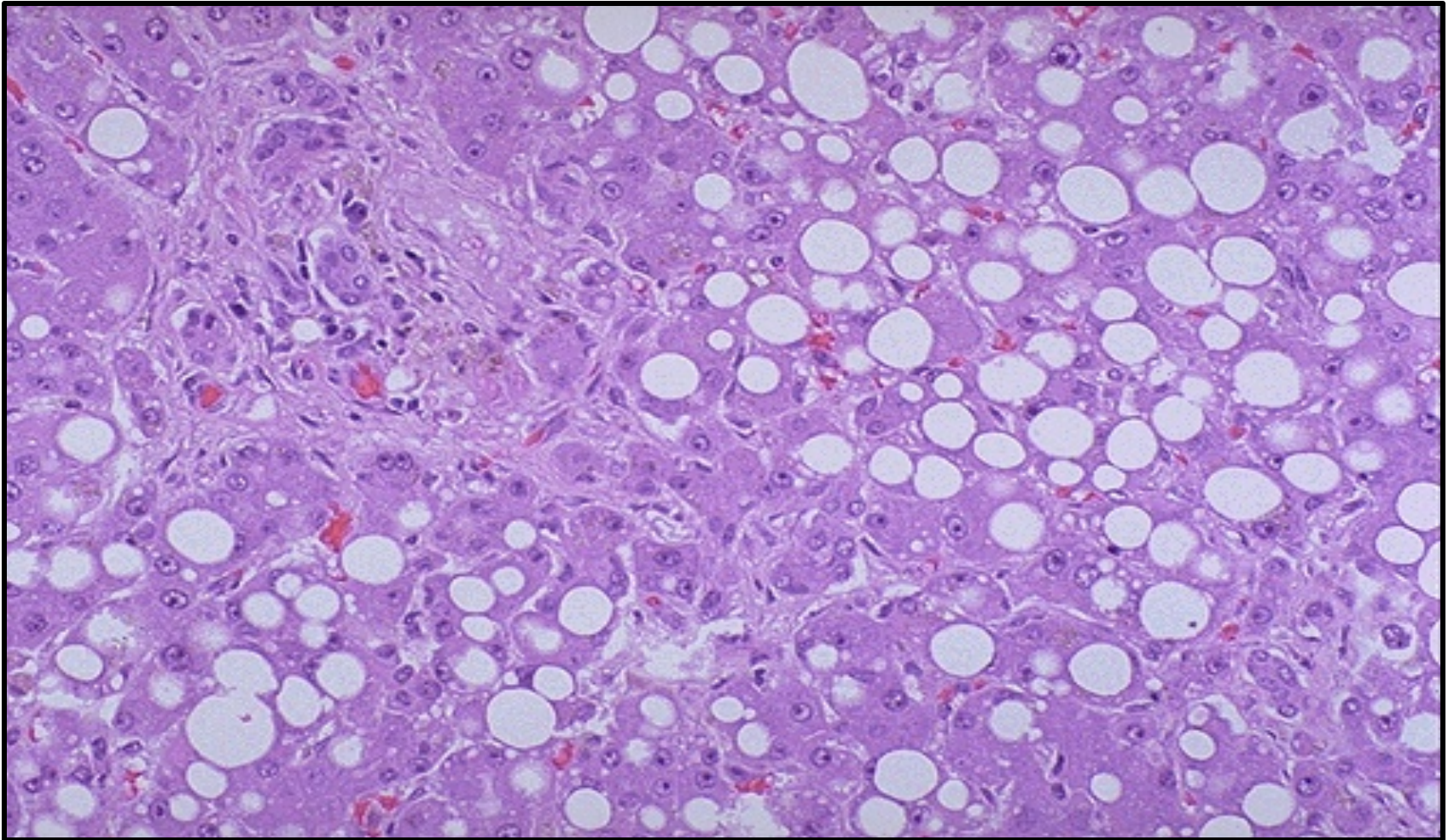
Steatosis – Fatty Liver



This is the histologic appearance of hepatic fatty change. The lipid accumulates in the hepatocytes as vacuoles. These vacuoles have a clear appearance with H&E staining.

The most common cause of fatty change in developed nations is alcoholism.

Steatosis – Fatty Liver

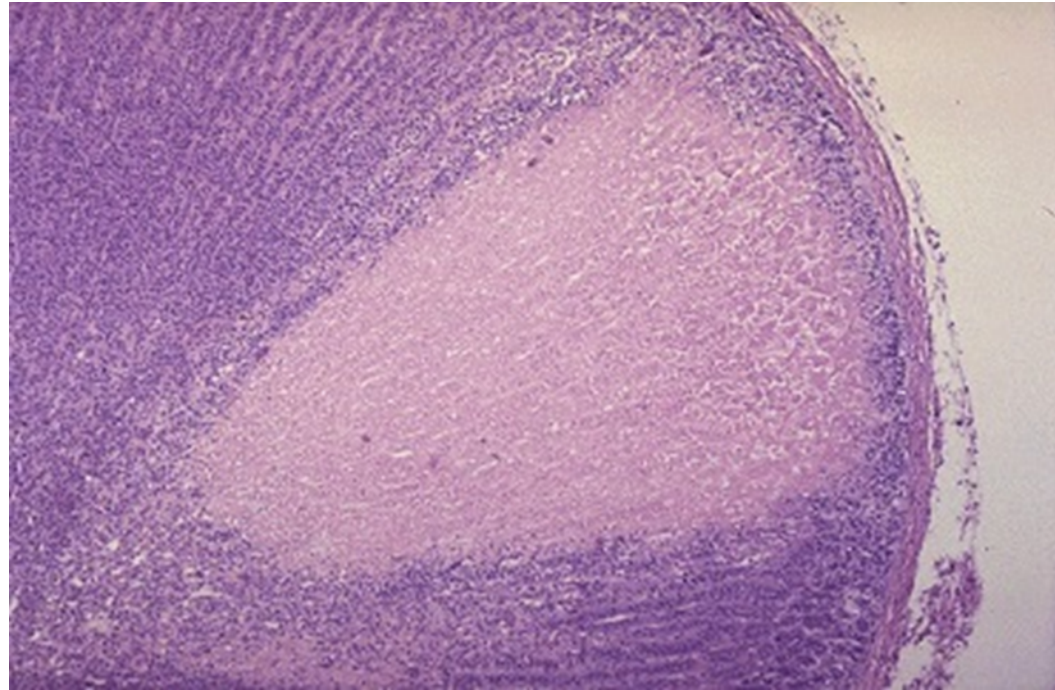
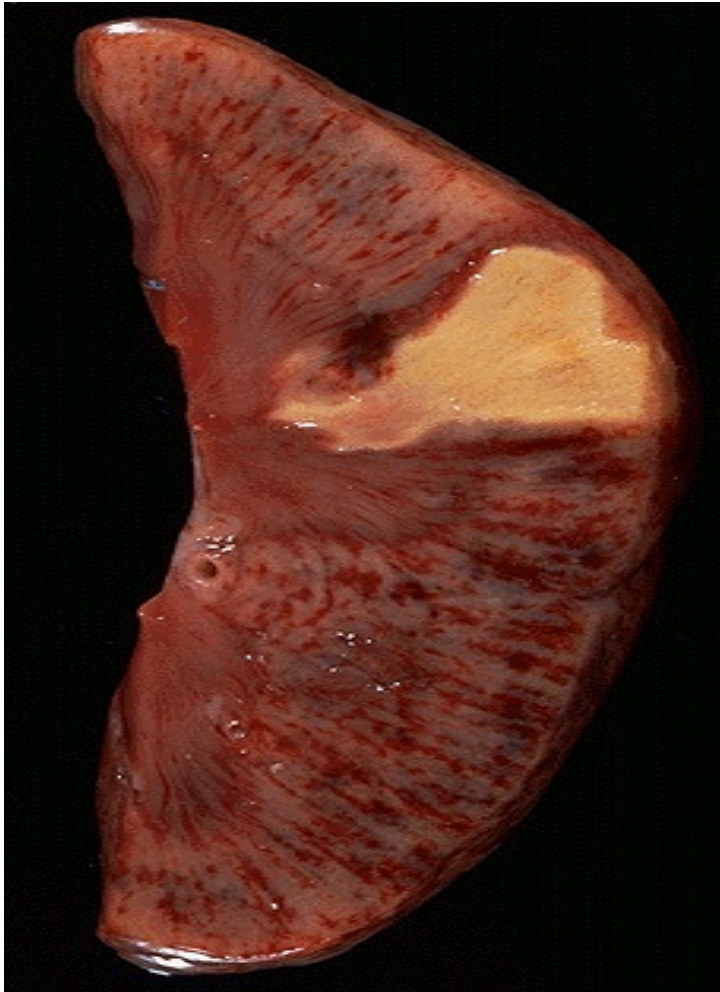

***Here are seen the lipid vacuoles within hepatocytes.
The lipid accumulates when lipoprotein transport is disrupted and/or when
fatty acids accumulate.***

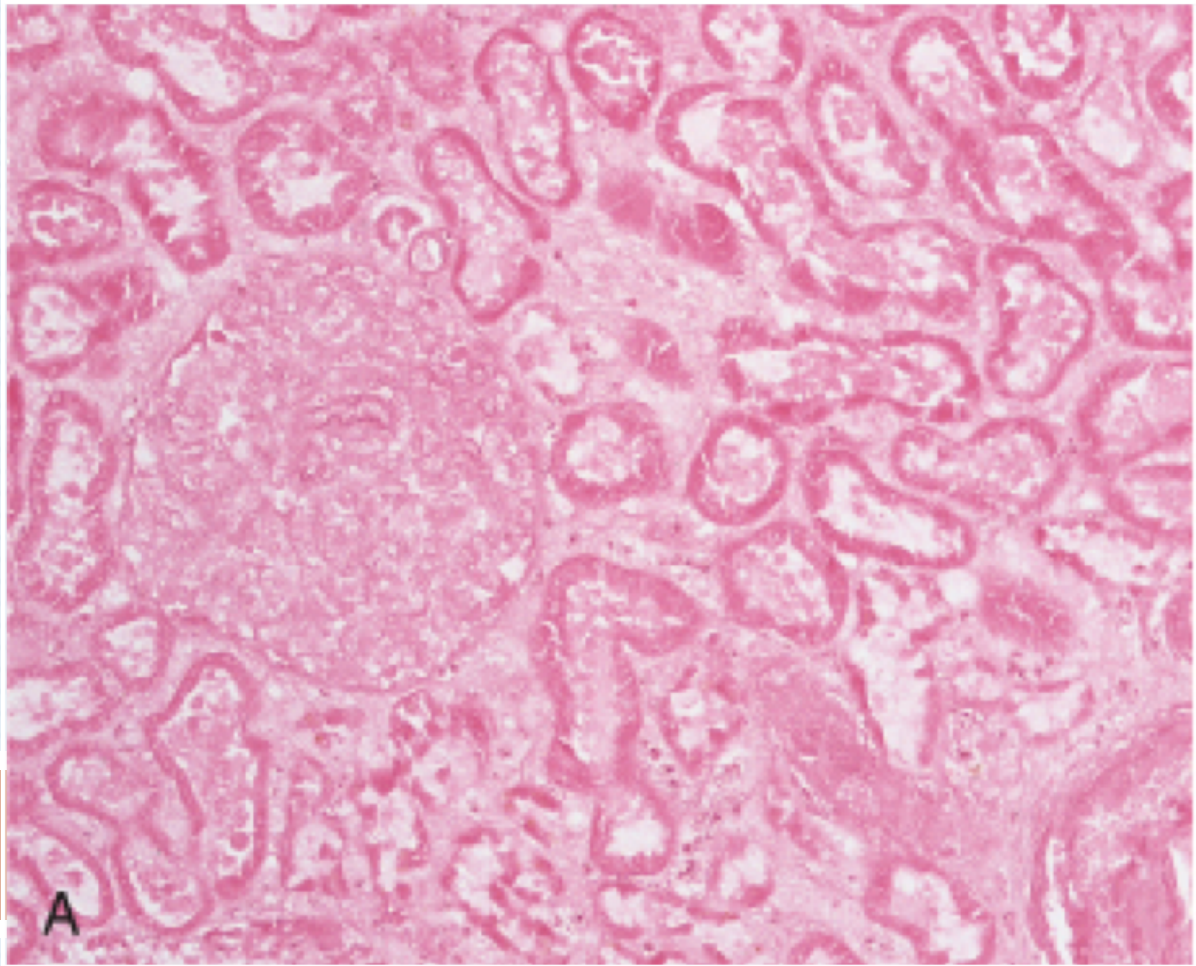
Alcohol is the most common cause

2- COAGULATIVE NECROSIS

Coagulative Necrosis of the Kidney



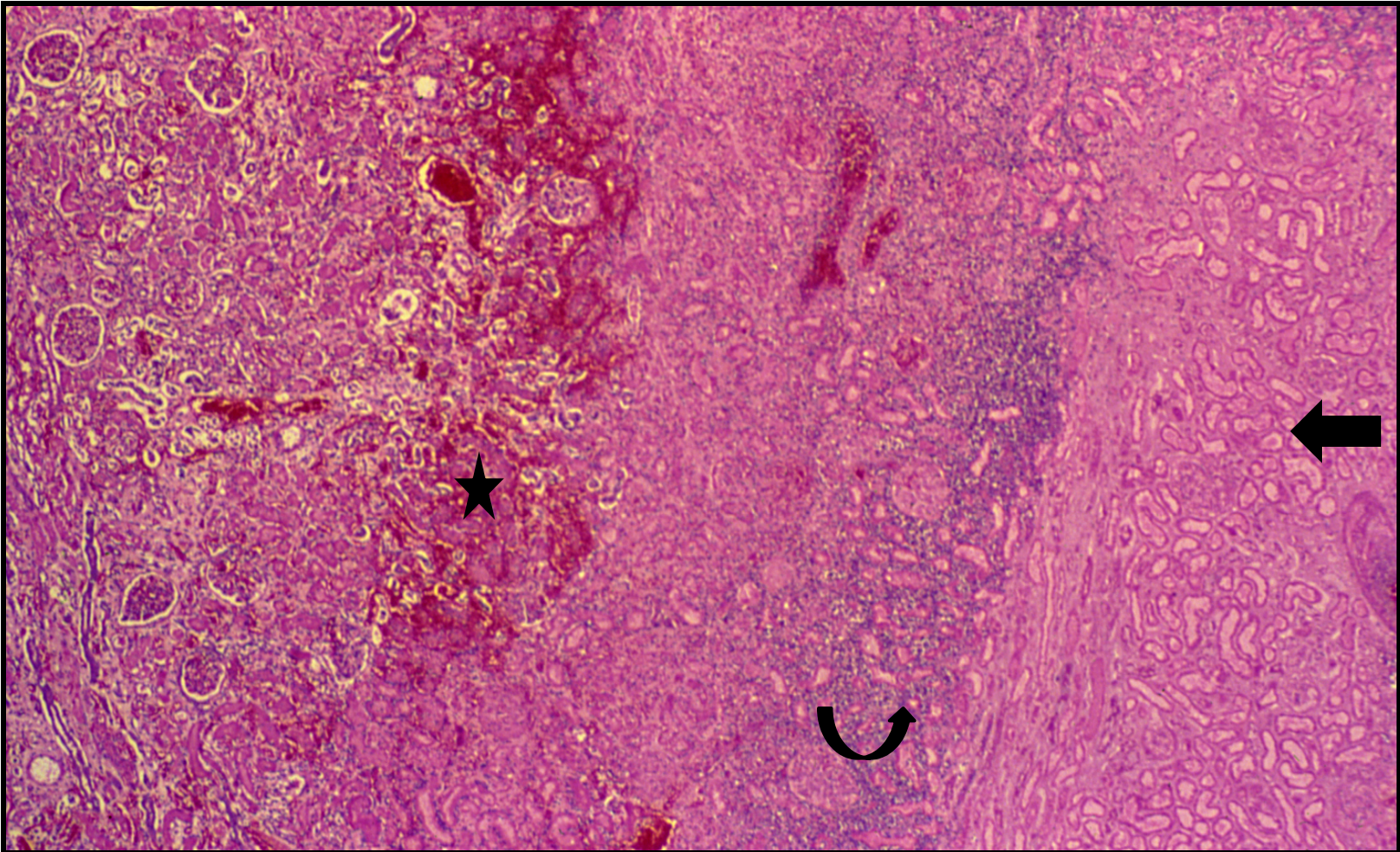
A typical pattern with ischemia and infarction of the kidney. Here, there is a wedge-shaped pale area of coagulative necrosis (infarction) in the renal cortex of the kidney.



**Kidney:
coagulative
necrosis**

Micro: Cell outlines are preserved (cells look ghostly), and everything looks red

Coagulative Necrosis of the Kidney - LPF



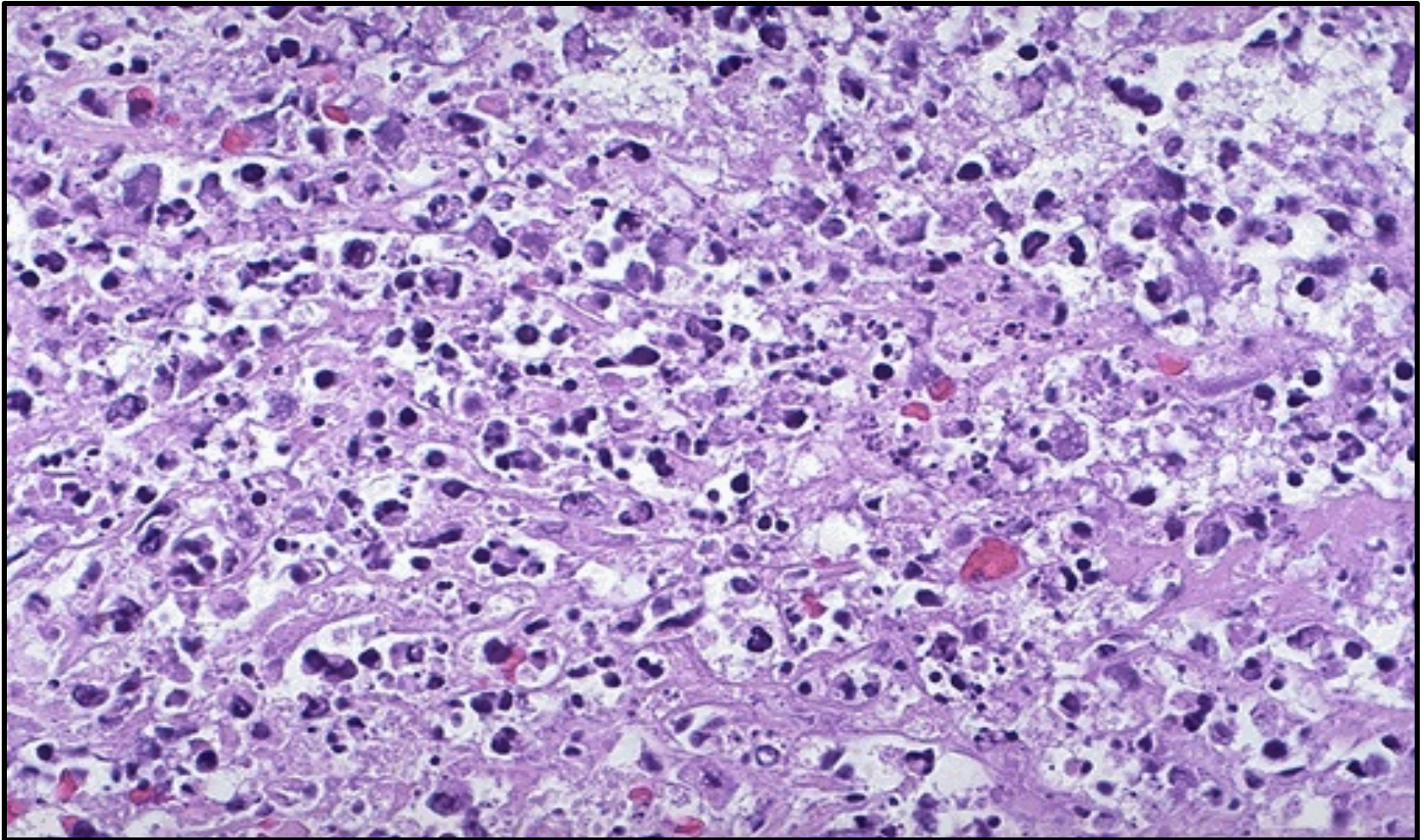
Coagulative necrosis (arrow) of glomeruli, tubules and interstitial tissue with loss of cell nuclei. The haemorrhagic zone (star) at the periphery of the infarct (arrow) shows dilated and congested blood vessels and cellular infiltrate by neutrophils, red blood cells and lymphocytes (curved arrow)

Coagulative Necrosis of the Spleen



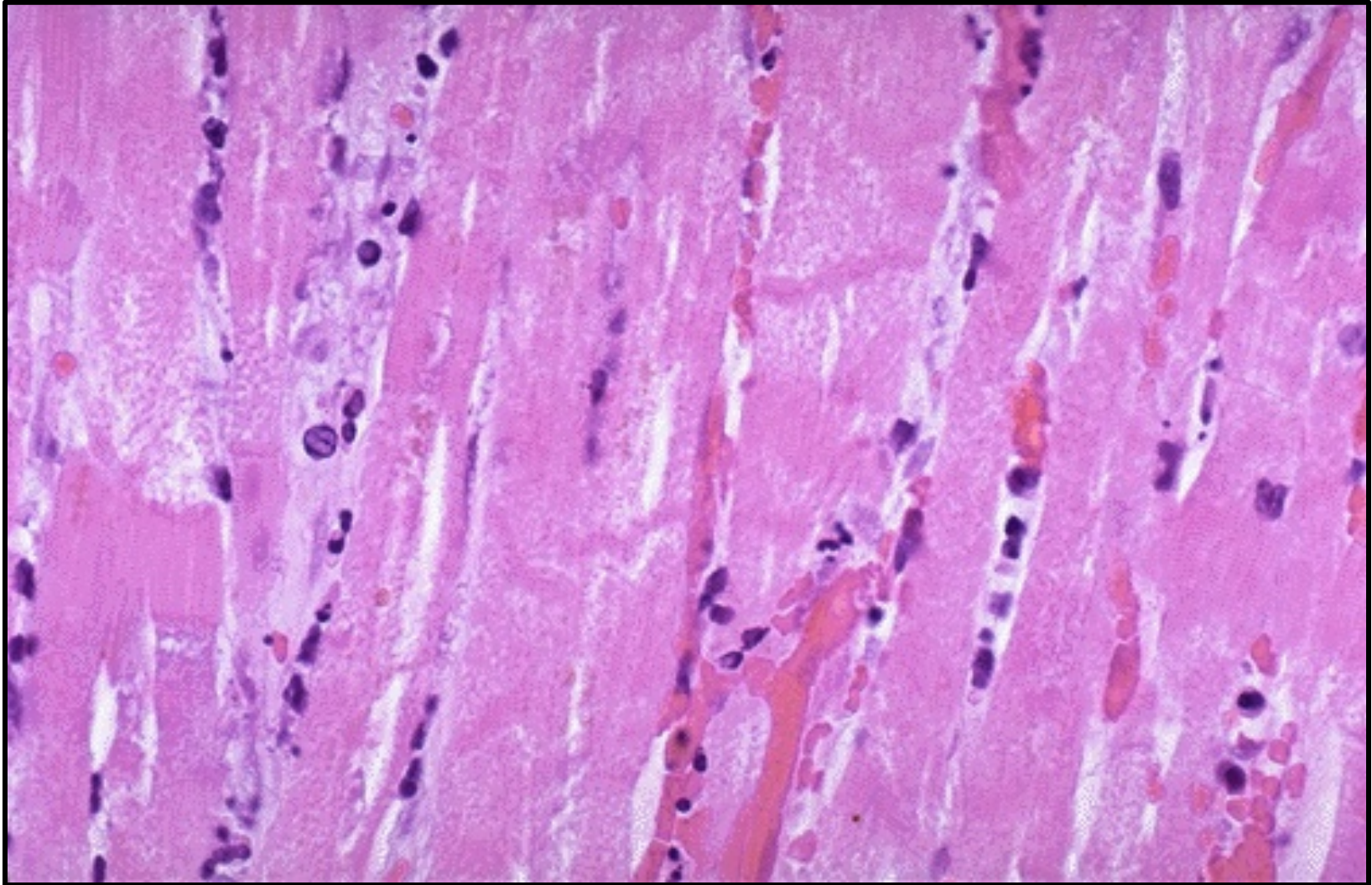
Two large infarctions (areas of coagulative necrosis) are seen in this sectioned spleen

Coagulative Necrosis of Infarcted Myocardium



Many nuclei have become pyknotic (shrunken and dark) and have then undergone karyorrhexis (fragmentation) and karyolysis (dissolution). The cytoplasm and cell borders are not recognizable.

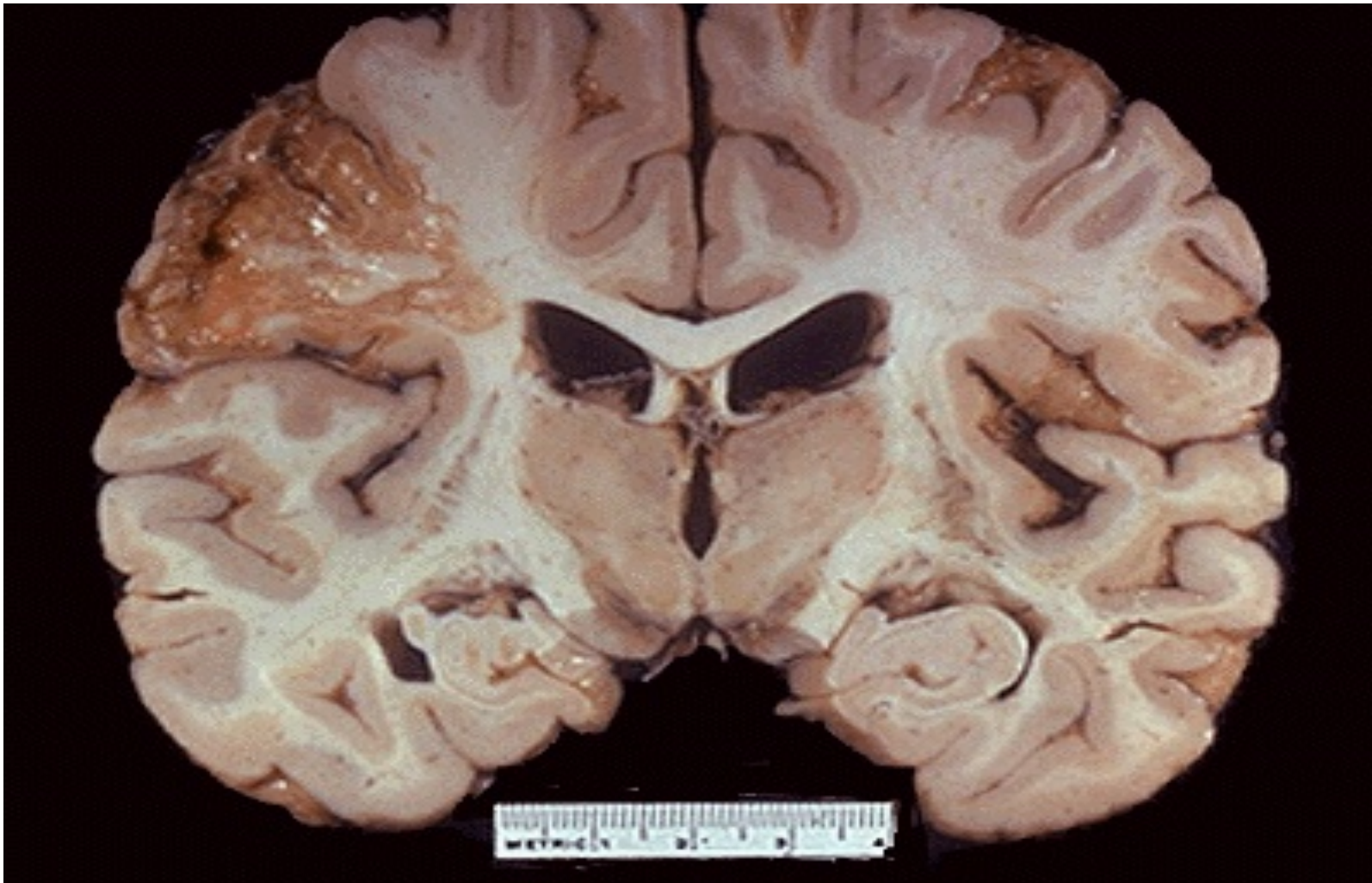
Coagulative Necrosis of Infarcted Myocardium



***The nuclei of the myocardial fibers are being lost.
The cytoplasm is losing its structure, because no well-defined cross-striations
are seen.***

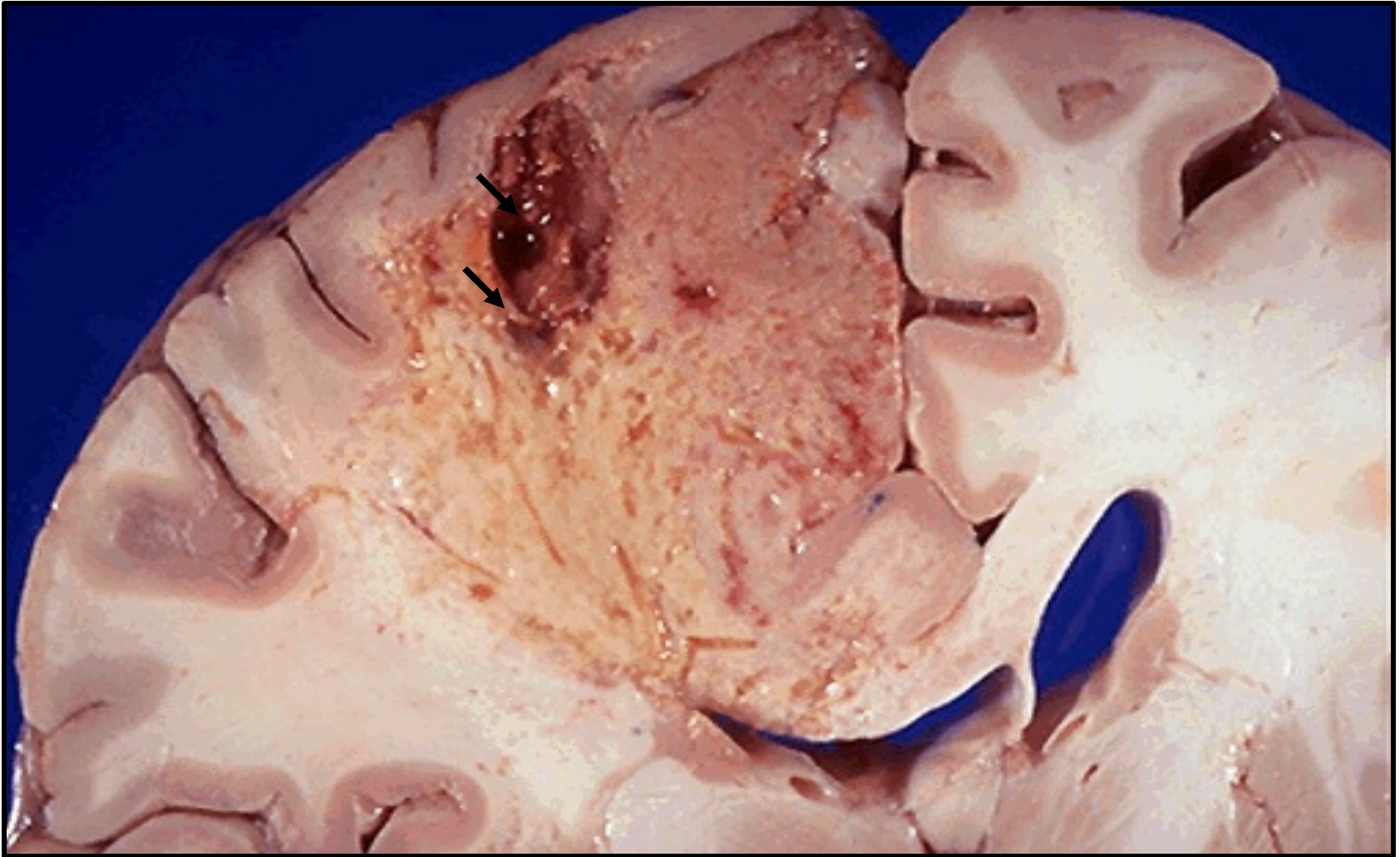3- LIQUEFACTIVE NECROSIS

Liquefactive Necrosis of the Brain



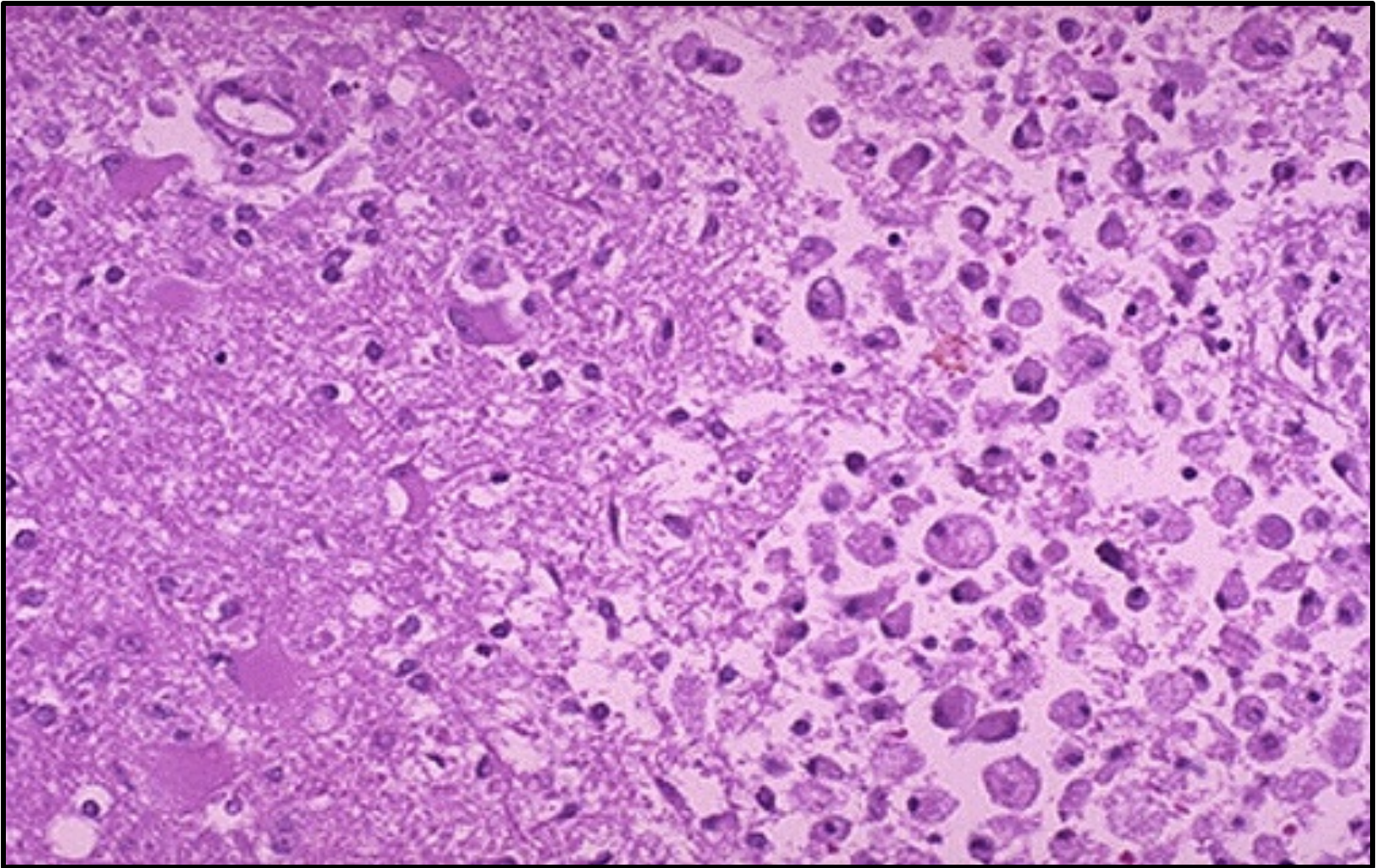
Grossly, the cerebral infarction at the upper right here demonstrates liquefactive necrosis. Eventually, the removal of the dead tissue leaves behind a cavity.

Liquefactive Necrosis of the Brain



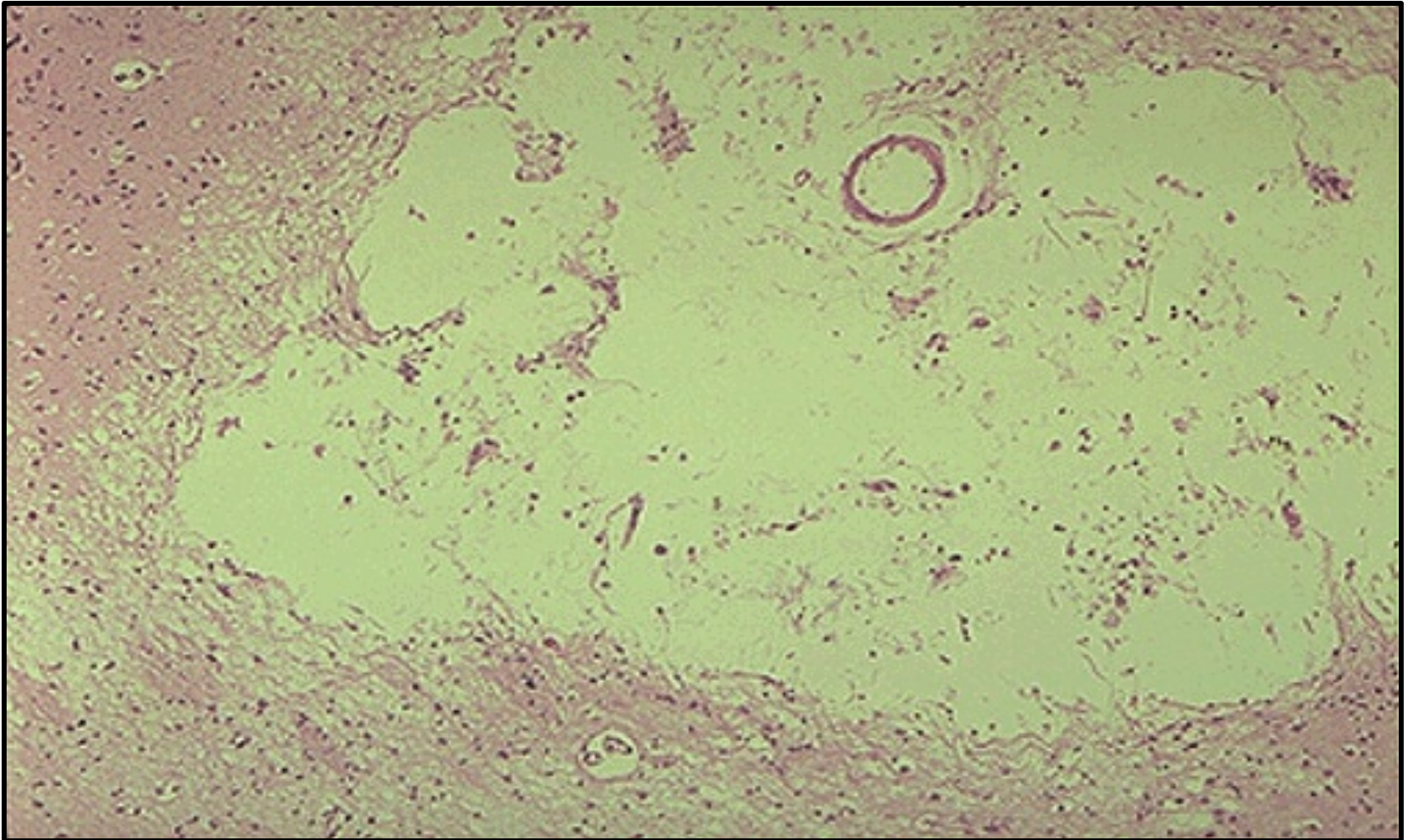
Liquefactive necrosis in brain leads to resolution with cystic spaces. The necrotic area is found in the upper right quadrant of the visual field.

Liquefactive Necrosis of the Brain



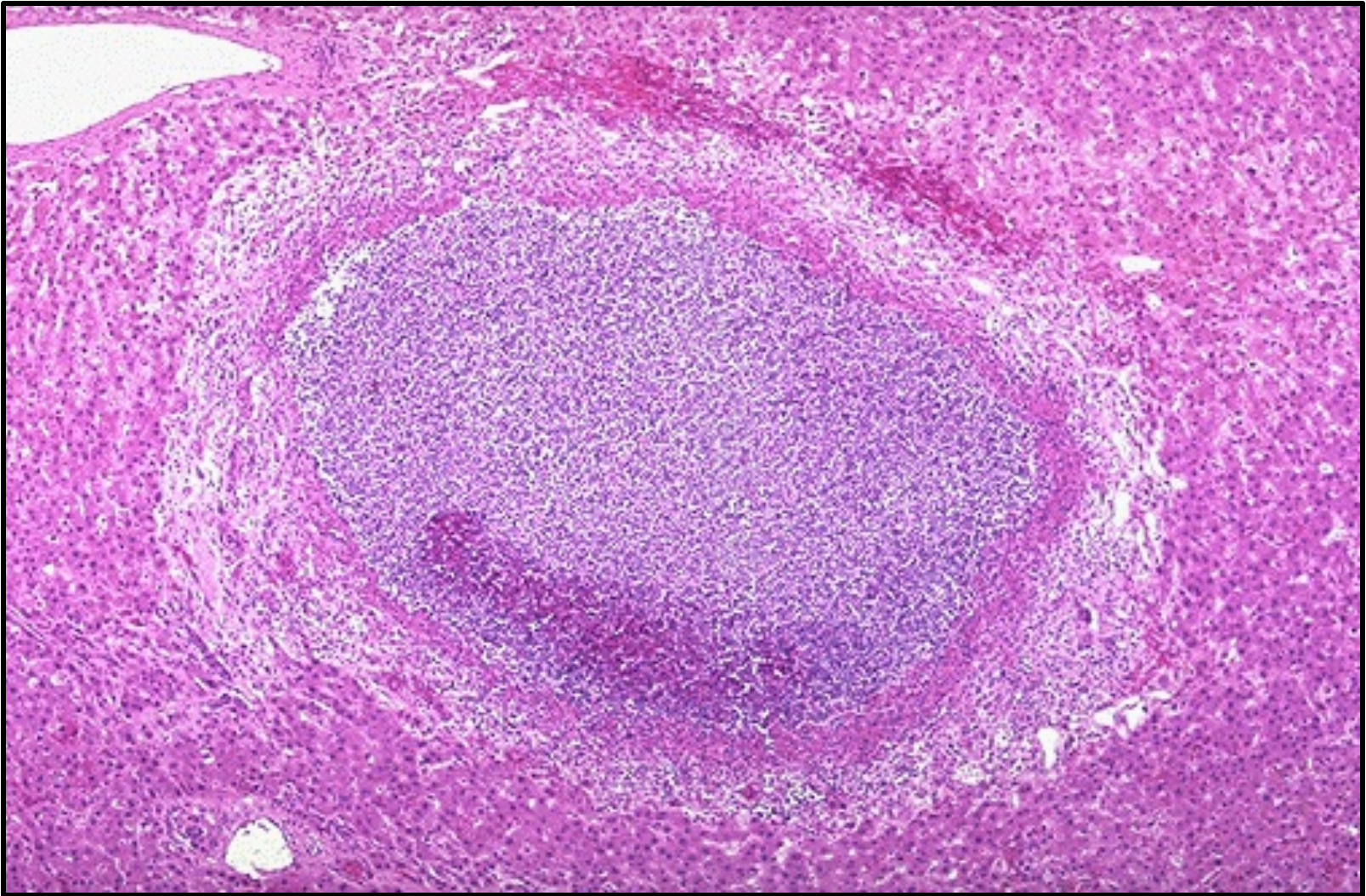
This cerebral infarction demonstrates the presence of many macrophages at the right which are cleaning up the lipid debris from the liquefactive necrosis.

Liquefactive Necrosis of the Brain



This is the microscopic appearance of a lacunar infarct. Note that it is a cystic space from the resolved liquefactive necrosis. There can be hemosiderin pigment from hemorrhage as well.

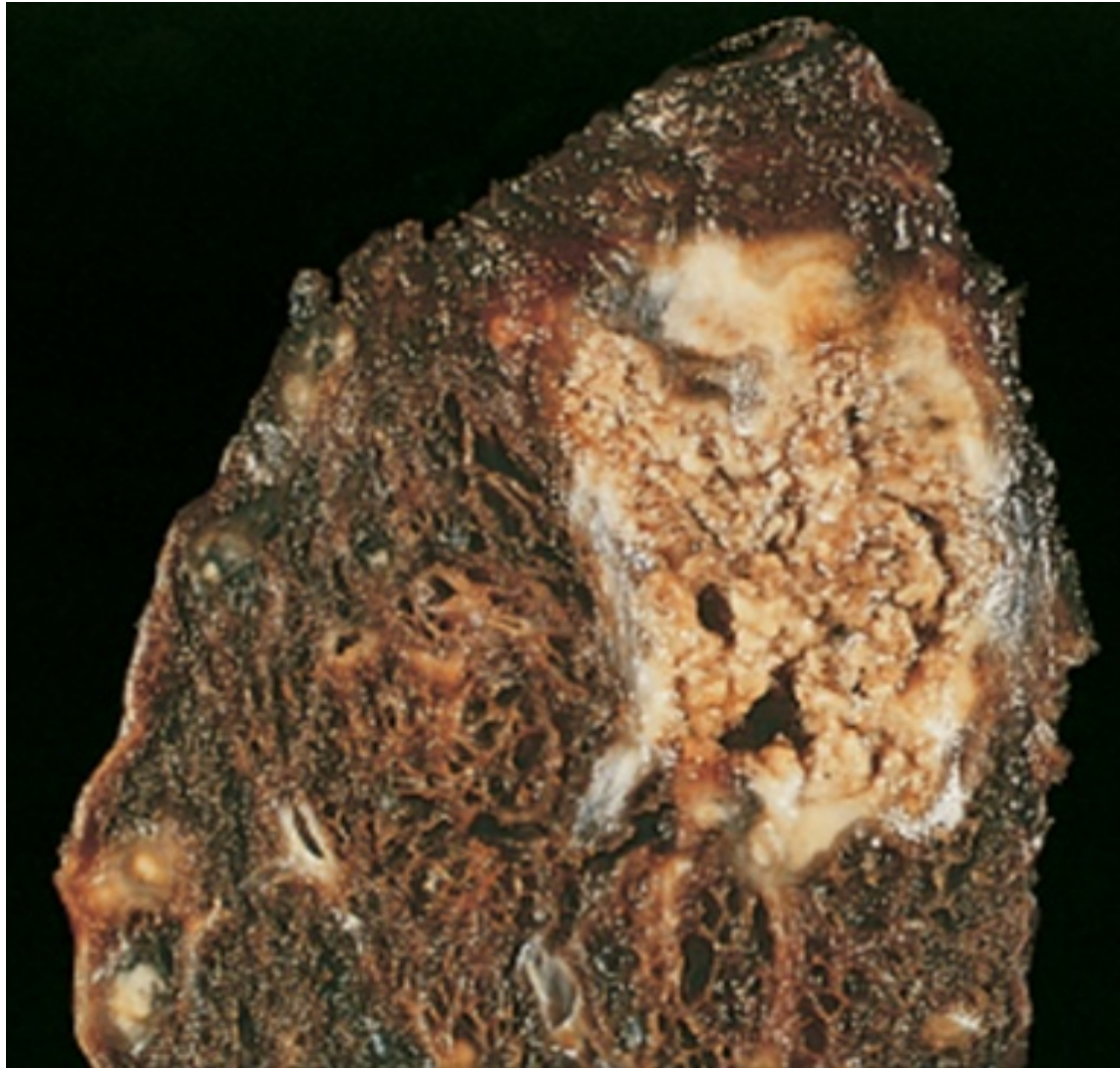Liquefactive Necrosis - Liver Abscess



The liver shows a small abscess here filled with many neutrophils. This abscess is an example of localized liquefactive necrosis

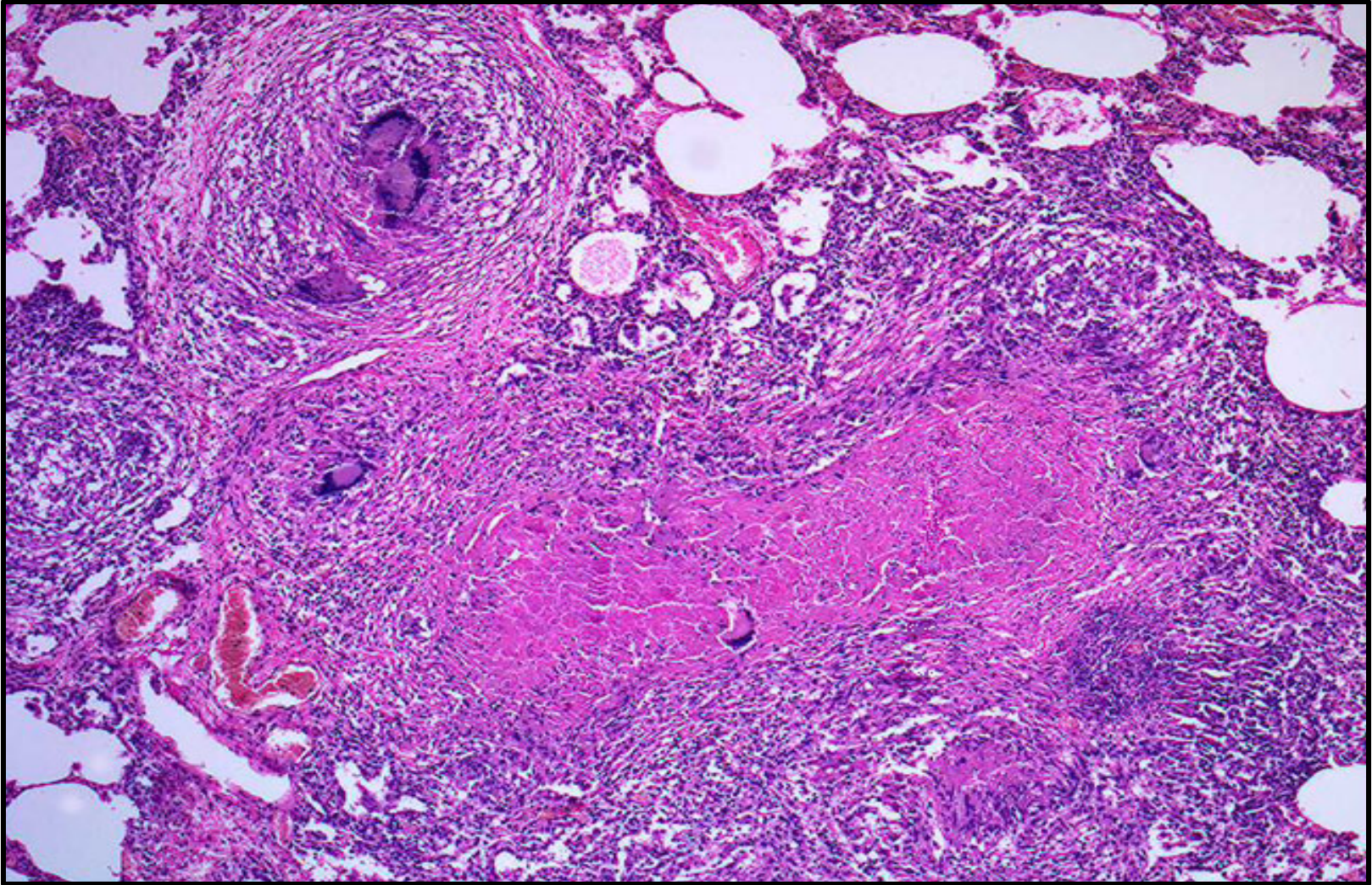
4- CASEOUS NECROSIS

Caseous Necrosis of the Lung “ TB. Lung”



Tuberculosis of the lung, with a large area of caseous necrosis containing yellow-white and cheesy debris

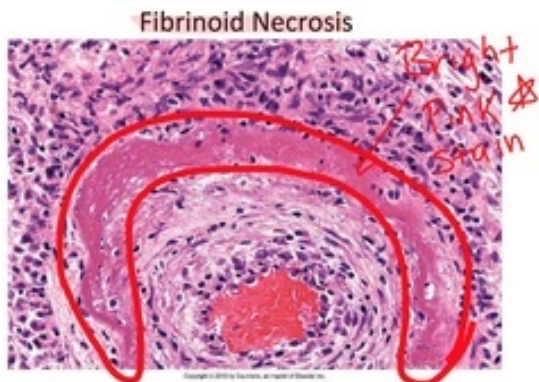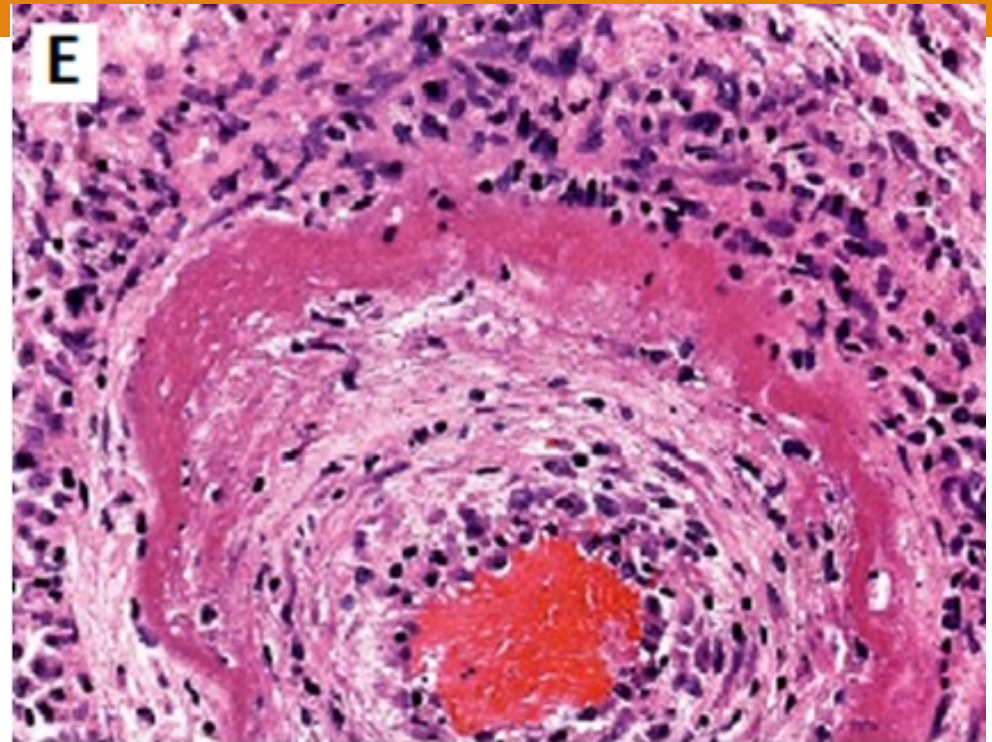
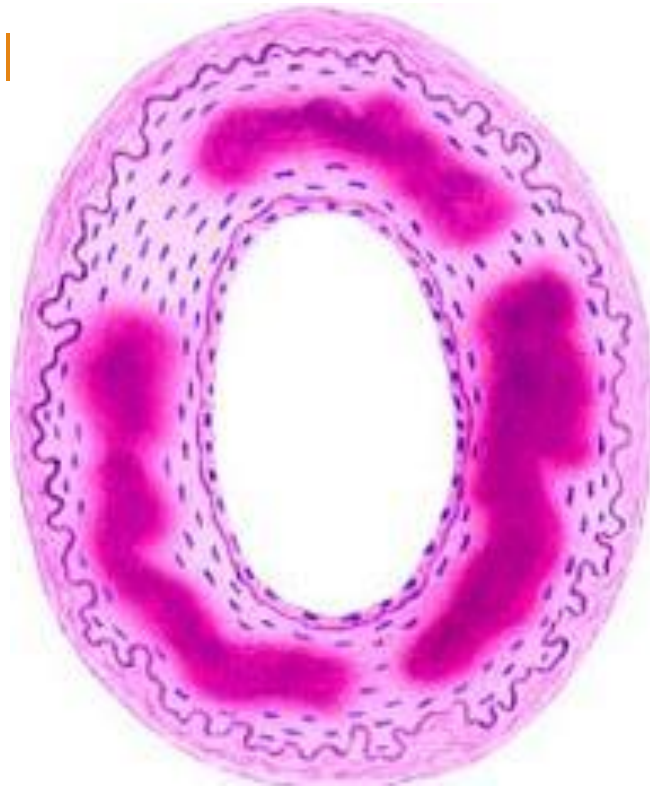T.B. Granuloma with Central Caseous Necrosis



Multiple caseating granulomas with giant cells and caseous necrosis. Note preserved alveolar spaces at the margins of the field.

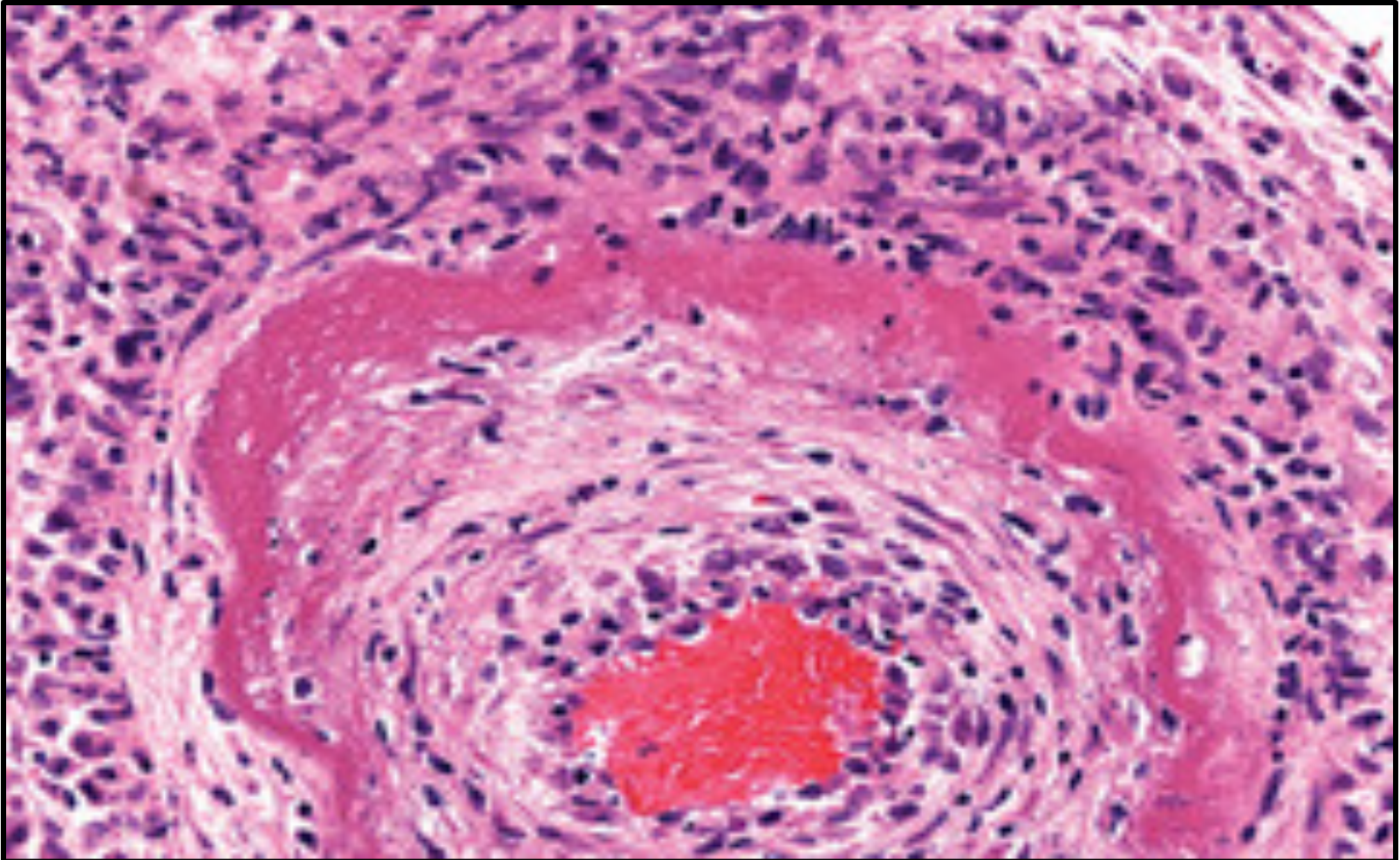
5 – FIBRINOID NECROSIS

Fibrinoid necrosis



Fibrinoid necrosis in an artery. The wall of the artery is bright pink with dark neutrophils

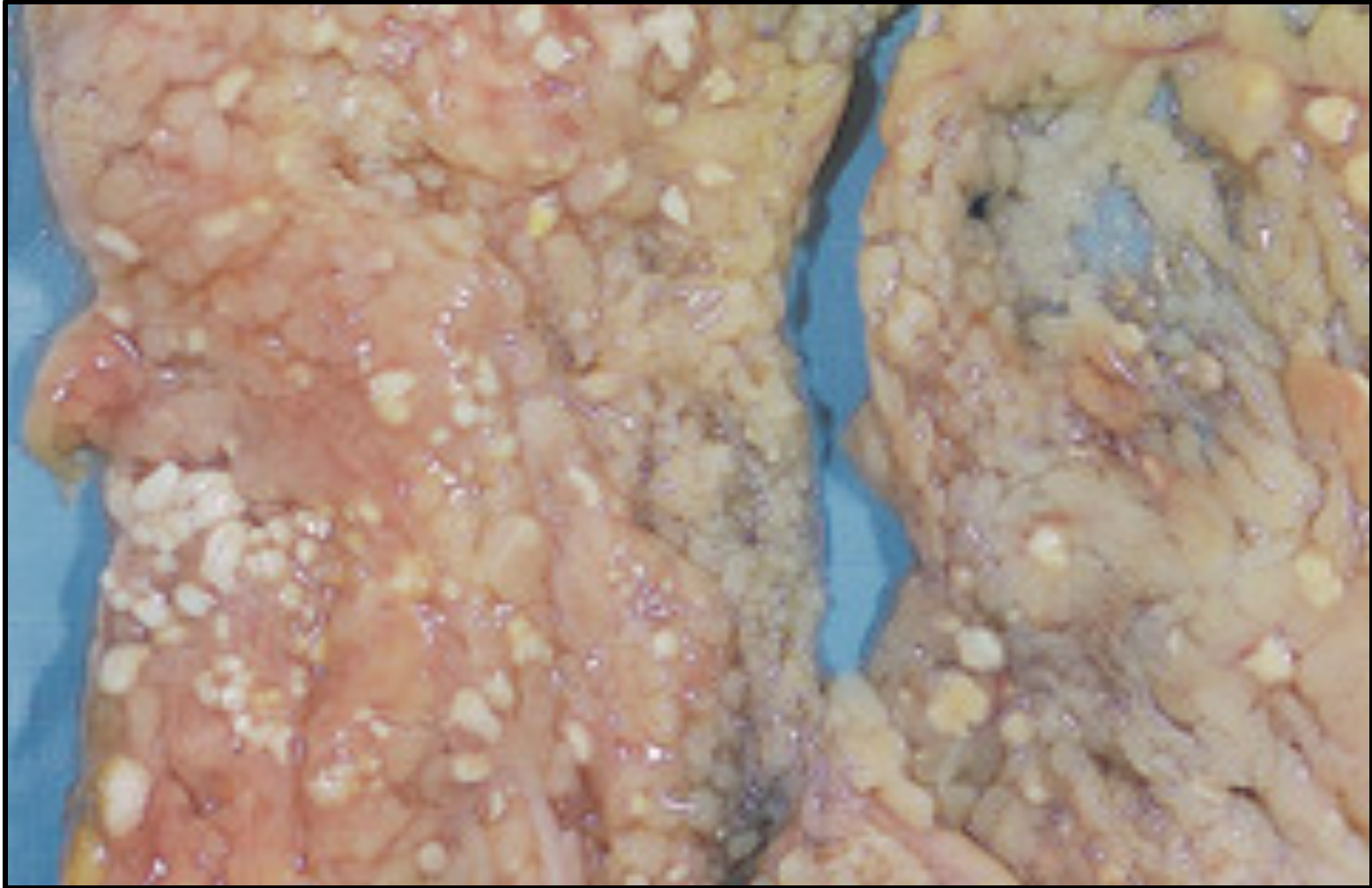
Fibrinoid Necrosis of an Artery - HPF



Fibrinoid necrosis in an artery. The wall of the artery shows a circumferential bright pink area of necrosis with inflammation (neutrophils with dark nuclei).

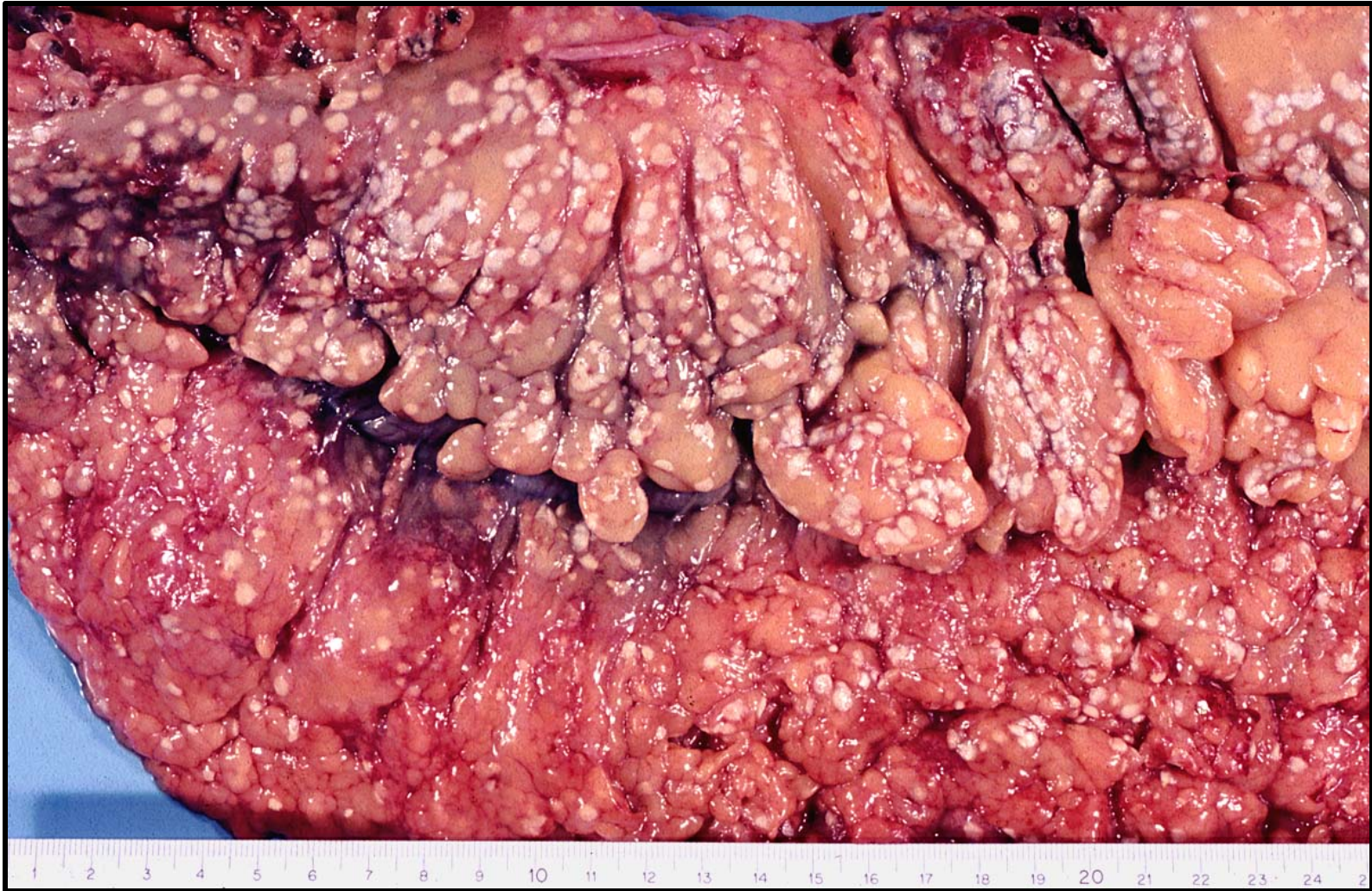
6 – FAT NECROSIS

Fat Necrosis in the Mesentery



The areas of white chalky deposits represent foci of fat necrosis with calcium soap formation (saponification) at sites of lipid breakdown in the mesentery

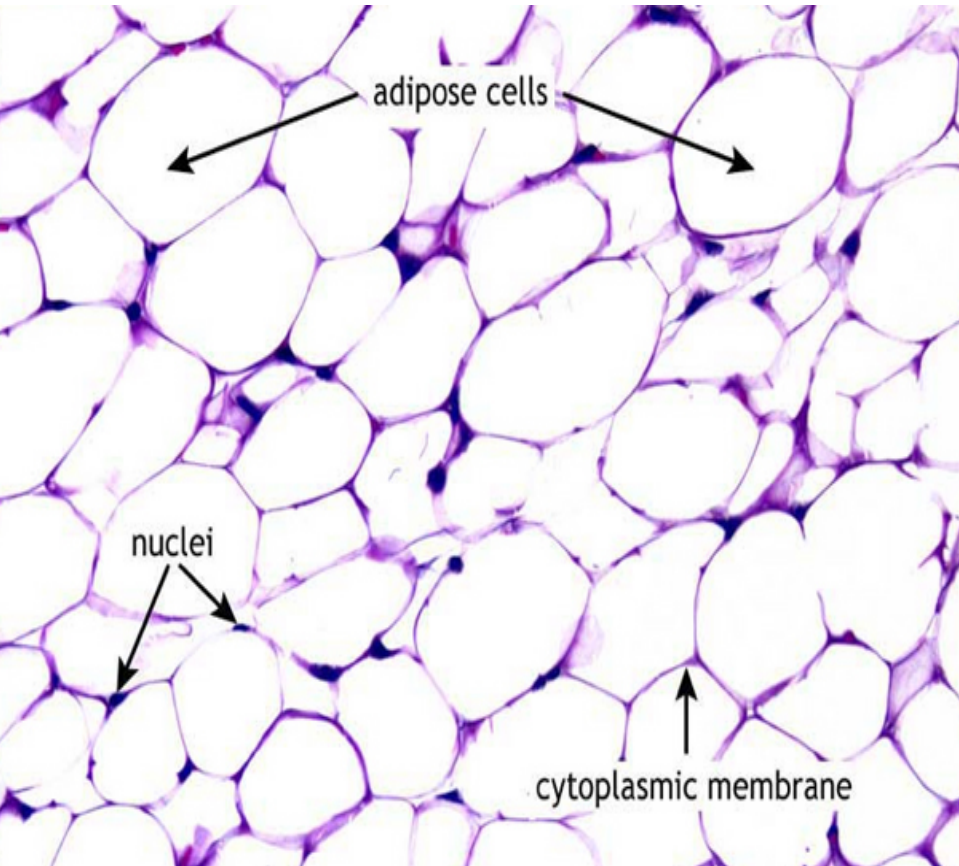
Fat Necrosis in the Mesentery



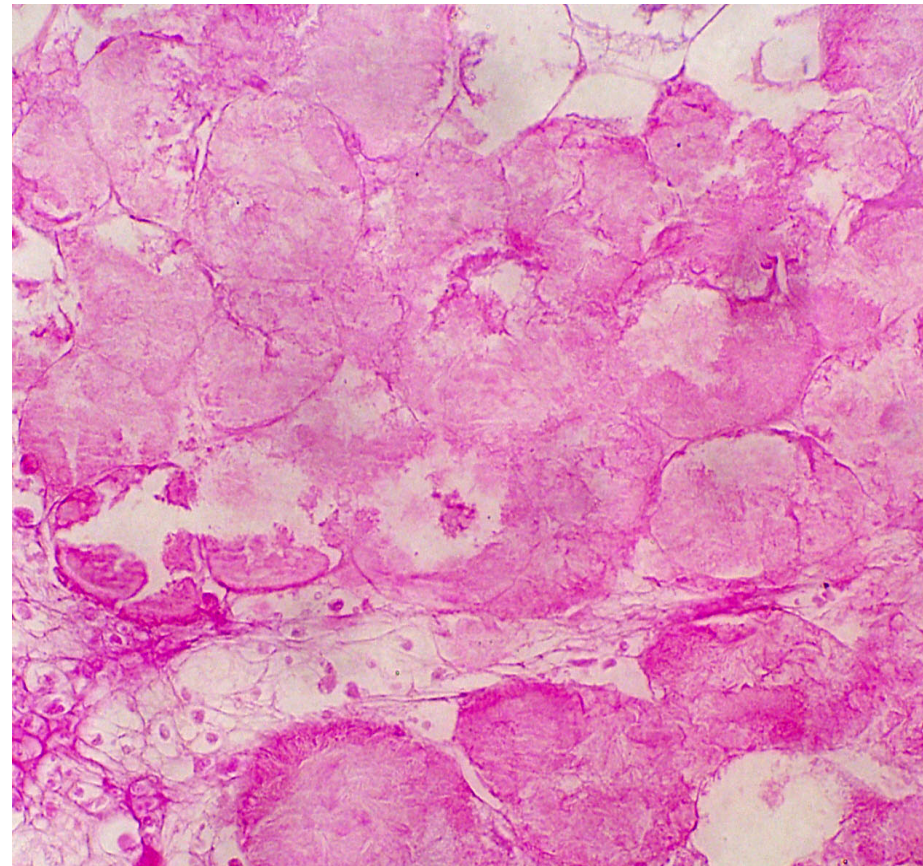
Fat necrosis of the mesentery in a case of acute pancreatitis
Numerous round white fat necroses

Fat Necrosis – Histopathology

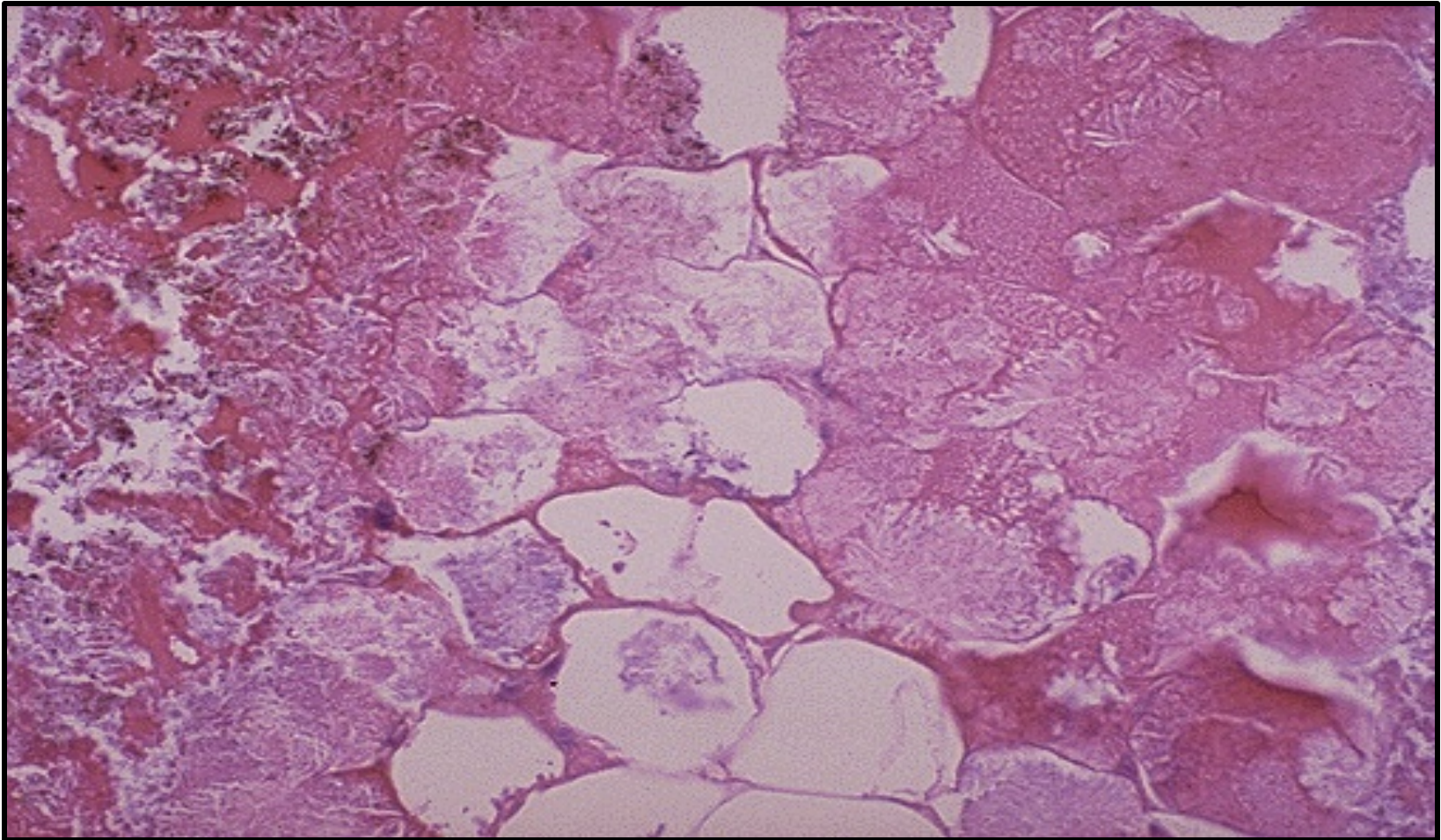
□ Normal adipocytes



□ Fat necrosis



Fat Necrosis – Histopathology

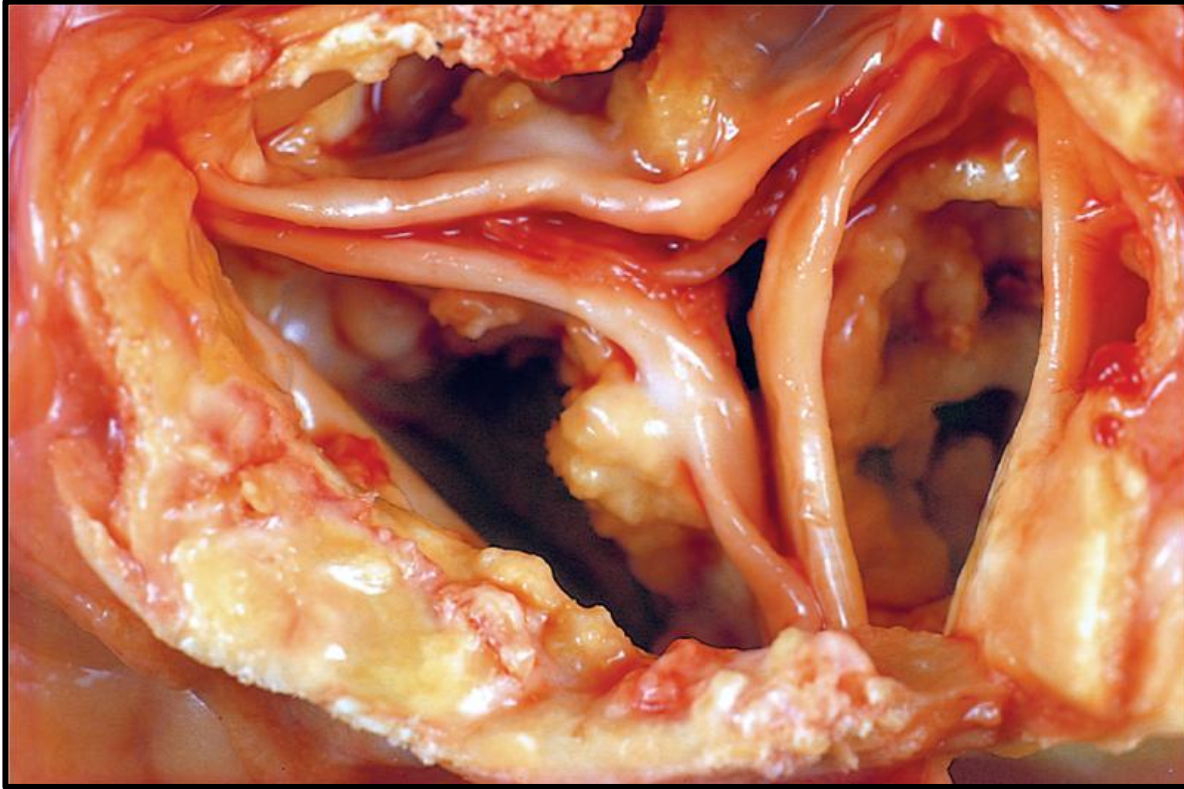

Picture of fat necrosis in the fat surrounding the pancreas is seen here. The fat cell (adipocytes) are necrotic. The necrotic fat cells have vague cellular outlines, have lost their peripheral nuclei, and their cytoplasm has become pink and amorphous

7 - DYSTROPHIC CALCIFICATION

(AORTIC VALVE – STOMACH - SKIN)

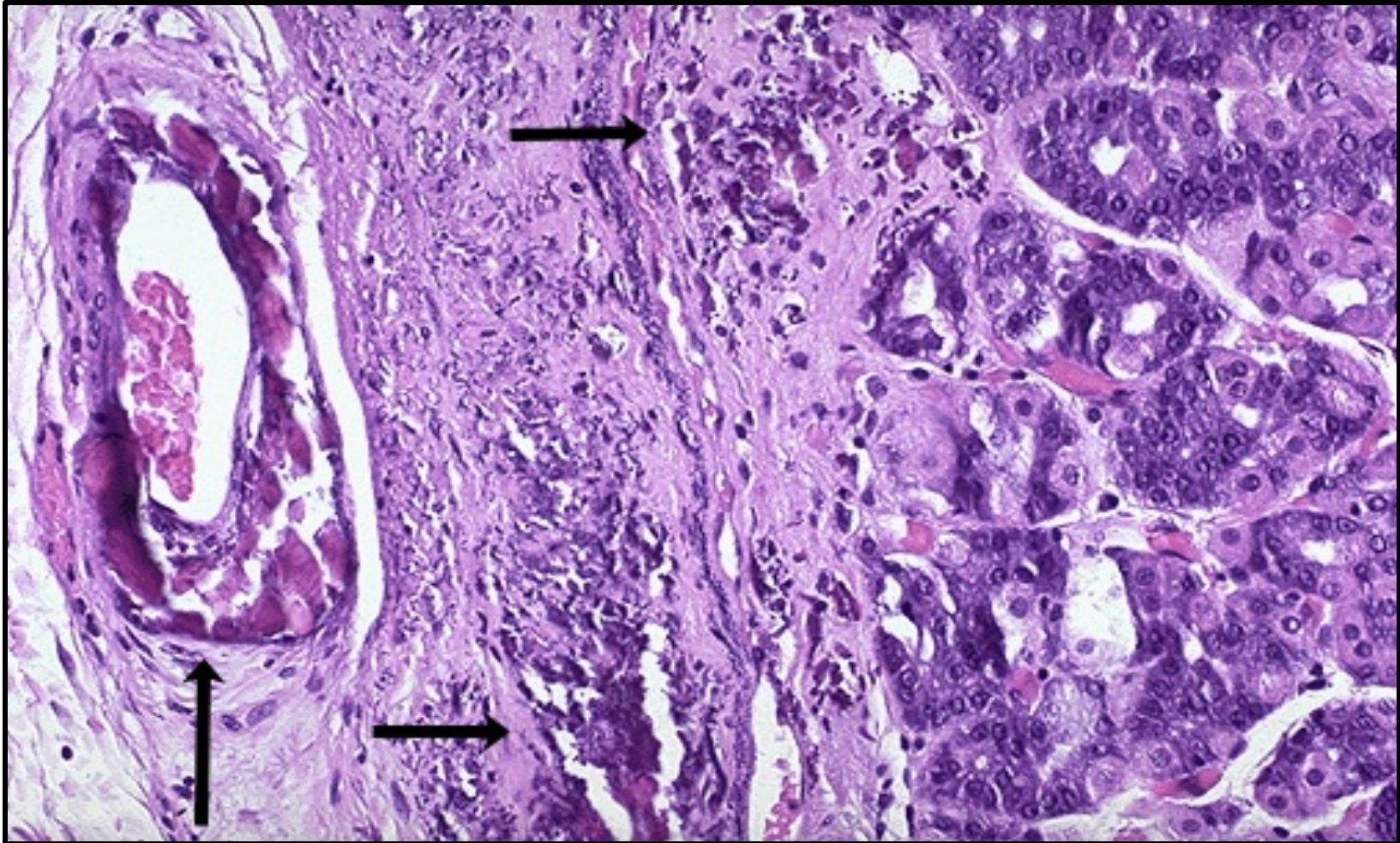
Dystrophic calcification of Aortic Valve



- ❑ Normal calcium metabolism
- ❑ Deposition of Calcium in dying tissue.
- ❑ Seen in aging or damaged heart valves (e.g. atherosclerosis)

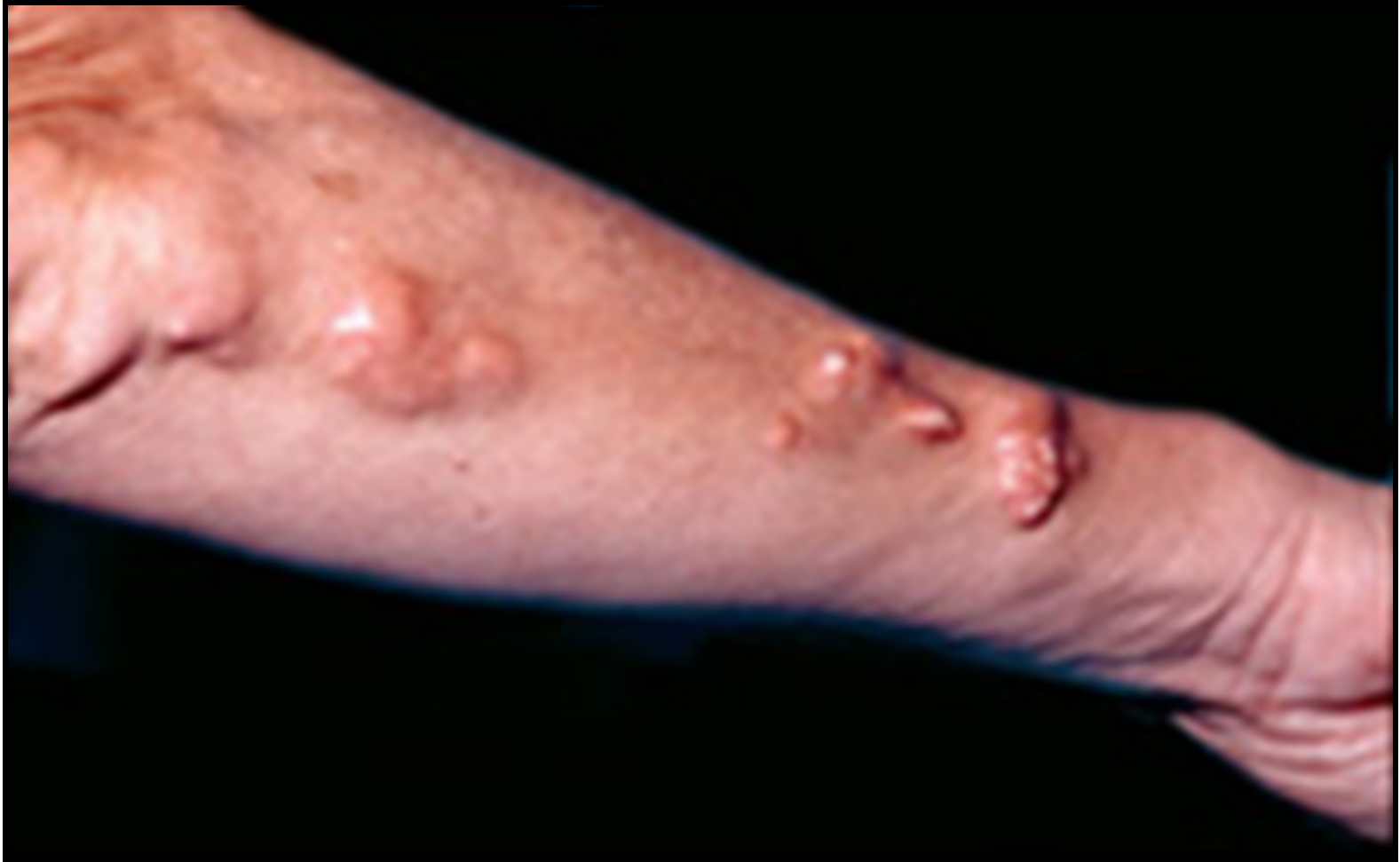View looking down onto the unopened aortic valve in a heart with calcific aortic stenosis. It is markedly narrowed (stenosis). The semilunar cusps are thickened and fibrotic, and behind each cusp are irregular masses of piled-up dystrophic calcification

Dystrophic Calcification of Stomach



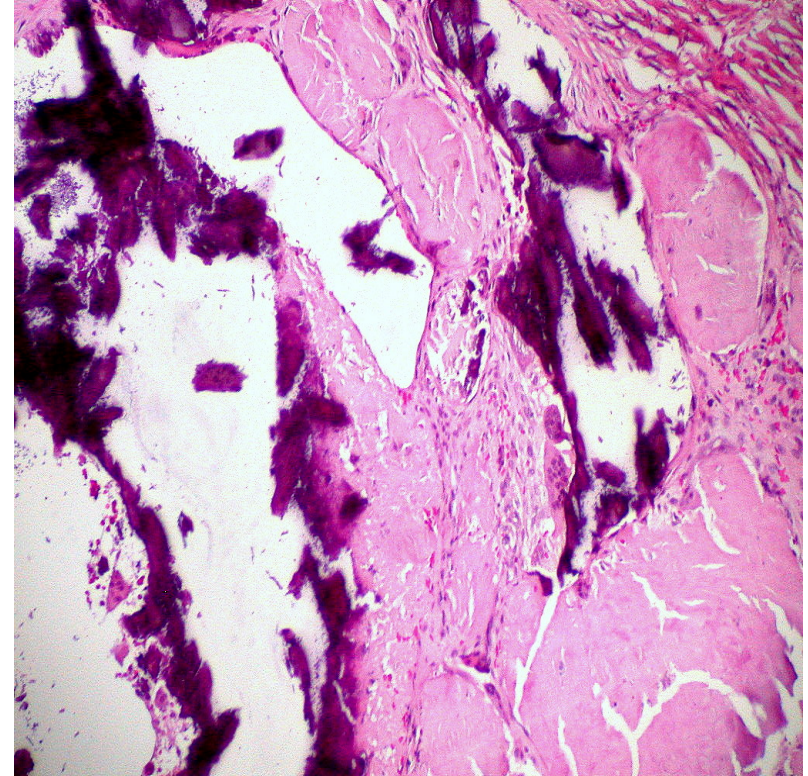
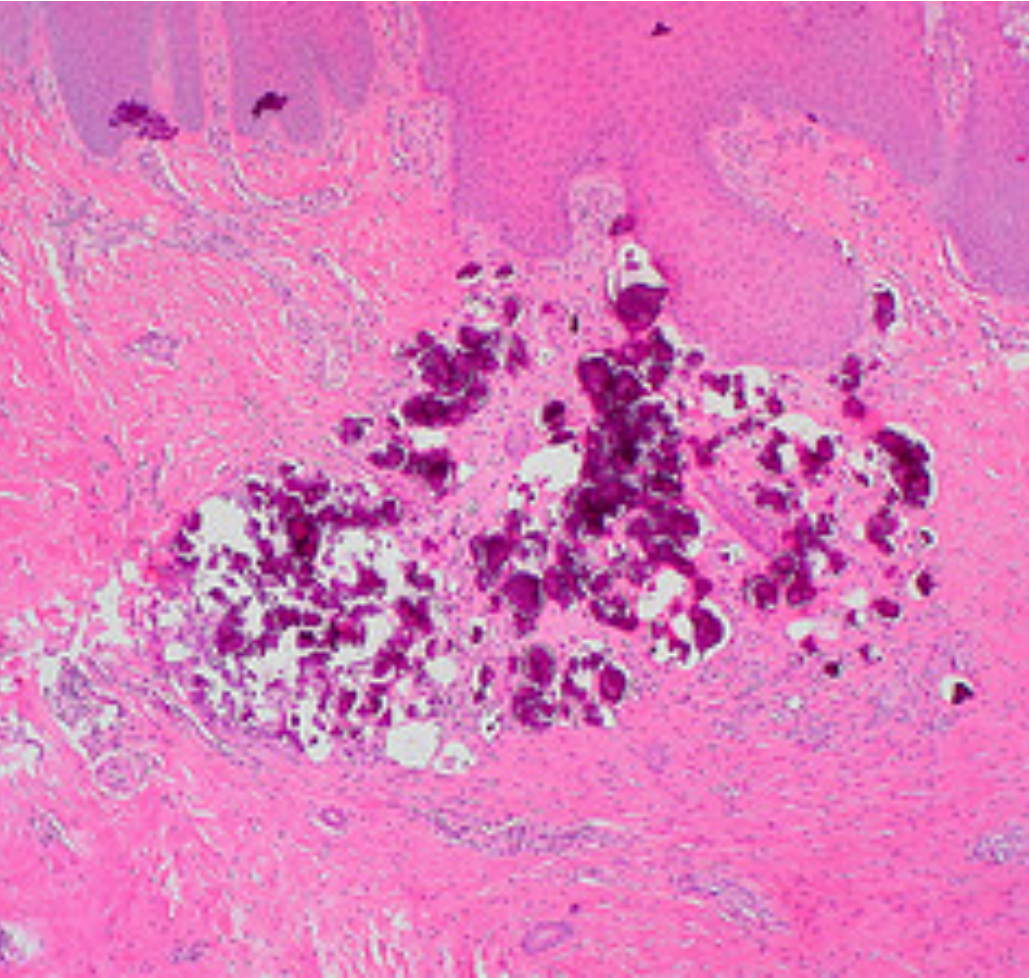
This is a dystrophic calcification in the wall of the stomach. At the far left is an artery with calcification in its wall. There are also irregular bluish-purple deposits of calcium in the submucosa. On the left are normal glands of the stomach.

Dystrophic Calcification of the Skin



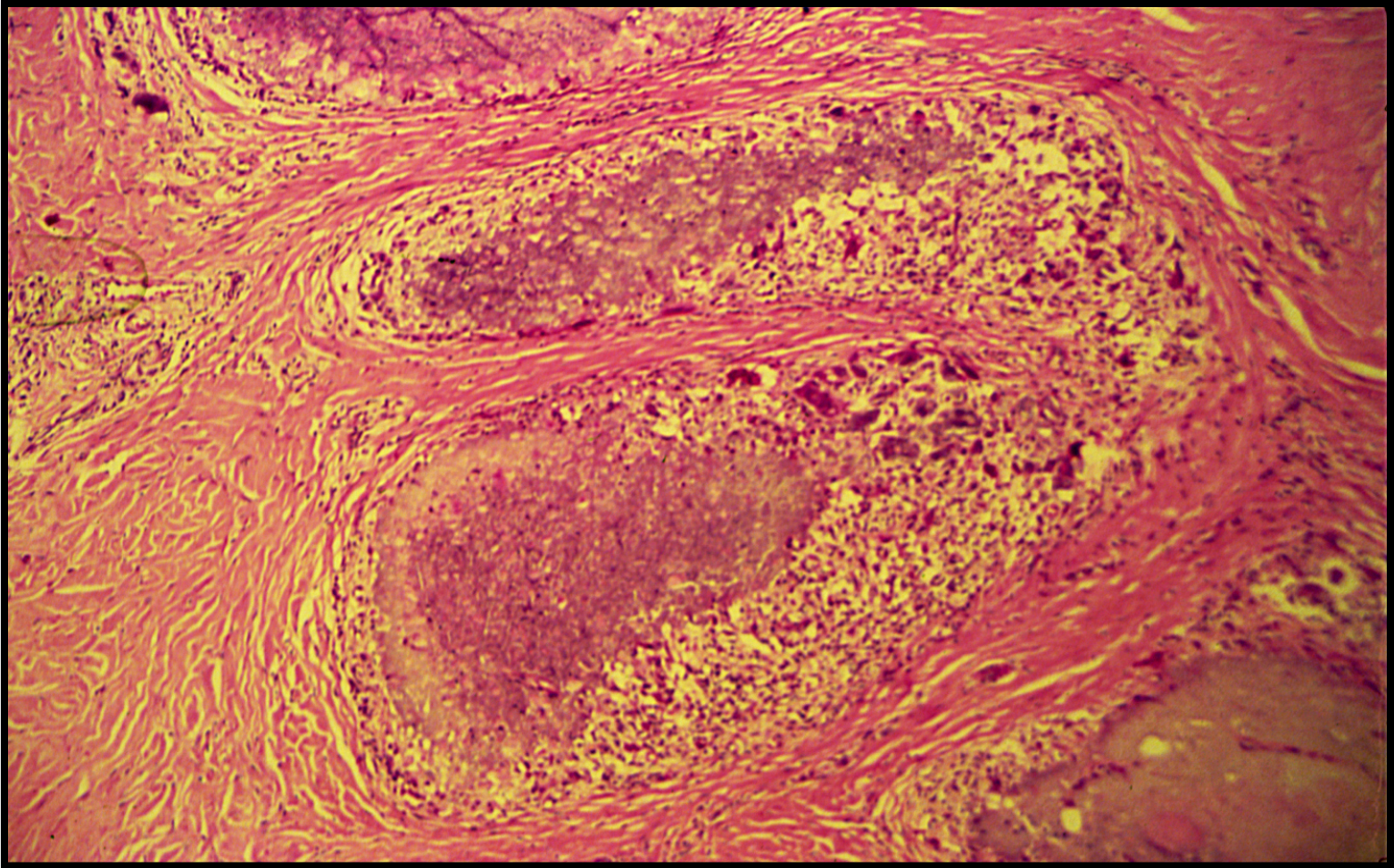
Multiple erythematous hard papules in linear configuration on the extensor aspect of the arm. Within the lesion there were several 2-5 mm white calcifications

Pathologic Calcification



Irregular blue/purplish/violet granular nodule or deposits of calcium in the dermis

Dystrophic Calcification of the Skin

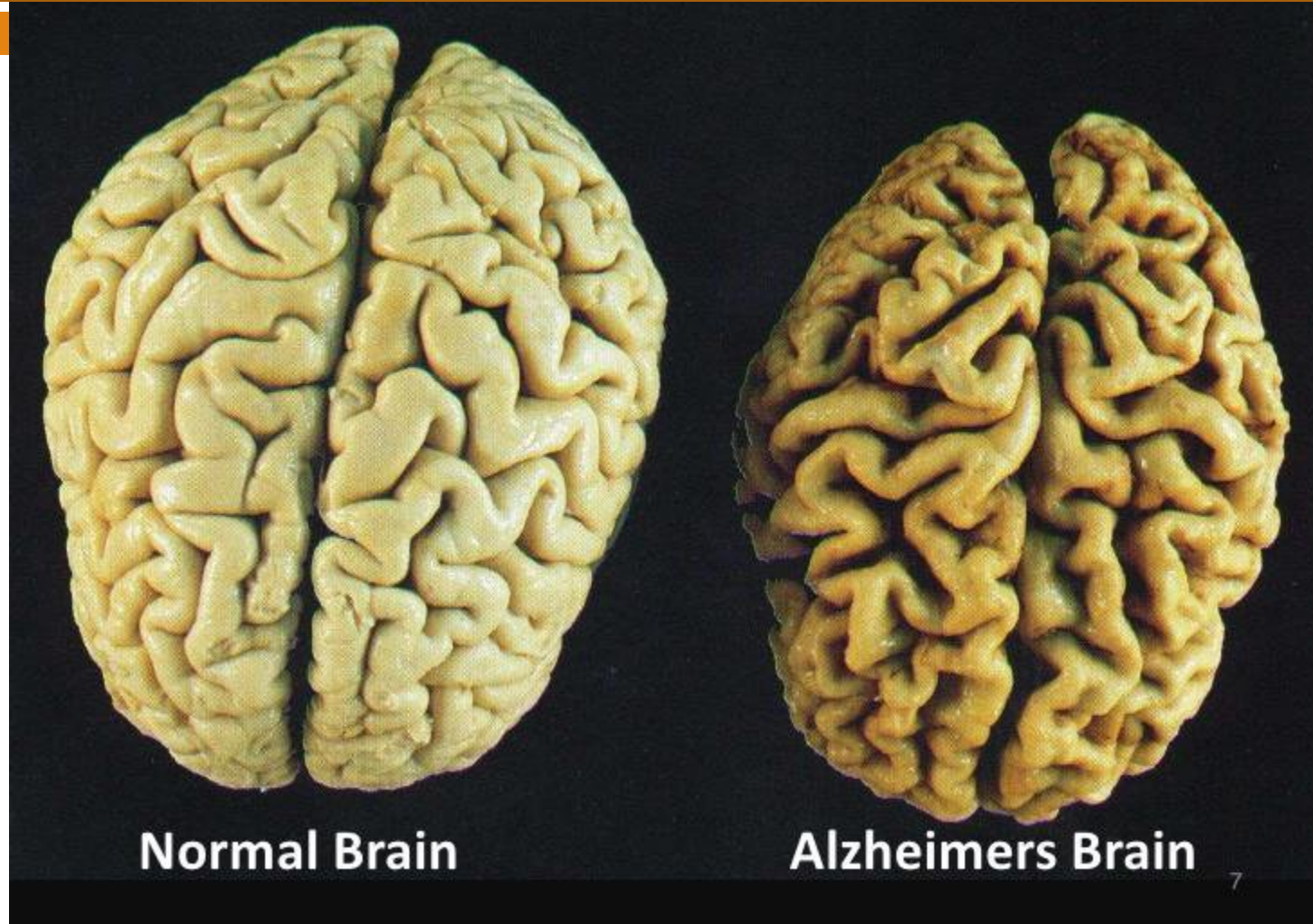


Irregular blue granular nodule or deposits of calcium in the dermis surrounded by fibrous, inflammatory cell like histiocytes and also multinucleated giant cells (called as foreign body giant cell reaction)

8- ATROPHY OF THE ORGANS

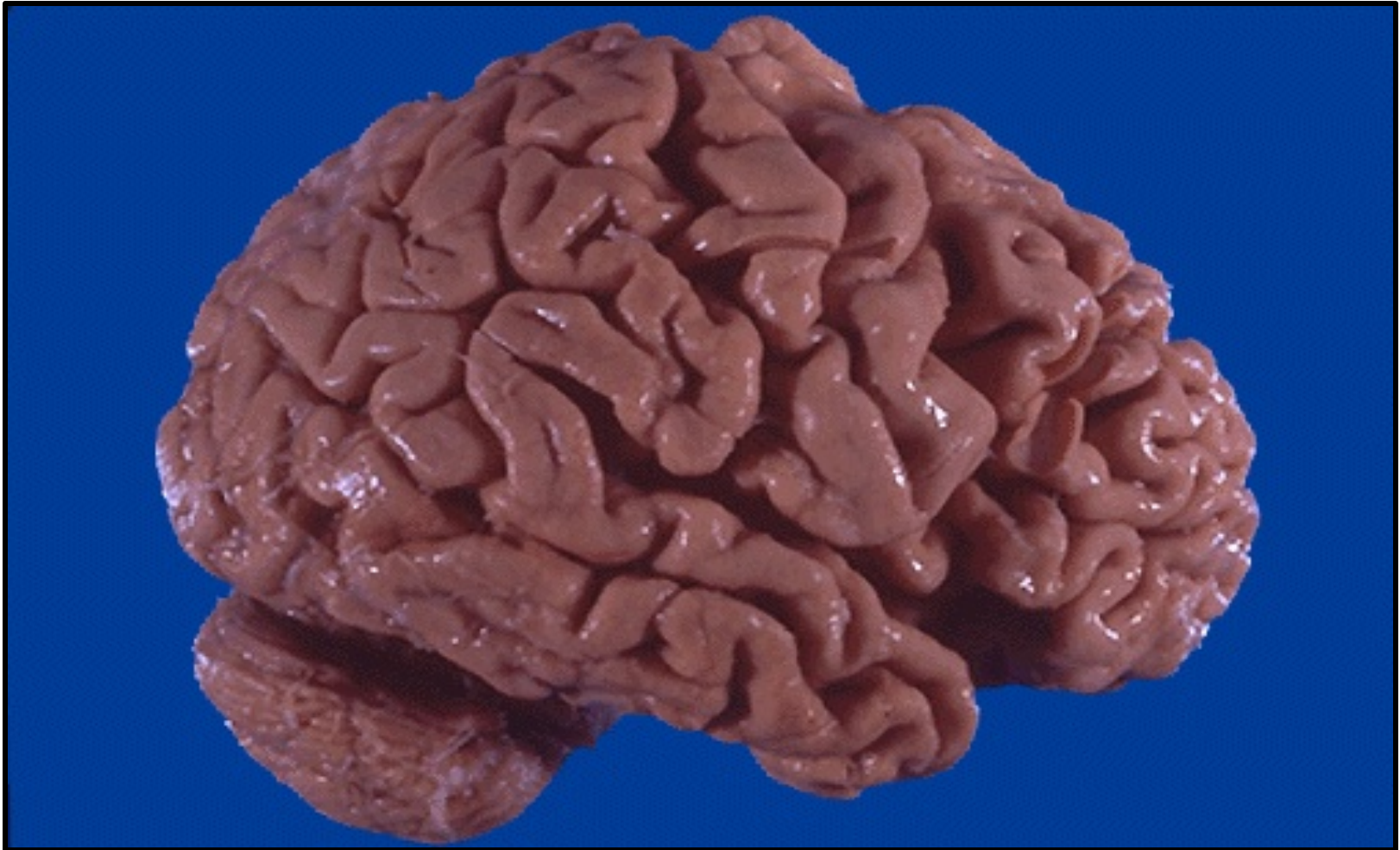(BRAIN – TESTIS)

Atrophy of the Brain



A normal brain is shown on the left and a brain with cortical atrophy caused by Alzheimer's disease is shown on the right with thinning of the gyri and prominence of the sulci.

Atrophy of the Brain

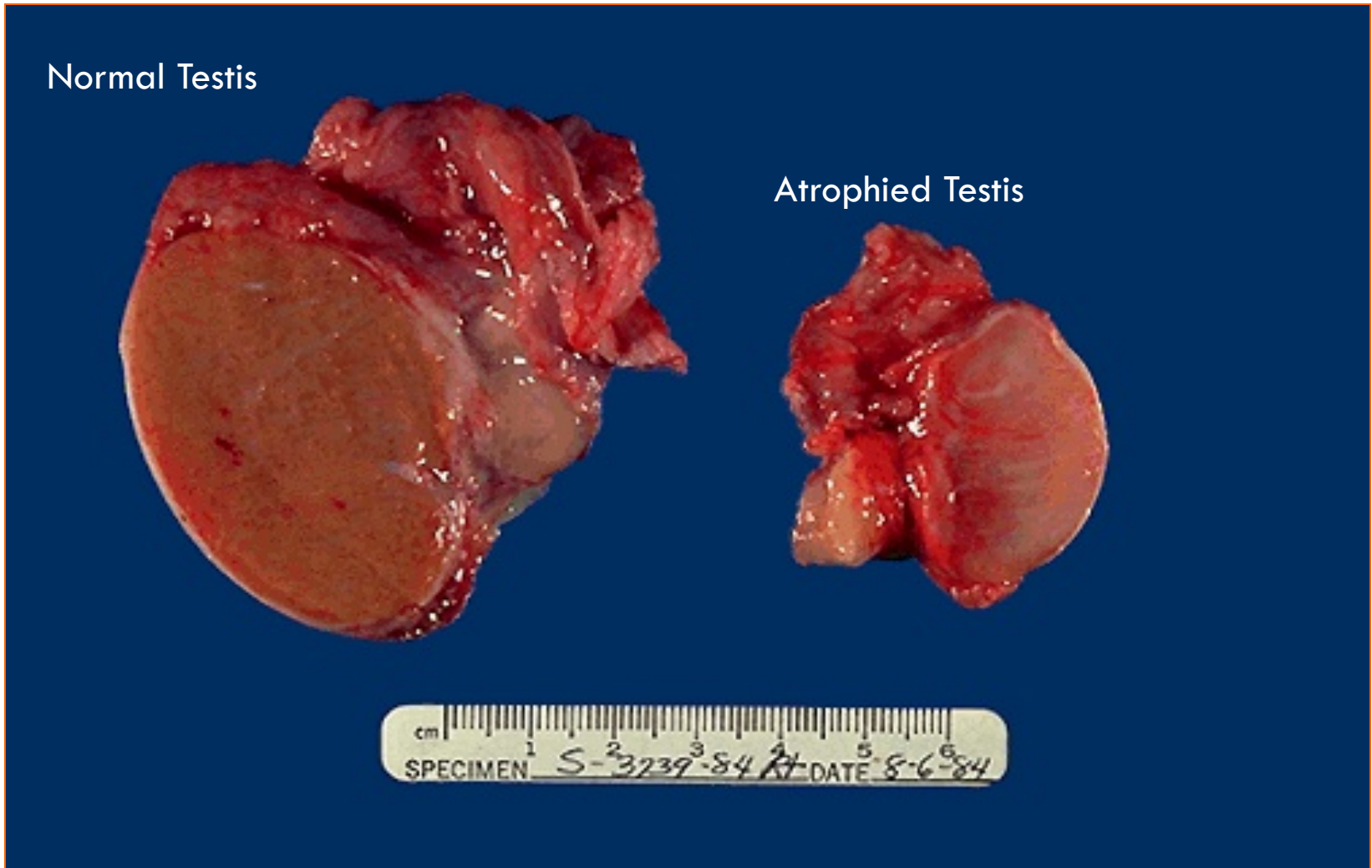


This is cerebral atrophy in a patient with Alzheimer disease. The gyri are narrowed and the intervening sulci are widened, particularly pronounced toward the frontal lobe region.

Right

Atrophy of the Testis

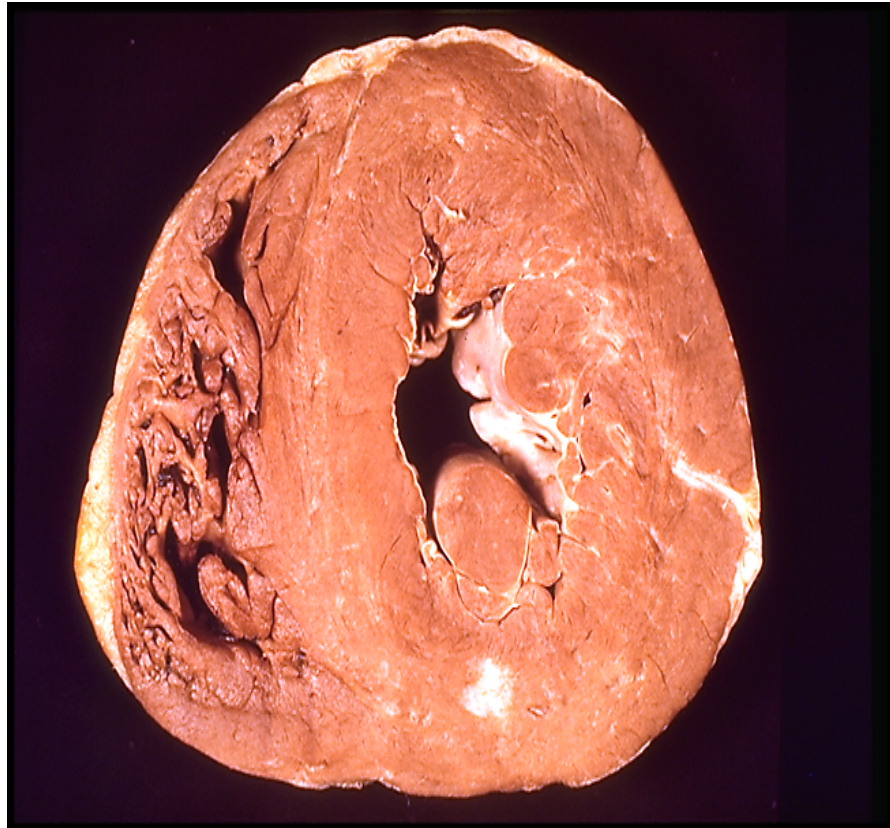
Left



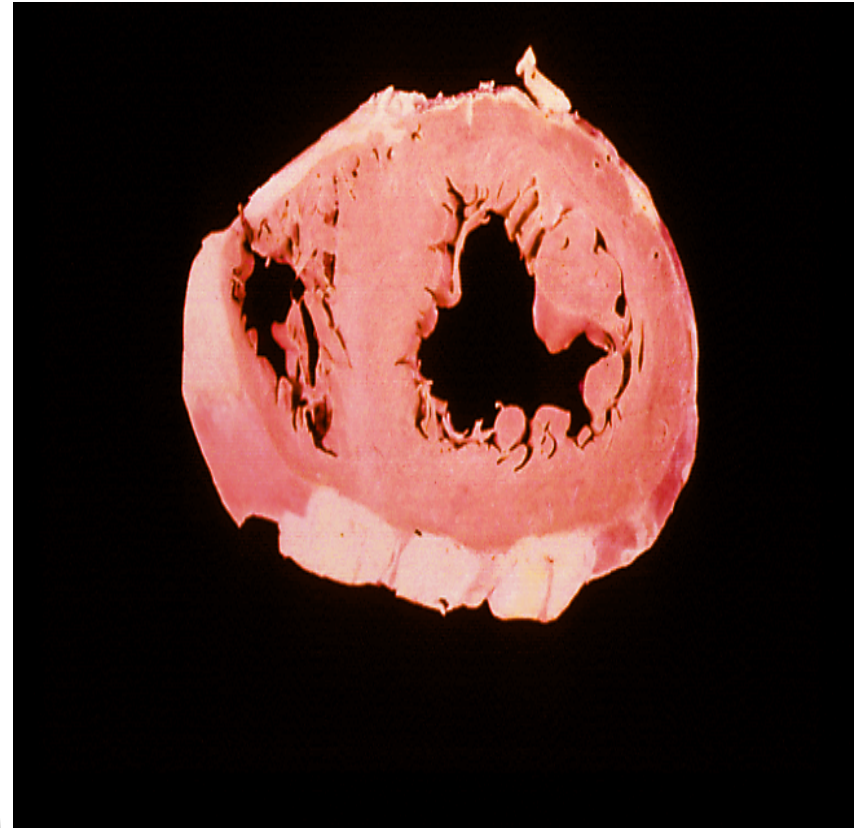
The testis at the left has undergone atrophy and is much smaller than the normal testis at the right.

9 - LEFT VENTRICULAR HYPERTROPHY

Normal and Hypertrophied Left Ventricle

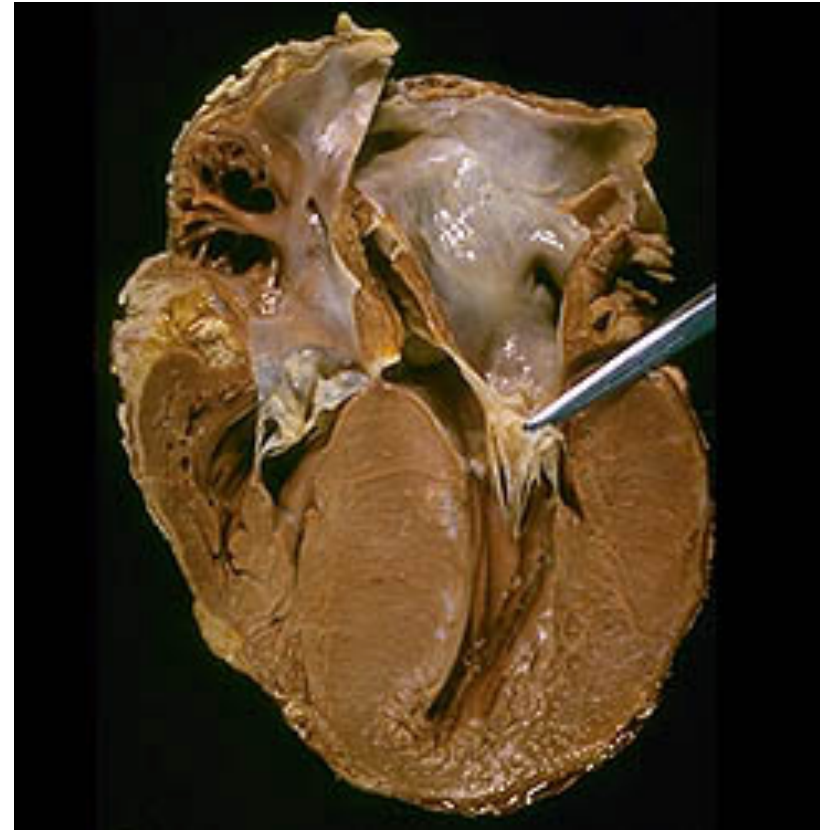
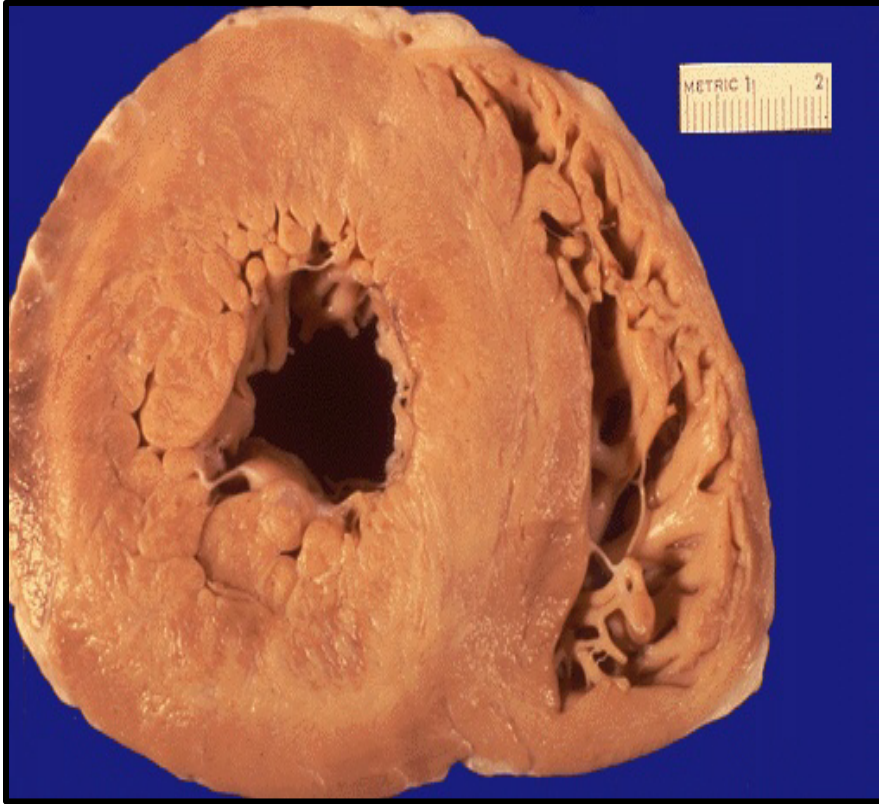

Left ventricular hypertrophy: The number of myocardial fibers does not increase, but their size increased in response to an increased workload



Normal ventricles

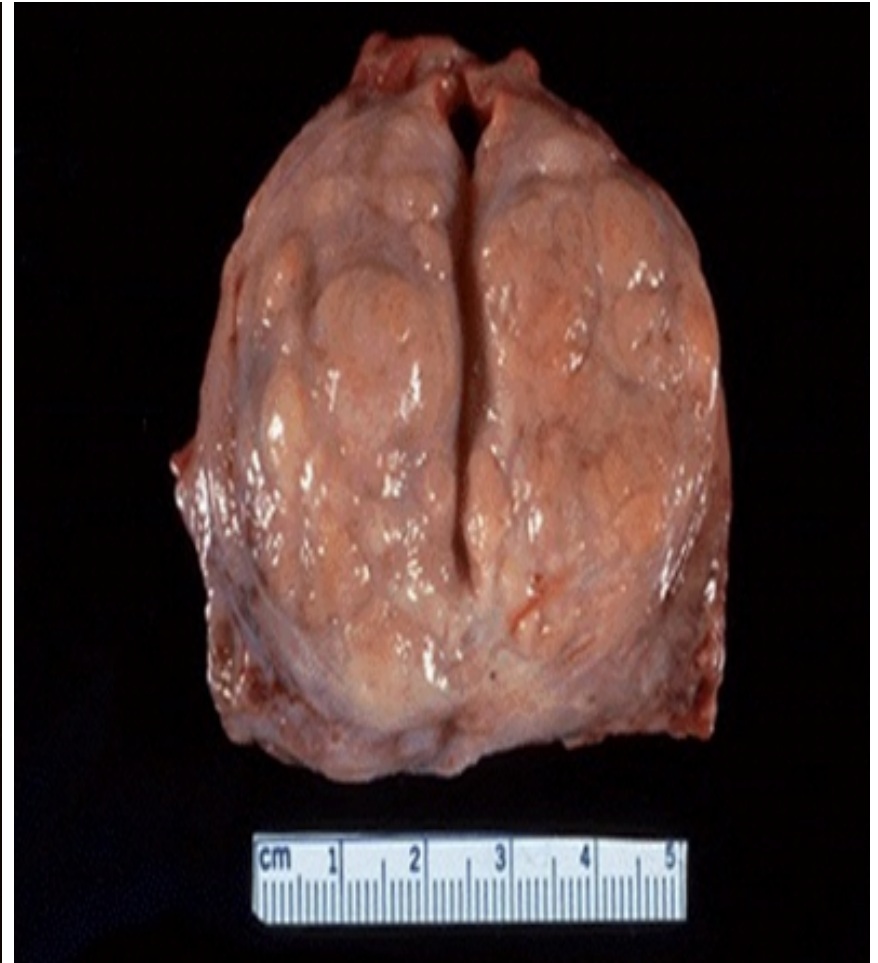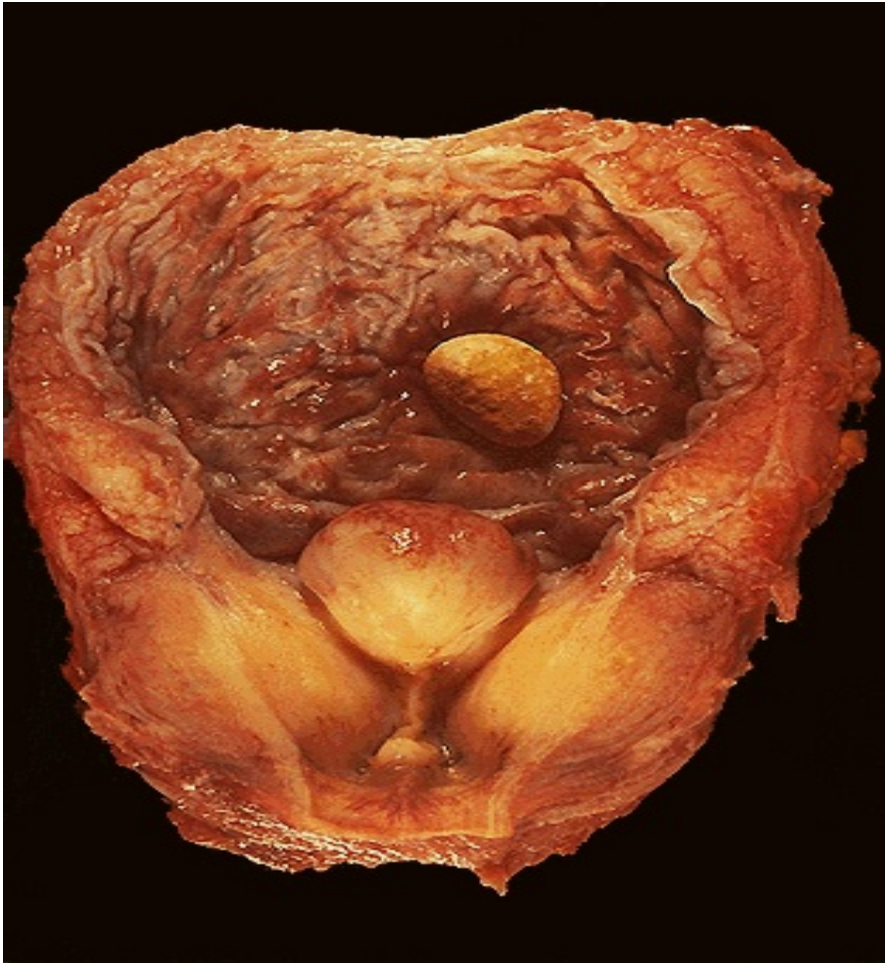Left Ventricular Hypertrophy



This cross section view (left) and longitudinal section view (right) of the heart. The heart is from a severe hypertensive patient. The left ventricle is grossly thickened. The myocardial fibers have undergone hypertrophy.

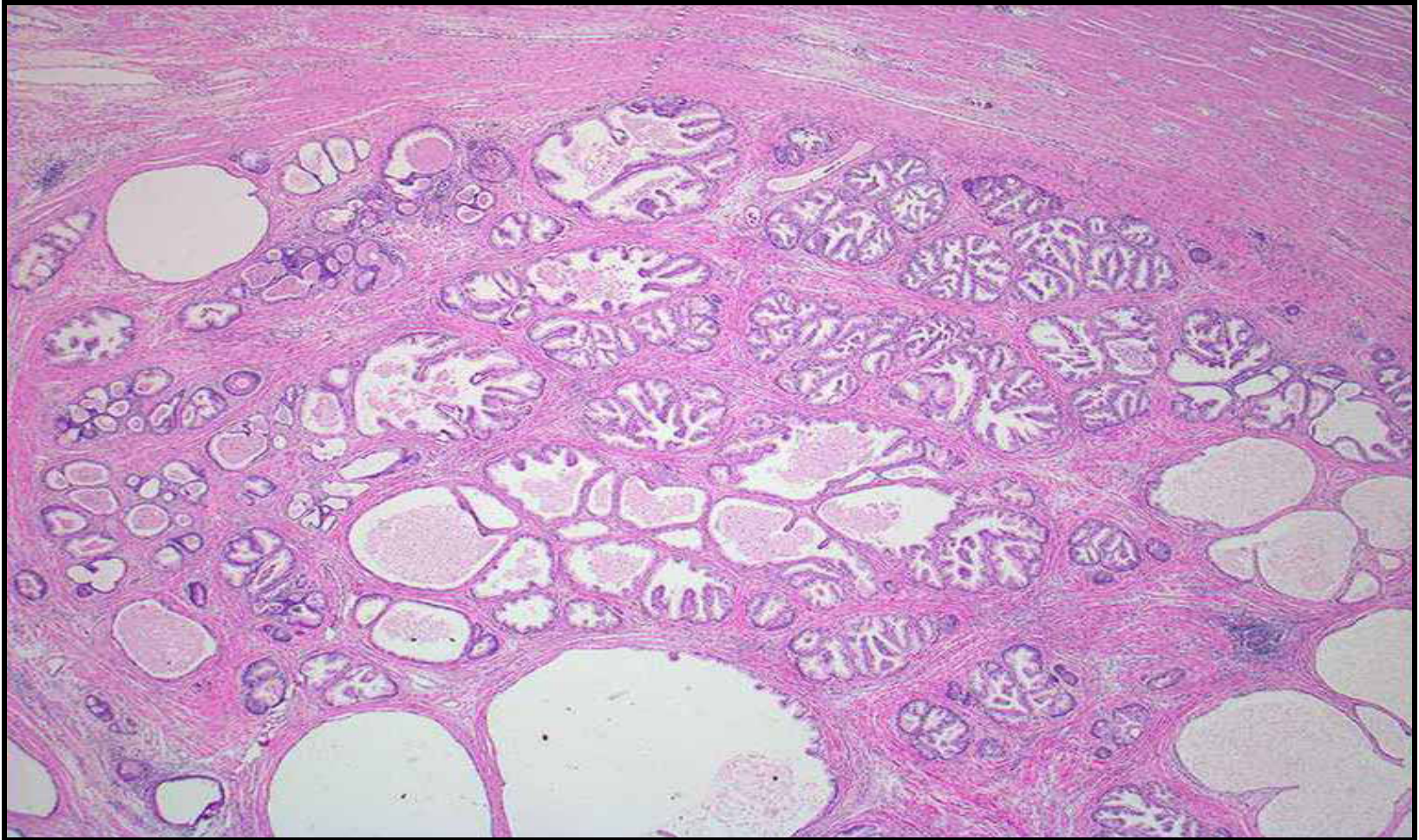10- PROSTATIC HYPERPLASIA

Prostatic Hyperplasia - Gross



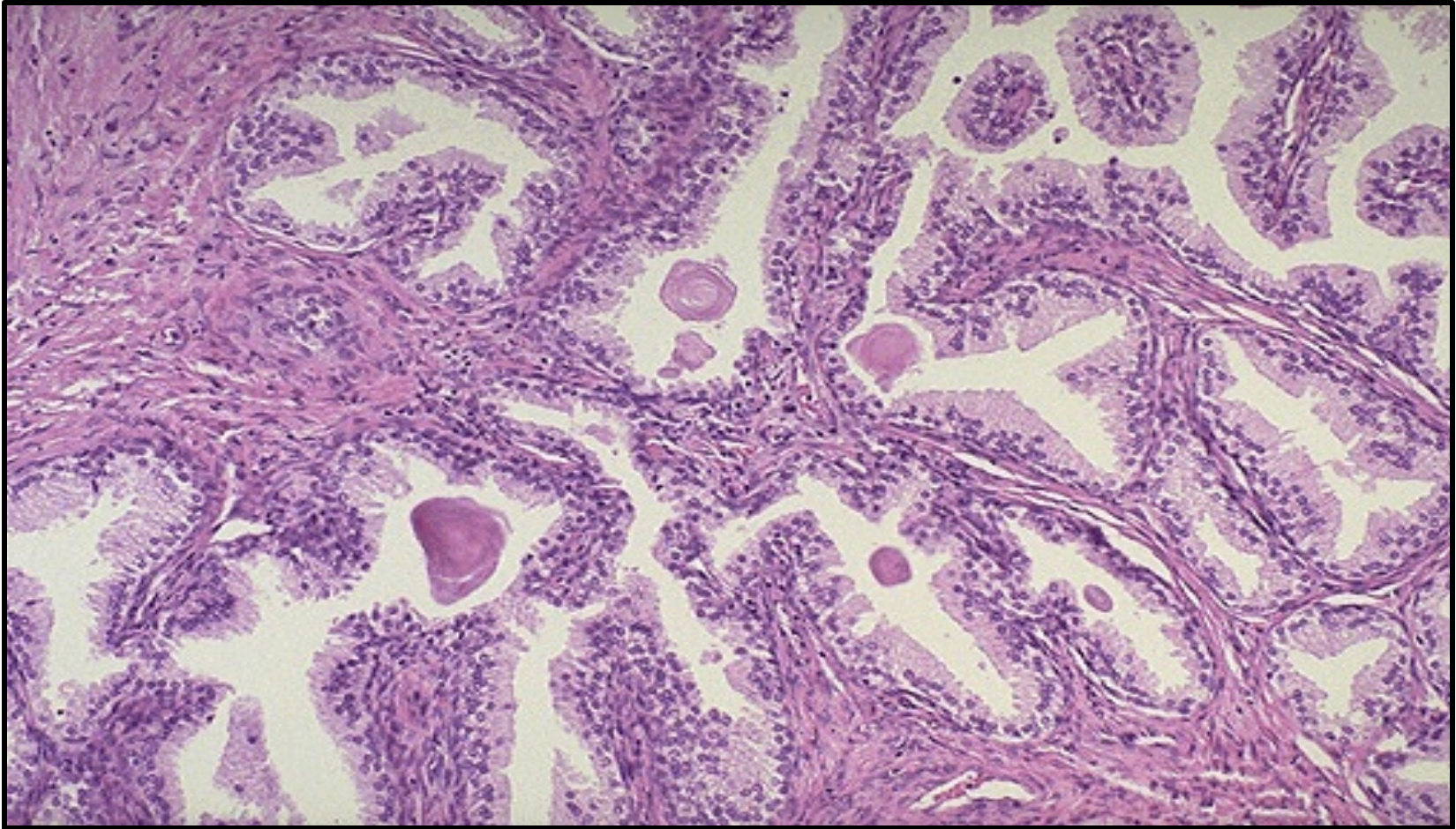
The normal adult male prostate is about 3 to 4 cm in diameter. The number of prostatic glands, as well as the stroma, has increased in this enlarged prostate

Prostatic Hyperplasia



Nodular hyperplasia of glandular and fibromuscular stromal tissue. Each nodule shows large number of glands of variable sizes lined by tall columnar epithelium and some are cystically dilated.

Prostatic Hyperplasia

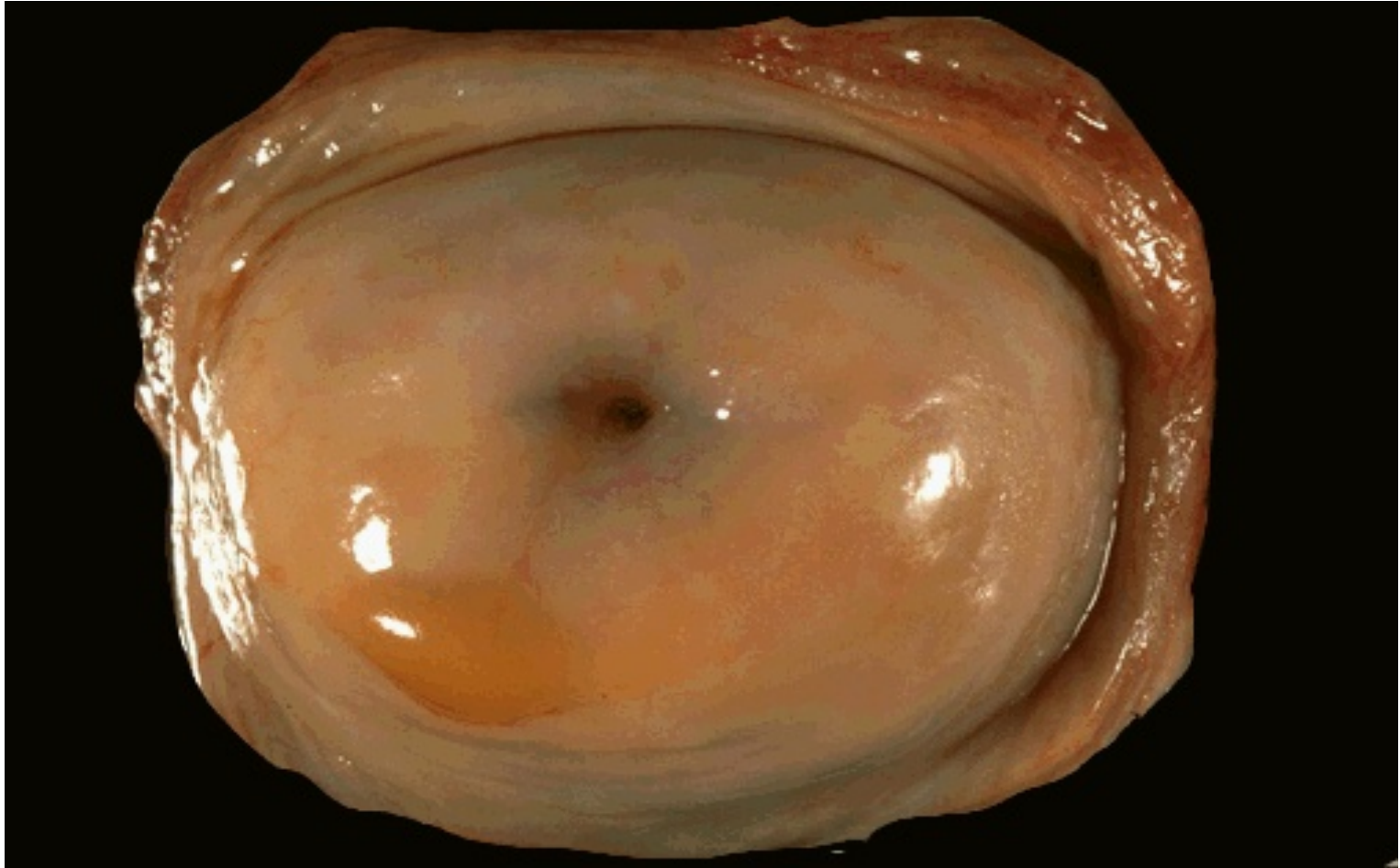


Here is one of the nodules of hyperplastic prostate, with many glands along with some intervening stroma.

The cells making up the glands are normal in appearance, but there are just too many of them. Eosinophilic hyaline corpora amylacea is present in some glands.

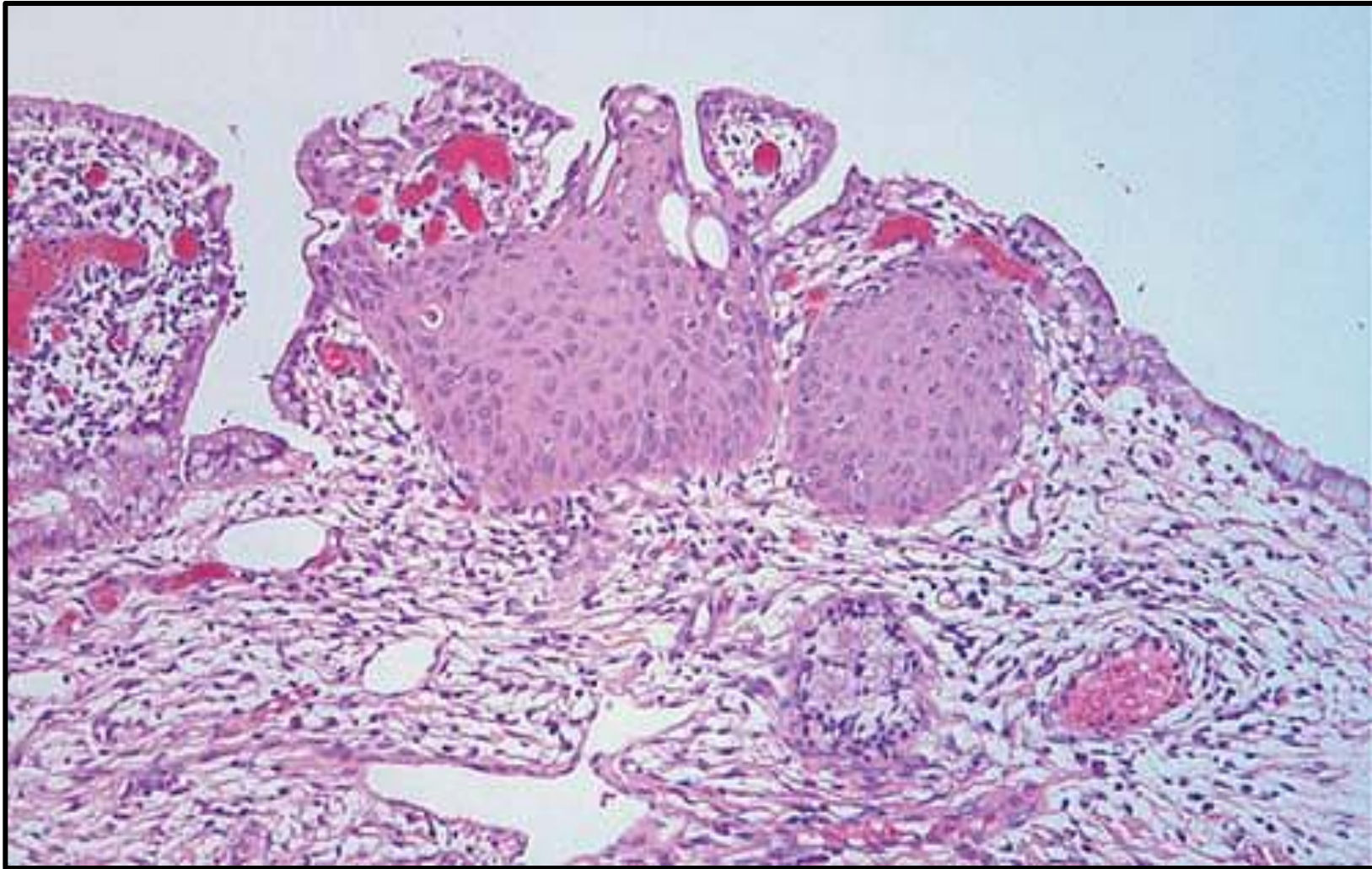
11 - SQUAMOUS METAPLASIA

Normal Uterine Cervix



Normal cervix with a smooth, glistening mucosal surface. There is a small rim of vaginal cuff from this hysterectomy specimen. The cervical os is small and round, typical for a nulliparous woman. The os will have a fish-mouth shape after one or more pregnancies

Endocervical Squamous Metaplasia

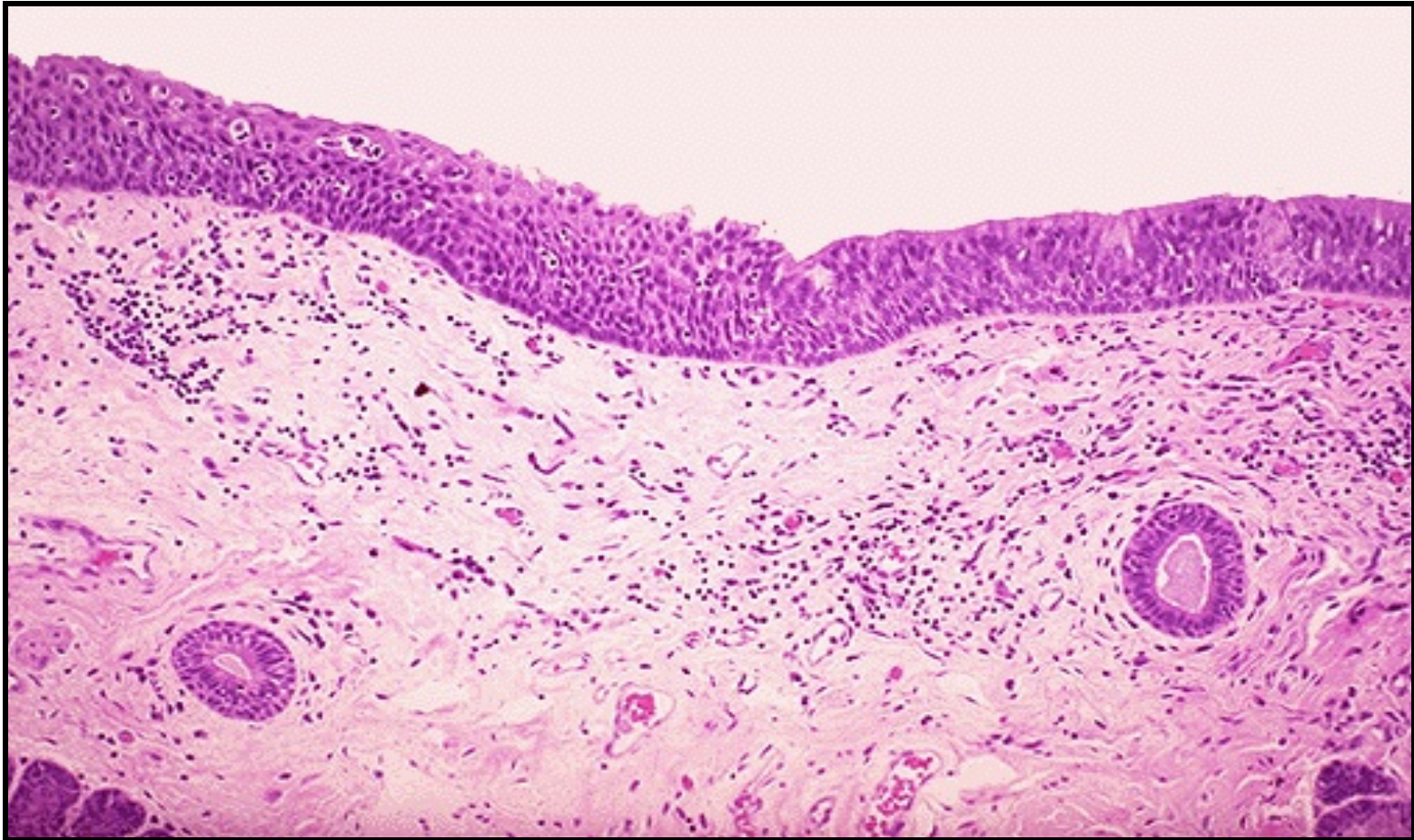


A section of endocervix shows the normal columnar epithelium at both margins and a focus of squamous metaplasia in the center.

Right

Laryngeal Squamous Metaplasia

Left



Metaplasia of laryngeal respiratory epithelium has occurred here in a smoker .The chronic irritation has led to an exchanging of one type of epithelium (the normal respiratory epithelium at the left) for another (the more resilient squamous epithelium at the right)

GOOD *LUCK*