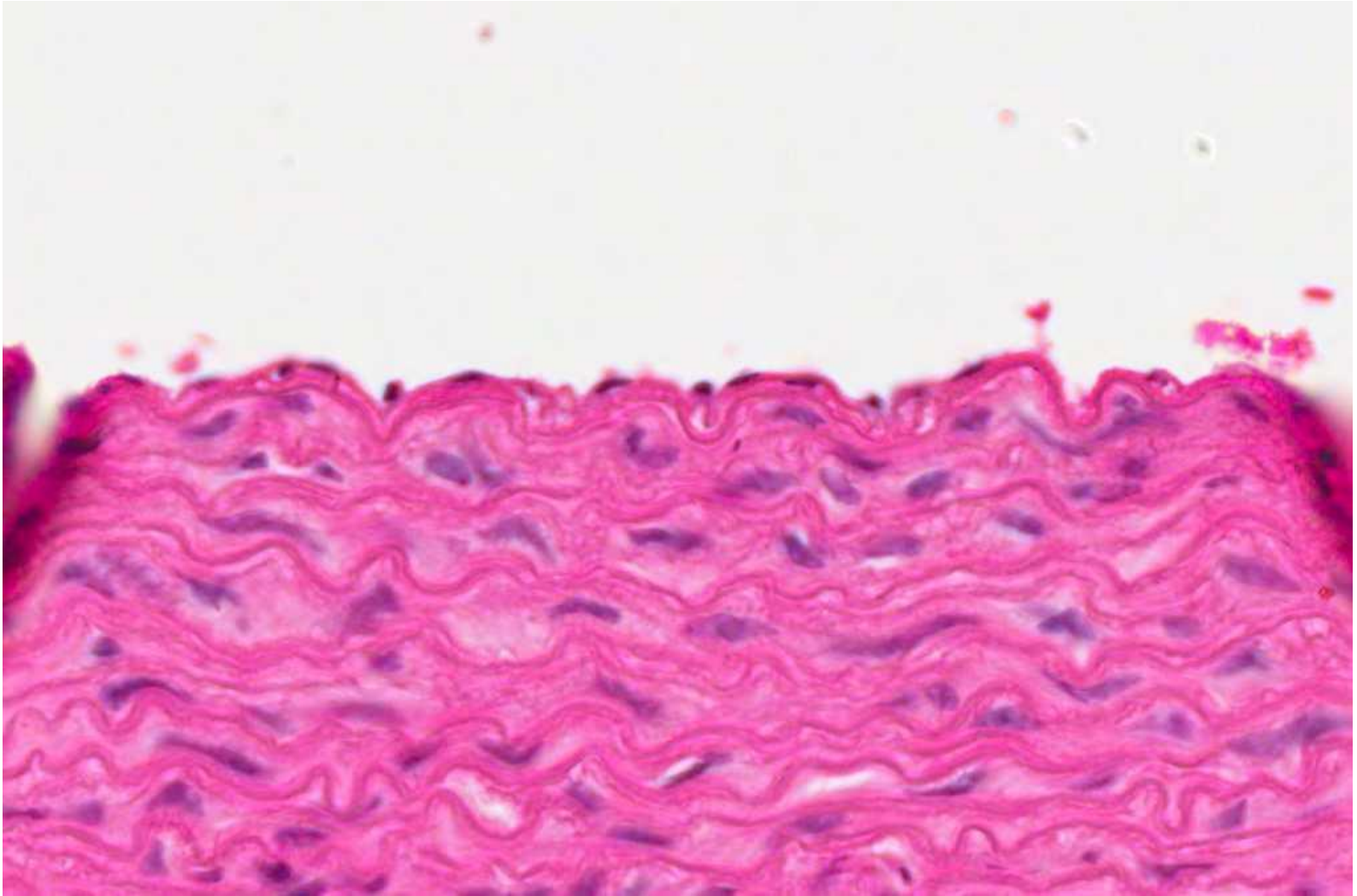
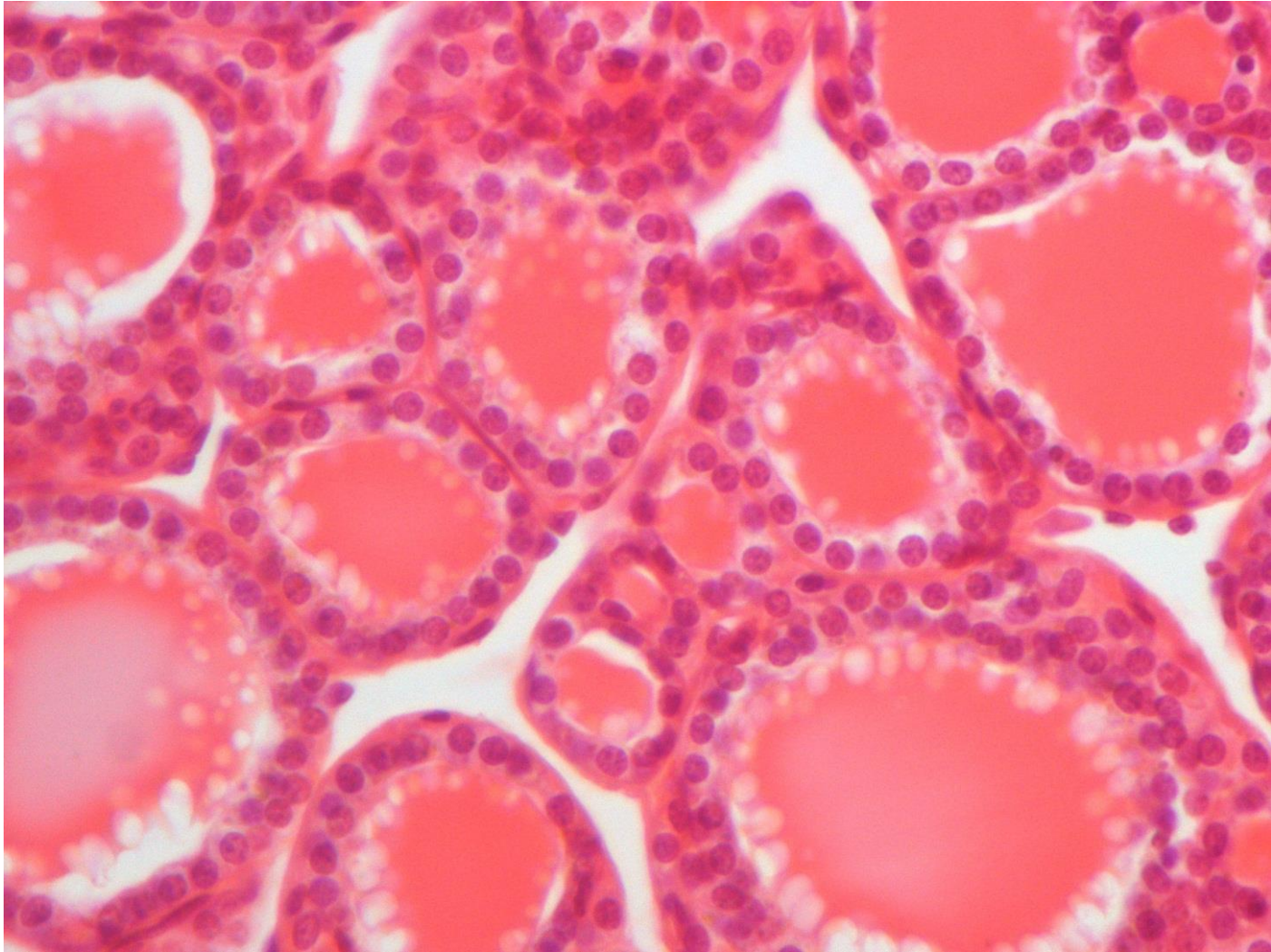


Practical Histology of Epithelium

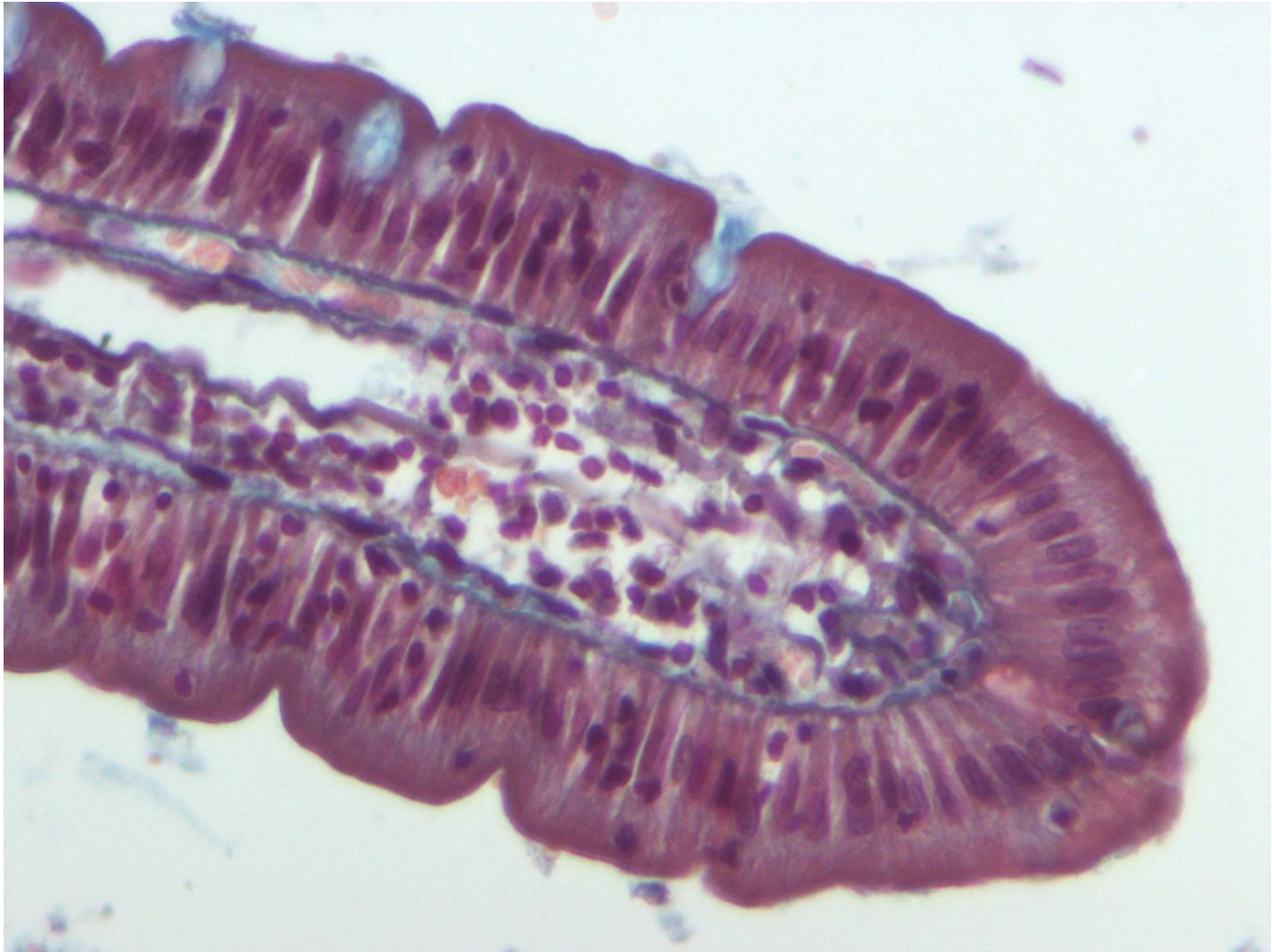
Simple squamous



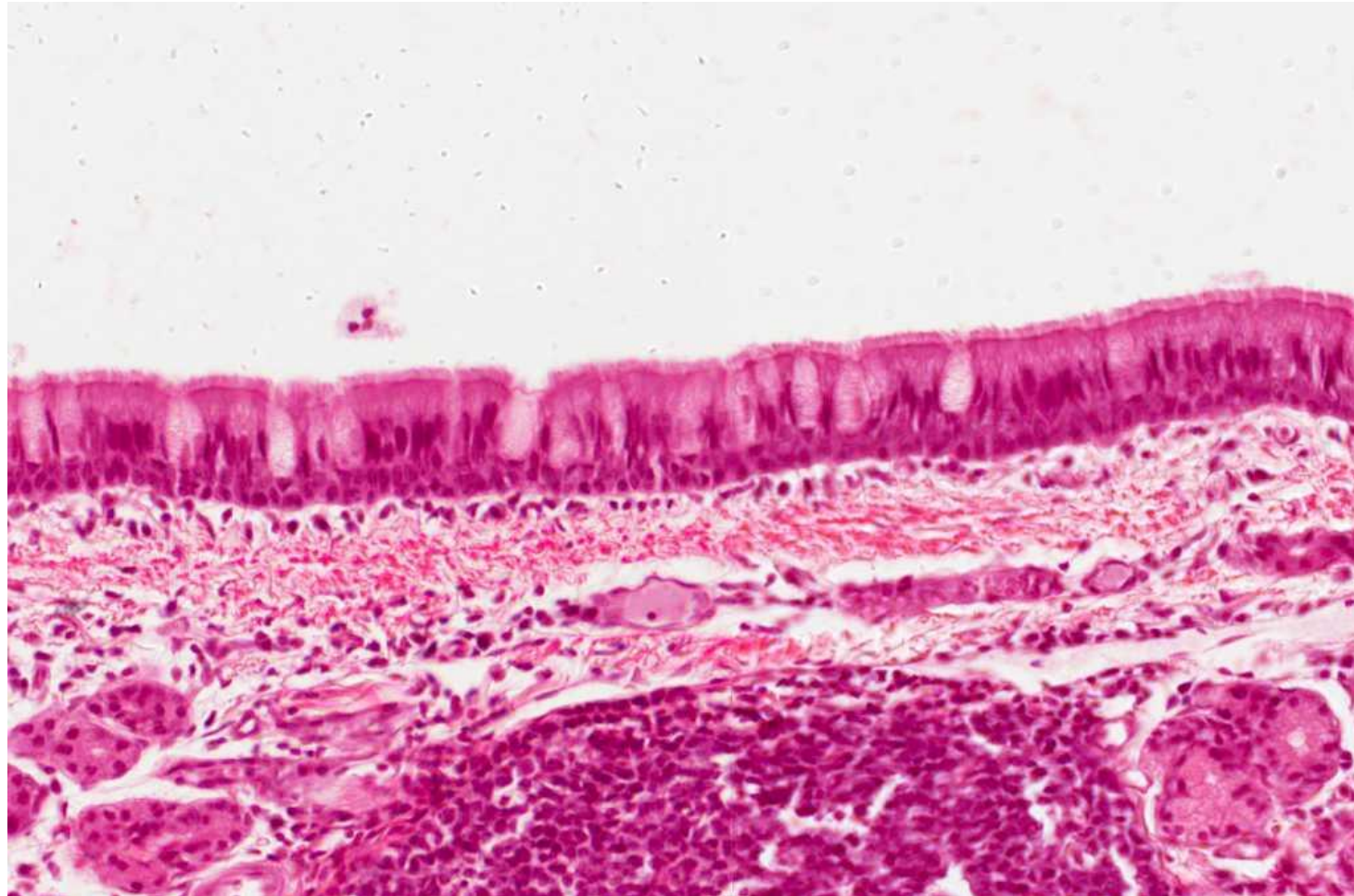
Simple cuboidal



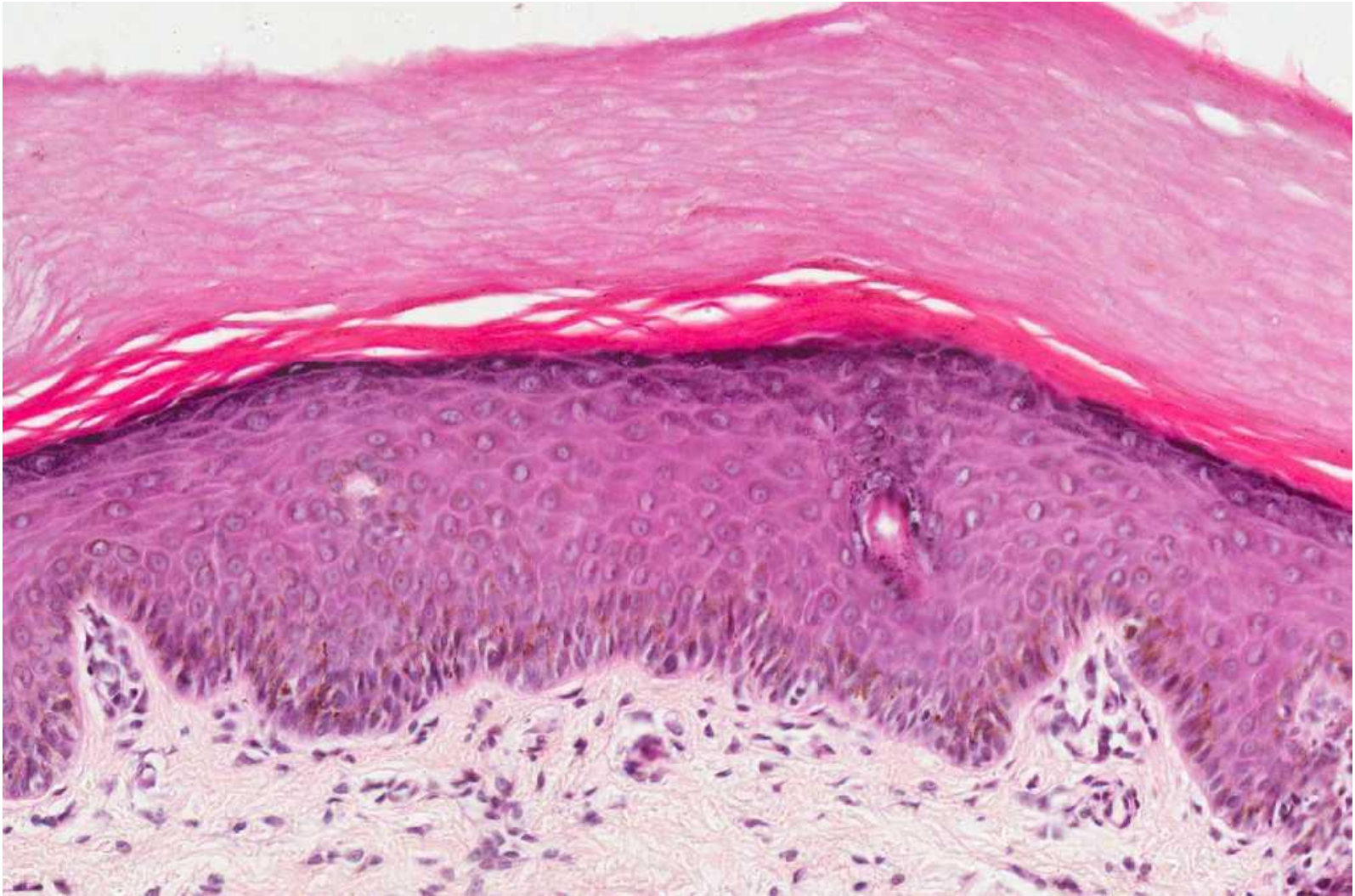Simple columnar



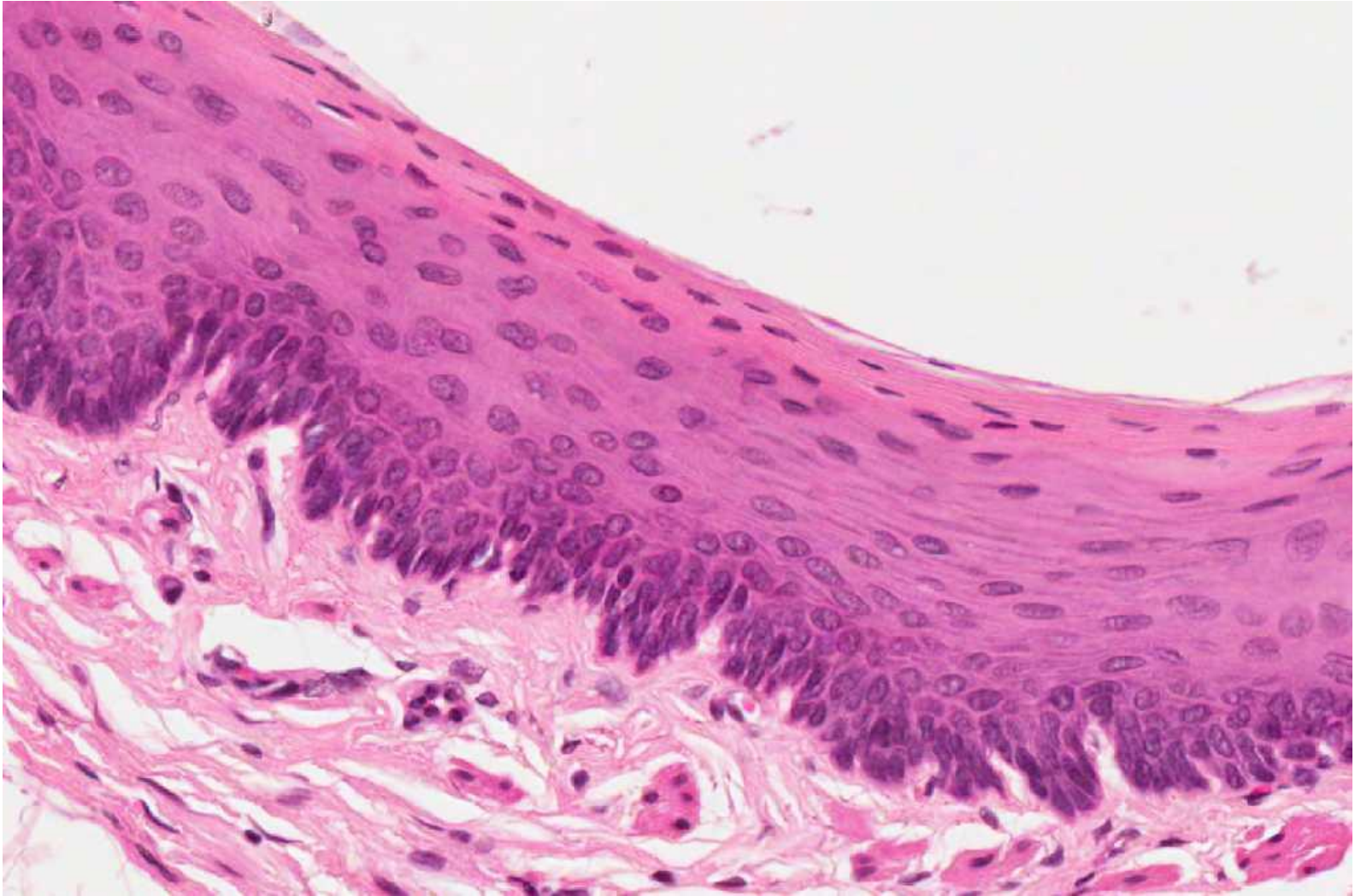
Pseudostratified columnar ciliated with goblet cells



Stratified squamous-keratinized



Stratified squamous non-keratinized



Transitional epithelium

