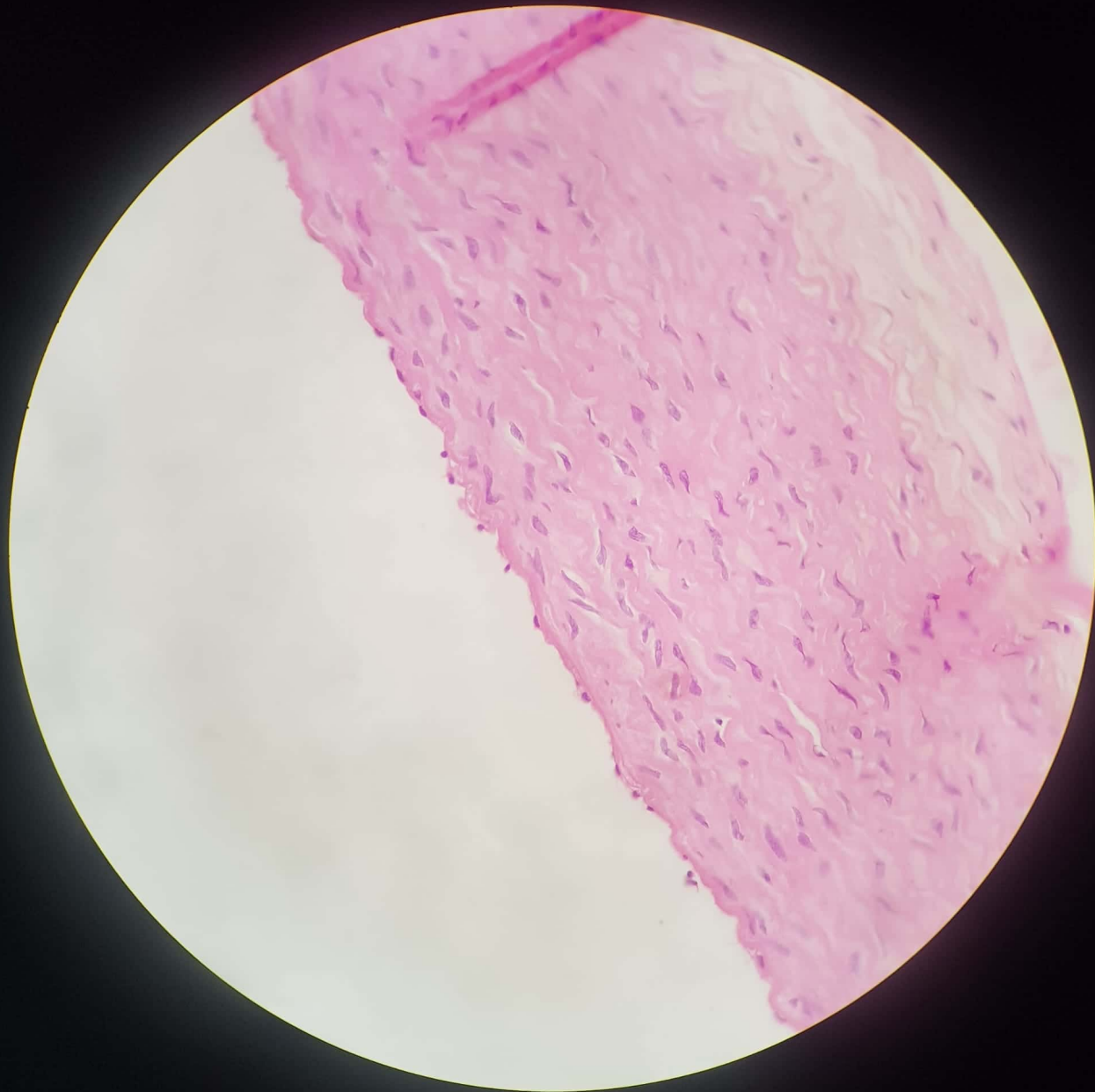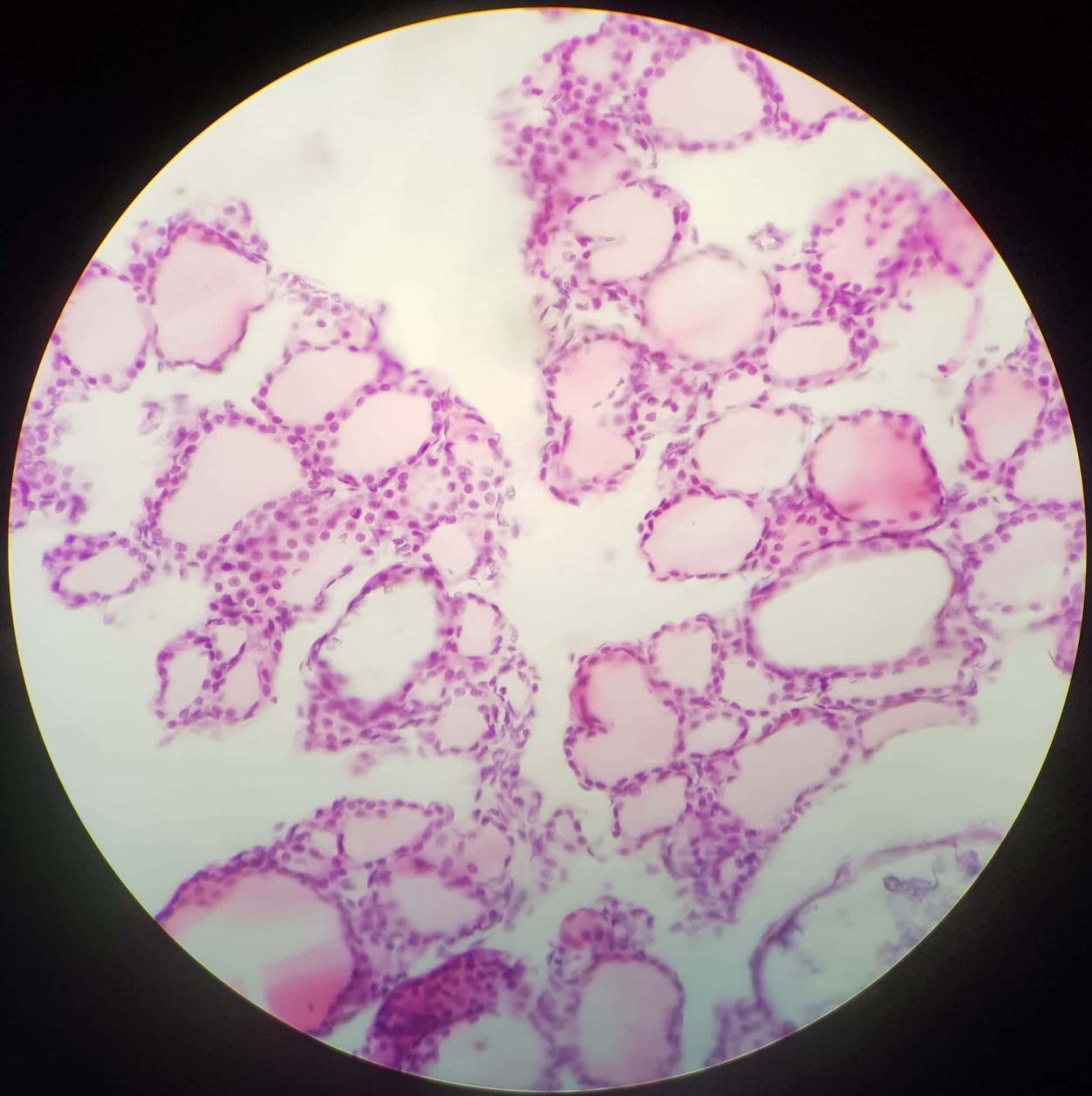

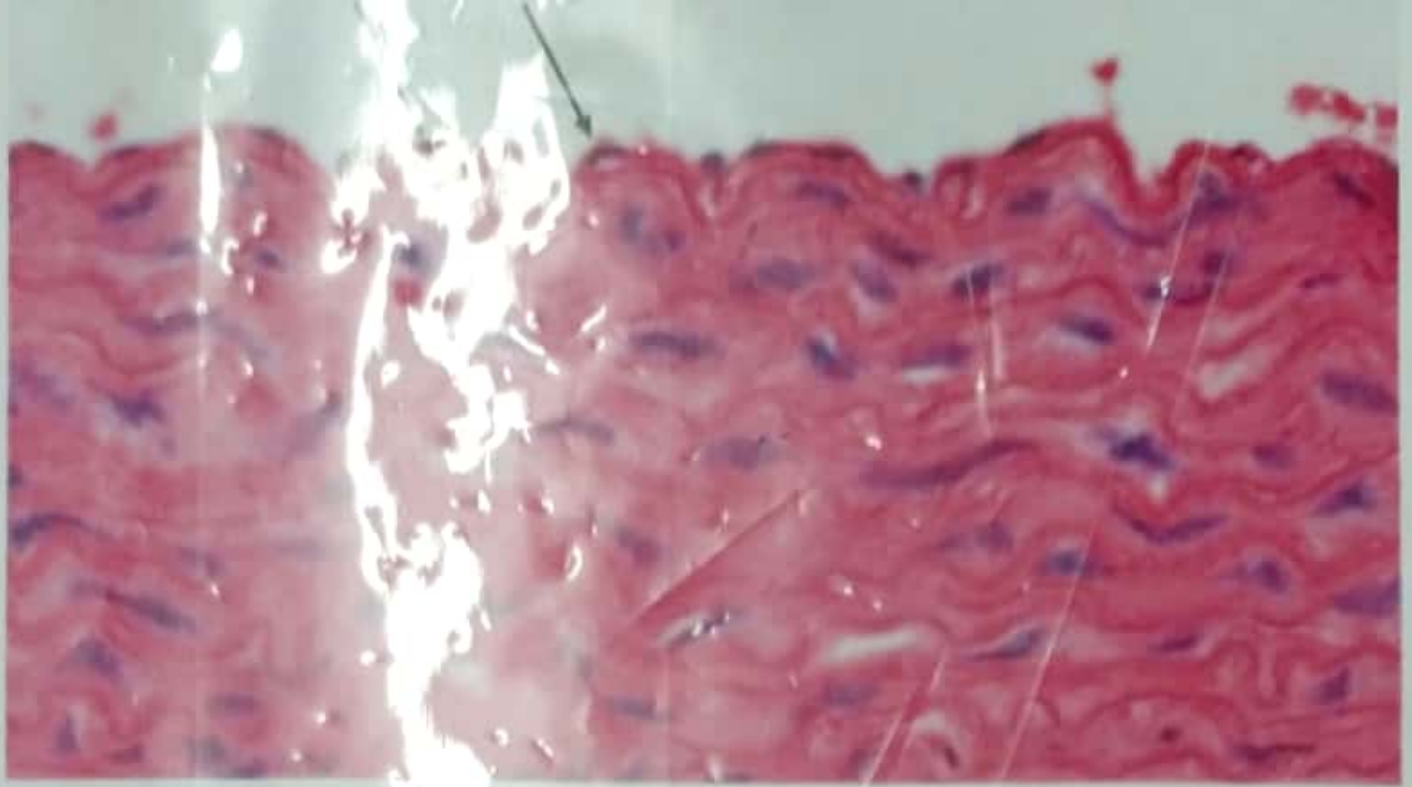
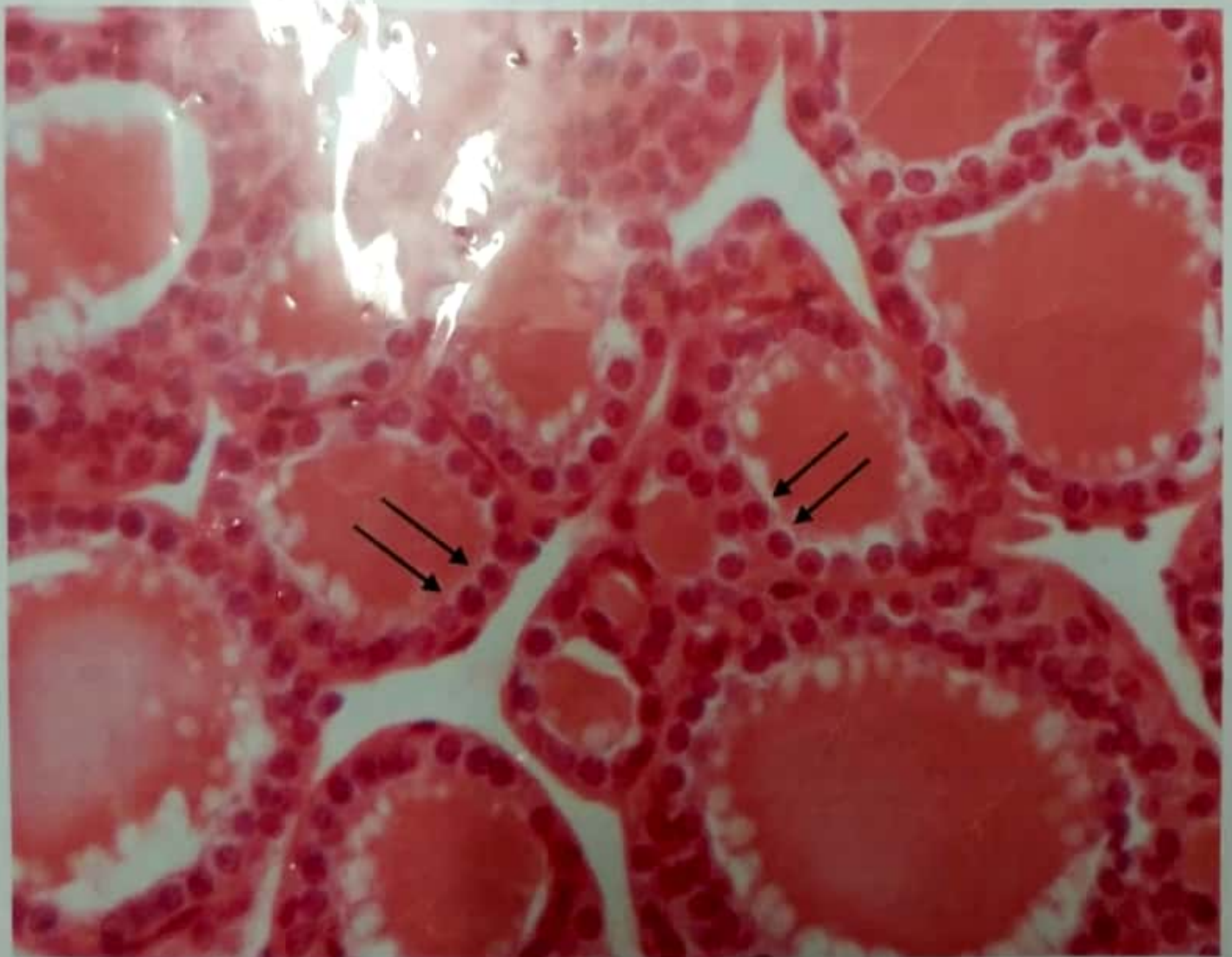Simple squamous Epithelium



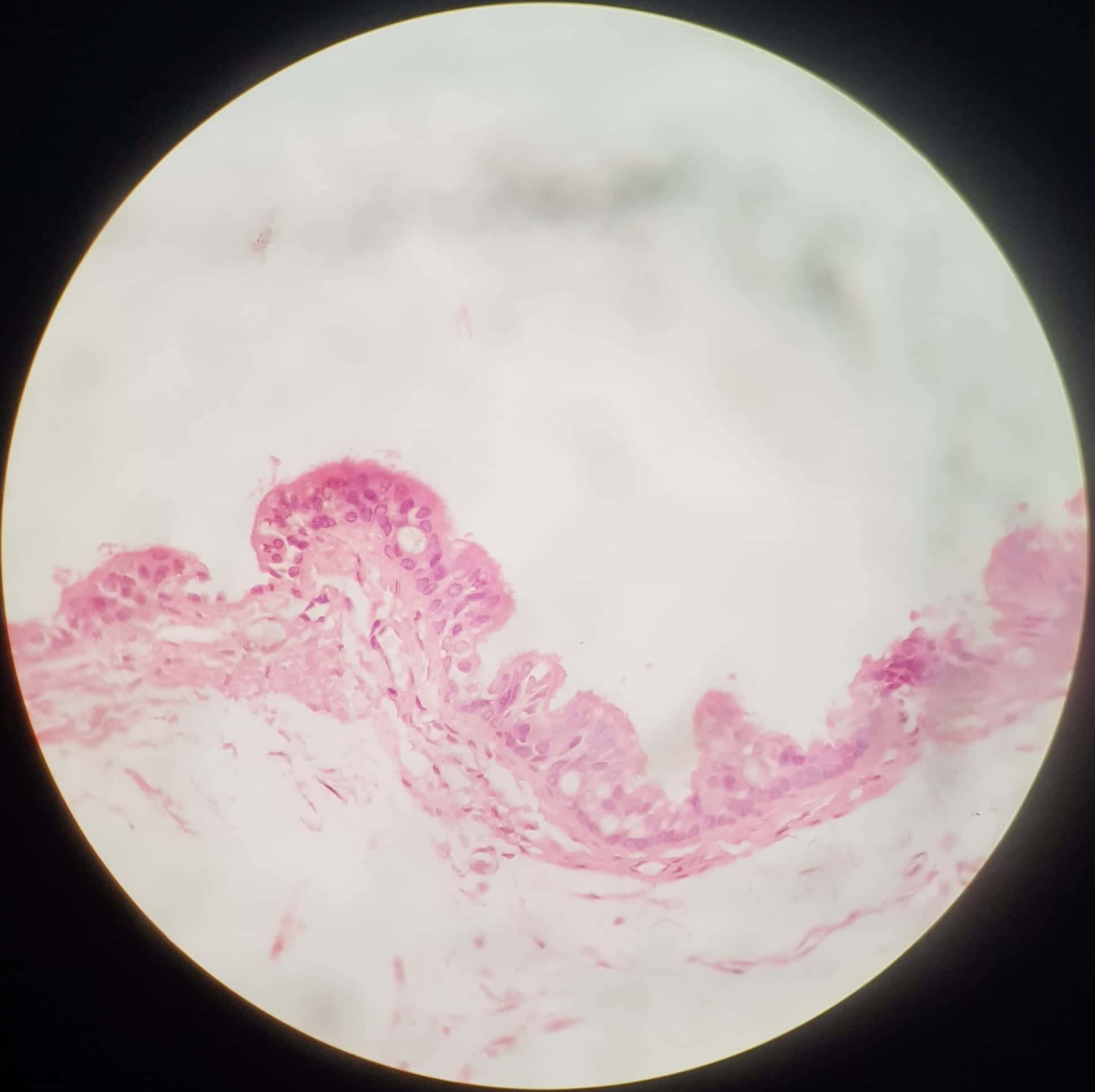
Simple Cuboidal Epithelium



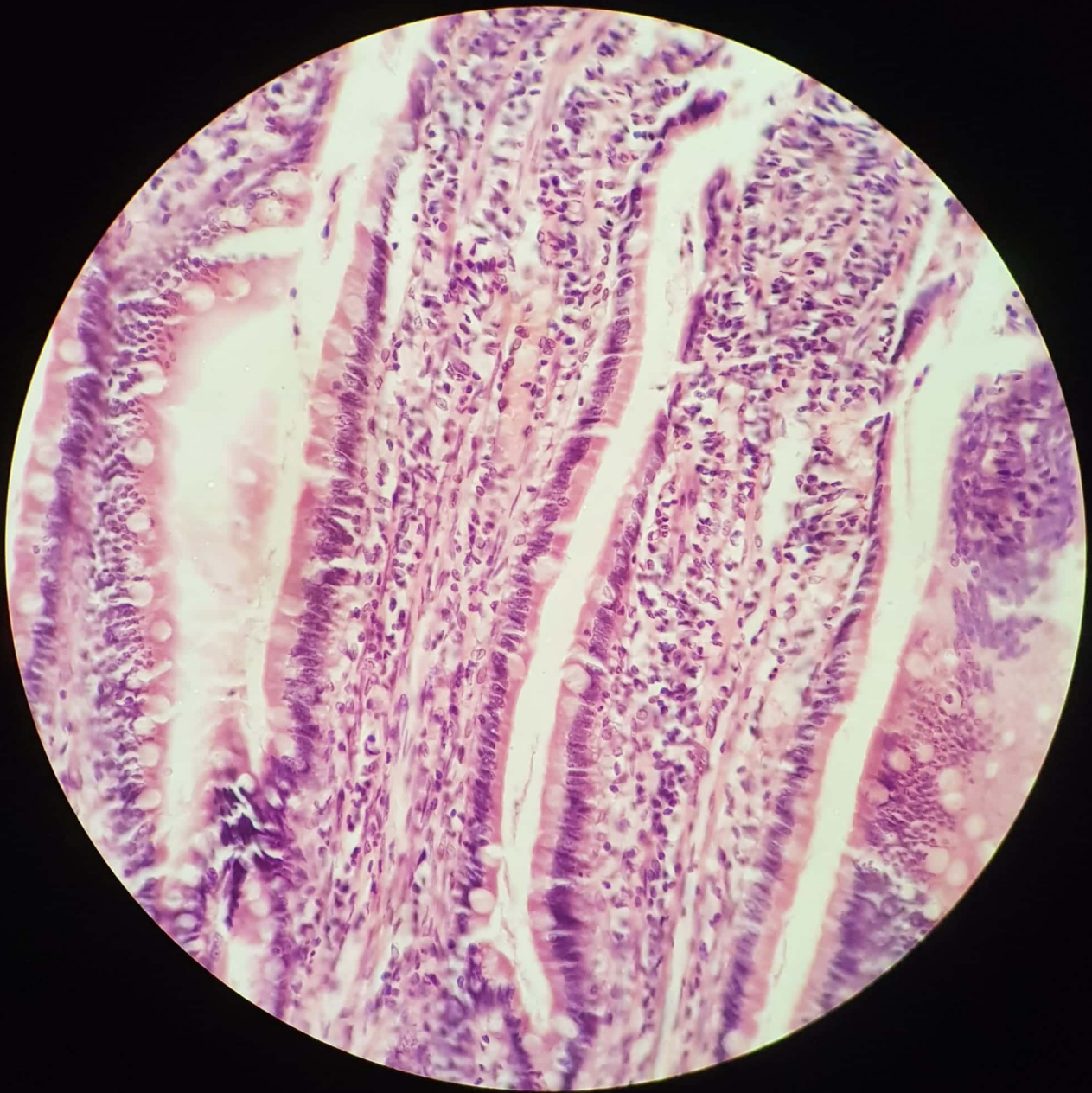
Simple Squamous Epithelium.



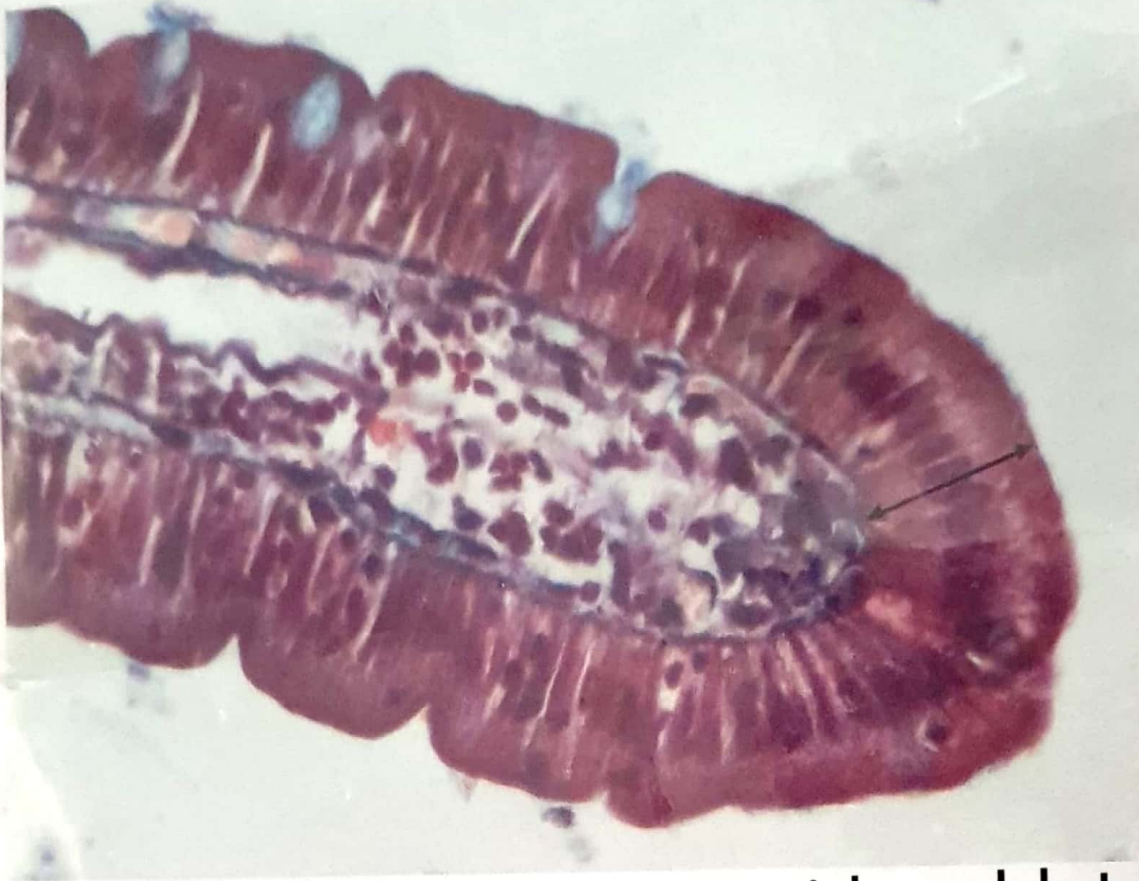Simple Cuboidal Epithelium.



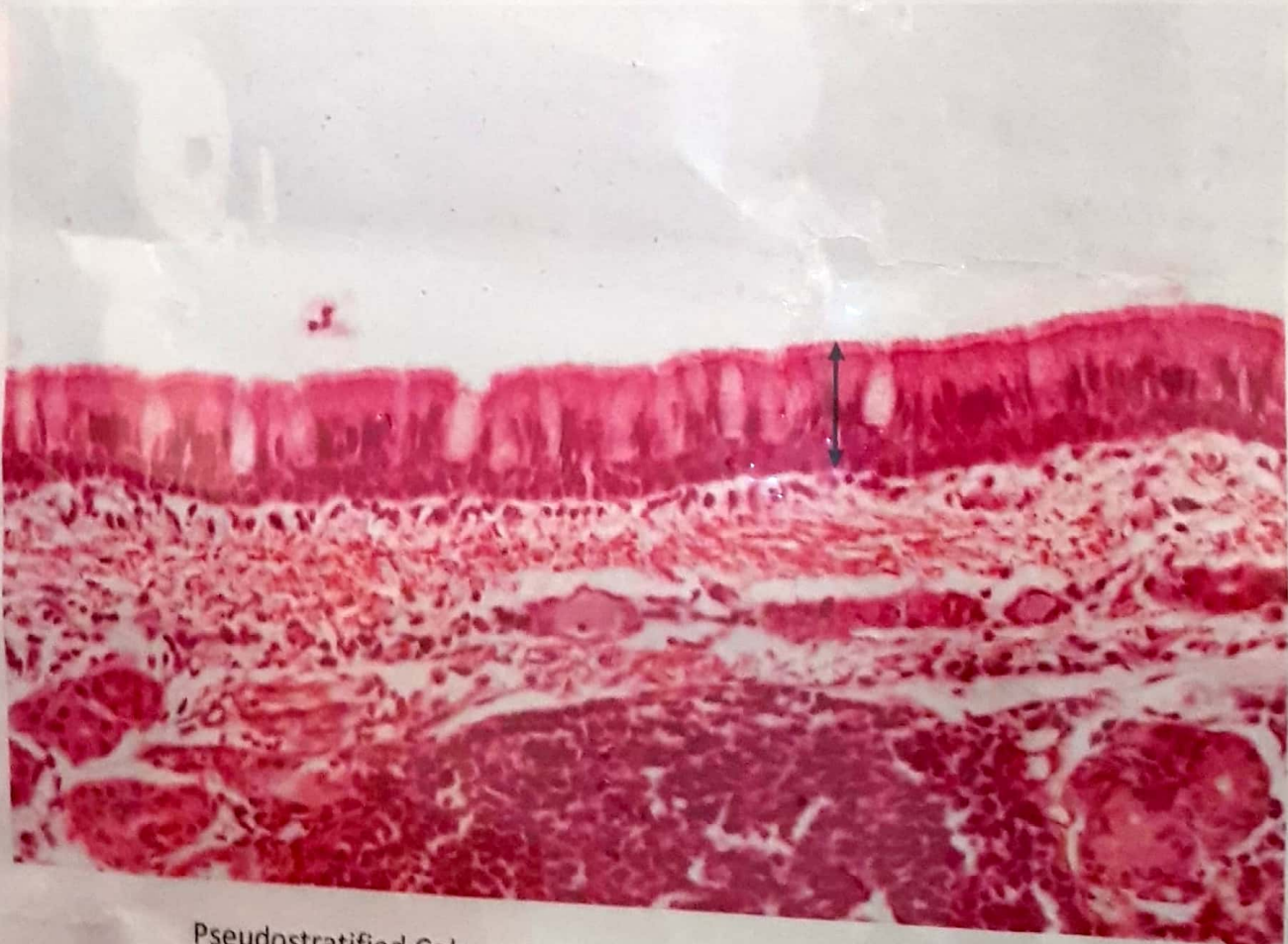**Pseudostratified Columnar Ciliated Epithelium
with Goblet Cells**



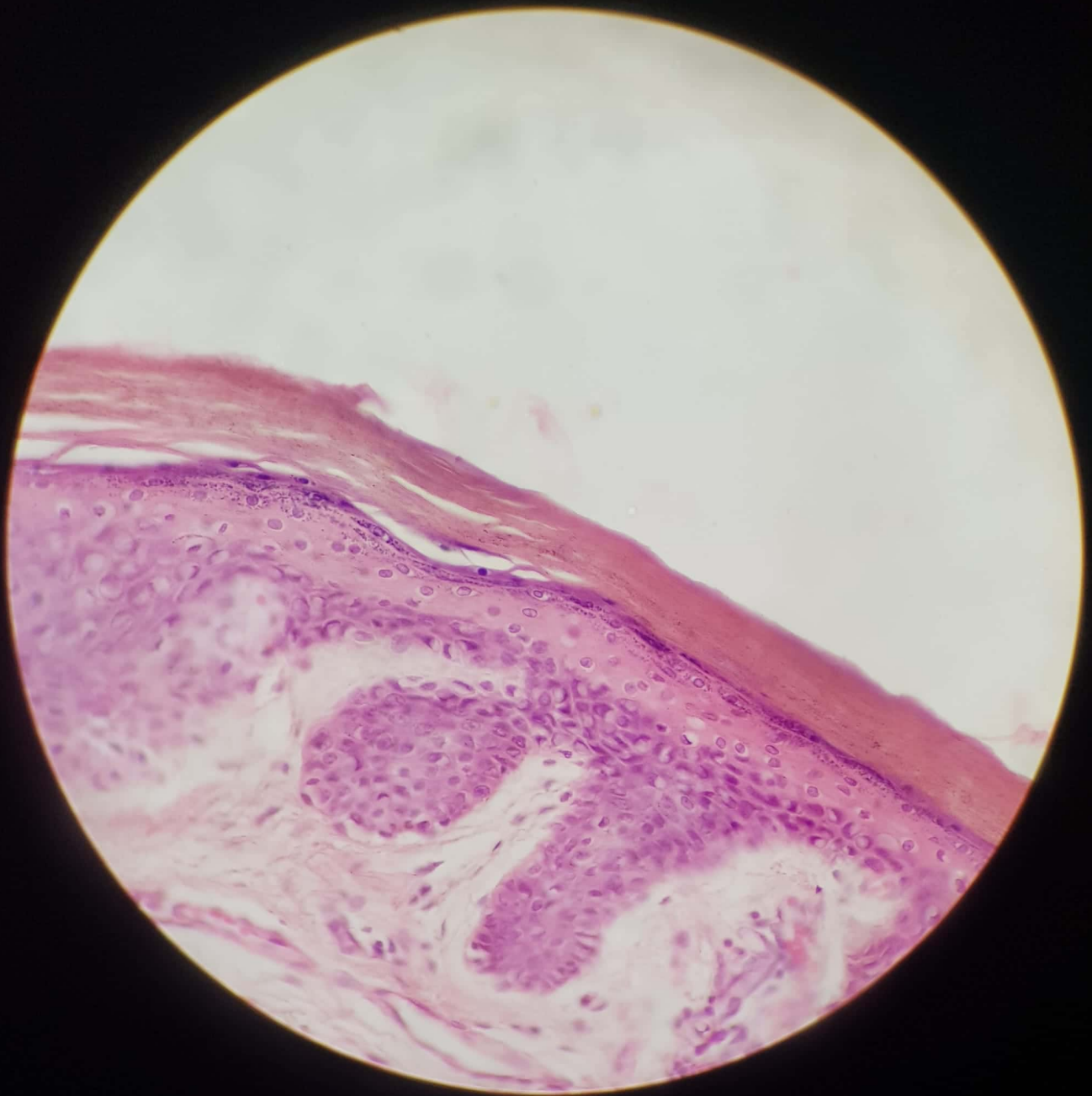
Simple Columnar Epithelium with Goblet Cells



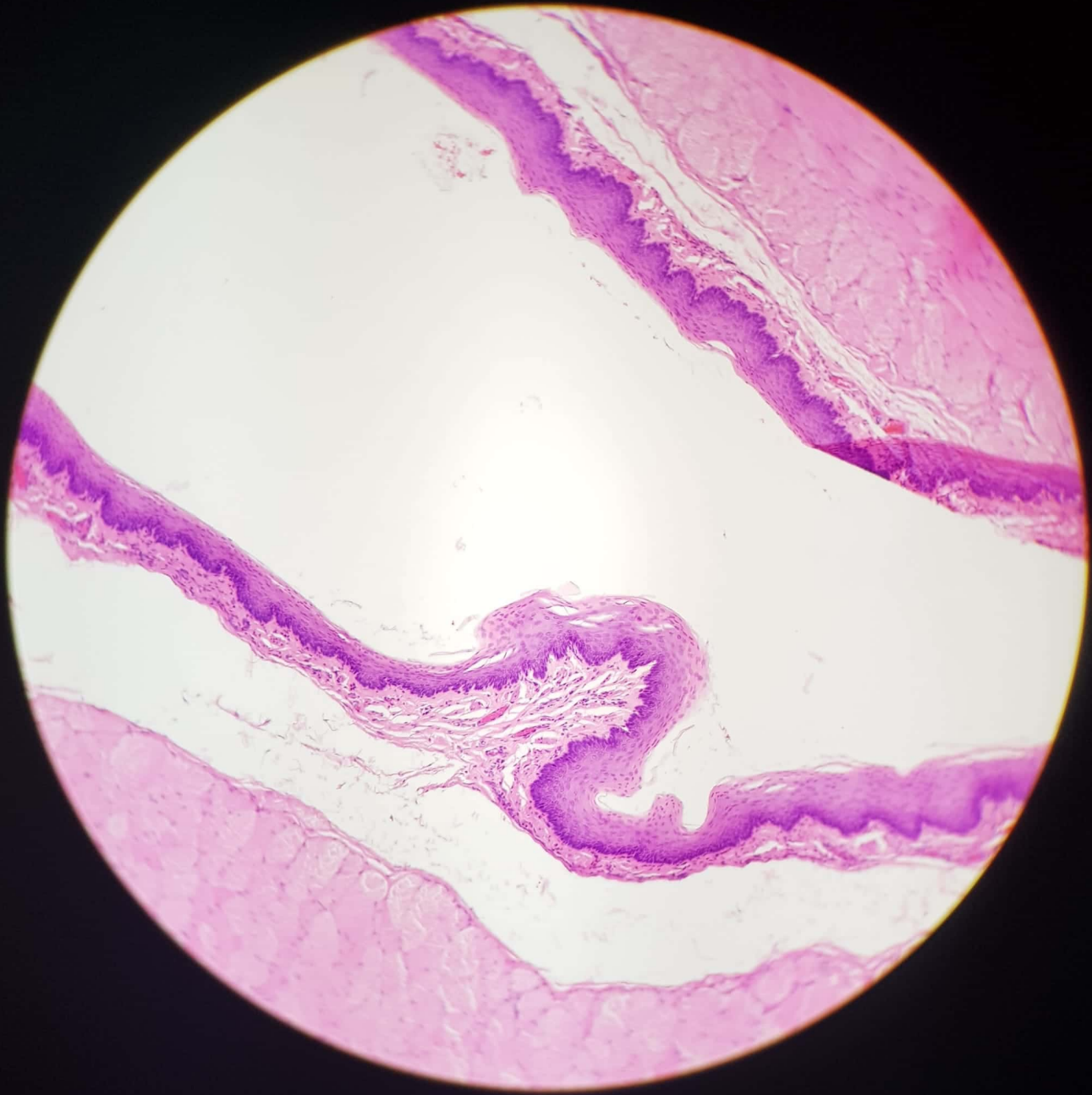
Simple Columnar Epithelium. with goblet cells



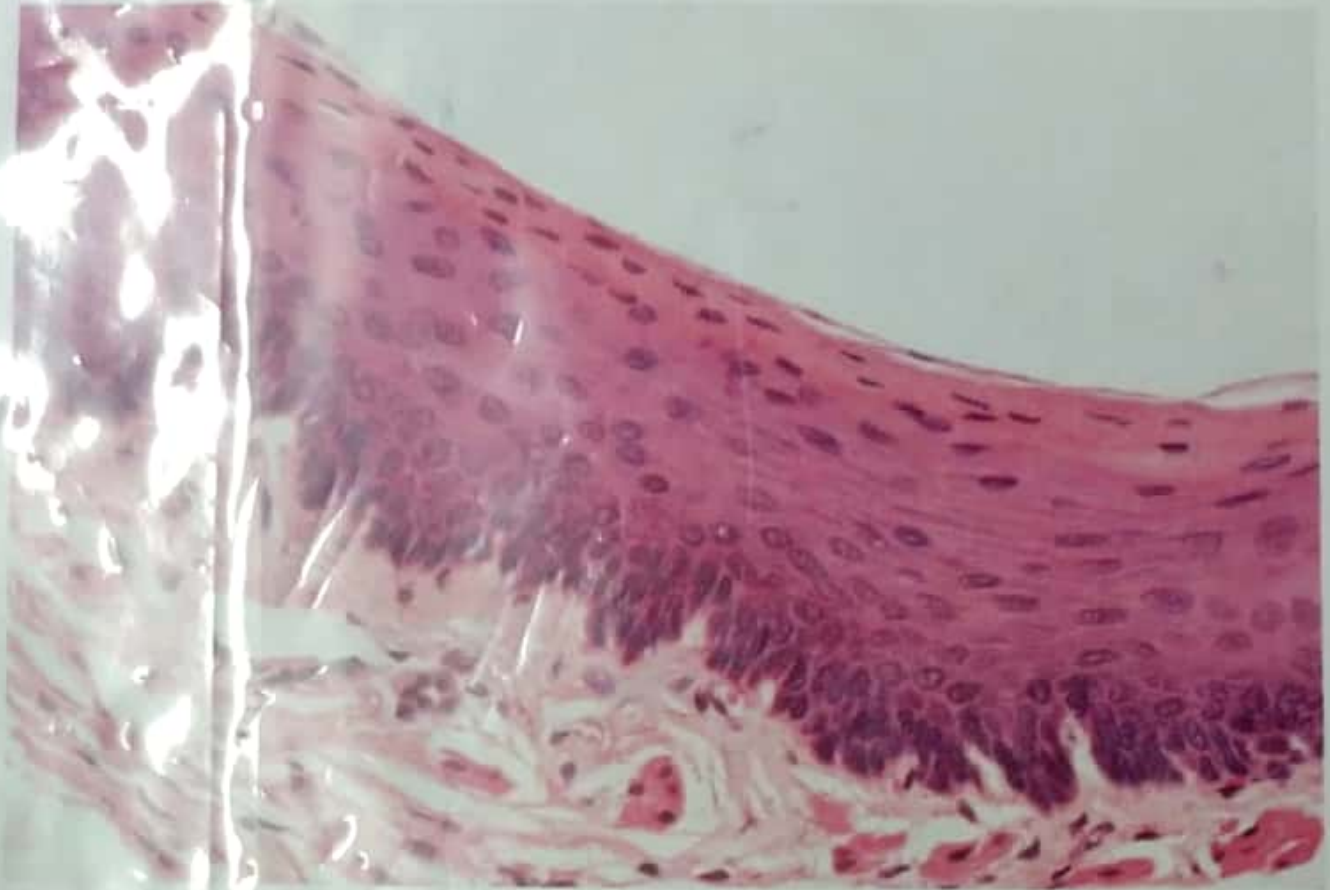Pseudostratified Columnar Ciliated Epithelium with Goblet Cells



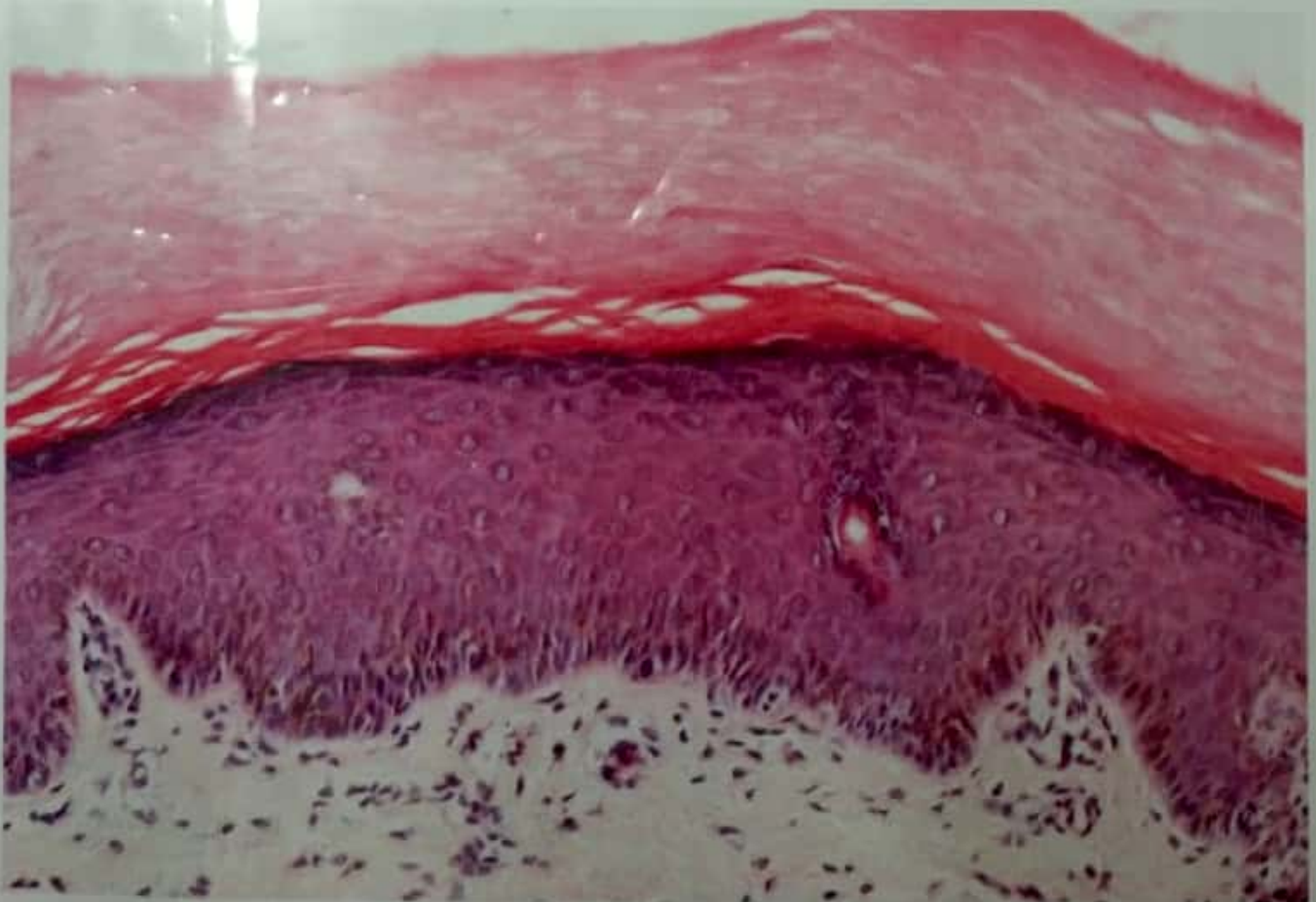
Keratinized Stratified Squamous Epithelium



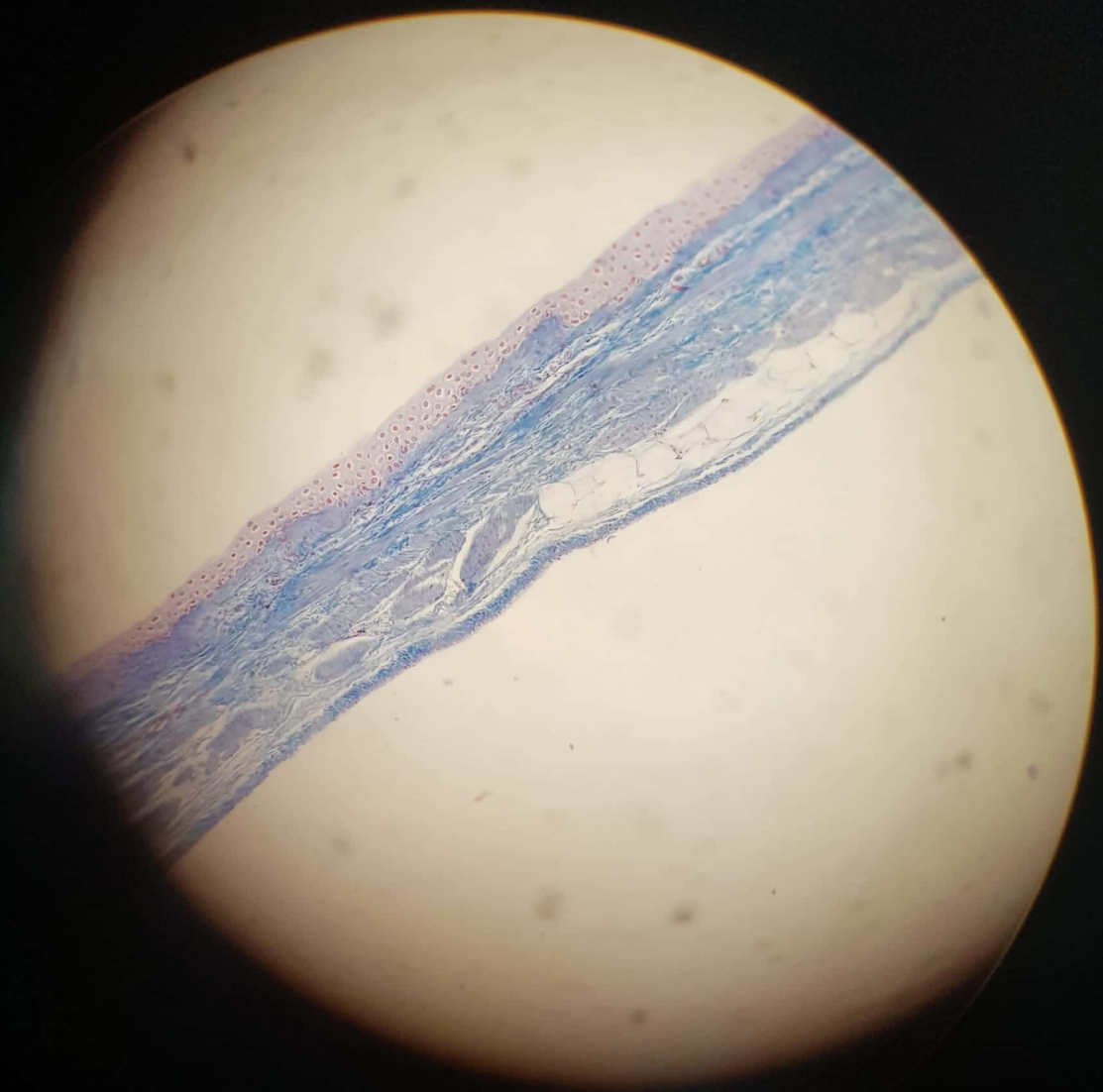
Non-Keratinized Stratified Squamous Epithelium



Non-Keratinized Stratified Squamous Epithelium.

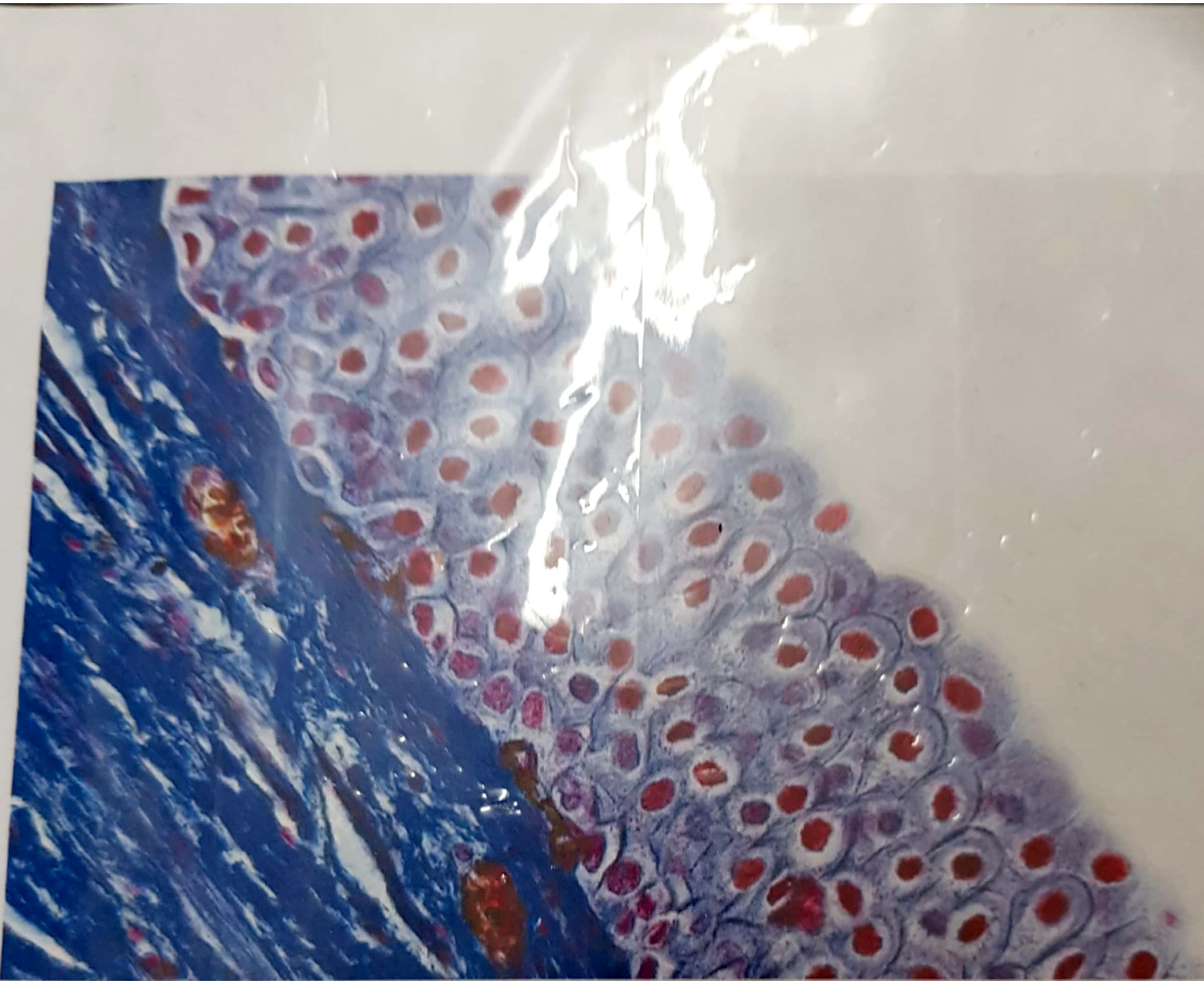


Keratinized Stratified Squamous Epithelium.



Transitional Epithelium

110
120



Transitional Epithelium.