



AXILLARY & MEDIAN NERVES

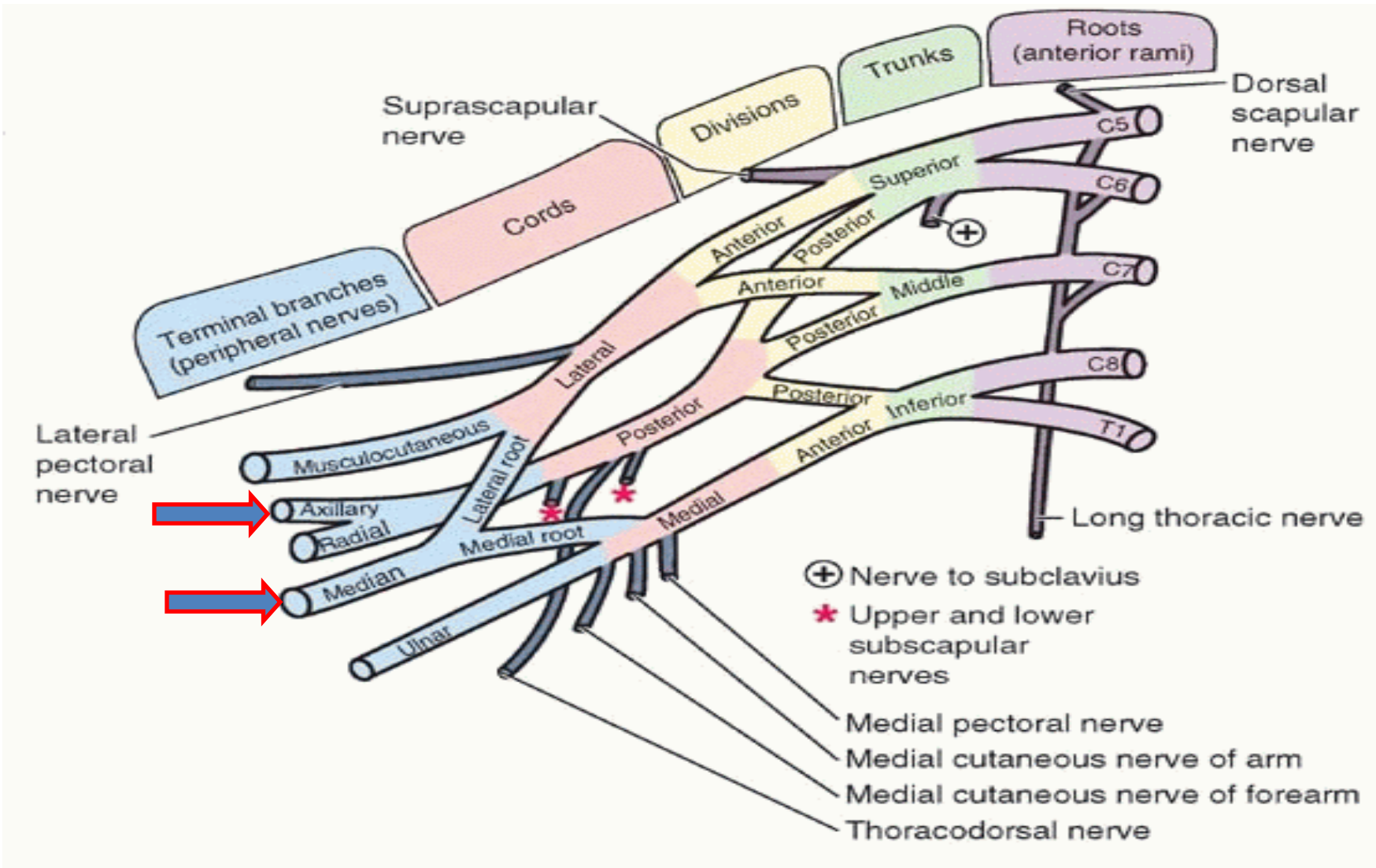
Dr Jamila ELMedany

Objectives

At the end of the lecture, students should be able to:

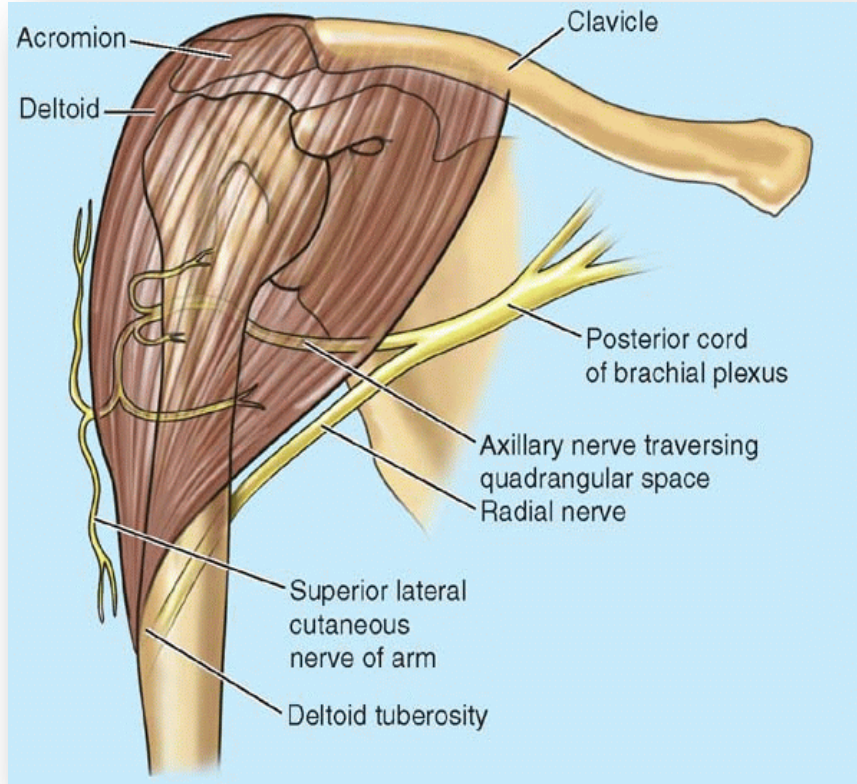
- Describe the origin, course, relations, branches and distribution of the axillary & median nerves
- Describe the common causes and affects of injury to the axillary and median nerves

Brachial plexus



Axillary Nerve

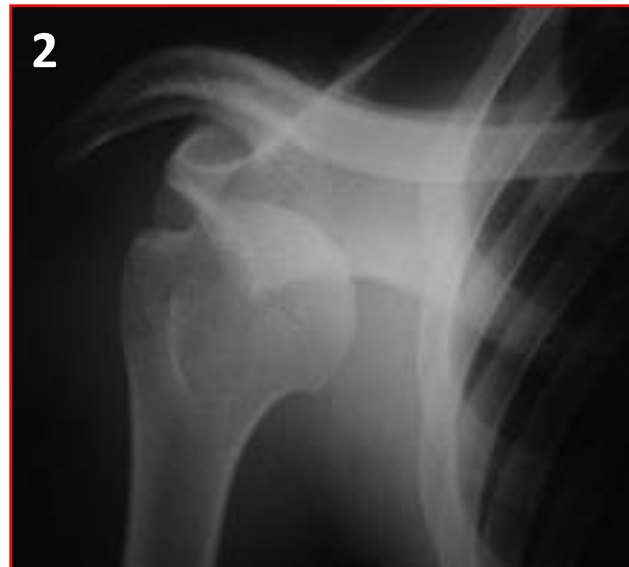
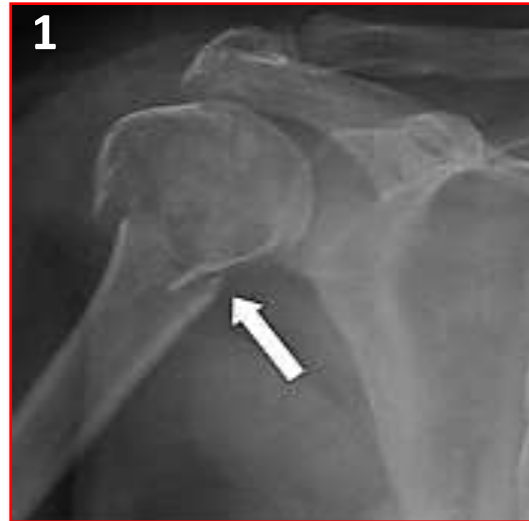- **Origin:** (C 5 & 6).
- Posterior cord of brachial plexus
- **Course:**
- It passes inferiorly and laterally along the posterior wall of the axilla to exit
- Then, it passes posteriorly **around the surgical neck of the humerus.**
- It is accompanied by the **posterior circumflex humeral artery.**



- **Branches:**
- **Motor** to the **deltoid and teres minor muscles.**
- **Sensory:** superior lateral cutaneous nerve of arm that loops around the posterior margin of the deltoid muscle to innervate skin in that region.

Axillary Nerve Lesion

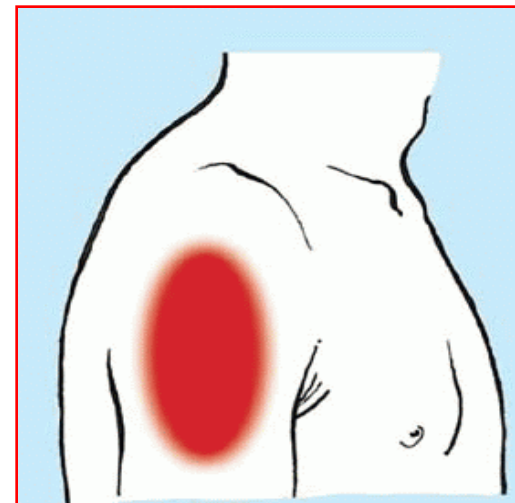
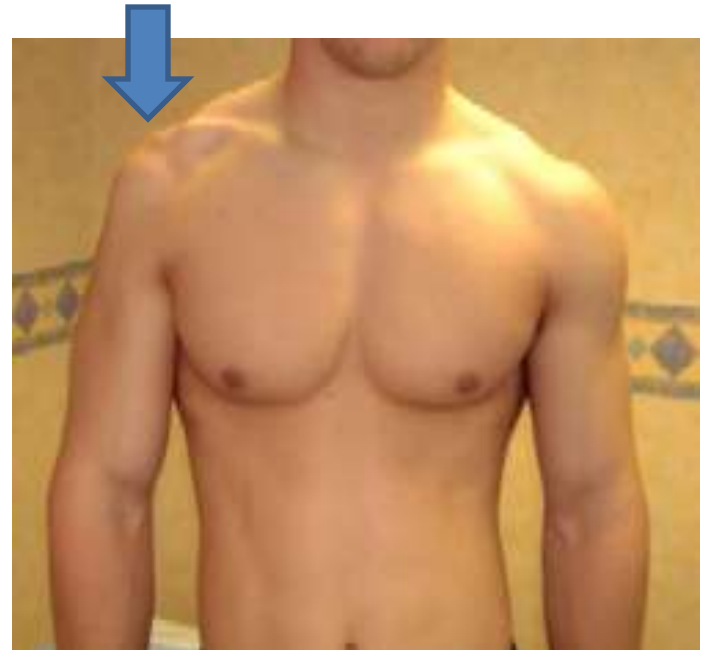
- The axillary nerve is usually injured due to:
 1. Fracture of surgical neck of the humerus.
 2. Downward dislocation of the shoulder joint
 3. Compression. from the incorrect use of crutches.



Axillary Nerve Lesion

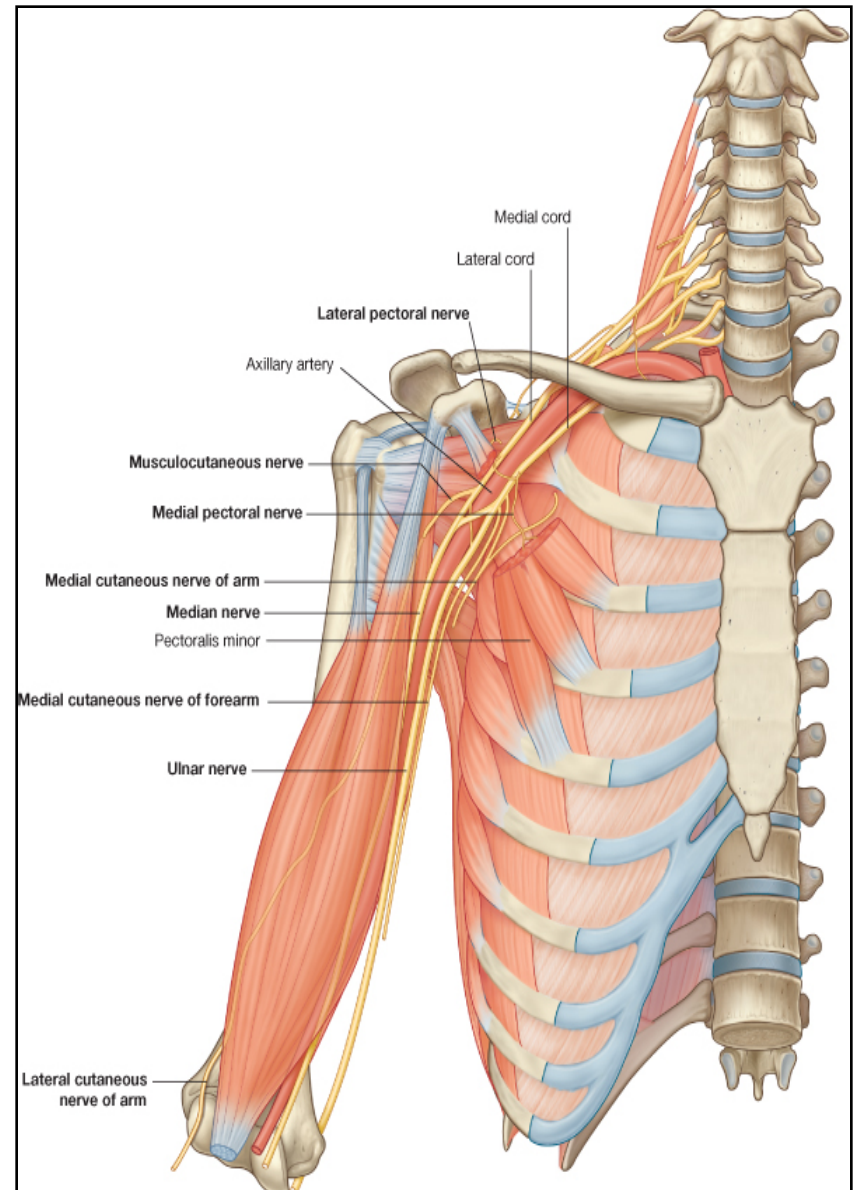
Effects:

- **Motor:**
- Paralysis of the deltoid and teres minor muscles.
- **Impaired abduction of the shoulder (30-90°).**
- The paralyzed deltoid wastes rapidly.
- As the deltoid atrophies, the rounded contour of the shoulder is flattened compared to the uninjured side.
- **Sensory:** Loss of sensation over the lateral side of the proximal part of the arm.



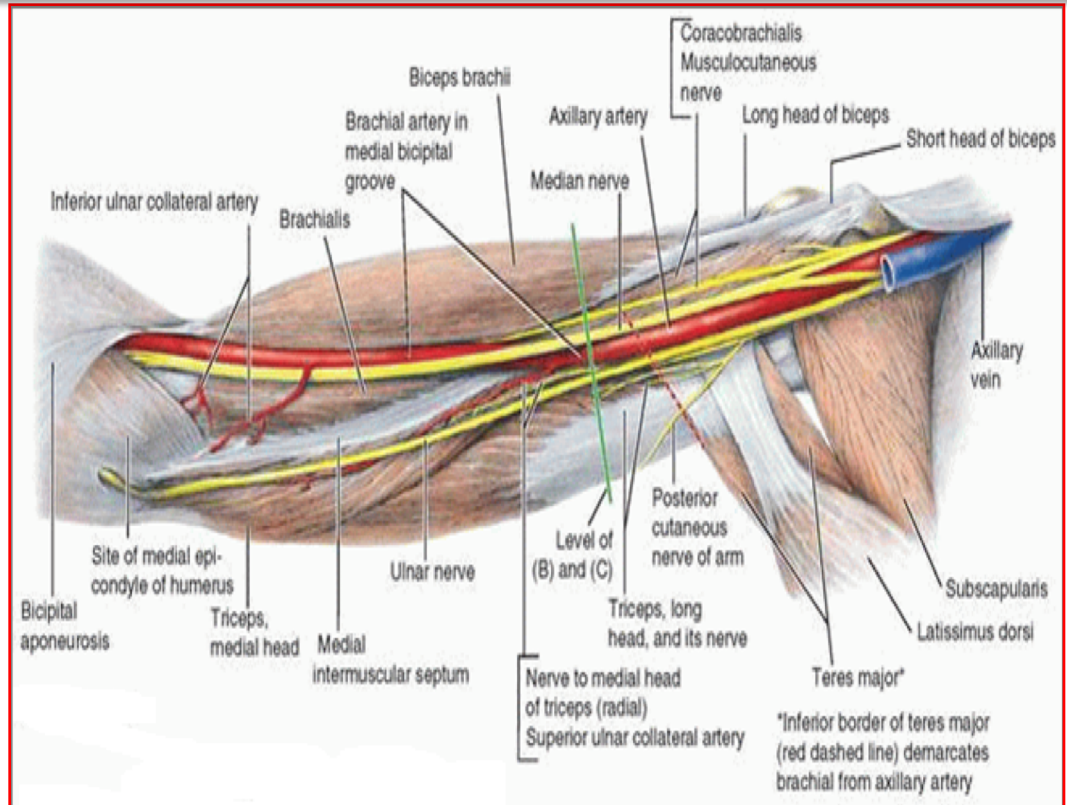
Median Nerve

- (C5,6,7, 8, T1)
- The median nerve is formed **anterior to the third part of the axillary artery** by the **union of lateral and medial roots** **originating from the lateral and medial cords of the brachial plexus.**



Median Nerve in the Arm

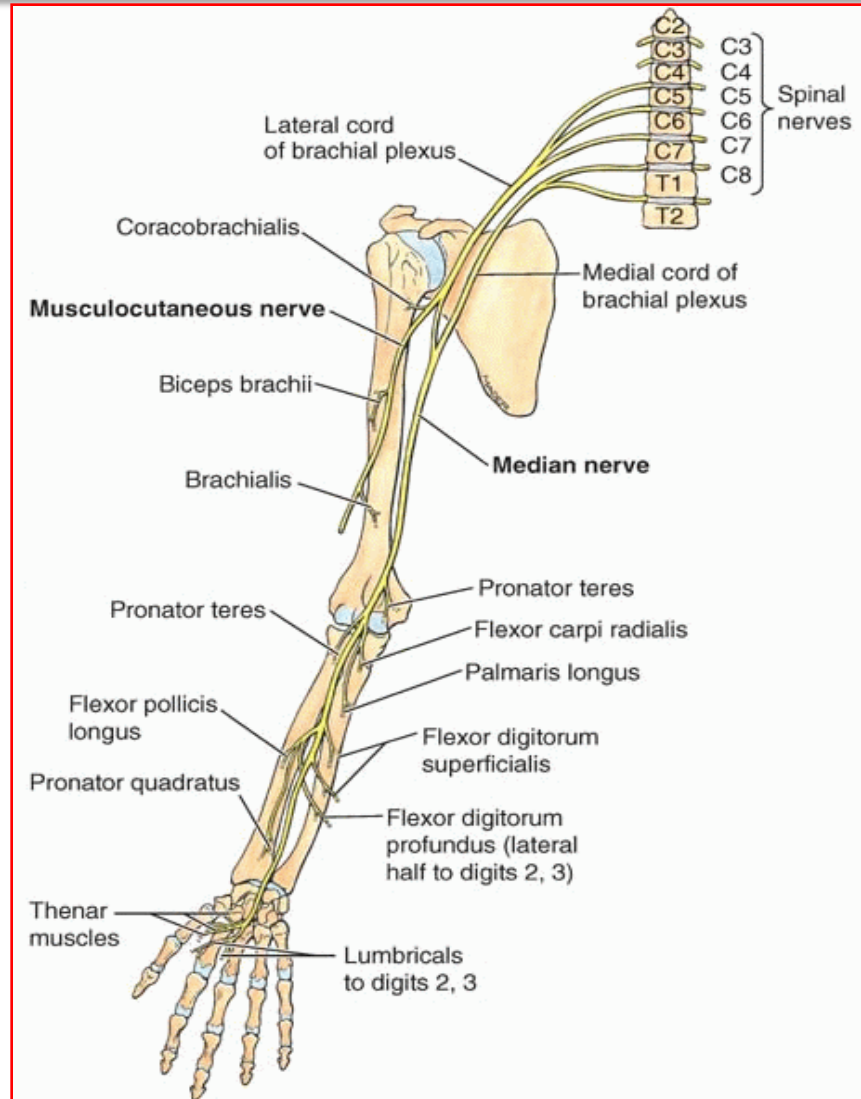
- It enters the arm from the axilla at the inferior margin of the teres major muscle.
- It passes vertically down the medial side of the arm in the anterior compartment and is related to the **brachial artery** throughout its course:
 - in proximal regions, it lies immediately lateral to the brachial artery;
 - in more distal regions it crosses to the medial side of the brachial artery and lies anterior to the elbow joint.



The median nerve has **no major branches in the arm**, but a branch to one of the muscles of the forearm, the (**Pronator Teres**), this branch may originate from the nerve immediately proximal to the elbow joint.

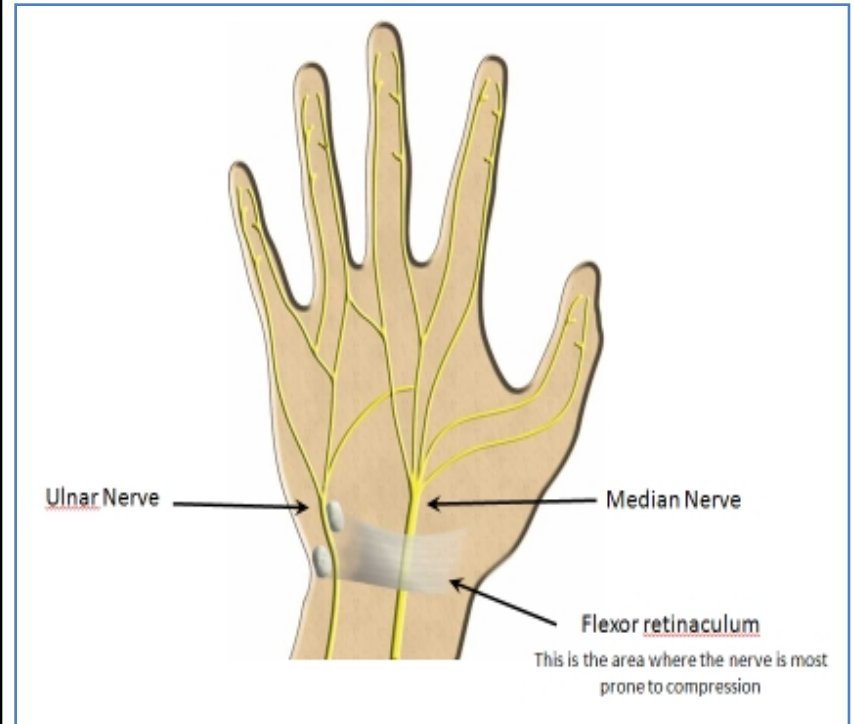
Median Nerve in the Forearm

- Median nerve passes into the forearm anterior to elbow joint, where it innervates **most of the muscles** in the anterior compartment of the forearm (**Except for the Flexor Carpi Ulnaris and the medial half of the Flexor Digitorum Profundus**, which are innervated by the **ulnar nerve**).



Median Nerve in the Hand

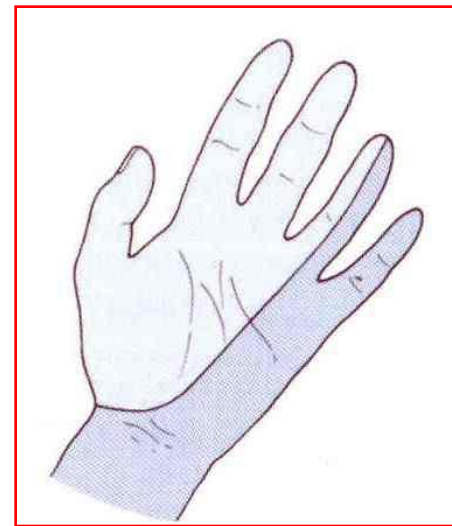
- The median nerve continues into the hand by passing deep to the **flexor retinaculum**.
- **It innervates:**
 - **Three thenar muscles** associated with the thumb
 - **Lateral 2 lumbrical muscles** associated with movement of the index and middle fingers; and
 - **Skin over the palmar surface of the lateral three and one-half digits and over the lateral side of the palm and middle of the wrist.**



Median Nerve Lesions

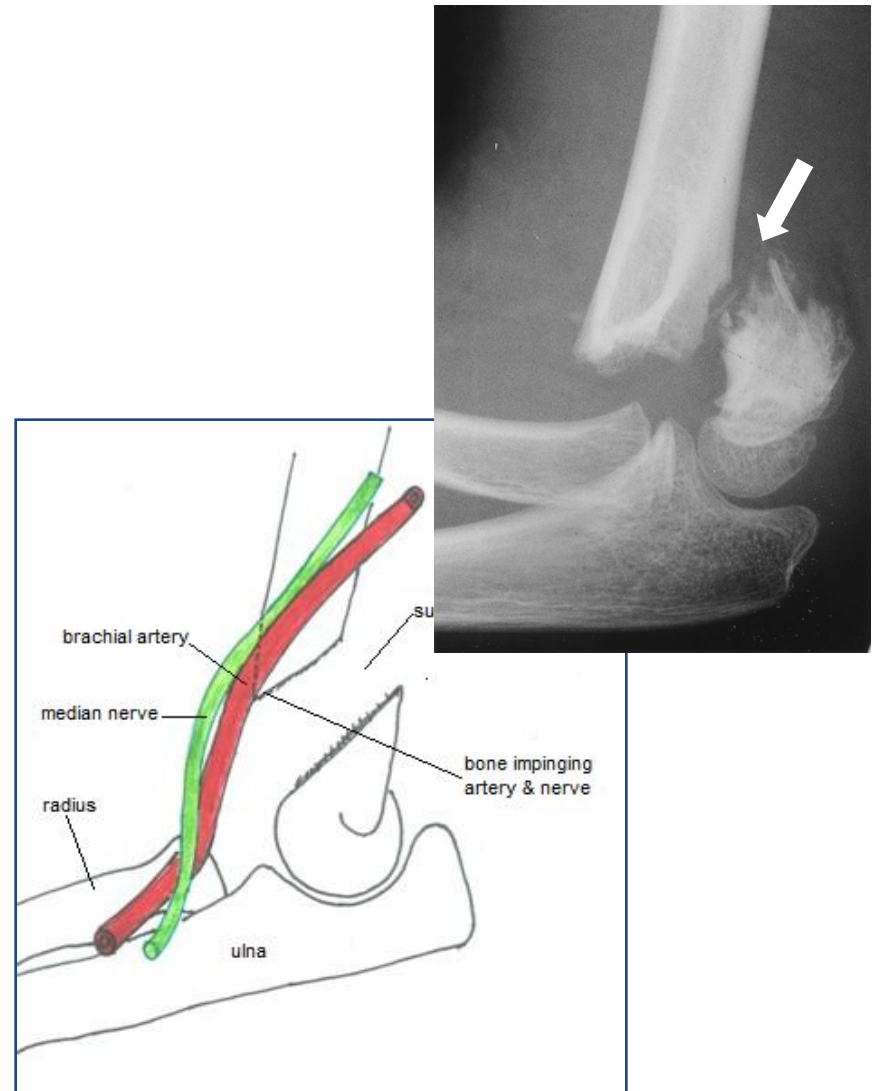
- Injury of median nerve at different levels cause different syndromes.
- In the arm and forearm the median nerve is usually not injured by trauma because of its relatively deep position.
- **Median nerve can be damaged:**
 - In the elbow region
 - At the wrist above the flexor retinaculum
 - In the carpal tunnel

- The most serious disability of median nerve injuries is the:
 - Loss of opposition of the thumb. The delicate pincer-like action is not possible
 - Loss of sensation from the thumb and lateral 2½ fingers & lateral ⅔ of the palm

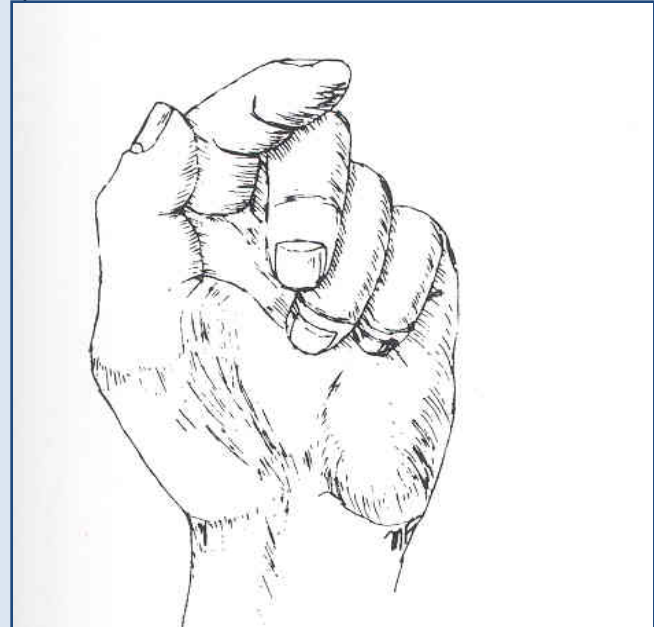


Median Nerve Lesion in the Elbow Region

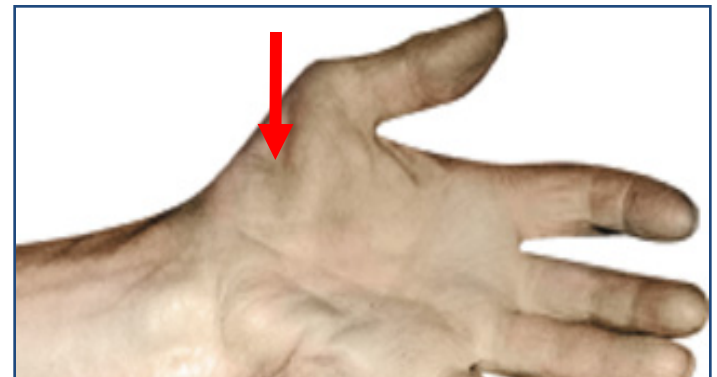- Damaged in supracondylar fracture of humerus
- **Muscles affected are:**
 - Pronator muscles of the forearm
 - All long flexors of the wrist and fingers except **flexor carpi ulnaris** and **medial half of flexor digitorum profundus**



- **Motor Effects:**
- **Loss of pronation.**
- Hand is kept in supine position
- Wrist shows weak flexion, and **ulnar deviation**
- **Loss of flexion** on the interphalangeal joints of the index and middle fingers
- **Weak** flexion of ring and little fingers
- **Thumb** is adducted and laterally rotated, with **loss of flexion** of terminal phalanx and loss of opposition
- **Wasting** of thenar eminence
- Hand looks flattened and **“ape-like”**, and presents an inability to flex the three most radial digits when asked to make a fist.



Wasting of thenar eminence

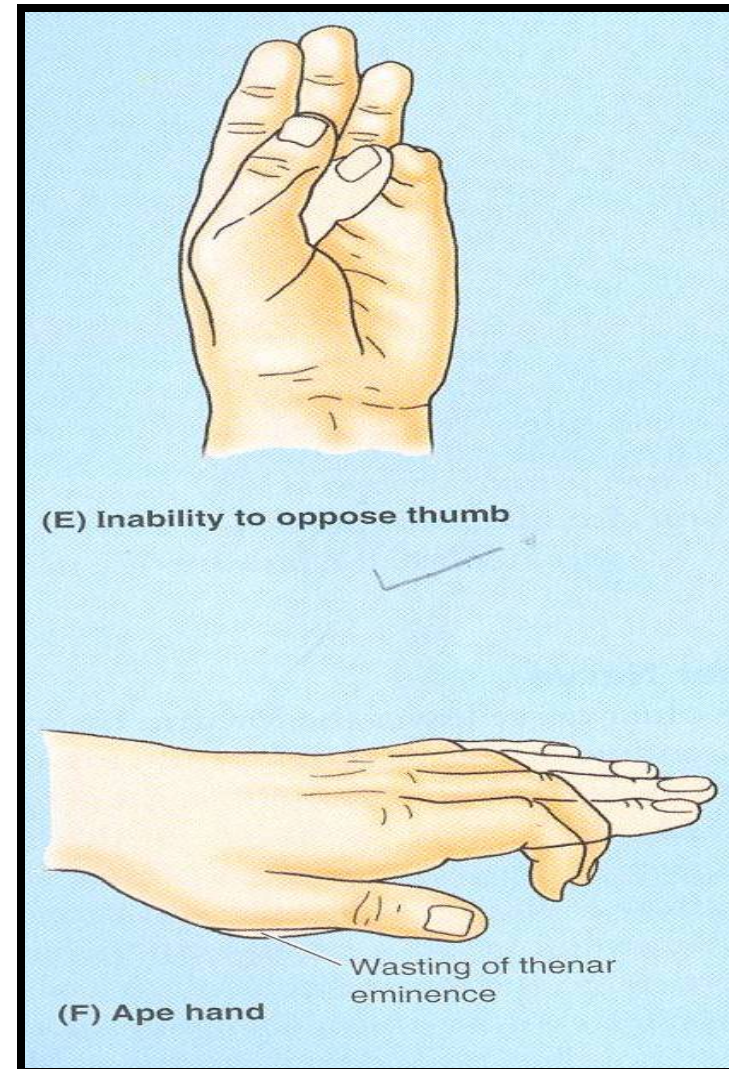


- **Sensory Effects:**
- Loss of sensation from:
 - The radial side of the palm
 - Palmer aspect of the lateral 3½ fingers
 - Distal part of the dorsal surface of the lateral 3½ fingers
- **Trophic Changes:**
 - Dry and scaly skin
 - Easily cracking nails
 - Atrophy of the pulp of the fingers



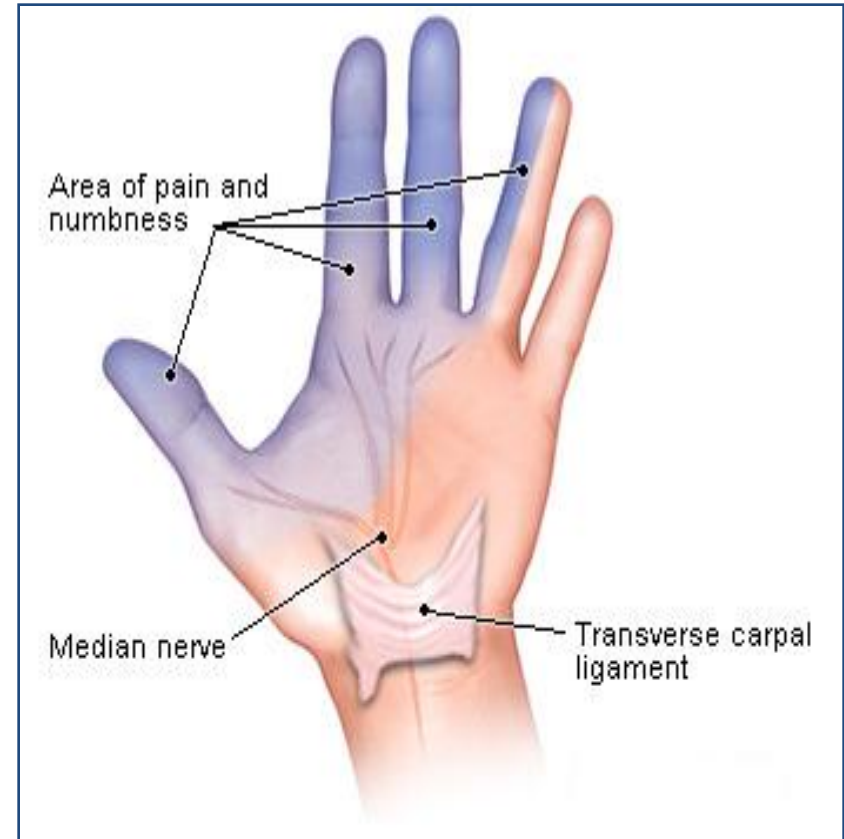
Median Nerve Lesion at the Wrist

- Often injured by penetrating wounds (stab wounds or broken glass) of the forearm.
- **Motor:**
 - Thenar muscles are paralyzed and atrophy in time so that the thenar eminence becomes flattened
 - Opposition and abduction of thumb are lost, and thumb and lateral two fingers are arrested in adduction and hyperextension position. “*Apelike hand*”
- Sensory & trophic changes are the same as in the elbow region injuries



Carpal Tunnel Syndrome

- The commonest neurological problem associated with the median nerve is compression beneath the flexor retinaculum at the wrist
- **Motor**: Weak motor function of thumb, index & middle fingers
- **Sensory**: Burning pain or 'pins and needles' along the distribution of median nerve to lateral 3½ fingers



No sensory changes over the palm as the **palmer cutaneous branch** is given before the median nerve enters the carpal tunnel

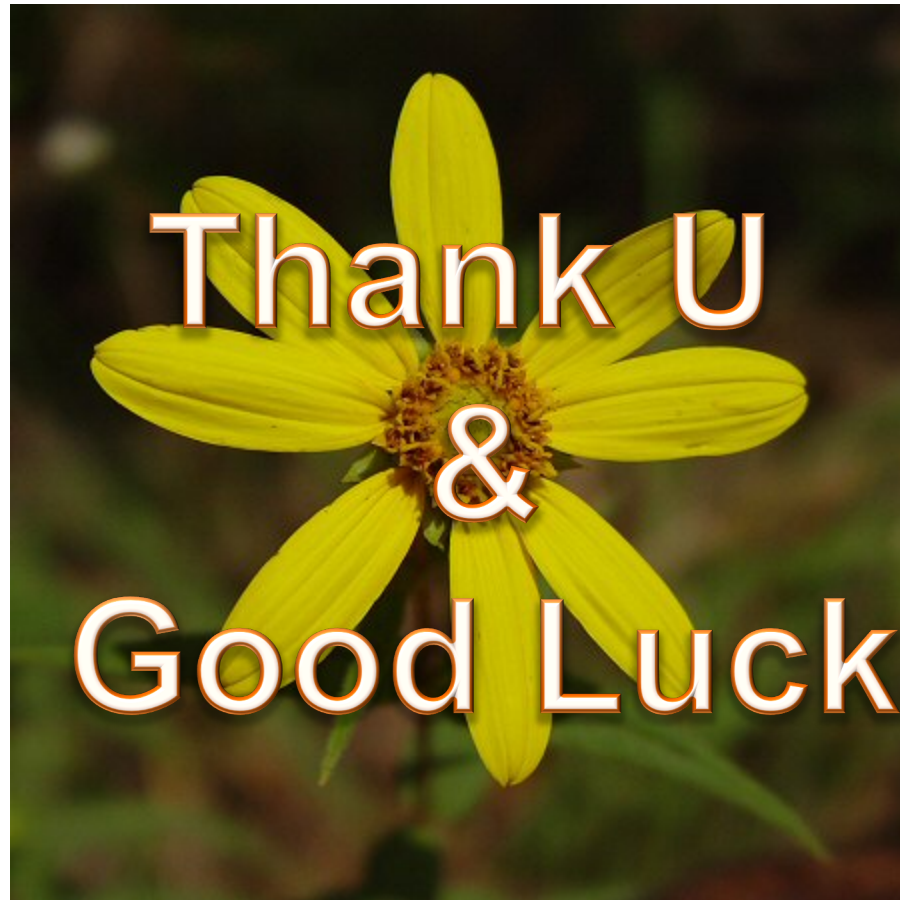Summary

• Axillary Nerve

- Origin:
Posterior cord
- Spinal segments: C5, C6
- Function:
 - Motor: Deltoid, teres minor
 - Sensory: Skin over upper lateral part of arm

• Median Nerve

- Origin: Medial and lateral cords
- Spinal segments: (C5), C6 to T1
- Function:
 - Motor
All muscles in the anterior compartment of the forearm (Except flexor carpi ulnaris and medial half of flexor digitorum profundus), three thenar muscles of the thumb and two lateral lumbrical muscles
 - Sensory
Skin over the palmar surface of the lateral three and one-half digits and over the lateral side of the palm and middle of the wrist



Thank U
&
Good Luck