

HAND & WRIST

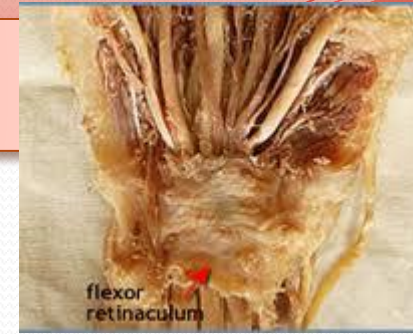**DR. JAMILA EL-
MEDANY**

**DR. ESSAM ELDIN
SALAMA**

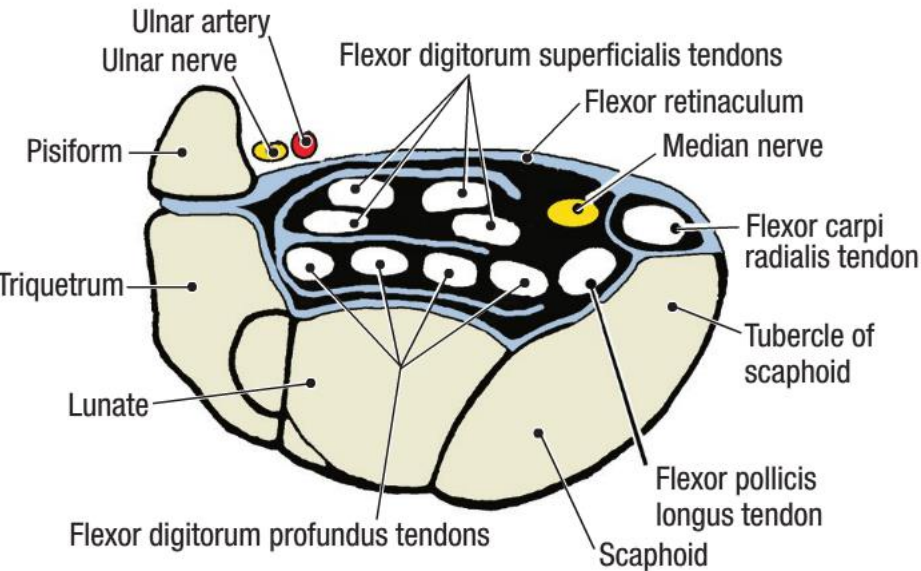
OBJECTIVES

- **At the end of the lecture, students should be able to:**
- **Describe the anatomy of the deep fascia of the wrist & hand (flexor & extensor retinaculae & palmar aponeurosis).**
- **List the structures passing superficial & deep to flexor retinaculum.**
- **Describe the anatomy of the insertion of long flexor & extensor tendons.**
- **Describe the anatomy of the small muscles of the hand (origin, insertion action & nerve supply)**

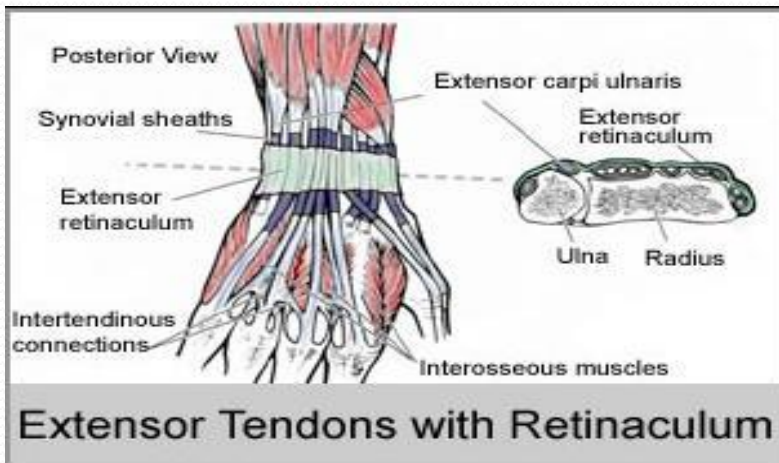
Retinacula



CARPAL TUNNEL WITH CONTENTS



- **Flexor & Extensor Retinacula:**
- ***Bands of Deep Fascia at the Wrist***
- **Function:**
 - *Hold the long flexor and extensor tendons at the wrist in position.*
- **Attachments:**
 - **Medially:** *Both retinacula attached to Pisiform & Hook of Hamate.*
 - **Laterally:**
 - ***Flexor Retinaculum attached to Tubercle of Scaphoid & Trapezium.***
 - ***Extensor Retinaculum attached to Distal end of Radius***

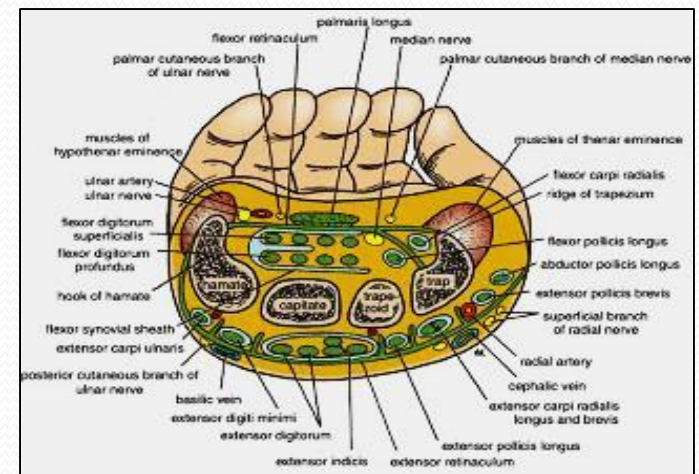
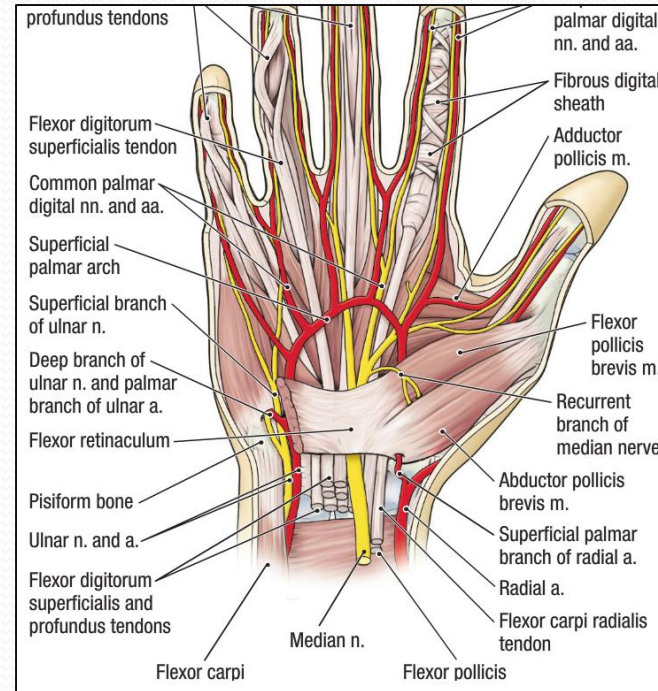


Extensor Tendons with Retinaculum

Structures Superficial to Flexor Retinaculum

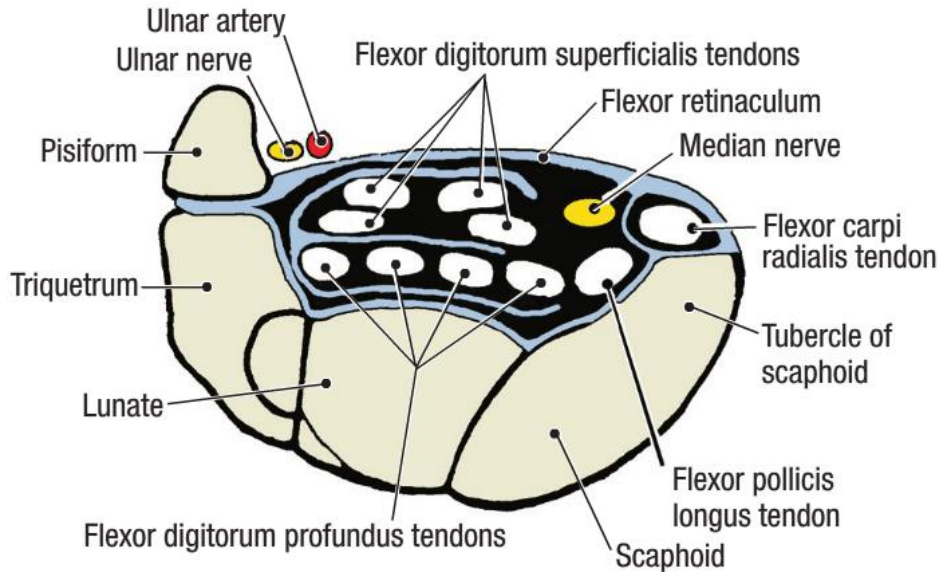
From Medial to Lateral

1. **Tendon of Flexor carpi ulnaris.**
2. **Ulnar nerve.**
3. **Ulnar artery.**
4. **Palmar cutaneous branch of ulnar nerve.**
5. **Palmaris longus tendon.**
6. **Palmar cutaneous branch of median nerve.**



Carpal Tunnel

CARPAL TUNNEL WITH CONTENTS



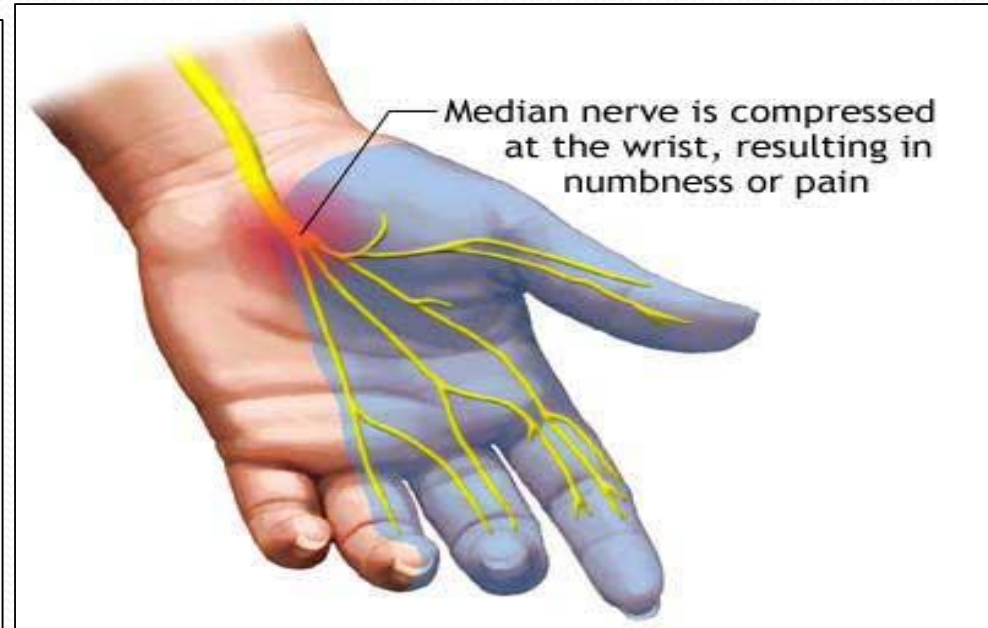
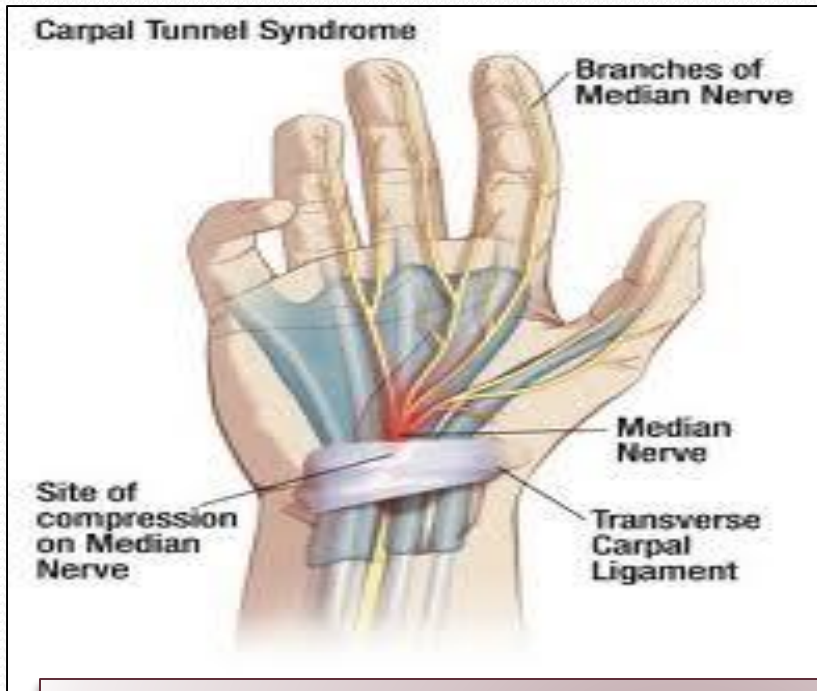
Formed from Concave anterior surface of the Carpus covered by Flexor Retinaculum

Contents

From Medial to Lateral

- Tendons of flexor digitorum superficialis & profundus
- Median nerve
- Flexor Pollicis Longus
- (Flexor carpi radialis)

Carpal Tunnel Syndrome



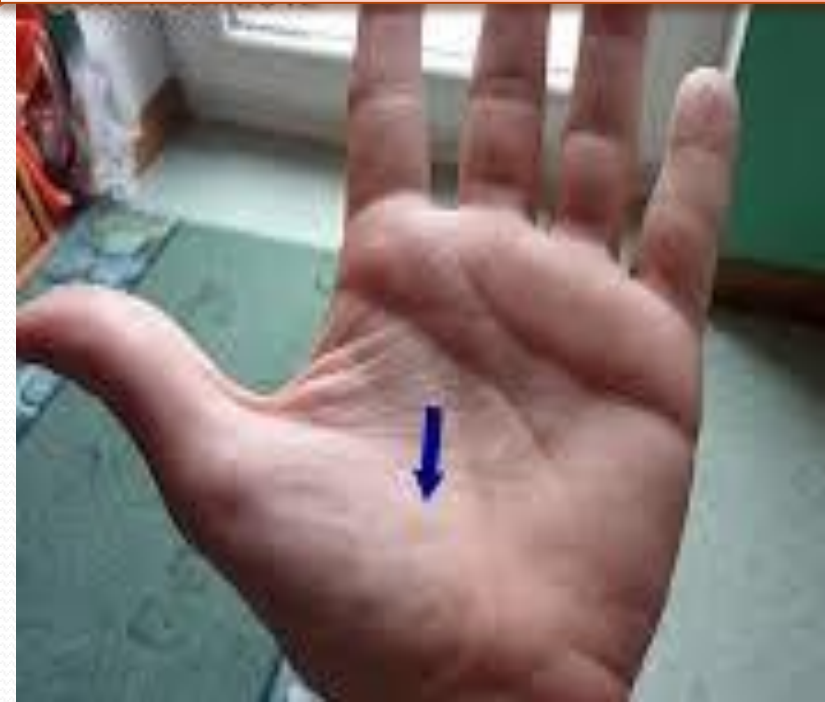Causes :

- *Compression of the median nerve within the carpal tunnel*

Manifestations:

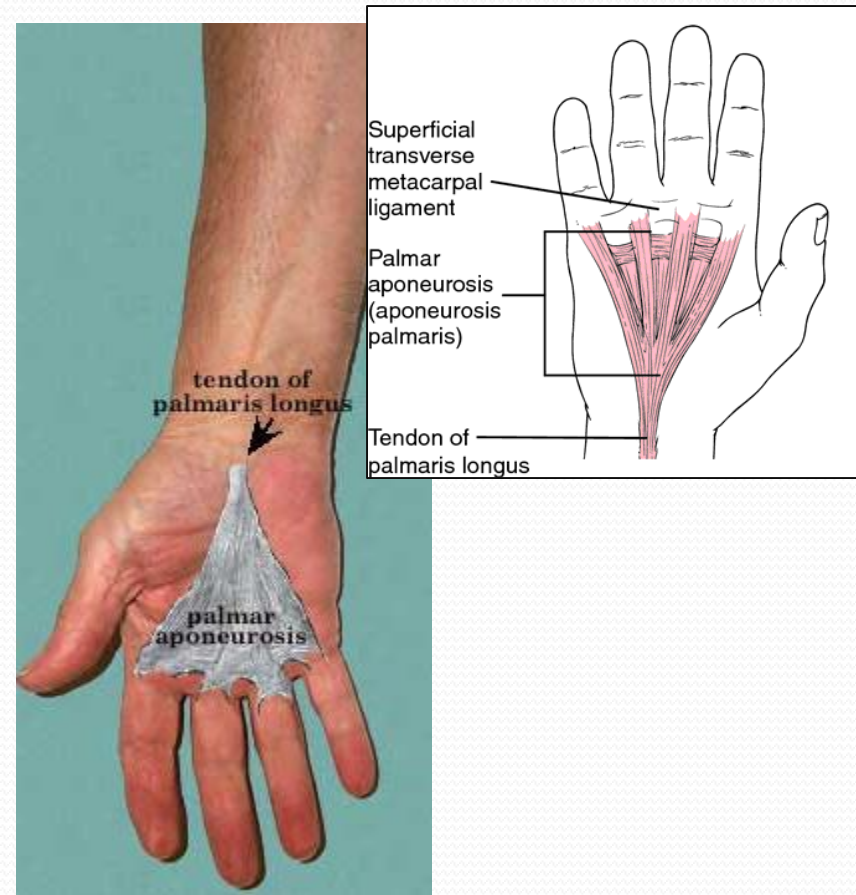
- *1. Burning pain (pins and needles) in the lateral three and half fingers.*
- *No paresthesia over the thenar eminence?*

Carpal Tunnel Syndrome



- 2. *Weakness or atrophy of the thenar muscles (Ape Hand).*
- *Inability to Oppose the thumb.*

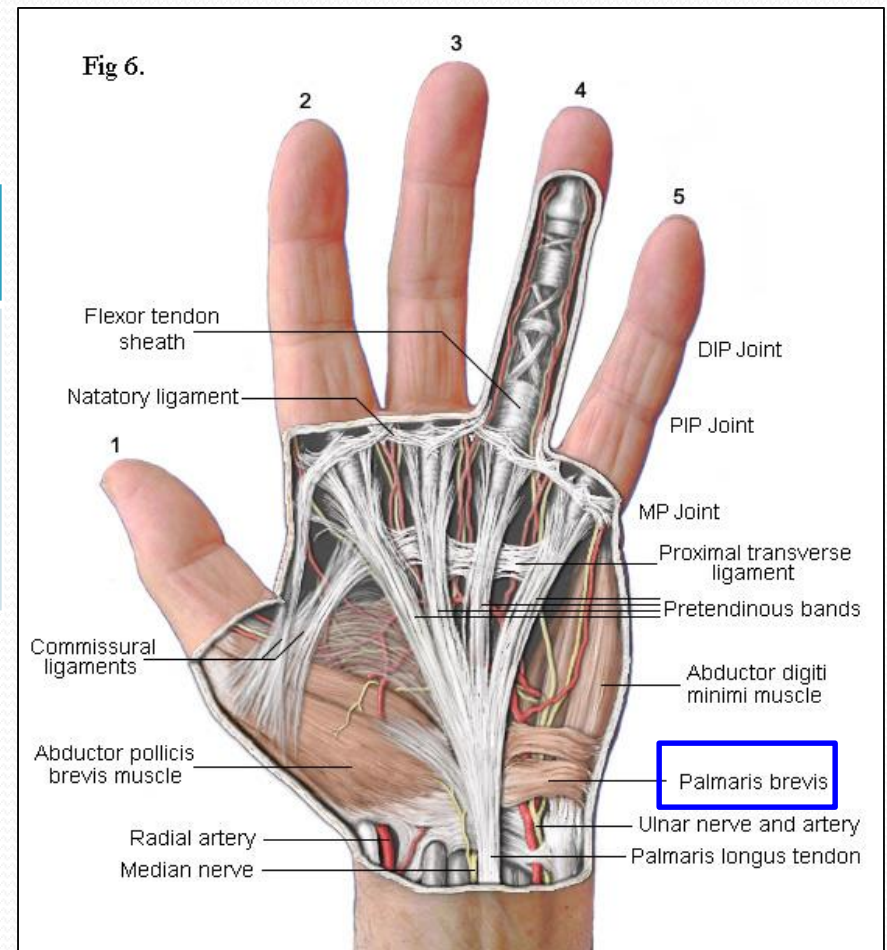
Palmar Aponeurosis



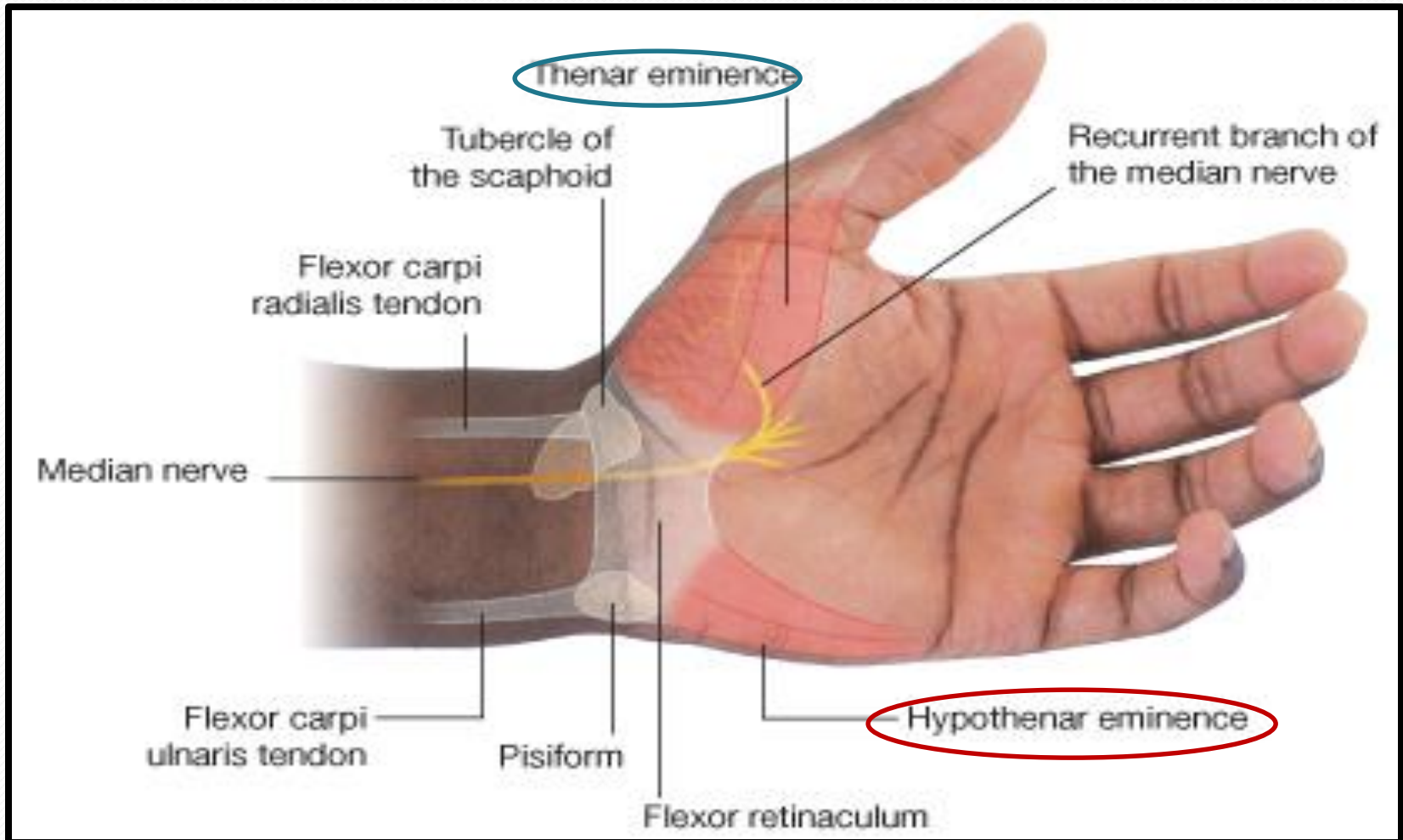
- **The Thickened deep fascia of the Palm.**
- It is Triangular in shape , occupies the central area of the palm.
- **Apex:**
 - Attached to the distal border of flexor retinaculum and receives the insertion of palmaris longus tendon.
- **Base:**
 - Divides at the bases of the fingers into four slips that pass into the fingers.
- **Functions:**
 - 1. Firmly attached to the overlying skin and improves the grip.
 - 2. Protects the underlying tendons, vessels & nerves.
 - 3. Gives origin to palmaris brevis muscle.

Palmaris Brevis

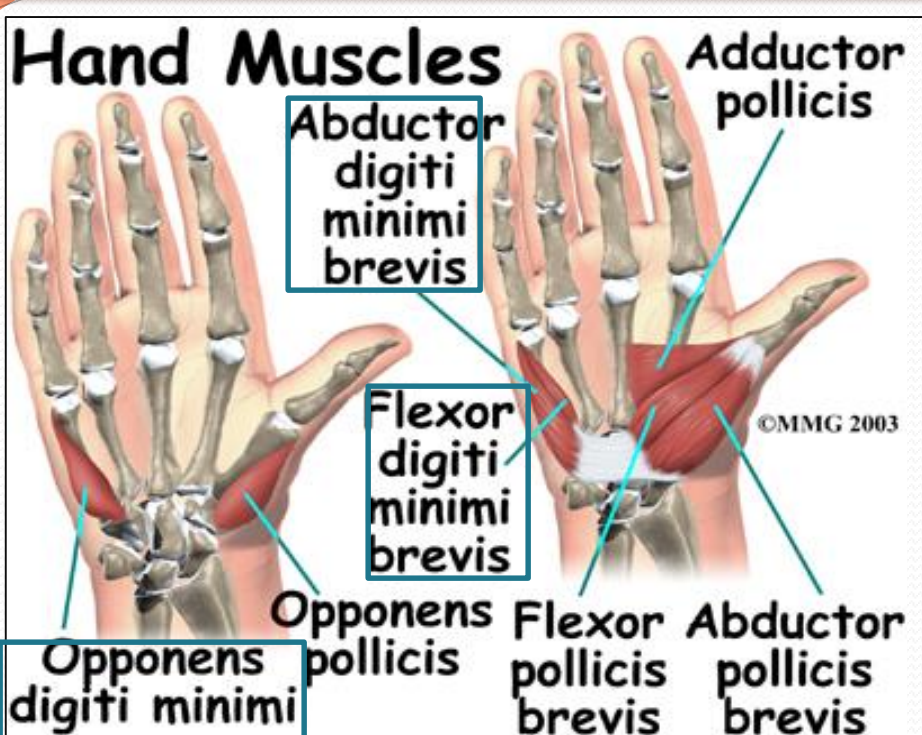
Origin	Insertion	NS	Action
FR and PA.	Skin of Palm	Ulnar Nerve (Superficial Branch)	Prevents Corrugation of skin to improve grip



Short Muscles of Thumb & Little Finger

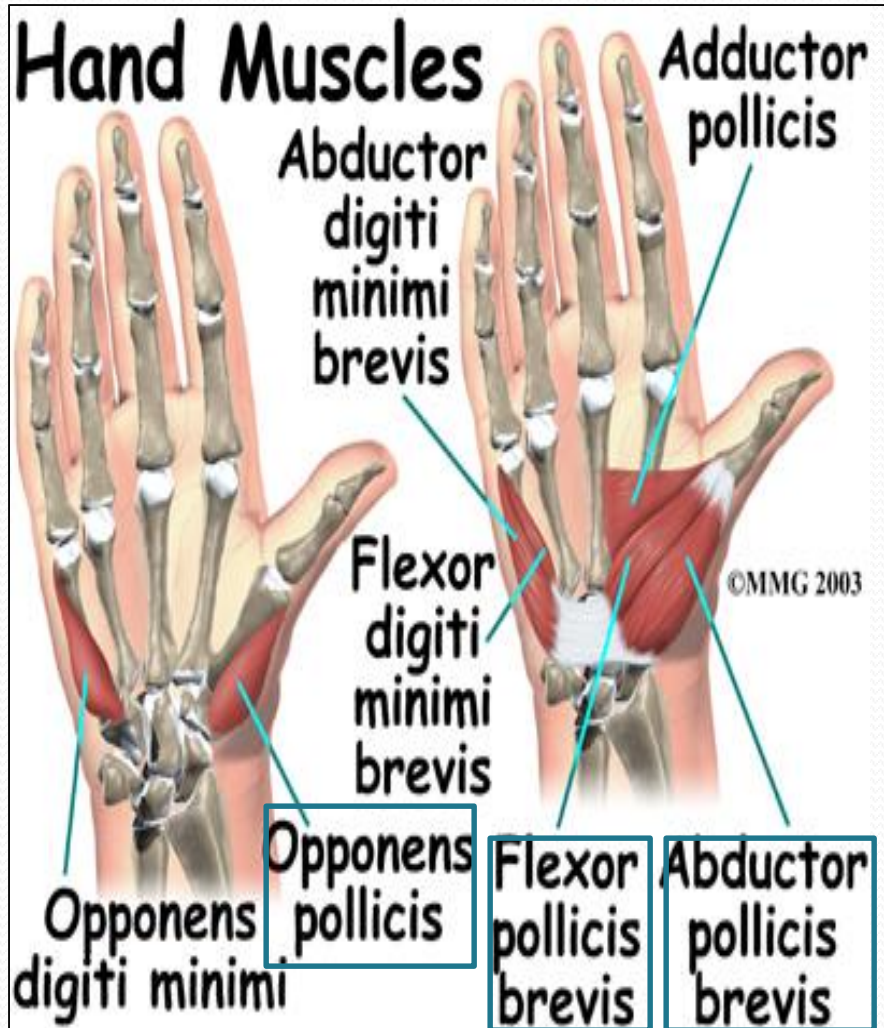

Hypothenar Eminence (3)



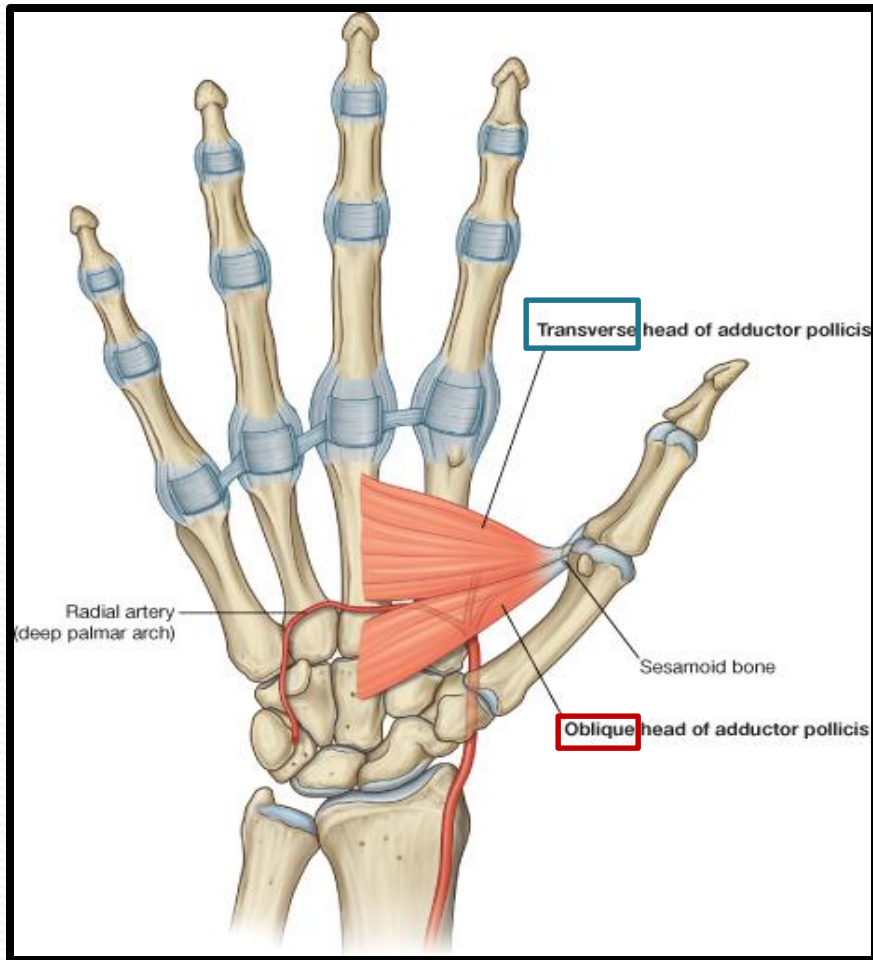
	<i>Origin</i>	<i>Insertion</i>	<i>NS</i>	<i>Action</i>
<i>Ab Dig Min</i>	Pisiform	Base of Prox. Ph.	All by Deep branch of Ulnar	Abduction
<i>Flx Dig Min B</i>	FR	<i>With AB DIG MIN</i>		Flexion
<i>Opp Dig Min</i>	Palmar surface of 5 th metacarpal			<i>Pulls the 5th metacarpal forward (Cup the palm)</i>

Thenar Eminence (3)



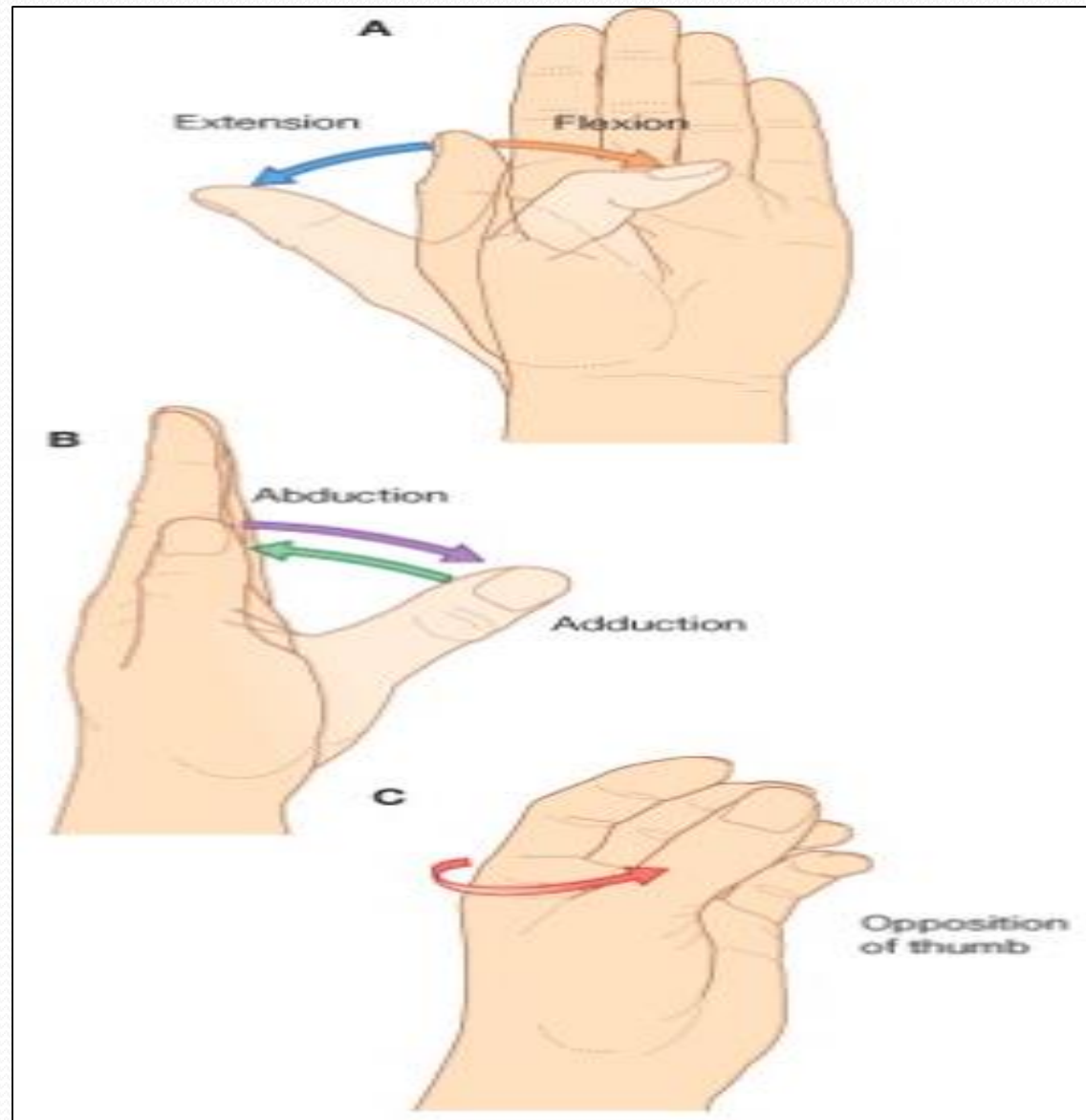
	Origin	Insertion	NS	ACT
Ab Poll B	FR Scaphoid & Trapez	(Base of Prox. Ph.)	All from Median N	AB
Flex Poll B	FR	With AB Poll B		FLX
Opp Poll	FR	Lateral part of 1 ST Met		Opp

Adductor Pollicis



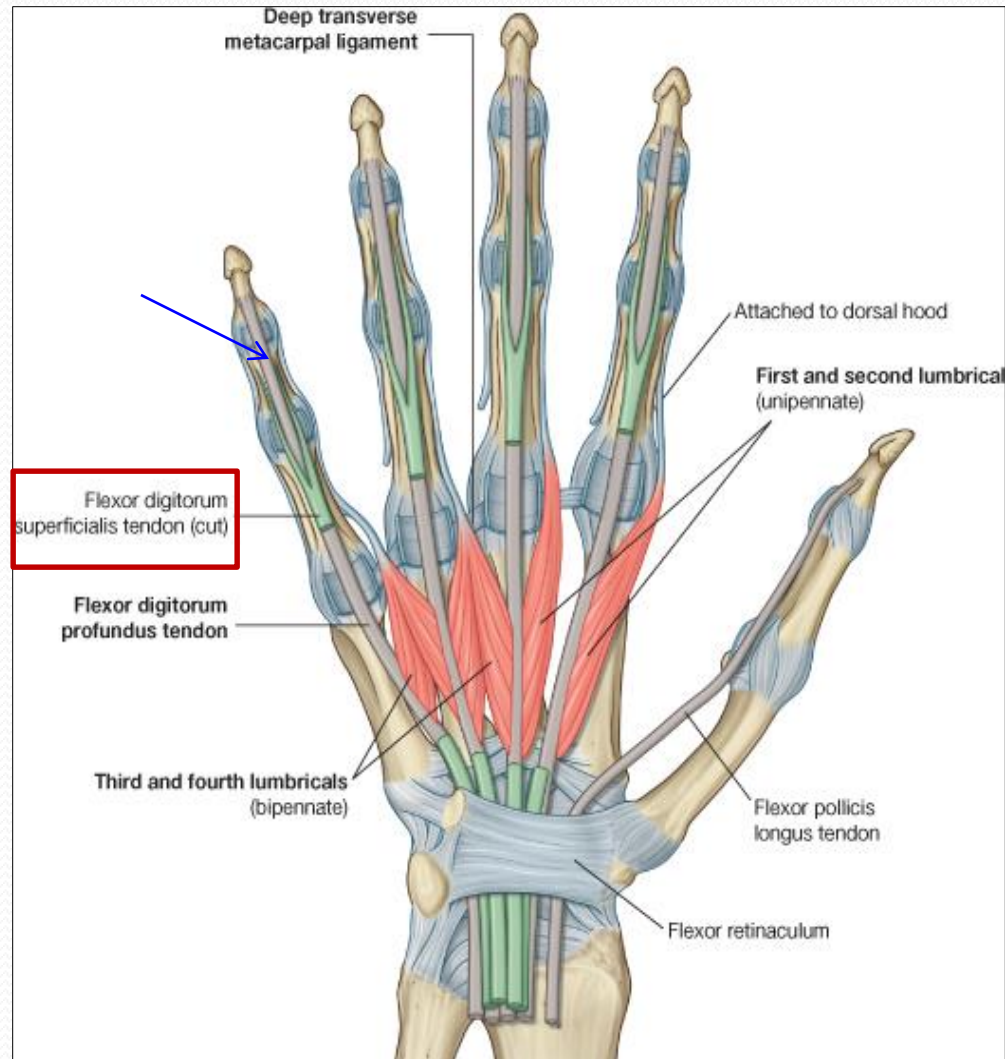
Origin	Insertion	Action	NS
Oblique Head: Ant. bases of 2 nd & 3 rd metacarpals	Medial side of base of prox. ph. of thumb	Add	Deep branch of Ulnar
Trans H: 3 rd metacarpal			

Movements of Thumb

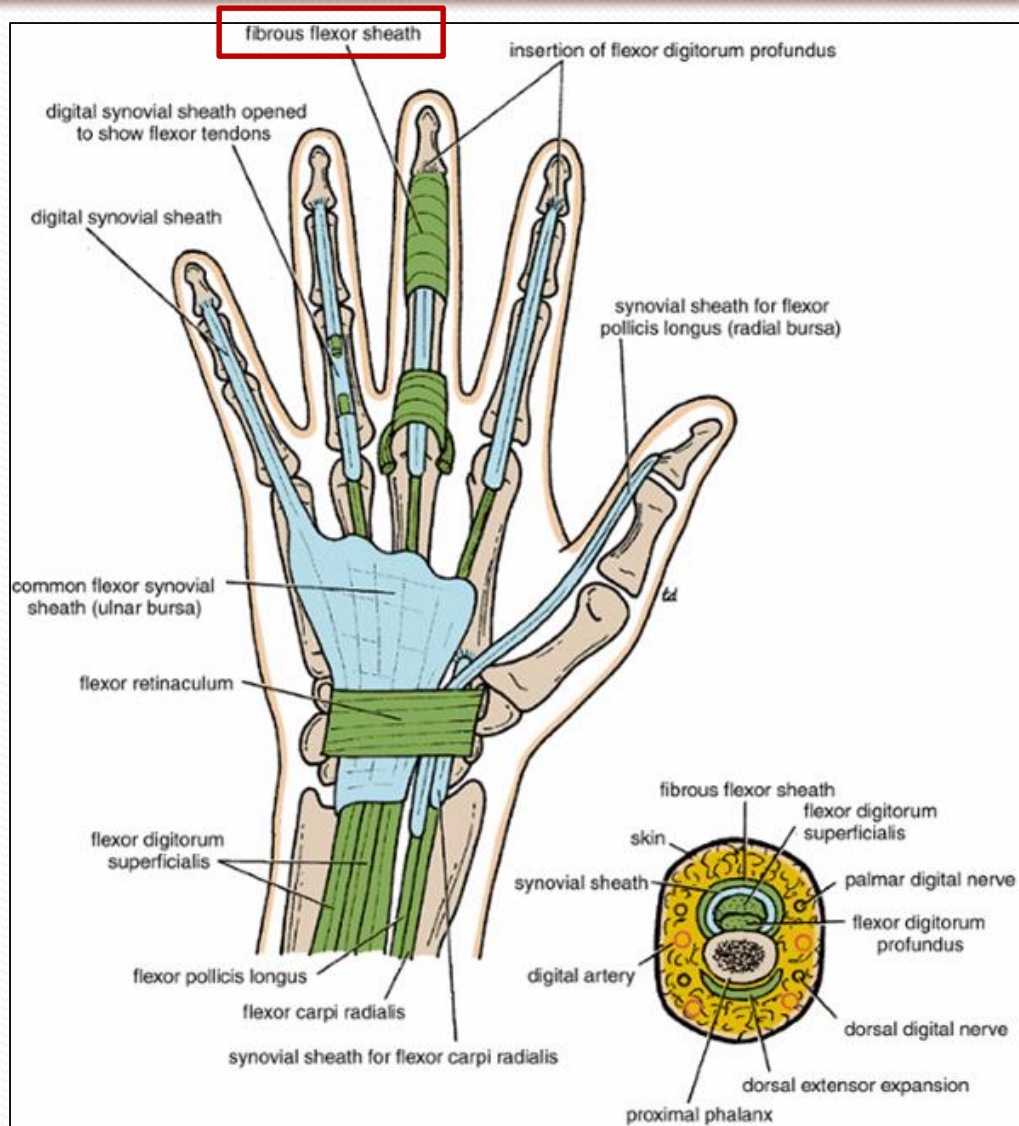


Insertion of Flexor Dig. Superficialis & Profundus

- **Flexor dig. superficialis**
- Each tendon:
 - **Divides** into two halves & pass around the Profundus Tendon.
 - The two halves **Meet** on the posterior aspect of Profundus tendon (partial decussation of fibers).
 - **Reunion** of the two halves.
 - **Further Division into two slips** attached to the **Borders of Middle Phalanx.**
- **Flexor dig Profundus**
 - Inserted into the **Base of the Distal Phalanx.**



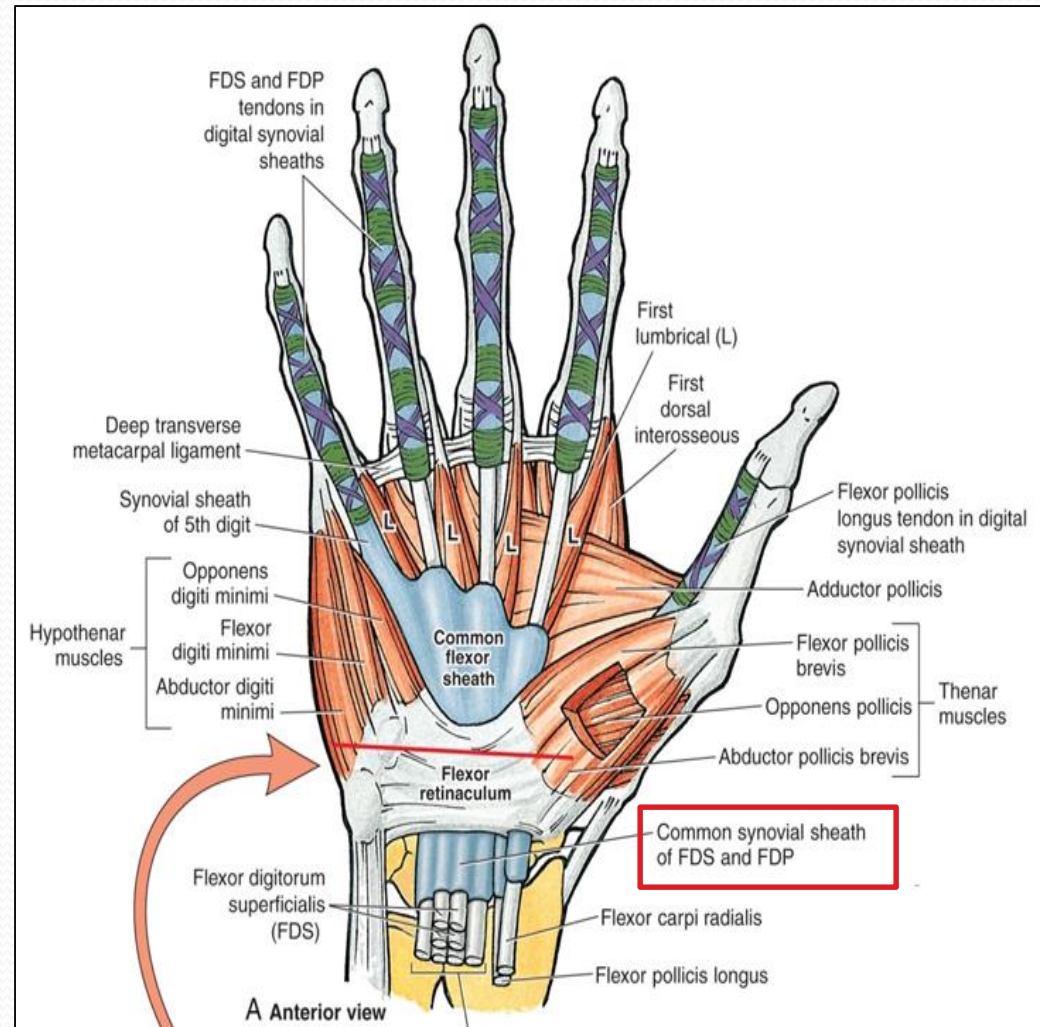
Fibrous Flexor (Digital) Sheath



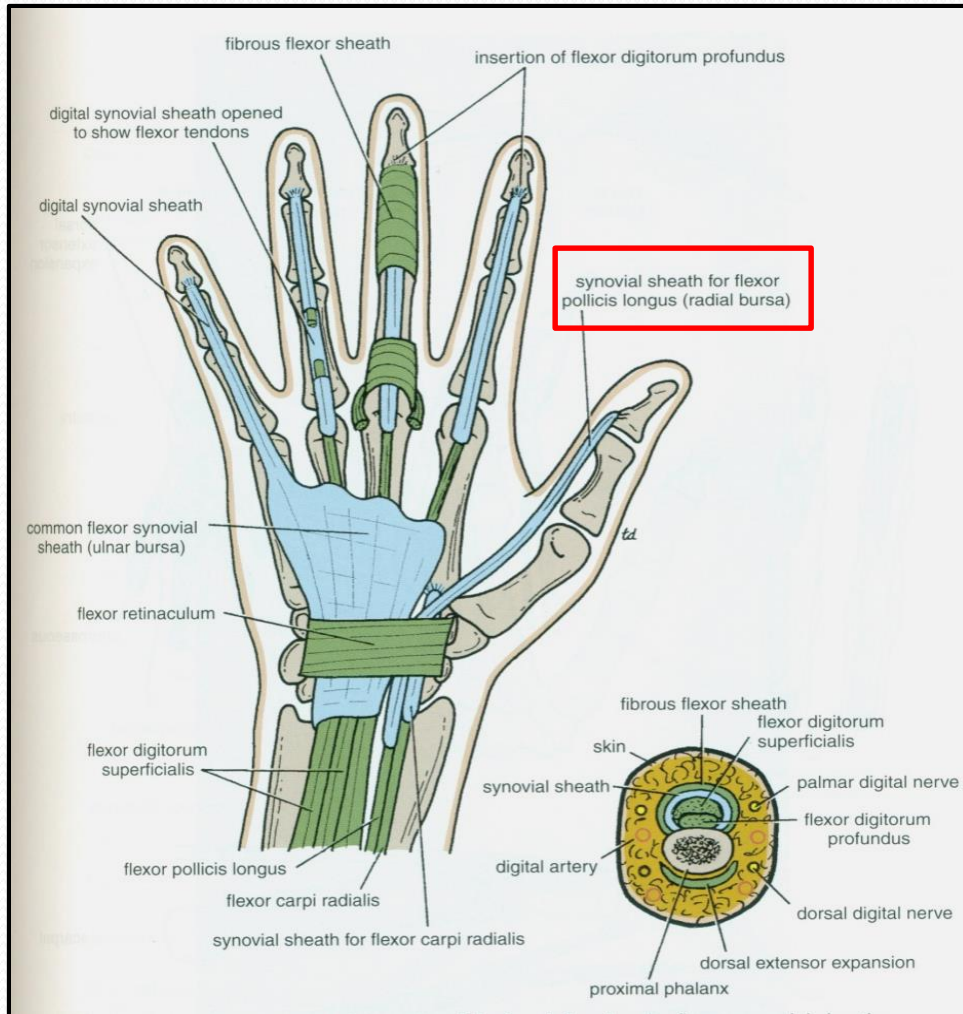
- **A Strong Fibrous Sheath**, which covers the anterior surface of the fingers and attached to the sides of the phalanges.
- Its Proximal end is **opened**
- Its Distal end is **closed**
- The Sheath with the anterior surfaces of the phalanges & the interphalangeal joints form an **Osteofibrous blind Tunnel** for the long flexor tendons of the fingers.

Synovial Flexor Sheaths

- Common Synovial sheath (*Ulnar Bursa*)
 - Contains tendons of Flexor Digitorum Superficialis & Profundus
 - The **Medial** part of the sheath extends distally (without interruption) on the tendons of the *little finger*.
 - The **Lateral part** of the sheath **stops** on the middle of the palm.
 - The distal ends of the long flexor tendons to (*Index, Middle & Ring*) fingers acquire **Digital Synovial Sheaths**.

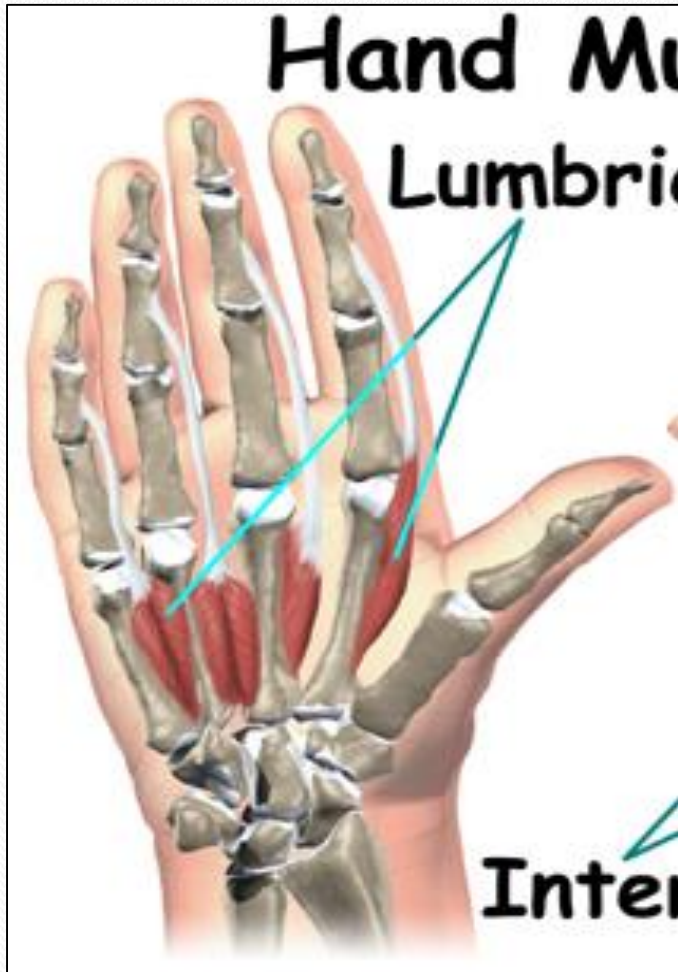

Synovial Flexor Sheaths

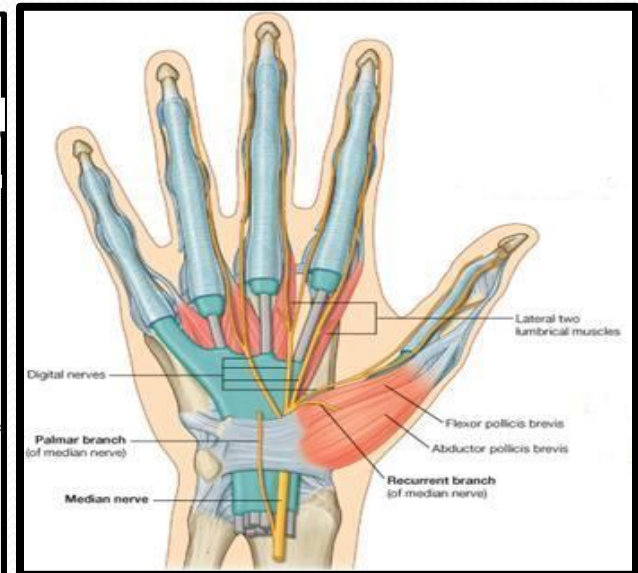
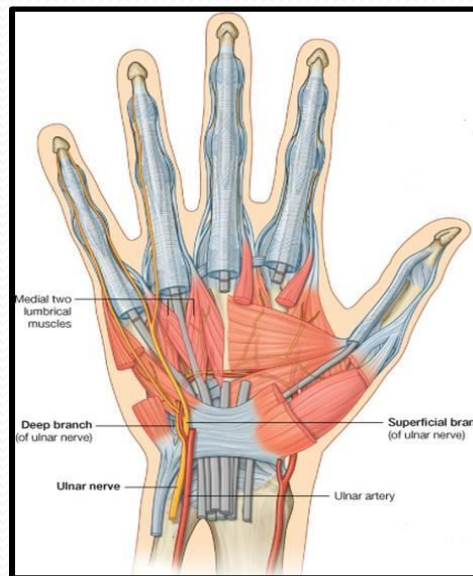


- ***Flexor Pollicis Longus*** tendon has its own synovial sheath (**Radial Bursa**)
- **Function of Synovial Sheaths:**
- ***They allow the long tendons to move smoothly with a minimum of friction beneath the flexor retinaculum and the fibrous flexor sheaths.***

Lumbrical Muscles (4)



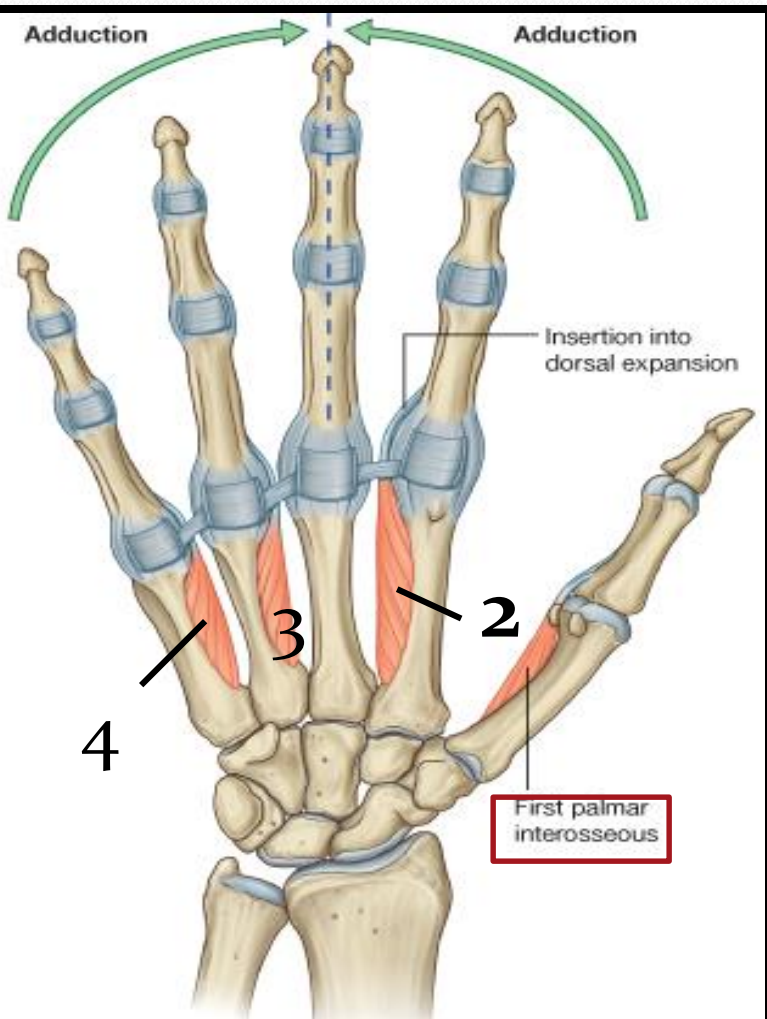
Origin	Insertion	NS
Tendons of Flex.dig. profundus	EXT. EXP of medial four fingers	1 ST & 2 ND (Lateral two) : Median N. 3 RD & 4 TH : Ulnar N (Deep branch)



Action:

Flex metacarpophalangeal joints and extend interphalangeal joints of fingers **Except thumb**

Palmar Interossei (4)

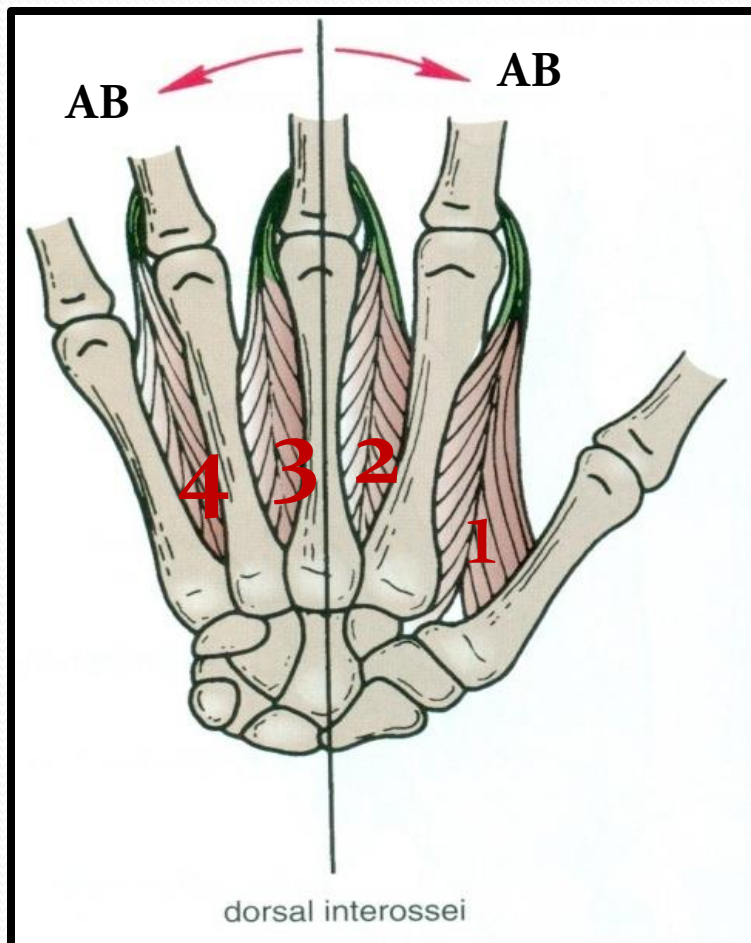


Origin	Insertion	NS
<p>1st : Base of 1st metacarpal.</p> <p>Other three: Ant. Surface of Shafts of 2nd , 4rd & 5th metacarpals.</p>	<p>Proximal phalanges of thumb ,index, ring, & little fingers and Extensor expansion</p>	<p>Ulnar nerve: deep Branch</p>

Action:

Adduction of fingers toward center of the 3rd one.

Dorsal Interossei (4)

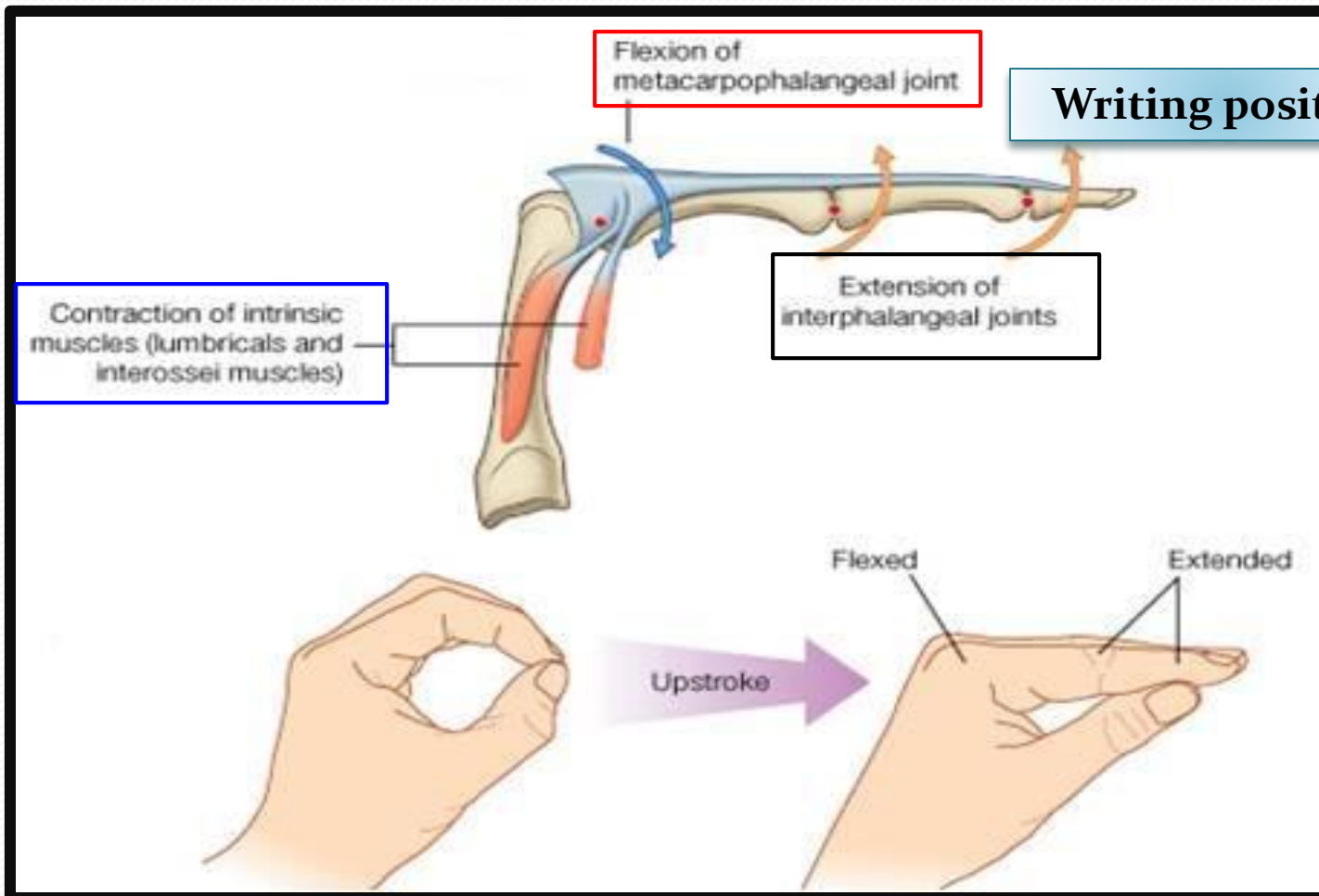


Origin	Insertion	NS
Contiguous sides of shafts of Metacarpals	Proximal Phalang of index, ring, mid finger & EX	Ulnar nerve deep Branch

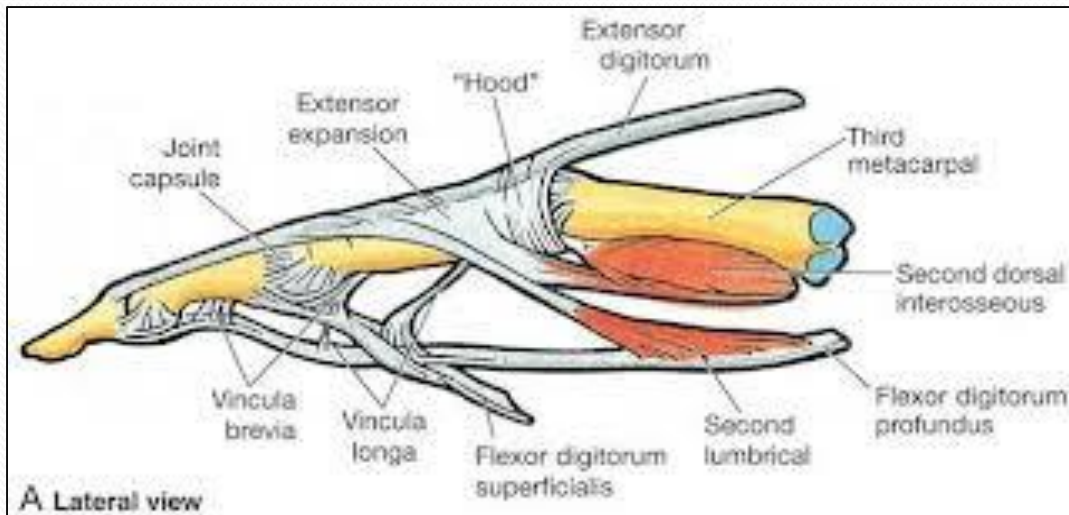
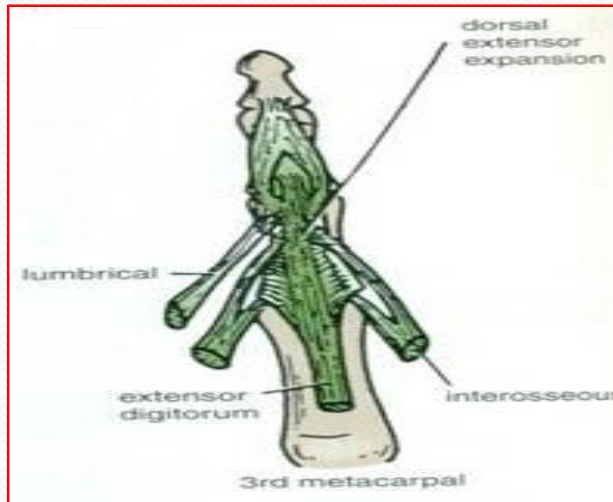
Action:

Abduction of fingers away from the 3rd one.

Action of Lumbricals & Interossei



Extensor Expansion



- Formed from the expansion of the tendons of extensor dig. at the P.I.J.
- The tendon splits into three parts:
 - **One Central:** inserted into the base of **Middle phalanx**.
 - **Two laterals:** inserted into the base of the **Distal phalanx**.
- The Expansion Receives the insertions of:
 - Corresponding **Interosseous** muscle (on each side).
 - **Lumbrical** muscle (on the lateral side).



Thank You