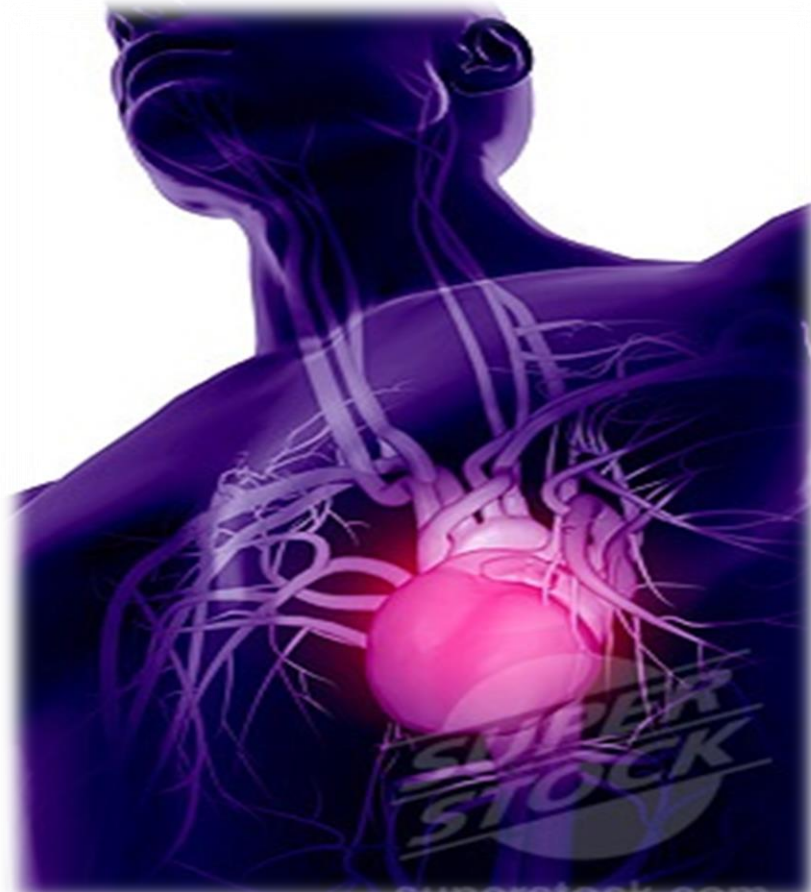

Major Blood Vessels-Veins



By Drs. Sanaa Alshaarawy &
Khaleel Alyahya.

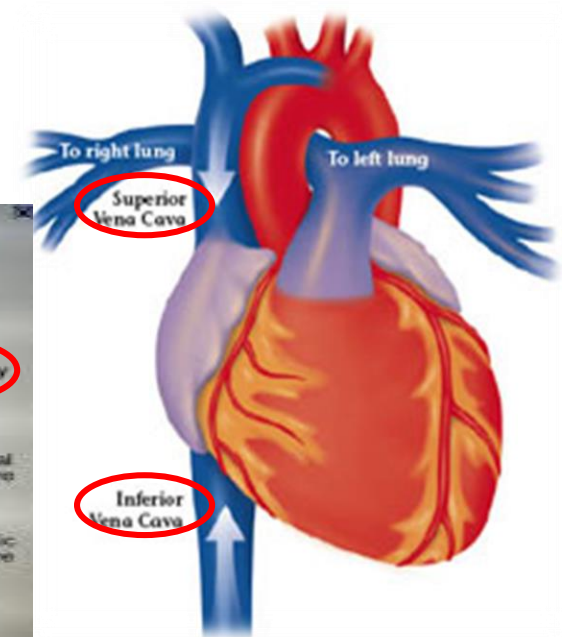
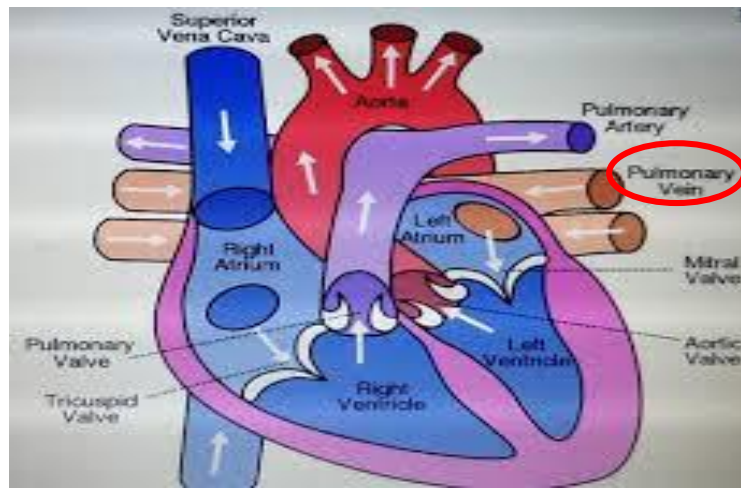
Objectives

At the end of the lecture, the student should be able to:

- ❖ **Define the veins**, and understand the **general principle** of the venous system.
- ❖ Describe the **superior & inferior Vena Cava** and their **tributaries**.
- ❖ List **major veins** and their **tributaries in the body**.
- ❖ Describe the **Portal Vein**.
- ❖ Describe the **Portocaval Anastomosis**.

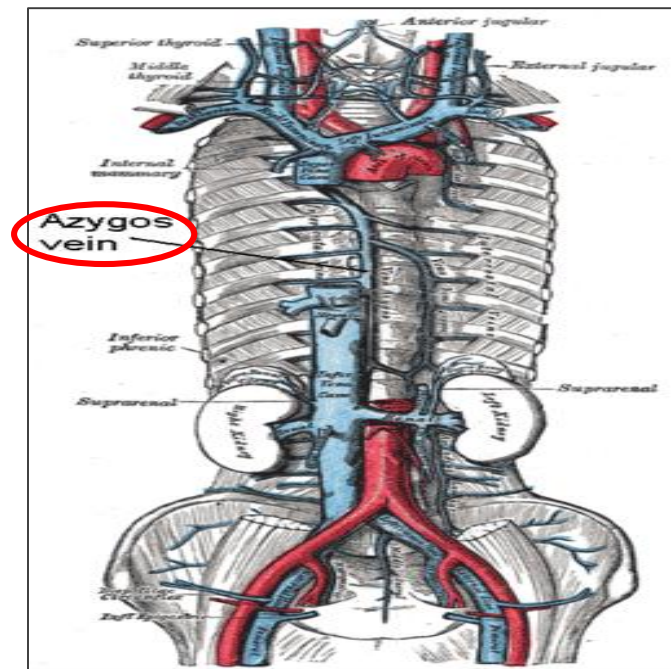
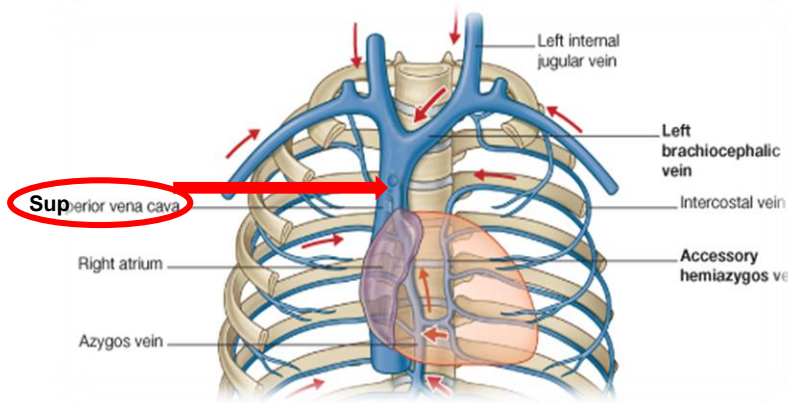
Veins

- ❖ Veins are blood vessels that bring blood back to the heart.
- ❖ All veins **carry deoxygenated blood**
 - with the exception of the **pulmonary veins** and **umbilical vein** (during fetal development).
- ❖ **There are two types of veins:**
 - **Superficial veins:** close to the surface of the body
 - ✓ NO corresponding arteries
 - **Deep veins:** found deeper in the body
 - ✓ With corresponding arteries
- ❖ **Veins of the systemic circulation:**
 - **Superior and Inferior vena cava** with their tributaries
- ❖ **Veins of the portal circulation:**
 - **Portal vein**



Superior Vena Cava

- ❖ **Formed by** the union of the **right and left Brachiocephalic veins**.
 - **Brachiocephalic veins** are formed by the union of **internal jugular and subclavian veins**.
- ❖ **Drains venous blood from :**
 - Head & neck
 - Thoracic wall
 - Upper limbs
- ❖ **It Passes** downward and **enter** the **right atrium**.
- ❖ **Receives azygos vein** on the posterior aspect just before it enters the heart.



Veins of Head & Neck

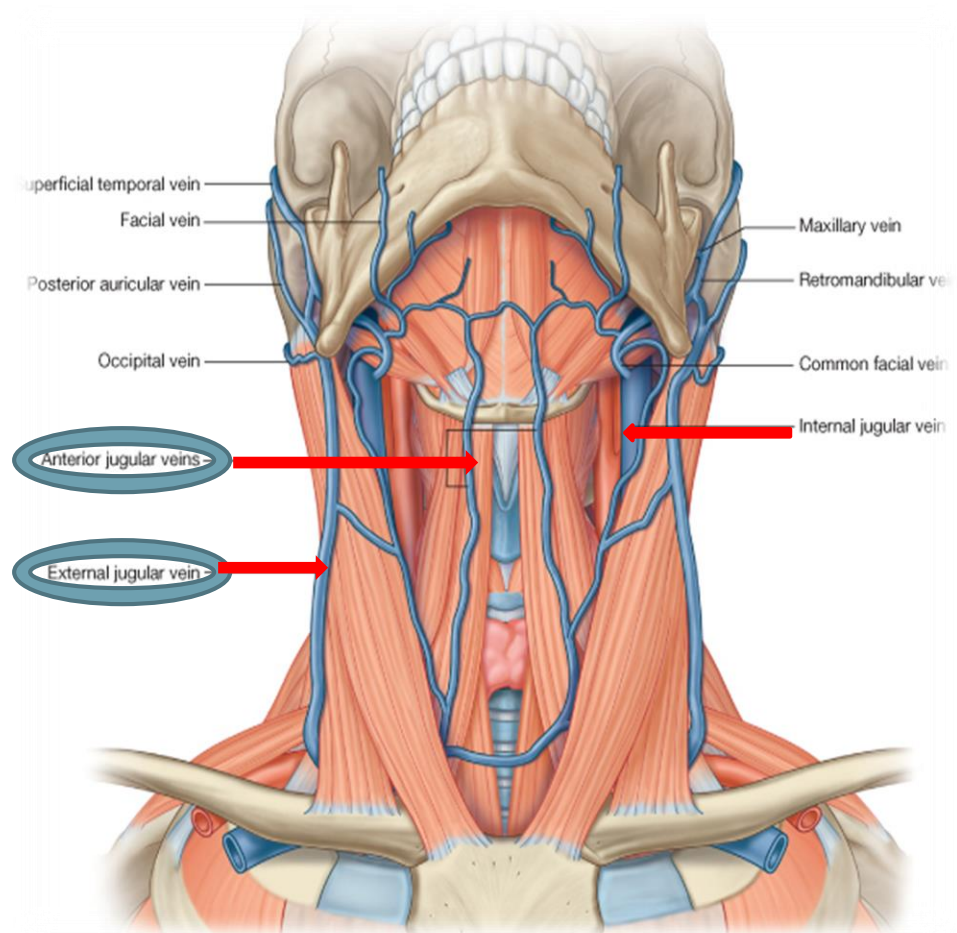
❖ Two divisions:

➤ Superficial Veins

- ✓ External Jugular veins
- ✓ Anterior jugular veins

➤ Deep Veins

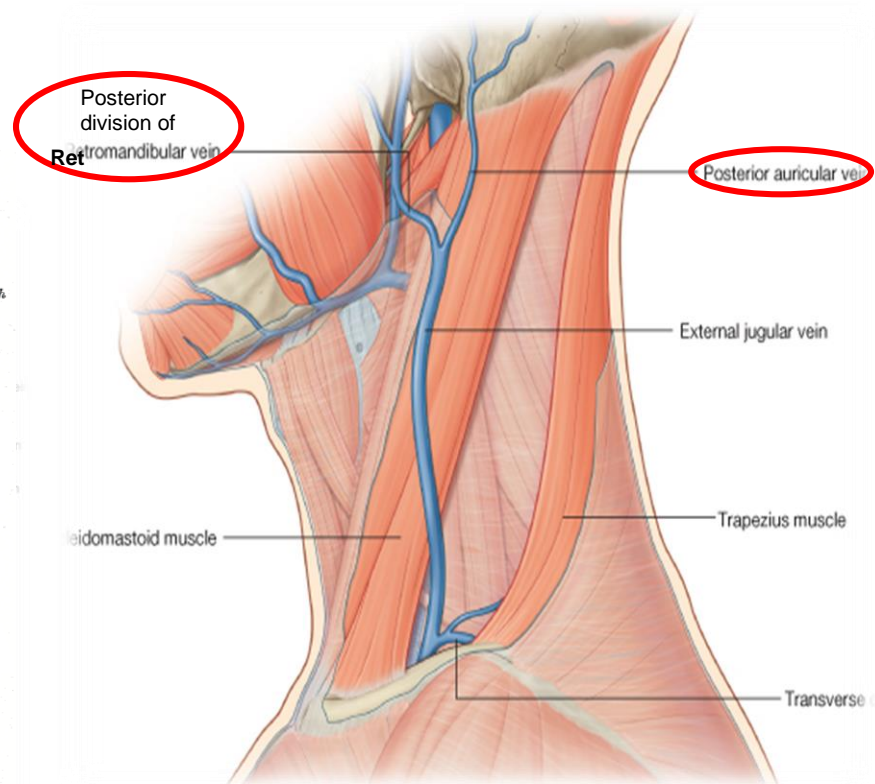
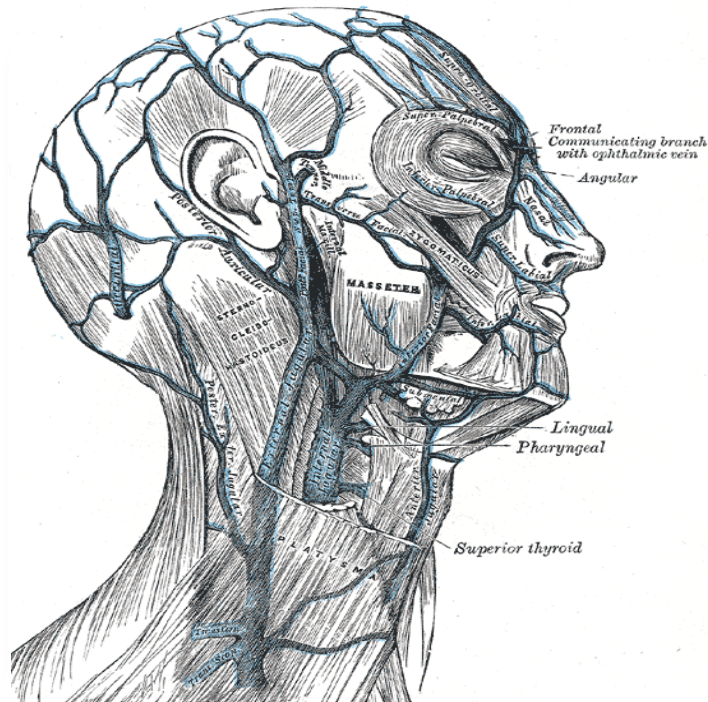
- ✓ Internal Jugulars veins.



Superficial Veins of Head & Neck

❖ External Jugular Vein:

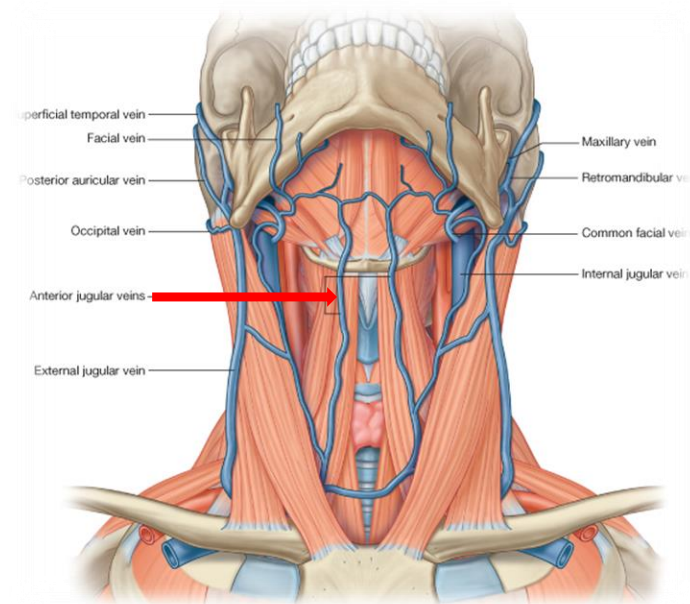
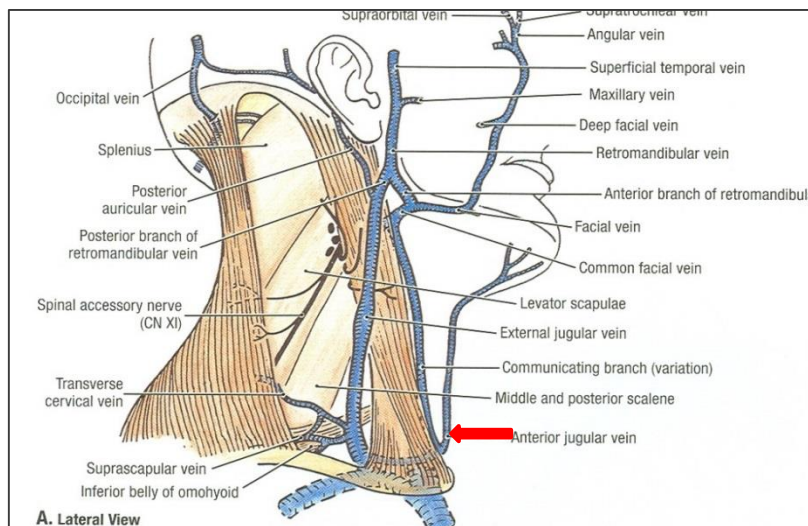
- Lies **superficial** to the **sternomastoid** muscle
- Begins just behind the angle of mandible by union of **posterior auricular vein** with the **posterior division of retromandibular vein**.
- It passes down the neck and it is the **only tributary** of the **subclavian vein**.
- **It drains** blood from:
 - ✓ Outside of the skull
 - ✓ Deep parts of the face.



Superficial Veins of Head & Neck

❖ Anterior jugular veins:

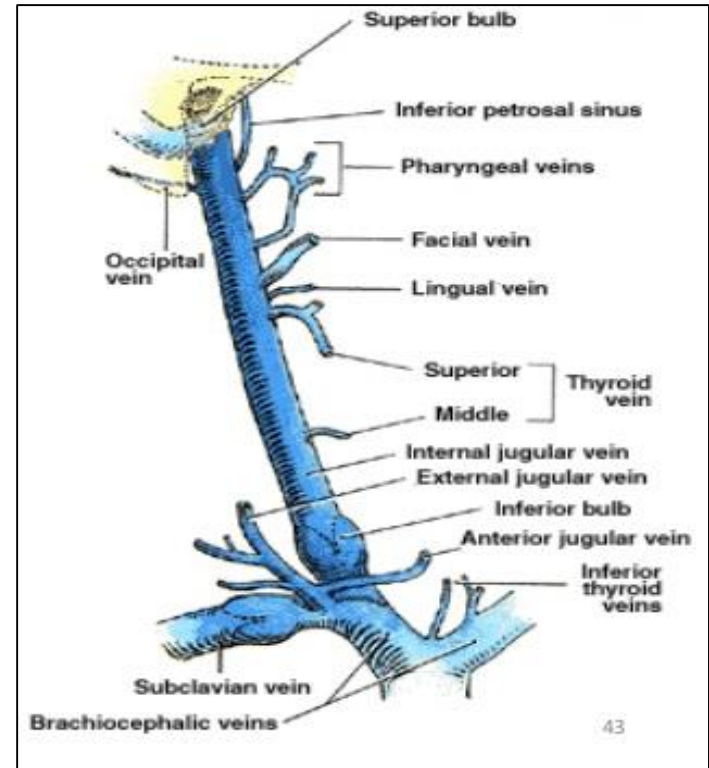
- **It begins** in the upper part of the neck by **the union of the submental veins**.
- **It descends** close to the median line of the neck, **medial to** the **sternomastoid**.
- **At the lower part of the neck**, it passes laterally **beneath (deep to) sternomastoid** muscle to **drain into** the **external jugular vein**.
- **Just above the sternum** the **two anterior jugular veins** **communicate** by a **transverse vein** to form the **jugular arch**.



Deep Veins of Head & Neck

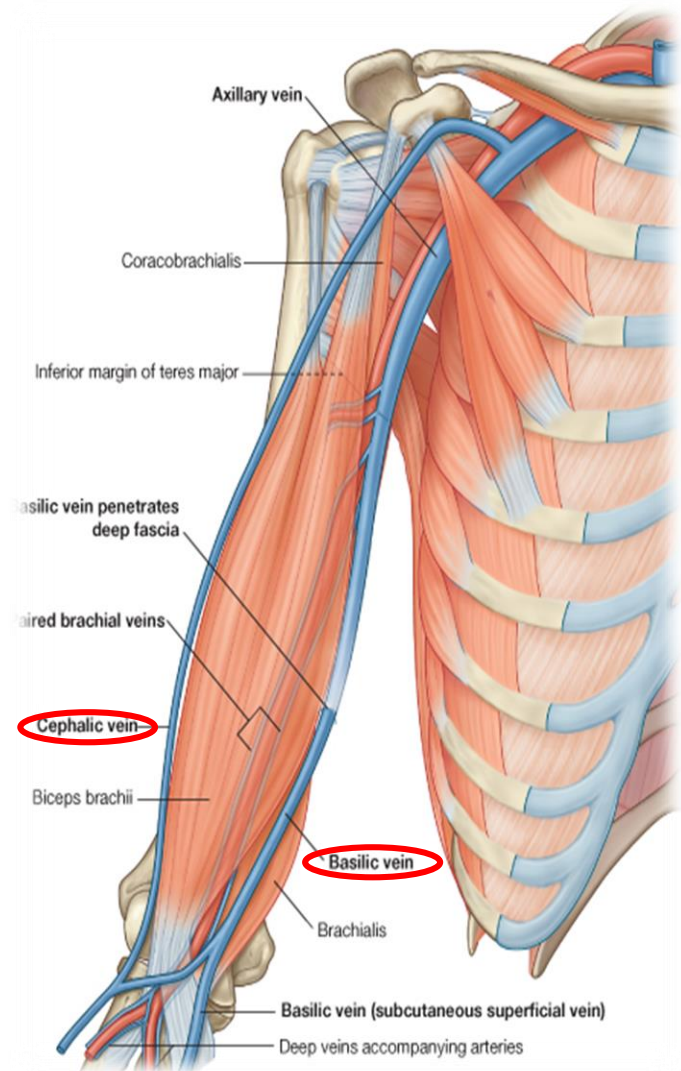
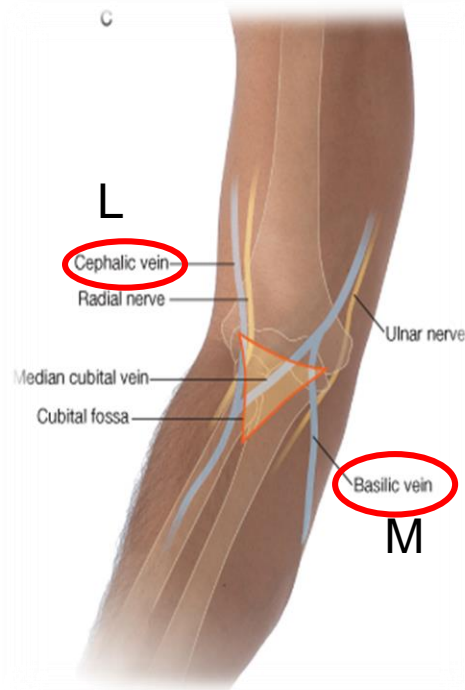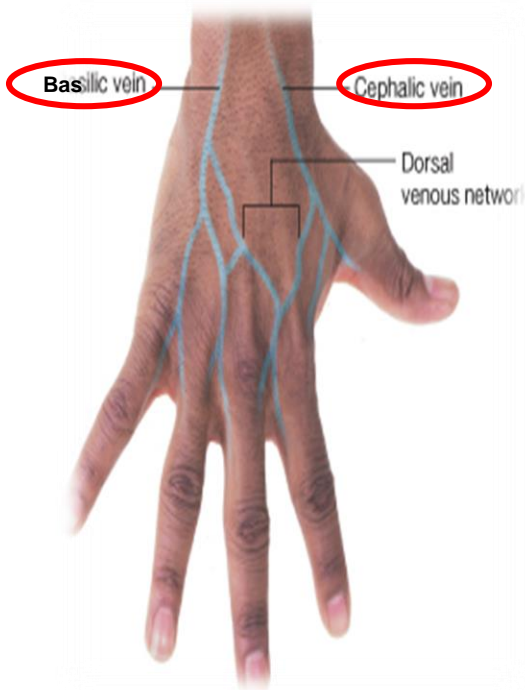
❖ Internal Jugulars vein:

- **Drains** blood from the brain, face, head & neck.
- It descends in the neck along with the **internal** and **common carotid** arteries and **vagus nerve**, within the **carotid sheath**.
- Joins the **subclavian vein** to form the **brachiocephalic vein**.
- **Tributaries:**
 - ✓ Superior thyroid
 - ✓ Lingual
 - ✓ Facial
 - ✓ Pharyngeal.
 - ✓ Occipital veins
 - ✓ Dural venous sinuses (inferior petrosal sinus).



Veins of Upper Limbs

- ❖ Two divisions:
 - Superficial Veins
 - Deep Veins



Veins of Upper Limbs

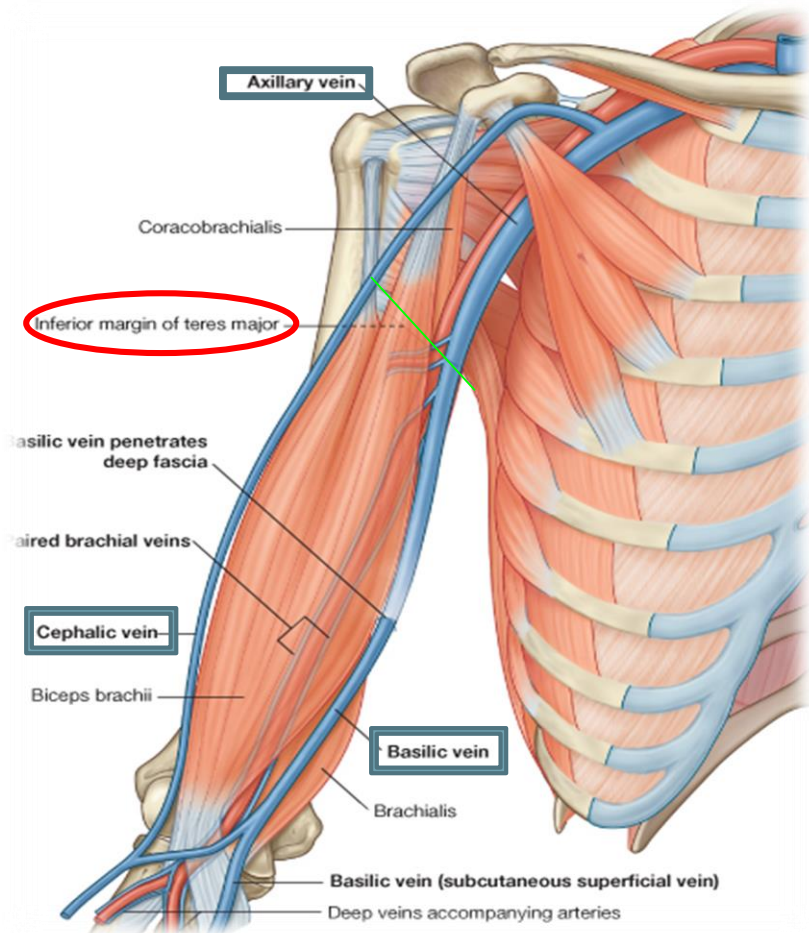
□ Superficial Veins

❖ Cephalic vein

- Ascends in the superficial fascia on the **lateral side** of the **biceps**.
- Drains into the **Axillary vein**.

❖ Basilic vein

- Ascends in the superficial fascia on the **medial side** of the **biceps**.
- Halfway up the arm, it **pierces the deep fascia**
- At the lower border of **teres major**; it **joins** the **venae comitantes** of the brachial artery **to form** the **Axillary vein**.



Veins of Upper Limbs

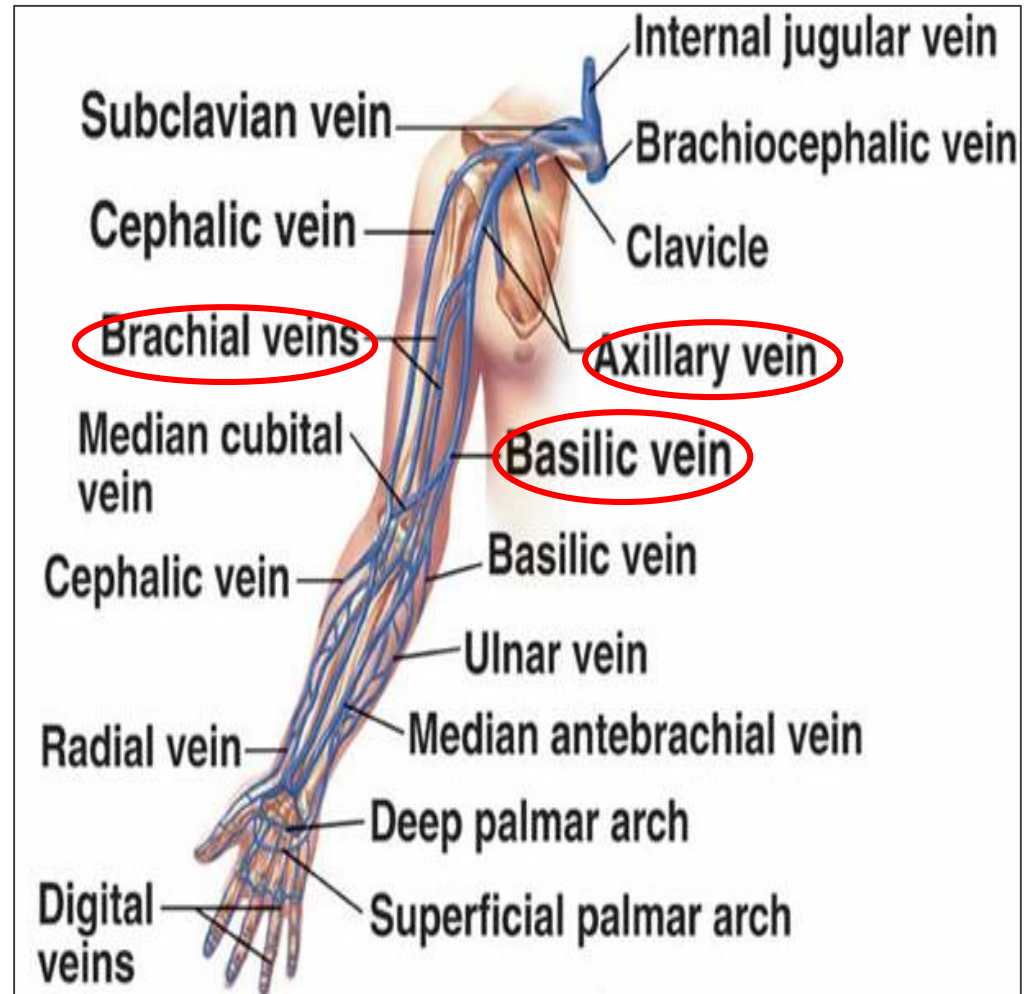
□ Deep Veins

❖ **Venae comitantes**

- Which accompany all the large arteries, usually in pairs.

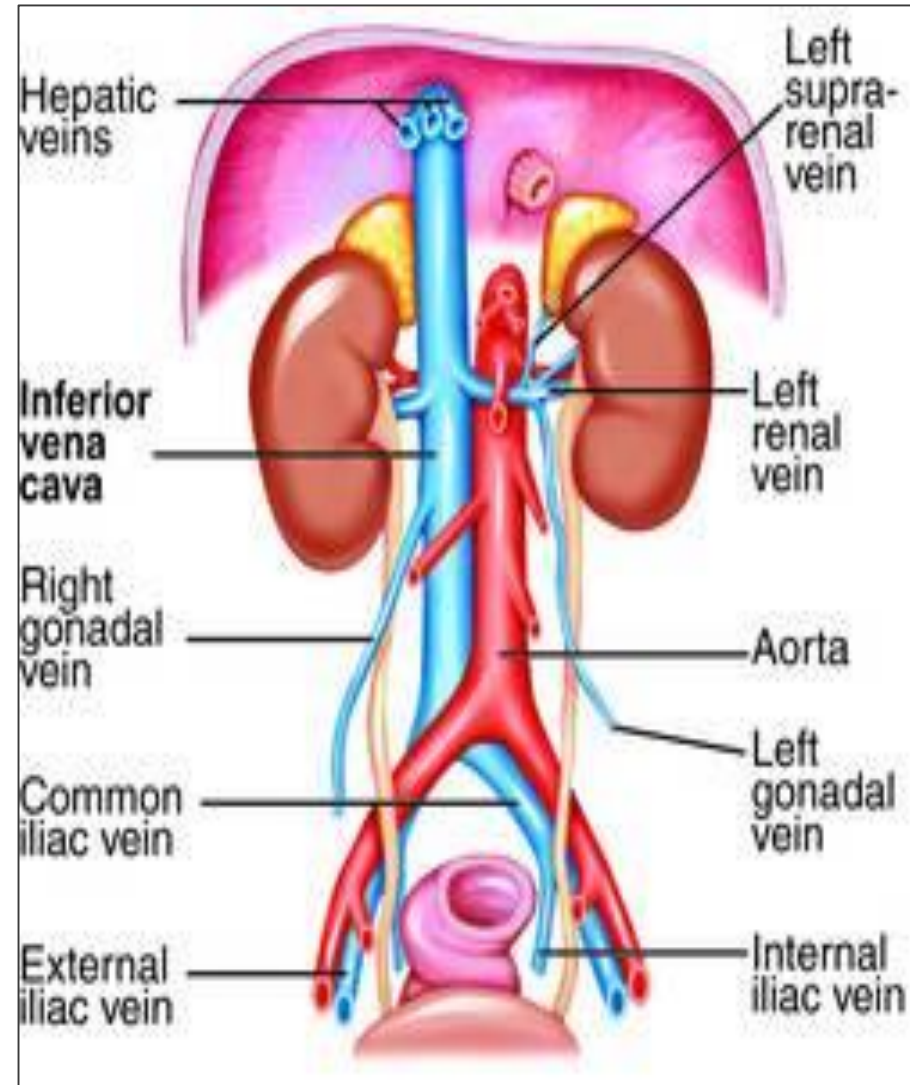
❖ **Axillary vein**

- **Formed by** the union of **basilic vein** and the **venae comitantes (brachial veins)** of the **brachial artery**.
- It drains **finally into** the **subclavian vein**.



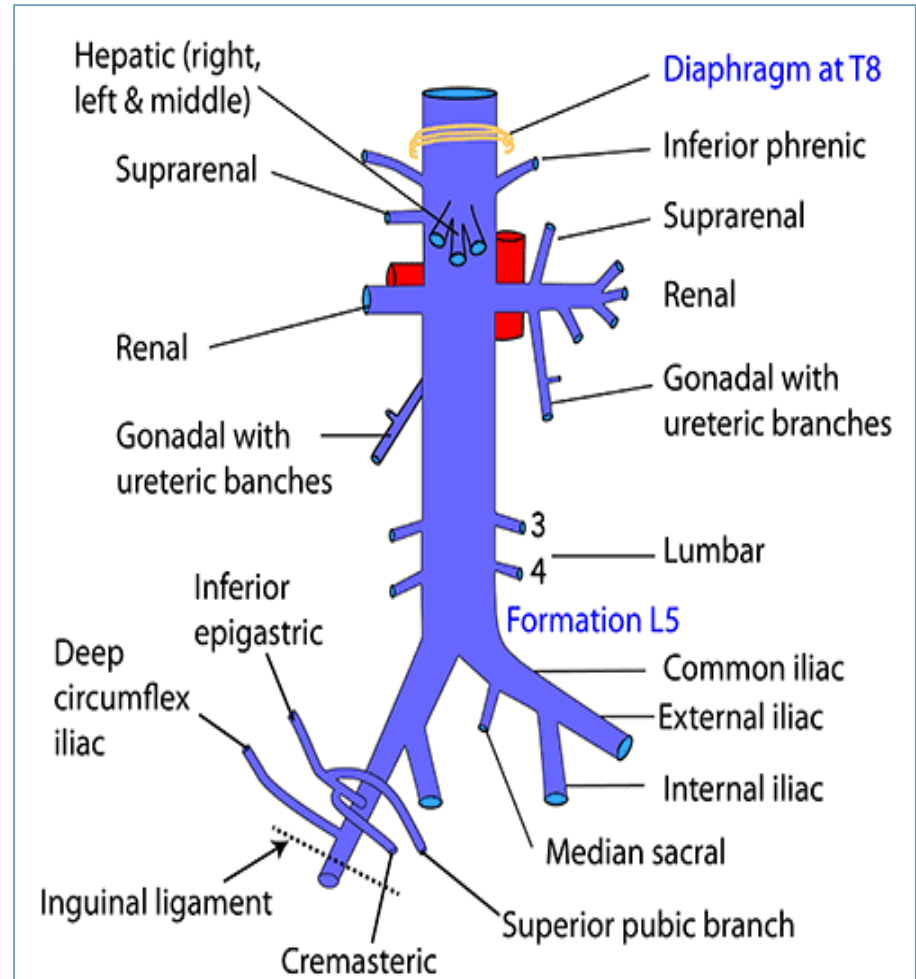
Inferior Vena Cava

- ❖ **Drains** most of the blood from the body below the diaphragm to the right atrium.
- ❖ **Formed by** the union of the 2 common iliac veins **behind** the **right common iliac artery at the level** of the 5th lumbar vertebra (L5).
- ❖ **Ascends** on the **right side** of aorta.
- ❖ **Pierces** the central tendon of **diaphragm** at the level of the 8th thoracic vertebra (T8).



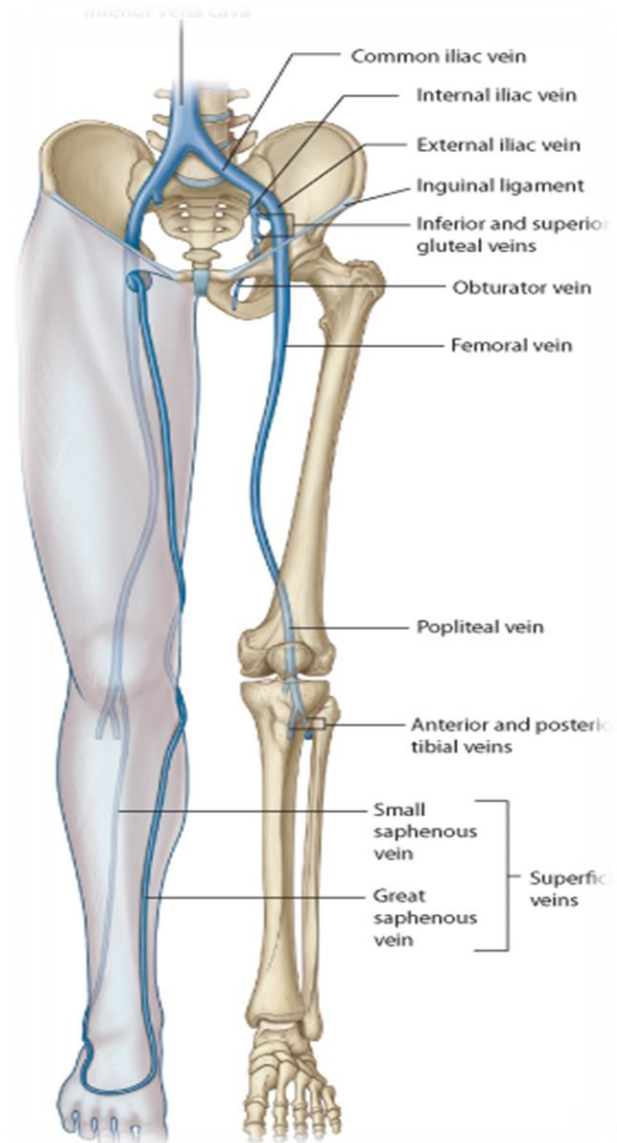
Tributaries of Inferior Vena Cava

- ❖ Two common iliac veins
- ❖ Median sacral vein
- ❖ Four paired lumbar veins
- ❖ Right gonadal vein
 - the left vein drains into the **left renal vein**
- ❖ Paired renal veins
- ❖ Right suprarenal vein
 - the left vein drains into the **left renal vein**
- ❖ Hepatic veins
- ❖ Paired inferior phrenic veins.



Veins of Lower Limbs

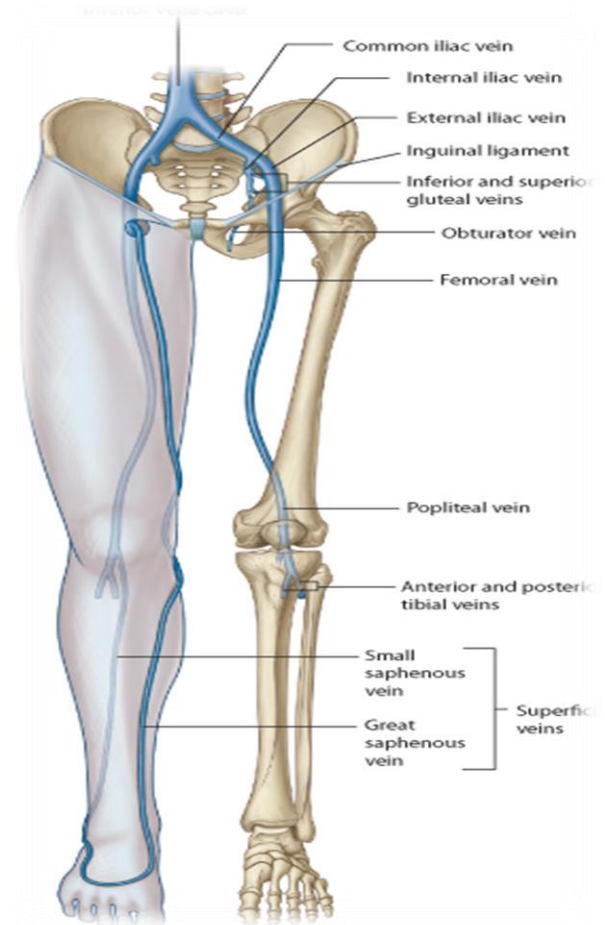
- ❖ **Two divisions:**
 - **Superficial Veins**
 - **Deep Veins**



Veins of Lower Limbs

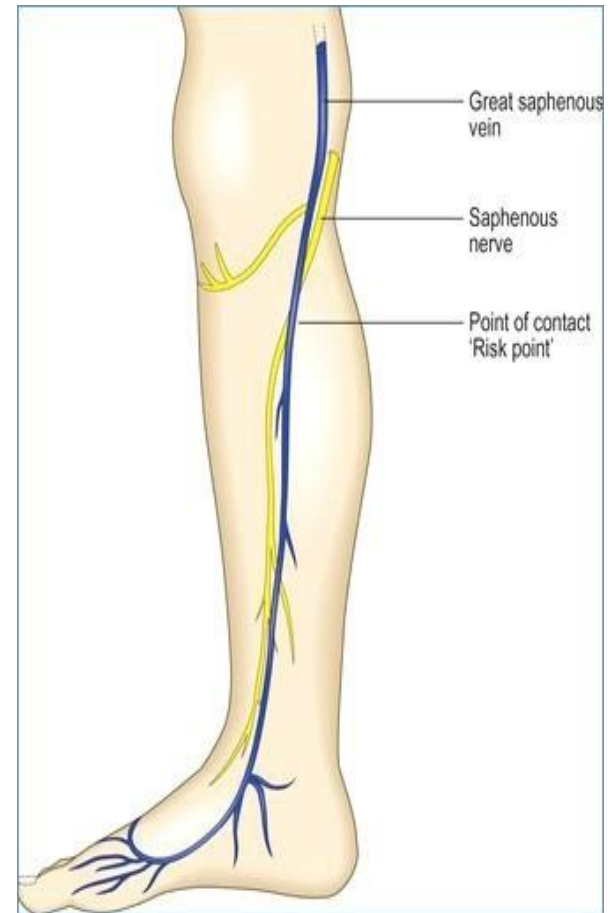
❑ Superficial Veins

- ❖ Form a network in the **subcutaneous tissue**.
- ❖ Pattern is variable
- ❖ **They are** the **tributaries** of the:
 - **Great (long) saphenous vein**
 - **Small (short) saphenous vein**



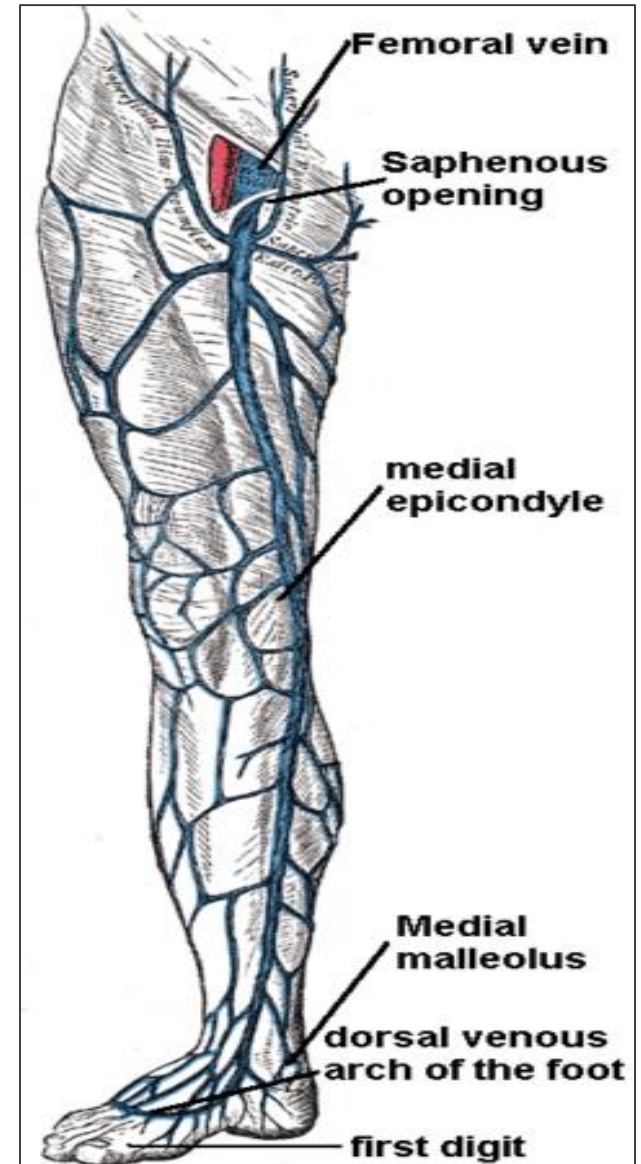
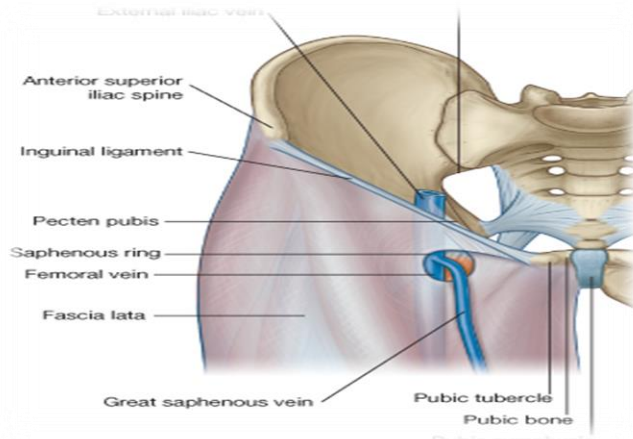
Great Saphenous Vein

- ❖ The longest vein
- ❖ **Begins** from the **medial end** of the **dorsal venous arch of the foot**.
- ❖ Passes upward **in front** of the **medial malleolus** with the **saphenous nerve**.
- ❖ Then it **ascends** in accompany with the **saphenous nerve in the superficial fascia** over the **medial side of the leg**.



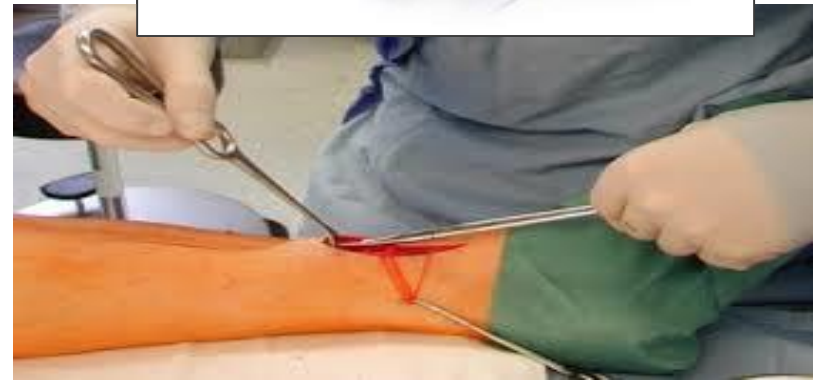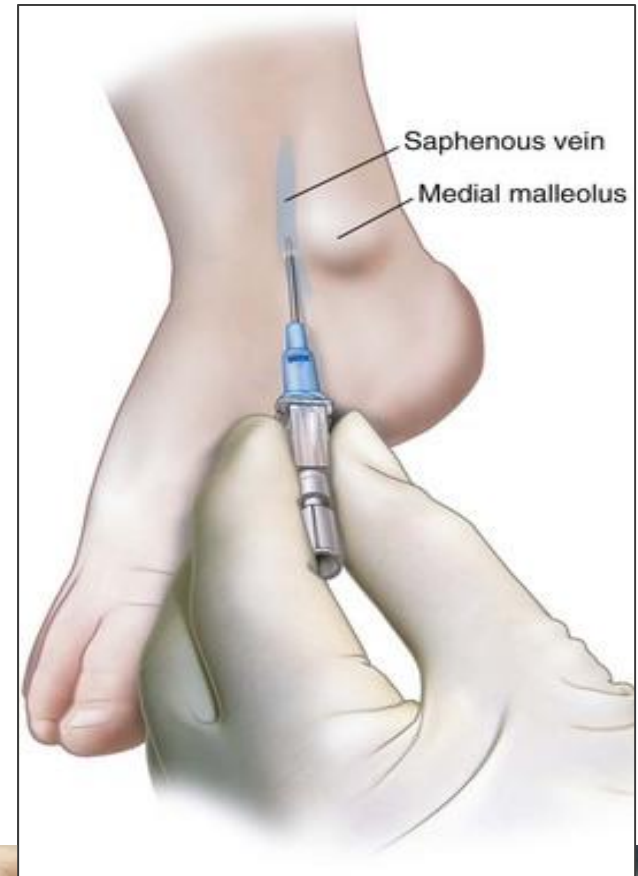
Great Saphenous Vein

- ❖ **Ascends** obliquely upwards, and lies **behind the medial border of the patella**.
- ❖ Passes **behind the knee** and curves forward around the **medial side of the thigh**.
- ❖ **Hooks** through the lower part of the saphenous opening in the deep fascia to **join the femoral vein** about 1.5 in. (4 cm) below and lateral to the **pubic tubercle**.



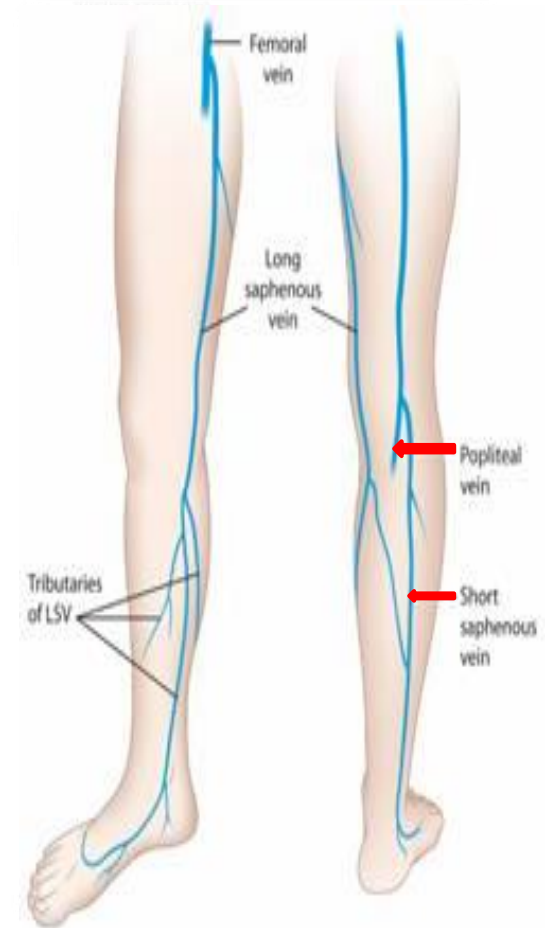
Great Saphenous Vein

- ❖ It is connected to the **small saphenous vein** **by one or two branches** that pass behind the knee.
- ❖ It is connected to the **deep veins** **by** numerous **perforating veins**.
- ❖ The **perforating veins** have **valves** which allow blood flow from **superficial** to **deep veins**.
- ❖ It is clinically significant in **coronary bypass surgery** and in **intravenous delivery of fluids** **due to other venous collapse**.
- ⦿ The great saphenous vein is **used in venous grafting** and **saphenous vein cutdown** may be necessary for inserting the needle or canula (take care of the **saphenous nerve**).



Small Saphenous Vein

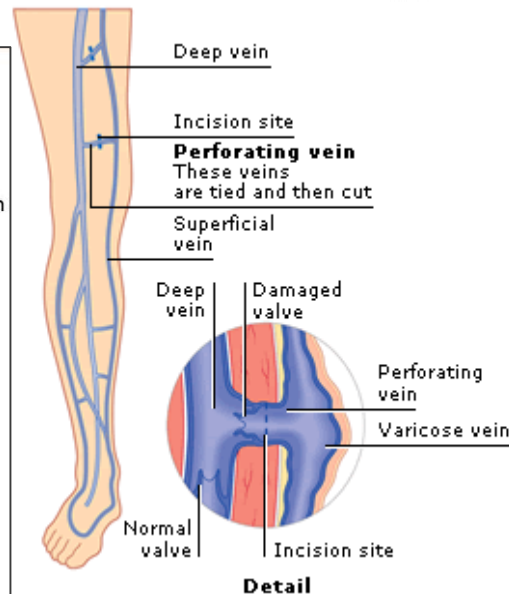
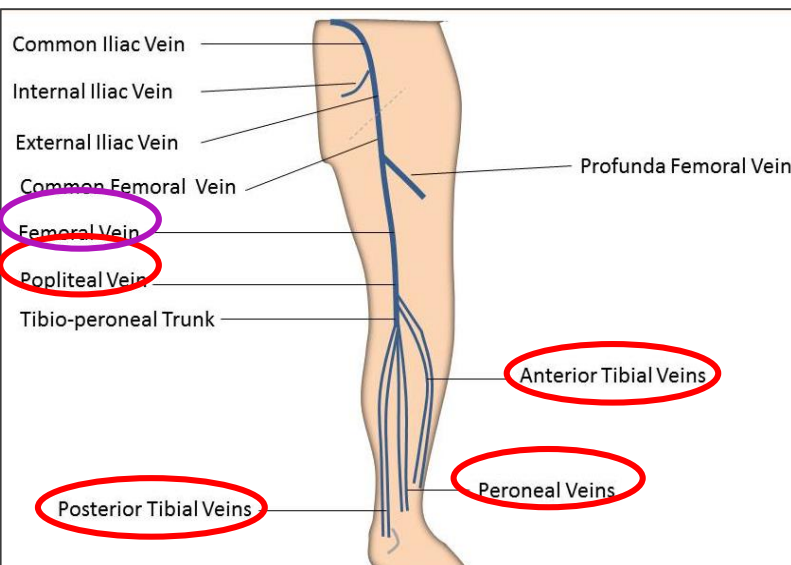
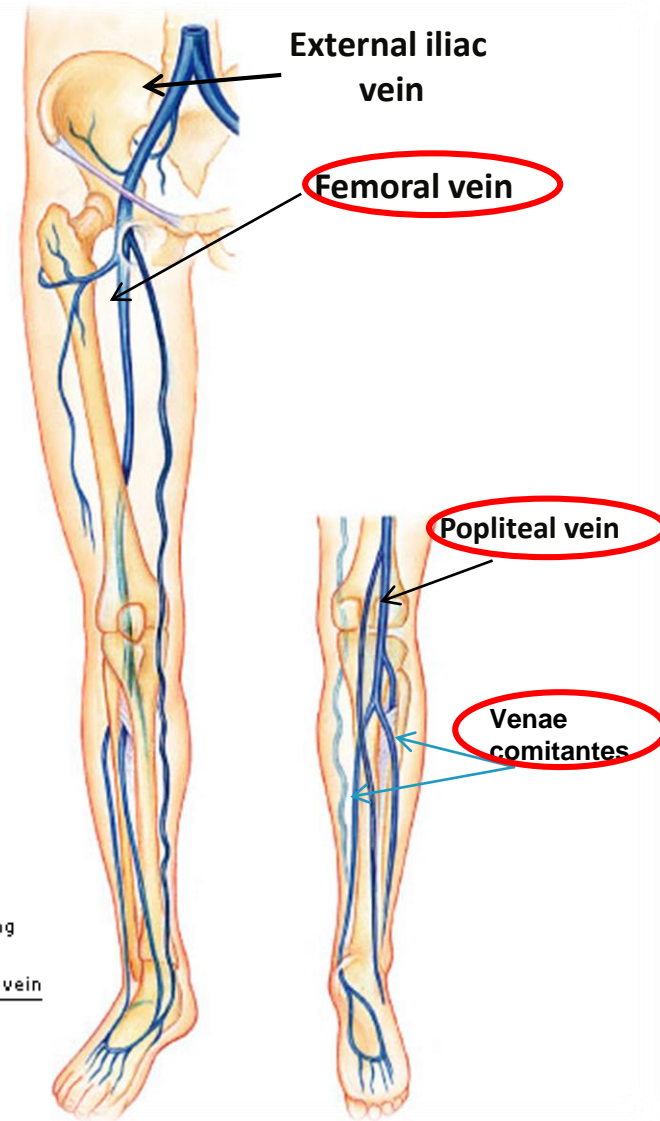
- ❖ **Arises** from the **lateral end** of the **dorsal venous arch**.
- ❖ **Ascends behind** the **lateral malleolus** in company with the **sural nerve**.
- ❖ **Ascends** along the lateral border of the **tendocalcaneus** and then **runs up** to the **back of the leg**.
 - **Pierces** the **deep fascia** in the **lower part** of the **popliteal fossa**
 - **Drains into** the **popliteal vein**
 - Has **numerous valves** along its course.
 - Anastomosis freely with great saphenous vein.



Veins of Lower Limbs

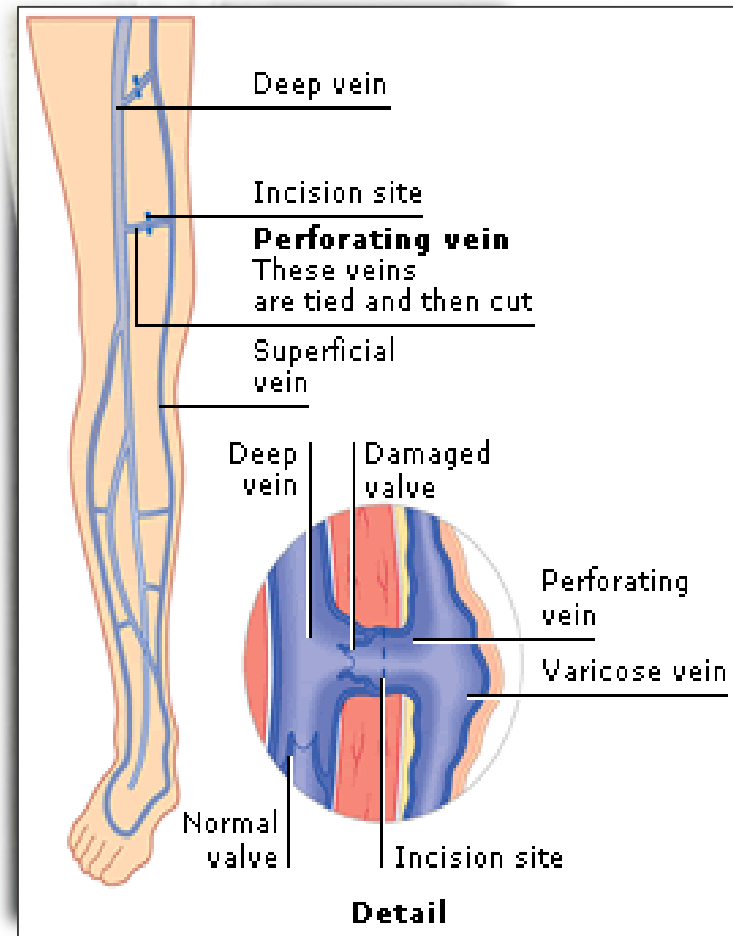
❑ Deep Veins

- ❖ Comprise the **venae comitantes**, which accompany all the large arteries, usually in pairs.
- ❖ **Venae comitantes** unite to form the **popliteal vein**, which continues as the **femoral vein**.
- ❖ **Deep veins** **Receive** blood from **superficial veins** through **perforating veins**.



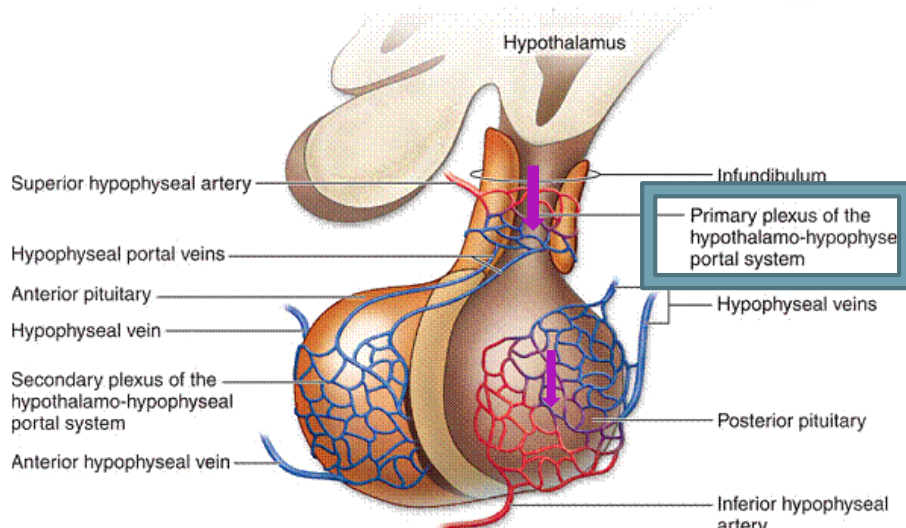
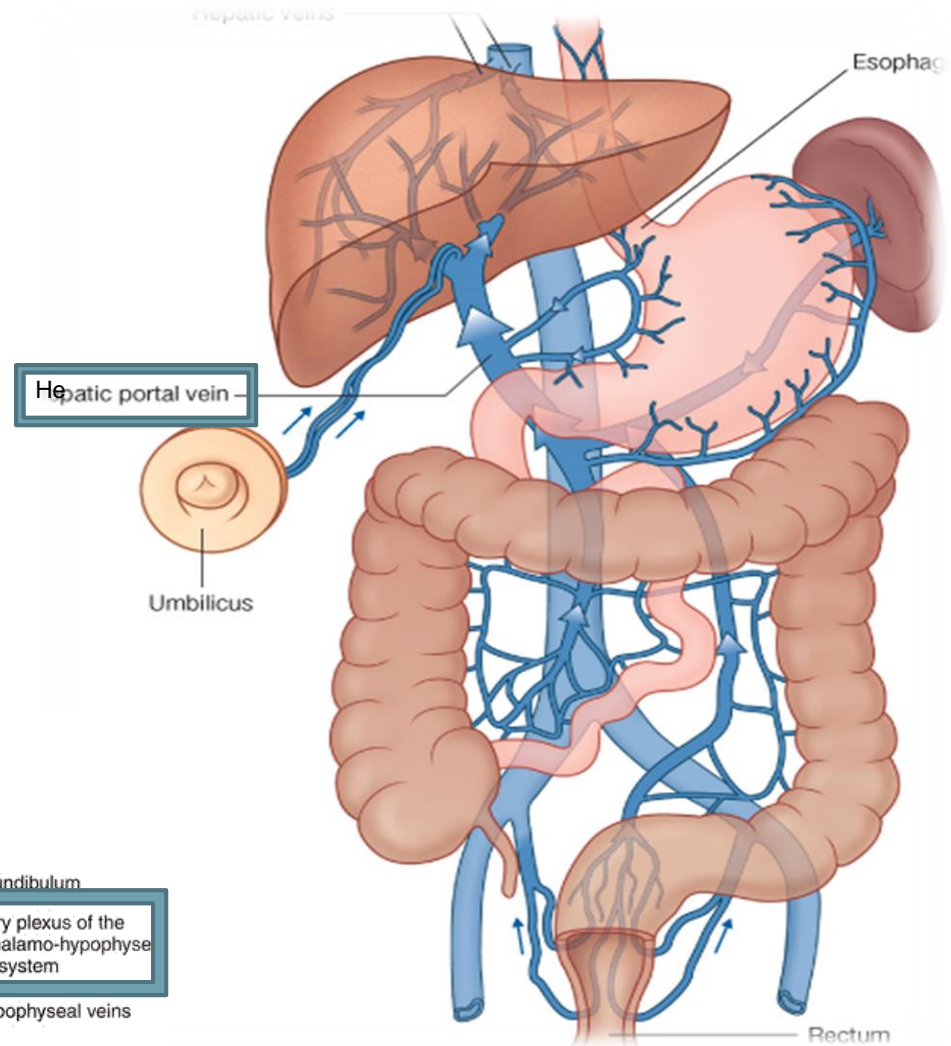
Mechanism of Venous Return from Lower Limb (FYI) (For Your Information)

- ❖ Much of the **saphenous blood** passes from **superficial to deep veins** through the **perforating veins**
- ❖ The blood is pumped upwards in the **deep veins** by the **contraction of the calf muscles (calf pump)**.
- ❖ This action of 'calf pump' is **assisted by the tight sleeve of deep fascia** surrounding these muscles.
- ❖ **Varicose veins:** If the **valves** in the **perforating veins** become **incompetent**, the direction of **blood flow is reversed** and the veins become **varicose**. Most common in **posterior & medial parts of the lower limb**, particularly in old people.



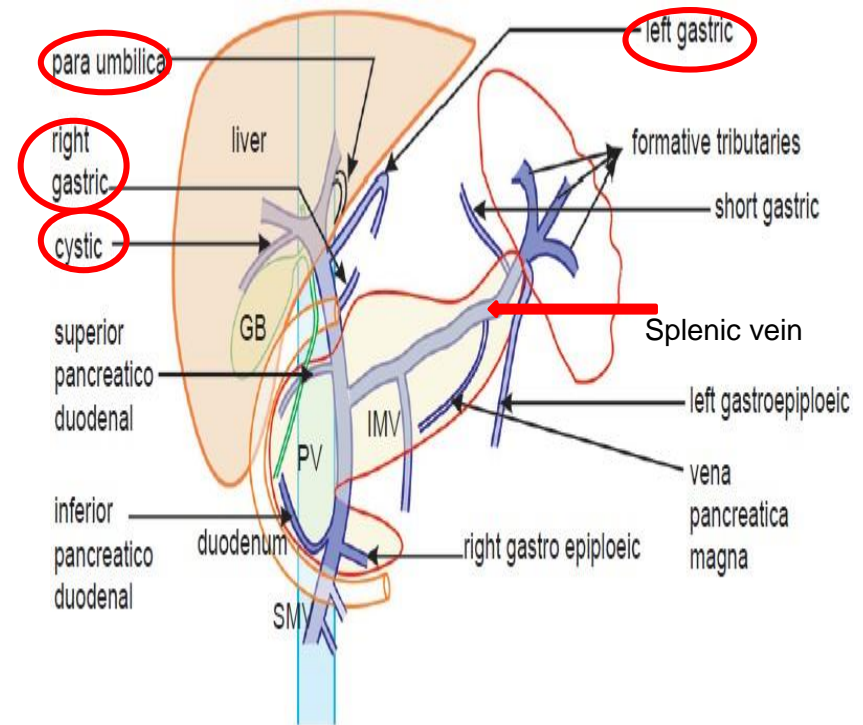
Portal Circulation

- ❖ **A portal venous system** is a series of veins or venules that directly connect two capillary beds (of arteriole & venule).
- ❖ **Examples** of such systems include the **hepatic portal vein** and **hypophyseal portal system**.



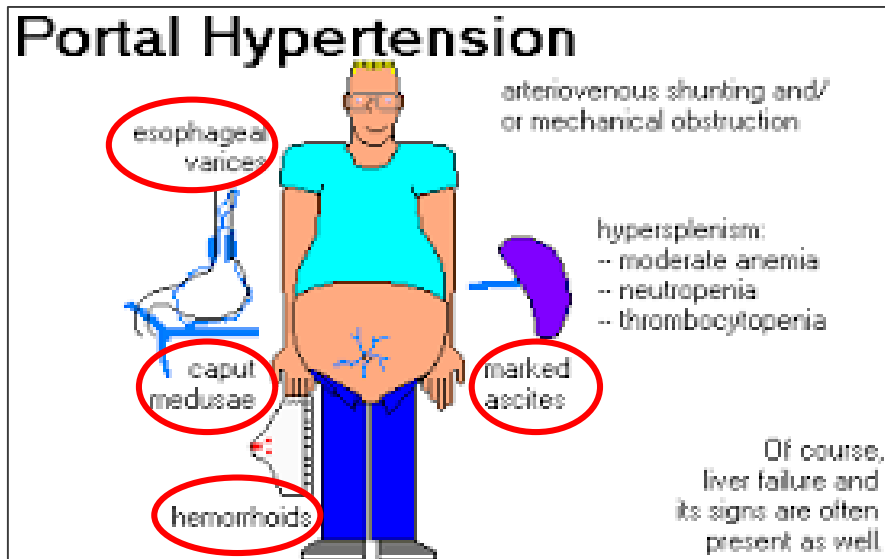
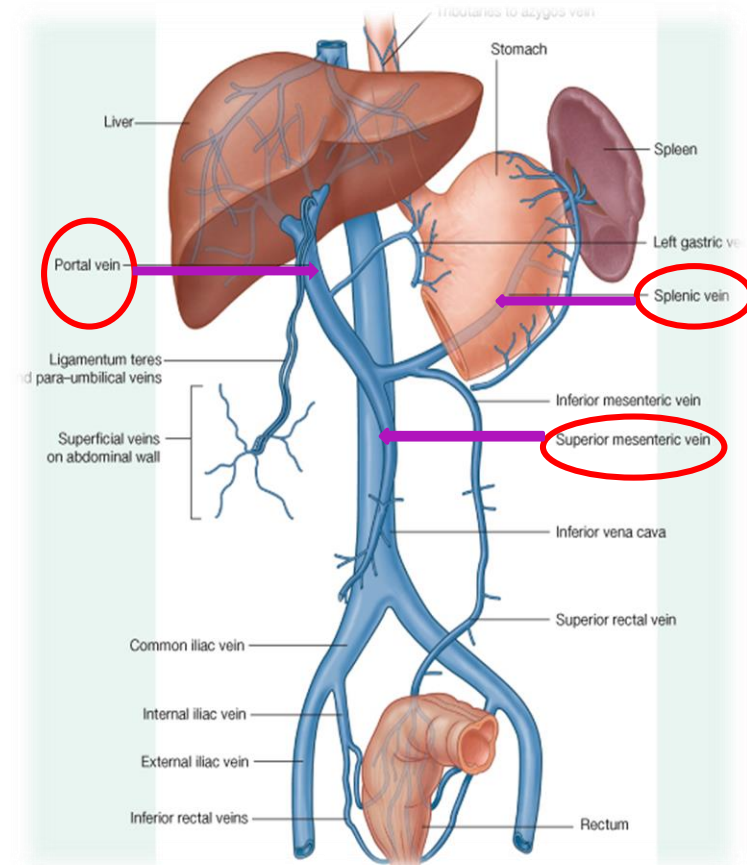
Hepatic Portal Vein

- ❖ Drains blood from the **gastrointestinal tract** and **spleen to the liver**.
- ❖ It is formed by the union of the **superior mesenteric** and **splenic veins behind the neck of pancreas**.
- ❖ Immediately before reaching the liver, the **portal vein divides** into **right** and **left** that **enter the liver**.
- ❖ Tributaries:
- ❖ **Right** and **Left Gastric veins**.
- ❖ **Cystic vein** from the gall bladder joins its right branch..
- ❖ **Para-umbilical veins** that drain veins from anterior abdominal wall to the hepatic portal vein.



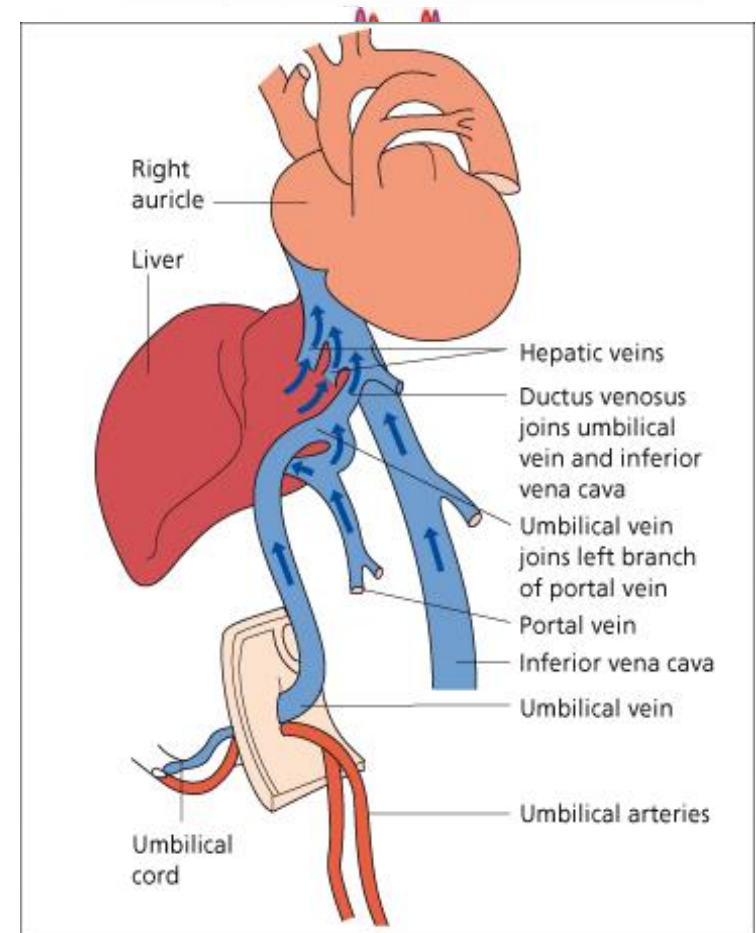
Portocaval Anastomosis

- ❖ A portocaval anastomosis (also known as portal systemic anastomosis) is a **specific** type of anastomosis that occurs **between** the **veins of portal circulation** and those of **systemic circulation (IVC)**.
- ❖ The anastomotic channels become **dilated (varicose)** in case of **portal hypertension**.



Sites of Portocaval Anastomosis

- ❖ **Lower end of esophagus:**
- ❖ (esophageal varices) left gastric vein (Portal) & esophageal branch of azygos vein.
- ❖ **Lower part of rectum: (Hemorrhoids)** superior rectal vein (Portal) & middle rectal and inferior rectal veins.
- ❖ **Para umbilical region : (Caput Medusae)** Para umbilical veins (portal) & superficial epigastric vein.
- ❖ **Retroperitoneal :** Colic veins (Portal) & veins of the posterior abdominal wall (Retroperitoneal veins).
- ❖ **Patent ductus venosus (intrahepatic portosystemic shunt) :**
Portosystemic shunts may be congenital or may be acquired with diseases that cause portal hypertension.
Umbilical vein + portal vein & IVC.
(Hepatomegaly, ascitis and signs of portal hypertension).



The image features two large, stylized yellow roses with white and yellow petals, set against a teal background. The roses are framed by a dark red border. The text "THANK YOU" is centered over the roses in a black, serif font with a white outline.

THANK YOU