



PATHOLOGY OF RENAL ALLOGRAFT

APRIL 2019

REFERENCE: ROBBINS & COTRAN PATHOLOGY AND RUBIN'S PATHOLOGY

OBJECTIVES:

- At the end of the lecture the students will be able to:
- Recognize the concept of renal allograft.
- Describe the pathology of rejection and differentiate acute cell-mediated and antibody-mediated rejection.
- Differentiate between acute and chronic rejection.
- Recognize the pathology of the principal infections inherent to renal transplantation.
- Recognize the pathology of acute and chronic drug toxicity.

Key Outlines:

- Acute T-cell mediated rejection.
- Acute antibody-mediated rejection.
- Pathology of chronic rejection.
- Pathology of the principal infections of the renal allograft: CMV-polyoma.
- Pathology of acute and chronic drug toxicity.

LECTURE OUTLINE

Pathology of injury in kidney transplant

- Harvest injury
- Rejection:
 - Hyper-acute rejection
 - Acute rejection
 - Chronic rejection
- Infections of the renal allograft e.g. CMV and polyoma virus.
- Acute and chronic immunosuppressive drug toxicity.
- Recurrence of primary disease
- De-novo (new) disease

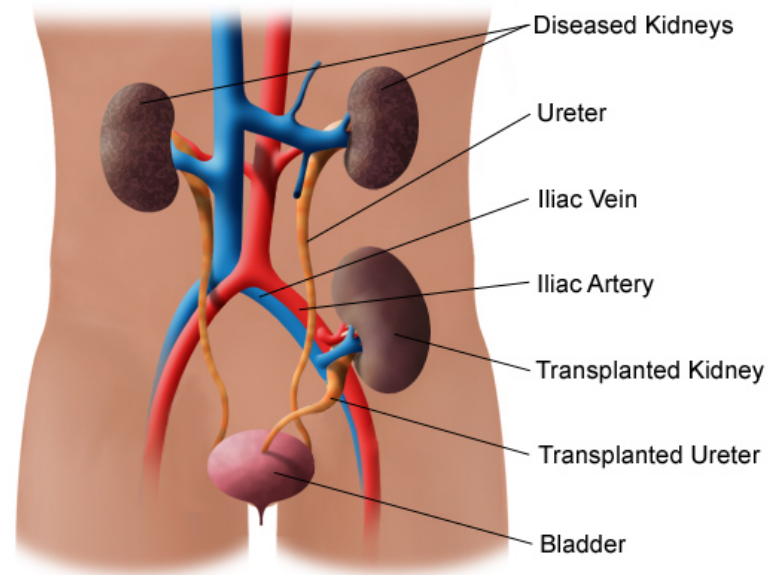
KIDNEY TRANSPLANT:

- Renal transplantation and dialysis are the treatments for patients with end-stage renal disease (ESRD) resulting from a variety of causes.
- Kidney transplantation is now a routine procedure in most large hospitals in the world.
- The first kidney transplant between humans, was conducted in 1933 by a Russian surgeon in Ukraine. The kidney was implanted in the groin under local anesthesia, and the host survived four days.
- The transplanted kidney is called the allograft or the graft.
- The antigens present in the allograft kidney are called alloantigens.

KIDNEY TRANSPLANT

- The donor kidney which is placed in the recipients iliac fossa or groin region. The ureter is inserted into the bladder. The blood vessels are anastomosed.
- The donor of the kidney can be living or deceased.

Example of a Kidney Transplant





HARVEST INJURY



HARVEST INJURY

- At the time of transplant there can be tubular injury to the transplanted allograft kidney.
- It is generally due to cold ischemia time or the mode of donor death.
- It can lead to non-functioning kidney immediately after engraftment in which the patient will have anuria.
- Harvest kidney usually recover.



REJECTION



REJECTION

- Rejection is a major complication seen post-transplantation.
- Transplant rejection occurs when transplanted tissue is rejected by the recipient's immune system and it destroys the transplanted tissue.

There are different types of rejection:

- a) Hyper-acute rejection
- b) Acute rejection
 - acute T-cell mediated rejection
 - and acute antibody-mediated rejection.
- c) Chronic rejection
 - chronic T-cell mediated rejection
 - and chronic antibody-mediated rejection.

Rejection has been classified by a system called as the Banff Classification

A) HYPERACUTE REJECTION

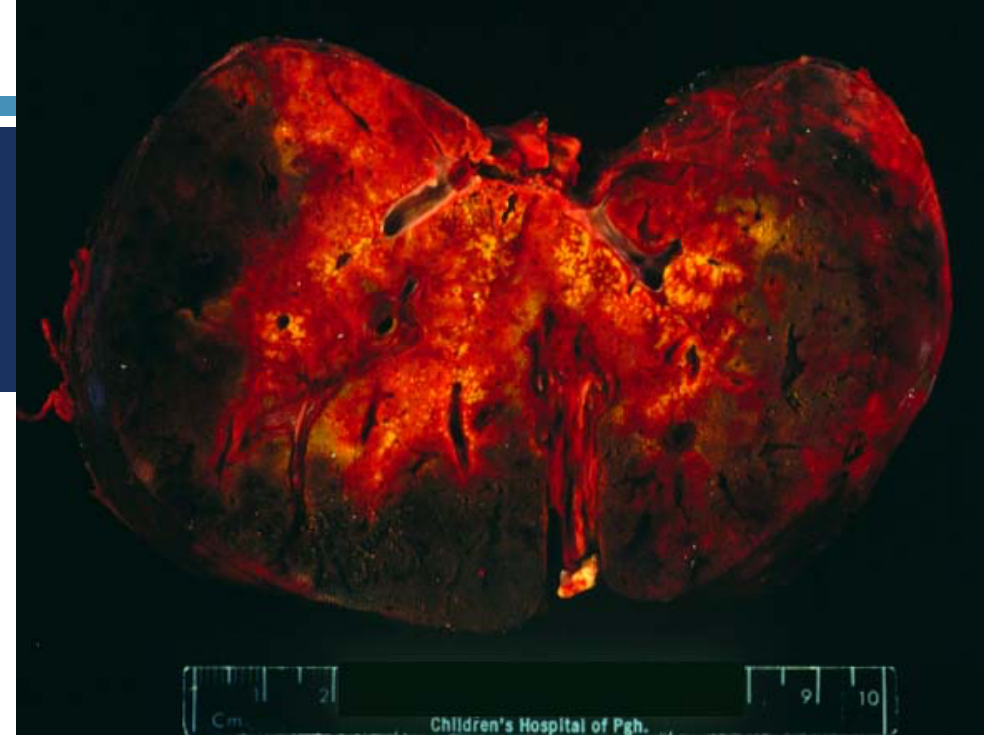- Rare
- Rejection immediately after implantation and perfusion of graft
- Occurs within minutes to hours after transplantation. It leads to vasculitis, arterial thrombosis, fibrinoid necrosis of the blood vessel, hemorrhage, edema, infarct of the kidney (coagulative necrosis) and loss of graft.

Gross

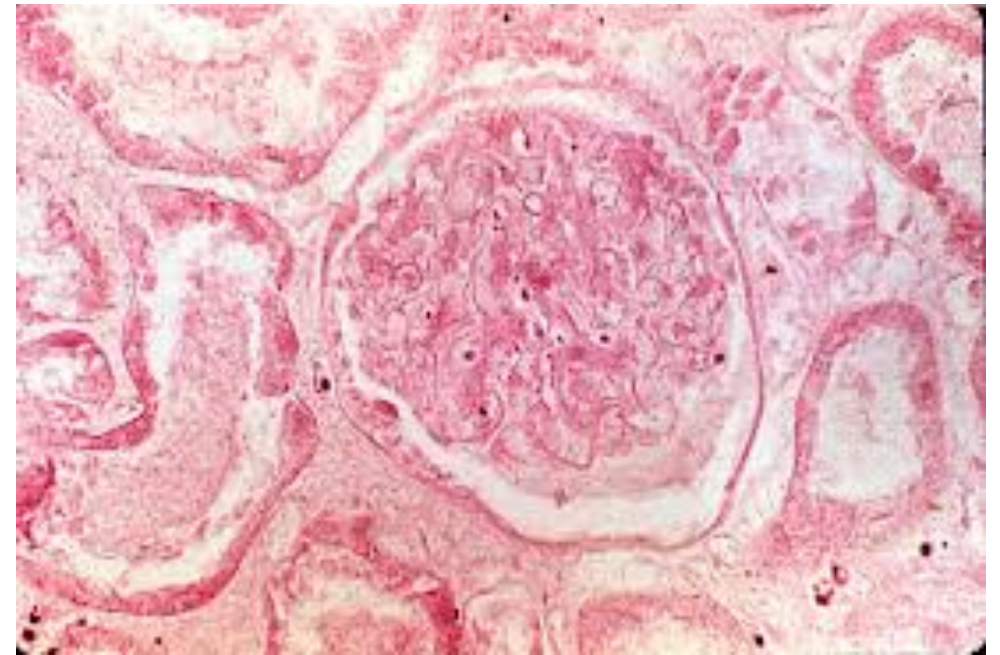
- Cyanosis of graft minutes to hours after perfusion
- Becomes swollen, hemorrhagic, and necrotic

Microscopic

- Thrombi in glomeruli and arterioles
- Interstitial edema and hemorrhage
- Cortical necrosis in 12-24 hours



<https://tpis.upmc.com/tpis/images/H00021k.jpg>



B) ACUTE REJECTION

- Acute Rejection is the most common type of rejection in the newly transplanted kidney patient. Developing in a short time span. It can occur within days or the first few months after surgery. Sometimes it can occur after years.
- 2 types
 - **Acute T-cell mediated rejection.**
 - **Acute antibody-mediated rejection.**

ACUTE REJECTION

ACUTE T-CELL MEDIATED REJECTION.

- It is a common form of rejection. It is an acute immune reaction by the recipient against the alloantigens (antigens present in the allograft). It is mediated by T cells.
- Classically it develops in the first 3 months after transplantation, but may erupt at any time, even after many years.
- Clinically → loss of graft function, rising creatinine. It responds well to immunosuppressive drug therapy
- There is infiltration of allograft by lymphocytes and other inflammatory cells.

ACUTE REJECTION

ACUTE T-CELL MEDIATED REJECTION.

MICROSCOPY

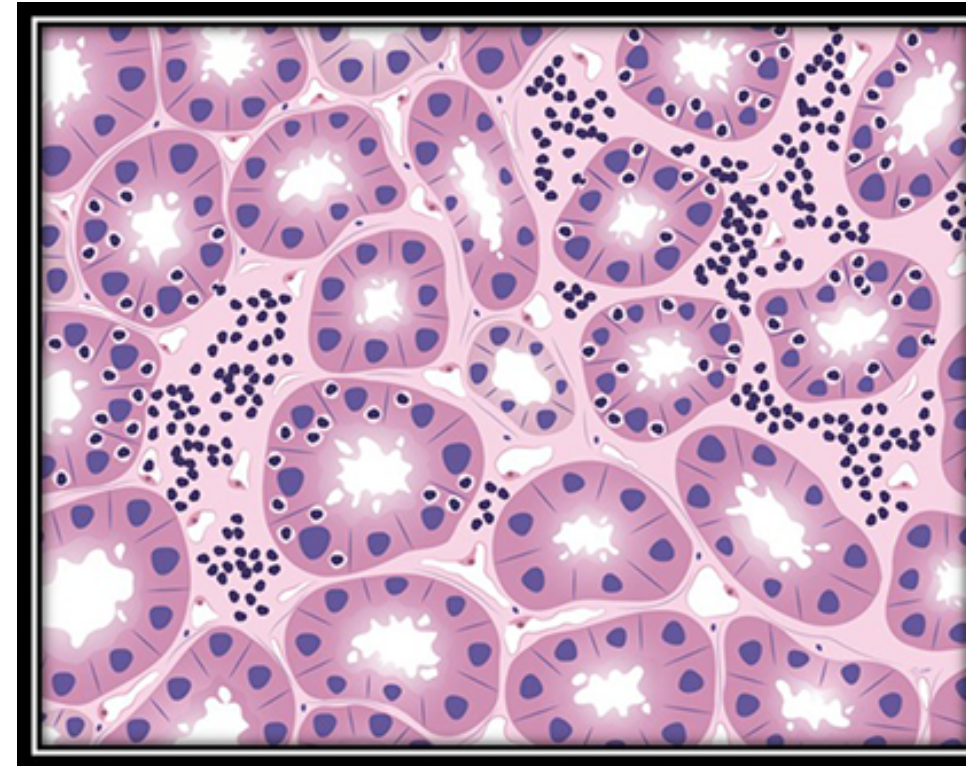
1. Tubulointerstitial inflammation
(interstitial inflammation & tubulitis)

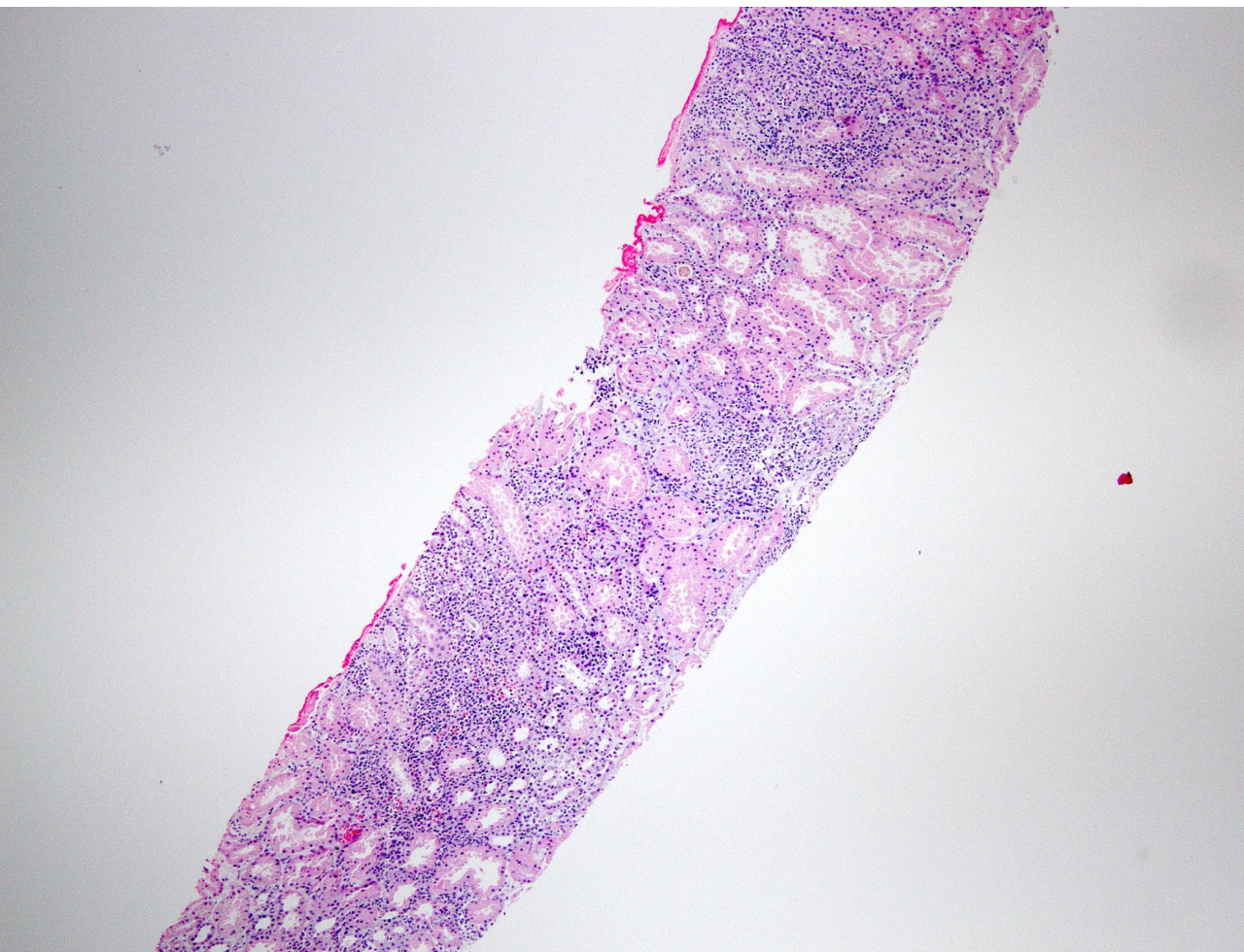
with or without

arteritis (+/- fibrinoid necrosis of arteries)

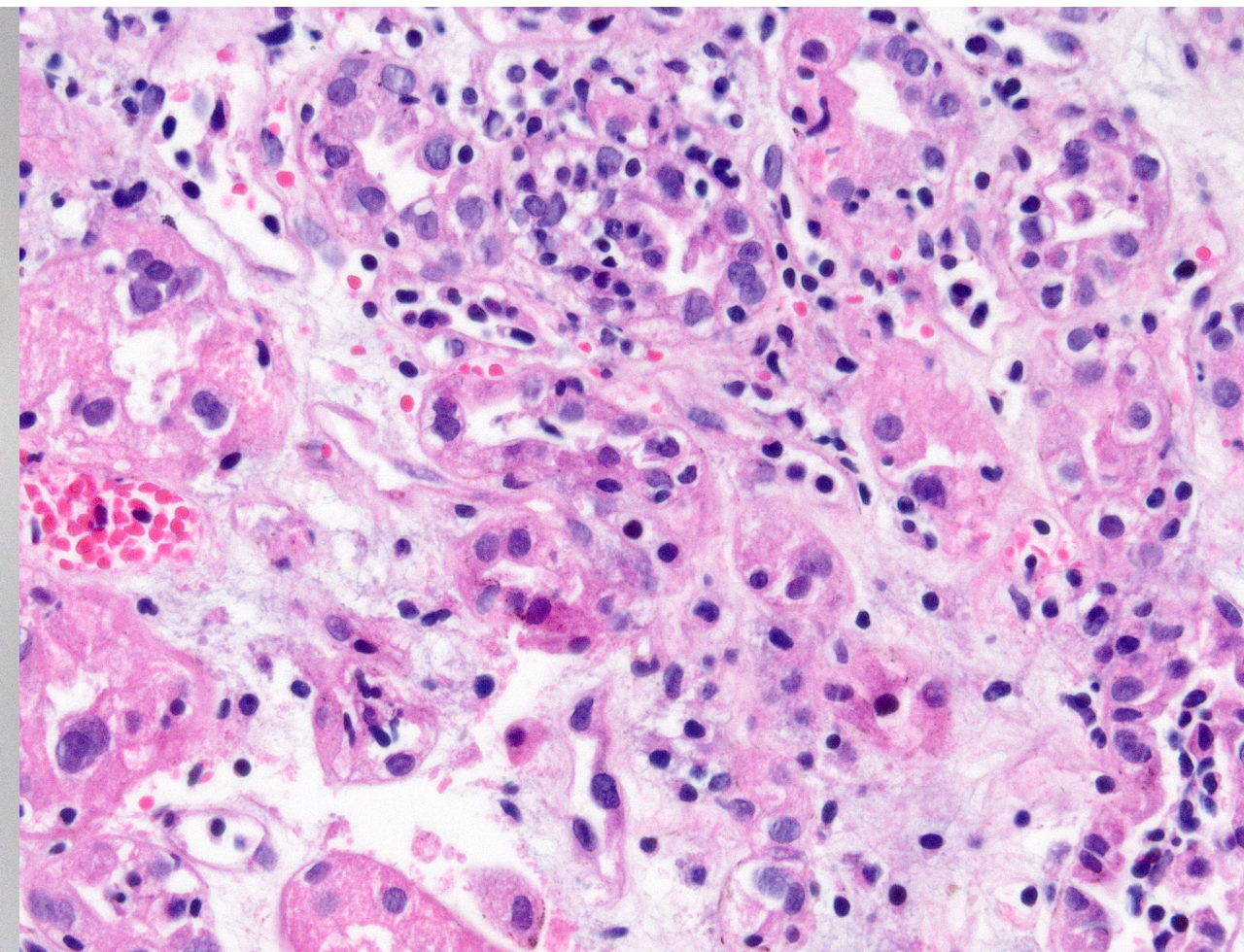
2. Interstitial edema and sometimes hemorrhage

Note: glomerular usually not involved



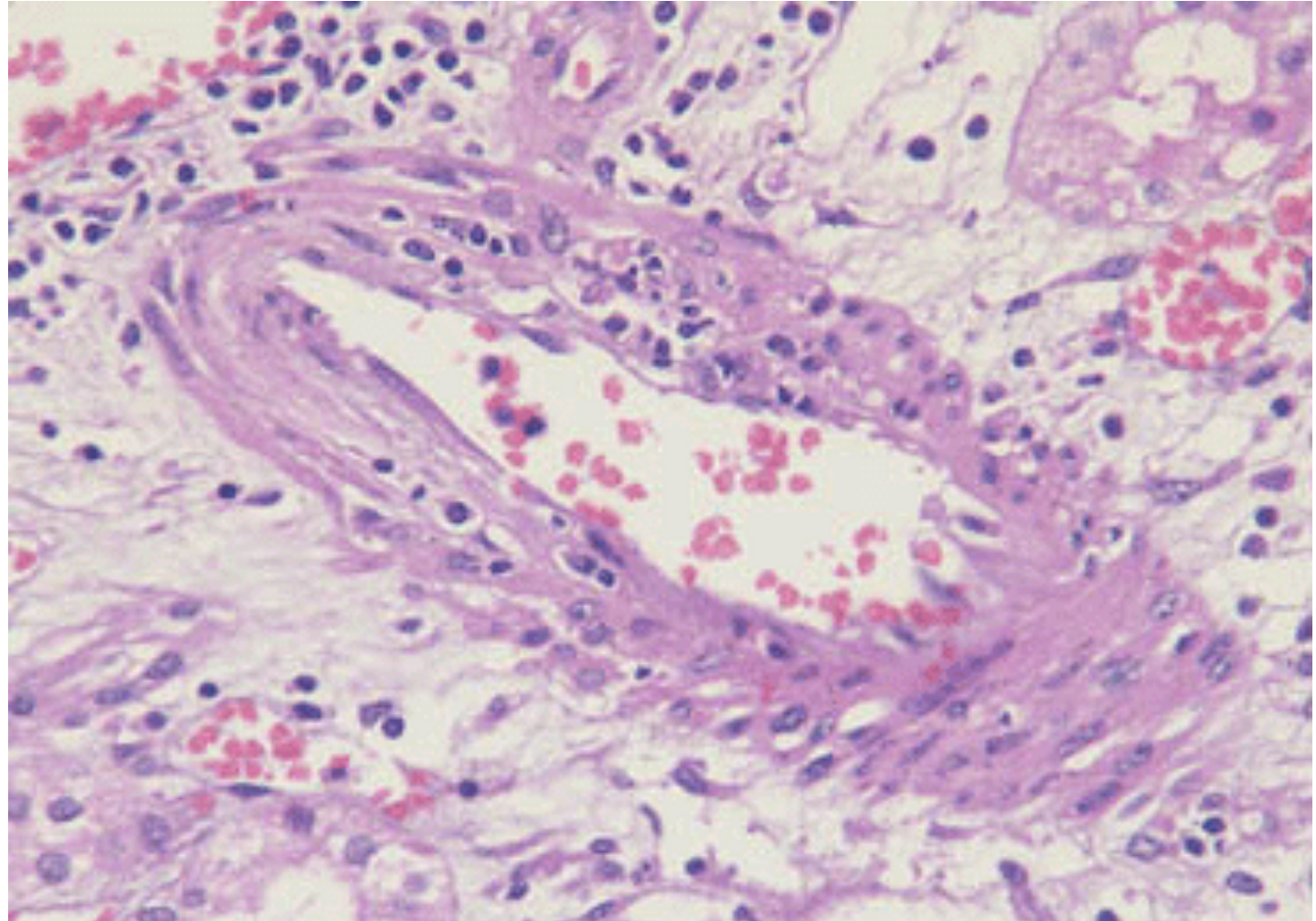


Low power demonstrates prominent inflammatory infiltrate in the tubulointerstitial space



Areas of tubulitis; note inflammatory cells within tubuli

ARTERITIS (VASCULITIS)



ACUTE REJECTION

ACUTE ANTIBODY-MEDIATED REJECTION

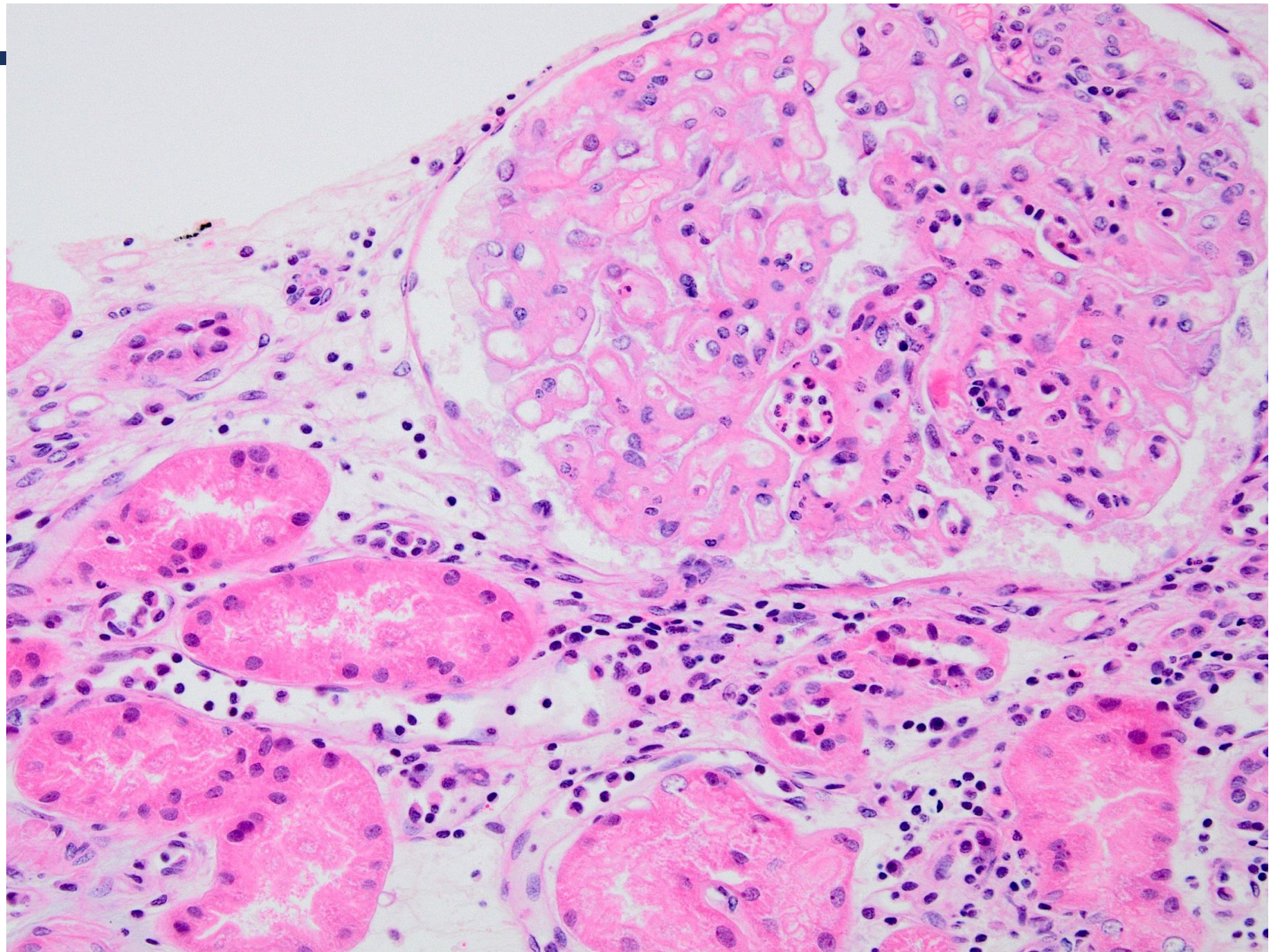
- Also called as acute humoral rejection.
- It is mediated by the anti-donor specific antibodies.
- It is an acute immune reaction in which the recipient has preformed circulating anti-donor specific alloantibodies (DSA). These antibodies are directed against the endothelial cells in the allograft → rejection.
- The microvasculature of the kidney (i.e. glomeruli and peritubular capillaries) is the main target.
- Clinical: loss of graft function, rising creatinine, acute renal failure and oliguria.

ACUTE REJECTION

ACUTE ANTIBODY-MEDIATED REJECTION

- Microscopy:
 - ✓ Glomerulitis, capillaritis of the peritubular capillaries, C4d stain positivity in the peritubular capillaries.
 - ✓ Acute tubular injury/ necrosis.
 - ✓ Arteritis +/- fibrinoid necrosis.
 - ✓ Acute thrombotic microangiopathy like picture

**GLOMERULITIS
&
PERITUBULAR
CAPILLARITIS**



C) CHRONIC REJECTION

- Chronic rejection is the type of rejection that happens over an extended period of time. This type of rejection can → loss of the graft.
- Usually occurs after the first year of transplantation.
- Clinically: gradual rise in serum creatinine. Patients presents with chronic graft dysfunction/ chronic renal failure, proteinuria and hypertension.
- It does not respond to immunosuppressive therapy.
- Persistent or recurrent episodes of T-cell-mediated rejection or antibody-mediated rejection → lead to chronic changes in allograft → chronic rejection.
- Microscopy
 - ✓ Tubular atrophy.
 - ✓ Interstitial fibrosis.
 - ✓ Arteries show intimal fibrosis with chronic inflammation.
 - ✓ Chronic antibody mediated rejection also shows a unique type of glomerular injury called transplant glomerulopathy.



INFECTIONS OF THE RENAL ALLOGRAFT



INFECTIONS OF THE RENAL ALLOGRAFT

- The renal allograft recipient immunosuppressed and predisposed to renal infections like adenovirus, cytomegalovirus and polyomavirus and Epstein–Barr virus (EBV).
- They cause mononuclear tubulointerstitial inflammation, acute tubular injury and the tubular epithelial cells show viral cytopathic changes.
- They can lead to graft loss.
- Infection with EBV can also lead to post transplant lymphoproliferative disorder (PTLD).



DRUG TOXICITY



DRUG TOXICITY

- Calcineurin inhibitors/CNI are immunosuppressive drugs used to decrease the recipients immune system's response to the transplanted kidney and therefore helps suppress acute rejection.
- Examples of CNI drugs: cyclosporine and tacrolimus
- CNIs are also nephrotoxic and can cause acute or chronic damage to the graft. They cause:
- Acute CNI toxicity in the kidney:
- Chronic CNI toxicity in the kidney:
- Lab result →
 - elevated of serum creatinine,
 - elevated blood/ serum CNI levels

ADDITIONAL/ OPTIONAL INFORMATION

- Acute CNI toxicity → acute tubular injury with focal isometric vacuolization of proximal tubular segments and acute thrombotic microangiopathy like picture.
- Chronic CNI toxicity → striped interstitial fibrosis and tubular atrophy, microcalcifications, nodular arteriolar hyalinosis and chronic thrombotic microangiopathy like picture.

RECURRENT & DE-NOVO DISEASE

5) Recurrence of primary disease

- The primary disease which lead to end stage kidney and eventual transplant can recur as early as 6 months post-transplant.
- It is not very common.

6) De-novo (new) disease/ glomerulonephritis

- It is the development of another kidney disease in the renal allograft, different from the disease the patient originally suffered from.
- It is very rare.



END

