

INFLAMMATION AND REPAIR

Lecture 5

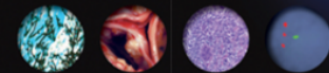
Tissue Repair and Regeneration

Dr. Maha Arafah
Associate Professor
Department of Pathology
King Saud University
Email: marafah@ksu.edu.sa
marafah@hotmail.com

Page 87-95

Robbins
**BASIC
PATHOLOGY**

TENTH EDITION



KUMAR
ABBAS
ASTER

ELSEVIER

Objectives

Upon completion of this lecture, the student should:

- 1. Describe the differences between repair processes: regeneration, healing and fibrosis. List examples of each cell type.**
- 2. Know the differences between the various cell in regenerative abilities types.**
- 3. Know the mechanism of repair and formation of granulation tissue.**
- 4. List the three main phases of cutaneous wound healing.**
- 5. Compare and contrast the difference between healing by primary intention and healing by secondary intention.**
- 6. List factors which are associated with delayed wound healing.**
- 7. List complication of wound healing.**

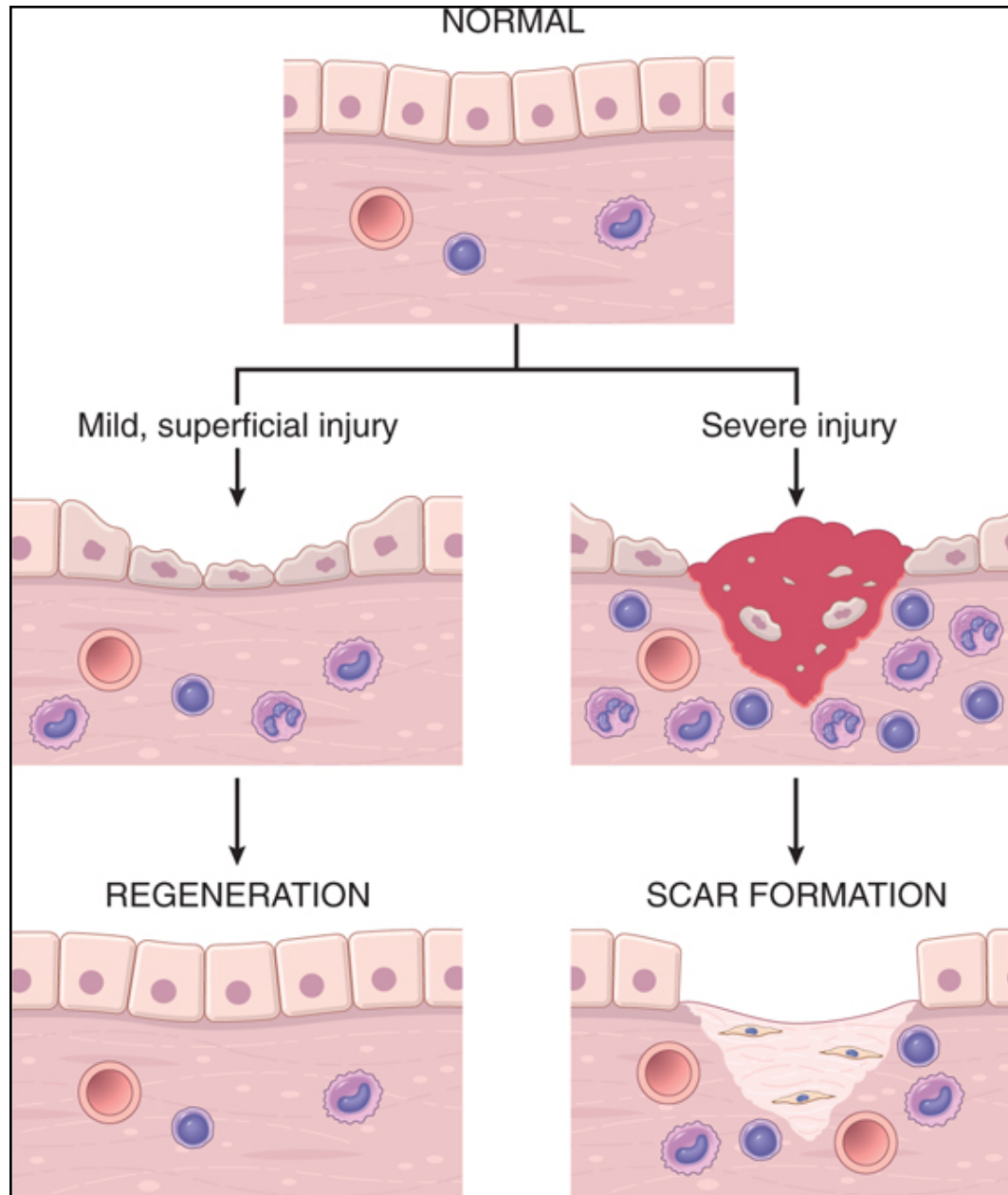
Goal of the repair process

- To restore the tissue to its original state after inflammatory reaction

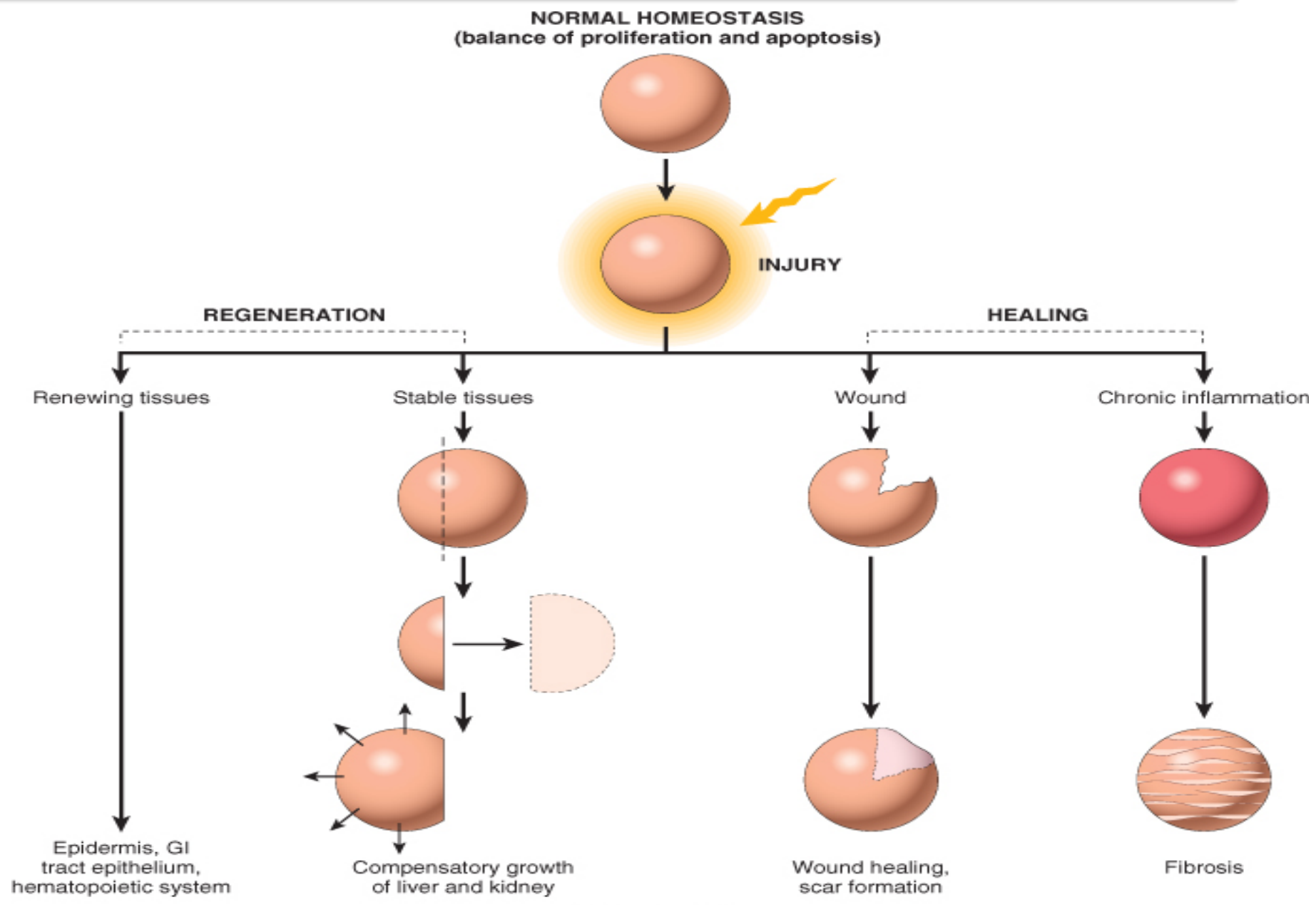
Some tissues can be completely reconstituted after injury, such as the repair of bone after a fracture or the regeneration of the surface epithelium in a cutaneous wound.

For tissues that are incapable of regeneration, repair is accomplished by connective tissue deposition, producing a scar.

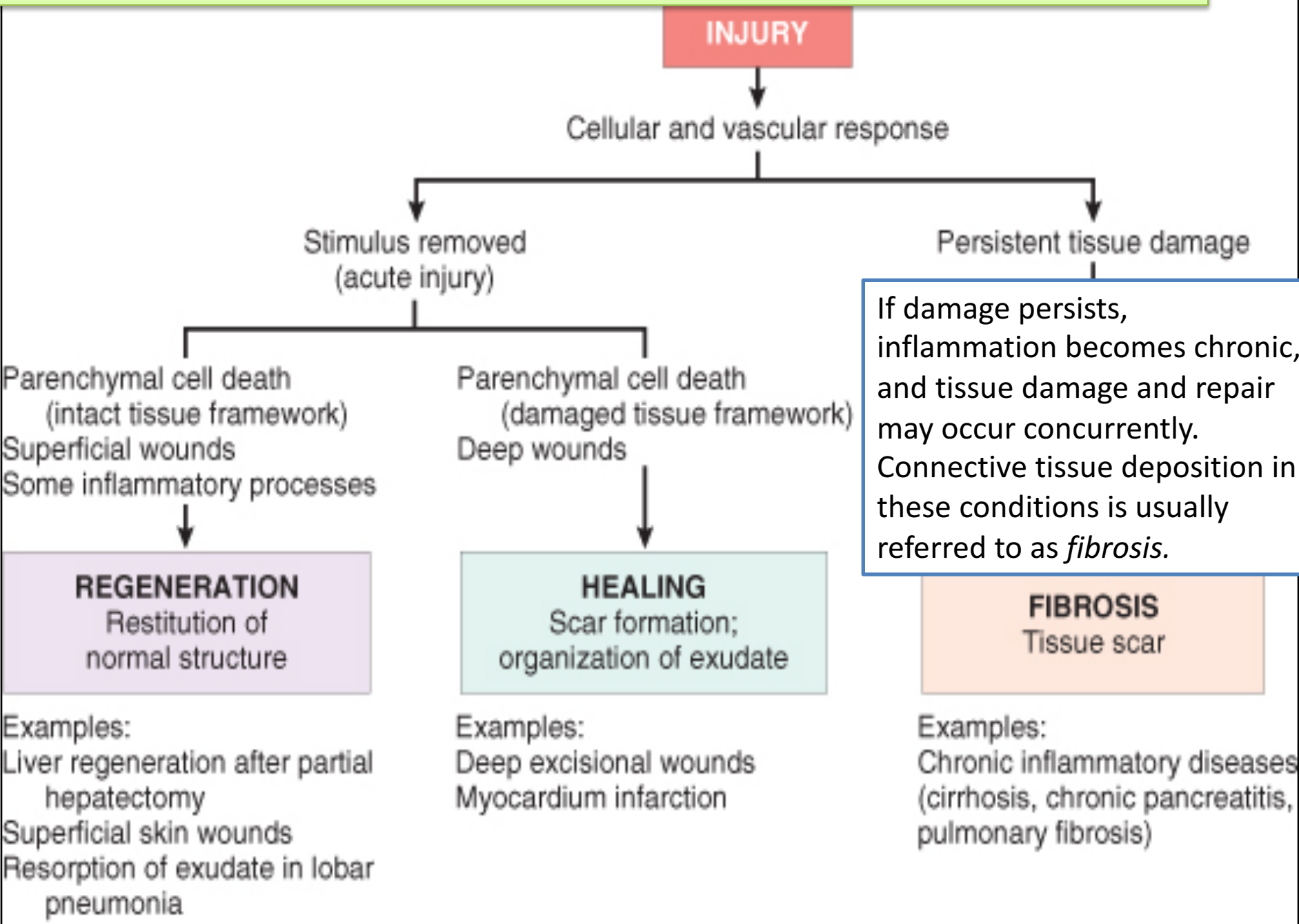
1. Describe the differences between regeneration, healing and fibrosis.



1. Describe the differences between regeneration healing and fibrosis.



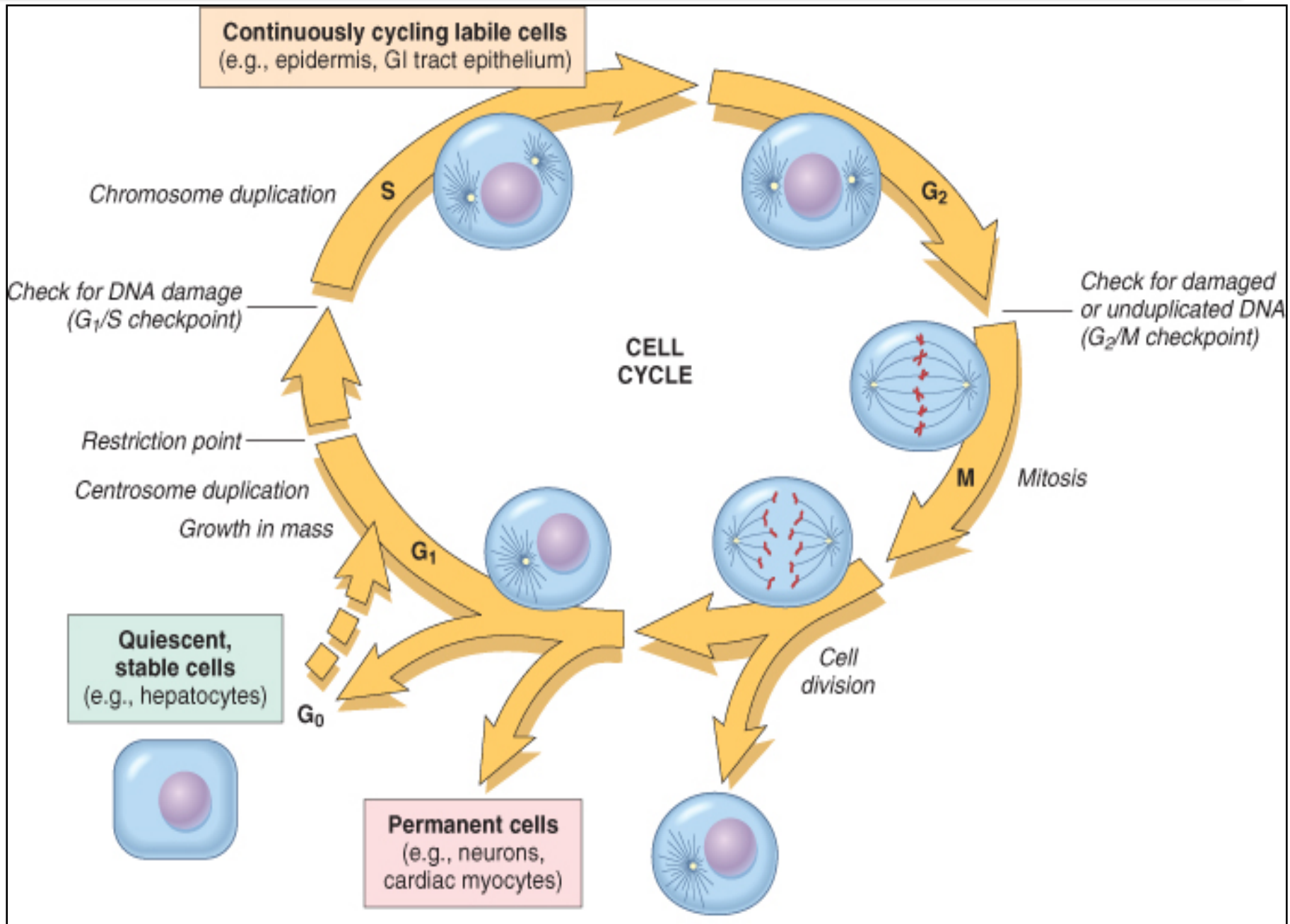
1. Describe the differences between regeneration healing and fibrosis.



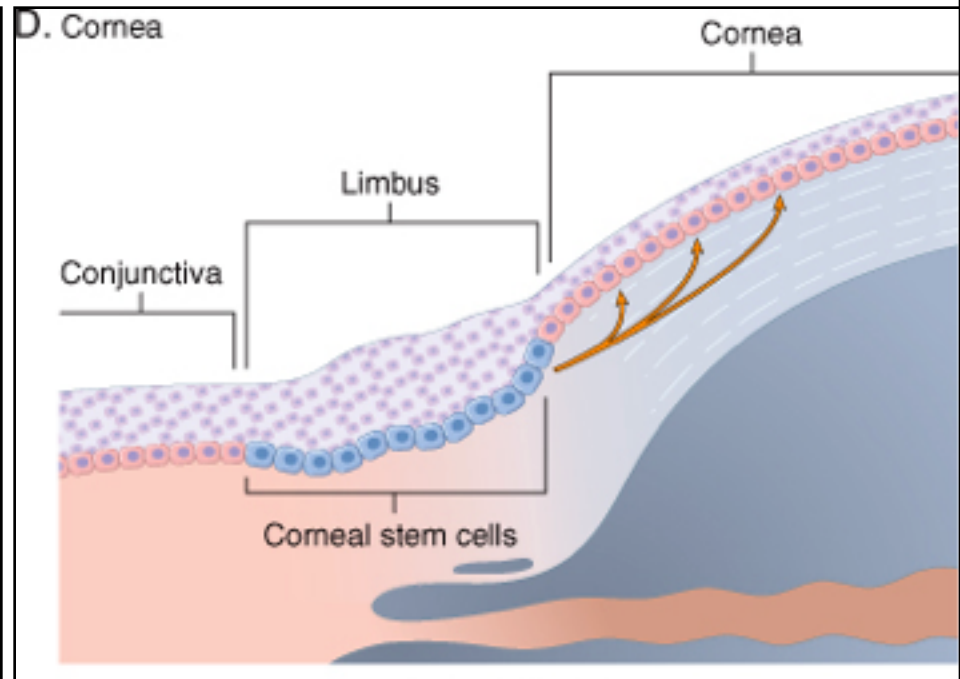
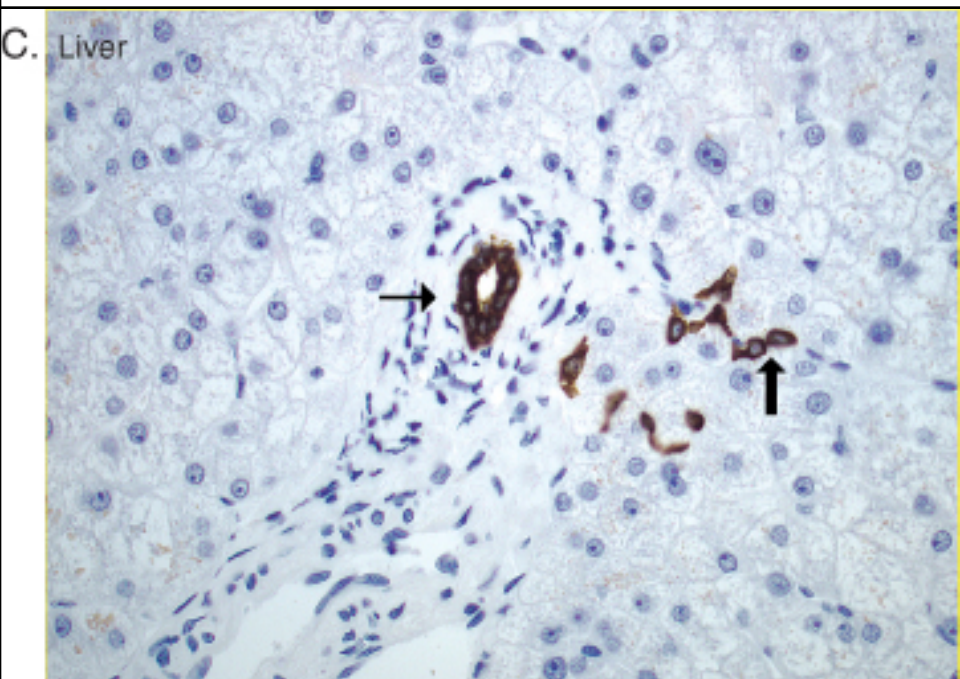
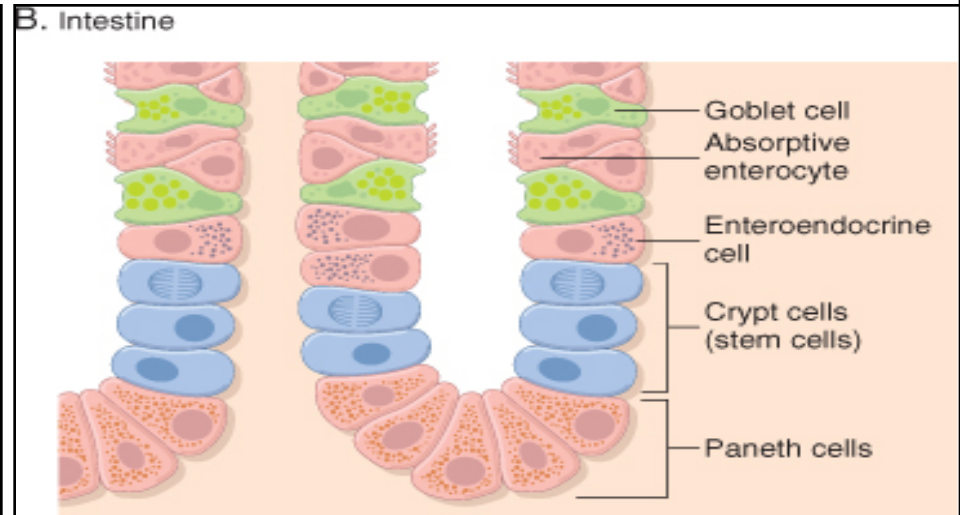
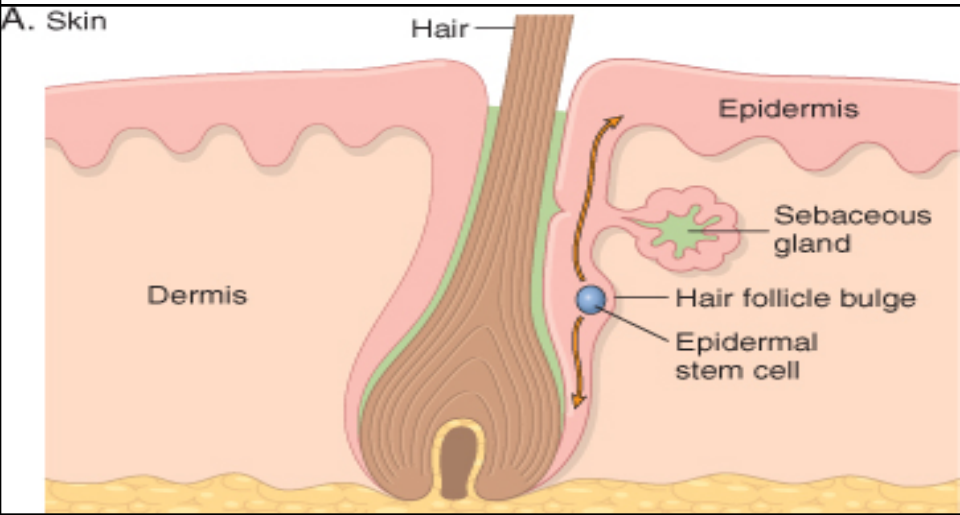
Repair by tissue regeneration or healing depend on cell type.

- **Labile cells:** continue to proliferate throughout life : squamous, columnar, transitional epithelia; hematopoietic and lymphoid tissues
- **Stable cells:** retain the capacity of proliferation but they don't replicate normally: parenchymal cells of all glandular organs & mesenchymal cells
- **Permanent cells:** cannot reproduce themselves after birth: neurons, cardiac muscle cells

2. The differences between the various cell in regenerative abilities types

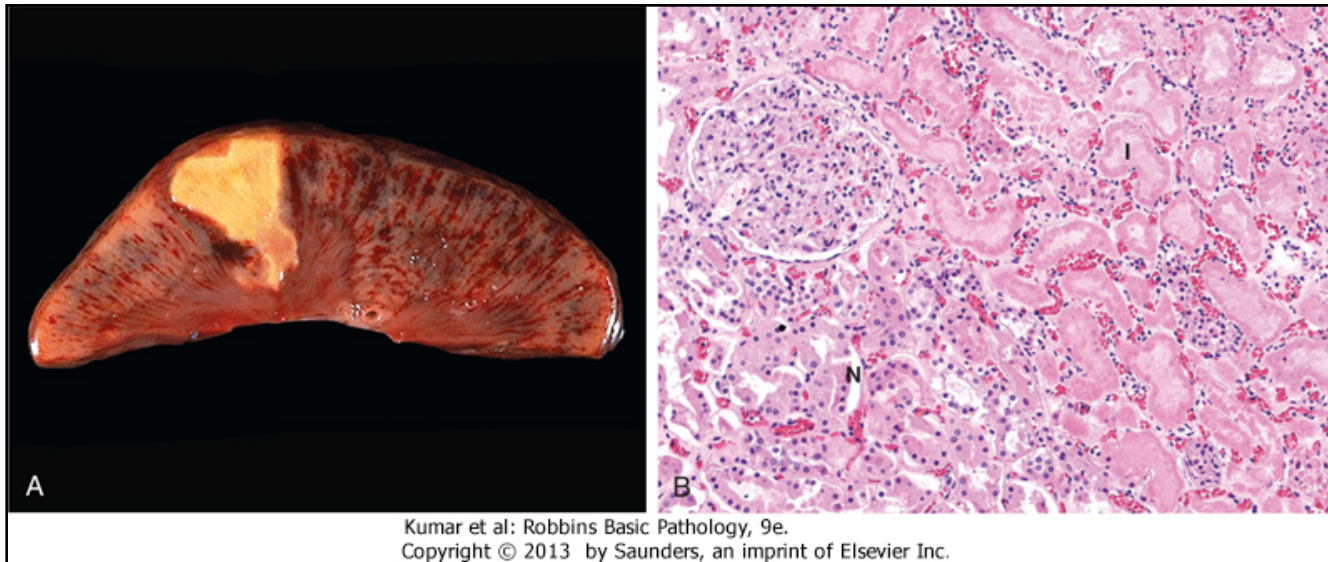


2. Examples of labile cells: STEM CELLS



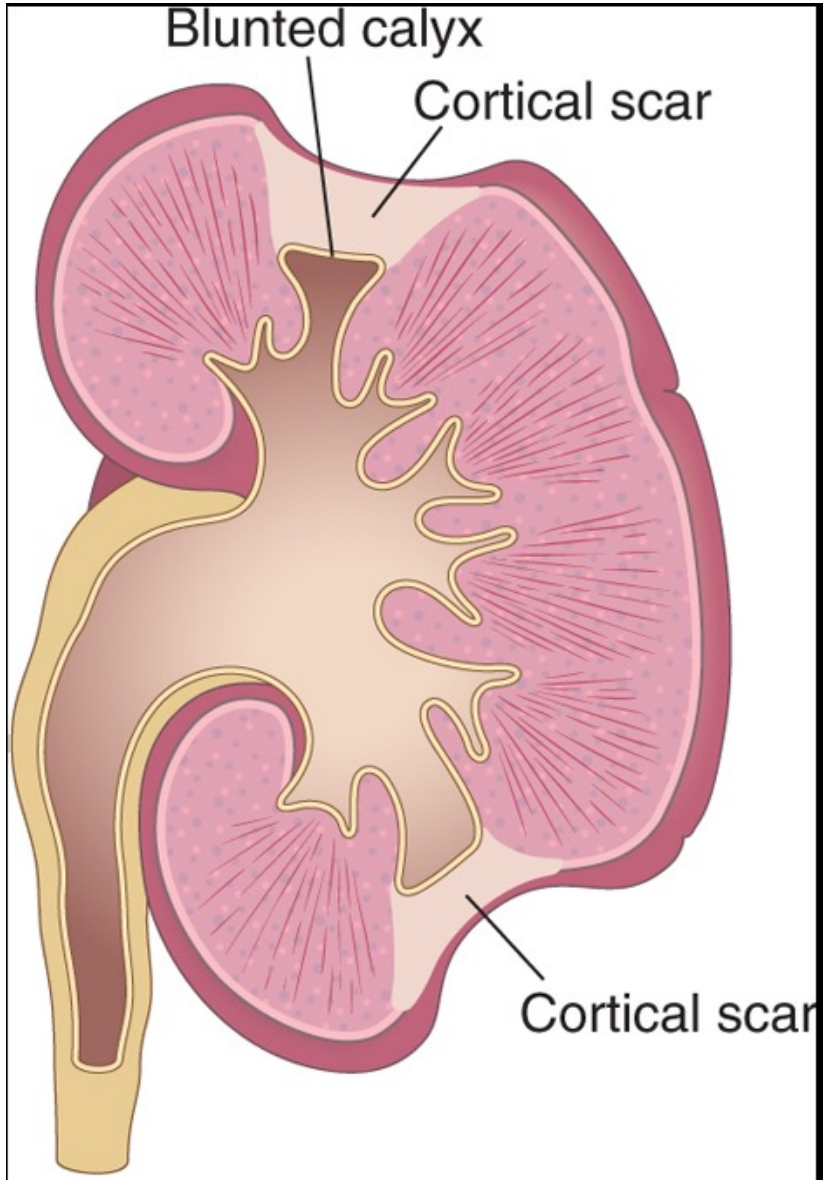
Healing

- *Healing* is usually a tissue response
 - (1) to a wound (commonly in the skin)
 - (2) to inflammatory processes in internal organs
 - (3) to cell necrosis in organs incapable of regeneration



3. Know the mechanism of repair and formation of granulation tissue.

Healing occur as a response to inflammatory processes in internal organs



Mechanism of repair

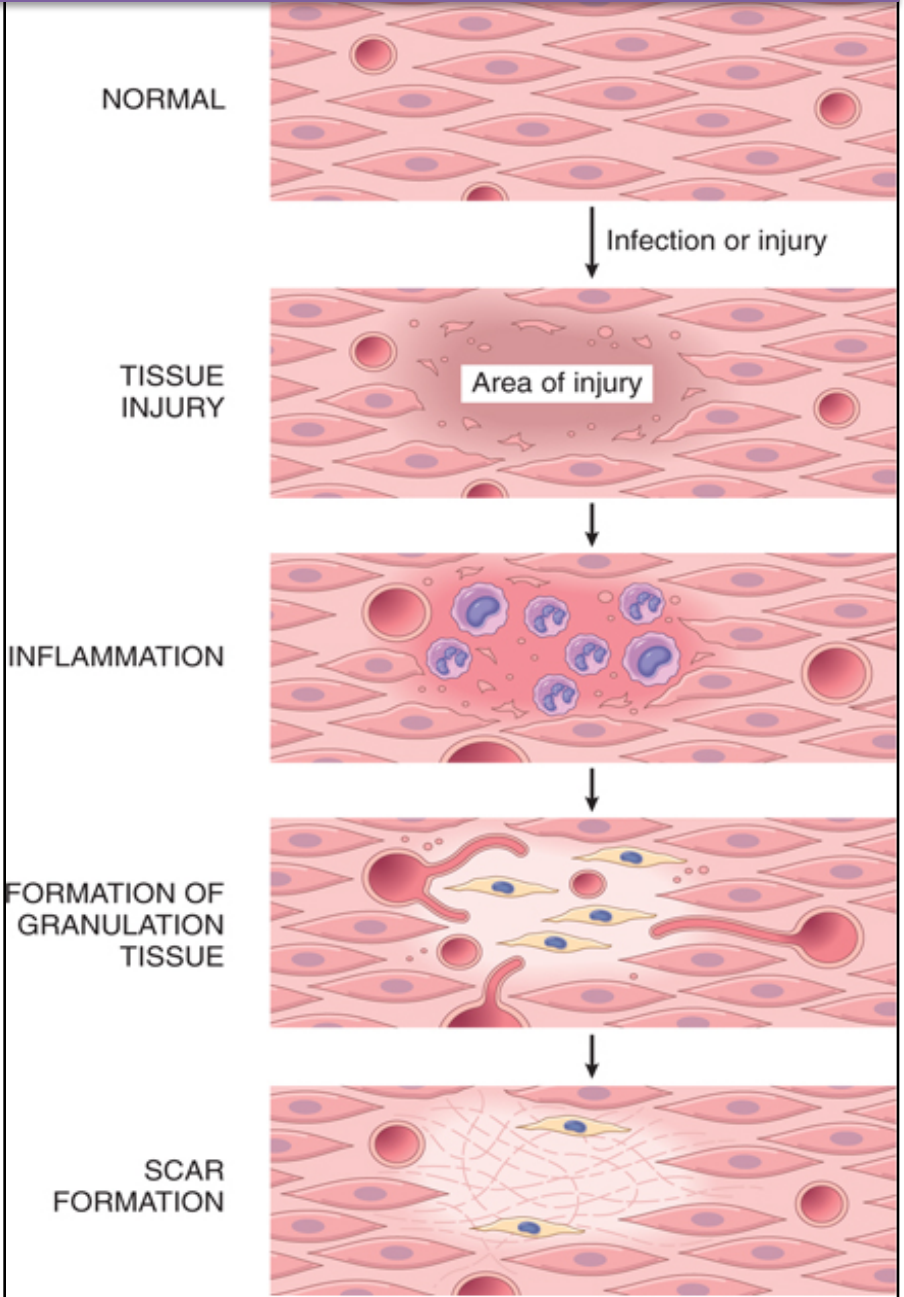
- Repair begins early in inflammation.
- At site of inflammation, fibroblasts and vascular endothelial cells begin proliferating to form a specialized type of tissue (hallmark of healing) called:

granulation tissue

- The process is called organization

3. Know the mechanism of repair and formation of granulation tissue.

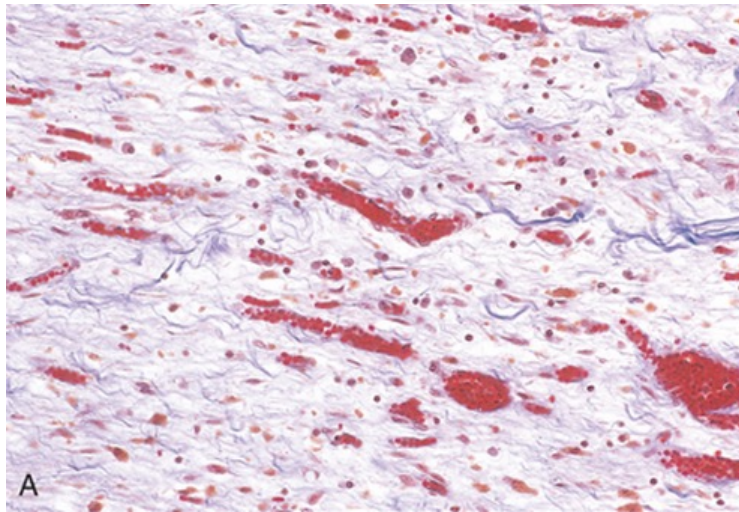
Granulation tissue



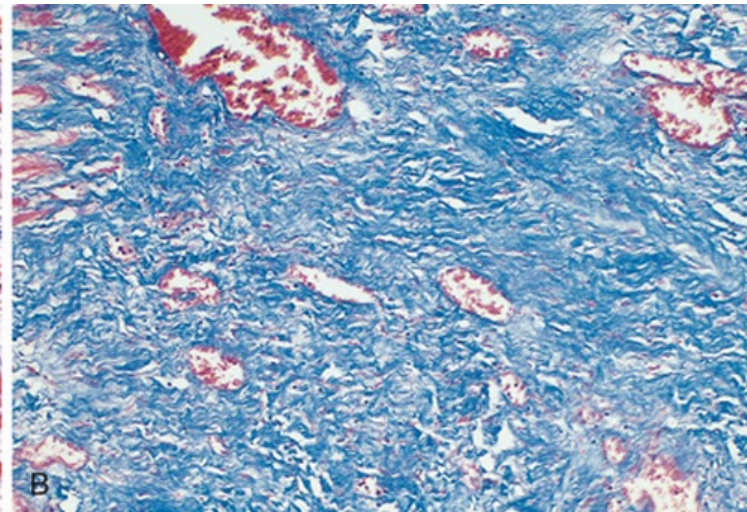
3. Know the mechanism of repair and formation of granulation tissue.

Granulation tissue

Early



Late

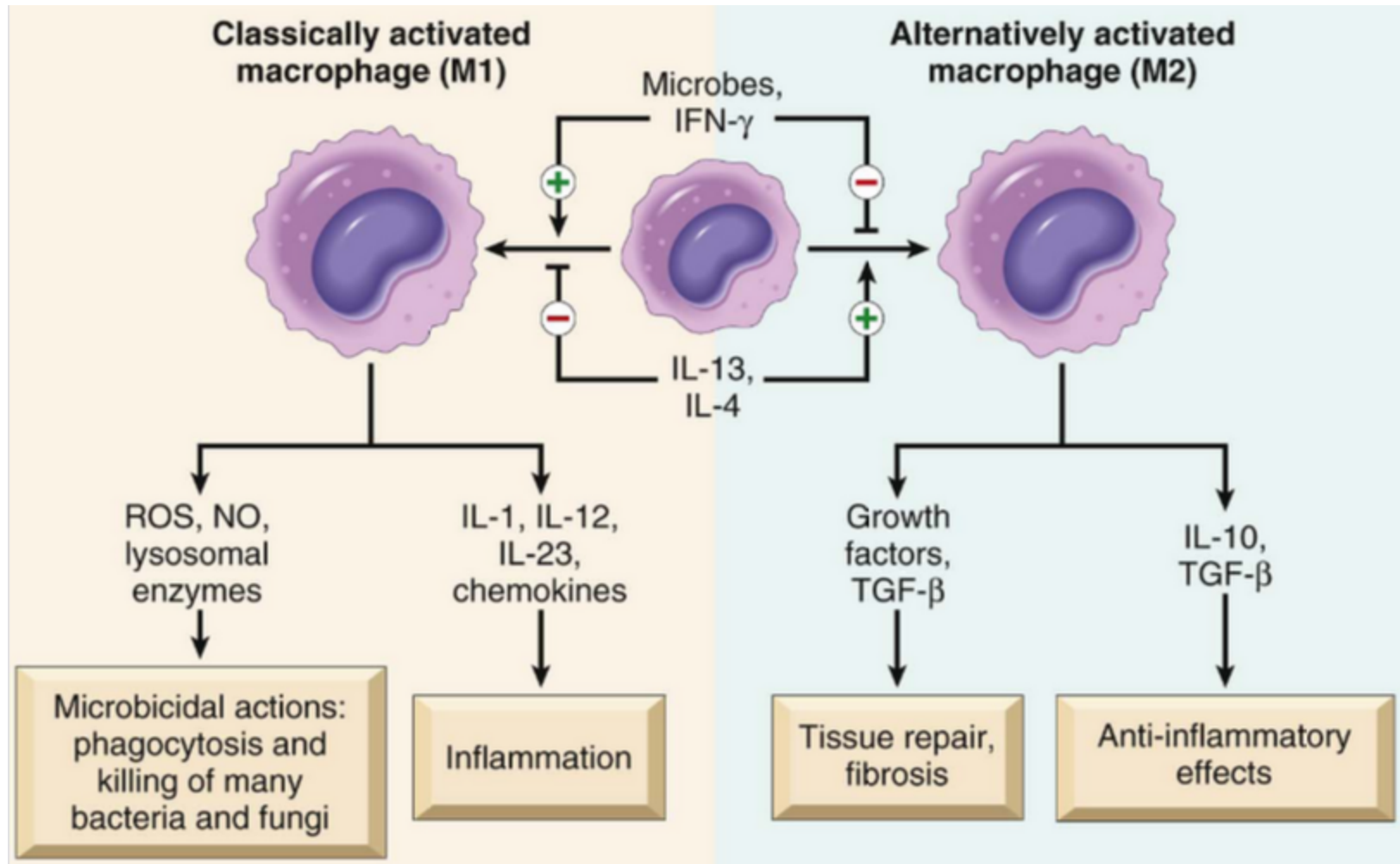


Repair by connective tissue (granulation tissue)

- It consists of:
 1. fibroblasts surrounded by abundant extracellular matrix
 2. newly formed blood vessels (sprouting of new capillaries)
 3. scattered macrophages and some other inflammatory cells.

3. Know the mechanism of repair and formation of granulation tissue.

Role of macrophages in wound healing



What is the role of macrophages in wound healing?

- Cleanup of debris, fibrin, and other foreign material at the site of repair.
- Macrophages recruit other cells: fibroblasts and angioblasts
- Stimulation of matrix production , interleukins that stimulate fibroblasts and angioblasts to produce the extracellular matrix.
- Remodeling of the scar. They secrete collagenases
- Secretion of transforming growth factor beta (*TGF-B*)
- TGF-beta has anti inflammatory action and plays a role in tissue repair and fibrosis

Fibroblast Migration and Proliferation

- *Migration* of fibroblasts to the site of injury and their subsequent *proliferation* are triggered by multiple growth factors, including mainly TGF- β and others e.g. PDGF, EGF, FGF, and the cytokines IL-1 and TNF
- This lead to:
 1. *increased synthesis of collagen and fibronectin*
 2. *decreased degradation of extracellular matrix (ECM) by metalloproteinases*

ECM Deposition and Scar Formation

- As repair continues, the number of proliferating endothelial cells and fibroblasts decreases.
- *Net collagen accumulation, however, depends not only on increased collagen synthesis but also on decreased degradation.*

Granulation tissue morphology

As early as 24 hr. after injury, fibroblasts and vascular endothelial cells begin proliferating to form (by 3-5 days) granulation tissue - pink soft granular appearance on the surface of the wound.

New granulation tissue is often edematous.

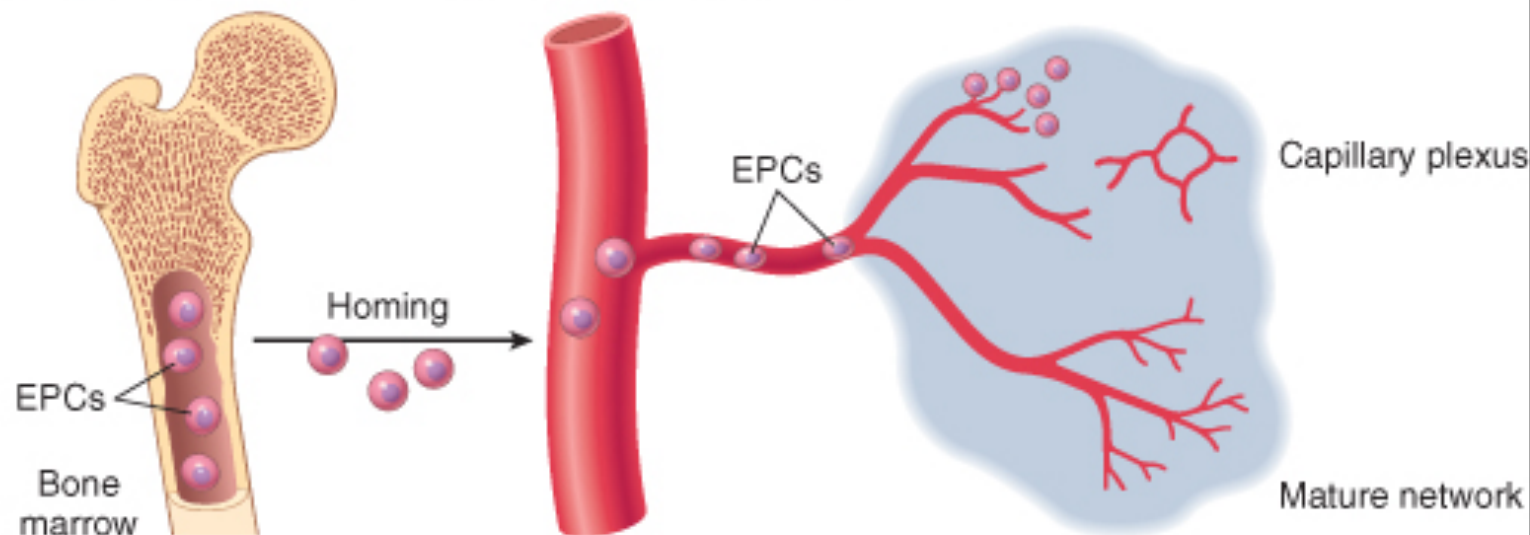
- **Histologically** : granulation tissue is composed of :
 - proliferation of new small blood vessels and
 - proliferation of fibroblasts
 - macrophags

3. Know the mechanism of repair and formation of granulation tissue.

Angiogenesis

Sprouting of new capillaries

A. Angiogenesis by mobilization of EPCs from the bone marrow



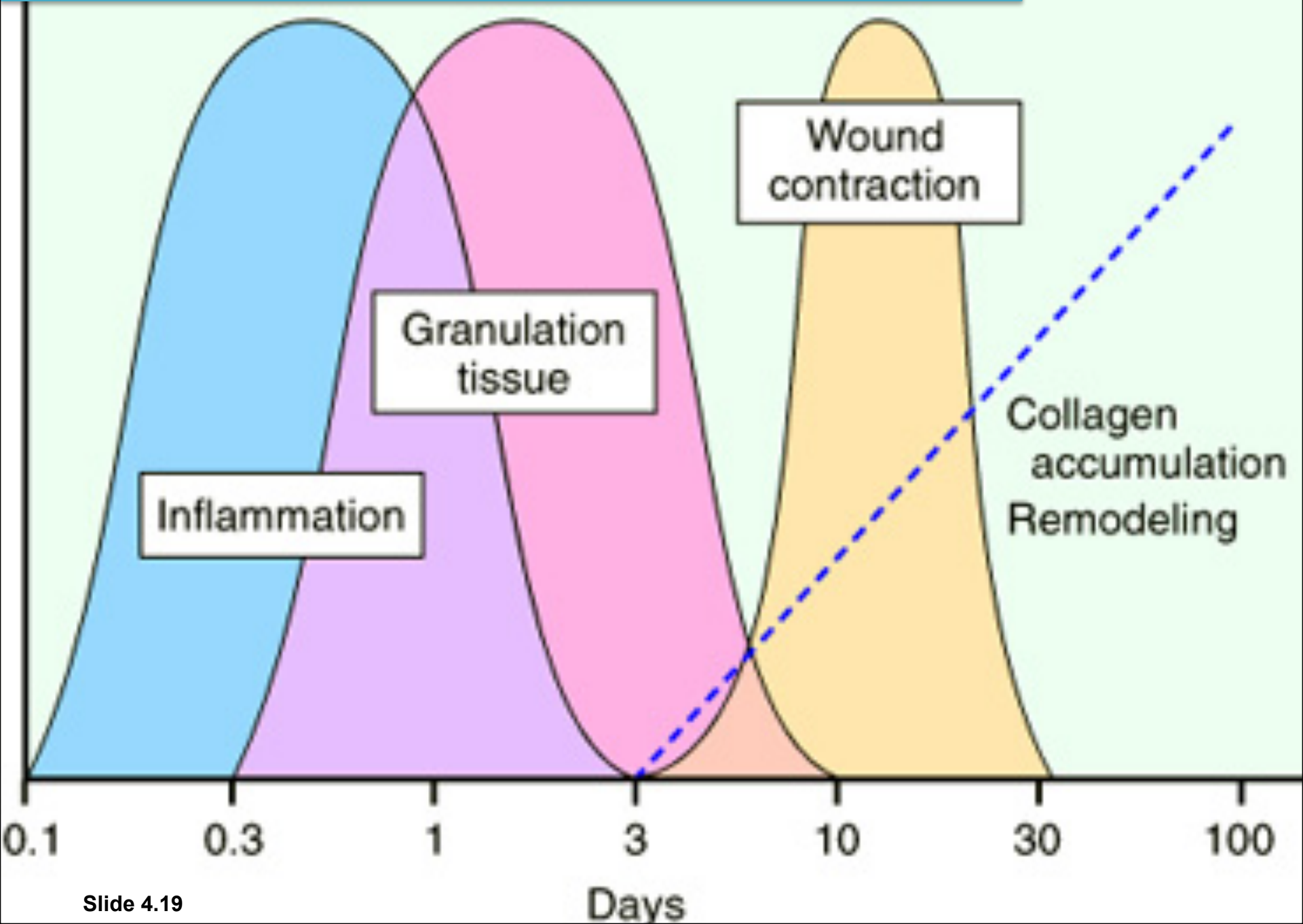
Angiogenesis from Endothelial Precursor Cells

Angiogenesis plays a major role in granulation tissue formation during wound healing

SCAR FORMATION

- Further healing: increased collagen, decreased active fibroblasts and new vessels (thrombosis and degeneration)
- At the end: scar (inactive fibroblasts, dense collagen, fragments of elastic tissue, extracellular matrix, few vessels).

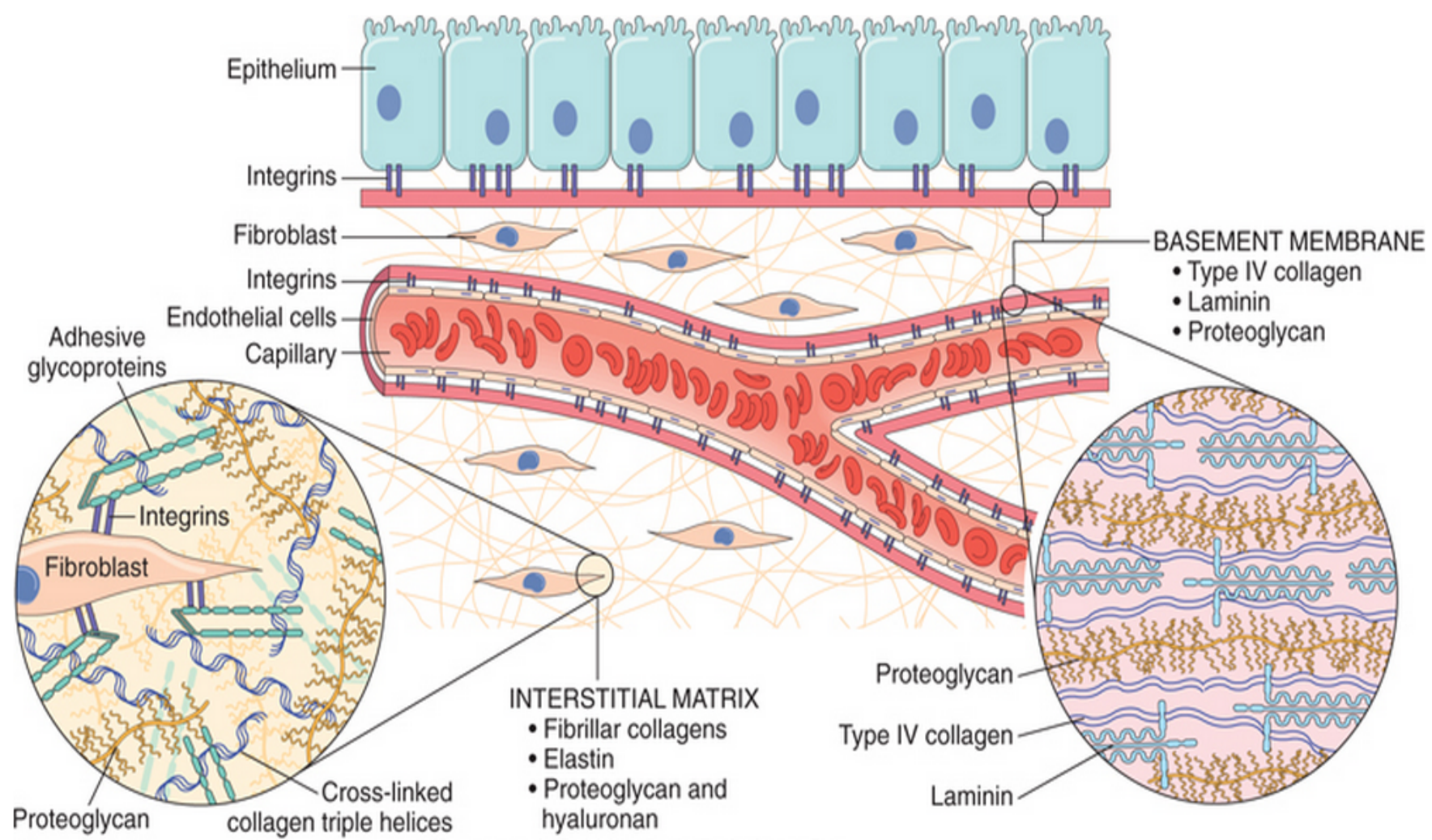
4. List the three main phases of cutaneous wound healing.



Functions of the Extracellular Matrix

- The ECM is much more than a space filler around cells. Its various functions:
 - *Mechanical support*
 - *Control of cell proliferation*
 - *Scaffolding for tissue renewal*
 - *Establishment of tissue microenvironments.*

4. List the three main phases of cutaneous wound healing.



Cutaneous Wound healing

Cutaneous Wound healing

1. Primary union

(healing by 1st intention)

- clean surgical incision
- no significant bacterial contamination
- minimal loss of tissue
- clot, scab formation

2. Secondary union

(healing by 2nd intention)

- more extensive loss of cells and tissue:
 - infarction
 - inflammatory ulceration
 - abscess formation
- surface wound with large defect
- large tissue defect that must be filled

Primary union (healing by first intention)

24 hr.: hematoma & neutrophils, mitotic activity of basal layer, thin epithelial layer

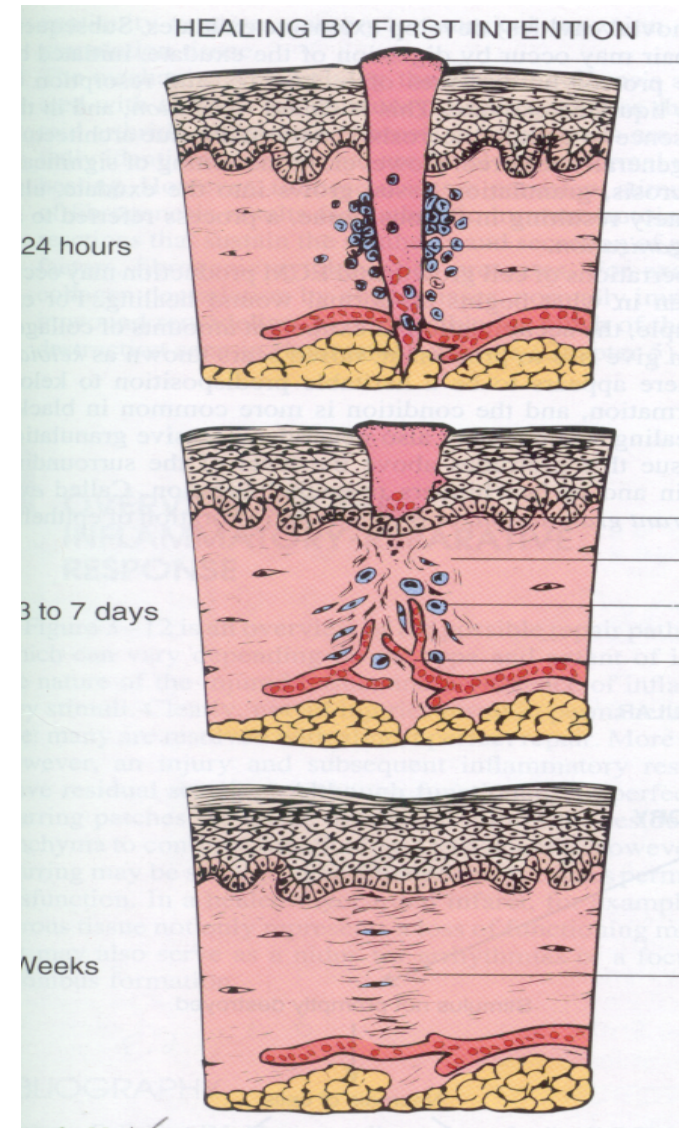
Hageman factor (factor 12) will activate both the coagulation sequence and the kinin system as an initial response to this injury

day 3: macrophages, granulation tissue

day 5: collagen bridges the incision, epidermis thickens

2nd week: continued collagen and fibroblasts, blanching

End of 1st month: scar (cellular connective tissue, intact epidermis, lost appendages)



Primary union (healing by first intention)

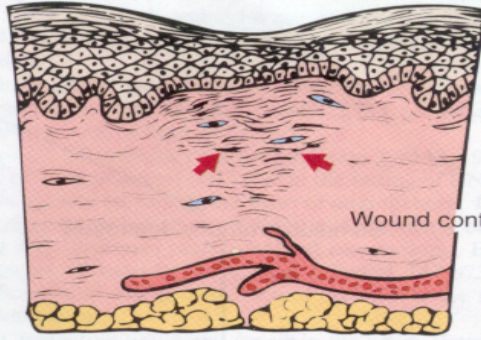
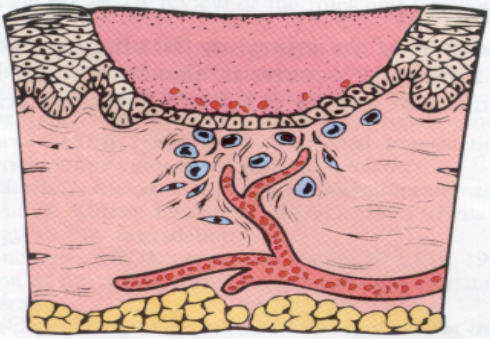
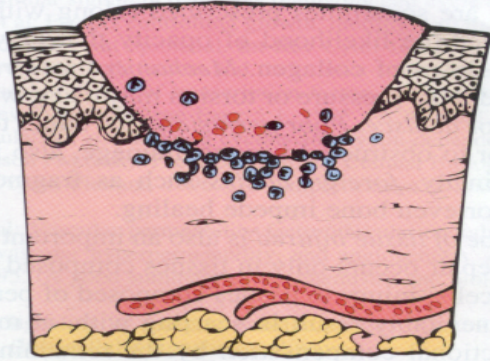
- Later, collagen type III is slowly replaced by collagen type I and the wound acquires tensile strength.
- By the end of third month, the tissue has approximately 80% of its original strength.

Cutaneous Wound healing

Secondary union (healing by 2nd intention)

It occur in large, gaping wounds, as well those that are infected or contain foreign material

HEALING BY SECOND INTENTION



Difference between primary intention and secondary intention

- The basic process of healing is the same in all wounds. In contrast to healing by primary intention, wounds healing by secondary intention
 - Require more time to close because the edges are far apart
 - Show a more prominent inflammatory reaction in and around the wound
 - Contain more copious granulation tissue inside the tissue defect
 - wound contraction (5 to 10%), caused by myofibroblasts

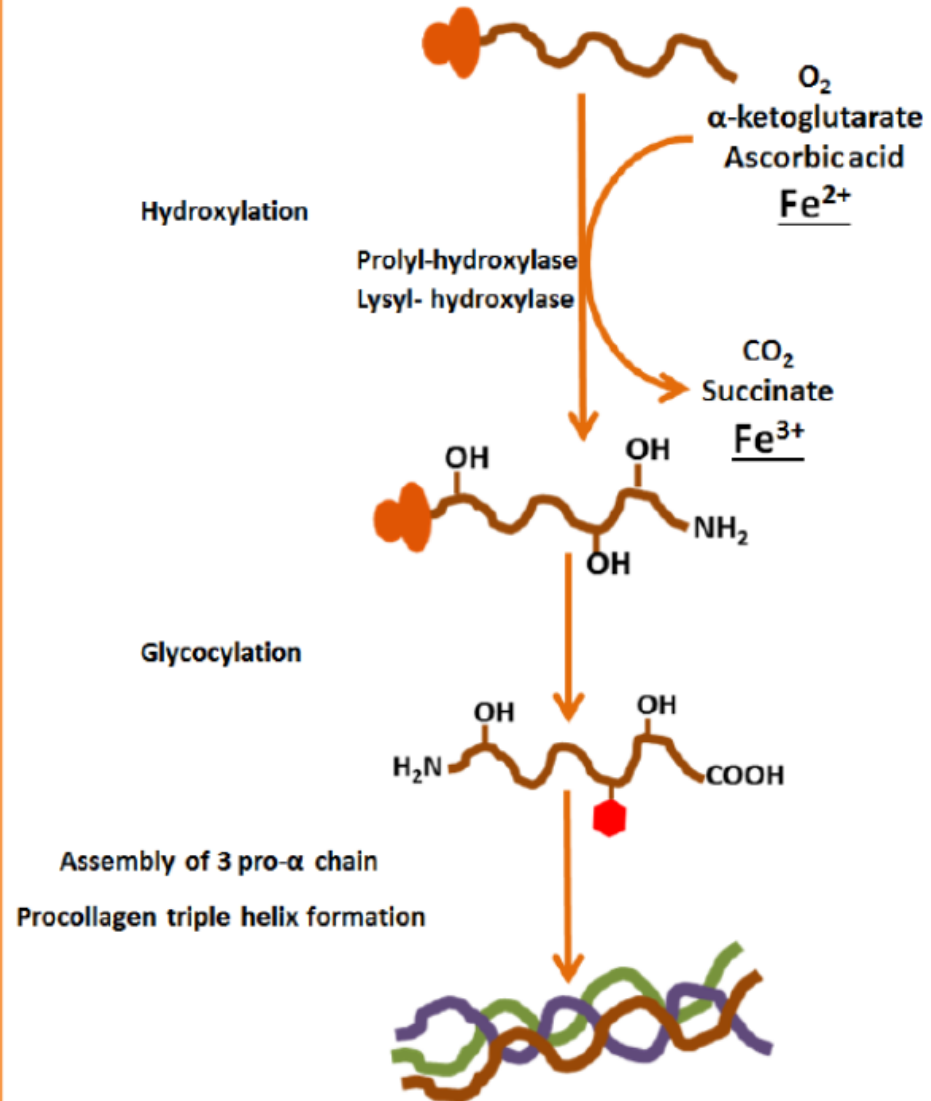
Delayed wound healing

What is the most common cause of delayed wound healing?

- **Infection** the most important cause of delay in healing; it prolongs inflammation and potentially increases the local tissue injury.
- **Foreign bodies in the wound**
- **Mechanical factors** Suture help healing of wound
- **Nutritional deficiencies** protein deficiency and vitamin C deficiency inhibit collagen synthesis and retard healing. Zinc and copper deficiency
- **Poor perfusion** due either to arteriosclerosis and diabetes or to obstructed venous drainage
- **Excess corticosteroid**

Collagen synthesis

Proline
hydroxylation
by vitamin C.



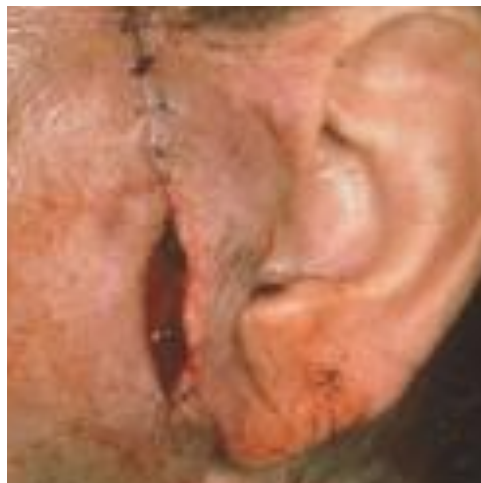Excess corticosteroid

- have well-documented anti-inflammatory effects, and their administration may result in weakness of the scar
- however, the anti-inflammatory effects of glucocorticoids are sometime desirable. For example, in corneal infections

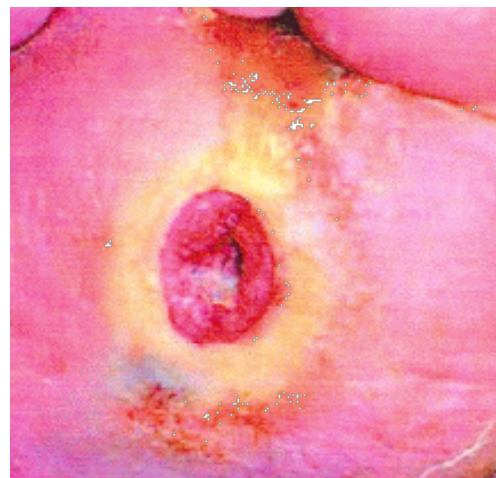COMPLICATIONS IN CUTANEOUS WOUND HEALING

- Complications in wound healing can arise from abnormalities in any of the basic components of the repair process. These aberrations can be grouped into three general categories:
 - (1) *deficient scar formation*
 - (2) *excessive formation of the repair components and connective tissue*
 - (3) *formation of contractures (myofibrblast).*

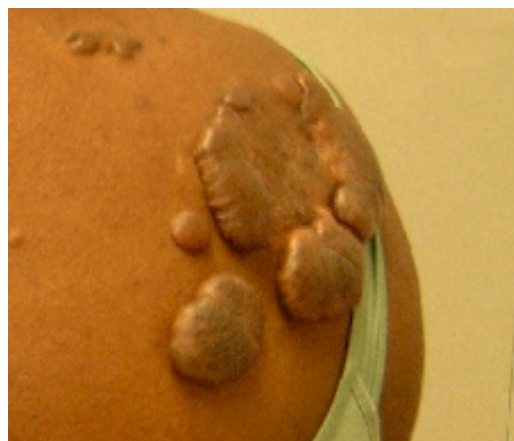6. Complications of wound healing



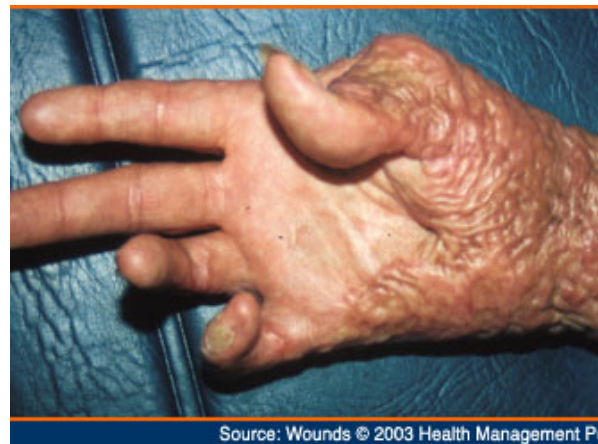Wound dehiscence



Wound ulceration



Keloid

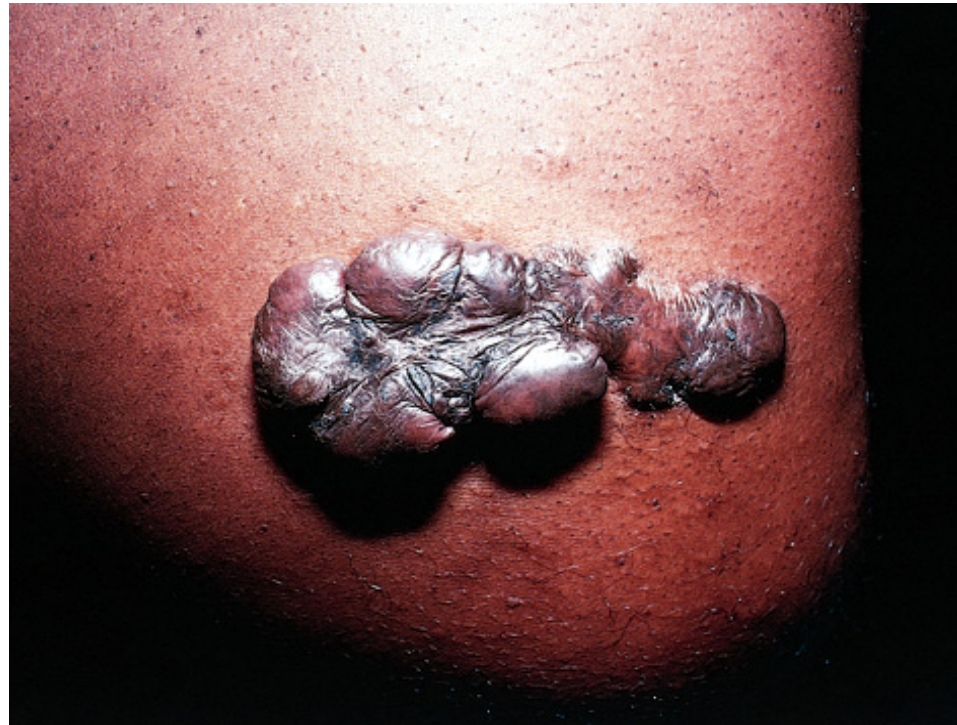

Source: Wounds © 2003 Health Management Publications

Contracture

What is a keloid?

- Keloids are excessive scars composed of irregularly deposited thick hyalinized collagen bands. They may appear as bulging masses.

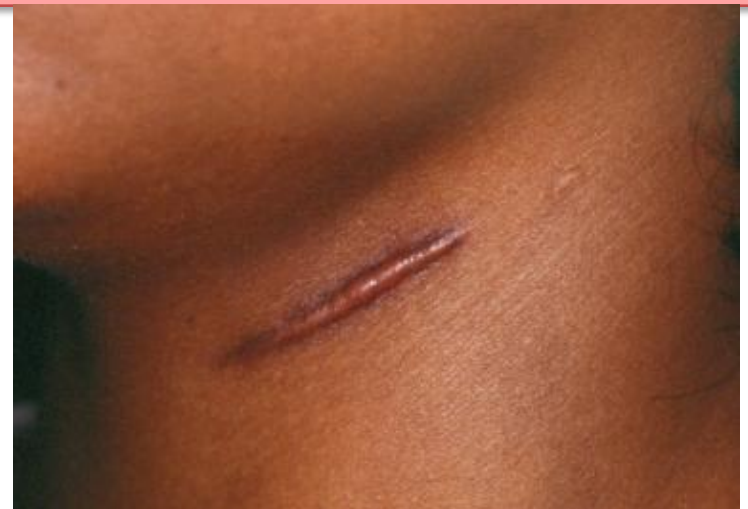
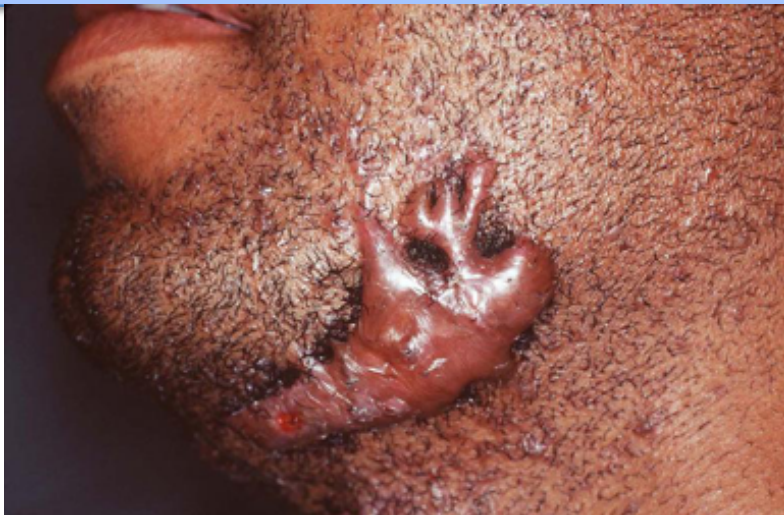
6. Complications of wound healing

What is the difference between keloid and hypertrophic scar?

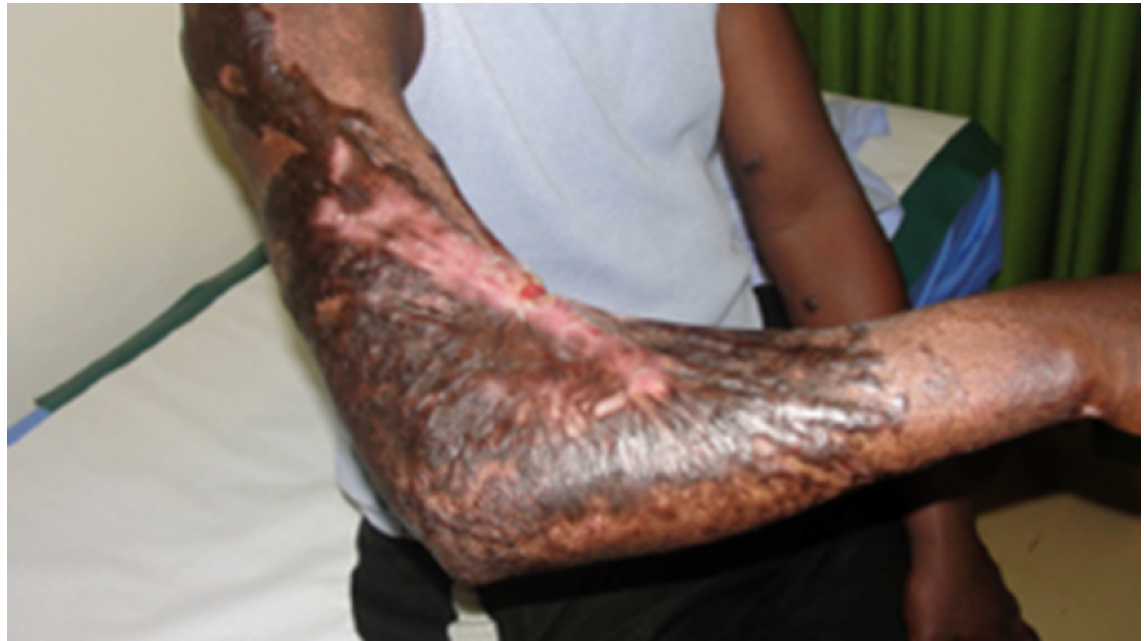- Keloids are the result of an overgrowth of dense fibrous tissue that usually develops after healing of a skin injury. The tissue extends beyond the borders of the original wound, does not usually regress spontaneously, and tends to recur after excision.

- hypertrophic scars are characterized by erythematous, pruritic, raised fibrous lesions that typically do not expand beyond the boundaries of the initial injury and may undergo partial spontaneous resolution. Hypertrophic scars are common after thermal injuries.



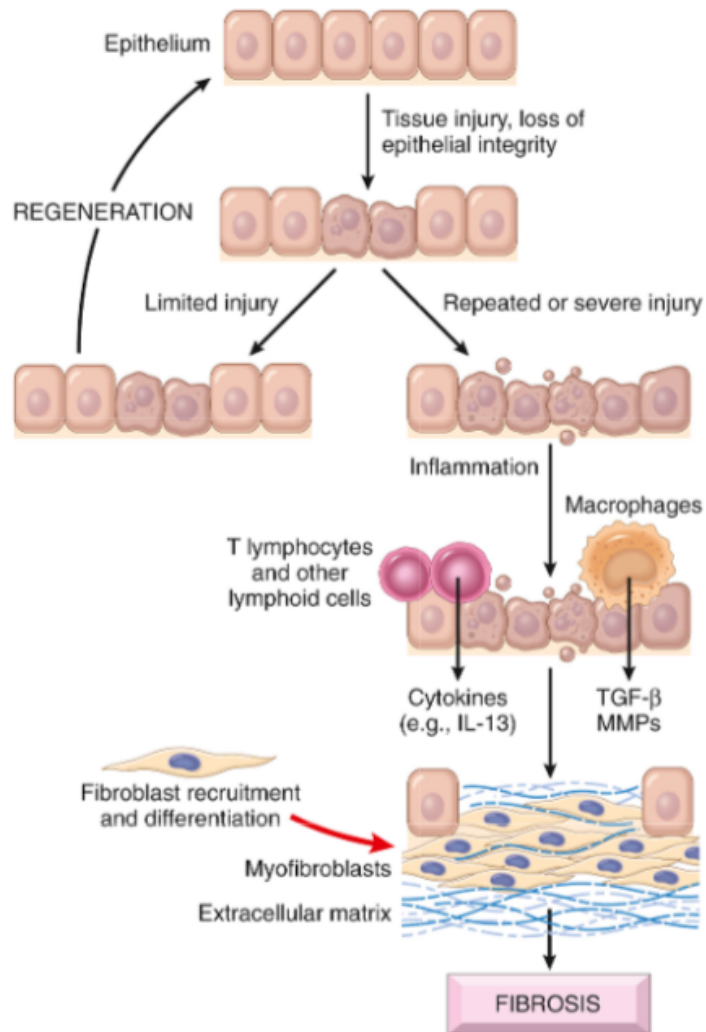
Formation of contractures

- common on the palms, the soles, and the anterior aspect of the thorax.
- Contractures are commonly seen after serious burns
- It can compromise the movement of joints.
- It is caused by myofibroblasts



Fibrosis in Parenchymal Organs

- Fibrosis is a pathologic process induced by persistent injurious stimuli such as chronic infections and immunologic reactions, and is typically associated with loss of tissue
- e.g. liver cirrhosis after chronic hepatitis or pancreatic insufficiency after chronic pancreatitis.



TAKE HOME MESSAGES:

- The various cell types (ie, labile, stable, and permanent cells) affect the outcome of healing.
- Three main phases of cutaneous wound healing:
 - (1) inflammation, (2) formation of granulation tissue, and (3) ECM deposition and remodeling
- Healing by primary intention occur in surgical clean wound and healing by secondary intention occur when excessive tissue damage is present.
- Several factors are associated with delayed wound healing.
- Complication of wound healing include failure of healing, contracture and excessive scar formation.