

NEOPLASIA – PRACTICAL SESSION 2

Dr. Maria A. Arafah

Assistant Professor – Department of Pathology

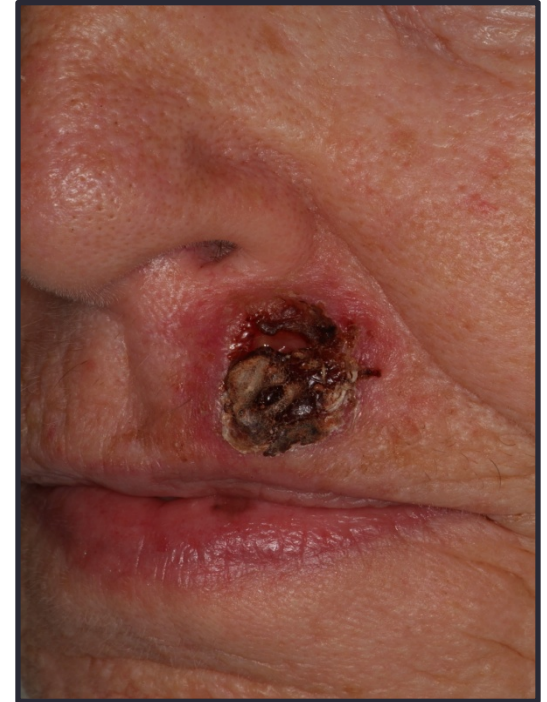
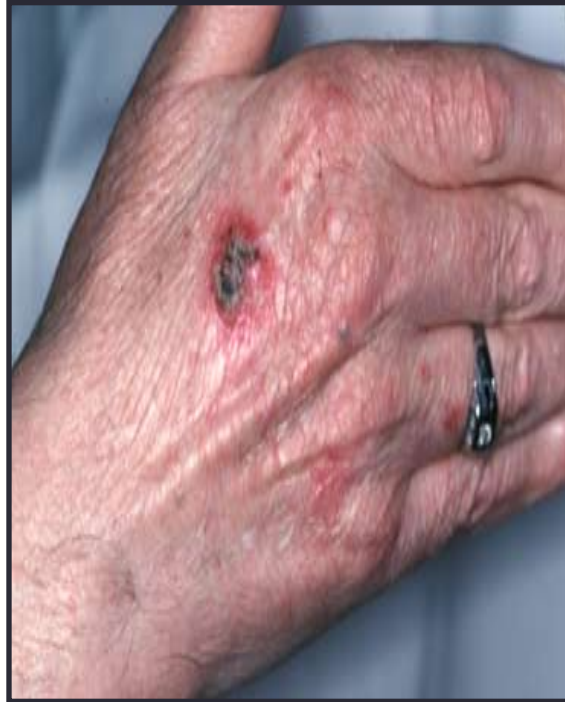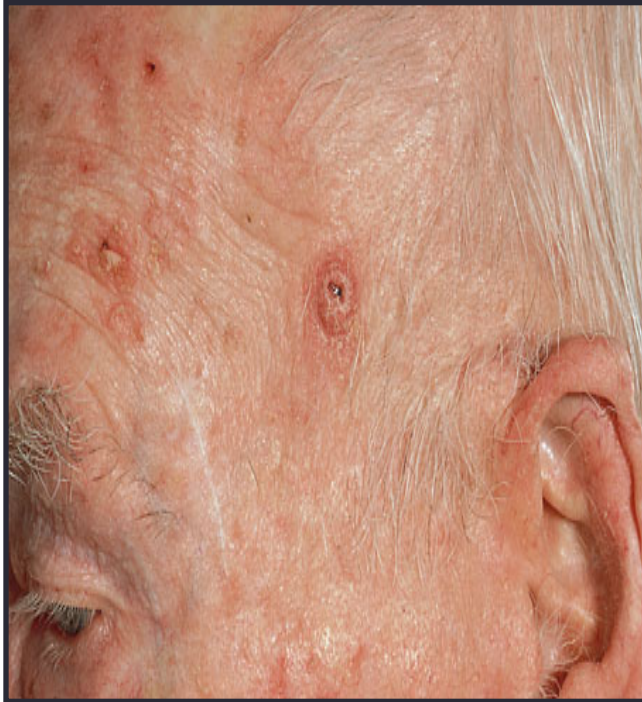<http://fac.ksu.edu.sa/mariaarafah/courses>

Contents

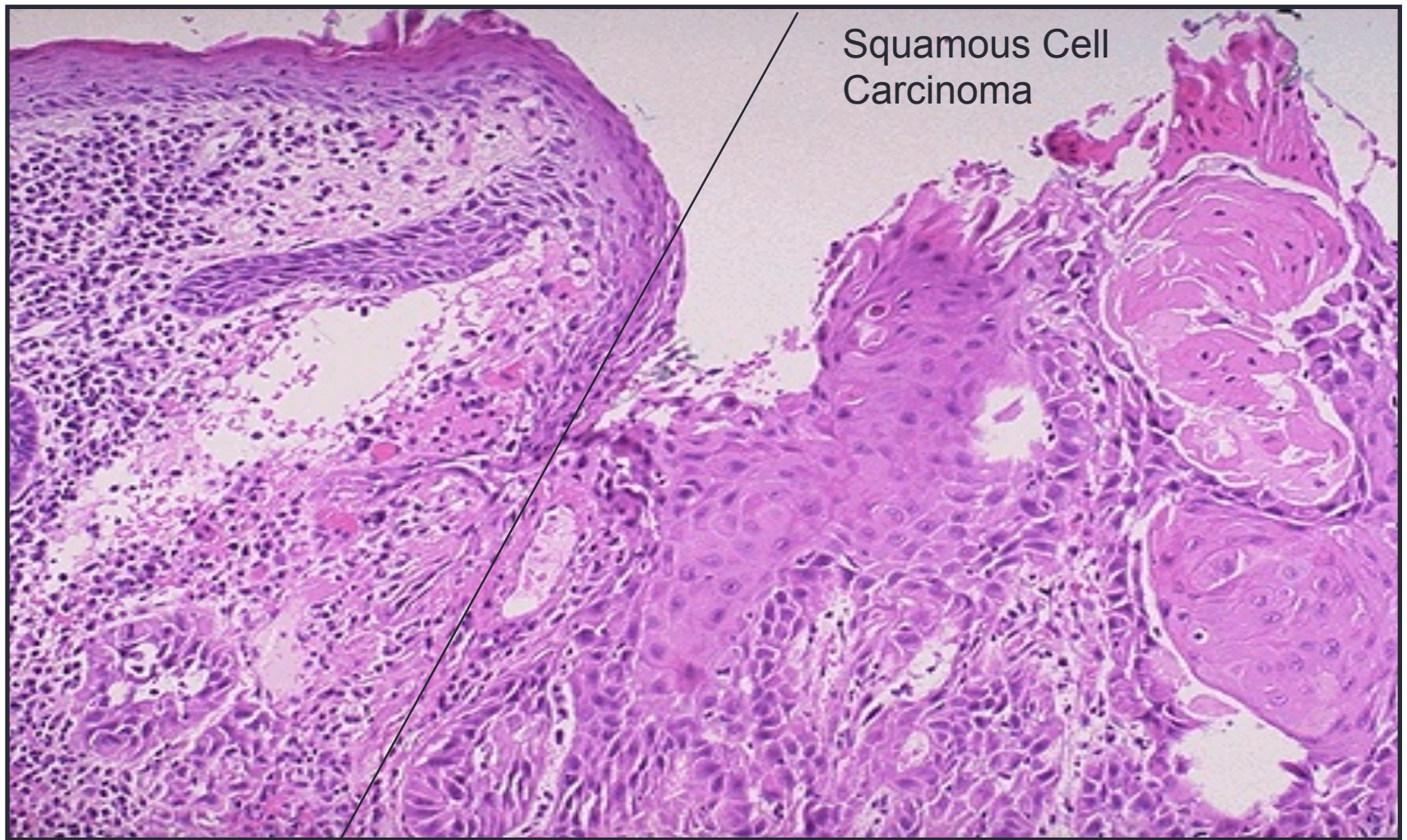
- Squamous cell carcinoma of the skin
- Adenocarcinoma of the large intestine
- Leiomyosarcoma

CASE 1

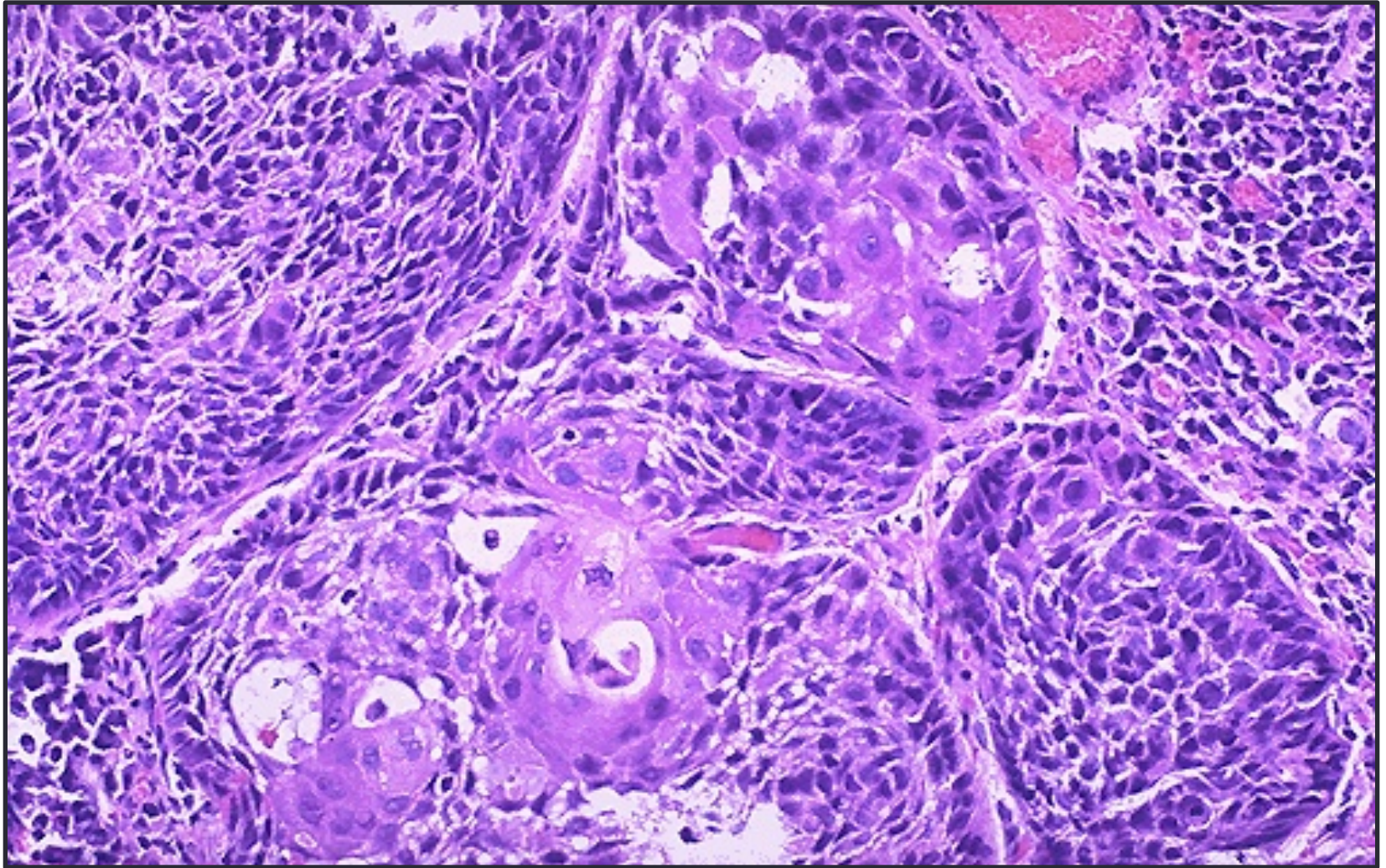
Squamous cell carcinoma of the skin



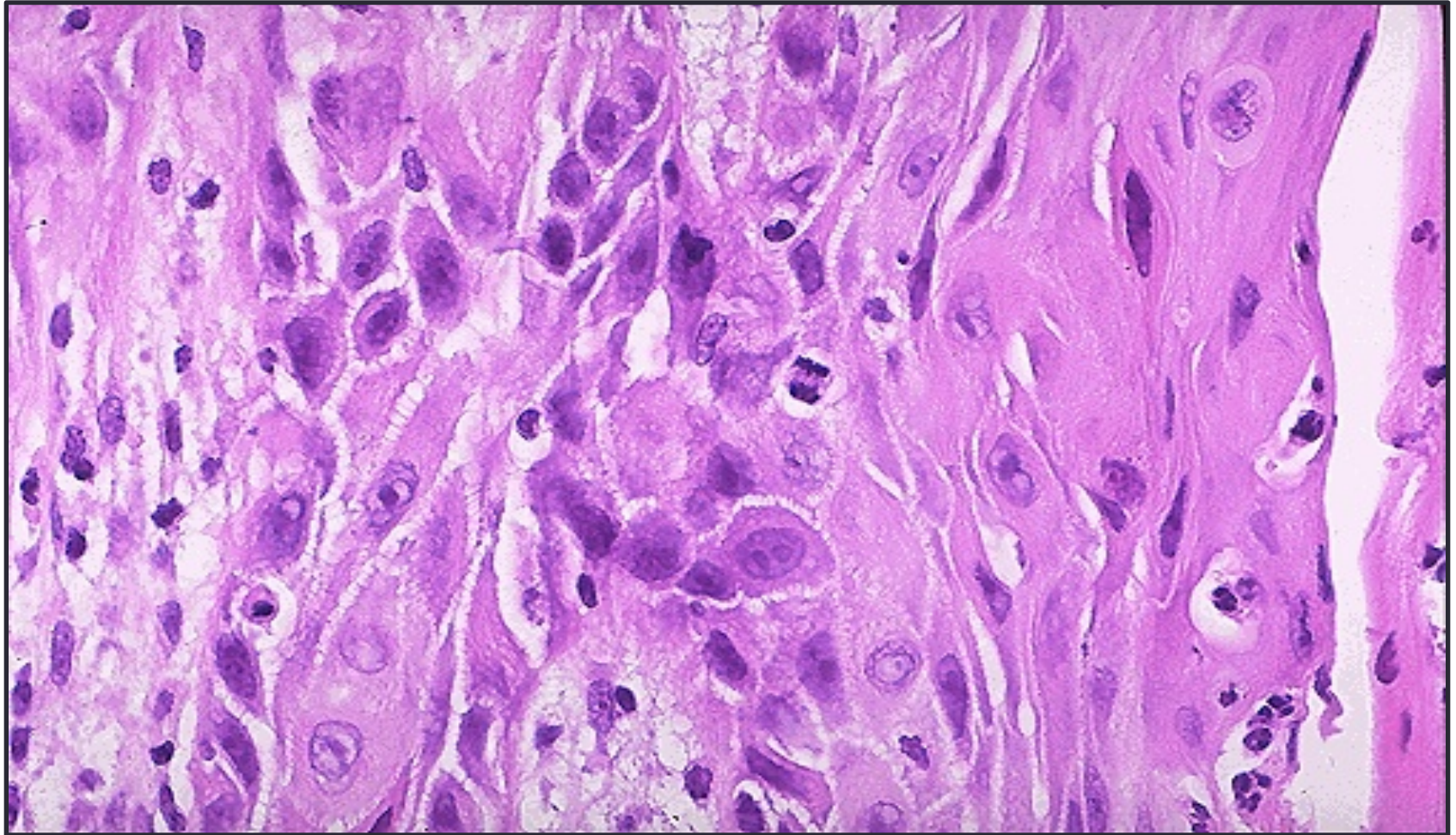
Squamous cell carcinoma (SCC) – gorrss: It is the second most common cancer of the skin. A sore that does not heal or any change in an existing mole, wart, or skin lesion can point to SCC. There may be an ulcer or a reddish skin plaque that grows very slowly, bleed occasionally (especially if located on the lip), have an ulcerated center with raised hard edges or have a pearly quality with tiny blood vessels. It is commonly present on sun-exposed areas (back of hands, lip, ears and scalp).



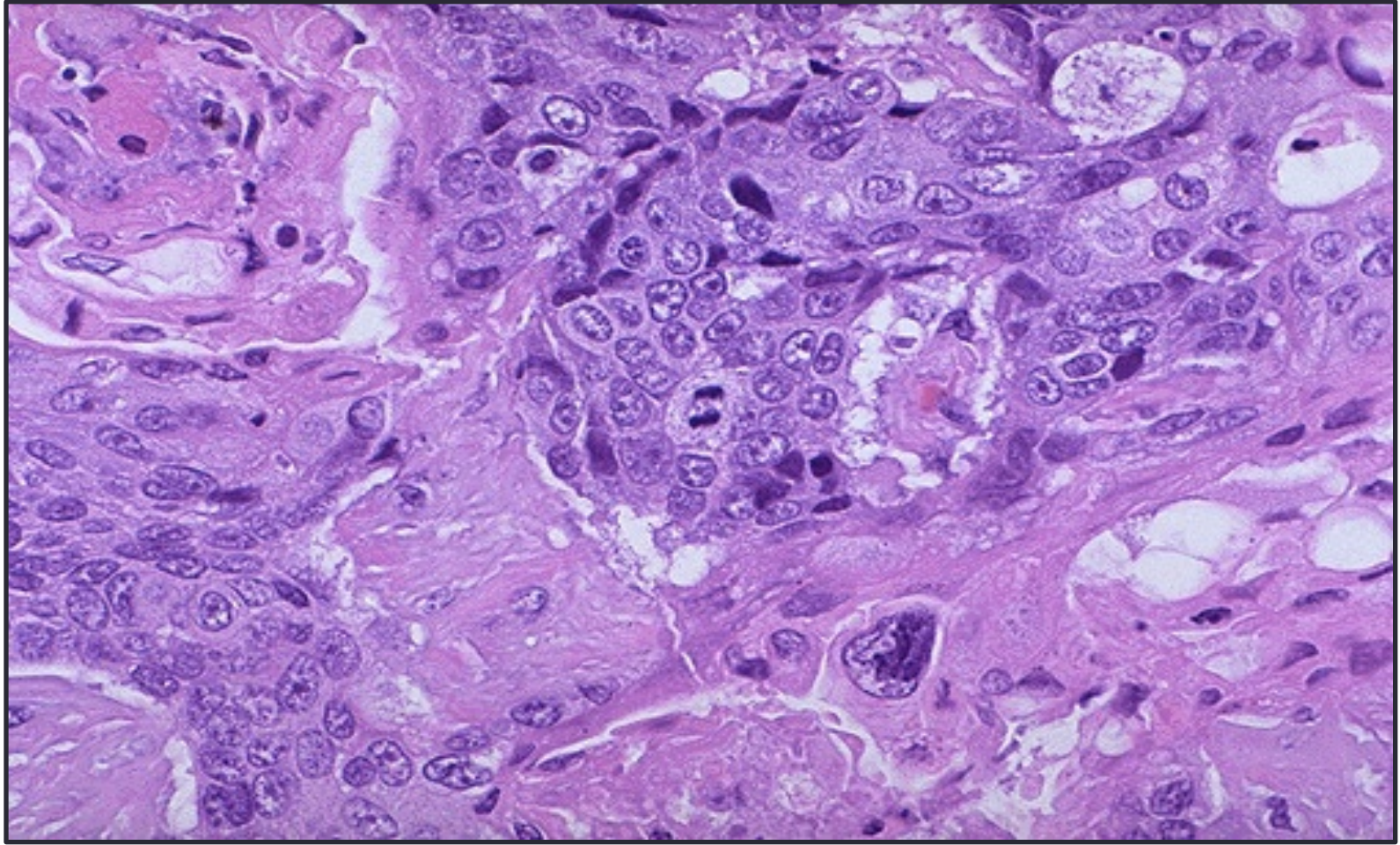
Squamous cell carcinoma – histopathology: The normal squamous epithelium at the right merges with the squamous cell carcinoma at the left, which is infiltrating downwards. The neoplastic squamous cells are still similar to the normal squamous cells, but are less orderly



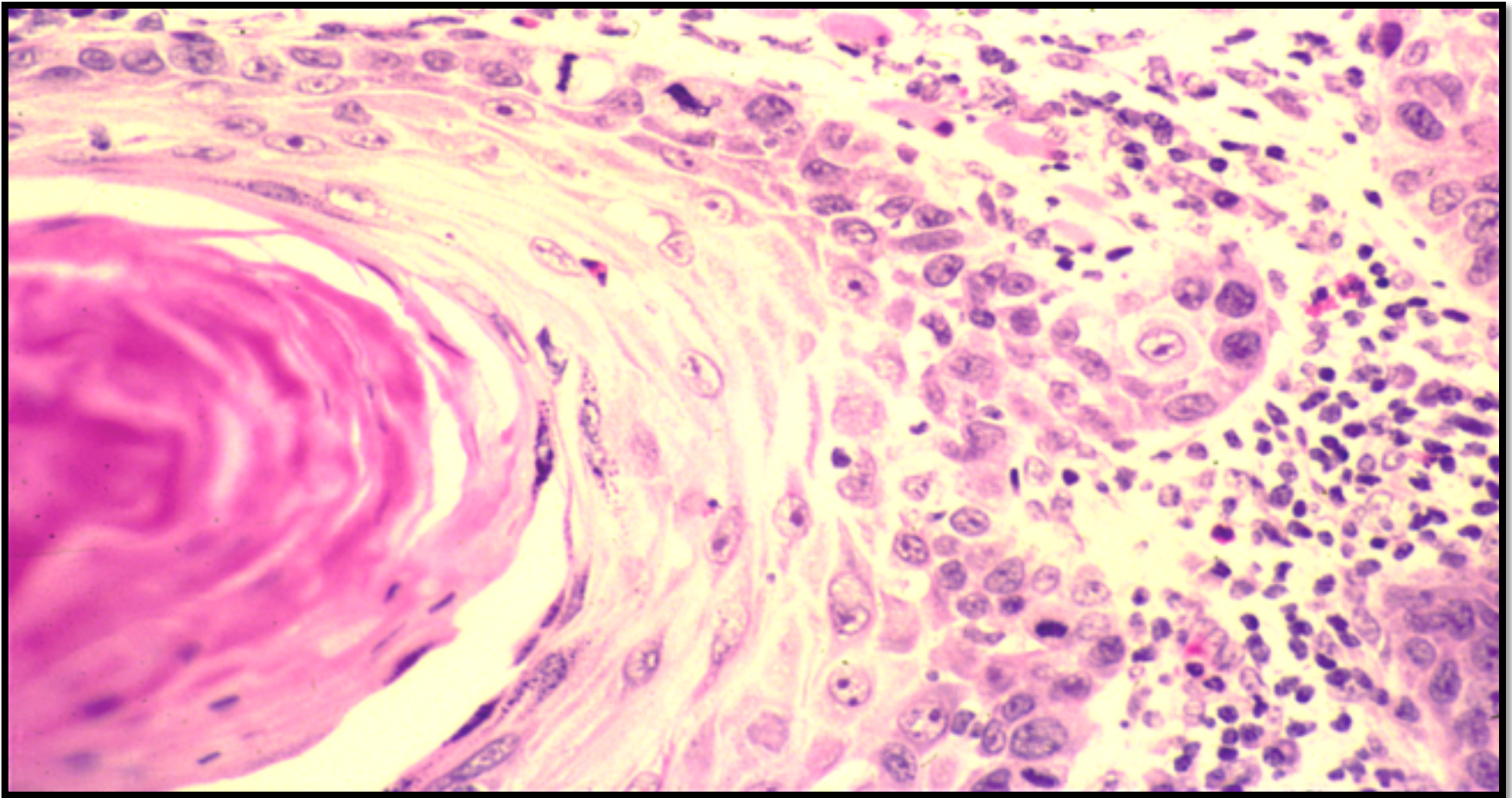
Squamous Cell Carcinoma – histopathology: Here is a moderately differentiated squamous cell carcinoma in which some, but not all, of the neoplastic cells are in nests and have pink cytoplasmic keratin.



Squamous cell carcinoma – high power field: At high magnification, this squamous cell carcinoma demonstrates enough differentiation to tell that the cells are of squamous origin. The cells are pink and polygonal in shape with intercellular bridges. The neoplastic cells show pleomorphism, with hyperchromatic nuclei. A mitotic figure is present near the center.



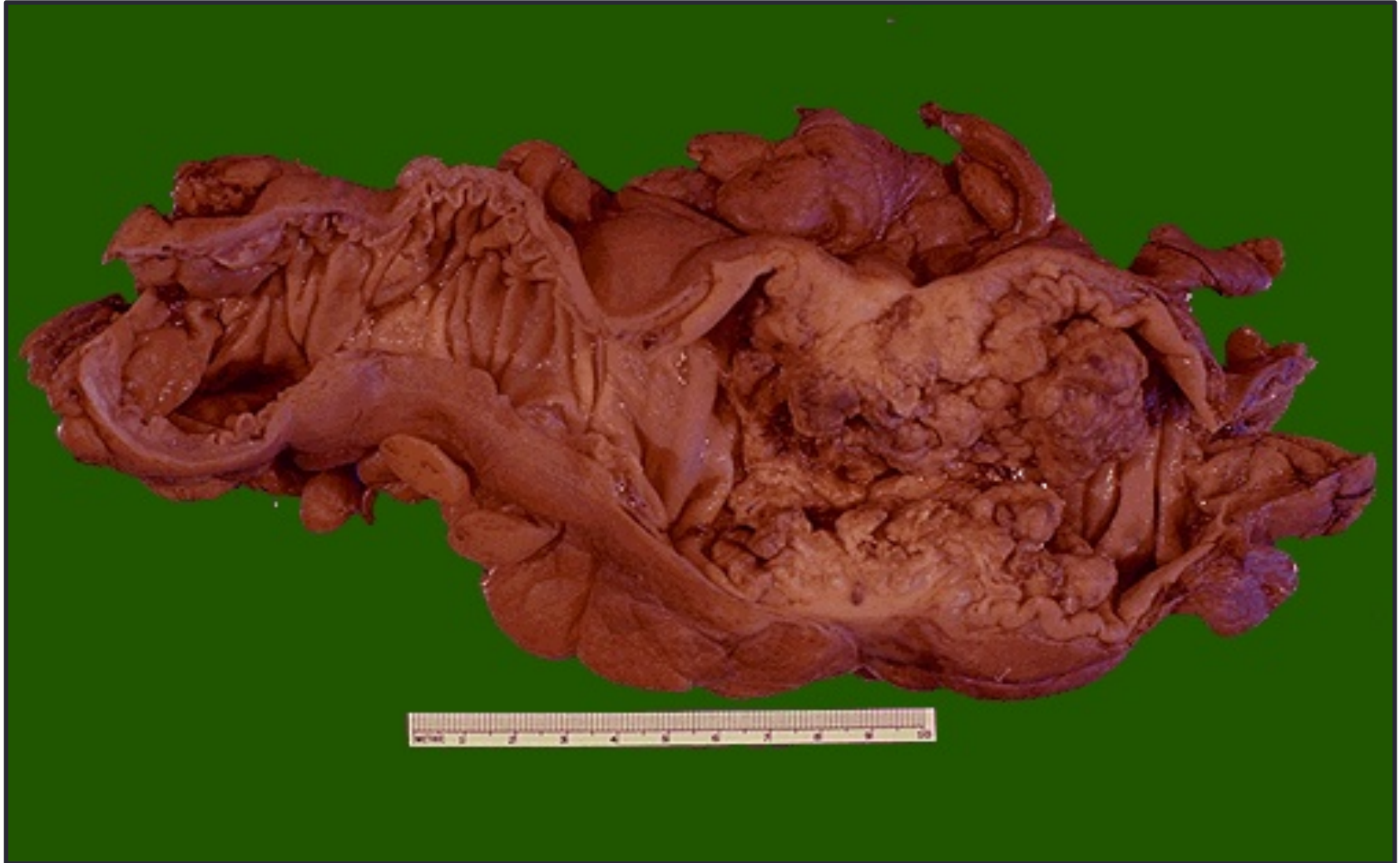Squamous cell carcinoma – high power field: A mitotic figure is seen in the center, surrounded by cells of a poorly differentiated squamous cell carcinoma, with pleomorphic cells that have minimal pink keratinization in their cytoplasm. In general, mitoses are more likely to be seen in malignant neoplasms.



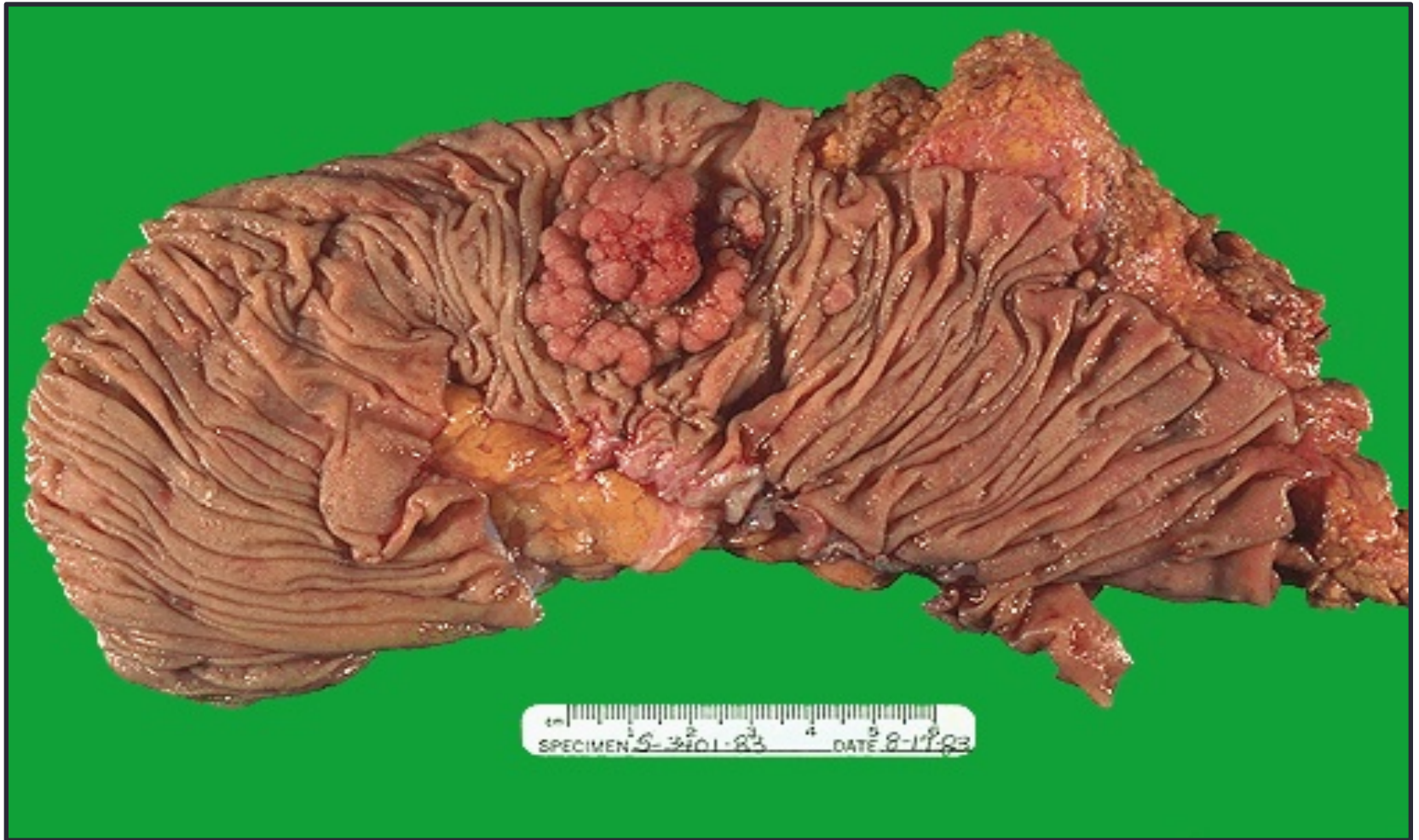
Squamous cell carcinoma – high power field: The dermis is infiltrated by masses of well differentiated neoplastic squamous cells separated by a fibrous tissue stroma with chronic inflammatory cells. Tumour cells show pleomorphism, hyperchromatism and many mitotic figures. Pinkish laminated keratin pearls (epithelial cell nests) are present in the center of some cell masses

CASE 2

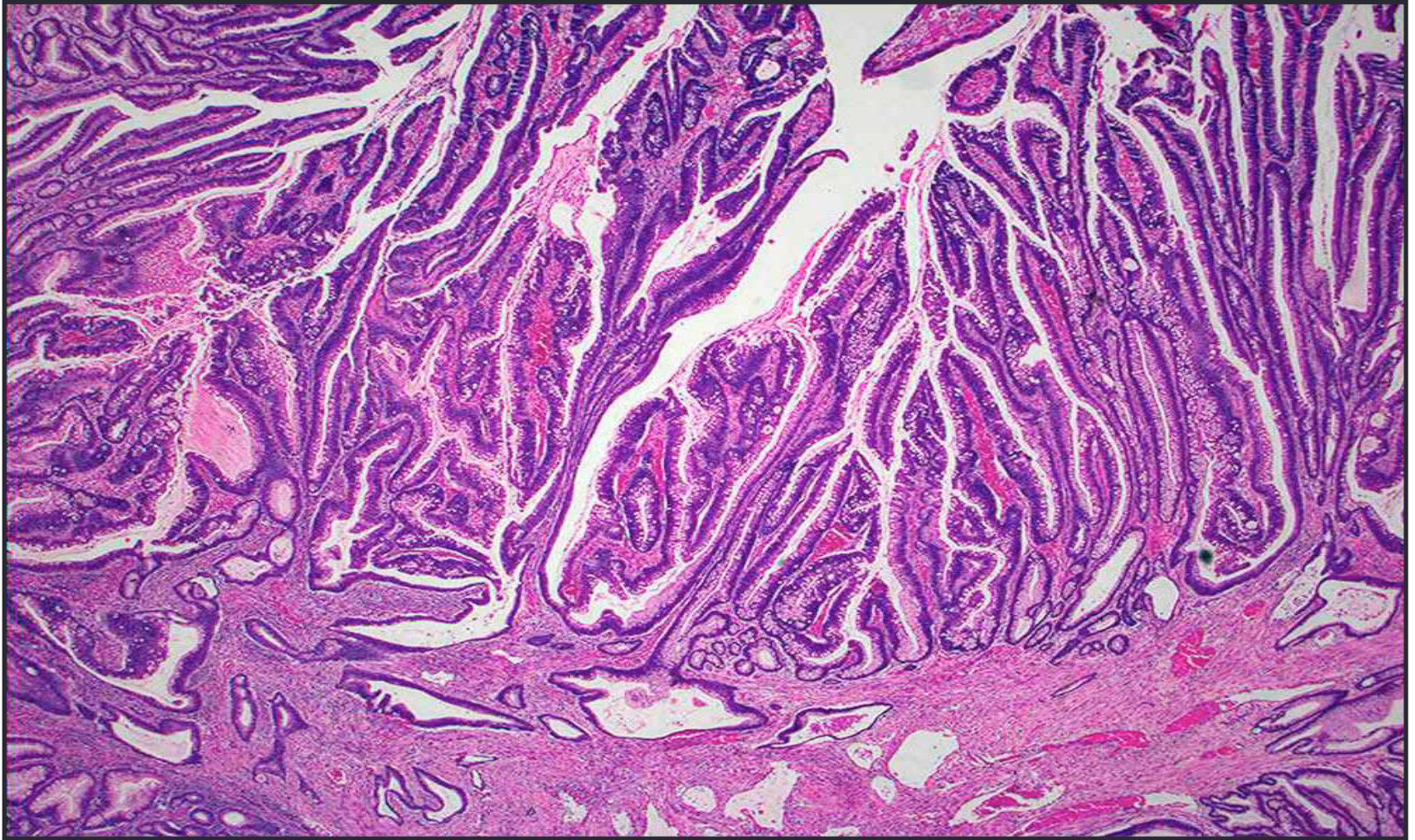
Adenocarcinoma of the large intestine



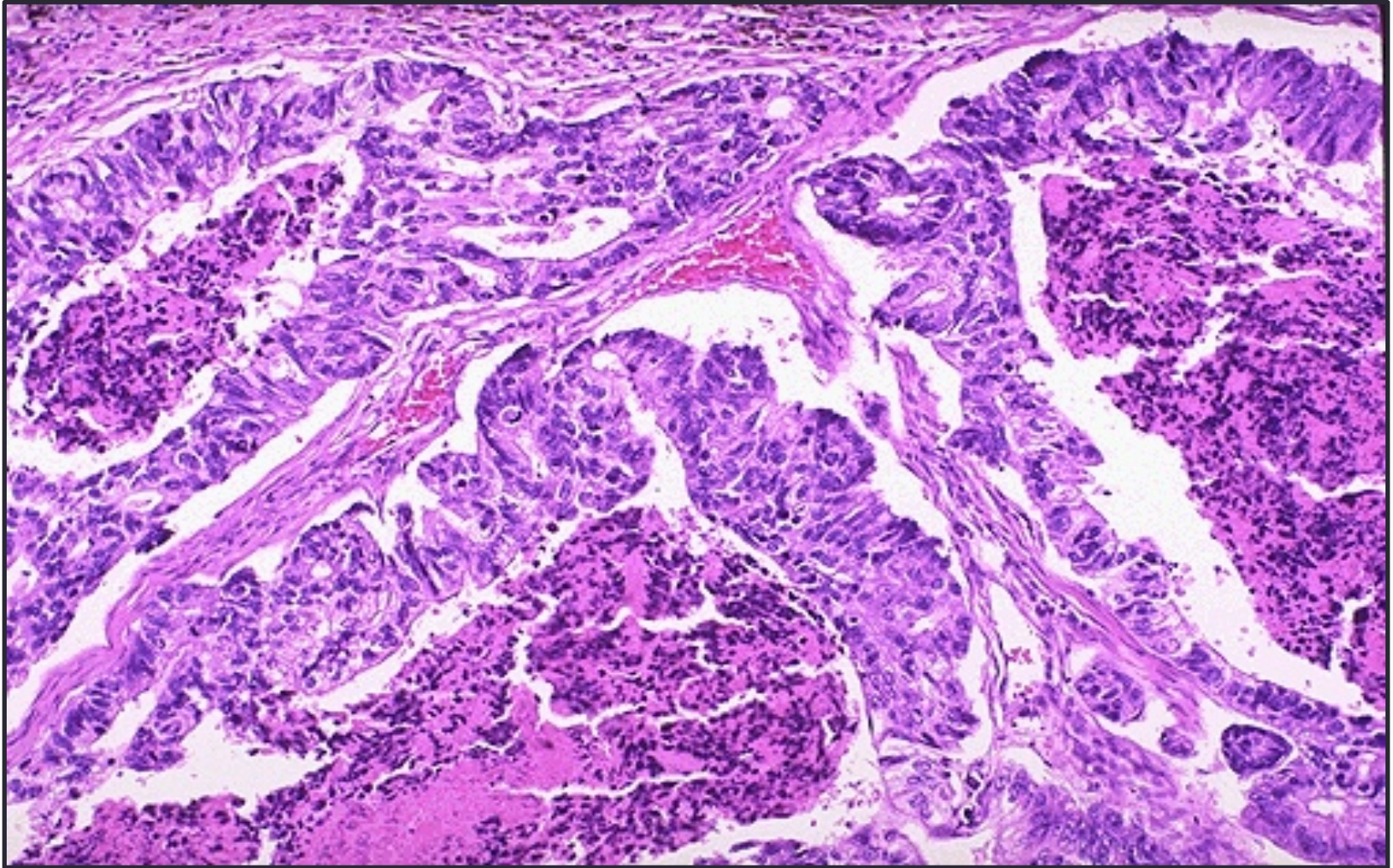
Adenocarcinoma of the colon: This cancer is more exophytic in its growth pattern. Thus, one of the complications of a carcinoma is obstruction (which is usually partial).



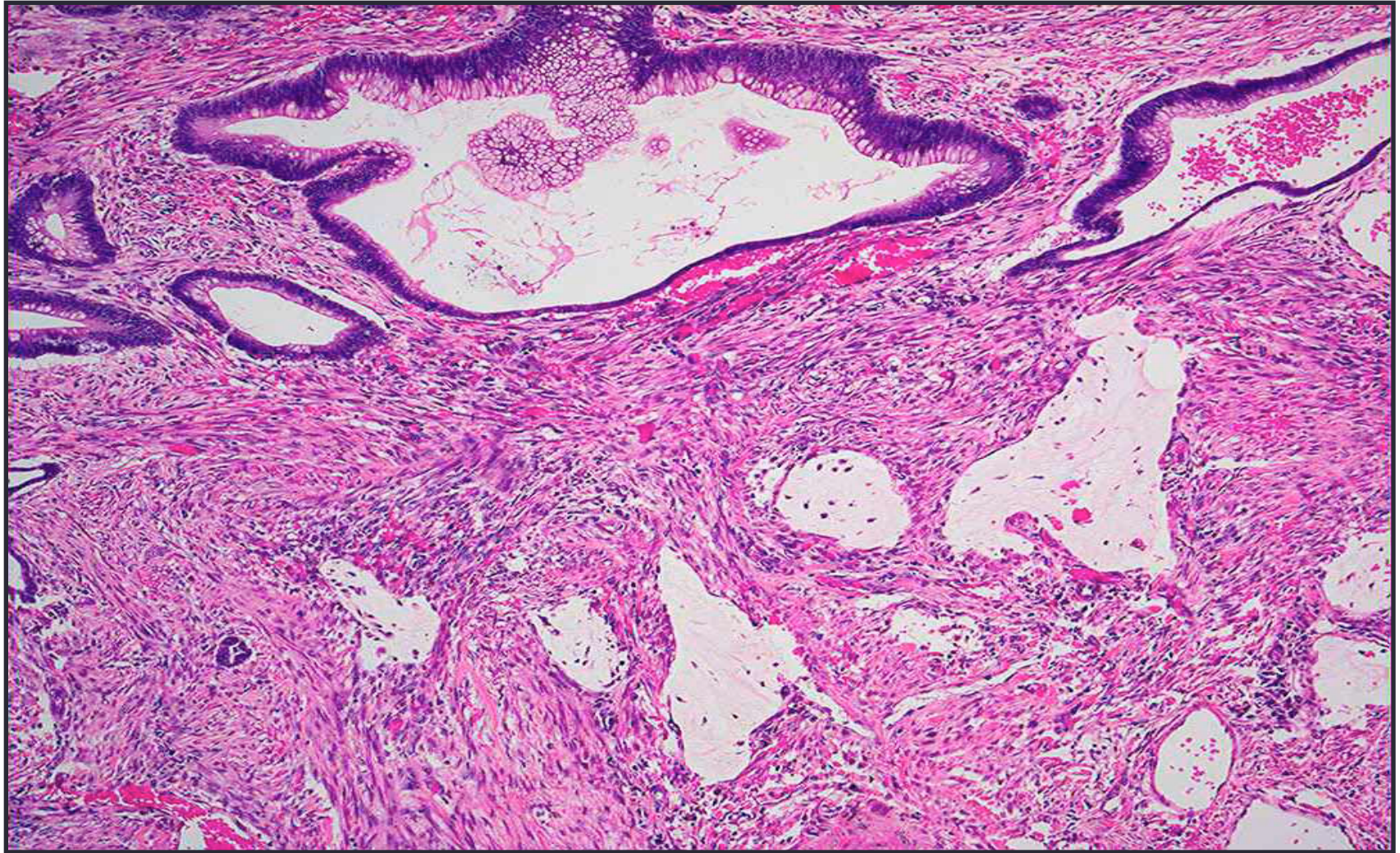
Adenocarcinoma of the colon: This is an adenocarcinoma arising in a villous adenoma. The surface of the neoplasm is polypoid and reddish pink. Hemorrhage from the surface of the tumor creates a positive guaiac stool test. This neoplasm was located in the sigmoid colon.



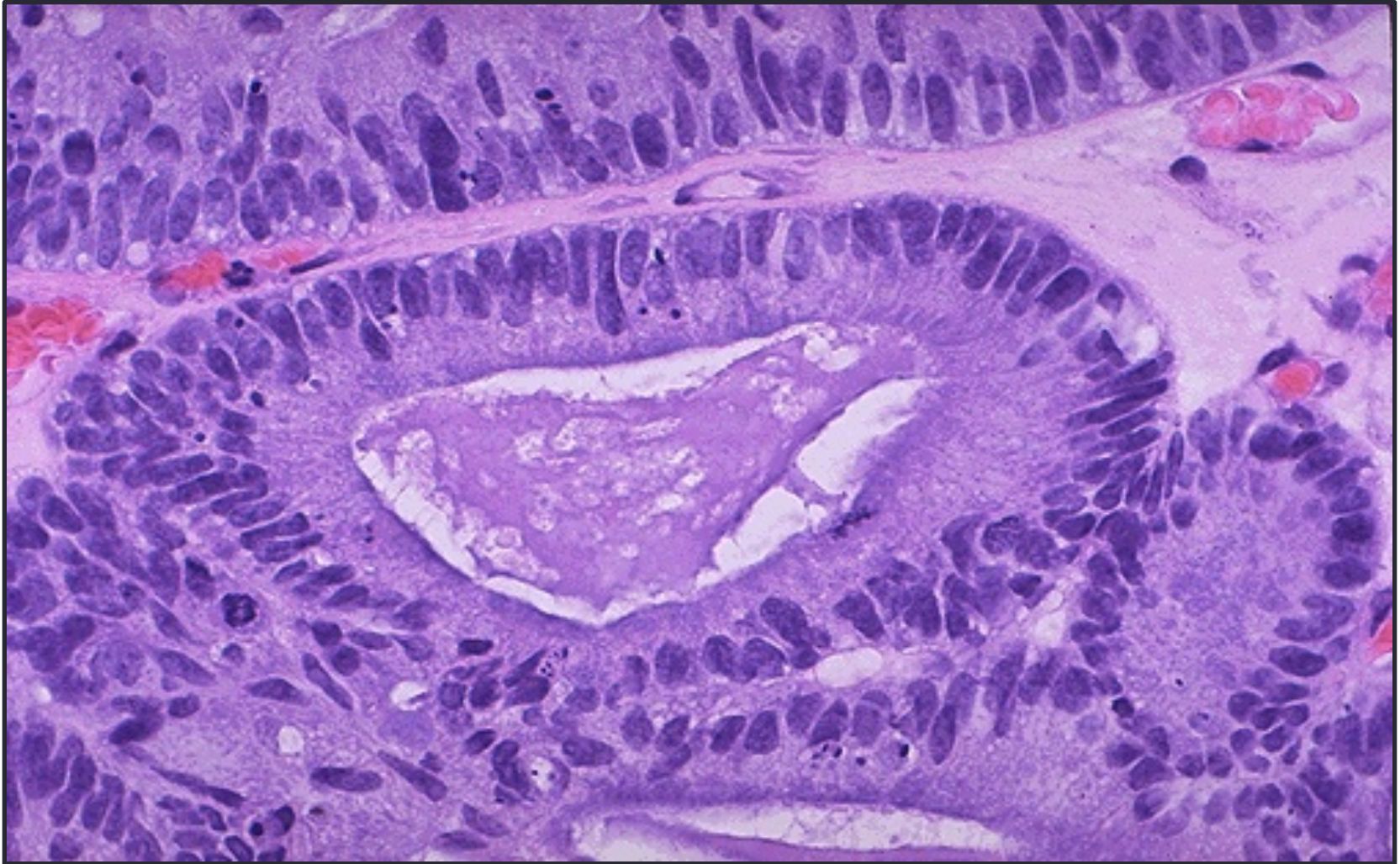
Adenocarcinoma of the colon: A moderately differentiated colonic adenocarcinoma. Tumour consists of crowded irregular malignant acini separated by thin fibrovascular stroma.



Adenocarcinoma of the colon – low power field: Here is an adenocarcinoma in which the glands are much larger and filled with necrotic debris.



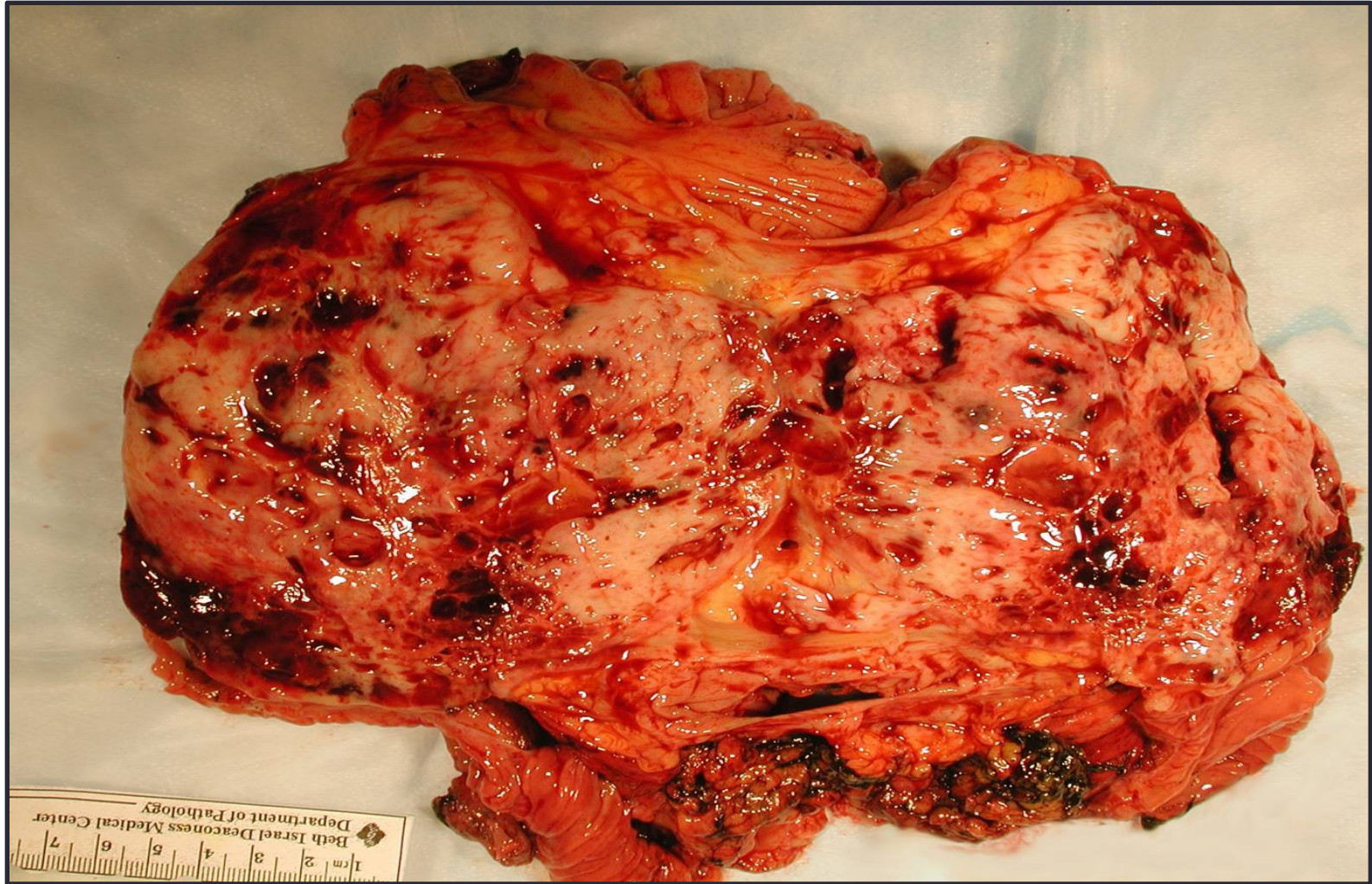
Adenocarcinoma of the colon – low power field: The acini are lined by one or several layers of neoplastic cells with papillary projection showing pleomorphism, hyperchromatism and few mitoses.



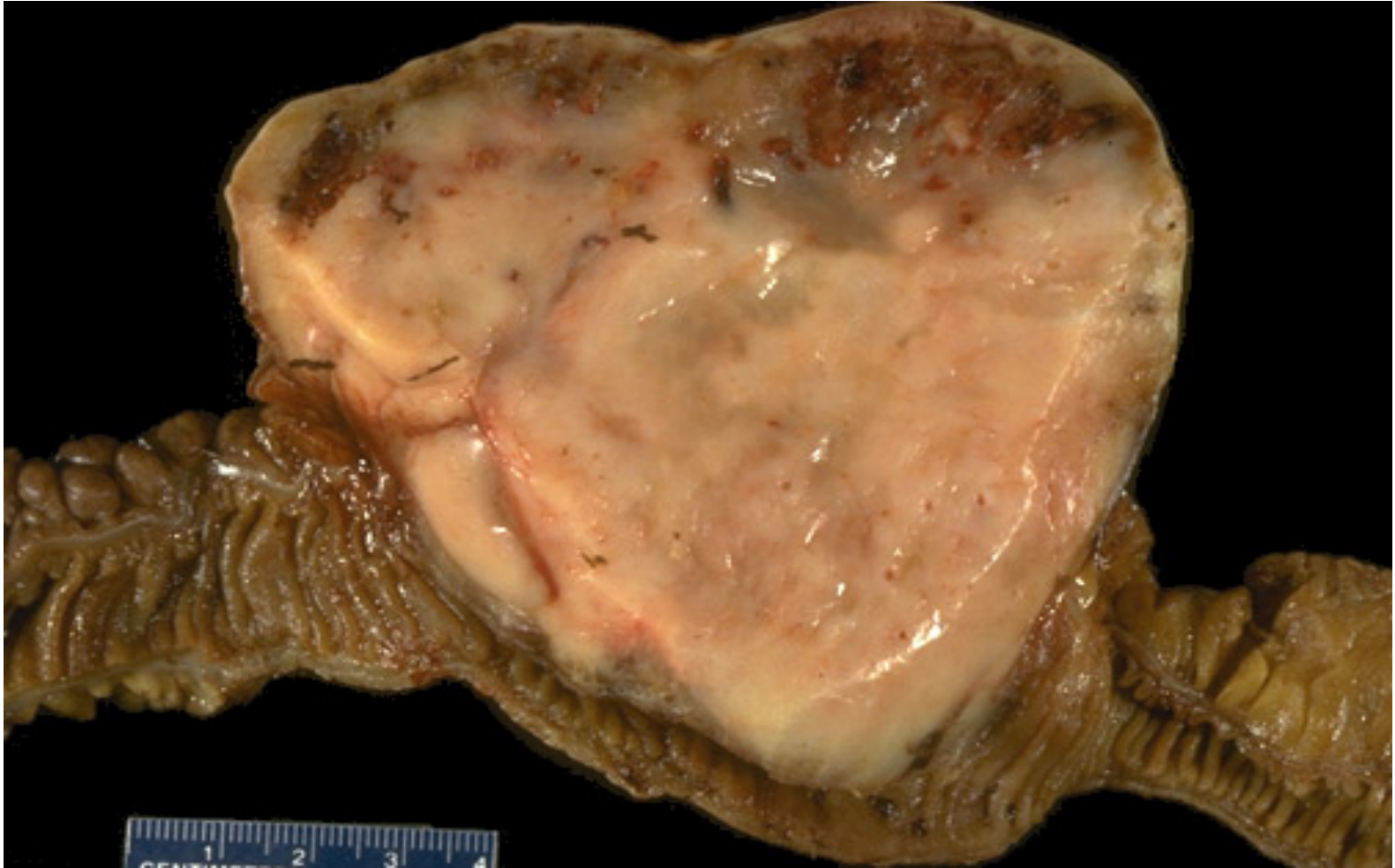
Adenocarcinoma of the colon – high power field: At high magnification, the neoplastic glands of adenocarcinoma have crowded nuclei with hyperchromatism and pleomorphism. No normal goblet cells are seen

CASE 3

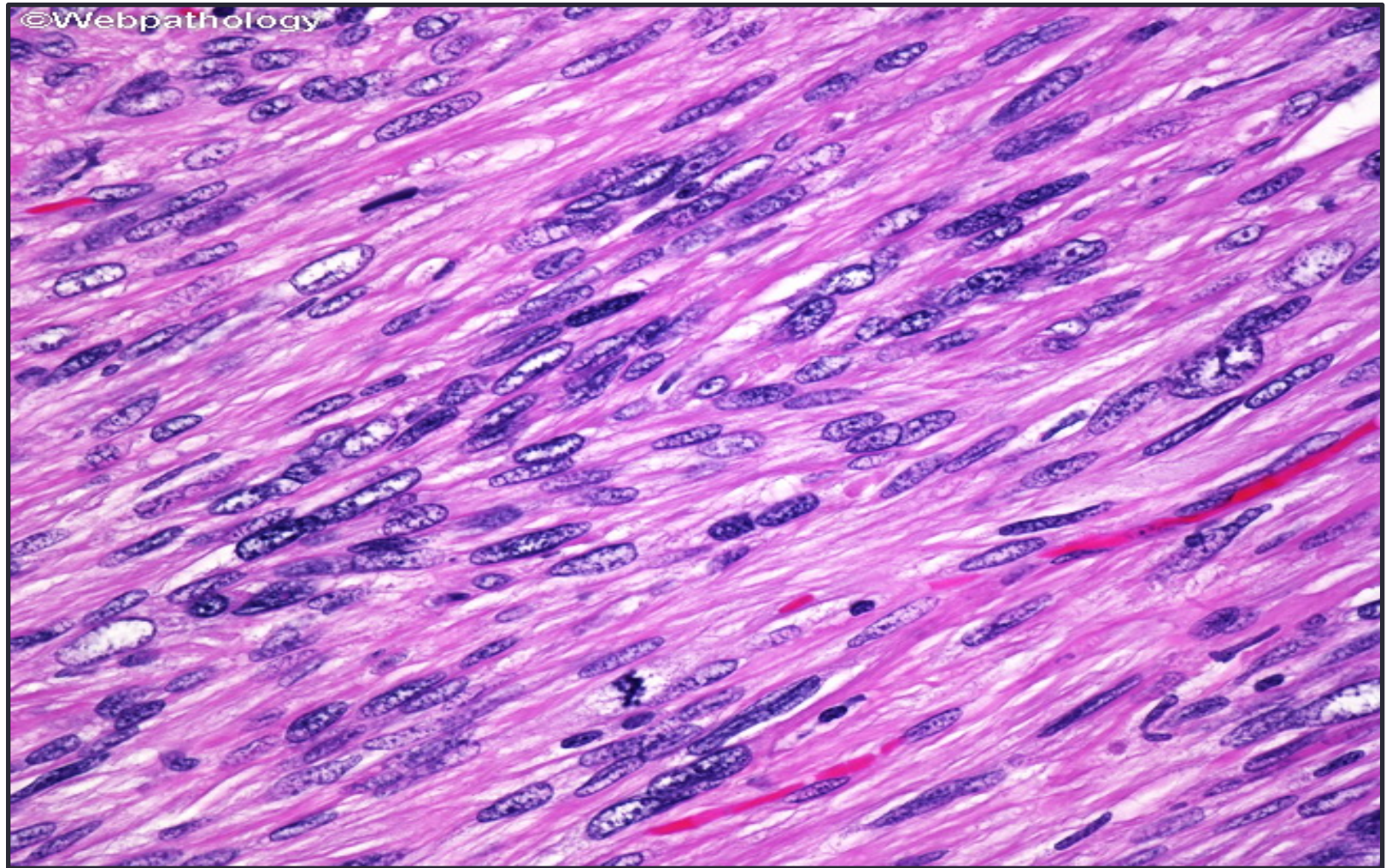
Leiomyosarcoma



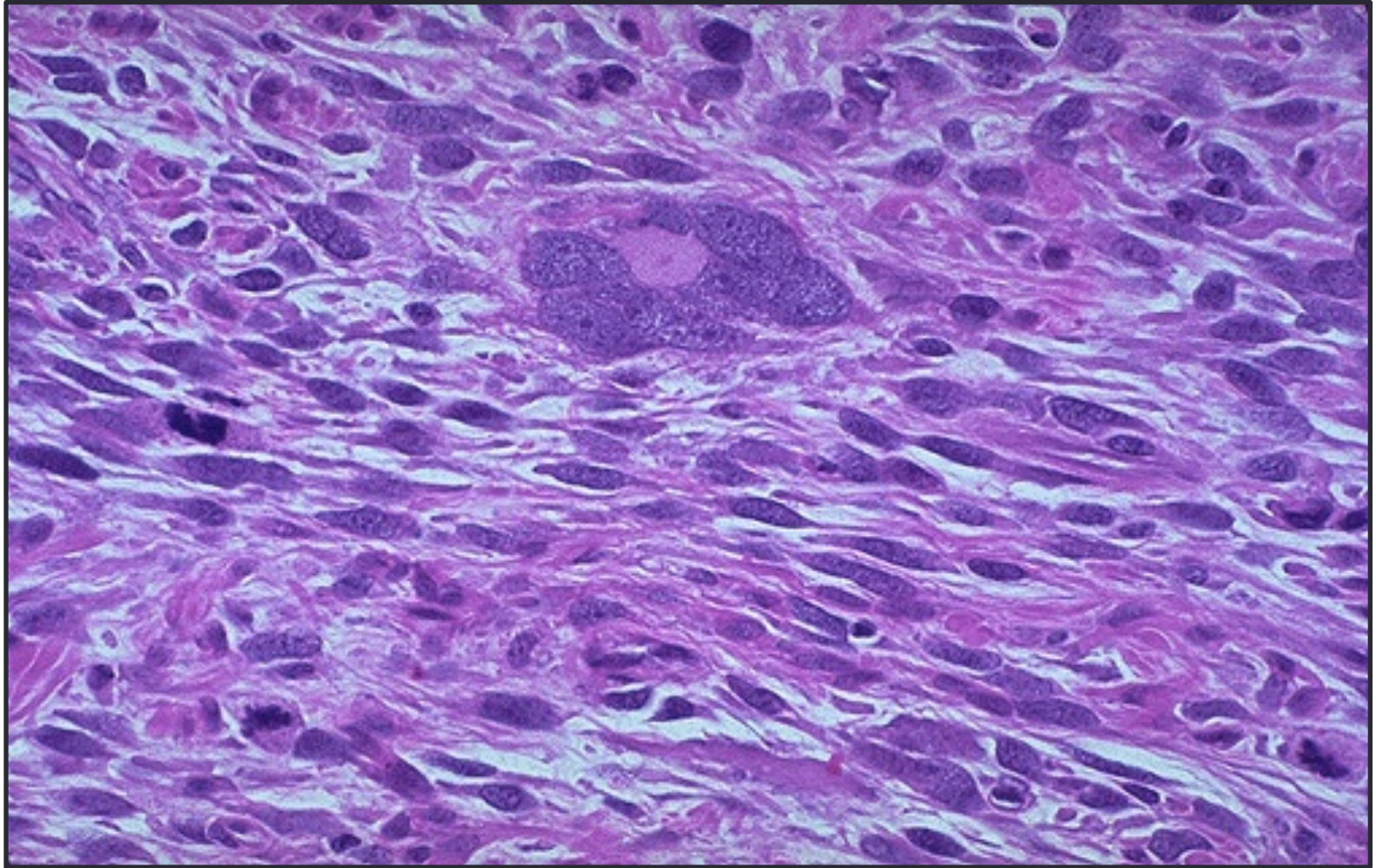
Leiomyosarcoma: Cut surface of this leiomyosarcoma shows an ill defined pale and soft large fleshy mass with hemorrhage and necrosis.



Leiomyosarcoma of small intestine: As with sarcomas in general, this one is big and bad. Sarcomas are uncommon at this site, but must be distinguished from other types of neoplasms.



Leiomyosarcoma – high power field microscopy: Marked atypia and cellularity with multiple mitoses present. Classic features of leiomyosarcoma include cigar shaped nuclei and arrangement of cells in fascicles.



Leiomyosarcoma of the uterus – high power field: Sarcomas, including leiomyosarcomas, often have very large bizarre giant cells along with the spindle cells. A couple of mitotic figures appear at the right and lower right sides of the picture.

END OF SESSION 2

Thank You